

Kyphosis, a rare cause of dysphagia

NIMIT GOYAL¹, RANJEET NARLAWAR², ANNE GARRETT³

¹Flat 102, Bradbury Court Apartments, Jubilee Road, Belfast BT9 7JL, UK

²Department of Radiology, Royal Liverpool Hospital, Prescot Street, Liverpool L7 8XP, UK

³Arrowe Park Hospital, Liverpool CH49 5PE, UK

Address correspondence to: N. Goyal. Fax: (+44) 28 9063 4807. Email: nimitgoyal@doctors.org.uk

Abstract

Degenerative kyphosis is mostly asymptomatic. When symptomatic, pain and humping of the back are the commonest features. Dysphagia associated with kyphosis is a rare presentation, though it is otherwise common in older people due to various reasons. We report the case of an 81-year-old kyphotic woman who presented with dysphagia. On barium swallow examination, she was found to have an acute bend in the mid-oesophagus leading to narrowing, secondary to the kyphosis.

Keywords: *kyphosis, dysphagia, barium swallow, elderly*

Case report

An 81-year-old woman was admitted to the medical ward for lower respiratory tract infection. Her past medical history included cardiac problems, kyphosis and long-standing dysphagia for both liquids and solids. To investigate the aetiology of dysphagia, a barium swallow was performed. In view of severe kyphosis, old age and weakness, the procedure was difficult to perform. When a bolus of barium was kept in her mouth and she was asked to swallow that, there was reflux into the mouth, instead of the barium going into the oesophagus. We had to adapt to the modified reclined position. The flow of barium till the mid-oesophagus was smooth; at this level there was a transient hold-up of the barium and the X-ray revealed that the oesophagus till this level was running horizontal to the ground. There was a 90° bend in the oesophagus here and the distal oesophagus ran perpendicular to this (Figure 1). Apart from this bend, there was no other abnormality.

Various treatment options were discussed with the patient, outlining the risks and benefits of any surgical intervention especially in view of her cardiac history. A decision in favour of conservative management was thought to be in the best interests of the patient.

Discussion

To variable degrees kyphosis is a common problem in geriatric patients. It occurs as a result of osteoporosis resulting in wedging and collapse of vertebral bodies. Usual consequences are humping of the back, loss of height,

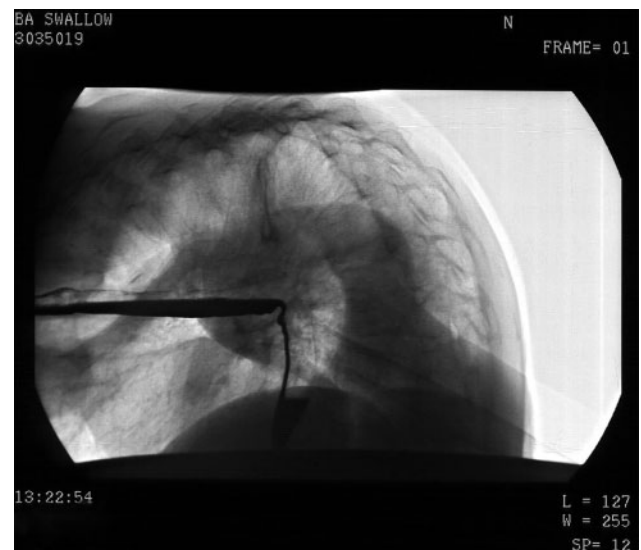


Figure 1. Lateral view of the barium swallow shows that the proximal oesophagus is completely horizontal to the ground and the distal oesophagus is perpendicular to it. Note the severe kyphosis of the spine.

pain in the back and referred spinal nerve root pain. Mechanical obstruction of the oesophagus resulting in dysphagia has not been described as a complication of severe kyphosis.

A similar case report described oesophageal atony as a complication of kyphosis resulting in dysphagia [1]. A case

of compression of the oesophagus between the spine and aorta has been reported as a consequence of untreated scoliosis [2]. Riley Day syndrome has been described in patients with familial dysautonomia, where there is a spinal defect and dysphagia results due to neurological involvement [3]. Cases of corrective surgery of the spine and halo suspension traction causing dysphagia due to hypoglossal nerve injury have also been reported [4].

Dysphagia is frequently seen in older patients and may be due to a variety of reasons. Physiological changes in oesophageal peristalsis where swallowing is followed by non-peristaltic tertiary waves instead of secondary contraction occur with age, causing dysphagia, and this has been termed presbyoesophagus [5]. Mechanical obstruction may result from causes within or outside the oesophagus.

A barium swallow is the investigation of choice for clearly depicting the level and cause of obstruction, though performing it can be quite challenging. Kyphosis and scoliosis promote reflux because of pressure on the stomach while reducing the vital capacity required for coughing and disrupting respiratory coordination. Slight reclining not only puts the head in a better position but also diminishes the pressure on the stomach while increasing respiratory support. A CT scan may be indicated for staging purposes if malignancy is suspected. Management of such cases would depend on age and comorbidity of the patient. Corrective surgery may be considered in physiologically younger patients. In a higher risk category, conservative management would include a puree diet and postural change during feeds.

Key points

- Kyphosis and dysphagia are common in the elderly.
 - Kyphosis can be a rare cause of dysphagia.
 - Barium swallow is the appropriate initial investigation.
-

Sources of funding

None.

Conflicts of interest

None.

References

1. Casati A. Senile dysphagia due to cervicodorsal kyphosis with esophageal atony. *G Gerontol* 1959; 7: 725–8.
2. Bar-On E, Harari M, Floman Y, Bar-Ziv J, Maayan C. Compression of the esophagus by the spine and the aorta in untreated scoliosis. *Arch Orthop Trauma Surg* 1998; 117: 405–7.
3. Ganz SB, Levine DB, Axelrod FB, Kahanovitz N. Physical therapy management of familial dysautonomia. *Phys Ther* 1983; 63: 1121–4.
4. Ginsburg GM, Bassett GS. Hypoglossal nerve injury caused by halo-suspension traction. A case report. *Spine* 1998; 23: 1490–3.
5. DeVault KR. Presbyesophagus: a reappraisal. *Curr Gastroenterol Rep* 2002; 4: 193–9.

Received 30 April 2005; accepted 12 May 2005

Non-fatal haemophagocytic syndrome in an elderly patient

ROY L. SOIZA¹, SHARMISTHA GHOSH¹, J. KENNETH McALPINE¹, MARK A. VICKERS²

¹Department of Medicine for the Elderly, Woodend Hospital, Aberdeen AB15 6LS, UK

²School of Medicine, University of Aberdeen, Aberdeen AB24 3FX, UK

Address correspondence to: R. L. Soiza. Email: roysoiza@doctors.org.uk

Abstract

A frail 78-year-old man presented with lethargy, fever, splenomegaly and pancytopenia. Bone marrow aspirate showed marked haemophagocytosis. A diagnosis of haemophagocytic syndrome secondary to diffuse splenic large B-cell lymphoma was eventually made. Treatment with laparoscopic splenectomy was successful. Secondary haemophagocytic