

REVIEWS

Movement disorders after stroke

ALEXANDRA HANDLEY, PIPPA MEDCALF, KATE HELLIER, DIPANKAR DUTTA

Gloucestershire Royal Hospital, Great Western Road, Gloucester GL1 3NN, UK

Address correspondence to: D. Dutta. Tel: (+44) 8454 226321; Fax: (+44) 8454 226326; Email: dipankar.dutta@glos.nhs.uk

Abstract

Many different types of hyperkinetic and hypokinetic movement disorders have been reported after ischaemic and haemorrhagic stroke. We searched the Medline database from 1966 to February 2008, retrieving 2942 articles from which 156 relevant case reports, case series and review articles were identified. The papers were then further reviewed and filtered and secondary references found. Here we review the different types of abnormal movements reported with anatomical correlation, epidemiology, treatment and prognosis. Post stroke movement disorders can present acutely or as a delayed sequel. They can be hyperkinetic (most commonly hemichorea-hemiballism) or hypokinetic (most commonly vascular parkinsonism). Most are caused by lesions in the basal ganglia or thalamus but can occur with strokes at many different locations in the motor circuit. Many are self limiting but treatment may be required for symptom control.

Keywords: stroke, chorea, hemiballismus, dystonia, parkinsonism, elderly

Introduction

Movement disorders are a recognised complication of stroke. Many different types of hyperkinetic and hypokinetic movement disorders have been reported and can be seen after ischaemic and haemorrhagic stroke [1]. Dystonia [2, 3–5, 6–8, 9–11, 12–14], chorea with or without hemiballismus [12, 14–17, 18, 19, 20, 21], tremor [13, 14, 23, 24, 25, 26, 27–29] parkinsonism [12, 20, 30, 31, 32–34], segmental or focal myoclonus [1, 14, 20, 21], athetosis, pseudoathetosis [14, 35] and asterixis [1, 21, 36] have all been described and occur at presentation of the stroke [20, 21, 37], in the delayed setting [2, 5, 14, 21, 37] or as a progressive condition [2, 14]. Transient dyskinesias or ‘limb shaking’ spells have been described as a symptom of transient ischaemic attacks [1, 38, 39].

Current knowledge is based on individual case reports, small case series and extracts from stroke registries. This article reviews the different types of abnormal movements with anatomical correlation, epidemiology, treatment and prognosis.

Definitions

Hemichorea—unilateral, rapid involuntary motions of flexion and extension, rotation or crossing, which may involve all body parts, but predominantly distal parts [1, 41].

Hemiballismus (hemiballism)—severe, violent, arrhythmic and large amplitude excursion of a limb from a proximal joint with an element of rotation [1, 41].

Dystonia—a syndrome characterised by prolonged muscle contractions causing sustained twisting movements and abnormal postures of the affected body part(s) [1, 6].

Tremor—rapid rhythmic oscillation generally of the hands [40].

Myoclonus—sudden, involuntary jerking of a single muscle or a group of muscles [41].

Athetosis—slow, sinuous, writhing movements affecting mainly the hands and feet [41].

Pseudoathetosis—abnormal writhing movements, usually of the fingers, caused by a failure of joint position sense (proprioception) [14, 42].

Asterixis—failure to sustain muscle contraction during postures with intermittent, generally arrhythmic lapses in muscle tone [41].

Parkinsonism—triad of bradykinesia, increased tone and tremor.

Movement disorders can be unilateral, bilateral, focal (affecting a single part of the body) or segmental (affecting two or more adjacent parts of the body).

Search strategy and selection criteria

We searched the Medline database from 1966 to February 2008 with the following terms: stroke and/or cerebrovascular

disease, movement disorder, hemiballismus (hemiballism), hyperkinesia, chorea, dystonia, myoclonus, parkinsonism, tics, tremor, athetosis, transient shaking limb and asterixis.

A total of 2,942 articles were retrieved and the titles and abstracts were reviewed. If the article was not in English it was discounted. From our review of the titles and abstracts, we identified 156 papers comprising case reports, series and review articles. These were further reviewed and filtered and their references were searched for secondary references. Reviewing and filtering was performed by two reviewers (AH and DD) and differences in opinion resolved by a third reviewer (PM). Articles were used if they included stroke patients with abnormal movements, and the focus of the study was to describe the abnormal movement, its anatomical lesion, epidemiology, pathophysiology, prognosis or treatment.

Frequency and prevalence

The frequency of post-stroke abnormal movements is unclear. Most reports are of isolated cases or relatively small series of cases compiled retrospectively from stroke registries. In a study of 56 patients with post-stroke abnormal movements, 3.7% of 1,500 stroke patients developed a movement disorder [20]. A review of the hospital based Lausanne Stroke Registry identified a prevalence of 1% and an estimated incidence of 0.08% per year [21]. Hemichorea was the most common movement disorder in the first case series [20] while hemichorea–hemiballism was most common in the second [21]. Dystonia was the next most common movement disorder [20, 21].

Temporal relationship

The time scale to develop a movement disorder varies considerably from the day of onset to several years after the stroke and also depends on the type of movement disorder [5, 14, 20, 21]. Chorea presented earlier (mean 4.3 days post-stroke) in one series and parkinsonism much later (mean 117.5 days post-stroke) [20]. However, there is a wide variability within each movement disorder; the delay in developing dystonia after stroke can be anything from 1 day to 5 years [5].

The delay between the stroke and the onset of the abnormal movement may reflect time required for the partial recovery of motor function and development of pathological circuitry [14].

Demography and risk factors

Abnormal movements following stroke occur in men and women equally [14, 20, 21]. Alarcon's study found an average age of 63.3 (range 17–90) [20]. The Lausanne stroke registry identified 29 patients with abnormal movements and found a mean age of 70 (range 32–90) [21]. In a study of delayed onset movement disorders in 35 patients after thalamic infarction, the mean age was 57.5 (range 28–74) [14]. The age of predilection for different movement disorders varies;

chorea affects older people while patients who develop dystonia are younger [2, 20].

Anatomy, type of stroke and lesion location

A number of different locations within the brain have been identified as areas that result in abnormal movements when affected by stroke. The basal ganglia are most often implicated in post-stroke movement disorders.

A simplified model of basal ganglia circuitry is shown in Figure 1. The basic function of the pathways is to act as a cortical feedback loop in which signals from the neo-cortex are relayed through the striatum, pallidum and thalamus back to the cortex. The cortex sends excitatory inputs to the striatum; the striatum inhibits the pallidum which in turn inhibits the thalamus [43]. The net effect of cortical activity is to trigger the striatum to release the thalamus from pallidal inhibition, thus allowing thalamic outputs to excite the cortex [43]. These direct pathways are modulated by other loops from the substantia nigra (dopaminergic) and subthalamic nucleus. At rest, neurones in the striatum are quiescent and those in the pallidum are active, thereby inhibiting the thalamic excitation of the motor cortex. Before and during a movement, the striatum becomes active and inhibits the pallidum, allowing more excitation of the motor thalamic nuclei and cortex [43]. Interruption of direct or indirect pathways by focal lesions may lead to movement disorders. However, there are no specific sites or arterial territories for any given dyskinesia and lesions in different parts of the motor pathways may be responsible for the same movement disorder [1, 21]. Figure 2 shows a drawing of a horizontal section of the cerebrum at the level of the insula showing the major grey and white matter structures and their blood supply [43, 44].

Small vessel disease, with small deep infarcts, was the most common sub-type of stroke leading to abnormal movements [20, 21]. In Alarcon's study, patients with deep lesions in the basal ganglia, thalamus and brain stem, who developed abnormal movements, had significantly more haemorrhages compared to controls [20]. Large and medium vessel atherothrombosis and cardiac embolism are other potential causes of strokes leading to abnormal movements [14, 20]. A case-control study of 35 patients with delayed onset dyskinesias after thalamic stroke found that 62.9% of patients had haemorrhagic strokes [14] while a cohort study of 27 patients with hemiballismus found that all the patients had infarcts [45].

Table 1 summarises the principle abnormal movements, associated lesions and drug treatments (see treatment below).

Several broad conclusions can be drawn: lenticular lesions are the most common lesions that result in dystonia [2, 7, 12, 20, 35, 46] and chorea \pm hemiballismus [15]. Lesions in the posterior thalamus or lesions disrupting the dentatorubrothalamic pathway are the most common causes of tremor [24, 25]. Parkinsonism after stroke is associated with lesions in the basal ganglia (mainly striatum or lentiform nucleus) which can be unilateral or bilateral [20, 33, 34, 47].

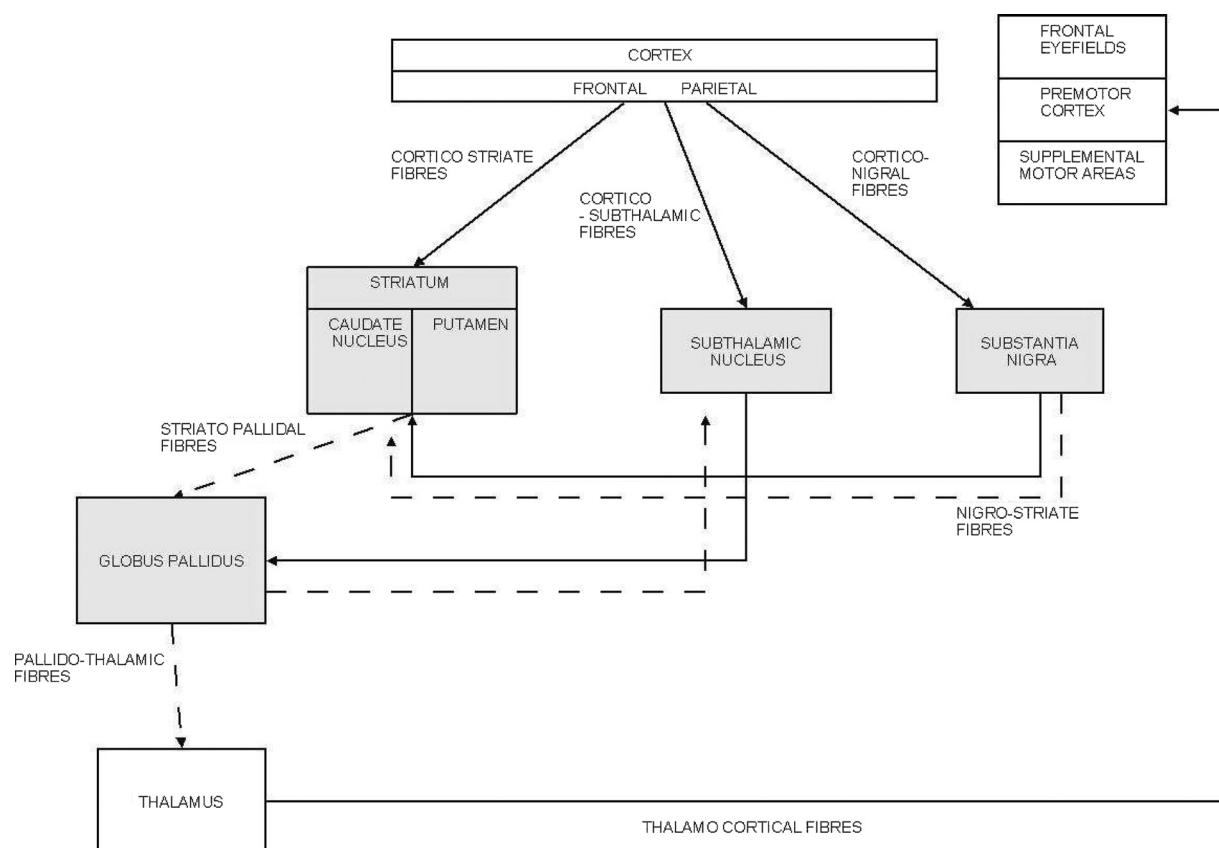


Figure 1. Schematic, simplified diagram of the connections of the basal ganglia. Stimulatory pathways are shown in unbroken lines and inhibitory pathways in broken lines.

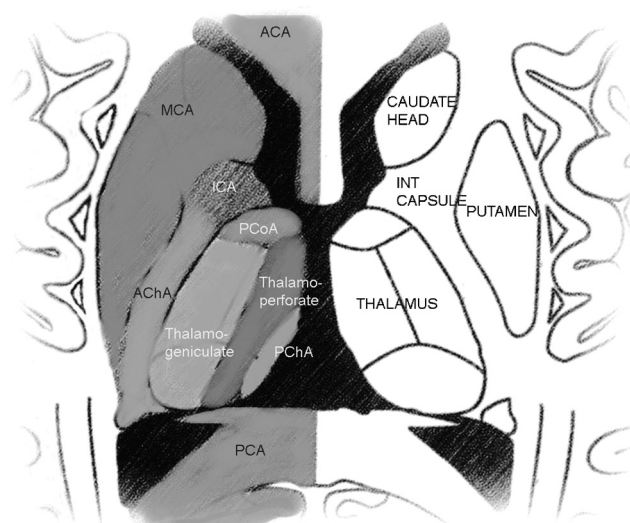


Figure 2. A drawing of a horizontal section of the cerebrum at the level of the insula showing the major grey and white matter structures and their blood supply. *ACA*: anterior cerebral artery (leptomeningeal branches); *MCA*: middle cerebral artery (lenticulo-striate branches); *ICA*: internal carotid artery (perforating branches); *PCoA*: posterior communicating artery (perforating branches); *AChA*: anterior choroidal artery; *thalamo-perforate* arteries: branches of the posterior cerebral artery; *PChA*: posterior choroidal artery; *PCA*: posterior cerebral artery (modified with permission from figure 29.8 in [44], p. 392).

Nature of abnormal movements and other associated stroke features

Patients who go on to develop abnormal movements after a stroke usually have motor dysfunction at presentation [14, 20, 21, 25]. The motor deficit tends to have improved by the time the abnormal movement develops [2, 14, 48].

There is variation in the presence of sensory involvement at the onset of the stroke. Sensory loss, which is often severe, has been described and often includes at least moderate position sense deficit [14, 25, 49]. Others have reported that sensory deficit is rarely present [2, 21]. In a case series of thalamic strokes, there were significantly more severe sensory deficits and ataxia in the abnormal movement group compared to controls [14]. It is postulated that the loss of proprioceptive inputs to multiple joint movements may cause impaired synergic stabilisation resulting in the abnormal movement [14].

Additional symptoms that have been described in case reports include somnolence, confusion, abulia, disinhibition, visual agnosia, visual hallucinations, visual field defects, dysphasia, dysarthria and corticobulbar signs [12, 14, 20, 21]. Kim reported nine patients with anterior cerebral artery strokes leading to abnormal movements and identified apathy in eight and mutism, stuttering speech, dysarthria and aphasia to variable degrees in all the patients [48].

Table 1. Abnormal movements, lesion localisation and pharmacotherapy options

Abnormal movement	Lesion localisation	Pharmacotherapy options
Hemichorea ± hemiballism	Caudate and putamen	Typical neuroleptics—haloperidol, pimozide, perphenazine, fluphenazine
	Basal ganglia	
	Putamen	Atypical anti-psychotics—olanzapine, quetiapine, sulpiride, clozapine
	Caudate	
	Thalamus and subthalamus	
	Posterior limb of internal capsule	Tetrabenazine, reserpine
	Corona radiata	
	Frontal or parietal lobe	Clonazepam
	External capsule	
	Pons	Sodium valproate
Dystonia	Temporal cortex	
	Thalamus	Botulinum toxin
	Caudate nucleus	Clonazepam, diazepam
	Putamen	
	Globus pallidus	Baclofen
	Parieto-occipital	
	Striatum	Benzhexol, trihexyphenidyl
	Internal capsule	
	Frontal infarcts	Tetrabenazine
	Pons	
Tremor	Caudate nucleus	Clonazepam
	Thalamus	
	Subthalamic infarcts	Sodium valproate
	Striatum	
	Frontal infarcts	
	Parietal infarcts	
	Cerebellum	
	Brainstem	
	Thalamus	No recommendations (self-limiting)
	Fronto-parietal cortex	
Myoclonus	Basal ganglia	
	Cerebellum	
	Brainstem	
	Midbrain	
	Pons	First line—clonazepam, sodium valproate
	Thalamus	
	Basal ganglia	Others—levetiracetam, piracetam, primidone, acetazolamide
	Rarely reported in isolation	
	Parietal lobe	See hemichorea/hemiballism above
	Thalamus	
Athetosis	Brainstem	No recommendations
Pseudoathetosis		

While post-stroke dyskinesias are often reported as pure movement disorders, they can be variable, encompass several components and difficult to classify [14, 21, 24] Chorea and hemiballismus may be part of the same spectrum of disease; the term hemichorea–hemiballism is used to reflect this [1]. Athetosis and sometimes dystonia may also be combined with hemichorea–hemiballism [1].

Dystonia can involve the ipsilateral face, arm and leg (hemidystonia) or can be segmental or focal [1, 2, 14, 20, 21]. Focal dystonia can affect the hand (most commonly), foot, facial or lingual muscles [14, 20]. Dystonia can be associated with abnormal movements such as jerks (dystonic myoclonus), tremor like (dystonic tremor) or athetoid movements [1, 8, 9]. The abnormal twisting movements of dystonia are caused by co-contraction of agonist and antagonist muscles and voluntary movement worsens this [49]. In contrast to post-stroke spasticity, which is associated

with muscle weakness and increased inhibitory impulses, dystonia is associated with muscle overactivity caused by reduced inhibition at many levels of the motor system [49].

Tremor has been observed to occur most commonly in a multifocal or segmental distribution. Most studies have found that the tremors generally occur on action; however, some exhibit a mixture of rest, postural and kinetic components [15, 20, 25, 48]. The term ‘rubral’ or midbrain tremor has been used to describe a resting tremor that becomes more severe on maintaining a posture and most severe at intention [25]. The involvement of the red nucleus has not always been identified [25].

Parkinsonism developing after a stroke is predominantly bilateral and is characterised by lower body signs, no tremor and a history of risk factors including hypertension [31, 47]. Some patients develop hemiparkinsonism [20, 48].

Asterixis is usually unilateral, associated with mild initial weakness and affects the upper limb predominantly [1, 21, 36, 48]. Bilateral asterixis has also been described [36, 48].

Athetosis is uncommon and is often a component of a mixed involuntary movement disorder such as dystonia–athetosis or choreoathetosis [1, 14, 35]. Proprioceptive loss impairs stability of movement at joints and leads to pseudoathetosis [14, 35].

Myoclonus is a rare symptom in patients with stroke, and generalised myoclonus has not been reported [1]. Segmental myoclonus has been reported in posterior circulation strokes, particularly midbrain, pontine and thalamic strokes [1, 20, 52, 53]. Palatal myoclonus has been described in pontine or bulbar strokes [1]. Ghika-Schmid *et al.* identified one patient with focal action myoclonus of the jaw and tongue [21].

Transient dyskinesias described as repetitive, involuntary ‘shaky limb’ episodes have been reported in carotid territory TIAs in association with severe unilateral or bilateral carotid stenosis or with ischaemia of the vertebro-basilar system [1, 21, 38, 39]. They last a few seconds or minutes and can be precipitated by sitting or standing. They have been described as shaking, flapping or trembling and may be difficult to distinguish from epileptic seizures, although electroencephalograms during attacks do not show any epileptiform activity. Diminished cerebral blood flow has been documented, and symptoms may disappear after endarterectomy [1, 21, 39].

Treatment

This section describes the treatment of each movement disorder. The drugs used in each condition are shown in Table 1. Few large-scale studies have been possible due to small numbers of patients and there are therefore no firm guidelines for the management of these conditions.

Hemiballismus, hemichorea and athetosis

Although these conditions spontaneously resolve, they do warrant urgent and vigorous short-term treatment in view of the distress and danger they incur. Non-pharmacological treatment includes good skin hygiene, high calorie nutritional support, fluids, appropriate mattress and padded bed rails.

Pharmacological therapy comprises anti-dopaminergic therapy with typical and atypical neuroleptics and catecholamine-depleting agents. Typical neuroleptic agents including haloperidol, pimozide, perphenazine and fluphenazine work by blocking dopamine receptors and are the first line drug treatments for hemiballismus [16, 45]. The atypical neuroleptic drugs olanzapine, quetiapine and sulpiride are less likely to cause drug-induced parkinsonism and tardive dyskinesia [54]. Clozapine has been successful in refractory cases, but can cause agranulocytosis [45, 55].

Tetrabenazine depletes presynaptic dopamine and blocks post-synaptic dopamine receptors. Reserpine depletes presynaptic stores of catecholamines and serotonin. Both are effective in treating hemiballismus but both can cause profound depression as well as hypotension and parkinsonism [56]. Other drugs which have been used with some success

include clonazepam and sodium valproate [56]. Surgical intervention should be considered in drug-resistant cases, but they are contraindicated in the very frail and those with uncontrolled hypertension. Both stereotactic ventral intermediate thalamotomy and chronic thalamic stimulation have been effective [57].

Dystonia

Treatment options may be used alone or in combination. Botulinum toxin injections have been a major breakthrough in the management of dystonia [58]. Muscle contraction is reduced by direct injection into the overactive muscle, which blocks the release of acetylcholine.

Other treatments include benzodiazepines, baclofen, anticholinergic drugs and dopamine-depleting/blocking agents [2]. Clonazepam and diazepam treat focal, segmental and generalised dystonias. Higher doses are limited by drowsiness. Like botulinum toxin, the anti-cholinergic drugs block the action of the neurotransmitter acetylcholine thereby deactivating the muscle contractions. Trihexyphenidyl (benzhexol) is the most common drug in this class, but may be more useful in younger patients due to the side-effects of confusion and constipation in the elderly [2, 59].

Tetrabenazine can be helpful, but may paradoxically cause dystonia. Combining benzhexol and tetrabenazine can be very effective in younger patients [60].

Tremor

Tremor is particularly refractory to drug treatment. Rubral and palatal tremor may respond to clonazepam and sodium valproate [61]. Dystonic tremor is treated as dystonia (see above). Adding weight to the affected limb (e.g. wrist weights) can dampen tremor [61]. Propranolol is traditionally used in essential and thyrotoxic tremor but may help dampen tremor from all causes. In severe cases, functional neurosurgery (see below) may be the only useful treatment option.

Myoclonus

The two most commonly used treatments are the GABAergic drugs, clonazepam and sodium valproate. Other tried treatments include levetiracetam, piracetam, primidone and acetazolamide. Treatment should be started with a single agent although eventually several drugs in combination may be required. Clonazepam is effective in all types of myoclonus. Side-effects include sedation, vertigo, behavioural changes and tolerance and it is contraindicated in people with acute narrow-angle glaucoma and liver problems [61]. Sodium valproate is effective in cortical and subcortical myoclonus. Side-effects include drowsiness, weight gain, tremor, nausea and alopecia. It is contraindicated in hepatic insufficiency [61]. Piracetam is less sedating and may be as effective as levetiracetam [62]. Both should be used with caution in renal impairment. Primidone and acetazolamide can be tried but primidone causes drowsiness, confusion and falls, and acetazolamide necessitates electrolyte monitoring.

Parkinsonism

Patients with true vascular parkinsonism rarely respond to conventional dopaminergic therapy [31]. Supportive therapy by the physiotherapists and occupational therapists should be arranged. Treatment for the risk factors for atherosclerotic diseases to arrest progression is recommended and includes anti-platelet agents, statins and anti-hypertensives.

The caveat to this is that parkinsonism and idiopathic Parkinson's disease can co-exist, and a controlled trial of levodopa gradually increased up to a maximum of 600 mg/day (rarely up to 1,000 mg) for a minimum of 1 month should be given in order not to miss any dopaminergic responsiveness [63]. Just as important in the apparent non-responders is to wean off the levodopa to confirm that no response, in fact, occurred and to stop unnecessary medication.

Motor cortex stimulation (MCS) and deep brain stimulation (DBS)

DBS of the thalamic nuclei has been useful in more than 70% of patients with post-stroke involuntary movements (hemiballism, chorea, athetosis and tremor) [64]. In clinical trials on MCS for the control of post-stroke pain, it was discovered that co-existent involuntary movements could be controlled [64]. Although expensive and invasive, these are reversible treatment options for severe, refractory post-stroke movement disorders. Transcranial magnetic stimulation of the motor cortex is another experimental approach to the treatment of movement disorders [65].

Prognosis

Ghika-Schmid found that 50% of their 29 patients had spontaneous regression of the abnormal movement, generally within 2 weeks [21]. Only three patients (with dystonia or delayed complex movements) were resistant to medication and had persistent dyskinesias for >6 months [21]. In Alarcon's study, at 1-year follow-up, 10% of patients with chorea had improved completely and 75% partially [20]. Other patients had variable results; 28% of patients with tremor had complete resolution (64% partial); in dystonia 31% had complete improvement (62% partial); in parkinsonism one out of six patient made a spontaneous recovery [20]. In a study of delayed onset abnormal movements in 35 patients with thalamic stroke, the dyskinesias persisted in 31 patients, worsened in 3 patients and gradually improved in just 1 [14]. In Kim's study of six patients with abnormal movements after anterior cerebral artery infarction, all the patients with hemiparkinsonism had spontaneous improvement in symptoms [48]. Asterixis has usually been reported as persisting for a few days only [36]. In a case series of 33 patients who developed hemidystonia following any cerebral insult (e.g. stroke, perinatal injury, trauma) none of the patients had complete resolution of symptoms (mean duration of follow-up 15.6 years) in spite of treatment with oral medication; side-effects in more than one-third led to discontinuation and half benefited partially [2]. In a study of vascular hemiballismus treated with haloperidol \pm diazepam (if these

medications were not of benefit after 3–4 weeks clozapine was started) 56% of patients had complete recovery within 15 days, 37% had residual choreic movements and 7% had no response at 30 months [45].

Conclusion

Although rare, many different varieties of abnormal movement can be found after a stroke either acutely or as a delayed sequel. They can be hyperkinetic (most commonly hemichorea–hemiballismus) or hypokinetic (most commonly vascular parkinsonism). Most are caused by lesions in the basal ganglia or thalamus but can occur with strokes at many different locations in the motor circuit. Many are self-limiting but treatment may be required for symptom control.

Key points

- Movement disorders are a rare complication of strokes.
- They can be hyperkinetic or hypokinetic.
- They can occur with damage to many different locations in the motor pathway, most commonly basal ganglia and thalamus.
- Some are self-limiting but treatment may be required for symptom control.

Conflicts of interest

One of the authors (PM) has received sponsorship from various pharmaceutical companies to attend educational conferences.

Supplementary data

Supplementary data are available at *Age and Ageing* online.

References

- (The very long list of references supporting this review has meant that only the most important are listed here and are represented by bold type throughout the text. The full list of references is available at *Age and Ageing* online.)
1. Ghika J, Bogousslavsky J. Abnormal movements. In: Bogousslavsky J, Caplan L, eds. *Stroke Syndromes*, 2nd edition. Cambridge: Cambridge University Press, 2001; 162–81.
 2. Chuang C, Fahn S, Frucht SJ. The natural history and treatment of acquired hemidystonia: report of 33 cases and review of the literature. *J Neurol Neurosurg Psychiatry* 2002; 72: 59–67.
 6. Fahn S. Concept and classification of dystonia. In: Fahn S, Marsden CD, Calne DB, eds. *Advances in Neurology, Dystonia* 2. New York: Raven Press, 1988; 58.

7. Pettigrew LC, Jankovic J. Hemidystonia: a report of 22 patients and review of the literature. *J Neurol Neurosurg Psychiatry* 1985; 48: 650–57.
8. Krystkowiak P, Martinat P, Defebvre L *et al.* Dystonia after striatopallidal and thalamic stroke: clinico-radiological correlations and pathophysiological mechanisms. *J Neurol Neurosurg Psychiatry* 1998; 65: 703–8.
12. Bhatia KP, Marsden CD. The behavioural and motor consequences of focal lesions of the basal ganglia in man. *Brain* 1994; 117: 859–76.
13. Lehericy S, Grand S, Pollak P *et al.* Clinical characteristics and topography of lesions in movement disorders due to thalamic lesions. *Neurology* 2001; 57: 1055–66.
14. Kim JS. Delayed onset mixed involuntary movements after thalamic stroke. Clinical, radiological and pathophysiological findings. *Brain* 2001; 124: 299–309.
15. Chung SJ, Im JH, Lee MC, Kim JS. Hemichorea after stroke: clinical-radiological correlation. *J Neurol* 2004; 251: 725–9.
16. Dewey RR, Jankovic J. Hemiballism-hemichorea. Clinical and pharmacological findings in 21 patients. *Arch Neurol* 1989; 46: 862–7.
17. Krauss JK, Pohle T, Borremans JJ. Hemichorea and hemiballism associated with contralateral hemiparesis and ipsilateral basal ganglia lesions. *Mov Disord* 1999; 14: 497–501.
20. Alarcon F, Zijlmans JC, Duenas G, Cevallos N. Post-stroke movement disorders: report of 56 patients. *J Neurol Neurosurg Psychiatry* 2004; 75: 1568–74.
21. Ghika-Schmid F, Ghika J, Regli F, Bogousslavsky J. Hyperkinetic movement disorders during and after acute stroke: the Lausanne Stroke Registry. *J Neurol Sci* 1997; 146: 109–16.
25. Miwa H, Hatori K, Kondo T, Imai H, Mizuno Y. Thalamic tremor: case reports and implications of the tremor generating mechanism. *Neurology* 1996; 46: 75–9.
26. Ferbert A, Gerwig M. Tremor due to stroke. *Mov Disord* 2004; 8: 179–82.
31. Fitzgerald PM, Jankovic J. Lower body Parkinsonism: evidence for a vascular aetiology. *Mov Disord* 1989; 4: 249–60.
35. Lee MS, Kim, YD, Kim, JT, Lyoo CH. Abrupt onset of transient pseudochoreoathetosis associated with proprioceptive sensory loss as a result of a thalamic infarction. *Mov Disord* 1998; 13: 184–6.
36. Kim JS. Asterix after unilateral stroke: lesion location of 30 patients. *Neurology* 2001; 56: 533–6.
38. Baquis GD, Pessin MS, Scott RM. Limb shaking. A carotid TIA. *Stroke* 1985; 16: 444–8.
39. Tatemichi TK, Young WL, Prohovnik I *et al.* Perfusion insufficiency in limb-shaking transient ischemic attacks. *Stroke* 1990; 21: 341–7.
41. Fahn S. Phenomenology of movement disorders. In: Fahn S, Marsden, Jankovic J, eds. 7th Annual Course: A Comprehensive Review of Movement Disorders for the Clinical Practitioner. New York: Columbia University, 1997; 3–61.
43. Barr's The Human Nervous System: an Anatomical Viewpoint, 8th edition. Kiernan JA, ed. Philadelphia: Lipincott, Williams & Wilkins, 2005; 193–222.
45. Ristic A, Marinkovic J, Dragasevic N *et al.* Long-term prognosis of vascular hemiballismus. *Stroke* 2002; 33: 2109–11.
47. Winikates J, Jankovic J. Clinical correlates of vascular Parkinsonism. *Arch Neurol* 1999; 56: 98–9.
48. Kim JS. Involuntary movements after anterior cerebral artery territory infarction. *Stroke* 2001; 32: 258–61.
54. Bashir K. Clozapine for the control of hemiballismus. *Clin Neuropharmacol* 1994; 17: 477–80.
56. Klawans HL, Moses H, Nausieda PA *et al.* Treatment and prognosis of hemiballismus. *N Engl J Med* 1976; 295: 1348–50.
57. Cardoso F. Outcome after stereotactic thalamotomy for dystonia and hemiballismus. *Neurosurgery* 1995; 36: 501–7.
60. Jankovic J, Orman J. Tetrabenazine therapy of dystonia, chorea, tics and other dyskinesias. *Neurology* 1988; 38: 391–4.
61. Movement Disorders in Clinical Practice. Sawle G, ed. Oxford: Isis Medical Media, 1999.

Received 30 September 2008; accepted in revised form 21 January 2009