

Pathologic Features of Chronic Hepatitis

A Review and Update

Kamal G. Ishak, MD, PhD

Key Words: Chronic hepatitis C; Chronic hepatitis B; Autoimmune hepatitis; Pathology; Nomenclature

Abstract

The general histopathologic changes of chronic hepatitis and those related to the various causes are reviewed. Consideration also is given to underlying or associated diseases and to mixed infections in chronic viral hepatitis. Changes occurring in exacerbations or relapses are described. Selected histopathologic changes are illustrated. The nomenclature is reviewed briefly, with emphasis on separation of activity from stage of disease.

The generally accepted definition of *chronic hepatitis* is necroinflammatory disease of the liver lasting more than 6 months. Histopathologic aspects of chronic hepatitis are herein reviewed and updated, with clinicopathologic correlations. Chronic hepatitis in the liver allograft is not included.

General Histopathologic Changes of Chronic Hepatitis

Chronic hepatitis, regardless of cause, is characterized by several lesions, the most important of which is “interface hepatitis” (piecemeal necrosis) ■ **Image 1** ■. This necroinflammatory change, sometimes referred to as “lymphocytic” piecemeal necrosis, initially destroys the limiting plate of liver cells (ie, is periportal). In the untreated patient, there is continuous erosion of the hepatic parenchyma with closer and closer approximation of expanded portal areas. The necroinflammatory changes are succeeded by fibrosis.

Interface hepatitis may not involve all portal areas equally in a given case and can affect a segment or the entire perimeter of a portal area. It can continue unabated in the cirrhotic liver, complicating chronic hepatitis and, thus, contributing to the activity of the cirrhotic process.

Degenerative changes affecting liver cells in areas of interface hepatitis include “cytoplasmic dissociation” (a change characterized by swelling of liver cells with cytoplasmic rarefaction, coarse clumping of cytoplasmic organelles, and, eventually, lysis of nuclei and cell membranes), and apoptosis ■ **Image 2** ■. The latter change results in the formation of variably sized, often rounded, fragments of liver cells that are located in the liver plates or sinusoids (Image 1). The larger apoptotic bodies, sometimes

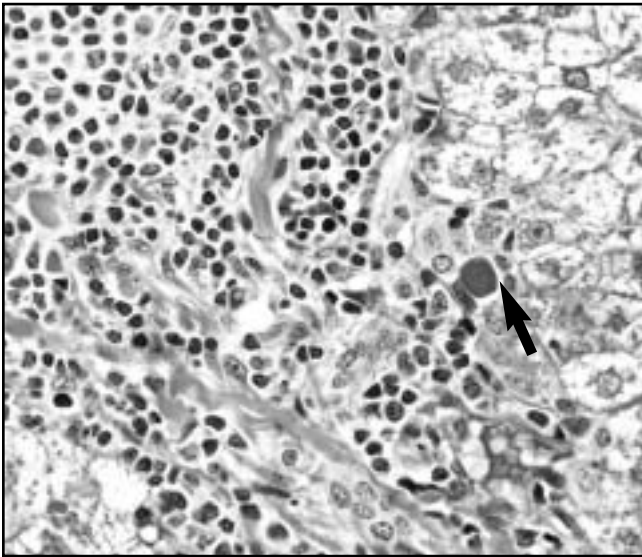


Image 1 Interface hepatitis. The junction of the markedly inflamed portal area with the hepatic parenchyma is ill-defined or eroded. Note the apoptotic body (arrow) (H&E, $\times 450$).

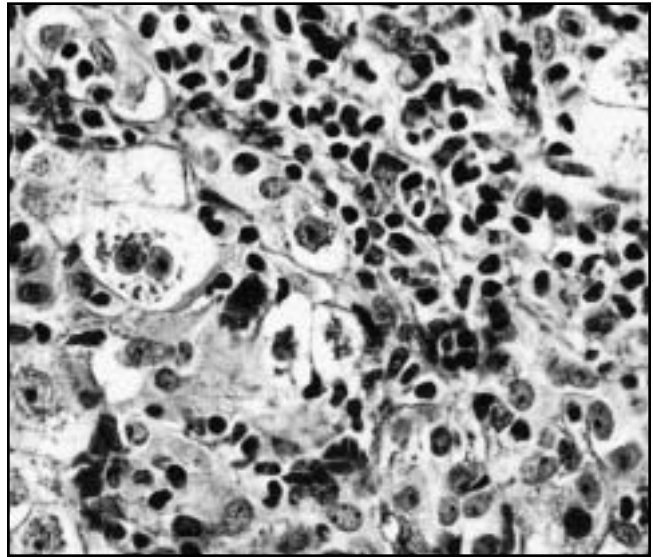


Image 2 Interface hepatitis. Separated liver cells are swollen and exhibit cytoplasmic clumping (dissociation) (H&E, $\times 440$).

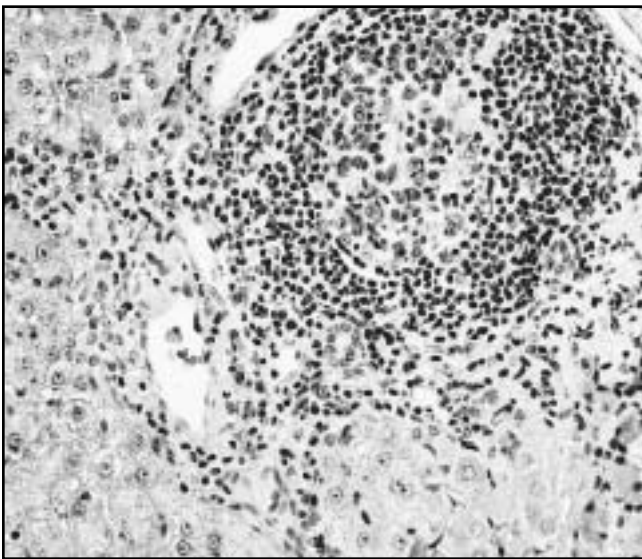


Image 3 Lymphoid follicle in portal area in chronic hepatitis C. Note the circumferential interface hepatitis (H&E, $\times 160$).

containing nuclear fragments, often are referred to as acidophilic bodies. Within the sinusoids, the apoptotic bodies are phagocytosed and ultimately digested by Kupffer cells. For further information on apoptosis in viral hepatitis, see the review by Lau et al.¹

There is an intimate relationship between lymphocytes or plasma cells and liver cells in chronic hepatitis. The degenerating hepatocytes and inflammatory cells are closely apposed, and the lymphocytes or plasma cells often are located in spaces of Disse, with indentation of the cytoplasm of liver cells (peripoleisis). Sometimes the hepatocyte

completely encircles a lymphocyte or plasma cell (emperipolesis). There is loss of microvilli of the plasma membrane of the liver cell facing the lymphocyte or plasma cell. Hassan et al² found that plasma cells in areas of interface hepatitis in chronic hepatitis produce interleukin-1. They suggested that interleukin-1 with other mediators might stimulate the production of collagen by hepatocytes in these areas. In another study, transforming growth factor- β_1 was found to be activated in chronic hepatitis C, and was considered to contribute to hepatic fibrogenesis.³ Zylberberg et al⁴ found that histologic fibrosis and activity in chronic hepatitis C correlated with levels of soluble tumor necrosis factor receptors, particularly R75. The tumor necrosis factor α -tumor necrosis factor receptor system also is activated in the liver in chronic hepatitis B virus (HBV) infection and is thought to have an important role in the pathogenesis of liver damage and viral clearance.^{5,6}

Portal inflammation often is variable in intensity and includes infiltration by lymphocytes and plasma cells. Lymphoid aggregates or follicles with reactive centers may be present. They are considered typical, although not pathognomonic, of chronic hepatitis C **Image 3**. Immunohistochemical studies of these aggregates have been performed by several groups of investigators; they are regarded as true functional lymphoid follicles. Mosnier et al⁷ found that they contained activated B cells in germinal centers surrounded by a follicular dendritic cell network. A mantle zone of B cells surrounds the activated B cells. The B-cell follicle in turn is surrounded by a T-cell zone.

Talc crystals may be seen in portal macrophages of abusers of intravenous drugs. The crystals are a specific but

not a sensitive marker of previous intravenous drug abuse.^{8,9} Such crystals are best visualized by polarizing microscopy and show a characteristic “pastry flake” appearance on scanning electron microscopy. In some addicts, the talc may be intermingled with black birefringent granules containing titanium **Image 4**. The elements silicon, magnesium in the talc, and titanium can be identified by x-ray microanalysis¹⁰ **Figure 1**. It is recommended that all liver biopsy sections with chronic hepatitis be examined routinely by polarizing microscopy inasmuch as the patient’s physician may be unaware of previous intravenous drug abuse, or because the patient may deny such abuse when asked.

A histopathologic feature that is highly characteristic, if not pathognomonic of chronic hepatitis, is the isolation and entrapment of single or groups of liver cells in the expanded portal areas (Image 2).¹⁰ Bile duct lesions, long assumed to be degenerative, are believed to represent diverticula; they are considered most characteristic, although not pathognomonic, of chronic hepatitis C **Image 5**. They were found in one third of cases of 1 series of chronic hepatitis C and were not associated with loss of bile ducts.¹¹ Vyberg¹² identified 3 types of hepatitis-associated bile duct lesions. The type 2 lesion is the one most frequently recognized in chronic hepatitis. It involves bile ducts with an outer diameter of 15 to 40 μm . The abnormal ducts frequently are surrounded by a lymphoid aggregate or follicle. Some represent preexisting ducts undergoing degeneration with swelling, cytoplasmic vacuolization, nuclear pyknosis or karyorrhexis, and infiltration by inflammatory cells, typically mononuclear. Kaji et al¹³ found that the dendritic cells involved in the bile duct damage in primary biliary cirrhosis differed from those in chronic hepatitis C. Thus, interdigitating dendritic cells frequently are seen in the early stages of primary biliary

cirrhosis, while follicular dendritic cells are observed more frequently in chronic hepatitis C. Bile duct inflammation has been noted to improve after interferon therapy.¹⁴

Most instances of chronic hepatitis reveal intra-acinar necroinflammatory changes of variable severity, in addition to periportal interface hepatitis. In the typical case, they are focal (“spotty”) and consist mainly of apoptotic bodies of varied size, as well as foci of necrosis with aggregates of lymphocytes and plasma cells **Image 6**. Hypertrophied Kupffer cells that have scavenged the apoptotic bodies and other granular debris also are present in the foci of necrosis.

Steatosis, mild to moderate, and generally macrovesicular, is considered typical of chronic hepatitis C, as will be noted later.

More severe intra-acinar injury generally is seen in exacerbations and relapses of chronic hepatitis. In chronic hepatitis B, these may be spontaneous, secondary to withdrawal of cytotoxic or immunosuppressive therapy, or associated with delta virus or HIV infection. Other than the clinical and biochemical findings, acute exacerbations of chronic hepatitis B are characterized by increases in serum HBV-DNA and IgM anti-hepatitis B core antigen titers. In addition to spontaneous exacerbations¹⁵ and relapses after interferon therapy, there are reports of reactivation of chronic hepatitis C after withdrawal of immunosuppressive therapy.¹⁶ Spontaneous flare-ups of chronic hepatitis C may be related to heterologous (mixed) infections of hepatitis C virus (HCV).¹⁷ In 1 study, spontaneous acute exacerbations of chronic hepatitis C occurred in 40% of patients.¹⁵ They were less severe than exacerbations of chronic hepatitis B biochemically and histologically, although interface hepatitis was observed more frequently. Exacerbations with marked elevations of aminotransferase levels have been reported in

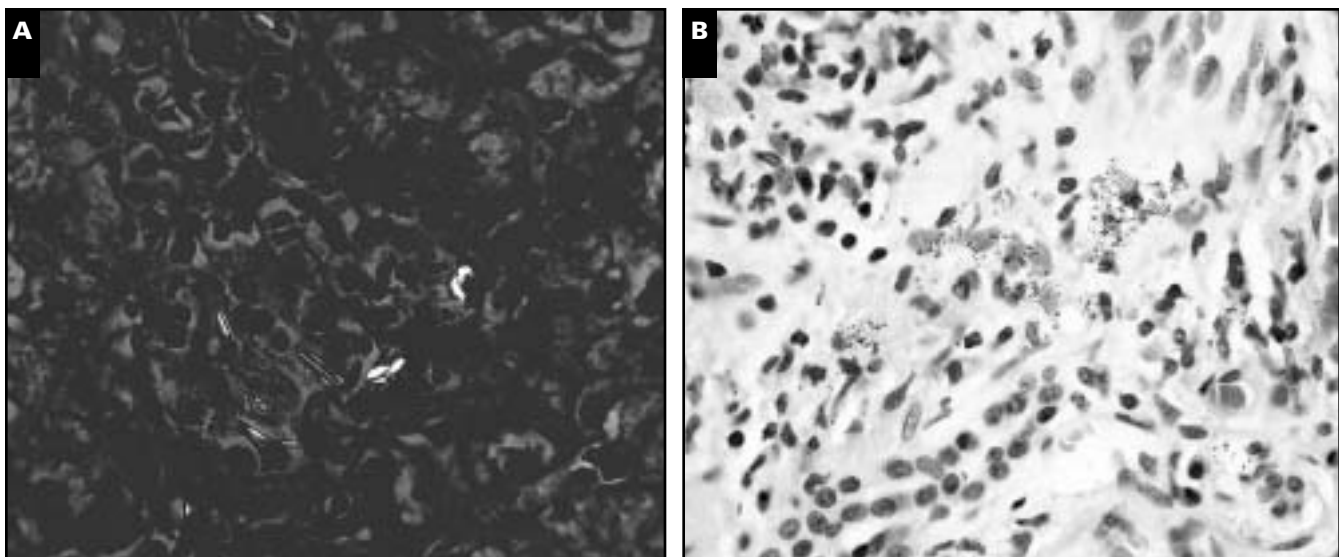


Image 4 A, Birefringent talc particles in portal area of an intravenous drug abuser ($\times 440$). B, Granular black pigment in portal area of an intravenous abuser of drugs is composed of titanium (H&E, $\times 450$).

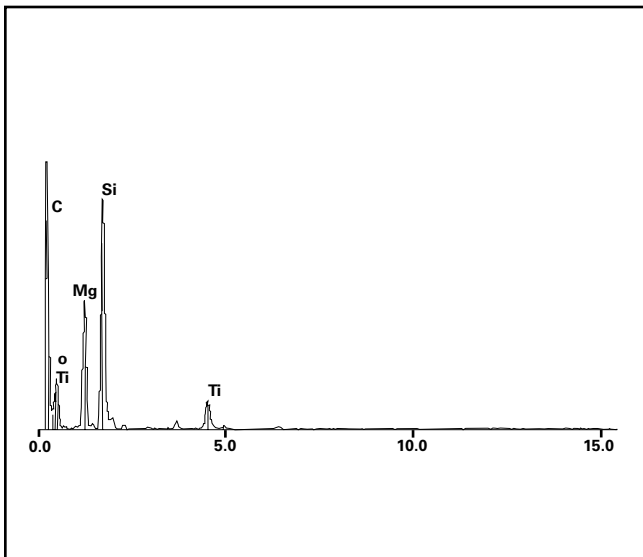


Figure 1 Elements identified by x-ray microanalysis of patient's liver depicted in Image 4B include magnesium and silicon (talc) and titanium.

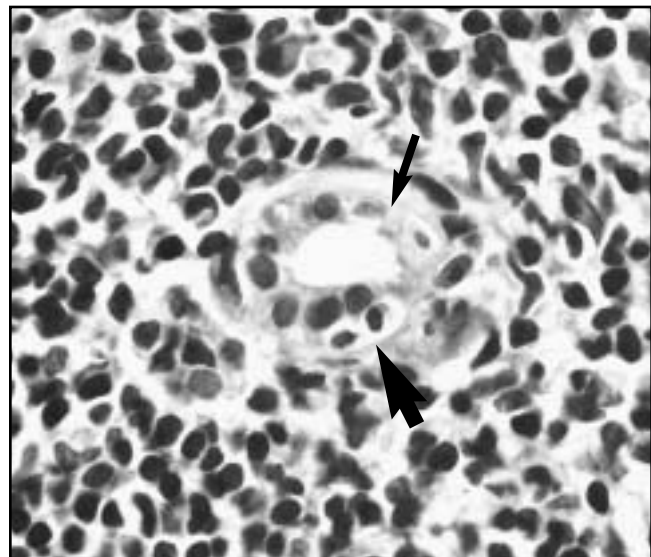


Image 5 Bile duct degeneration in chronic hepatitis C. The bile duct is infiltrated by 2 lymphocytes (large arrow), and at least 2 degenerating cells have lost their nuclei (small arrow) (H&E, $\times 880$).

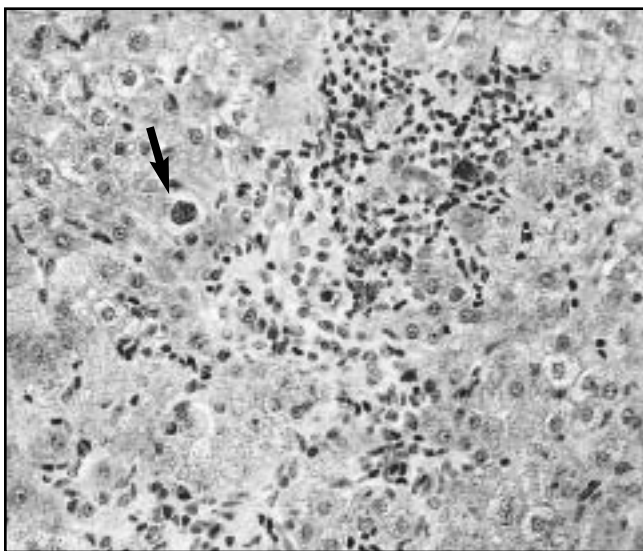


Image 6 Intra-acinar focal necrosis and an apoptotic body (arrow) in chronic hepatitis C (H&E, $\times 350$).

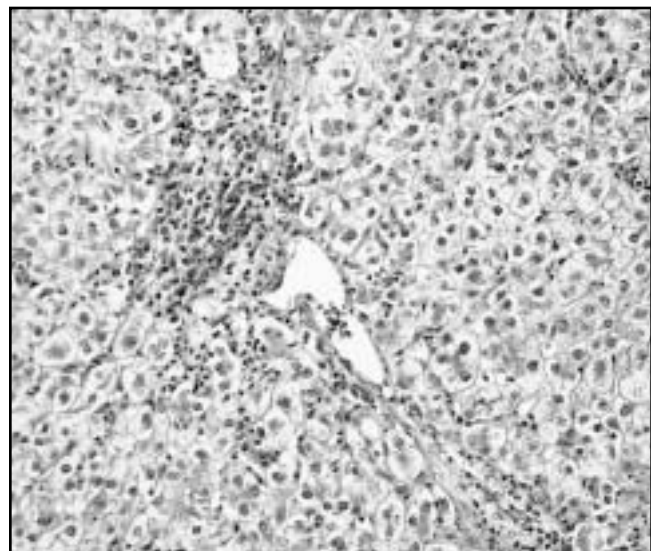


Image 7 Zone 3 necrosis with bridging in patient with autoimmune hepatitis who had a relapse (H&E, $\times 120$).

several cases of ibuprofen-induced hepatotoxic effects in chronic hepatitis C.¹⁸ Relapses of chronic autoimmune hepatitis have been reported after treatment withdrawal,¹⁹ but relapses also can be spontaneous.

In my experience, 1 or more of the following histopathologic changes can be observed in exacerbations or relapses of chronic hepatitis: (1) an increase in the degree of spotty necrosis; (2) ballooning degeneration, often most severe in zone 3, with dropout of hepatocytes and central-to-central and central-to-portal bridging necrosis that is subsequently followed by fibrosis **Image 7**; ballooning degeneration

may be associated with variable cholestasis; in such cases there is significant periportal cholangiolar proliferation, with infiltration of the cholangioles by neutrophils (acute cholangiolitis); (3) multiacinar necrosis, followed eventually by the formation of irregularly shaped, multiacinar scars. It is important to emphasize that those changes are superimposed on the chronic portal or periportal changes that characterize chronic hepatitis.

Regeneration in chronic hepatitis typically is seen in the form of 2-cell-thick plates (periportal or periseptal) and an increased number of binucleated and trinucleated cells.

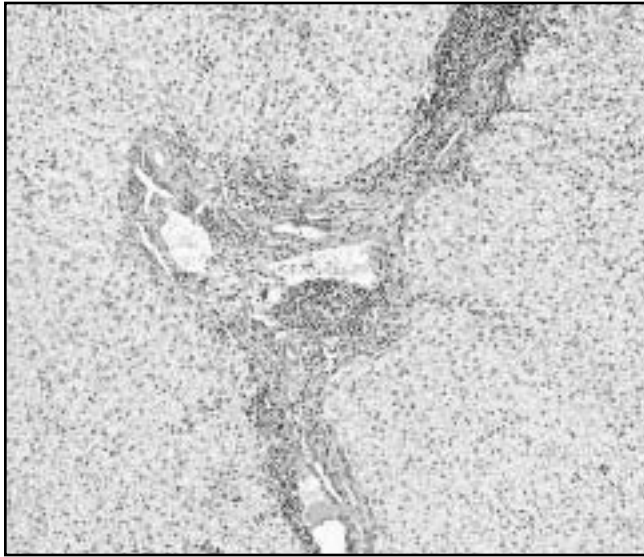


Image 8 Portal-to-portal bridging fibrosis in chronic hepatitis C (H&E, $\times 75$).

Mitoses may be present in cases with recent exacerbations or relapses. The usually progressive necroinflammation of piecemeal necrosis is associated with collagenization of the spaces of Disse and deposition of basement membrane material, a process of “capillarization” that was described many years ago by Schaffner and Popper.²⁰ Central to this process is the extracellular matrix (interstitial and basement membrane collagens, glycoproteins, and proteoglycans) that is increased markedly as a result of synthesis by stellate cells (or perisinusoidal lipocytes) and transitional cells. Initially, the fibrosis has a characteristic stellate or arachnoidal appearance. Capillarization of sinusoids around regenerated, 2-cell-thick plates of liver cells leads to rosette formation. A typical rosette consists of 4 to 6 hepatocytes, resting on a basement membrane and fibrous tissue, that surround a small centrally located canaliculus. Marked rosetting is thought to be more characteristic of autoimmune than viral chronic hepatitis.

As the fibrosis progresses, portal-to-portal fibrous bridges are formed; central-to-portal (and even central-to-central) fibrous bridges can develop from superimposed episodes of necrosis involving zone 3 **Image 8**, and broad areas of fibrosis can result from the healing of bouts of multiacinar necrosis. Elastic fibers are deposited during healing, in addition to collagen fibers; their presence can be demonstrated by the same stains used for identification of hepatitis B surface antigen (HBsAg) in tissue sections, viz orcein, aldehyde fuchsin, or Victoria blue. It should be noted that fibrosis need not be an irreversible process. Thus, the progression rate of fibrosis can be decreased in patients with chronic hepatitis C treated with interferon.²¹ Fibrosis may be decreased in chronic hepatitis C²² or even reversed in autoimmune hepatitis²³ after successful therapy. The end

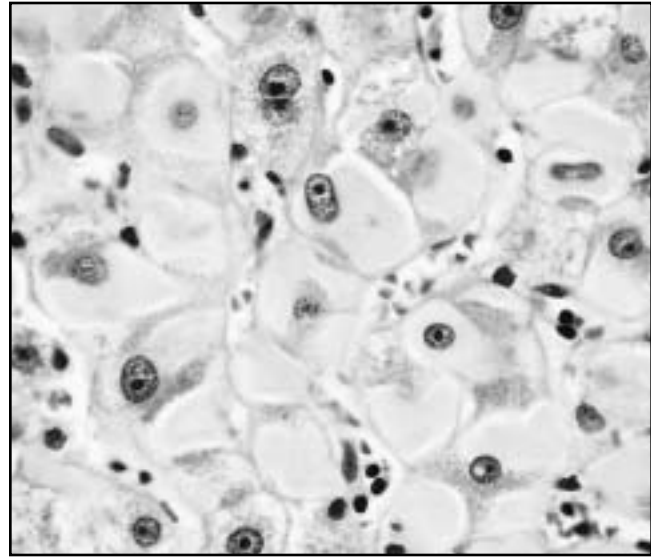


Image 9 Ground-glass cells in chronic hepatitis B (H&E, $\times 450$).

result of fibrosis in chronic hepatitis is the development of cirrhosis, in which the necroinflammatory changes of interface hepatitis (now periseptal) often continue unabated (“chronic hepatitis with cirrhosis” or “cirrhosis with chronic hepatitis”). Episodes of gastrointestinal hemorrhage can result in anoxic (coagulative) necrosis in the cirrhotic nodules. Delta virus superinfection of HBV cirrhosis can lead to extensive necrosis with decompensation and liver failure.

The cirrhosis following chronic hepatitis is macronodular or mixed macronodular and micronodular type. Needless to say, large or small cell change, dysplastic nodules (high- or low-grade), and hepatocellular carcinoma, when present, should be noted in the histopathologic description and diagnosis. The definition and terminology of these putative preneoplastic lesions should follow that recommended by the International Working Party in 1995.²⁴

Distinctive features of the various types of chronic hepatitis are discussed further in the succeeding paragraphs.

Histopathology of Various Types of Chronic Hepatitis

Chronic Hepatitis B (Delta Virus–Negative or Delta Virus–Positive)

Clearly, the specific markers of HBV infection, demonstrable by light or electron microscopy or immunohistochemically, are crucial in diagnosis **Image 9**. Ground-glass cells that contain HBsAg can be identified positively by special stains (orcein, Victoria blue, or aldehyde fuchsin). “Sanded” liver cell nuclei due to excess

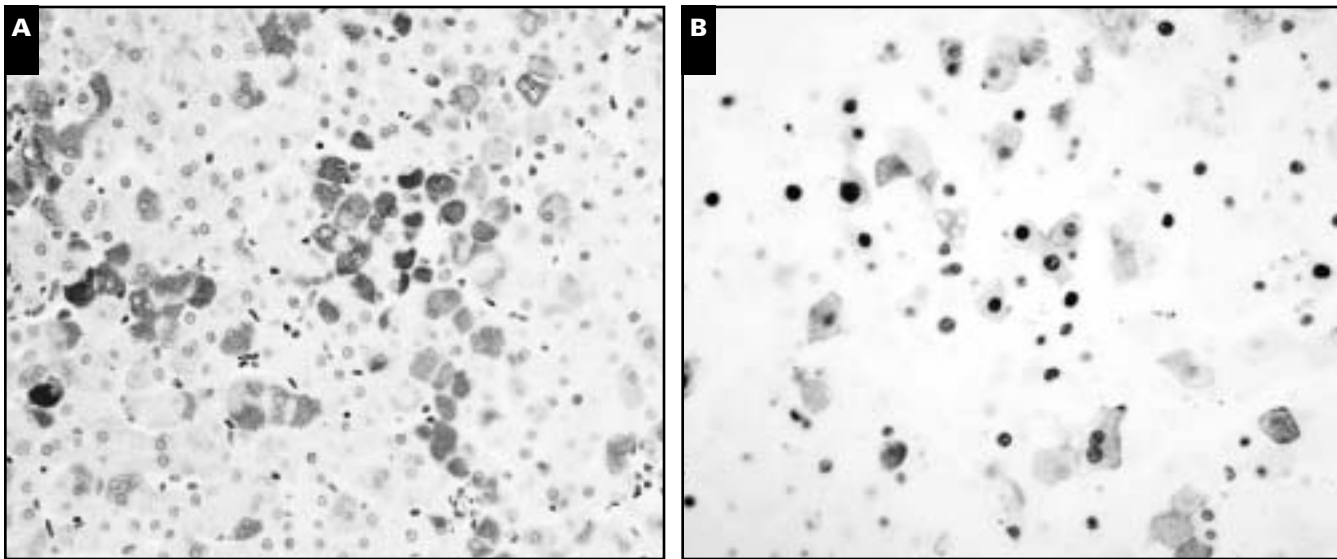


Image 10 A, Immunohistochemical expression of hepatitis B surface antigen in cytoplasm of liver cells ($\times 300$). B, Immunohistochemical expression of hepatitis B core antigen in nuclei and cytoplasm of liver cells ($\times 250$).

hepatitis B core antigen (HBcAg) accumulation are difficult to recognize histopathologically.²⁵ Furthermore, similar nuclei have been seen in delta hepatitis.²⁶ HBsAg and HBcAg are readily demonstrable immunohistochemically in the cytoplasm and nuclei of liver cells, respectively, in paraffin sections by commercially available antibodies **Image 10**. Cytoplasmic and membranous expression of HBcAg correlates with high degree with liver inflammatory activity.²⁷ Membranous expression of HBsAg correlates closely with active viral replication.²⁷ Readers interested in the complex immunopathology of HBV should consult the comprehensive review by Chisari and Ferrari.²⁸

Delta antigen can be demonstrated in tissue sections immunohistochemically; it is located mainly in nuclei of liver cells, but there may be occasional cytoplasmic expression. In situ hybridization studies for HBV and hepatitis delta virus (HDV) have been reviewed by Negro et al.²⁹ Routine assays for serum HBV DNA or liver HBcAg are more sensitive and reliable and less time consuming than in situ hybridization of tissue HBV nucleic acids. The polymerase chain reaction (PCR) can be used for detection of HBV DNA in paraffin-embedded liver tissue.

Other Superinfections or Coinfections of Chronic Hepatitis B

A number of viruses have been implicated in superinfections of patients with chronic hepatitis B. They include hepatitis A, HDV, hepatitis C, cytomegalovirus, and HIV, and are discussed in detail elsewhere.¹⁰ Superimposed hepatitis A seems to have an adverse effect on the course of chronic hepatitis B. In a critical review of the literature, Keefe³⁰ found such infections to be associated with higher

peak laboratory abnormalities, more severe disease including fulminant hepatic failure, and a higher case fatality rate. Superinfection with HDV is associated with acute exacerbations, a sudden worsening and a fatal outcome, or more severe and progressive chronic liver disease. In general, most experts agree that the degree of degeneration and necrosis is greater in delta-positive than in delta-negative chronic hepatitis B. The prognosis seems to depend to some extent on the individual immune response; it is much poorer in patients addicted to drugs than in those who are not addicted. Occasionally, in some patients, both hepatitis B and delta infections may clear after delta virus superinfection.

Double infections with HBV and HCV have been reported by several groups of investigators. The chronic infections with the 2 viruses can be acquired simultaneously or at different times. Coinfection with both viruses has been documented in at least 1 study of posttransfusion hepatitis. An inverse relation between HBV and HCV replication was found in a study of 55 patients with double infections by Pontisso et al.³¹ Liver disease activity generally was milder in patients with an active HCV infection and inactive HBV status, suggesting that HBV replication might be more harmful than HCV replication in that particular subgroup of patients. More recently, Zarski et al³² found that HBV DNA replication actually inhibited HCV RNA replication in patients with chronic hepatitis B and C but increased the severity of histologic lesions. In a study of triple infection with HBV, HCV, and HDV, Liaw et al³³ found that the disease was severe in the acute superinfection stage but that the course was relatively benign, slowly progressive, and usually dominated by HCV. The role of

HCV in dual and triple hepatitis viral infections is reviewed comprehensively by Liaw.³⁴

Cytomegalovirus infection superimposed on HBsAg-positive chronic hepatitis can lead to a fatal outcome.

As noted, HIV infection can result in reactivation of hepatitis B. The influence of HIV infection on chronic hepatitis B was studied recently in a series of 132 homosexual male patients by Colin et al.³⁵ These investigators found that HIV infection was associated with higher levels of HBV replication and a greater risk for cirrhosis without increased liver necroinflammatory activity.³⁵ Immunohistochemically, many more hepatitis B e antigen- and HBcAg-positive hepatocytic nuclei are seen in HIV-positive patients, and there often is cytoplasmic expression of HBcAg. The findings resemble those of patients receiving immunosuppressive drugs.

Chronic Hepatitis C

Detailed studies of non-A, non-B hepatitis in hemophiliac and other patients had accurately delineated most of the changes now considered characteristic of chronic hepatitis C. In 1987, Bianchi et al³⁶ found that steatosis, sinusoidal inflammatory infiltrates, prominence of Kupffer cells, lymphoid follicle formation, and bile duct epithelial changes all were histologic features favoring chronic non-A, non-B hepatitis. Similar observations were made by Lefkowitz and Apfelbaum in 1989.³⁷

Of all the lesions of chronic hepatitis C, the most characteristic (although not pathognomonic) are the lymphoid aggregates and follicles, bile duct damage, and steatosis, usually macrovesicular and mild to moderate. In 1 study, steatosis occurred more often in chronic hepatitis C than in chronic hepatitis B (52% vs 22%; $P = .03$).³⁸ While plasma cells are present infrequently in chronic hepatitis C, they are present in abundance in 1 subtype characterized by autoimmune features.³⁹ One finding is the presence of epithelioid granulomas in a small percentage of cases of chronic hepatitis C; in 1 series, they were detected in 5% of cases.⁴⁰ Goldin et al⁴¹ emphasized the need for ruling out other causes of granulomas, which were present in 50% of their cases. In this context, it is worth noting that granulomas in 1 case of chronic hepatitis C were believed to be due to treatment with interferon-alfa,⁴² but Okuno et al⁴³ were unable to relate the granulomas in the 4 patients they studied to therapy with interferon-alfa. Granulomas that developed in a liver allograft of 1 patient were attributed to HCV infection.⁴⁴ Harada et al⁴⁵ believe that granulomas may predict a favorable response to interferon-alfa therapy in chronic hepatitis C. Another finding in chronic hepatitis C is the presence of Mallory bodies in 7.1% of nonalcoholic patients with hepatitis C.⁴⁶

Stainable iron in sinusoidal cells and portal tracts,^{47,48} an increased hepatic iron content, and an elevated serum iron concentration have been linked to a poor response of chronic

hepatitis C to interferon therapy. Barton et al⁴⁷ suggested that the percentage of portal areas staining for iron should be included in the pathology report; these investigators found that patients who responded to interferon therapy had less than 40% portal areas positive for iron. Hemochromatosis gene mutations (C282Y and H63D) contribute to but do not fully explain hepatic iron accumulation in chronic hepatitis C.⁴⁹ The subject of iron and its relationship to chronic viral hepatitis is reviewed by Bonkovsky et al.⁵⁰

It must be emphasized at this juncture that the fundamental lesions of chronic hepatitis, as described in an earlier section, viz the diffuse portal inflammation, interface hepatitis, spotty necrosis and apoptosis, and the sequelae of the necroinflammation (periportal fibrosis, bridging fibrosis, and cirrhosis), are all an integral part of the morphologic spectrum of chronic hepatitis C. The pathogenesis of the hepatocellular damage in chronic hepatitis C infection is reviewed extensively by other authors.^{51,52}

PCR has been used to detect HCV RNA in serum samples, liver tissue (fresh or paraffin-embedded), or both by several groups of investigators. In 1 series, HCV was detected by reverse transcription-PCR in paraffin-embedded liver biopsy specimens in 60% of anti-HCV antibody-positive patients who were seronegative for HCV RNA, thus avoiding repeated testing and delayed therapy.⁵³ Immunohistochemistry has been used successfully to detect HCV antigens in fresh frozen tissue. In paraffin-embedded tissue, however, conflicting results have been reported with the use of the commercially available antibody TORDJI-22 (Biogenex, San Ramon, CA). One group of investigators found it to be a very specific and fairly sensitive test for HCV in fixed liver tissue,⁵⁴ while others found it to be nonspecific.^{55,56} HCV RNA has been demonstrated in liver tissue by *in situ* hybridization and more recently by *in situ* PCR. In all cases, the HCV antigens have been located in the cytoplasm of liver cells.

Coinfections of HCV and HBV (with or without HDV) already have been discussed. A high fatality rate of patients with chronic hepatitis C superinfected with hepatitis A was reported by Vento et al⁵⁷ but could not be confirmed in another study.⁵⁸ Patients with chronic hepatitis C who also are HIV-infected have a more progressive course toward cirrhosis; current antiretroviral therapies have no effect on the course of HCV infection.⁵⁹

In addition to mixed viral infections, the clinical course and histopathologic changes of chronic hepatitis C may be influenced by other factors, such as the mode of transmission and genotype of HCV. Thus, Gordon et al⁶⁰ found that transfusion-associated chronic hepatitis C leads to more aggressive histologic inflammatory activity than does hepatitis secondary to intravenous drug abuse. In reference to the HCV genotypes in the United States, the

predominant types are 1a and 1b; these genotypes are associated with more severe liver disease and lower rates of response to interferon therapy than are types 2a or 2b.⁶¹ Conflicting results, however, were reported in a study that found no correlation between HCV genotypes or subtypes, viremia, liver test results, and histologic features.⁶²

Hepatitis G Virus and Liver Disease

Hepatitis G virus (HGV), a recently discovered flavivirus, has been found in the serum samples of 1.4% of volunteer blood donors in the United States.⁶³ It can be transmitted by blood transfusions and is prevalent in populations with frequent parenteral exposure (intravenous drug users, hemophiliac patients, and patients receiving hemodialysis).^{63,64} It does not worsen the course of concurrent HCV infection.⁶³⁻⁶⁶ Persistent infection with HGV is common, but it does not lead to chronic disease nor does it affect the clinical course in patients with hepatitis A, B, or C.⁶⁷ Infection with HGV does not affect the histopathologic severity and characteristics of chronic hepatitis C.^{68,69} Evidence for a possible role of HGV in fulminant hepatic failure was presented recently.⁷⁰

TT Virus and Liver Disease

The TT virus (TTV) is a recently discovered human DNA virus common in blood donors and blood products,^{71,72} but it also is found in high prevalence in the general population in the United Kingdom and Japan.⁷² The virus was named TT for the initials of the patient from whom it was recovered⁷³ but later was mistakenly referred to as "transfusion-transmitted" virus.^{71,74} No clear disease association was found in 1 study of TTV infection from the United Kingdom.⁷⁴ More recently, TTV DNA was detected in acute and chronic liver disease in Japan by Ikeda et al.⁷³ Thus, it was found in 29% of patients with acute hepatitis and 47% of patients with chronic liver disease of unknown cause. In a study from the United States, Charlton et al.⁷² found TTV infection to be common in patients with liver disease, including those with cryptogenic cirrhosis and fulminant hepatic failure. Clearly, further studies are needed to clarify the role of TTV in acute and chronic liver diseases.

Host Factors and Interaction of Chronic Hepatitis with Other Diseases

A variety of host factors (age and sex, genetic susceptibility, major histocompatibility complex class I and class II associations and others), which in part help to explain clinical outcomes in hepatitis B or C infections, are reviewed by Thursz and Thomas.⁷⁵

The combined effects of alcoholism and infection with HBV or HCV have interested clinical investigators for many years. In a study of an urban population in the United

States, alcoholism was found to be associated with HCV but not HBV.⁷⁶ The increased seroprevalence of HCV in actively drinking alcoholic patients without known risk factors suggests that alcoholism is a predisposing factor for HCV infection. Chronic alcoholism in patients with chronic hepatitis C causes more severe and rapidly progressive disease leading more frequently to cirrhosis and hepatocellular carcinoma.⁷⁷ In the study by Wiley et al.,⁷⁸ alcoholic patients with hepatitis C infection had a 2- to 3-fold greater risk of liver cirrhosis and decompensated liver disease than did patients who were not alcoholic. In addition, cirrhosis developed faster in the alcoholic patients than in the nonalcoholic patients (50% and 10%, respectively) by the second decade of disease. Changes that should suggest a viral cause for chronic hepatitis in the alcoholic patient (who is HBsAg-positive or anti-HCV-positive) include interface hepatitis and lymphoplasmacytic portal and parenchymal inflammation. The presence of steatohepatitis with Mallory bodies and perivenular ("chicken wire") fibrosis in zone 3, in addition to the histopathologic features of chronic hepatitis C, lend support to a combined alcoholic-HCV cause for the chronic liver disease. Needless to say, the serologic tests for hepatitis B and C markers and the biochemical findings (in particular the gamma-glutamyl transferase and the aspartate aminotransferase/alanine aminotransferase ratio) are critical for the differential diagnosis. Changes resembling those of alcoholic steatohepatitis occasionally may be seen in patients who are obese or diabetic patients who have nonalcoholic steatohepatitis and chronic hepatitis C.

Chronic hepatitis in patients with genetic hemochromatosis is rare and almost always due to infection with HCV or HBV. The occurrence of end-stage liver disease in a 13-year-old boy with chronic hepatitis C and genetic hemochromatosis suggests a synergism between the 2 diseases.⁷⁹

The relationship of chronic hepatitis C in adults and alpha₁-antitrypsin deficiency is discussed later.

Porphyria cutanea tarda (PCT) is associated with a high prevalence of HCV and HBV infection. In 1 study from Spain, viral genomes of HCV and HBV were detected in 65% and 40% of patients with PCT, respectively.⁸⁰ In another study from Italy, HCV antibody was detected in 100% of patients with chronic hepatitis and PCT, leading to the conclusion that it was the main pathogenetic factor in the liver disease in those patients.⁸¹ In a study from North America, 56% of patients with PCT had evidence of HCV infection.⁸² In that series, 73% of patients had mutations of the HFE gene (C282Y mutations). Alcohol and estrogen use also were important additional risk factors. The resolution of skin lesions of PCT after interferon-alfa therapy lends further support to a role of HCV infection in that disease.⁸³

Table 1
Histopathology of Autoimmune Hepatitis

Presentation	Histopathology
Chronic	Chronic hepatitis: (1) Variable interface hepatitis, portal inflammation with plasma cell predominance, and spotty intra-acinar necrosis and apoptosis, with or without multinucleated giant hepatocytes; (2) Fibrous expansion of portal areas, with or without bridging fibrosis; (3) Marked fibrosis with bridging and nodule formation, ie, cirrhosis “Overlap syndromes”: (1) Chronic hepatitis and primary sclerosing cholangitis; (2) Chronic hepatitis and primary biliary cirrhosis
Acute	Superimposed on chronic hepatitis: (1) Marked diffuse intra-acinar necroinflammation; (2) Zone 3 necrosis, with or without bridging; (3) Cholestasis Without underlying chronic hepatitis: (1) Zone 3 (submassive) necrosis; (2) Massive necrosis

Autoimmune Chronic Hepatitis

A predominance of plasma cells in portal areas and in foci and zones of necrosis is characteristic of autoimmune chronic hepatitis and is most helpful for distinguishing it from chronic hepatitis C, in which the predominant cell is the lymphocyte. However, an abundance of plasma cells can be found in chronic hepatitis B and some cases of drug-induced chronic hepatitis and in 1 subtype of chronic hepatitis C,³⁹ as noted earlier.

It is important to mention briefly that anti-HCV antibody has been detected in type 2 autoimmune chronic hepatitis, which is characterized by liver-kidney-microsomal (LKM-1) antibodies.⁸⁴⁻⁸⁷ However, anti-LKM-1 was not observed in patients from the United States with chronic hepatitis C, in contrast with French patients in whom the antibody was noted in 3.7%.⁸⁸ It has been suggested that differences in the induction of anti-LKM-1 may be related to environmental factors, host genetic factors, genomic variation in HCV, or a combination of these.⁸⁸ Autoantibodies to cytosol antigen type 1 seem to be a more specific marker for autoimmune chronic hepatitis type 2 than are anti-LKM-1 autoantibodies.⁸⁹ Several groups of investigators have suggested that HCV might be directly responsible for the development of type 2 (anti-LKM-1-positive) autoimmune chronic hepatitis in genetically predisposed persons.^{85,87,90} It should be noted that a variety of autoantibodies (eg, anti-smooth muscle and antinuclear antibodies) can occur in chronic hepatitis C. In 1 series, they were found in 27% of patients⁹¹ and in another series, in 66% of patients.⁹² Zein et al⁹¹ determined that the antibodies were not associated with viral genotype, clinical profile, or treatment outcome. It should be noted that autoantibodies also are common in chronic HBV infection and that their prevalence is uninfluenced by interferon-alfa.⁹³

In 1993, the International Autoimmune Hepatitis Group recommended replacing the term *autoimmune chronic active hepatitis* with *autoimmune hepatitis*, inasmuch as autoimmunity implies chronicity and because the disease may become inactive for long periods during treat-

ment-induced or spontaneous remissions.⁹⁴ In the scoring system that was devised, however, the histologic findings were referred to as “chronic active hepatitis with piecemeal necrosis,” with or without lobular involvement and bridging necrosis. Rosetting of liver cells and the predominance of plasma cells in the inflammatory infiltrate were recognized as characteristic, although not pathognomonic, features **Image 11**. I believe that the morphologic spectrum of noncholestatic autoimmune chronic liver disease cannot and should not be lumped into 1 rubric—autoimmune hepatitis. My concept of the histopathologic changes of autoimmune hepatitis, including acute and chronic changes, is summarized in **Table 1**. The degree of activity and stage of disease also should be reflected in the diagnosis, as is customary for other types of chronic hepatitis. The so-called overlap syndromes listed in Table 1 will not be discussed. Interested readers are referred to the review by Dienes et al⁹⁵ for a discussion of the histopathologic features of these syndromes.

It is important to emphasize that autoimmune hepatitis may have a sudden onset.⁹⁶⁻¹⁰⁰ In some of the reported cases, acute changes, such as hepatocellular necrosis and cholestasis, seem to have been superimposed on chronic hepatitis. However, the 4 cases described by Pratt et al⁹⁸ showed only zone 3 necrosis with sparing of portal areas, and 1 of the cases reported by Herzog et al¹⁰⁰ had massive necrosis. Several cases on file at the Armed Forces Institute of Pathology, Washington, DC, resembled those described by Pratt et al⁹⁸ **Image 12**.

Multinucleated giant cells **Image 13** have been reported in some cases of autoimmune hepatitis, other disorders with autoimmune features (eg, autoimmune hemolytic anemia in children, lupus erythematosus), and a number of hepatotropic viral infections.¹⁰¹⁻¹¹⁶ The terms *postinfantile giant cell hepatitis*,¹⁰⁴ *syncytial giant cell hepatitis*,¹⁰⁷ and *postinfantile giant-cell transformation in hepatitis*¹⁰⁶ have been used to identify such cases. Phillips et al¹⁰⁷ described 10 patients, 4 with subacute hepatic failure and 6 with severe chronic hepatitis. Electron

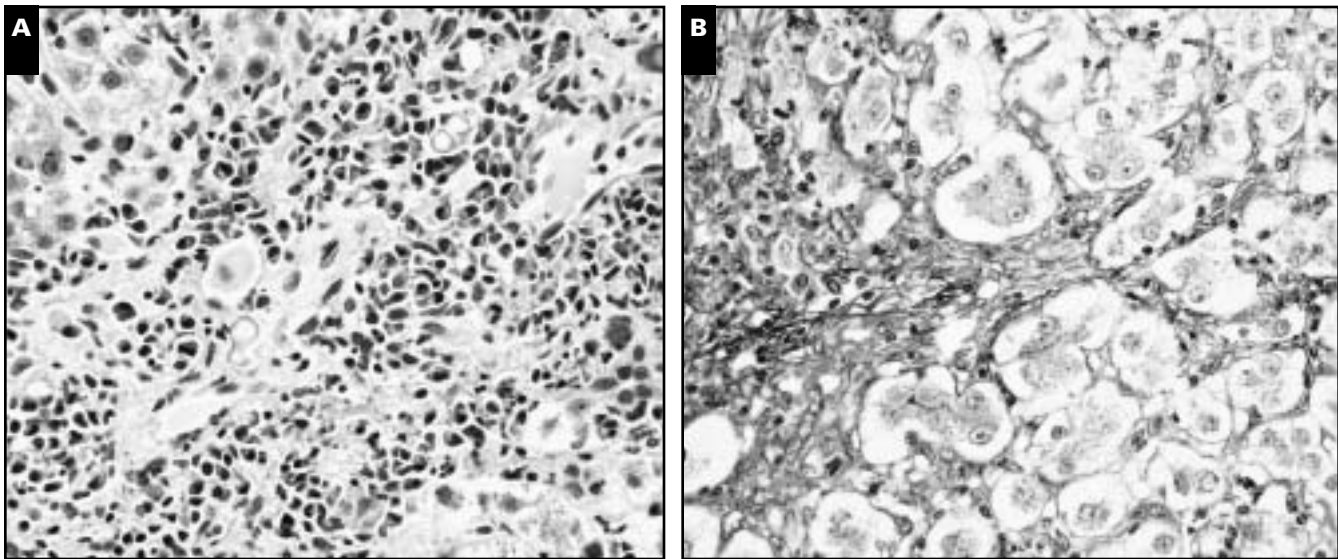


Image 11 A, Chronic autoimmune hepatitis. Most of the inflammatory cells in the expanded portal area and area of interface hepatitis are plasma cells (H&E, $\times 300$). B, Periportal rosette formation (periodic acid–Schiff after diastase digestion $\times 300$).

microscopy revealed structures resembling paramyxovirus nucleocapsids, and it was suggested that the virus could be the cause of the liver disease. Fimmel et al¹⁰⁸ subsequently described a case with abundant nucleocapsid-like protein material in the cytoplasm and nuclei of hepatocytes; these structures were similar to but distinct from those of known Paramyxoviridae, suggesting infection with a novel related virus. Two series have questioned the conclusions of Phillips et al¹⁰⁷ that postinfantile liver disease with giant cell transformation is a single entity or that it always carries an ominous prognosis. In the series by Devaney et al,¹⁰⁹ the most frequently identified association was with autoimmune disease. Corticosteroid therapy has led to clinical, biochemical, and histologic improvement in some cases.¹¹² The recurrence of syncytial giant cell hepatitis after liver transplantation^{115,116} and the detection of paramyxoviral-like particles ultrastructurally, however, suggest a transmissible agent as a cause, at least of some cases.

Cryptogenic Chronic Hepatitis

This label, as well as its end stage, “cryptogenic cirrhosis,” have been used as a “wastebasket” for chronic necroinflammatory disease of unknown cause. Many such cases now have been shown to be related to hepatitis C. Thus, 18% of cases of cryptogenic chronic hepatitis studied at the Mayo Clinic were found to be anti-HCV–positive.¹¹⁷ In another study from the United Kingdom, 67% of cases of cryptogenic chronic liver disease had hepatitis C nucleocapsid antibodies.¹¹⁸ In a third study from Spain, 82% of patients with cryptogenic chronic hepatitis were anti-HCV–positive.¹¹⁹ Cases not due to hepatitis C are associ-

ated infrequently with autoantibodies, suggesting that cryptogenic cirrhosis is distinct from autoimmune liver disease.¹²⁰ However, in a comparative study of 12 patients with cryptogenic hepatitis and 94 patients with autoimmune hepatitis, Czaja et al¹²¹ found no differences in clinical expression, genetic phenotype, and corticosteroid responsiveness between the 2 groups. They therefore concluded that cryptogenic hepatitis may be an autoimmune disorder that has escaped detection by conventional immunoserologic markers.¹²¹ It recently has been suggested, however, that a considerable number of cases of cryptogenic cirrhosis may be “burned out” nonalcoholic steatohepatitis.¹²² Histopathologically, there are no characteristic features of “true” cryptogenic hepatitis or cirrhosis; the activity of the hepatitis and cirrhosis may be mild.^{120,123}

Drug-Induced Chronic Hepatitis

A number of drugs have been incriminated in the causation of chronic hepatitis. They have included acetaminophen, aspirin, amineptine, clometacin, dantrolene, diclofenac, fenofibrate, glafenine, isoniazid, isaxonine, lisinopril, methyldopa, minocycline, nitrofurantoin, oxyphenisatin, papaverine, pemoline, perhexilene maleate, propylthiouracil, sulfonamides, ticrynafen, and tolazamide. While the list seems lengthy, only 1 or 2 instances have been reported with some of the drugs. Furthermore, many of the older reports antedated the discovery of HCV, making at least some suspect. Histopathologic differences between drug-induced and other types of chronic hepatitis (other than the specific or distinctive features of chronic hepatitis B or C) have not been forthcoming. Some drugs lead to a syndrome resembling type 1 autoimmune

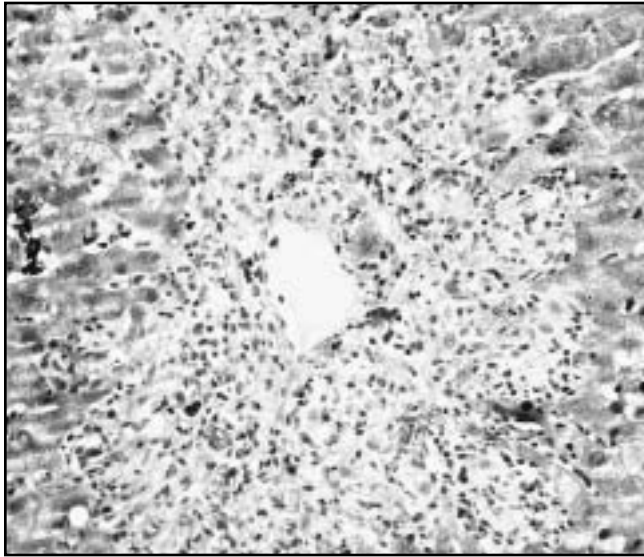


Image 12 Zone 3 necrosis in acute autoimmune hepatitis (H&E, ×170).

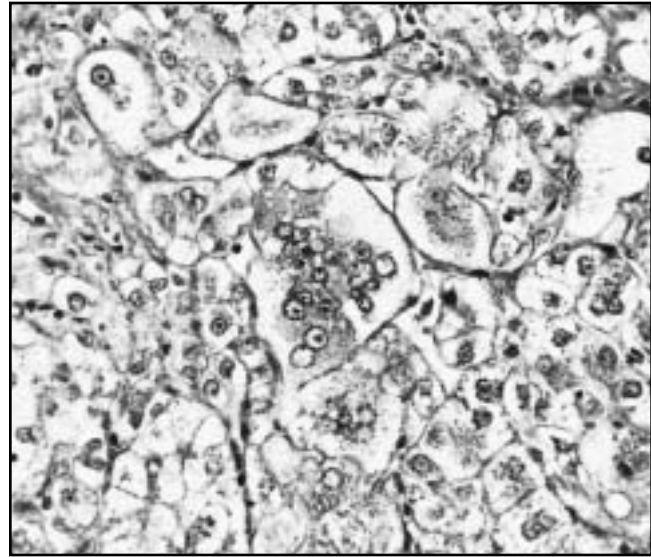


Image 13 Multinucleated giant cells in chronic autoimmune hepatitis (H&E, ×300).

hepatitis. The topic of drug-induced chronic hepatitis was reviewed recently by Strader and Seeff¹²⁴ and Zimmerman.¹²⁵

Chronic Hepatitis Associated With the Inherited Metabolic Diseases

Chronic hepatitis has been reported in patients with Wilson disease.^{126,127} It should always be considered in the differential diagnosis of chronic hepatitis in a young person. Helpful histopathologic clues include steatosis, glycogenated nuclei in zone 1, cytochemically demonstrable copper accumulation, presence of Mallory bodies in periportal liver cells (in the absence of other features of cholestasis), and clusters of oxyphil hepatocytes; these changes are in addition to the other features that are found in all cases of chronic hepatitis (eg, interface hepatitis, portal inflammation) regardless of the cause. The ultrastructural changes, particularly the pleomorphism of mitochondria and widening of their intercrystal spaces, are considered pathognomonic of Wilson disease.

Chronic hepatitis, reported in heterozygotes (MZ phenotype) with α_1 -antitrypsin deficiency by Hodges et al¹²⁸ some 18 years ago, has not been confirmed by others. Propst et al^{129,130} and others^{131,132} found that most instances of chronic hepatitis in adults with homozygous and heterozygous α_1 -antitrypsin deficiency were related to hepatotropic viruses (80% had HCV infection) or other risk factors (eg, autoimmune hepatitis).

Terminology of Chronic Hepatitis

All authorities have called for abandoning the widely used division of chronic hepatitis into chronic persistent

hepatitis, chronic active hepatitis, chronic aggressive hepatitis, and chronic lobular hepatitis and using 1 designation for chronic necroinflammatory disease—chronic hepatitis—with varying degrees of activity and emphasizing the cause.^{10,133-135} The need for reassessment of the previous classifications is borne of the extensive experience gained from morphologic studies of all types of chronic hepatitis, in particular hepatitis C, the availability of new drugs (such as interferon, ribavirin, and lamivudine) for treatment of chronic viral hepatitis, and the long-term follow-up studies that have shown discordance between the prognosis and the histologic subtype of chronic necroinflammatory disease of the liver. The histopathologic features can change from active to inactive and vice versa depending on the natural course of the disease (quiescent phase vs reactivation or relapse), host factors, therapy, superinfection with other viral agents, underlying genetic diseases (eg, α_1 -antitrypsin deficiency), or modifying disorders (eg, alcoholism).

Liver Biopsy Interpretation and Diagnosis of Chronic Hepatitis

After review of a liver biopsy specimen from a patient with a clinical diagnosis of chronic hepatitis, the pathologist should provide the clinician with the following information: (1) confirmation of the diagnosis of chronic hepatitis; (2) an indication of the degree of activity of the chronic hepatitis **Table 2**; (3) an etiologic diagnosis based on the results of serologic tests, routine and histochemical stains, and immunohistochemical stains; (4) the stage of the disease, ie, presence or absence of fibrosis (and

Table 2
Degree of Activity in Chronic Hepatitis

Category	Lesions and Degree of Injury			
	Portal Area Inflammation	Piecemeal Necrosis	Spotty Necrosis	Bridging and/or Multiacinar Necrosis
Mild	Mild, patchy	Absent or mild	Mild	Absent
Moderate	Moderate	Moderate	Moderate	Absent
Marked	Marked	Marked	Marked	Absent
Very marked	Marked	Marked	Marked	Present

Table 3
Degree of Fibrosis in Chronic Hepatitis

Category	Component Lesions		
	Fibrous Expansion of Portal Areas	Bridging Fibrosis*	Bridging With Nodules (Cirrhosis)
Mild	Absent or mild	Absent	Absent
Moderate	Moderate	Absent [†]	Absent
Marked	Marked	Marked	Absent [‡]
Very Marked	Marked	Marked	Present

* Bridging can be portal to portal, portal to zone 3 (central), or zone 3 to zone 3.

[†] Occasional bridging may be present.

[‡] Occasional nodule may be present ("incomplete cirrhosis").

its distribution and degree) or cirrhosis (Table 3); (5) a description of other lesions that may be present, eg, alcoholic liver disease, hemosiderosis, granulomas, or, in a cirrhotic liver, the presence of superimposed ischemic necrosis ("anoxic pseudolobular necrosis"); and (6) a description of any putative preneoplastic lesions, such as large or small cell changes or dysplastic nodules (low- or high-grade), or the presence and degree of differentiation of hepatocellular carcinoma. A major role of histopathologic evaluation during the last few years has been assessment of the efficacy of therapy by comparison of pretreatment with posttreatment liver biopsy specimens. A semiquantitative histologic activity index ("Knodell score") has been used widely for that purpose,¹³⁶ but other scoring systems also have been used.^{137,138} Tables 2 and 3 also could be used as the basis for a simple grading system similar to that of Scheuer.¹³³

Summary and Conclusions

Chronic hepatitis is defined as necroinflammatory disease of the liver lasting longer than 6 months. It usually is the result of chronic infection with the hepatotropic viruses—HCV, HBV, or HDV—but may be autoimmune or drug-induced. All types of chronic hepatitis are characterized by periportal interface hepatitis (piecemeal necrosis). Additional distinctive or pathognomonic features, depending on

the cause, are discussed briefly in this review.

Chronic hepatitis C is characterized by variable portal, predominantly lymphocytic, inflammation (often with lymphoid aggregates or follicles), bile duct degenerative changes (without significant bile duct loss), scattered focal necrosis and apoptosis, and mild to moderate steatosis. Hemosiderin in portal areas, noncaseating granulomas, and Mallory bodies are present in some cases. Hepatitis G infection does not affect the course or histopathologic changes of chronic hepatitis C.

Chronic hepatitis B reveals variable portal inflammation (lymphoplasmacytic), scattered focal necrosis and apoptosis, and ground-glass hepatocytes (which can be identified by orcein or Victoria blue stains). HBsAg and HBcAg are expressed in different patterns immunohistochemically. Exacerbations and relapses are characterized further by more severe necroinflammatory injury, sometimes with bridging or multiacinar necrosis.

Chronic delta hepatitis is indistinguishable histopathologically from chronic hepatitis B, except for ground-glass cells that express cytoplasmic HBsAg (but not nuclear HBcAg) immunohistochemically. Delta virus antigen can be immunostained in the nuclei of liver cells.

The histopathologic features and the course of chronic viral hepatitis can be affected adversely by 1 or more coexistent conditions or diseases, such as multiple viral infections, AIDS, alcoholism, and porphyria cutanea tarda.

Autoimmune (chronic) hepatitis has no pathognomonic

histopathologic features, but periportal rosette formation and a predominance of plasma cells in portal and periportal areas are typical. A sudden onset with zone 3 necrosis, as well as exacerbations or relapses also characterized by zone 3 bridging necrosis or multiacinar necrosis, may occur. One variant is associated with giant cell transformation. Cryptogenic chronic hepatitis, thought by some authorities to be autoimmune hepatitis with negative serum autoantibodies, has no distinctive morphologic features.

Drug-induced chronic hepatitis is indistinguishable from chronic autoimmune or other types of chronic hepatitis. The diagnosis must be based on the drug history, clinical features, and negative serologic viral or autoantibody markers.

The only important, albeit rare, metabolic cause of chronic hepatitis is Wilson disease. It should be ruled out in all cases of chronic hepatitis in children or young adults. Some histopathologic features that may be helpful for the differential diagnosis include the presence of steatosis, glycogenated nuclei, foci of oncocytic hepatocytes, and histochemical demonstration of copper and copper-binding protein.

Progression of chronic hepatitis is associated with fibrous expansion of portal areas, portal-to-portal or portal-to-central bridging, and nodule formation with incomplete or complete cirrhosis. Putative preneoplastic lesions in the cirrhotic liver include large or small cell change (liver cell dysplasia) and dysplastic nodules (low- or high-grade). Hepatocellular carcinoma typically develops in a cirrhotic liver, in particular that complicating chronic hepatitis C or B.

The diagnosis of chronic hepatitis should include the cause, the degree of activity, the stage of disease (degree and extent of fibrosis and presence of cirrhosis), and the presence of any putative preneoplastic or neoplastic lesions. Associated lesions or diseases, eg, steatohepatitis, alcoholic or nonalcoholic, should be coded separately.

From the Department of Hepatic and Gastrointestinal Pathology, Armed Forces Institute of Pathology, Washington, DC.

Address reprint requests to Dr Ishak: Armed Forces Institute of Pathology, Department of Hepatic and GI Pathology, Washington, DC 20306-6000.

References

- Lau JYN, Xie X, Lai MMC, et al. Apoptosis and viral hepatitis. *Semin Liver Dis.* 1998;18:169-176.
- Hassan G, Moreno S, Massimi M, et al. Interleukin-1 producing plasma cells in close contact with hepatocytes in patients with chronic active hepatitis. *J Hepatol.* 1997; 27:6-17.
- Nelson DR, Gonzalez-Peralta RP, Qian K, et al. Transforming growth factor-beta₁ in chronic hepatitis C. *J Viral Hepatol.* 1997;4:29-35.
- Zylberberg H, Rimaniol A-C, Pol S, et al. Soluble tumor necrosis factor receptors in chronic hepatitis C: a correlation with histological fibrosis and activity. *J Hepatol.* 1999;30:185-191.
- Marinos G, Naumov NV, Rossol S, et al. Tumor necrosis factor in patients with chronic hepatitis B virus infection. *Gastroenterology.* 1995;108:1453-1463.
- Fang JWS, Shen WW, Meager A, et al. Activation of the tumor necrosis factor-alpha system in the liver in chronic hepatitis B virus infection. *Am J Gastroenterol.* 1996;91:748-753.
- Mosnier J-F, Degott C, Marcellin P, et al. The intraportal lymphoid nodule and its environment in chronic active hepatitis C: an immunohistochemical study. *Hepatology.* 1993;17:366-371.
- Allaire GS, Goodman ZG, Ishak KG, et al. Talc in liver tissue of intravenous drug abusers with chronic hepatitis: a comparative study. *Am J Clin Pathol.* 1989;92:583-588.
- Sherman KE, Lewey SM, Goodman ZD. Talc in the liver of patients with chronic hepatitis C infection. *Am J Gastroenterol.* 1995;90:2164-2166.
- Ishak KG. Chronic hepatitis: morphology and nomenclature. *Mod Pathol.* 1994;7:690-713.
- Kaji K, Nakanuma Y, Sasaki M, et al. Hepatic bile duct injuries in chronic hepatitis C: histopathologic and immunohistochemical studies. *Mod Pathol.* 1994;7:937-945.
- Vyberg M. The hepatitis-associated bile duct lesion. *Liver.* 1993;13:289-301.
- Kaji K, Nakanuma Y, Harada K, et al. Dendritic cells in portal tracts in chronic hepatitis C and primary biliary cirrhosis: an immunohistochemical study. *Hepatol Res.* 1997;8:1-12.
- Banner BF, Allan C, Smith L, et al. Effect of interferon therapy on bile duct inflammation in hepatitis C. *Virchows Arch.* 1996;428:253-259.
- Sheen I-S, Liaw Y-F, Lin D-Y, et al. Acute exacerbations in chronic hepatitis C: a clinicopathological and prognostic study. *J Hepatol.* 1996;24:525-531.
- Vento S, Cainelli F, Mirandola F, et al. Fulminant hepatitis on withdrawal of chemotherapy in carriers of hepatitis C virus. *Lancet.* 1996;347:92-93.
- Kao J-H, Chen P-J, Lai M-Y, et al. Mixed infections of hepatitis C virus as a factor in acute exacerbations of chronic type C hepatitis. *J Infect Dis.* 1994;170:1128-1133.
- Riley TR, Smith JP. Ibuprofen-induced hepatotoxicity in patients with chronic hepatitis C: a case series. *Am J Gastroenterol.* 1998;93:1563-1565.
- Hegarty JE, Aria KTN, Portmann B, et al. Relapse following treatment withdrawal in patients with autoimmune chronic active hepatitis. *Hepatology.* 1983;3:685-689.
- Schaffner F, Popper H. Capillarization of hepatic sinusoids in man. *Gastroenterology.* 1963;44:239-242.
- Sobesky R, Mathurin P, Charlotte F, et al. Modeling the impact of interferon alpha treatment on liver fibrosis progression in chronic hepatitis C: a dynamic view. *Gastroenterology.* 1999;116:378-386.
- Duchatelle V, Marcellin P, Giostra E, et al. Changes in liver fibrosis at the end of alpha interferon therapy and 6 to 18 months later in patients with chronic hepatitis: quantitative assessment by a morphometric method. *J Hepatol.* 1998;29:20-28.
- Dufour J-F, DeLellis R, Kaplan MM. Reversibility of hepatic fibrosis in autoimmune hepatitis. *Ann Intern Med.* 1997;127:981-985.

24. International Working Party. Terminology of nodular hepatocellular lesions. *Hepatology*. 1995;22:983-994.
25. Bianchi L, Gudan F. Sanded nuclei in hepatitis B. *Lab Invest*. 1976;35:1-5.
26. Moreno A, Ramon Y, Cajal S, et al. Sanded nuclei in delta patients. *Liver*. 1989;9:367-371.
27. Chu C-M, Liaw Y-F. Intrahepatic distribution of hepatitis B surface and core antigens in chronic hepatitis B virus infection: hepatocytes with cytoplasmic/membranous hepatitis B core antigen as a possible target for immunohistochemistry. *Gastroenterology*. 1987;92:220-225.
28. Chisari FV, Ferrari C. Hepatitis B virus immunopathology. *Springer Semin Immunopathol*. 1995;17:261-281.
29. Negro F, Pacchioni D, Mondardini A, et al. In situ hybridization in viral hepatitis. *Liver*. 1992;12(special issue):217-226.
30. Keeffe E. Is hepatitis A more severe in patients with chronic hepatitis B and other chronic liver diseases? *Am J Gastroenterol*. 1995;90:201-205.
31. Pontisso R, Ruvoletto MG, Fattovich G, et al. Clinical and virological profiles in patients with multiple hepatitis virus infections. *Gastroenterology*. 1993;105:1529-1533.
32. Zarski J-P, Bohn B, Bastie A, et al. Characteristics of patients with dual infection by hepatitis B and C viruses. *J Hepatol*. 1998;28:27-33.
33. Liaw Y-F, Tsai S-L, Sheen IS, et al. Clinical and virological course of chronic hepatitis B virus infection with hepatitis C and D virus markers. *Am J Gastroenterol*. 1998;93:354-359.
34. Liaw Y-F. Role of hepatitis C virus in dual and triple hepatitis virus infection. *Hepatology*. 1995;22:1101-1108.
35. Colin J-F, Cazals-Hatem D, Lioriot MA, et al. Influence of human immunodeficiency virus infection in chronic hepatitis B in homosexual men. *Hepatology*. 1999;29:1306-1310.
36. Bianchi L, Desmet VJ, Popper H, et al. Histologic patterns of liver disease in hemophiliacs with special reference to morphologic characteristic of non-A, non-B hepatitis. *Semin Liver Dis*. 1987;7:203-209.
37. Lefkowitz JH, Apfelbaum TF. Non-A, non-B hepatitis: characterization of liver biopsy pathology. *J Clin Gastroenterol*. 1989;11:225-232.
38. Czaja AJ, Carpenter HA, Santrach PJ, et al. Host- and disease-specific factors affecting steatosis in chronic hepatitis C. *J Hepatol*. 1998;29:198-206.
39. Czaja AJ, Carpenter HA. Histological findings in chronic hepatitis C with autoimmune features. *Hepatology*. 1997;26:459-466.
40. Emile JF, Sebah M, Féray C, et al. The presence of epithelioid granulomas in hepatitis C virus-related cirrhosis. *Hum Pathol*. 1993;24:1095-1097.
41. Goldin RD, Levine TS, Foster GR, et al. Granulomas and hepatitis C. *Histopathology*. 1996;28:265-267.
42. Veerabagu MP, Finkelstein SD, Rabinovitz M. Granulomas in a patient with chronic hepatitis C treated with interferon-alpha. *Dig Dis Sci*. 1997;42:1445-1448.
43. Okuno T, Arai K, Matsumoto M, et al. Epithelioid granulomas in chronic hepatitis C: a transient pathological feature. *J Gastroenterol Hepatol*. 1995;10:532-537.
44. Sebah M, Farges O, Emile J-F, et al. An unusual pattern of hepatitis C virus infection in a liver allograft. *Histopathology*. 1995;27:190-192.
45. Harada K, Minato H, Hiramatsu K, et al. Epithelioid cell granulomas in chronic hepatitis C: immunohistochemical character and histological marker of favorable response to interferon-alpha therapy. *Histopathology*. 1998;33:216-221.
46. Hu B, French SW. Mallory body and empty cell in hepatitis C. *Hepatol Res*. 1997;8:13-20.
47. Barton AL, Banner BF, Cable EE, et al. Distribution of iron in the liver predicts the response of chronic hepatitis C infection to interferon therapy. *Am J Clin Pathol*. 1995;103:419-424.
48. Ikura Y, Morimoto H, Johmura H, et al. Relationship between iron deposits and response to interferon in chronic hepatitis C. *Am J Gastroenterol*. 1996;91:1367-1373.
49. Kazemi-Shirazi L, Datz C, Maier-Dobersberger T, et al. The relation of iron status and hemochromatosis gene mutations in patients with chronic hepatitis C. *Gastroenterology*. 1999;116:127-134.
50. Bonkovsky HL, Banner BF, Rothman AL. Iron and chronic viral hepatitis. *Hepatology*. 1997;25:759-768.
51. Gonzalez-Peralta RP, Lau JYN. Pathogenesis of hepatocellular damage in chronic hepatitis C infection. *Semin Gastrointest Dis*. 1995;6:28-34.
52. Nelson DR, Lau JYN. Pathogenesis of hepatocellular damage in chronic hepatitis virus infection. *Clin Liver Dis*. 1997;1:515-528.
53. Dries V, von Both I, Müller M, et al. Detection of hepatitis C virus in paraffin-embedded liver biopsies of patients negative for viral RNA in serum. *Hepatology*. 1999;29:223-229.
54. Brody RI, Eng S, Melamed J, et al. Immunohistochemical detection of hepatitis C antigen by monoclonal antibody TORDJI-22 compared with PCR viral detection. *Am J Clin Pathol*. 1998;110:32-37.
55. Vartanian RR, Dupuis B, Rock N, et al. Nonspecificity of the novel paraffin-reactive hepatitis C virus, clone TORDJI-22. *Lab Invest*. 1996;74:138A.
56. Doughty AL, Painter DM, McCaughan GW. Nonspecificity of monoclonal antibody Tordji-22 for the detection of hepatitis C virus in liver transplant recipients with cholestatic hepatitis. *Liver Transpl Surg*. 1999;5:40-45.
57. Vento S, Garofano T, Renzini C, et al. Fulminant hepatitis associated with hepatitis A virus superinfection in patients with chronic hepatitis C. *N Engl J Med*. 1998;338:286-290.
58. Mele A, Tosti ME, Stroffolini T. Hepatitis associated with hepatitis A superinfection in patients with chronic hepatitis C [letter]. *N Engl J Med*. 1998;338:1771.
59. Spengler U, Rockstroh JK. Hepatitis C in the patient with human immunodeficiency virus infection. *J Hepatol*. 1998;29:1023-1030.
60. Gordon SC, Elloway RS, Long JC, et al. The pathology of hepatitis C as a function of mode of transmission: blood transfusion vs intravenous drug use. *Hepatology*. 1993;18:1338-1343.
61. Zein NN, Rakela J, Krawitt EL, et al. Hepatitis C virus in the United States: epidemiology, pathogenicity, and response to interferon therapy. *Ann Intern Med*. 1996;125:634-639.
62. Zeuzem S, Franke A, Lee J-H, et al. Phylogenetic analysis of hepatitis C virus isolates and their correlation to viremia, liver function tests, and histology. *Hepatology*. 1996;24:1003-1009.
63. Alter HJ, Nakatsuji Y, Melpolder J, et al. The incidence of transfusion-associated hepatitis G virus infection and its relation to liver disease. *N Engl J Med*. 1997;336:747-754.

64. Batts KP. Hepatitis G: a virus in search of a disease. *Am J Clin Pathol.* 1997;108:616-618.
65. Mphahlele MJ, Lau GKK. HGV: the identification, biology and prevalence of an orphan virus. *Liver.* 1998;18:143-155.
66. Yashina TL, Favorov MO, Khudyakov YE, et al. Detection of hepatitis G virus (HGV) RNA: clinical characteristics of acute HGV infection. *J Infect Dis.* 1997;175:1302-1307.
67. Alter MJ, Gallagher M, Morris TT, et al. Acute non-A-E hepatitis in the United States and the role of hepatitis G virus infection. *N Engl J Med.* 1997;336:741-746.
68. Bralet M-P, Roudot-Thoraval F, Pawlotsky J-M, et al. Histopathologic impact of GB virus C infection on chronic hepatitis C. *Gastroenterology.* 1997;112:188-192.
69. Goldstein NS, Underhill J, Gordon SC, et al. Comparative histologic features of liver biopsy specimens with hepatitis G and C viruses with chronic hepatitis C virus alone: an age-, sex-, disease duration-, and transmission-matched controlled study of chronic hepatitis. *Am J Clin Pathol.* 1997;108:625-632.
70. Inoue K, Yoshida M, Sekiyama, et al. Possible association between serum GB virus C RNA level and disease activity in fulminant hepatitis type G. *J Hepatol.* 1999;30:801-806.
71. Simmonds P, Davidson F, Lycett C, et al. Detection of a novel DNA virus (TTV) in blood donors and blood products. *Lancet.* 1998;352:191-195.
72. Charlton M, Poterucha J, Zein N, et al. TT-virus in North American blood donors, patients with fulminant hepatic failure, and cryptogenic cirrhosis. *Hepatology.* 1998;28:839-842.
73. Ikeda H, Takasu M, Inoue K, et al. Infection with an unenveloped DNA virus (TTV) in patients with acute or chronic liver disease of unknown etiology and in those positive for hepatitis C virus RNA. *J Hepatol.* 1999;30:205-212.
74. Naoumov NV, Petrova EP, Thomas MG, et al. Presence of a newly described DNA virus (TTV) in patients with liver disease. *Lancet.* 1998;352:195-197.
75. Thursz MR, Thomas HC. Host factors in chronic viral hepatitis. *Semin Liver Dis.* 1997;17:345-350.
76. Rosman AS, Waraich A, Galvin K, et al. Alcoholism is associated with hepatitis C but not hepatitis B in an urban population. *Am J Gastroenterol.* 1996;91:198-205.
77. Schiff ER. Hepatitis C and alcohol. *Hepatology.* 1997;26(suppl 1):39S-42S.
78. Wiley TE, McCarthy M, Breidl L, et al. Impact of alcohol on the histological and clinical progression of hepatitis C infection. *Hepatology.* 1998;20:805-809.
79. Miller M, Crippin JS, Klintmalm G. End stage liver disease in a 13-year old secondary to hepatitis C and hemochromatosis. *Am J Gastroenterol.* 1996;91:1427-1429.
80. Navas S, Bosch O, Castillo I, et al. Porphyria cutanea tarda and hepatitis C and B virus infections: a retrospective study. *Hepatology.* 1995;21:279-284.
81. Fargion S, Piperno A, Cappellini MD, et al. Hepatitis C virus and porphyria cutanea tarda: evidence of a strong association. *Hepatology.* 1992;16:1322-1362.
82. Bonkovsky HL, Poh-Fitzpatrick M, Pimstone M, et al. Porphyria cutanea tarda, hepatitis C and HFE gene mutations in North America. *Hepatology.* 1998;27:1661-1699.
83. Sheikh MY, Eber BB. Dramatic resolution of skin lesions associated with porphyria cutanea tarda after interferon-alpha therapy in a case of chronic hepatitis C. *Dig Dis Sci.* 1998;43:529-533.
84. Lenzi M, Ballardini G, Fusconi M, et al. Type 2 autoimmune hepatitis and hepatitis C virus infection. *Lancet.* 1990;335:258-259.
85. Garson JA, Lenzi M, Ring C, et al. Hepatitis C viraemia in adults with type 2 autoimmune hepatitis. *J Med Virol.* 1991;34:223-226.
86. Todros L, Touscoz G, D'Urso N, et al. Hepatitis C virus-related chronic liver disease with autoantibodies to liver-kidney microsomes (LKM). *J Hepatol.* 1991;13:128-131.
87. Giostra F, Manzin A, Lenzi M, et al. Low hepatitis C viremia in patients with anti-liver/kidney microsomal antibody type 1 positive chronic hepatitis. *J Hepatol.* 1996;25:433-438.
88. Reddy KR, Krawitt EL, Homberg J-C, et al. Absence of anti-LKM-1 antibody in hepatitis C viral infection in the United States of America. *J Viral Hepat.* 1995;2:175-179.
89. Abuaf N, Johenet C, Chretien P, et al. Characterization of the liver cytosol antigen type 1 reacting with autoantibodies in chronic active hepatitis. *Hepatology.* 1992;16:892-898.
90. Vento S, Cainelli F, Renzini C, et al. Autoimmune hepatitis type 2 induced by HCV and persisting after viral clearance. *Lancet.* 1997;350:1298-1299.
91. Zein NN, Persing DH, Czaja AJ. Viral genotypes as determinants of autoimmune expression in chronic hepatitis C. *Mayo Clin Proc.* 1999;74:454-460.
92. Clifford BD, Donahue D, Smith L, et al. High prevalence of serological markers of autoimmunity in patients with chronic hepatitis C. *Hepatology.* 1995;21:613-619.
93. Gregorio GV, Jones H, Choudhuri K, et al. Autoantibody prevalence in chronic hepatitis B virus infection: effect of interferon alfa. *Hepatology.* 1996;24:520-523.
94. Johnson PJ, McFarlane IG. Meeting report: International Autoimmune Hepatitis Group. *Hepatology.* 1993;18:998-1005.
95. Dienes HP, Gerken G, Lohse AW, et al. In: Berg P, Lohse AW, Tiegs G, et al, eds. *Autoimmune Liver Disease.* Dordrecht, the Netherlands: Kluwer Academic Publishers; 1997:80-85.
96. Lefkowitz JH, Apfelbaum TF, Weinberg L, et al. Acute liver biopsy lesions in early autoimmune ("lupoid") chronic active hepatitis. *Liver.* 1984;4:379-386.
97. Amontree JS, Stuart TD, Bredfeldt JE. Autoimmune chronic active hepatitis masquerading as acute hepatitis. *J Clin Gastroenterol.* 1989;11:303-307.
98. Pratt DS, Fawaz KA, Rabson A, et al. A novel histological lesion in glucocorticoid-responsive chronic hepatitis. *Gastroenterology.* 1997;113:664-668.
99. Motoo Y, Sawabu N, Watanabe H, et al. Prolonged intrahepatic cholestasis in acute-onset, severe autoimmune hepatitis. *J Gastroenterol.* 1997;32:410-413.
100. Herzog D, Rasquin-Weber A-M, Debray D, et al. Subfulminant hepatic failure in autoimmune hepatitis type 1: an unusual form of presentation. *J Hepatol.* 1997;27:578-582.
101. Richey J, Rogers S, Van Thiel DH, et al. Giant multinucleated hepatocytes in an adult with chronic active hepatitis. *Gastroenterology.* 1977;73:570-574.
102. Bernard O, Hadchouel M, Scotto J, et al. Severe giant cell hepatitis with autoimmune hemolytic anemia in early childhood. *J Pediatr.* 1981;99:704-711.
103. Shinozaki T, Saito K, Shiraki K. HBsAg-positive giant-cell hepatitis with cirrhosis in a 10-month-old infant. *Arch Dis Child.* 1981;56:64-66.
104. Thaler H. Post-infantile giant cell hepatitis. *Liver.*

- 1982;2:393-403.
105. Thijs JC, Bosna KA, Henzen-Logmans SC, et al. Post-infantile giant cell hepatitis in a patient with multiple autoimmune features. *Am J Gastroenterol.* 1985;80:294-297.
 106. Britchard B, Sokal E, Buts JP, et al. Coombs-positive giant cell hepatitis of infancy: effect of steroids and azathioprine therapy. *Eur J Pediatr.* 1991;150:314-317.
 107. Phillips MJ, Blendis LM, Poucell S, et al. Syncytial giant cell hepatitis: sporadic hepatitis with distinctive pathological features, a severe clinical course, and paramyxoviral features. *N Engl J Med.* 1991;324:455-460.
 108. Fimmel CJ, Guo L, Compano RW, et al. A case of syncytial giant cell hepatitis with features of a paramyxoviral infection. *Am J Gastroenterol.* 1998;93:1931-1937.
 109. Devaney K, Goodman ZD, Ishak KG. Post-infantile giant-cell transformation in hepatitis. *Hepatology.* 1992;16:327-333.
 110. Lau JYN, Koukoulis G, Mieli-Vergani G, et al. Syncytial giant-cell hepatitis: a specific disease entity? *J Hepatol.* 1992;15:216-219.
 111. Sanna G, Faa G, Forresu S, et al. Syncytial giant cell hepatitis: a new form of chronic liver disease. *Eur J Intern Med.* 1993;4:155-158.
 112. Weinstein U, Valderrama E, Pettei M, et al. Early steroid therapy for the treatment of giant cell hepatitis with autoimmune hemolytic anemia. *J Pediatr Gastroenterol Nutr.* 1993;17:313-316.
 113. Johnson SJ, Mathew J, MacSween RNM, et al. Post-infantile giant cell hepatitis: histological and immunohistochemical study. *J Clin Pathol.* 1994;47:1022-1027.
 114. Cairns A, McMabon RFT. Giant cell hepatitis associated with systemic lupus erythematosus. *J Clin Pathol.* 1996;49:183-184.
 115. Pappo O, Yunis E, Jordan JA, et al. Recurrent and de novo giant cell hepatitis after orthotopic liver transplantation. *Am J Surg Pathol.* 1994;18:804-813.
 116. Durand F, Degott C, Sauvanet A, et al. Subfulminant syncytial giant cell hepatitis: recurrence after liver transplantation treated with ribavirin. *J Hepatol.* 1997;26:722-726.
 117. Czaja AJ, Hay JE, Rakela J. Clinical features and prognostic implications of severe corticosteroid cryptogenic chronic active hepatitis. *Mayo Clin Proc.* 1990;65:23-30.
 118. Brown J, Dourakis S, Karayannis P, et al. Seroprevalence of hepatitis C virus nucleocapsid antibodies with cryptogenic chronic liver disease. *Hepatology.* 1992;15:175-179.
 119. Sanchez-Tapias JM, Barrera JM, Costa J, et al. Hepatitis C virus infection in patients with nonalcoholic chronic liver disease. *Ann Intern Med.* 1990;112:921-924.
 120. Greeve M, Ferrell L, Kim M, et al. Cirrhosis of undefined pathogenesis: absence of evidence for unknown viruses or autoimmune processes. *Hepatology.* 1993;17:593-598.
 121. Czaja AJ, Carpenter HA, Santrach PJ, et al. The nature and prognosis of severe cryptogenic chronic active hepatitis. *Gastroenterology.* 1993;104:1755-1761.
 122. Caldwell SH, Oelsner DH, Lezzoni JC, et al. Cryptogenic cirrhosis: clinical characterization and risk factors for underlying disease. *Hepatology.* 1999;29:664-669.
 123. Goldstein NS, Kodali V-P, Gordon SC. Histologic spectrum of cryptogenic chronic liver disease and comparison with chronic autoimmune and chronic type C hepatitis. *Am J Clin Pathol.* 1995;104:567-573.
 124. Strader DB, Seeff LB. Drug-induced chronic liver disease. *Clin Liver Dis.* 1998;2:501-522.
 125. Zimmerman HJ. Drug-induced liver injury: clinical. In: Bloomer JR, Goodman ZD, Ishak KG, eds. *Clinical and Pathological Correlations in Liver Disease: Approaching the Next Millennium.* Washington, DC: Armed Forces Institute of Pathology; 1998:252-268.
 126. Sternlieb I, Scheinberg IH. Chronic hepatitis as a first manifestation of Wilson's disease. *Ann Intern Med.* 1972;76:59-64.
 127. Scott J, Gollan JL, Samourian S, et al. Wilson's disease presenting as chronic active hepatitis. *Gastroenterology.* 1978;74:645-651.
 128. Hodges JR, Millward-Sadler GH, Barbatis C, et al. Heterozygous MZ alpha₁-antitrypsin deficiency in adults with chronic hepatitis and cryptogenic cirrhosis. *N Engl J Med.* 1981;304:557-560.
 129. Propst T, Propst A, Dietze O, et al. High prevalence of viral infection in adults with homozygous and heterozygous alpha₁-antitrypsin deficiency and chronic liver disease. *Ann Intern Med.* 1992;117:641-645.
 130. Propst T, Propst A, Dietze O, et al. Alpha₁-antitrypsin deficiency and liver disease. *Dig Dis.* 1994;12:139-149.
 131. Vogel W, Propst T, Propst A, et al. Causes of liver disease in an adult population with heterozygous and homozygous alpha₁-antitrypsin deficiency. *Acta Paediatr Suppl.* 1994;393:24-26.
 132. Banner BF, Karamitsios N, Smith L, et al. Enhanced phenotypic expression of alpha₁-antitrypsin deficiency in an MZ heterozygote with chronic hepatitis C. *Am J Gastroenterol.* 1998;93:1541-1545.
 133. Scheuer PJ. Classification of chronic viral hepatitis: a need for reassessment. *J Hepatol.* 1991;13:372-374.
 134. Desmet VJ, Gerber M, Hoofnagle JH, et al. Classification of chronic hepatitis: diagnosis, grading and staging. *Hepatology.* 1994;19:1513-1520.
 135. Batts KP, Ludwig J. Chronic hepatitis: an update on terminology and reporting. *Am J Surg Pathol.* 1995;19:1409-1417.
 136. Knodell RG, Ishak KG, Black WC, et al. Formulation and application of a numerical scoring system for assessing histologic activity in asymptomatic chronic active hepatitis. *Hepatology.* 1981;1:431-435.
 137. Ishak KG, Baptista A, Bianchi L, et al. Histological grading and staging of chronic hepatitis. *J Hepatol.* 1995;22:696-699.
 138. Bedossa P, Poynard T. An algorithm for the grading of activity in chronic hepatitis C. *Hepatology.* 1996;24:289-293.

First and Only FDA Cleared Digital Cytology System

Genius™ Cervical AI

Genius™ Review Station

Genius™ Digital Imager



Empower Your Genius With Ours

Make a Greater Impact on Cervical Cancer
with the Advanced Technology of the
Genius™ Digital Diagnostics System



Click or Scan
to discover more

ADS-04159-001 Rev 001 © 2024 Hologic, Inc. All rights reserved. Hologic, Genius, and associated logos are trademarks and/or registered trademarks of Hologic, Inc. and/or its subsidiaries in the United States and/or other countries. This information is intended for medical professionals in the U.S. and other markets and is not intended as a product solicitation or promotion where such activities are prohibited. Because Hologic materials are distributed through websites, podcasts and tradeshows, it is not always possible to control where such materials appear. For specific information on what products are available for sale in a particular country, please contact your Hologic representative or write to diagnostic.solutions@hologic.com.

genius™
DIGITAL DIAGNOSTICS