Can Core Biopsy Reliably Diagnose Mucinous Lesions of the Breast?

Jun Wang, MD, PhD,[1] Aylin Simsir, MD,[1] Cecilia Mercado, MD,[2] and Joan Cangiarella, MD[1]

Key Words: Core biopsy; Breast; Mucinous

DOI: 10.1309/DTDQM4C7X8ENDQ0X

Downloaded from https://academic.oup.com/ajcp/article/127/1/124/1760318 by guest on 19 April 2024

Abstract

Mucinous lesions in the breast are uncommon. They constitute a wide spectrum of lesions ranging from extravasated mucin associated with fibrocystic change to mucinous carcinoma. There are limited data on the reliability of core biopsy in the diagnosis of mucinous lesions of the breast. We reviewed the core biopsy and surgical biopsy diagnoses in 32 mucinous lesions of the breast. We conclude that core biopsy is highly reliable for accurate diagnosis of mucinous lesions of the breast.

Mucinous lesions of the breast constitute a wide spectrum of lesions ranging from fibrocystic changes with rupture and extravasation of mucin to mucocele-like lesions (MLLs) to mucinous (colloid) carcinoma. The diagnosis of mucinous lesions on core biopsy specimens may be challenging, especially when extravasated mucin is present. An accurate diagnosis is important because subsequent management differs. Mucinous breast lesions diagnosed by core biopsy are reported infrequently in the literature. They are mainly included in reported series of breast core biopsies[1,2] or in small series of MLLs.[3,4] There is only a single report in the literature focusing specifically on the diagnosis of mucinous lesions by core biopsy.[5] In this report, a review of 15 cases led to the conclusion that the majority of mucinous lesions could be accurately diagnosed by core biopsy. More problematic is the diagnosis of MLLs on core biopsy. MLLs are defined by Rosen[6] as mucin-containing cysts lined by flat or low-cuboidal epithelium, with or without extravasated mucin. Careful examination of MLLs of the breast is recommended because of the association with atypical ductal hyperplasia (ADH) or carcinoma.[3,7]

We report the largest series of mucinous lesions diagnosed by core biopsy with the intent of evaluating the reliability of core biopsy in the diagnosis of mucinous lesions and discussing management recommendations for this heterogeneous group of breast lesions.

Materials and Methods

Breast core biopsy specimens with the terms "extravasated mucin," "mucocele," or "mucinous (colloid) carcinoma" were retrieved from the pathology computer system at New

© American Society for Clinical Pathology

York University Hospitals Center and Bellevue Hospital Center, New York, NY, from January 1991 to January 2006. Mucinous breast lesions included cases of fibrocystic change with extravasated mucin, MLLs with and without atypia, and mucinous carcinoma. The core biopsy reports were reviewed and compared with the diagnosis at subsequent surgical excision. Among the 4,577 core biopsy cases, 41 patients (0.90%) had a mucinous breast lesion diagnosed by core biopsy. Of these, 32 had excisional biopsy follow-up and form the basis of this report.

The core biopsies were performed by radiologists with expertise in breast imaging. Fourteen cores were performed using vacuum-assisted biopsy with 11-gauge needles. Twelve cores were performed with 14-gauge needles and stereotaxic (7 cases) or ultrasound (5 cases) guidance. In 6 cases, the method of biopsy was not described in the pathology report. All cores were submitted in formalin, paraffin embedded, sectioned with 3 levels, and stained with H&E. Diagnoses were grouped into 4 categories: mucinous carcinoma, MLL without atypia, MLL with atypia, and any other benign lesion with extravasated mucin. The pathology reports of core biopsies and subsequent surgical excisions were compared, and the reliability of core biopsy in mucinous lesions was examined.

Results

Mucin-containing lesions constituted 0.90% of all biopsies, higher than the 0.51% reported by Renshaw.[5] The 32 core biopsy specimens all were from women with an age range from 42 to 87 years (mean, 61 years). Radiographically, core biopsies were performed for calcifications in 9 cases and masses in 23. All patients had a single lesion, as described, and core biopsy of this lesion was obtained. Among all the core biopsies, 21 cases (66%) were diagnosed as mucinous carcinoma **Image 1**, 6 cases (19%) as MLL without epithelial atypia **Image 2**, 4 cases (13%) as MLL with ADH, and 1 case (3%) as fibrocystic change with extravasated mucin. Findings at core biopsy are summarized in **Table 1**.

The diagnosis obtained at core biopsy was unchanged at excision in 29 cases (91%). In 2 cases diagnosed as MLL without atypia, subsequent excision showed only fibrocystic changes without residual MLL. In 1 case diagnosed as MLL with atypia, subsequent biopsy showed only fibrocystic changes with ADH with no residual MLL. All cases of mucinous carcinoma were confirmed at excision. The comparison of diagnoses at core biopsy and excision is summarized in **Table 2**.

Discussion

Mucin production is seen in a variety of pathologic conditions in the breast. These include extravasated mucin in cases of fibrocystic change, MLL with and without atypia, and mucinous carcinoma. There is only a single study focusing on the diagnosis of mucinous lesions on core biopsy published in the literature.[5] This study reviewed 15 mucinous lesions on core biopsy for which surgical follow-up was available. Of these 15 cases, 8 were benign on core biopsy and 7 were malignant. In all cases, the diagnosis at core biopsy remained the same at excision. Our study of 32 mucinous lesions diagnosed by core biopsy is the largest series in the literature. In our study, all 21 cases diagnosed as mucinous carcinoma on core biopsy were confirmed at excision.

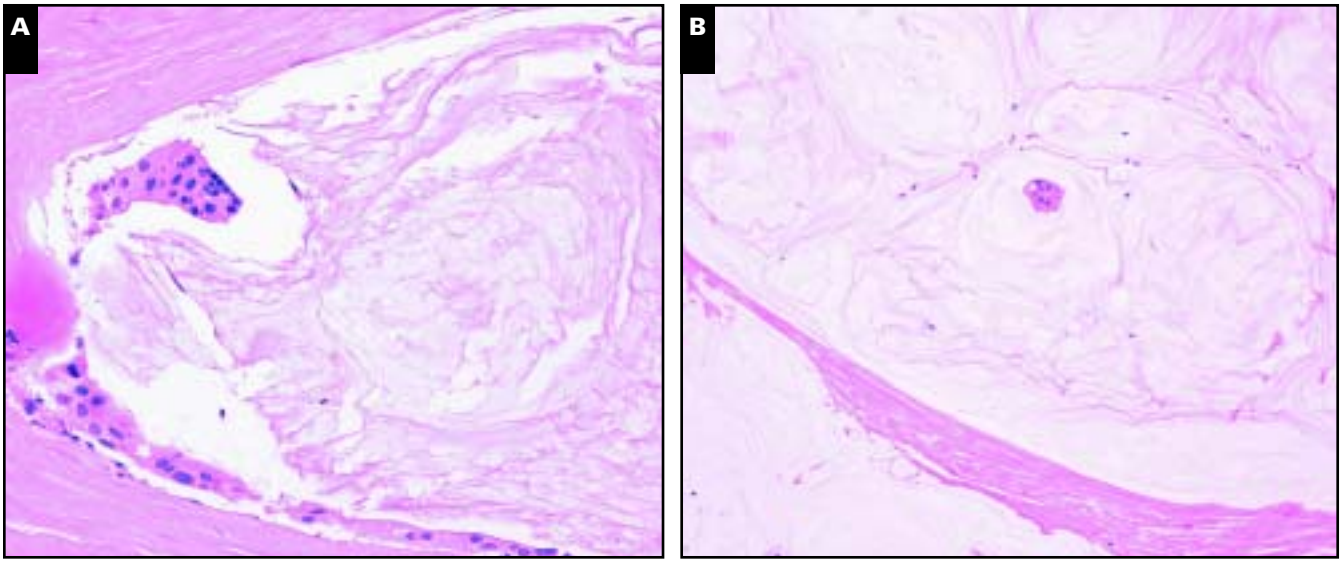

Image 1 **A**, Core biopsy specimen shows malignant clusters of epithelial cells floating in mucin diagnostic for mucinous carcinoma (H&E, ×200). **B**, The diagnosis of mucinous carcinoma is confirmed at surgical excision (H&E, ×200).

Downloaded from https://academic.oup.com/ajcp/article/127/1/124/1760318 by guest on 19 April 2024

© American Society for Clinical Pathology

DOI: 10.1309/DTDQM4C7X8ENDQ0X

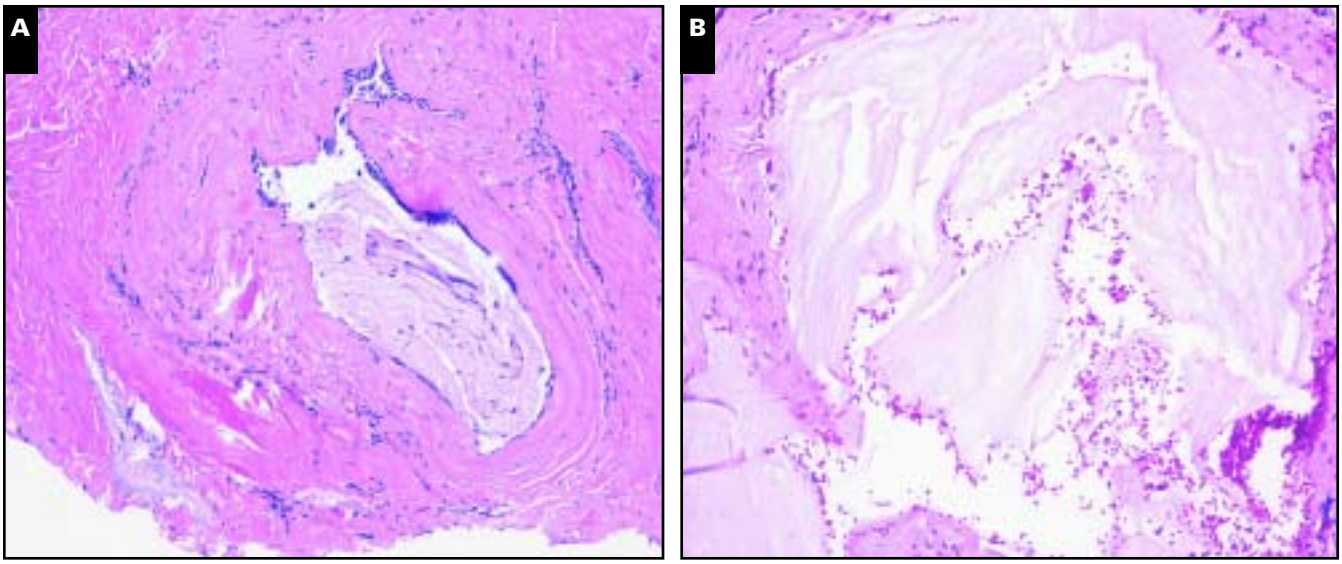

Image 2 **A**, Core biopsy specimen shows a mucocele-like lesion with dilated cysts lined by flattened epithelium with extravasated mucin (H&E, ×100). **B**, The diagnosis of mucocele-like lesion without atypia is confirmed at surgical excision (H&E, ×100).

Thus, core biopsy is reliable and accurate for the diagnosis of mucinous carcinoma of the breast.

There are few data regarding the management of patients with an MLL found on core biopsy. Jacobs et al[3] recommended surgical excision in all cases of MLL found on core biopsy based on the problem of sampling error and the possibility that MLLs, mucinous ductal carcinoma in situ, and mucinous carcinoma may represent a pathologic continuum.

Table 1
Core Biopsy Diagnoses in 32 Mucinous Lesions

Diagnosis	Number (%)
Mucinous carcinoma	21 (66)
MLL without atypia	6 (19)
MLL with atypia	4 (13)
Extravasated mucin	1 (3)
Total	32

MLL, mucocele-like lesion.

In another study, 10 cases with the core biopsy diagnosis of MLL with surgical follow-up were reviewed.[8] In 4 cases, ADH also was noted at core biopsy. Of these 4 cases, 3 showed malignancy ranging from ductal carcinoma in situ to invasive mucinous carcinoma at excision, and 1 case had ADH at excision. The 6 cases without epithelial atypia at core biopsy all proved to be benign at excision, but 2 cases had ADH. This study concluded that surgical excision is warranted following a core biopsy diagnosis of MLL. Renshaw[5] included core biopsies from 3 mucoceles and 5 mucoceles with ADH. None of these showed carcinoma at excision.

In our study, we examined 10 MLLs at core biopsy, 4 with ADH and 6 without. All cases with ADH found on core biopsy also had ADH at excision. All cases without ADH were benign at excision. No carcinoma was seen at excision in any of the cases of MLL (with or without atypia) at excision. In 3 of our cases of MLL diagnosed by core biopsy, only fibrocystic changes were seen at excision. The core biopsy specimens

Table 2
Comparison of Core Biopsy and Excisional Biopsy Diagnoses in 32 Mucinous Lesions

	Diagnosis at Surgical Excision				
Diagnosis at Core Biopsy	Mucinous Carcinoma	MLL Without Atypia	MLL With ADH	Fibrocystic Changes With ADH	Benign Fibrocystic Change
Mucinous carcinoma	21	0	0	0	0
MLL without atypia	0	4	0	0	2
MLL with ADH	0	0	3	1	0
Extravasated mucin	0	0	0	0	1

ADH, atypical ductal hyperplasia; MLL, mucocele-like lesion.

Downloaded from https://academic.oup.com/ajcp/article/127/1/124/1760318 by guest on 19 April 2024

DOI: 10.1309/DTDQM4C7X8ENDQ0X
© American Society for Clinical Pathology

in these cases showed mucin-containing cysts with extravasation of mucin; however, at excision, no extravasation of mucin was seen and these were characterized as fibrocystic change. Based on these studies, a core biopsy showing an MLL with atypia should be removed owing to the small risk of carcinoma at excision. However, the diagnosis of an MLL without atypia may not require surgical excision. Further studies are needed.

We present the largest series of mucinous lesions diagnosed by core biopsy. Core biopsy is reliable for diagnosing mucinous lesions of the breast. A diagnosis of mucinous carcinoma on core biopsy was confirmed at excision in all cases. Although it is possible that in a patient with mucinous carcinoma a core biopsy may detect only mucin without any epithelial atypia, the available data suggest that in practice, this is extremely rare. As a result, until further data become available, we suggest it would be prudent to discuss this possibility with a patient in this situation but it does not seem necessary to excise every mucinous lesion detected by core biopsy.

From the Departments of [1]Pathology and [2]Radiology, New York University School of Medicine, New York, NY.

Address reprint requests to Dr Cangiarella: Dept of Pathology, New York University Hospitals Center, 530 First Avenue, Skirball Suite 10U, New York, NY 10016.

References

1. Janes RH, Bouton MS. Initial 300 consecutive stereotactic core-needle biopsies by a surgical group. *Am J Surg*. 1994;168:533-536.
2. Parker SH, Jobe WE, Dennis MA, et al. US-guided automated large-core needle biopsy *Radiology*. 1983;187:507-511.
3. Jacobs TW, Connolly JL, Schnitt SJ. Nonmalignant lesions in breast core needle biopsies: to excise or not to excise? *Am J Surg Pathol*. 2002;26:1095-1110.
4. Farshid G, Pieterse S, King KM, et al. Mucocele-like lesions of the breast: a benign cause for indeterminate or suspicious mammographic microcalcifications. *Breast J*. 2005;11:15-22.
5. Renshaw AA. Can mucinous lesions of the breast be reliably diagnosed by core needle biopsy? *Am J Clin Pathol*. 2002;118:82-84.
6. Rosen PP. Mucocele-like tumors of the breast. *Am J Surg Pathol*. 1986;10:464-469.
7. Ro JY, Sneige N, Sahin AA, et al. Mucocelelike tumor of the breast associated with atypical ductal hyperplasia or mucinous carcinoma: a clinicopathologic study of seven cases. *Arch Pathol Lab Med*. 1991;115:137-140.
8. Carder PJ, Murphy CE, Liston JC. Surgical excision is warranted following a core biopsy diagnosis of mucocoele-like lesion of the breast. *Histopathology*. 2004;45:148-154.

Downloaded from https://academic.oup.com/ajcp/article/127/1/124/1760318 by guest on 19 April 2024

© American Society for Clinical Pathology

DOI: 10.1309/DTDQM4C7X8ENDQ0X

HOLOGIC®

First and Only FDA Cleared
Digital Cytology System

Genius™ Cervical AI

Genius™ Review Station

Genius™ Digital Imager

Empower Your Genius With Ours

Make a Greater Impact on Cervical Cancer
with the Advanced Technology of the
Genius™ Digital Diagnostics System

Click or Scan
to discover more

ADS-04159-001 Rev 001 © 2024 Hologic, Inc. All rights reserved. Hologic, Genius, and associated logos are trademarks and/or registered trademarks of Hologic, Inc. and/or its subsidiaries in the United States and/or other countries. This information is intended for medical professionals in the U.S. and other markets and is not intended as a product solicitation or promotion where such activities are prohibited. Because Hologic materials are distributed through websites, podcasts and tradeshows, it is not always possible to control where such materials appear. For specific information on what products are available for sale in a particular country, please contact your Hologic representative or write to **diagnostic.solutions@hologic.com**.

genius™
DIGITAL DIAGNOSTICS