

# A Histologically Defined Subset of High-Grade Dysplasia in Barrett Mucosa Is Predictive of Associated Carcinoma

Weijian Zhu, MD,<sup>1</sup> Henry D. Appelman, MD,<sup>1</sup> Joel K. Greenson, MD,<sup>1</sup> Stephen R. Ramsburgh, MD,<sup>1</sup> Mark B. Orringer, MD,<sup>2</sup> Andrew C. Chang, MD,<sup>2</sup> and Barbara J. McKenna, MD<sup>1</sup>

**Key Words:** Barrett esophagus; High-grade dysplasia; Esophageal adenocarcinoma; Dysplasia; Esophagectomy; Biopsy

DOI: 10.1309/AJCP78CKIOJWVFN

## Abstract

To ascertain the prevalence of carcinoma in esophagi resected for high-grade dysplasia (HGD) using current criteria and to evaluate histologic features that may predict concurrent carcinoma, we studied specimens from 127 esophagectomies performed for HGD, or HGD “suspicious” for carcinoma (HGD/S) in Barrett mucosa. Corresponding biopsy specimens in 69 cases were reviewed and reclassified.

Based on original diagnoses, carcinoma was present in 15 (17%) of 89 HGD and 28 (74%) of 38 HGD/S cases. By reclassification, only 1 (5%) of 21 cases with HGD had carcinoma in the resection specimen. Of 25 cases reclassified as HGD/S, 18 (72%) had carcinoma in the resection specimen, as did 17 (74%) of 23 reclassified as adenocarcinoma. With 1 additional select histologic feature, the risk of carcinoma was 39%; with 2 or more features, the risk increased to 83% to 88%.

Based on current criteria, no more than 5% of esophagectomies performed for a biopsy diagnosis of Barrett HGD harbor carcinoma. When HGD/S is diagnosed based on certain additional features, carcinoma is found in nearly 40% of cases with 1 feature and more than 80% with 2 or more features. Our findings highlight the evolution of diagnostic criteria for Barrett dysplasia.

Barrett esophagus is a gastroesophageal reflux-associated premalignant condition that is defined as the presence of endoscopic columnar mucosa in the lower esophagus, histologically confirmed to include goblet cells (intestinal metaplasia).<sup>1,2</sup> Development of esophageal adenocarcinoma is thought to be preceded by dysplasia in Barrett esophagus.<sup>1-4</sup> The degree of dysplasia has been shown to correlate significantly with the risk of progression to cancer and to be predictive of the presence of concurrent, unrecognized adenocarcinoma. The reported prevalence of invasive adenocarcinoma in esophagectomies undertaken for high-grade dysplasia (HGD) diagnosed on endoscopic biopsy varies from 15% to 50%.<sup>5-11</sup>

The optimal management of patients remains controversial. Currently, once a diagnosis of HGD is established, surgical resection of the esophagus is considered because of the possibility of concurrent cancer.<sup>2</sup> This view has been challenged by the results of several studies in which HGD in Barrett mucosa has been documented to be present for several years without progression to cancer. There is even the suggestion that HGD may be reversible because of its absence in subsequent biopsy specimens in some cases. Esophagectomy is considered a high-risk operation with significant morbidity and mortality,<sup>4,7,9,12-15</sup> although at the University of Michigan, Ann Arbor, where the technique of transhiatal esophagectomy without thoracotomy has been popularized, the operative mortality in the last 1,000 patients has been 1%.<sup>16</sup>

Because there are reports implying that successful eradication of HGD can be accomplished by using techniques such as endoscopic mucosal resection, laser ablation, and photodynamic therapy, some authorities recommend continued endoscopic surveillance, reserving esophagectomy for

patients with biopsy-proven invasive carcinoma.<sup>14-19</sup> To date, there are no clearly defined histologic features that reliably predict which patients with HGD will have adenocarcinoma at the time of esophagectomy. In 1 study, the extent of HGD was identified as a potential predictor for the subsequent development of adenocarcinoma,<sup>20</sup> but this finding is not supported by other published data.<sup>21</sup>

The purposes of this study were 2-fold. First, we sought to determine the prevalence of adenocarcinoma in Barrett esophagus resected for HGD based on biopsies performed at a number of institutions, using current histologic criteria for dysplasia. Because patients referred to a tertiary institution for treatment of HGD have not been followed up or evaluated in a uniform way, we did not include data about endoscopic or radiographic findings. Second, we sought to evaluate which specific morphologic features in preoperative endoscopic biopsy specimens from patients with HGD can be used to predict adenocarcinoma at the time of esophagectomy.

## Materials and Methods

Esophagectomy specimens from 127 patients who underwent resection for the indication of HGD in Barrett esophagus from 1994 to 2004 were studied to determine the prevalence of adenocarcinoma in these resection specimens. Most cases, including the biopsy specimens, had been referred from other institutions. Thus, the patients had not been biopsied according to a standard protocol, and the number and sites of biopsies varied, as they do whenever patients are referred to a tertiary care institution. Resubmission of the biopsy specimens was requested as part of the study. As a result, 69 biopsy specimens were available for review, including specimens from biopsies performed at the University of Michigan.

Gross evaluation and sampling of resection specimens was performed according to a departmental protocol that requires submission of the entire Barrett segment in cases in which carcinoma is not grossly evident. Thus, the resection specimens in these cases had the entire Barrett segments submitted for microscopy. The biopsy and resection specimens were reclassified based on the consensus of a group of 5 pathologists (W.Z., H.D.A., J.K.G., S.R.R., and B.J.M.) with long-term experience with biopsies of Barrett mucosa and its neoplastic complications. Excluded from the study were cases with original biopsy diagnoses of invasive adenocarcinoma. Medical records were reviewed for demographic information.

HGD in Barrett esophagus was defined by our current criteria, which include cytologic and architectural abnormalities. The cytologic features include epithelial cells with full-thickness nuclear stratification and/or loss of polarity, nuclear enlargement, hyperchromasia, and numerous mitotic figures.<sup>22</sup>

The architectural features include crowding of dysplastic tubules in the superficial mucosa and/or complex, budding tubules, as well as variation in size and shape of tubules.<sup>23,24</sup>

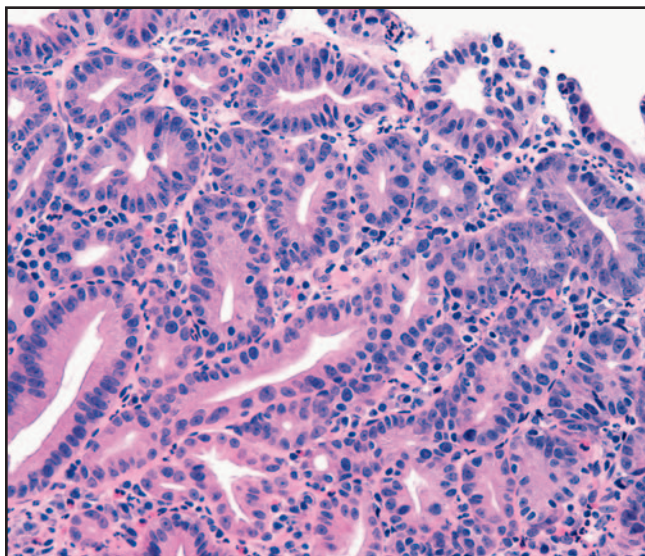
We also studied a set of additional histologic features to see if they were associated with the presence of adenocarcinoma in subsequent resection specimens. These include architecture so complex as to form solid or cribriform arrangements (defined by the presence of multiple secondary lumens within 1 glandular structure), ulcers occurring within the high-grade dysplastic mucosa, dilated dysplastic tubules containing necrotic debris, large numbers of polymorphonuclear neutrophils within high-grade dysplastic epithelium, and dysplastic tubules that become incorporated into overlying squamous epithelium **Image 1**, **Image 2**, **Image 3**, **Image 4**, **Image 5**, and **Image 6**. Based on anecdotal experience but few published data, such features, especially when multiple, led us to make a diagnosis of HGD with features “suspicious” for carcinoma (HGD/S), similar to the category of the Vienna classification system of gastrointestinal neoplasia termed *noninvasive high-grade dysplasia/suspicion of invasive carcinoma*.<sup>25</sup> The term *adenocarcinoma* was used only for invasive neoplasms, not for in situ lesions. Intramucosal carcinoma was defined as small clusters or single neoplastic cells in the lamina propria or muscularis mucosae separate from the dysplastic tubules **Image 7**. Carcinoma invading the submucosa was defined as neoplastic cells or tubules surrounded by a desmoplastic stroma **Image 8** because it has been our experience that this desmoplastic stroma only occurs when the carcinoma reaches the submucosa.

The statistical significance of the findings was analyzed by using the Student *t* or  $\chi^2$  test. *P* values less than .05 were considered significant.

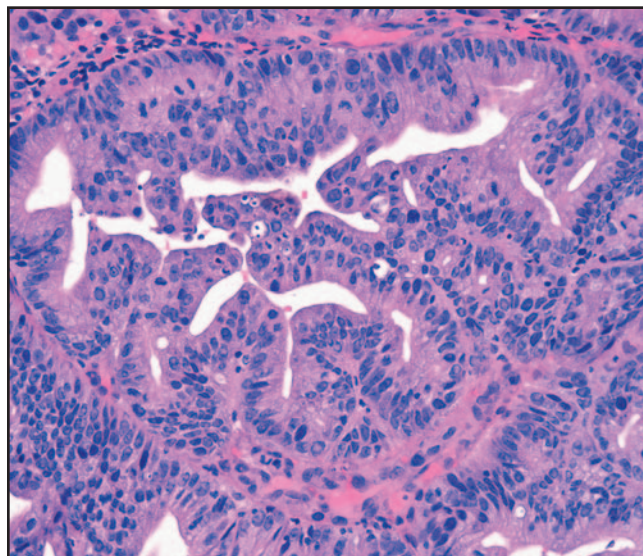
## Results

For 127 patients who underwent esophagectomy, the original preoperative biopsy diagnosis in 89 cases was HGD and in 38 cases was HGD/S. As shown in **Table 1**, 15 (17%) of 89 cases in the original HGD biopsy group had carcinoma in the resection specimen, compared with 28 (74%) of 38 in the original HGD/S group (*P* < .001). Of the 89 cases in the original HGD group, 67 (75%) had HGD confirmed in the resection but did not have carcinoma.

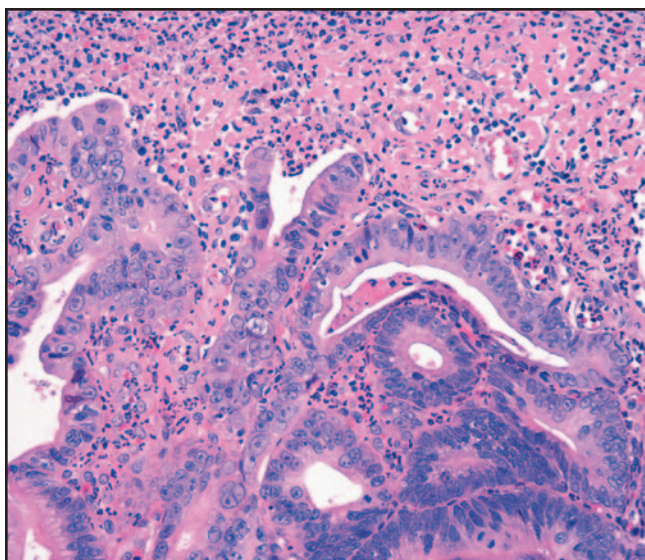
We were able to obtain, review, and reclassify, based on the criteria outlined in the “Materials and Methods” section, 69 of 127 preoperative biopsy specimens, and we compared these diagnoses with those for the corresponding resection specimens, also reviewed and reclassified. As summarized in **Table 2**, of the 69 preoperative biopsy specimens, 21 were reclassified as HGD, 25 as HGD/S, and 23 as adenocarcinoma. Of the 21 cases reclassified as HGD, only 1 (5%) had an invasive



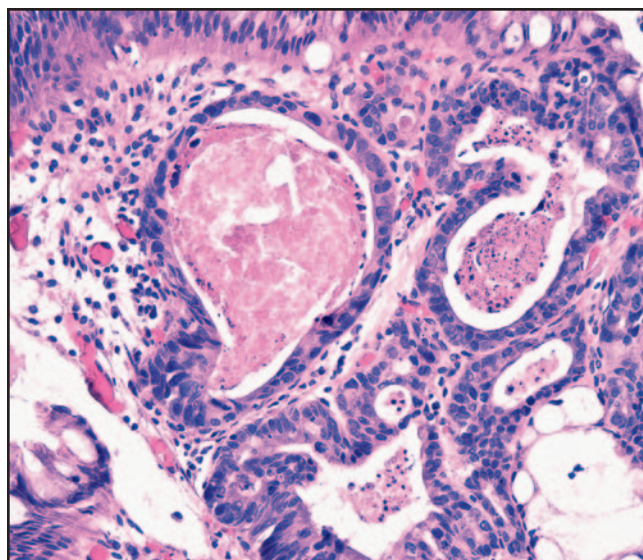
**Image 1** Barrett mucosa with high-grade dysplasia. Surface epithelium and underlying crowded but separate tubules are lined by cells with cytologically high-grade nuclei (H&E,  $\times 200$ ).



**Image 2** Barrett mucosa with high-grade dysplasia with features suggestive of carcinoma. Cribriform architecture characterized by solid nests of dysplastic cells with multiple secondary lumens (H&E,  $\times 200$ ).



**Image 3** Barrett mucosa with high-grade dysplasia with features suggestive of carcinoma. Superficial ulcer marked by the presence of fibrinopurulent exudate adherent to the surface (H&E,  $\times 200$ ).

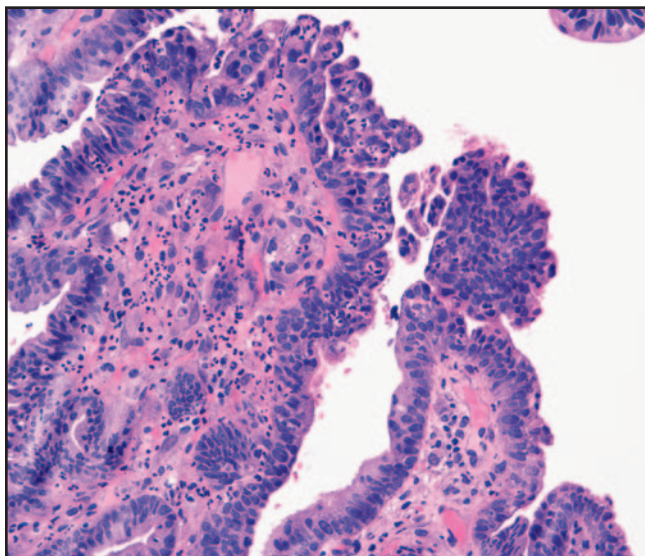


**Image 4** Barrett mucosa with high-grade dysplasia with features suggestive of carcinoma. Dilated dysplastic tubules containing granular eosinophilic and nuclear debris (H&E,  $\times 200$ ).

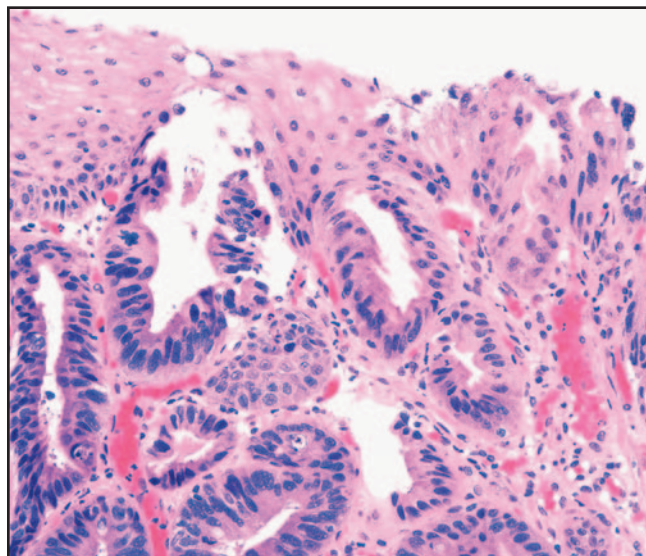
carcinoma in the subsequent resection specimen. This is a significantly lower prevalence than among 18 (72%) of 25 cases in which biopsy specimens were reclassified as HGD/S ( $P < .001$ ). Of 21 cases of a reclassified diagnosis of HGD, 16 had HGD confirmed in the resection specimen. Of the remaining 4 cases with a revised biopsy diagnosis of HGD, 1 still had foci suggestive but not diagnostic of invasive carcinoma, 2 had low-grade dysplasia, and 1 had Barrett mucosa without dysplasia in the subsequent esophagectomy specimens. When the

reclassified diagnoses of HGD and HGD/S were combined, the prevalence of invasive carcinoma was 41% (19/46), close to that previously reported for a biopsy diagnosis of HGD alone.<sup>5-9,11</sup>

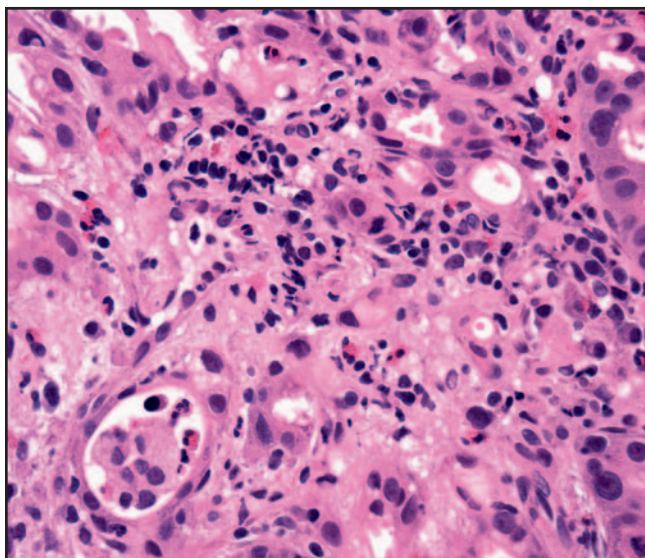
All cases with single infiltrating cells in the lamina propria ( $n = 14$ ) or desmoplasia ( $n = 2$ ), features we considered diagnostic of invasive carcinoma, had carcinoma in the subsequent resection specimen, confirming the usefulness of these features in establishing that diagnosis. The set of histologic



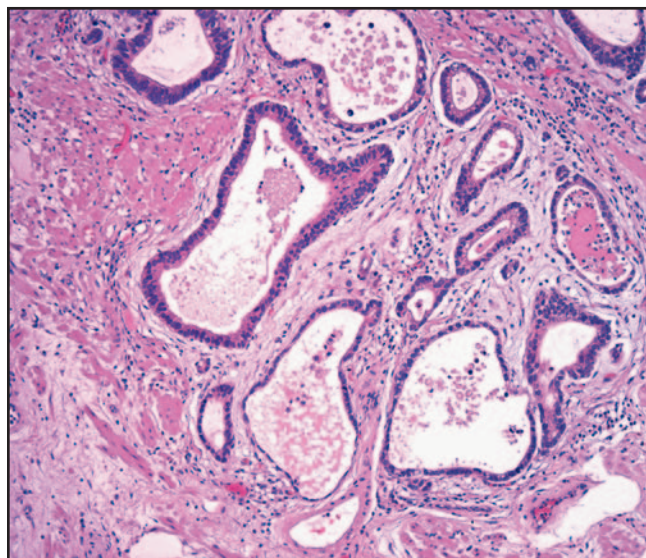
**Image 5** Barrett mucosa with high-grade dysplasia with features suggestive of carcinoma. Infiltration by numerous polymorphonuclear neutrophils (H&E, ×200).



**Image 6** Barrett mucosa with high-grade dysplasia with features suggestive of carcinoma. Dysplastic tubules appear to extend upward and be incorporated into benign squamous epithelium (H&E, ×200).



**Image 7** Invasive adenocarcinoma. Individual cells infiltrate the stroma adjacent to neoplastic tubules, indicating adenocarcinoma invading the lamina propria (H&E, ×100).



**Image 8** Invasive adenocarcinoma. Carcinomatous tubules are invested by a desmoplastic stromal reaction that appears pale owing to abundant extracellular ground substance (H&E, ×200).

features anecdotally found to be associated with adenocarcinoma was compared with the findings in esophagectomy specimens **Table 3**. Cribriform or solid tubular architecture, dilated tubules containing necrotic debris, prominent neutrophilic infiltrates in dysplastic epithelium, ulcerated HGD, and neoplastic tubules incorporated within overlying squamous epithelium were associated with adenocarcinoma in the subsequent esophagectomy specimen in 73% (33/45), 79% (23/29), 80% (16/20), 83% (19/23), and 100% (5/5), respectively.

**Table 1**  
Findings in Esophagectomy Specimens From Resection for a Biopsy Diagnosis of HGD\*

Original Biopsy Diagnosis	Original Resection Diagnosis		
	Adenocarcinoma	HGD	HGD/S
HGD (n = 89)	15 (17)	67 (75)	7 (8)
HGD/S (n = 38)	28 (74)	7 (18)	3 (8)

HGD, high-grade dysplasia; HGD/S, HGD with features “suspicious” for carcinoma. \* Data are given as number (percentage).

**Table 2**  
**Comparison of Revised Biopsy and Resection Diagnoses in 69 Cases Originally Classified as HGD\***

Revised Biopsy Diagnosis	Revised Resection Diagnosis			
	Adenocarcinoma	HGD/S	HGD	LGD and Negative for Dysplasia and Carcinoma
HGD (n = 21)	1 (5)	1 (5)	16 (76)	3 (14)
HGD/S (n = 25)	18 (72)	2 (8)	4 (16)	1 (4)
HGD + HGD/S (n = 46)	19 (41)	3 (7)	20 (43)	4 (9)
Adenocarcinoma (n = 23)	17 (74)	3 (13)	1 (4)	2 (12)

HGD, high-grade dysplasia; HGD/S, HGD with features "suspicious" for adenocarcinoma; LGD, low-grade dysplasia.

\* Data are given as number (percentage).

**Table 3**  
**Association of High-Risk Histologic Features in Preoperative Biopsy Specimens With Carcinoma in Esophagectomy Specimens\***

Histologic Feature	Carcinoma in Resection Specimen
Cribriform/solid growth	33/45 (73)
Dilated tubules/necrotic debris	23/29 (79)
Ulcerated high-grade dysplasia	19/23 (83)
Polymorphonuclear neutrophils in dysplasia	16/20 (80)
Invasion of squamous epithelium	5/5 (100)
None of above	0/16 (0)
One of above	7/18 (39)
Two of above	10/12 (83)
Three of above	13/15 (87)
Four of above	7/8 (88)

\* Data are given as number with feature/total (percentage).

Most of the time these histologic features occurred together: only 18 cases had one of these features in isolation, too few to make conclusions about the relative predictive value of each feature. Isolated cribriform architecture, dilated dysplastic tubules with necrotic debris, ulcerated dysplasia, and neutrophilic infiltrates within dysplastic epithelium were associated with carcinoma in the subsequent esophagectomy specimen in 5 of 12, 0 of 2, 1 of 1, and 1 of 3 cases, respectively. No case had isolated invasion of dysplastic tubules into squamous epithelium.

Altogether, when only 1 of these features was present in the biopsy specimen, there was carcinoma present in the subsequent resection specimen in 39% (7/18). The association with subsequent carcinoma increased to 83% (10/12) for 2 features, 87% (13/15) for 3 features, and 88% (7/8) for 4 features. In contrast, there were 16 cases without any of these features, and none of the 16 cases had carcinoma in the esophagectomy specimen.

## Discussion

During the last several decades, the incidence of esophageal adenocarcinoma has been increasing worldwide.

In the United States, the incidence has surpassed that of esophageal squamous carcinoma.<sup>1,2,26</sup> Esophageal adenocarcinoma is thought to be preceded by dysplasia arising in Barrett esophagus, a premalignant metaplasia resulting from gastroesophageal reflux disease.<sup>1-4</sup> The finding of HGD in a biopsy specimen of Barrett mucosa has been considered a marker for progression to carcinoma and for overall risk of concurrent carcinoma elsewhere in the Barrett segment. Previous studies have indicated that unrecognized adenocarcinoma is found in about 30% to 50% of esophagectomy specimens resected for a biopsy diagnosis of HGD in Barrett mucosa,<sup>5-9,11</sup> providing justification for esophageal resection in the management of HGD. Unfortunately, the data supporting these figures are up to 2 decades old and were based on histologic criteria in vogue at the time.

Newer data on the predictive value of HGD for esophageal adenocarcinoma suggest a downward trend. It has been reported that the incidence of unrecognized carcinoma in esophageal resections for HGD has declined from 43% during the 1982-1994 period to 17% during 1994-2001. It is postulated that this decline is at least partially due to current surveillance practices.<sup>10</sup> However, the extent to which differences in histologic interpretation affect these data is not clear.

The histologic diagnosis of HGD in Barrett esophagus is prone to interobserver variation, even among experienced pathologists, although the interobserver agreement is far better for HGD than it is for low-grade dysplasia.<sup>23</sup> This interobserver variation may also be a factor explaining the wide range of the prevalence of unexpected carcinoma identified in specimens from esophagectomies performed for HGD.

In the present study, a set of 69 esophageal biopsy specimens diagnosed as HGD or HGD/S during a 10-year period were reclassified according to current histologic criteria. Based on the original diagnoses, HGD was associated with unrecognized adenocarcinoma in subsequent esophagectomy specimens in 17% of cases. However, many of these biopsy specimens were reclassified as HGD/S or as carcinoma outright, resulting in only 5% of the remaining patients with a revised biopsy diagnosis of HGD having an unrecognized

carcinoma in the subsequent esophagectomy. These results suggest that we are currently better at identifying carcinoma than we were at the times the biopsy specimens were originally seen and that the decreased rate of unrecognized carcinomas in esophagectomy specimens for HGD may be a result of more accurate biopsy diagnoses. Because most cases in this study were referred from other institutions, the number of biopsies and extent of sampling varied. However, the same glass slides were used for the reclassified diagnoses as for the original diagnoses, so the improvement in recognizing carcinoma seems to be valid.

There have been a few studies attempting to find additional morphologic features to predict occult carcinoma in patients with HGD. It has been reported that patients with focal HGD are less likely to have a high risk of progression to adenocarcinoma compared with patients with diffuse HGD,<sup>20</sup> although these findings were not supported by another retrospective study.<sup>21</sup> In 1 study, the finding of ulcerated dysplasia was a predictive marker for invasive carcinoma in Barrett esophagus with HGD.<sup>27</sup>

What features are we using to diagnose or suspect carcinoma in a biopsy of Barrett mucosa? Are these valid? In this set of 69 biopsy specimens, we defined carcinoma by the presence of single cells infiltrating the lamina propria and/or a desmoplastic stroma reaction around neoplastic tubules. The finding of carcinoma in all 14 esophagectomy specimens following biopsies with single infiltrating cells and both biopsy specimens with desmoplasia validate these criteria.

The criteria that we use to indicate suspicion for invasive carcinoma consist of cribriform/solid growth, dilated dysplastic tubules containing necrotic debris, ulcerated HGD, prominent neutrophilic infiltrates within high-grade dysplastic epithelium, and dysplastic tubules that appear to be incorporated into overlying squamous epithelium. The last of these may actually be carcinoma invading the squamous epithelium, but we do not have proof that this is true. The first two of these are equivalent to features considered as suspicious for carcinoma in a recent report of interobserver variation in the diagnosis of HGD and carcinoma in Barrett esophagus.<sup>28</sup> Carcinoma was found in esophagi following biopsies with these features in 73% (33/45), 79% (23/29), 83% (19/23), 80% (16/20), and 100% (5/5), respectively, confirming our anecdotal experiences that these features are worrisome, especially when more than one is present. When only 1 of these features is present, carcinoma is found in the subsequent resection specimen in 39% (7/18) of cases. When 2, 3, or 4 are present, carcinoma is found in 83% (10/12), 87% (13/15), and 88% (7/8) of cases. Thus, one of these features alone increases the risk for cancer significantly, but 2 or more are virtually equivalent to a diagnosis of cancer. When none of these features was present, carcinoma was not found in the esophagectomy specimen (0/16). Based on these data, at the University of Michigan,

we use this set of features to diagnose biopsy specimens of Barrett mucosa as suspicious for carcinoma.

Several factors have stimulated interest in nonoperative approaches to HGD in Barrett esophagus. First, the natural course of HGD is variable. Although HGD and invasive carcinoma may be concurrent, or carcinoma may develop within a short time after the diagnosis of HGD, HGD may remain stable or even appear to regress.<sup>4,12,15</sup> Second, although esophagectomy offers the greatest likelihood of cure for cancer, it remains a technically difficult operation with mortality ranging from 3% to 5% at centers with high surgical volume and expertise to nearly 20% at low-volume centers.<sup>9,13,16</sup> Third, many patients with HGD or even intramucosal carcinoma are elderly, they have comorbid diseases that increase operative risk, or both. Fourth, endoscopic therapies are being developed that may effectively eradicate Barrett epithelium with HGD or even intramucosal carcinoma in selected patients.<sup>17-19</sup>

Ideally, all patients being followed up for Barrett esophagus would be managed in a standardized way, with adequate sampling, and pathologists evaluating their biopsy specimens would do so with full knowledge of the endoscopic, ultrasonographic, and radiographic findings. However, in reality, patient management varies greatly, and pathologists must evaluate biopsy specimens with variable clinical and endoscopic information. This is true at small community hospitals, large commercial laboratories, and many referral centers where patients arrive with biopsy specimens in hand. Whatever the management algorithm, accurate classification of surveillance biopsy specimens is important to making effective treatment decisions. Attention to the histologic features that we have identified as indicating high risk for unrecognized carcinoma should provide better information on which to base decisions about the more varied treatment options available today.

Patients with Barrett esophagus whose biopsies reveal HGD with none of the additional high-risk histologic features have a low risk of concurrent unrecognized carcinoma (5%) and may be good candidates for conservative management, including continued surveillance. On the other hand, 1 or more high-risk histologic features indicate a high likelihood of concurrent carcinoma, and this risk should be considered in weighing the operative and endoscopic therapeutic options.

*From the Departments of <sup>1</sup>Pathology and <sup>2</sup>Surgery, Section of Cardiothoracic Surgery, University of Michigan, Ann Arbor.*

*Address reprint requests to Dr McKenna: Dept of Pathology, University of Michigan, 1500 E Medical Center Dr, Ann Arbor, MI 48109-0054.*

## References

1. Cameron AJ, Ott BJ, Payne WS. The incidence of adenocarcinoma in columnar-lined (Barrett's) esophagus. *N Engl J Med.* 1985;313:857-859.

2. Wang KK, Sampliner RE. Updated guidelines 2008 for the diagnosis, surveillance, and therapy of Barrett's esophagus. *Am J Gastroenterol*. 2008;103:788-797.
3. Hamilton SR, Smith RR. The relationship between columnar epithelial dysplasia and invasive adenocarcinoma arising in Barrett's esophagus. *Am J Clin Pathol*. 1987;87:301-312.
4. Theisen J, Nigro JJ, DeMeester TR, et al. Chronology of the Barrett's metaplasia-dysplasia-carcinoma sequence. *Dis Esophagus*. 2004;17:67-70.
5. Edwards MJ, Gable DR, Lentsch AB, et al. The rationale for esophagectomy as the optimal therapy for Barrett's esophagus with high-grade dysplasia. *Ann Surg*. 1996;223:585-591.
6. Ferguson MK, Naunheim KS. Resection for Barrett's mucosa with high-grade dysplasia: implications for prophylactic photodynamic therapy. *J Thorac Cardiovasc Surg*. 1997;114:824-849.
7. Heitmiller RF, Redmond M, Hamilton SR. Barrett's esophagus with high-grade dysplasia: an indication for prophylactic esophagectomy. *Ann Surg*. 1996;224:66-71.
8. Pera M, Trastek VF, Carpenter HA, et al. Barrett's esophagus with high-grade dysplasia: an indication for esophagectomy? *Ann Thorac Surg*. 1992;54:199-204.
9. Rice TW, Falk GW, Achkar E, et al. Surgical management of high-grade dysplasia in Barrett's esophagus. *Am J Gastroenterol*. 1993;88:1832-1836.
10. Tseng EE, Wu TT, Yeo CJ, et al. Barrett's esophagus with high grade dysplasia: surgical results and long-term outcome: an update. *J Gastrointest Surg*. 2003;7:164-171.
11. Zaninotto G, Parenti AR, Ruol A, et al. Oesophageal resection for high-grade dysplasia in Barrett's oesophagus. *Br J Surg*. 2000;87:1102-1105.
12. Eckardt VF, Kanzler G, Bernhard G. Life expectancy and cancer risk in patients with Barrett's esophagus: a prospective controlled investigation [abstract]. *Am J Med*. 2001;111:33-37.
13. Levine DS, Haggitt RC, Blount PL, et al. An endoscopic biopsy protocol can differentiate high-grade dysplasia from early adenocarcinoma in Barrett's esophagus. *Gastroenterology*. 1993;105:40-50.
14. Reid BJ, Weinstein WM, Lewin KJ, et al. Endoscopic biopsy can detect high-grade dysplasia or early adenocarcinoma in Barrett's esophagus without grossly recognizable neoplastic lesions. *Gastroenterology*. 1988;94:81-90.
15. Schnell TG, Sontag SJ, Chejfec G, et al. Long-term nonsurgical management of Barrett's esophagus with high-grade dysplasia. *Gastroenterology*. 2001;120:1607-1619.
16. Orringer MB, Marshall B, Chang AC, et al. Two thousand transhiatal esophagectomies: changing trends, lessons learned. *Ann Surg*. 2007;246:363-374.
17. Barr H, Shephard NA, Dix A, et al. Eradication of high-grade dysplasia in columnar lined (Barrett's) oesophagus by photodynamic therapy with endogenously generated protoporphyrin IX. *Lancet*. 1996;348:584-585.
18. Ell C, May A, Gossner L, et al. Endoscopic mucosal resection in early cancer and high-grade dysplasia in Barrett's oesophagus. *Gastroenterology*. 2000;118:670-677.
19. Gossner L, May A, Stolte M, et al. KTP laser destruction of dysplasia and early cancer in columnar lined Barrett's esophagus. *Gastrointest Endosc*. 1999;49:8-12.
20. Buttar NS, Wang KK, Sebo TJ, et al. Extent of high-grade dysplasia in Barrett's esophagus correlates with risk of adenocarcinoma. *Gastroenterology*. 2001;120:1630-1639.
21. Dar MS, Goldblum JR, Rice TW, et al. Can extent of high grade dysplasia in Barrett's oesophagus predict the presence of adenocarcinoma at oesophagectomy? *Gut*. 2003;52:486-489.
22. Cameron AJ, Carpenter HA. Barrett's esophagus, high-grade dysplasia, and early adenocarcinoma: a pathological study. *Am J Gastroenterol*. 1997;92:586-591.
23. Reid BJ, Haggitt RC, Rubin CE, et al. Observer variation in the diagnosis of dysplasia in Barrett's esophagus. *Hum Pathol*. 1988;19:166-178.
24. Montgomery E, Bronner MP, Goldblum JR, et al. Reproducibility of the diagnosis of dysplasia in Barrett esophagus: a reaffirmation. *Hum Pathol*. 2001;32:368-378.
25. Schlemper RJ, Riddell RH, Kato Y, et al. The Vienna classification of gastrointestinal epithelial neoplasia. *Gut*. 2000;47:251-255.
26. Profumo RJ. Barrett's esophagus. *J Insur Med*. 2002;34:70-73.
27. Montgomery E, Bronner MP, Greenson JK, et al. Are ulcers a marker of invasive carcinoma in Barrett's esophagus? data from a diagnostic variability study with clinical follow-up. *Am J Gastroenterol*. 2002;97:27-31.
28. Downs-Kelly E, Mendelin JE, Bennett AE, et al. Poor interobserver agreement in the distinction of high-grade dysplasia and adenocarcinoma in pretreatment Barrett's esophagus biopsies. *Am J Gastroenterol*. 2008;103:2333-2340.

# First and Only FDA Cleared Digital Cytology System

**Genius™ Cervical AI**

**Genius™ Review Station**

**Genius™ Digital Imager**



## Empower Your Genius With Ours

**Make a Greater Impact on Cervical Cancer**  
with the Advanced Technology of the  
Genius™ Digital Diagnostics System



Click or Scan  
to discover more

ADS-04159-001 Rev 001 © 2024 Hologic, Inc. All rights reserved. Hologic, Genius, and associated logos are trademarks and/or registered trademarks of Hologic, Inc. and/or its subsidiaries in the United States and/or other countries. This information is intended for medical professionals in the U.S. and other markets and is not intended as a product solicitation or promotion where such activities are prohibited. Because Hologic materials are distributed through websites, podcasts and tradeshows, it is not always possible to control where such materials appear. For specific information on what products are available for sale in a particular country, please contact your Hologic representative or write to [diagnostic.solutions@hologic.com](mailto:diagnostic.solutions@hologic.com).

**genius™**  
DIGITAL DIAGNOSTICS