

Fat Preservation Technique of Lower-lid Blepharoplasty

This refinement of lower-lid blepharoplasty replaces bulging fat of the lower lid back into the orbit. Capsulopalpebral repair strengthens the orbital septum to retain the orbital fat in the orbit. The author describes his operative technique, focusing closely on relevant anatomy. (*Aesthetic Surg J* 2001;21:450-459.)

Lower-lid fat replacement, or repositioning, is technically straightforward and predictable in outcome. My personal experience with this procedure,¹ introduced by de la Plaza and Arroyo in 1988,² has led to the refined and standardized technique that I present here. Two major theoretic problems, the potential for vertical lid shortening and the tendency for recurrent lid bulging, can be avoided if the technique is performed as described.

The concept of replacing the bulging fat of the lower lid back into the orbit and maintaining it there by strengthening the orbital septum is appealing because it epitomizes the goal of aesthetic surgery—to restore the youthful ideal by reversing the structural changes of aging. This concept contrasts with that of standard blepharoplasty procedures that use a simple excisional and tightening approach to achieve superficial improvement.

Aesthetics and Anatomy

A youthful lid (Figure 1, A) appears to be vertically short because the lid is not flat, but concave. Furthermore, the transition from lid concavity to cheek convexity occurs high over the upper preseptal lid, not low at the infraorbital rim, as was presumed in the past. Fat excision techniques led to the assumption that the transition from lid concavity to cheek convexity occurs low at the infraorbital rim. For the cheek to appear to extend higher than the orbital rim, the fat of the lid immediately above the orbital rim must contribute to the fullness.

The capsulopalpebral fascia (a structure usually not seen by plastic surgeons) is the mirror image of the levator of

the upper lid. It approaches the orbital septum of the lower lid from its deep aspect and fuses with the upper part of the septum (Figure 1, B). Accordingly, the orbital septum of the lower lid is composed of 2 distinct parts separated by a boundary at the lower edge of the attachment of the capsulopalpebral fascia to the posterior surface of the septum (Figure 1, A and B). The upper part of the septum is reinforced by the fusion with the capsulopalpebral fascia on its posterior surface, and this conjoined structure extends for 5 to 10 mm up to the lower border of the tarsal plate. The lower part of the septum does not have the support of the capsulopalpebral fascia, and in the normal youthful eyelid, the lower part of the septum has a slight bulge.

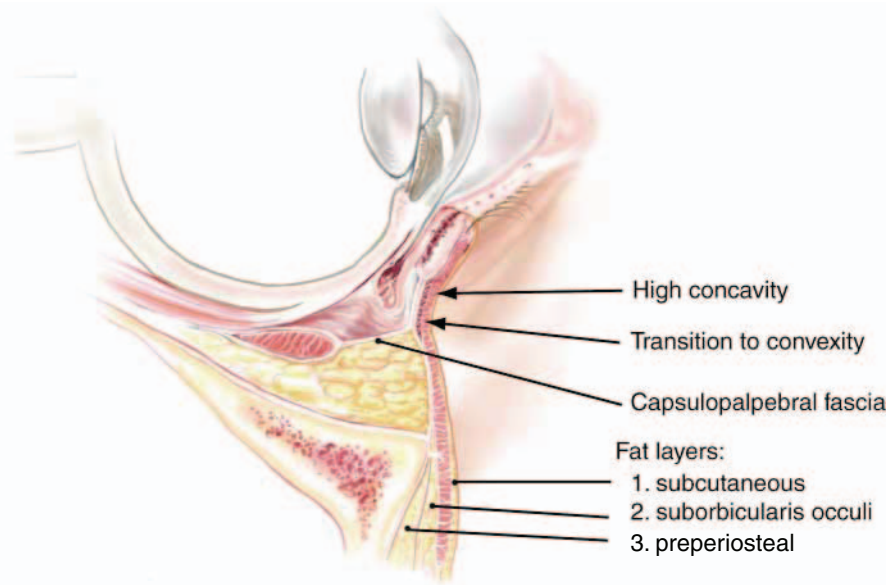
In the older or congenitally weak lower eyelid, orbital fat bulges through weaknesses of the fibrous support system of the orbit and pushes out the less reinforced part of the septum, which becomes attenuated (Figure 1, C).

Surgical repair corrects the weak and vulnerable lower part of the septum over the centromedial fat compartment by bringing the capsulopalpebral fascia and upper septum orbitale down to the inferior orbital rim, reinforcing the lower septal segment (Figure 1, D). The surgically created new septum now consists entirely of capsulopalpebral fascia-reinforced septum.

The external appearance of the lid reflects both structural components: the posterior lamella (orbital septum), orbital fat, and capsulopalpebral fascia; and the anterior lamella (skin, orbicularis oculi, and orbicularis muscle fascia). The posterior lamella is confined to the orbit proper, whereas the anterior lamella extends from the cheek onto the lid. Accordingly, aging-related changes of the orbit and the cheek alter the appearance of the lower lid. Replacing lid fat in the orbit corrects changes of the



Bryan C. Mendelson, MD, Melbourne, Australia, is a plastic surgeon and an ASAPS member.



Illustrations by William M. Winn, Atlanta, GA.

Figure 1. A. The youthful ideal is characterized by a high infratarsal concavity that overlies the upper septal segment. The lower septal segment is convex, so that the convexity of the cheek extends above the orbital rim, and the lid appears to be short.

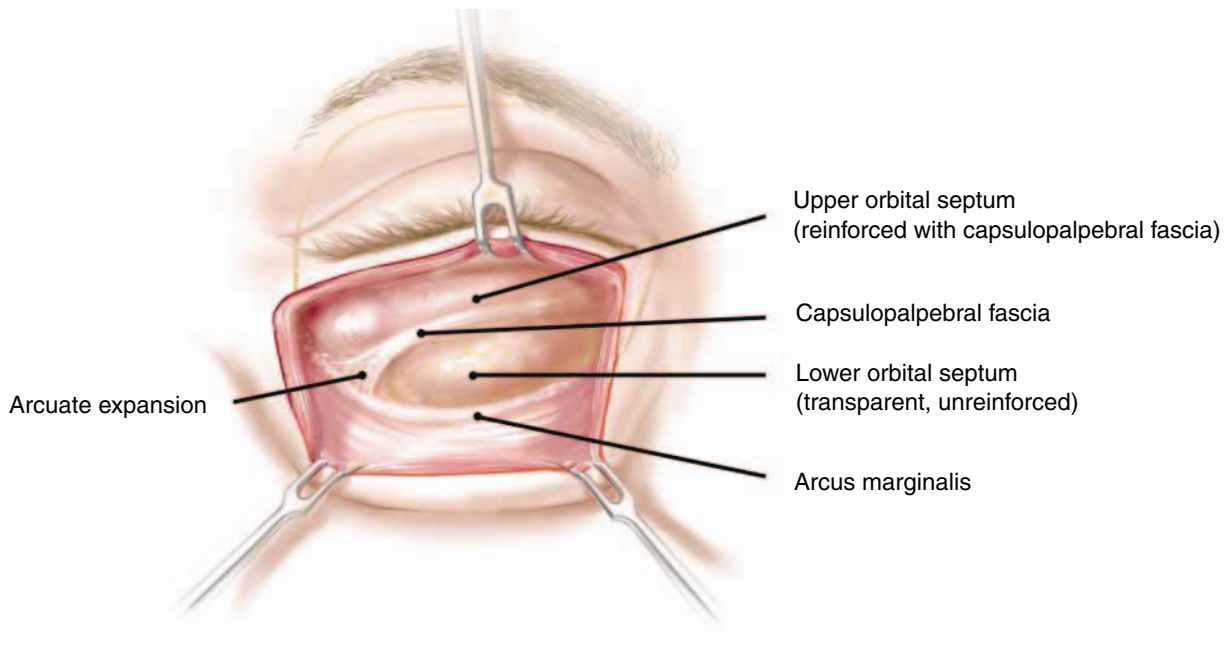


Figure 1. B. Anatomy of the posterior lamella after reflection of a skin muscle flap (anterior lamella). The septum orbitale (orbital septum) consists of 2 distinct parts demarcated by the line of attachment of the capsulopalpebral fascia. The arcuate expansion is the firm attachment of the capsulopalpebral fascia to the inferolateral orbital rim. The upper part of the septum is opaque and thick because it is reinforced by the capsulopalpebral fascia. Bulging of the lateral fat compartment appears through this layer, directly above the arcuate expansion. The lower part of the septum is thin and distensible where it overlies the medial and central fat compartments. The arcus marginalis is a distinct white fibrous thickening of the peripheral 1 to 3 mm of the orbital septum as it fuses with the periorbita and periosteum.

Figure 1. C, Aged lid in context of aged cheek. As the fat bulge increases, the resistance of the overlying orbicularis results in a mushrooming effect. The bulge toward the tarsal plate causes the lower septal segment to overlap the upper septal segment. The inferior bulging over the orbital rim is limited by the orbicularis retaining ligament, the attachment of the anterior lamella to the orbital rim periosteum. Ptosis of the soft tissue cheek mass results in loss of cheek convexity. The resulting concavity below the orbital rim exaggerates the visibility and convexity of the lid bulge.

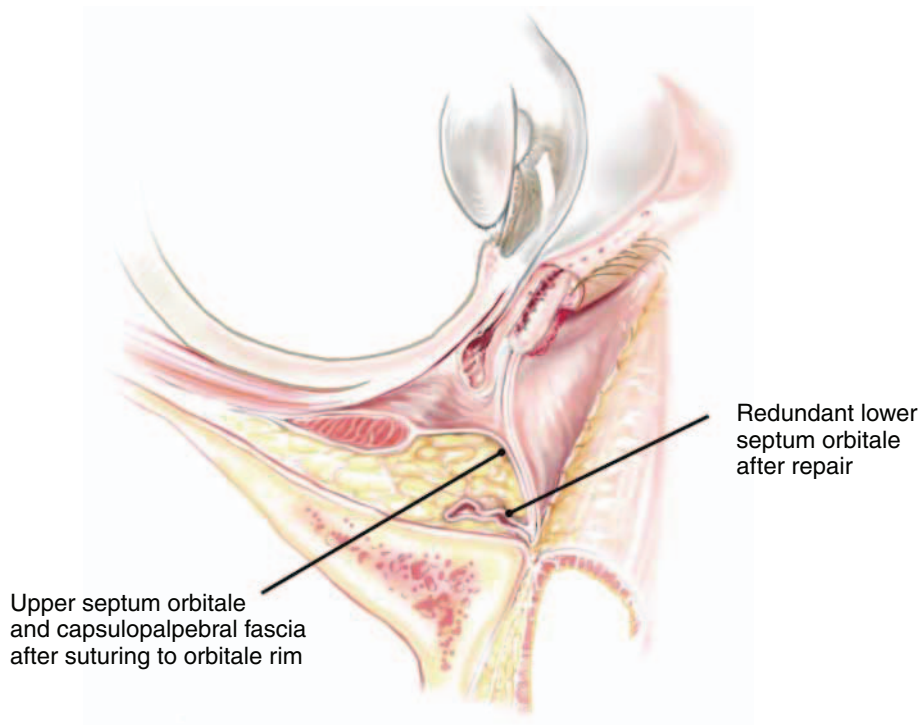
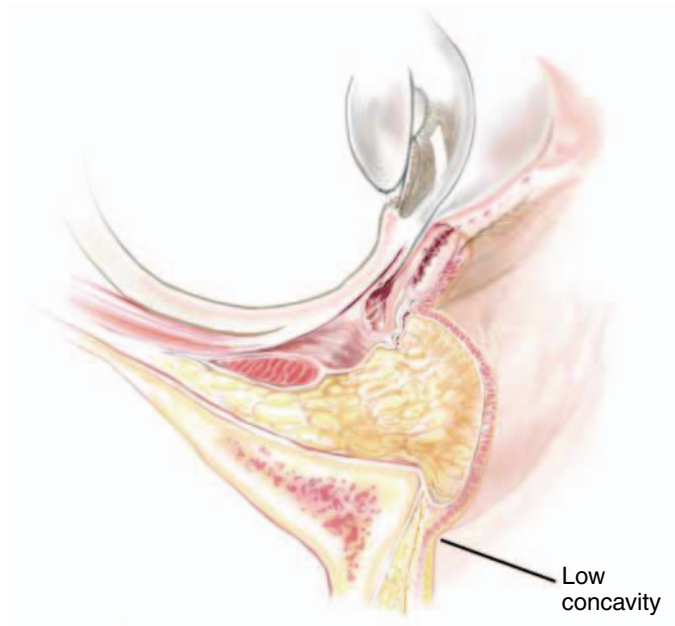


Figure 1. D, Schematic representation of reinforcement of lower septum orbitale by suturing capsulopalpebral fascia to orbital rim. The desired posterior lamella surgical result mimics the youthful ideal, with a high septal concavity and slight bulge immediately above the orbital rim.

posterior lamella only. Correcting aging changes of the anterior lamella requires a separate procedure.

In contrast to the above method is the arcus release tech-

nique³ in which the bulging orbit fat is drawn out over the orbital rim onto the cheek and is not replaced into the orbit (Figure 1, E). In the arcus release technique, orbital fat is applied to correct the contour of the upper cheek,

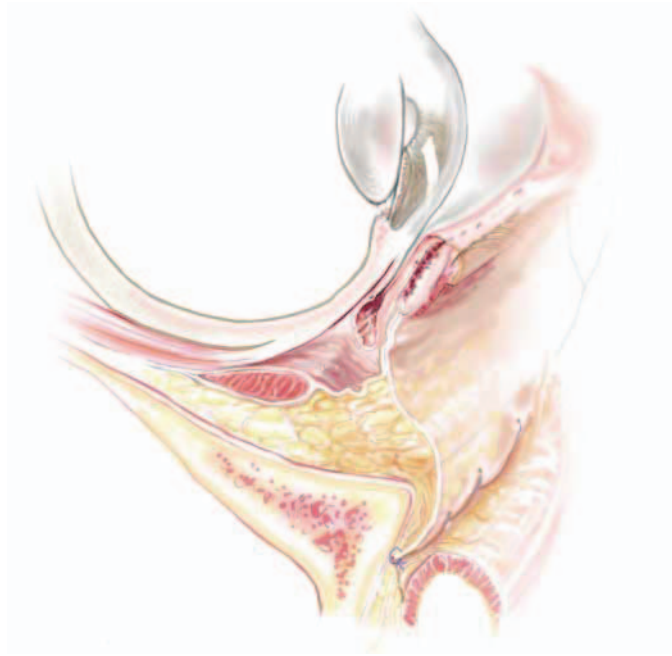


Figure 1. E. The arcus release procedure produces a similar lid shape but by a different mechanism. The lid fat is drawn over the inferior orbital rim. This ensures fullness immediately above the orbital rim, as well as compensating for the deficient soft tissue volume of the upper cheek.

partly at the expense of the posterior lamella. The fat is added to the face but not preserved in the orbit.

Resection of Lid Fat

In a standard blepharoplasty (regardless of surgical approach) in which fat is excised without restoring tension to its container, the excised fat has 2 components: first is the obvious bulging excess, and second is the safety margin of extra fat taken as insurance against recurrence. Because of the surgical gray zone between undercorrection and overresection, the tendency is to overresect.

However, there is a third component to the bulging lid fat that is not considered with excisional blepharoplasty. This is the fat that appears to be bulging because of poor tissue tone that no longer bulges when tone is restored to the lid, that is, restoration of tone within the fat compartments reduces the amount of obvious bulging fat. In addition, a proper hernia repair of the fat compartment reduces, if not eliminates, the requirement for resection of a safety margin of fat. Accordingly, restoration of lid tone is an important and underappreciated aspect of lower-lid blepharoplasty. It is achieved in varying degrees in 3 ways: canthopexy (anterior and posterior lamella),

direct posterior lamella repair, and direct anterior lamella tightening (by skin muscle flap, face lift, or deep temporal lift). It may also be achieved by a combination of the 3 techniques. The appearance of the lid is improved when tone is restored. However, at present, we do not know whether anterior or posterior lamella correction, alone or in combination, is the best way to achieve this.

Patient Selection

The most difficult part of fat-repositioning surgery is knowing the correct role of this procedure in our surgical armamentarium. Soon after this concept was reintroduced, advances in correcting aging-related changes of the periorbital region became available. Although the lid-cheek junction had been previously neglected, it now became possible to reposition the orbicularis oculi of the lower lid (anterior lamella) by using a face lift (superficial musculoaponeurotic system or subperiosteal) or deep temporal lift.

If, in the context of overall facial aging, a lid is bulging, correction of the lid alone, without correction of the upper cheek, can achieve only a partial rejuvenation. The quality of anterior lamella correction achieved by a skin muscle flap blepharoplasty is not the same as that of total

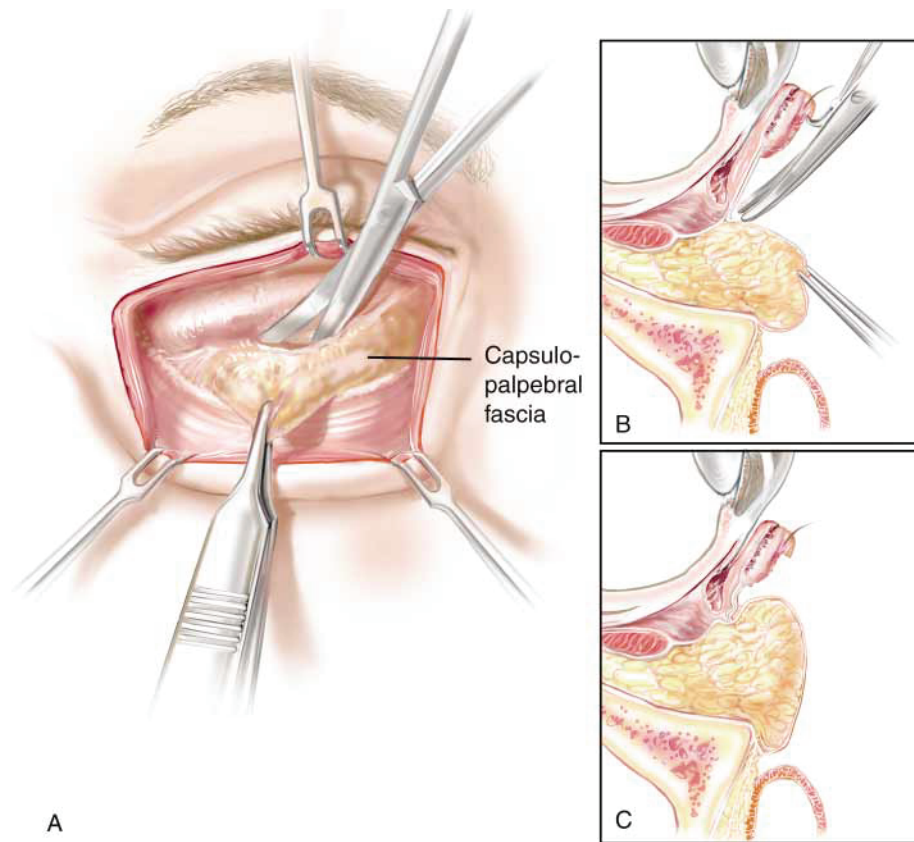


Figure 2. Technique for identification of the capsulopalpebral fascia. **A, B,** Cephalic traction with a double hook on the free margin of the lower lid provides tension to the capsulopalpebral fascia as well as the attached upper part of the septum. Simultaneous downward traction on the bulged lower septal segment facilitates blunt scissor dissection to separate the lower septal segment from the upper septal segment. The exact site at which the delicate lower part of the septum attaches to the fusion of the upper septal segment/capsulopalpebral fascia is identified. It is usually seen as a transverse white line. **C,** Parasagittal section showing attachment and pseudofusion of upper and lower septal segments. In **A** and **B** this area of fusion is being separated by spreading scissor dissection.

correction of the anterior lamella by redraping across the midcheek junction. A skin muscle flap corrects vertical laxity only; correction of transverse and oblique laxity is achieved from the cheek approach.

Accordingly, repair of the posterior lamella is most dramatically effective in the patient who does not have significant periorbital (anterior lamella) aging. When a major correction of the anterior lamella across the lid cheek junction is being performed, it is unclear whether adding posterior lamella repair provides sufficient further correction to be worthwhile; retoning of the lid, resulting from a deep temporal lift or proper face lift, may be sufficient without additional increase in tone from a posterior lamella repair.

In my practice, the ideal candidate for lower-lid fat preservation with posterior lamella tightening is the younger

patient (under 50 years) with bulging lower-lid fat for whom there is concern that the consequences of complete excision of the bulging fat may be detrimental to long-term appearance. The only contraindication is severe maxillary hypoplasia. Removal of the shelf of bulging lid fat combined with tightening of the posterior lamella in a negative vector are likely to result in malposition of the lower lid.

Operative Technique

Flap elevation and arcus identification (Figure 1, B)

Elevation of a standard lower-lid blepharoplasty skin muscle flap is the initial step. The flap is elevated right down to the inferior orbital rim. The fascia on the deep surface of orbicularis muscle does not adhere to the upper septal segment, but the orbicularis fascia is more tightly applied to the expanded lower septal segment. Therefore, the undersurface of the orbicularis fascia

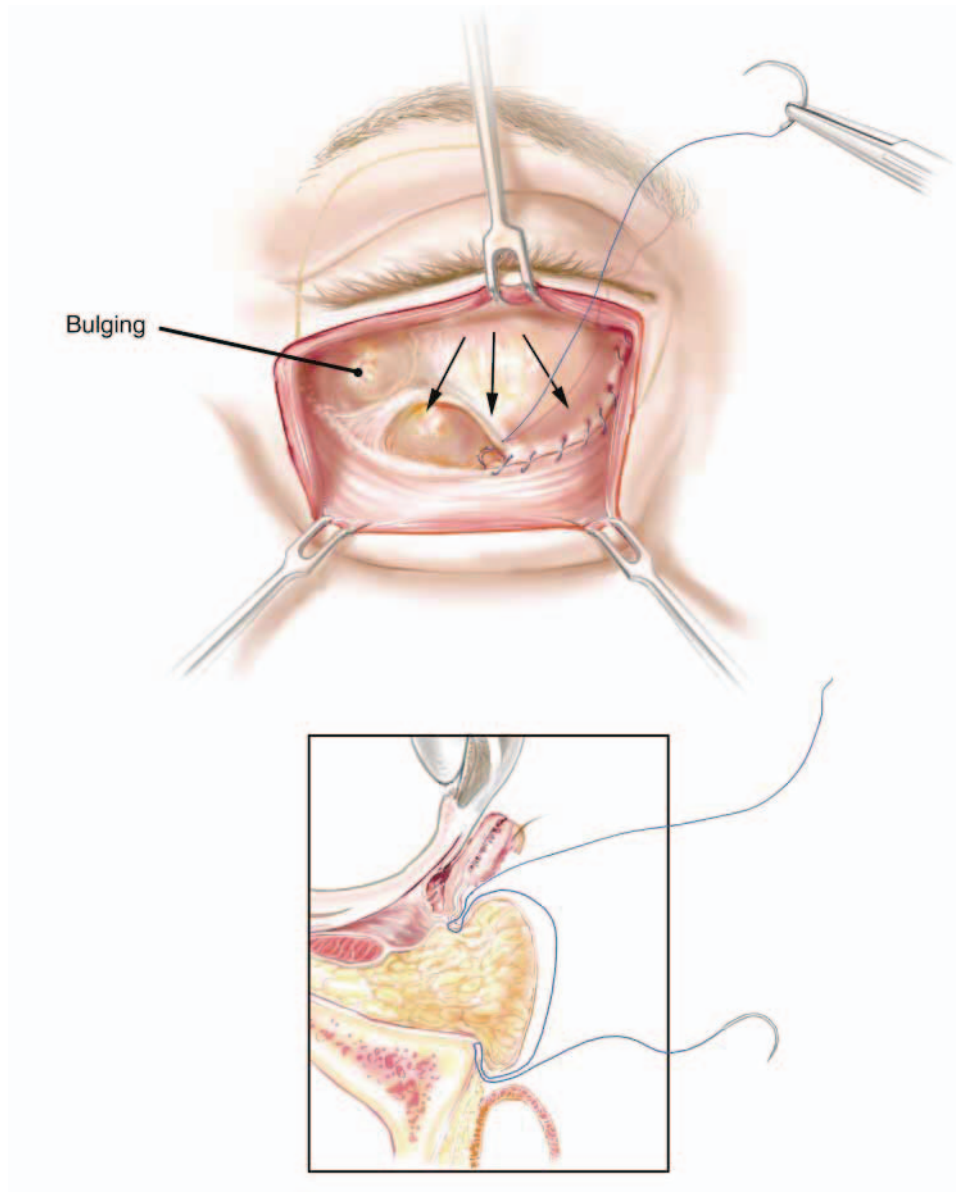


Figure 3. Suturing the centromedial compartment. The precise suture location is indicated in the inset. The upper bite is into the white line fold formed by the lower border of the capsulopalpebral fascia fusion with the upper septal segment. This septal segment reinforced by the capsulopalpebral fascia is sutured down to the arcus marginalis along the orbital rim. Repositioning the fat into the orbit increases retroseptal orbital pressure, leading to an increased bulging of the fat in the central lateral areas that are yet to be corrected.

needs to be gently peeled off the lower septal segment to preserve the integrity of the septum and to avoid spilling the orbital fat into the field.

The arcus marginalis, which should be clearly defined, is easily identifiable as white thickening at the periphery of the septum where the septum fuses with the periosteum at the orbital rim.

Identification of the capsulopalpebral fascia (Figure 2)

This step, facilitated by the correct use of traction, is not always easy but is most important. Vertical traction applied to the lid margin tightens the capsulopalpebral fascia. Simultaneous outward and downward traction applied to the bulging lower septum aids a peeling back of the lower septal segment from the upper septal segment. A distinct groove separating these 2 segments is

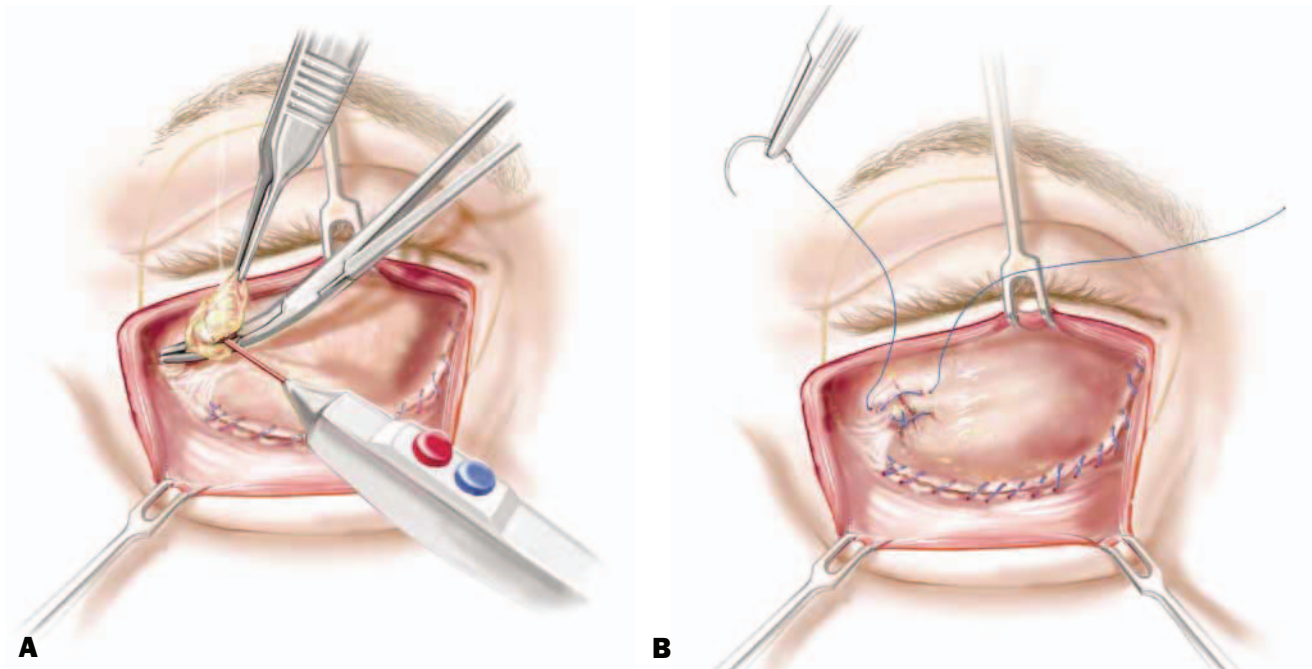


Figure 4. **A.** Graded removal of fat to avoid excessive orbital pressure is frequently required in the lateral compartment and occasionally required in the central compartment. Excessive orbital pressure appears as bulging of the new septum. **B.** Repair of the upper septal segment overlying the lateral fat compartment is performed with 2 or 3 simple sutures. These sutures pass from strong septum to strong septum on either side of the small bulge. The sutures are placed obliquely parallel to the border of the arcuate expansion.

formed by the fusion of the capsulopalpebral fascia with the posterior aspect of the septum. Frequently, a distinct white fascial fold of capsulopalpebral fascia identifies this fusion. The groove or white fold is defined laterally to where it broadens to extend down to the inferolateral orbital rim. This is the arcuate expansion of the capsulopalpebral fascia. Because the arcuate expansion is nondistensible, it contrasts with the bulging of the central and lateral fat compartments on either side and is easily identifiable. It is not necessary to open the orbital septum to reposition the bulging fat into the orbit.

Suturing of the centromedial fat compartment (Figure 3)

Use a continuous suture of 5-0 nonabsorbable monofilament on a half-circle (T30) taper needle (Novofil, Davis and Geck, Danbury, CT). Begin suturing well medial to avoid postoperative medial fat herniation. The suture approximates the white line of the mobile capsulopalpebral fascia down to the white line of the arcus marginalis along the inferior orbital rim to the site where the capsulopalpebral fascia joins the arcus marginalis at the arcuate expansion on the inferolateral orbital rim. When suturing, keep the needle point away from the branches of the infraorbital artery, which cross the orbital rim onto the septum. Bleeding inside the orbit can be a nuisance, and even a small hematoma

here can cause postoperative scar contracture of the middle lamella.

Key point 1. Vertical shortening of the lid does not occur if the suture grasps the capsulopalpebral fascia at the exact level at which it fuses with the septum. Taking the suture bite any higher up the septum is inadvisable because of the real risk of shortening the lid.

As the suturing continues and the bulging fat is returned within the confines of the orbital cavity, the pressure within the orbit increases. The increasing tension placed on the enclosed fat tends to cause it to bulge out from the part of the central compartment that is yet to be sutured. If the orbital pressure is greater, it will cause increased bulging of the lateral fat compartment.

Fat excision

At this point the surgeon must decide whether the fat is under the appropriate tension or whether excessive pressure of the fat is causing distension of the compartment.

Key point 2. The correct tension of the enclosed fat is pivotal to success because it provides tone to the posterior lamella. Excessive pressure is easy to see because it causes

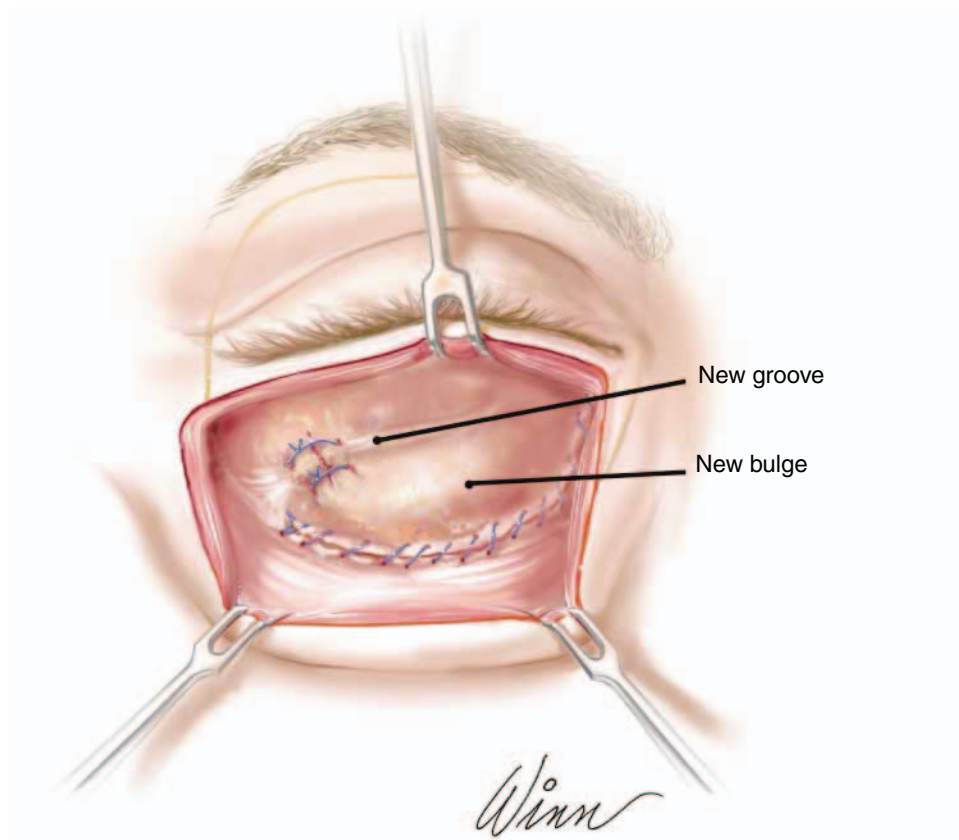
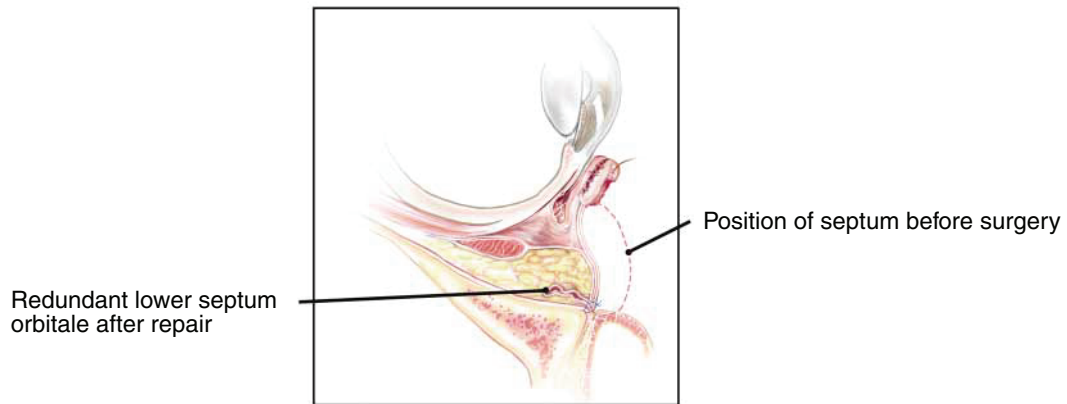


Figure 5. At completion, the reinforced upper septal segment has been drawn down to the orbital rim over the bulging fat of the centromedial compartment. The maneuver can be compared with closing a partly open window. The lower part of the septum now becomes inverted and redundant. The oblique plicating sutures not only repair the bulging lateral fat compartment, but also contour the new septum (*inset*). The line of tension creates a new groove extending toward the medial canthus and a new bulge between the groove and the inferior orbital rim. The shape of the new septum should reconstruct the shape of the ideal youthful posterior lamella.

bulging of the repaired septum and predisposes to recurrence of lid bulging. If excessive tension is present, a graded removal of fat is performed, with removal of enough fat to decompress the compartment. There is no advantage to leaving extra fat (because it causes pressure) and no advantage in resecting excess fat. When the fat compartment is near the correct tension, with or without fat

resection, closure of the compartment is completed. An exact estimation is not required at this stage, as the fine-tuning decompression is performed at the next stage by removal of lateral-compartment fat.

Suturing of the lateral compartment (Figure 4)

If the volume of fat in this compartment needs to be

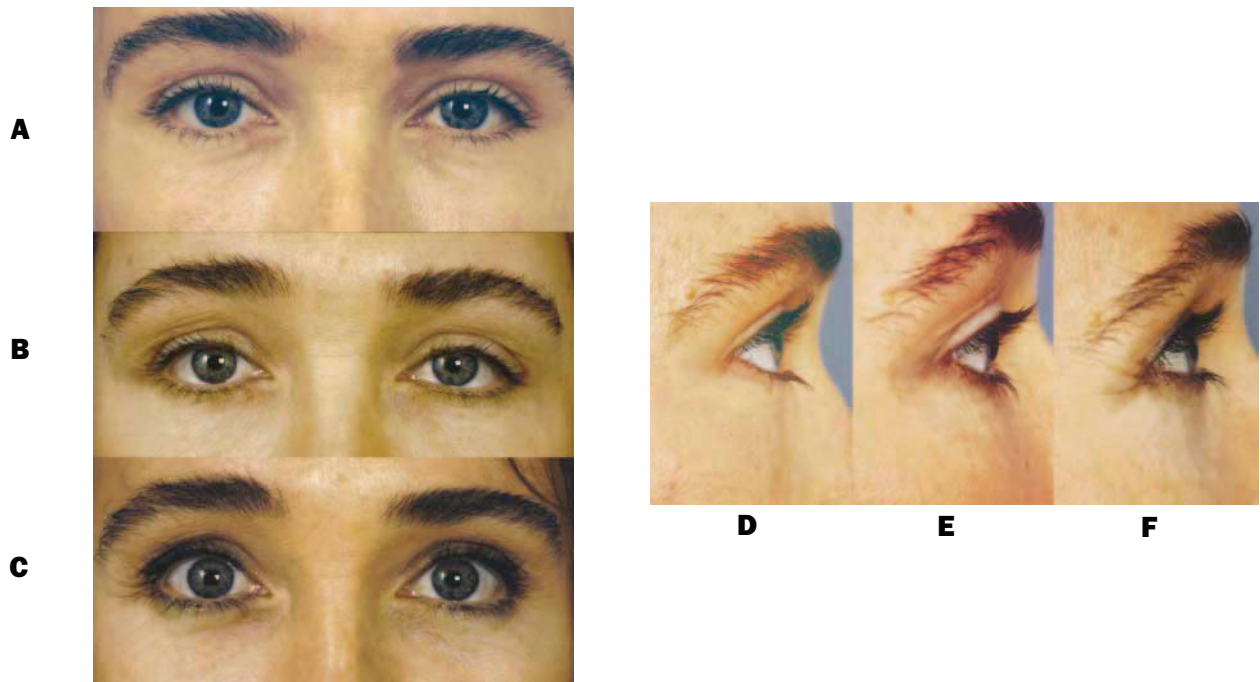


Figure 6. **A, D,** Preoperative view of a 28-year-old woman. **B, E,** Postoperative view 5 years after fat conserving lower-lid blepharoplasty. The pathology is predominately of the posterior lamella. At surgery, only a small volume of lateral compartment fat was excised during the capsulopalpebral fascia repair. **C, F,** Postoperative view after 8 years. Note the minimal bulging and the lack of hollowing from overresection of fat

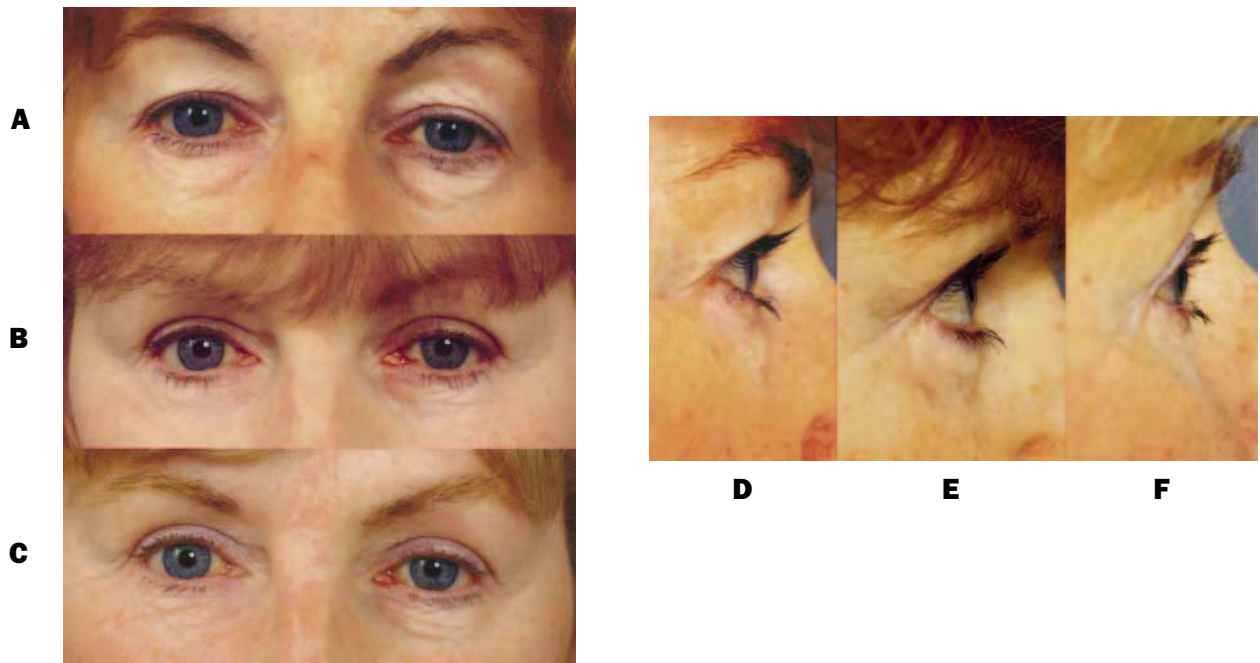


Figure 7. **A, D,** Preoperative view of a 40-year-old woman. **B, E,** Postoperative view 5 years after upper- and lower-lid blepharoplasty with total preservation of orbital fat. **C, F,** Postoperative view after 10 years. Note that the posterior lamella repair is largely maintained despite progressive changes of the anterior lamella.

reduced, reduction is performed by placing a small incision through the area of laxity located at the summit of the most prominent point of the bulge. The area of laxity is made more prominent by the increased orbital pressure. The objective is to extract the minimum amount of fat necessary.

Because the lateral part of the septum is dense and quite rigid over most of the compartment, only 2 or 3 interrupted sutures are required to control the central bulging. These are sufficient to tighten and flatten the entire lateral compartment. The orientation of these sutures is important. They should be placed obliquely, parallel to the arcuate expansion, so that in addition to the secure closure, a line of tension also is created across the new (repaired) septum extending up toward the medial canthus (Figure 5). This suturing provides a contouring effect for the new septum. The line of tension becomes a line of flatness, but it appears as a concavity because of the slight bulge of the new septum between the rigidity of the tension line and the orbital rim. This contouring with an inferior bulge replicates the youthful ideal and prevents the occurrence of a totally flat septum. A flat septum resulted from the original suturing method² because it produced the maximum concavity at the orbital rim, contributing to a vertically long lid, which increases the appearance of aging.

Checking for adequacy of repair and lid mobility

Before the skin muscle flap is replaced, the following simple tests are used to confirm that the repaired septum is sufficiently tight and to confirm the absence of any vertical tethering of the reconstructed septum:

1. Direct gentle vertical traction of the lid margin to demonstrate normal mobility of the lid.
2. Indirect pressure on the lid achieved by applying finger pressure onto the globe through the upper lid. This increases pressure on the fat behind the lower lid. There should be minimal bulging of the new posterior lamella. In the rare occasion when increased bulging occurs as a result of laxity, additional oblique lateral septal sutures are placed. The lid margin moves up over the globe if mobility is unrestricted. A minor degree of restriction sometimes occurs that is easily released with a light touch of the cutting cautery to the restricting part of the new septum while traction is applied. Real restriction does not occur if the technique has been performed correctly.

Completion of the anterior lamella

This is performed in the standard skin muscle flap tech-

nique. Excess skin, and possibly some orbicularis muscle, is excised. Preoperative measurement of the anticipated skin redundancy, with the patient gazing upward, provides a baseline for the amount of excision. There is less excess skin (and muscle) to be excised than with a traditional blepharoplasty because of the increased vertical length of flap required to follow the 3-dimensional contour of the new posterior lamella. Resuspension of the orbicularis fascia to the arcus marginalis of the lateral orbital rim is performed before incisional closure. I place a firm suture into the periosteum of the inner edge of the orbital rim (not the outer surface), directly below the lateral canthal tendon. This suture grasps the orbicularis fascia just below the edge of the flap without passing superficially into the orbicularis itself, avoiding the consequence of a skin dimple. Finally, a useful precaution is a Frost suture to temporarily support the lower lid in an elevated posture for 24 to 48 hours.

A qualitative difference, resulting in elegant contouring of the lower lid, occurs when the septum is reinforced and contoured with the optimum amount of fat preserved within the orbit (Figures 6 and 7). The capsulopalpebral repair maintains the orbital fat under real pressure, and the repair holds over time, unless the pressure is excessive.

There is a limit as to how much of the protruding fat can be replaced in the orbit before the retroseptal pressure rises to excess. Accordingly, removal of some of the bulging fat is required in more than half of the cases, but usually only from the lateral compartment.

Optimal preservation of lid fat is a better alternative than the standard complete removal of all the protruding fat. Meticulous technique with correct use of the capsulopalpebral fascia does not interfere with lid mobility or cause vertical shortening of the lid.■

References

1. Mendelson BC. Herniated fat and the orbital septum of the lower lid. *Clin Plast Surg* 1993;20:323-330.
2. de la Plaza R, Arroyo JM. A new technique for the treatment of palpebral bags. *Plast Reconstr Surg* 1988;91:677-685.
3. Hamra ST. Arcus marginalis release and orbital fat preservation in midface rejuvenation. *Plast Reconstr Surg* 1995;96:354-362.

Reprint requests: Bryan C. Mendelson, MD, 109 Mathoura Road, Toorak, Victoria, Australia 3142.

Copyright © 2001 by The American Society for Aesthetic Plastic Surgery, Inc.

1084-0761/2001/\$35.00 + 0 **70/1/119405**

doi:10.1067/maj.2001.119405