



Correction of Accessory Axillary Breast Tissue Without Visible Scar

Young Soo Kim, MD

Dr. Kim is Assistant Professor, Department of Plastic and Reconstructive Surgery, Sanggye Paik Hospital, Inje University Medical Center, Seoul, Korea.

Background: Various methods for correction of accessory axillary breast tissue have been proposed, including simple excision, diamond-shaped excision, a Y-V technique, and lipoplasty.

Objective: We present an effective method for correction of a prominent axillary mound that combines lipoplasty with excision of accessory breast tissue along the axillary transverse line.

Methods: Preoperative markings included an incision within the natural wrinkle line in the axillary fold, and demarcation of areas in which lipoplasty and excision were to be performed. After lipoplasty, deep dissection was performed to isolate and remove accessory breast tissue and excess fat tissue. A compression dressing was applied for 1 to 2 weeks postoperatively, and the patient was instructed to wear a sports bra for 1 to 2 months after removal of the dressing.

Results: We treated 7 patients using this procedure between October 1999 and March 2003. No major postoperative complications were detected and recurrence was not noted during the follow-up periods. Aesthetic results were satisfactory.

Conclusions: We believe that a procedure that combines lipoplasty and excision provides numerous advantages as a surgical option in treating a prominent axillary mound. The main advantage is that the final scar is laid in the natural axillary fold, rendering scars less conspicuous and eliminating the need to remove excess skin. The one disadvantage was that elevation of the skin flap via small, remote incisions initially produced surgical difficulties, but these were overcome with experience. (Aesthetic Surg J 2004;24:531-535.)

A prominent or sagging axillary mound, appearing as a mass in the axilla, is the most frequently encountered form of polymastia, or ectopic breast.¹ These axillary masses are thought to be caused by remnant accessory breast tissue and an excessive buildup of dermafat.

Accessory breast tissue can occur anywhere between the axilla and the groin. Axillary breast tissue may represent true ectopic tissue that is not contiguous with the breast but more commonly represents enlargement of the "axillary tail of Spence."² The condition is usually bilateral. Most patients with an axillary mound opt to have the mass removed for purely aesthetic reasons. However, there are few documented reports of surgical removal of an axillary mound, despite its relatively high prevalence. The reported cases of simple excision, diamond-shaped excision, and applications of the Y-V technique³ have failed to provide satisfactory results with respect to the aesthetic outcome.

In this paper, we present an effective surgical method and supporting cases for surgical removal of a prominent axillary mound via incision along the axillary transverse line.

The procedure allows placement of the final scar within natural axillary wrinkle lines, leaving a less conspicuous scar regardless of any movement of the arm.

Patients and Methods

Patients

We treated 7 women, aged 22 to 45 years (mean age 32.1 years), with axillary mounds between October 1999 and March 2003. Accessory breast tissue was removed through incisions made within the natural wrinkle line in the axillary fold using a method that combined lipoplasty and excision under local anesthesia. Follow-up ranged from 5 to 12 months (mean 9.1 months) (Table).

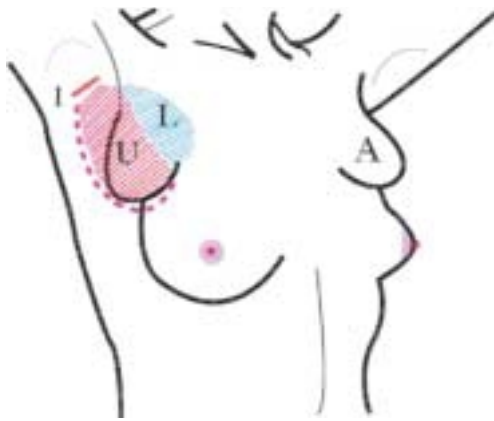


Figure 1. Schematic illustration of the preoperative design. A, Accessory breast; L, incision line; L, area of performing lipoplasty; U, area of undermining for excision.

Table. Patient summary

Case	Age	Size (cm)	Mean weight exised (g)	Complication	Follow-up (months)
1	24	10 × 7, r	40, r	No	12
2	34	6 × 4, r	15, r	No	12
		7 × 4, l	17, l		
3	33	6 × 5, r	15, r	No	8
		5 × 5, l	14, l		
4	25	9 × 7, r	20, r	No	5
		8 × 5, l	17, l		
5	22	6 × 5, r	14, r	No	9
		7 × 6, l	15, l		
6	42	8 × 7, r	20, r	No	12
		7 × 6, l	18, l		
7	45	10 × 9, r	30, r	Some seroma	6
		8 × 9, l	25, l		

r, Right; l, left.

Surgical Technique

The preoperative design was marked along the margin of the axillary mound with the patient standing during adduction of the arm and with the arm at rest. The markings included an incision line within the natural wrinkle line in the axillary fold, and demarcation of the area in which lipoplasty was to be performed and also of the area in which undermining was to be performed for excision of accessory breast tissue and excess dermofat tissues (Figure 1). A solution of 2% lidocaine and 1:100,000 epinephrine was injected into the incision line

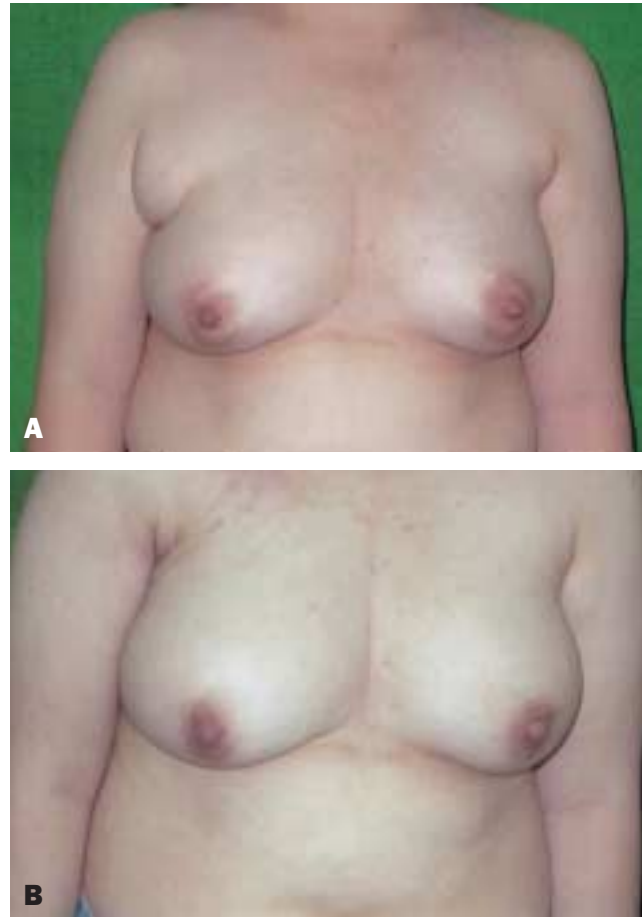


Figure 2. A, Preoperative photograph of a 24-year-old woman with a bulging mass just above the right breast (case 1). B, Postoperative photograph 3 months after removal of axillary mass.

and mixed solutions (1000 mL 0.9% normal saline + 25 mL 0.5% bupivacaine + 25 mL 1% lidocaine + 1 cc epinephrine 1:1000) were administered into the lipoplasty site through a stab incision in the incision line. Lipoplasty was performed in the designated area (area L in Figure 1). After an incision was made to the depth of the superficial fat layer, the skin flap was elevated along the designated undermining area (area U in Figure 1) using a light retractor to fully expose the mass. Further deep dissection was performed to separate isolated accessory breast tissue and excess fat tissue from the underlying axillary tissues. The mass was then removed, taking care to avoid damage to the subcutaneous plexus or axillary neurovascular structures when isolating the main mass. The wound was irrigated with copious saline, and a drain was placed to stitch up the opening once bleeding was controlled. Excess skin removal was

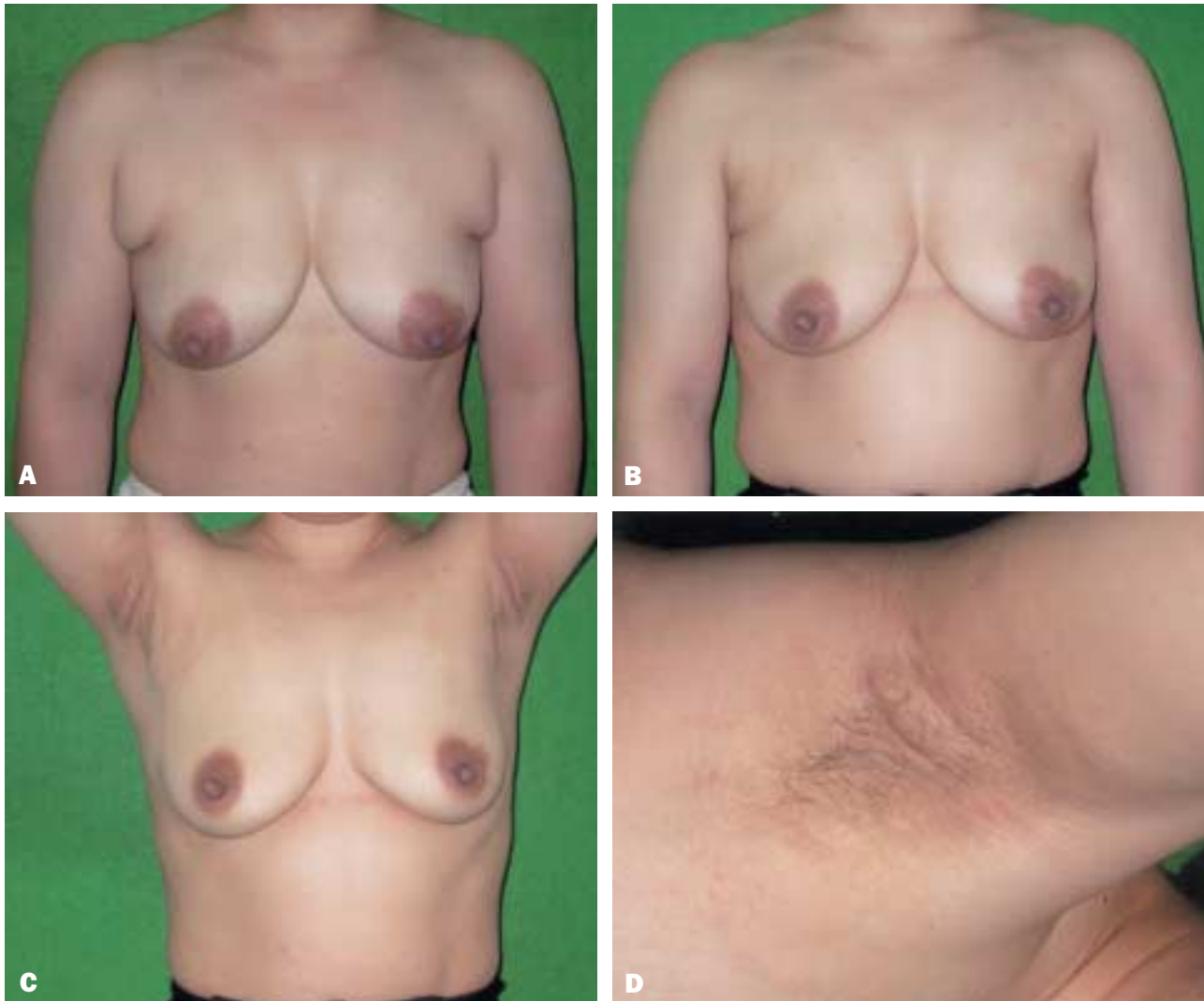

Figure 3. **A**, Preoperative view of a 34-year-old woman with bilateral bulging masses above the breasts. **B**, Postoperative result 12 months after removal of axillary mounds. No residual deformity above the breast was noted. **C**, Postoperative view during arm abduction. No residual or shifting mass was noted. **D**, Close-up view of the scar. The scar was laid within the normal, natural axillary wrinkle lines and was not conspicuous even through arm abduction. The length of the scar was about 4 cm.

unnecessary. The drain was removed 3 days after the surgery and an Elatex compression dressing (ALCARE Co., Kyojima, Sumida-ku, Tokyo, Japan) was applied for 1 to 2 weeks postoperatively. The patient was instructed to wear a sports bra for approximately 1 to 2 months after removal of the dressing.

Results

In all 7 patients, no major postoperative complications that required treatment, such as skin flap necrosis, hematoma, or seroma, were detected. Only 1 patient (case 5) developed a seroma in the first postoperative

week that regressed spontaneously without other sequelae. Excess skin resulting from the procedure was remedied by applying compression bandages and instructing the patient to wear a sports bra. Two representative cases are reported here.

Patient 1

A 24-year-old woman was admitted for aesthetic correction of an axillary mass in the right breast. The mass was approximately 10 cm by 7 cm in size, felt even to the touch, and did not show any signs of tenderness, bleeding, or skin discoloration. There were no complications

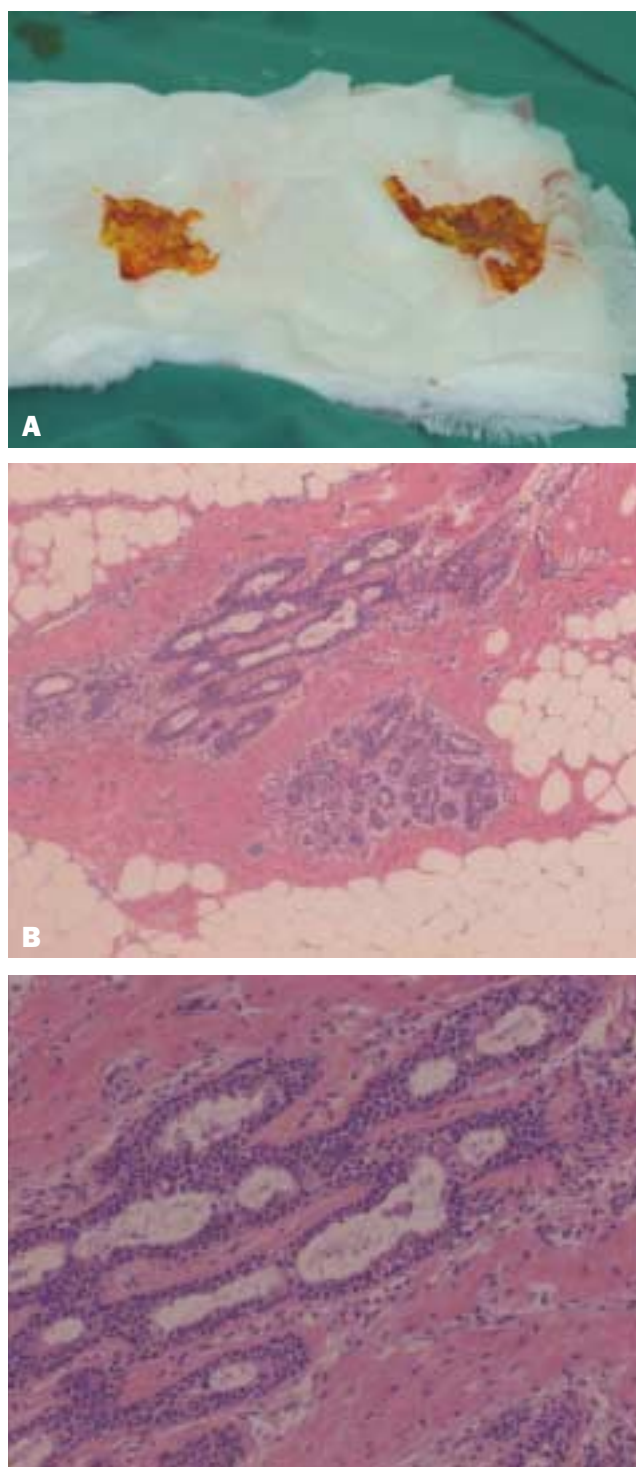


Figure 4. **A**, Tissue specimen shows a well-demarcated yellow ovoid mass. On sectioning, the cut surface has a homogeneously yellow, fatty appearance. **B, C**, Histopathologic specimen. Note the heterotopic benign ductal structures in the adipose tissue (H&E stain; **B**, $\times 40$; **C**, $\times 100$).

of surgery, and the aesthetic result was satisfactory (Figure 2).

Patient 2

A 34-year-old woman was admitted for removal of bilateral axillary mounds. The patient's medical and family histories were unremarkable. The masses were measured at 6 cm by 4 cm and 7 cm by 4 cm, respectively. No postoperative complications were noted, and the aesthetic result at 12 months postoperatively was satisfactory (Figures 3 and 4).

Discussion

A prominent axillary mound may first become symptomatic during pregnancy, especially during puerperium. Such mounds may also undergo cyclic changes during the menstrual period. Occasionally, they are totally asymptomatic.

Histopathologic transformation resulting in serious clinical conditions, such as cystic disease, fibroadenoma, mastitis, and atypical ductal hyperplasia or carcinoma, can occur in ectopic breast tissue.⁴

The disorder is often misdiagnosed, with lipoma being the most frequent incorrect diagnosis. Correct diagnosis of accessory axillary breast tissue is based on its initial appearance during pregnancy or by the history of cyclic changes during the menstrual period.

Patients diagnosed with accessory axillary breast tissue generally request surgical removal of the mass for aesthetic rather than clinical reasons. The protrusion of these masses in their armpits makes it difficult for them to wear bathing suits or clothing with short sleeves without embarrassment. It should be noted, however, that the possibility of malignant tumor or lipoma must be ruled out before removal of an axillary mass for aesthetic reasons. Despite the relatively common occurrence of axillary mounds, few treatment approaches have been reported, and no single surgical method has been generally accepted as standard.

In 1896, Verchere removed a large triangle-shaped skin flap and made a Y-shaped seal of the opening, while Joseph removed a diamond-shaped dermal section as part of his surgical removal of an axillary mass in 1927.³ The method proposed by Kaye called for excision of the mass through a long incision high on the inner surface of the arm, just lateral to the mass itself.⁵ Although the resulting

long scar was laid within the natural axillary wrinkle lines using this technique, it was visible with arm abduction and an undercorrected upper portion of the mass just above the normal breast remained. The most recent report was by Papadimitriou³ in 1999. His technique featured a Y-shaped incision made with the perpendicular portion laid towards the posterior and the V-shaped section placed towards the anterior. After removing the 2 opposing triangular skin flaps, the V-shaped flap was pushed posteriorly and stitched to produce an inconspicuous final scar. Scars generated through this procedure may not be visible with adductive movement of the arm but are noticeable with abductive movement. Consequently, Papadimitriou's method did not provide optimal results for patients with socially active lifestyles and/or those who require physical exposure.

Attempts to remove axillary mounds through lipoplasty techniques have recently been made. However, lipoplasty offers relatively little benefit, because extensive aspiration would result in further sagging of the axillary folds.³ Moreover, because of the dense fibrous tissue found in the axillary tail of Spence, lipoplasty alone fails to produce any substantial results. Ultrasound-assisted lipoplasty (UAL), which is more effective in addressing dense, fibrous lipodystrophy, has recently emerged as a preferred technique for management of various conditions, such as gynecomastia⁶ and axillary bromidrosis.⁷ Rohrich et al⁶ have reported a success rate of 86.9% using suction-assisted lipoplasty and UAL for management of gynecomastia. Nevertheless, in addressing the unfavorable results (13.1%), they recommended use of additional excision techniques for severe gynecomastia with significant skin excess.⁶

Conclusion

We believe that a procedure that combines lipoplasty and excision as described here provides numerous advantages as a surgical option in treating a prominent axillary mound with virtually no postoperative complications. The advantage of our technique is that the final scar is laid in the natural axillary fold, thus minimizing the evidence of surgery by rendering scars less conspicuous with any outward movement of the arm and eliminating the need to remove excess skin. The one disadvantage of the technique is that elevation of the skin flap on the large area via remote, small incisions ini-

tially produced surgical difficulties, but these were overcome eventually. ■

References

1. Haagensen CD. *Diseases of the Breast*. Philadelphia, PA: W. B. Saunders Co.; 1971.
2. Greer KE. Accessory axillary breast tissue. *Arch Dermatol* 1974;109:88-89.
3. Andreas MP, Andreas MY. A method for correcting prominent axillary folds. *Plast Reconstr Surg* 1999;104:595-596.
4. De Chonoky T. Accessory breast tissue in the axilla. *New York J Med* 1951;51:2245-2248.
5. Kaye BL. Accessory axillary breast tissue. A significant aesthetic deformity. *Plast Reconstr Surg* 1974;53:61-63.
6. Rohrich RJ, Ha RY, Kenkel JM, Adams WP. Classification and management of gynecomastia: defining the role of ultrasound-assisted liposuction. *Plast Reconstr Surg* 2003;111:909-923.
7. Hong JP, Shin HW, Yoo SC, Chang H, Park SH, Koh KS, et al. Ultrasound-assisted lipoplasty treatment for axillary bromidrosis: clinical experience of 375 cases. *Plast Reconstr Surg* 2004;113:1264-1269.

Accepted for publication June 15, 2004.

Reprint requests: Young Soo Kim, MD, Department of Plastic and Reconstructive Surgery, Sanggye Paik Hospital, Inje University Medical Center, Seoul, 139-707, Korea.

Copyright © 2004 by The American Society for Aesthetic Plastic Surgery, Inc. 1090-820X/\$30.00

doi:10.1016/j.asj.2004.08.004