



# The Crooked Nose: Principles of Treatment

Nazim Cerkes, MD

Aesthetic Surgery Journal  
31(2) 241–257  
© 2011 The American Society for  
Aesthetic Plastic Surgery, Inc.  
Reprints and permission:  
[http://www.sagepub.com/  
journalsPermissions.nav](http://www.sagepub.com/journalsPermissions.nav)  
DOI: 10.1177/1090820X10394167  
[www.aestheticsurgeryjournal.com](http://www.aestheticsurgeryjournal.com)



## Abstract

Correction of the crooked nose is one of the most challenging procedures in rhinoplasty. The goals of the surgery are creation of a rigid and straight cartilaginous L-strut, correction of the deviated bony structures, and improvement of the nasal airway. Curvatures of the dorsal septum can be corrected with several techniques. Spreader grafts, cartilage batten grafts, or ethmoid bone grafts can be utilized for internal stenting to straighten the dorsal deviations. The surgical treatment for a deformed caudal septum with the most predictable and successful outcome is resection and replacement with a straight septal cartilage graft. In severe deviations of septum cartilage involving both dorsal and caudal portions of the L-strut, extracorporeal reconstruction of the septal cartilage may be the required method. For correction of the deviated bony pyramid, several osteotomy methods can be employed. Medial osteotomy, low-to-low or low-to -high internal lateral osteotomy, double-level lateral osteotomies, and external lateral osteotomy are the options, depending on the deformity. Dorsal onlay grafts can provide camouflage for any residual asymmetries after septal reconstruction or can be applied for dorsal augmentation.

## Keywords

septum, airway, dorsum, dorsal augmentation, upper lateral cartilages, columella strut, spreader graft, radix, nasolabial angle, dorsal hump

The correction of a crooked nose presents a twofold challenge for plastic surgeons, because they must address a problem that is both functional and aesthetic. Furthermore, the crooked nose can be a result of varying pathologies and etiologies, which must all be addressed during the preoperative evaluation. Depending on the individual patient's anatomy, the deviation may be related to bony pyramid pathology or septal deformity; most patients present with a combination of the two pathologies.<sup>1,2</sup>

The nasal deviation itself can be produced by both extrinsic and intrinsic forces,<sup>3</sup> which result in distortion of the septal cartilage. Extrinsic forces include those secondary to deviation of the nasal pyramid, such as forces acting through the attachments of the upper lateral cartilages (ULC) and forces resulting from deviation or injury to the vomer, perpendicular plate of the ethmoid, or maxillary crest. Release of these extrinsic forces may allow correction of the cartilaginous septal deformity, whereas failure to achieve complete release contributes to recurrence. Intrinsic forces, in contrast, may be secondary to the growth and development of the septal cartilage or may result from injury to the cartilage itself. These forces must be overcome by weakening the cartilage and overpowering the deforming forces with grafts.

The etiology of the crooked nose may be congenital or acquired. Acquired deviations can result from trauma or a previous surgery. There is a difference between the chronic changes that occur after trauma in childhood and acute

traumatic deviations in adults. Developmentally deviated noses show a variance from recently traumatized, depressed nasal fractures, in which there is no preexisting skeletal or soft tissue asymmetry.

## CONSULTATION AND PREOPERATIVE ANALYSIS

Successful treatment of a crooked nose requires the surgeon to have significant knowledge of the structural anatomy of the nose, which will lead to accurate preoperative diagnosis. During the initial consultation, a detailed medical history must be taken from the patient, including details of any earlier trauma, breathing difficulties, or prior surgeries. Finger palpation is also helpful in identifying any anatomic deformities of the bony and cartilaginous structures, since curvatures and irregularities in the nasal bones and septal cartilage can be discerned with this method. A detailed internal examination is also critical. Endoscopy is a very useful tool for this portion of the consultation, in particular for mapping the posterior septum and turbinates. Additional

Dr. Cerkes is a plastic surgeon in private practice in Istanbul, Turkey.

### Corresponding Author:

Dr. Nazim Cerkes, Yeni Sulun Sok No. 17, Levent, Istanbul, Turkey  
Email: [ncerkes@hotmail.com](mailto:ncerkes@hotmail.com)

meticulous observation and evaluation of the septum, turbinates, and paranasal sinuses can be achieved with paranasal computed tomography scans. Photographs should be taken of each patient; these enable direct discussion with the patient about his or her postoperative goals, since any aesthetic irregularities can be clearly identified. On frontal view, deviations from the midline and dorsal asymmetries should be discussed; a lateral view provides the opportunity to assess the nasal dorsum, radix, nasolabial angle, and nasal tip projection. The basal view is excellent for assessing nostril asymmetries.

In his private practice, this author has found a simulation tool useful for planning the surgery. By showing the patients possible postoperative results, he can provide them with a realistic understanding of the intended result and assess their expectations. Extreme care should be taken to avoid showing patients unrealistic (or overly optimistic) results, which can lead to postoperative dissatisfaction. Furthermore, patients with external deviation must be made aware that perfect symmetry is not always achievable, especially if severe bony deviation is present.

## CLASSIFYING NASAL DEVIATION

Following the preoperative evaluation, it can be helpful to classify each patient's nasal deviation into one of five main types. This enables the surgeon to choose the appropriate operative intervention and then tailor the operation to each patient's individual needs.

### Caudal Septal Deviation (Septal Tilt)

This is the most common type of nasal deviation. In this condition, the patient's septal cartilage is shifted to one side of the nose internally and the other side externally. Caudal septal deviations may compromise the airway significantly because they affect the anteroinferior part of the external nares.

### Anteroposterior C-Shaped Deviation

This is the second most common type of septonasal deviation. External deviation is on the opposite side of internal deviation.

### Cephalocaudal C-Shaped Deviation

This deformity externally presents as a visible "C" shape.

### Anteroposterior S-Shaped Deviation

Anteroposterior S-deviations are externally visible as a shift to one side of the nose.

## Cephalocaudal S-Shaped Deviation

This deformity, which is difficult to correct, is visible externally as an "S" shape to the nose.

## PRINCIPLES OF SURGICAL TREATMENT

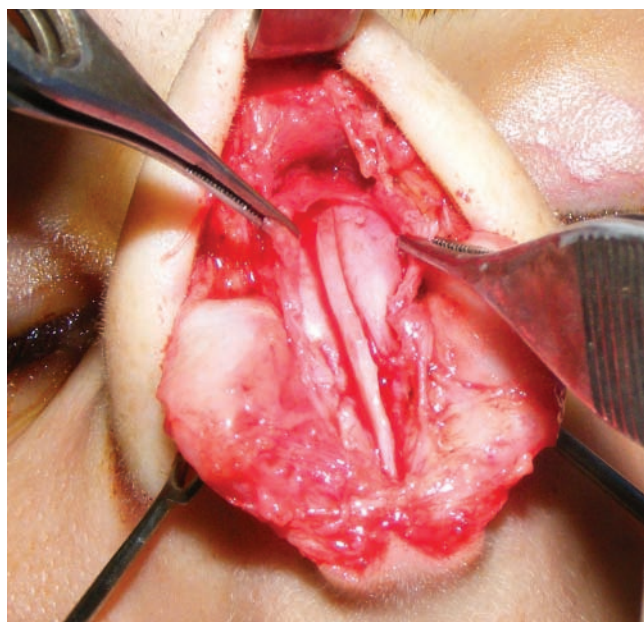
Generally speaking, the operative sequence for a crooked nose takes the same course, regardless of deformity. First, the deviated structures are exposed. Second, the muco-perichondrial attachments are released, followed by a resection of the deviated parts (which were identified during preoperative consultation and may include the septal cartilage, maxillary crest, vomer, and/or perpendicular plate). The deviated septum is then straightened and septal support is restored. Corrective osteotomies are performed, and the operation is concluded by reduction of the hypertrophied turbinates.

The author prefers an open rhinoplasty technique performed under general anesthesia, since the open approach provides direct visualization of the anatomic structures and offers unlimited access to the septum, bony structures, and tip cartilages. To begin, a midcolumellar inverted-V incision is made. The skin of the nasal tip and midvault is elevated on a supraprimerichondrial plane. Next, the caudal border of the septal cartilage is exposed with the division of the anterior septal ligaments. To elevate the perichondrium of the ULC and the periosteum of the nasal bones, a vertical incision is made along the dorsum. With a fine elevator, the perichondrium of the ULC is elevated about a centimeter on both sides (Figure 1). If a bony correction is to be performed, dissection is extended in a subperiosteal plane over the bony dorsum.

The next stage of the operation is the subperichondrial degloving of the septum on both sides. This dissection is begun at the anterior septal angle. A few millimeters of caudal septum is dissected with a number 15 blade until the subperichondrial plane is reached. Then, the dissection is continued with a Cottle elevator to the cephalic portion of the septal cartilage, where the perichondrium is less densely adherent. Afterward, septal degloving is performed bilaterally over the septal cartilage, perpendicular plate, and the cephalad portion of the vomer. Finally, the vomerine-maxillary crest is dissected in the subperiosteal plane.

The ULC are separated from the septal cartilage with a number 15 blade, with care taken to preserve the integrity of the mucosal lining. This submucosal release eliminates the extrinsic forces on the dorsal septum and allows the cartilaginous septum to reorient itself in the midline.<sup>4,5</sup> Once the nasal septum is released from the ULC, the actual degree of deviation of the dorsal septal cartilage can be determined.

Next, the cephalic and posterior part of the cartilaginous septum and a portion of the attached perpendicular plate of ethmoid and vomer are resected, preserving at least 12 mm of septal cartilage at the dorsal and caudal L-strut.



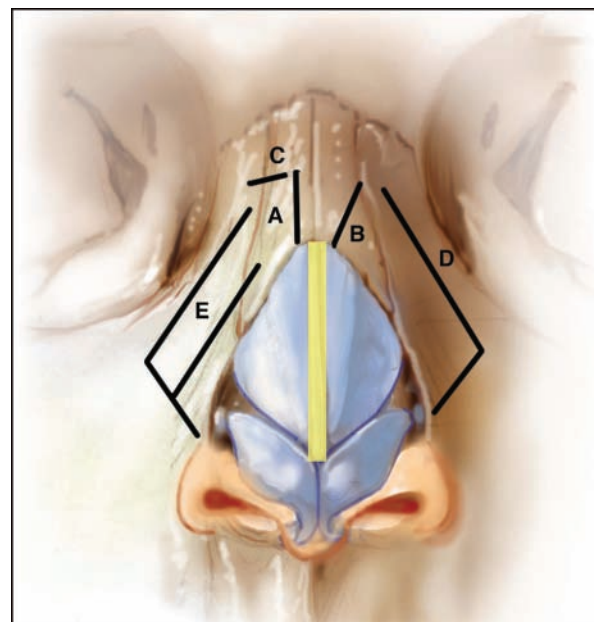
**Figure 1.** The perichondrium of the upper lateral cartilages and the periosteum of the nasal bone are elevated in continuity.

This resection significantly eliminates both the intrinsic and extrinsic forces that may be deforming the dorsal and caudal portion of the septal cartilage. At this time, all deviated portions of the perpendicular plate, vomer, and maxillary crest should be resected. The author prefers to perform septal resection prior to dorsal hump reduction, since the septal resection itself may reduce the height of the cartilaginous dorsum, especially on the caudal part of the septum. The unpredictability of potential height reduction results in possible overresection of the dorsal cartilaginous hump if the septal resection is not completed first.

After septal resection, both mucosal layers are approximated with a continuous horizontal mattress suture of 5-0 catgut. This suturing is commenced at the caudal posterior portion of the septum, is continued cephalically, and then proceeds anteriorly and caudally to join the starting point. The aim of this suture is to close the dead space between the two mucosal layers, thereby avoiding the need for post-operative intranasal packing, which can be a significant source of patient discomfort. Gauze coated with Vaseline is packed into the nose on both sides until the end of the operation to promote adhesion of the mucosal layers.

## Dorsal Hump Removal

If the nasal dorsum is high, a cartilaginous and bony hump removal is carried out. In these cases, the author prefers to reduce the bony hump first, with a 6-mm straight osteotome. In the severely deviated bony vault, less bone should be excised from the nasal bone on the deviated side. This will prevent excessive reduction in nasal bone height



**Figure 2.** Various types of osteotomy for correction of bony deviations are illustrated. (A) Medial oblique osteotomy, (B) medial osteotomy, (C) transverse osteotomy, (D) low-to-low lateral osteotomy, and (E) double level lateral osteotomy.

of that side after corrective osteotomy. If there are irregularities on the nasal bones after bony reduction, rasping can be performed. Dorsal septum reduction is achieved with a number 11 blade. The ULC are preserved; no resection is performed from the ULC in this step.

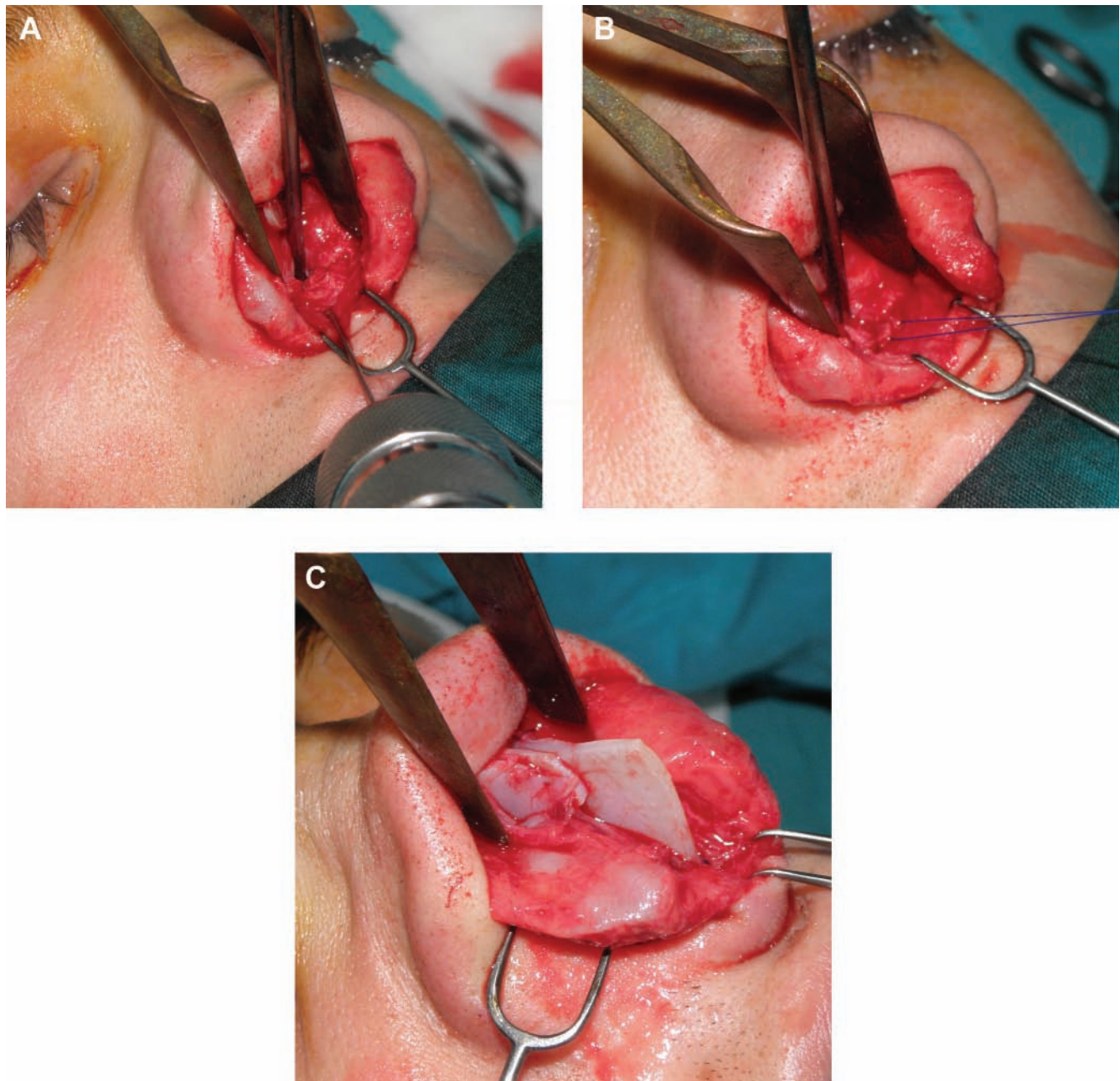
## Osteotomies

Osteotomies should be individualized to meet the requirements of each patient's anatomy, depending on the deformity present (Figure 2). With bony pyramid deviations, osteotomies must be performed adequately to eliminate the extrinsic forces on the septal cartilage. If there is no deviation on the bony vault from the midline, internal lateral osteotomy (or combination of lateral and medial oblique [Figure 2B] osteotomies) can be performed with a 3-mm straight osteotome. In this group of patients, if narrowing of the bony pyramid is not required, osteotomies are not performed.

If there is a deviation from the midline and a symmetric bony pyramid present, the correction may be achieved with medial and internal lateral osteotomies. A greenstick fracture of the perpendicular plate of ethmoid bone should also be performed in cases of this nature to prevent any recurrence. In a patient who has a deviated bony pyramid with asymmetric nasal bones, medial and external lateral (percutaneous) osteotomies may be required to achieve symmetry.

In patients with asymmetric nasal bones, generally the nasal bone on the opposite side of deviation has a convex

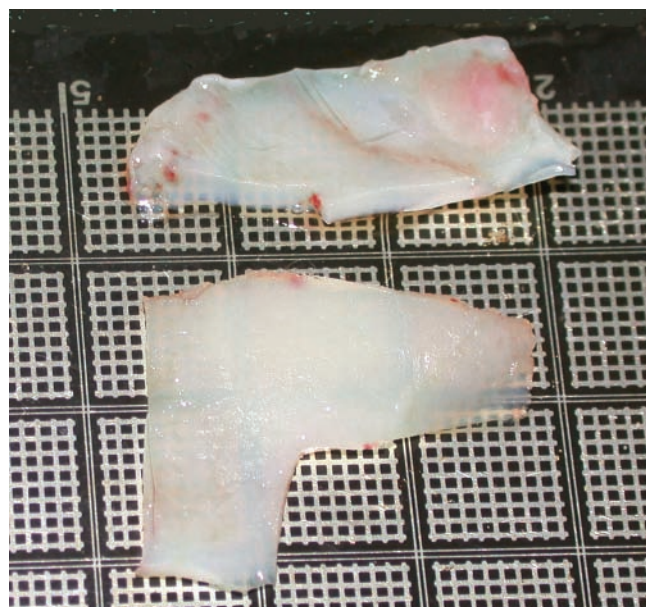




**Figure 3.** (A) With a hand drill, a hole is made in the anterior nasal spine for caudal septal fixation. (B) A 4-0 polypropylene suture is threaded through the hole. (C) A caudal septal replacement graft is fixed to the anterior nasal spine with a figure-of-eight suture.

form, whereas the one on the deviated side has a concave form. Depending on the deformity present, several osteotomy combinations may be indicated. Medial osteotomies shift the perpendicular plate to the midline and allow independent movement of the nasal bones. For the concave nasal bone, a low-to-high lateral or double-level lateral osteotomy (Figure 2E) can be performed. My preference is to perform lateral osteotomies internally on the concave side. When double-level osteotomies are

required, the higher osteotomy should be completed before the lower one. This is essential for preventing displacement of fragments. Further caution should be exercised to avoid “freeing up” the periosteum of the nasal bones. For correction of convex nasal bones, adequate osteotomies must be performed, allowing complete mobilization. For the convex side, the author generally prefers to perform an external low-to-low lateral osteotomy (Figure 2D) with a 2-mm osteotome. In extreme bony



**Figure 4.** A deformed caudal septum is resected. A straight graft is prepared from the harvested septal cartilage for replacement.

pyramid deviations, a high-level transverse osteotomy in combination with a low-to-low external lateral osteotomy can be utilized for adequate mobilization of the convex bone to the midline.

## Reconstruction of the Septal L-Strut

If a deviation of the septal L-strut remains after release of all extrinsic forces and resection of the deviated septum, a septal reconstruction must be carried out.<sup>6</sup> Correction of deformities of the cartilaginous septum is difficult because of the inherent “memory” of cartilaginous tissues and their tendency to persist in a deviated state.

### Caudal Septal Reconstruction

The major support mechanisms of the nasal tip are dependent on the stability of the caudal septum. If the caudal septum is missing or severely deviated, there may be significant loss of nasal tip support, with resulting loss of tip projection. The loss of caudal septal support may also result in an overly short nose or a retracted columella. Furthermore, caudal septal deviations may cause significant airway compromise because they affect the antero-inferior part of the external nares. Therefore, caudal septal deviations must be remedied to achieve nasal tip support and airway correction.

**Caudal septal relocation.** If the caudal septum does not lie directly on the midline, it must be repositioned. To achieve this, the caudal portion of the L-strut is released from the maxillary crest and anterior nasal spine. A small triangle of cartilage at the posterior septal angle can be excised, which

allows the caudal septum to shift to the midline. In selected cases, straightening of the septum can be achieved with the development of a “swinging door” flap, including vertical wedge sectioning of the septum at the point of caudal deviation. The repositioned caudal septum should be buttressed with a batten graft or spreader grafts on the dorsal septum and stabilized to anterior nasal spine to preventing recurrence. The most reliable method of fixation is to puncture a small hole in the anterior nasal spine with a drill (Figure 3A), followed by threading of 4-0 polypropylene or Vicryl (Ethicon, Somerville, New Jersey) through the hole (Figure 3B) and subsequent fixation to the spine with a figure-of-eight suture (Figure 3C). This is an effective technique for repositioning caudal septal deviations, as well as stabilizing caudal septal replacement grafts.

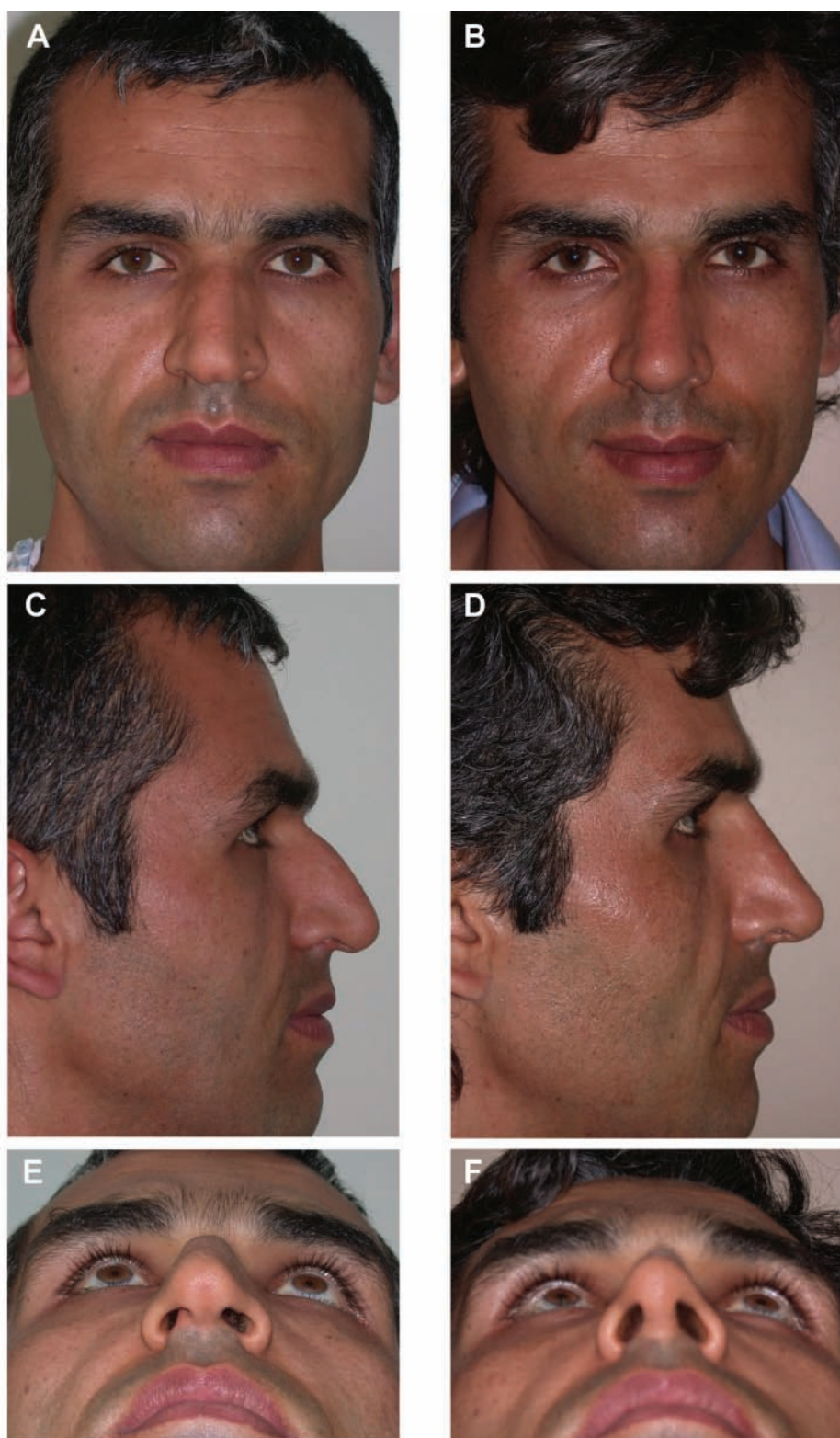
### Caudal septal resection and replacement with a straight strut.

If the caudal portion of the patient’s L-strut is deformed, it should be corrected through resection of the caudal septum and replacement with straight septal cartilage (Figure 4).<sup>7</sup> The replacement graft must be fixed to the dorsal septum and the anterior nasal spine. Buttressing of a twisted caudal septum can be performed in selected cases, but it is not the author’s preferred method, given the possibility of bending and subsequent formation of a thicker caudal septum, which may then compromise the airway. In cases where tip rotation or projection is required, replacement grafts can be extended caudally and the medial crura can be fixed to the graft to achieve a rotation or/and projection on the nasal tip (shown subsequently).<sup>8</sup> In secondary cases, if sufficient septal cartilage is not available for grafting, straight struts can be prepared from rib cartilage and placed for caudal septal reconstruction.) Ear cartilage grafts are not the author’s preferred choice for this type of reconstruction, given their surface irregularities and curvatures.

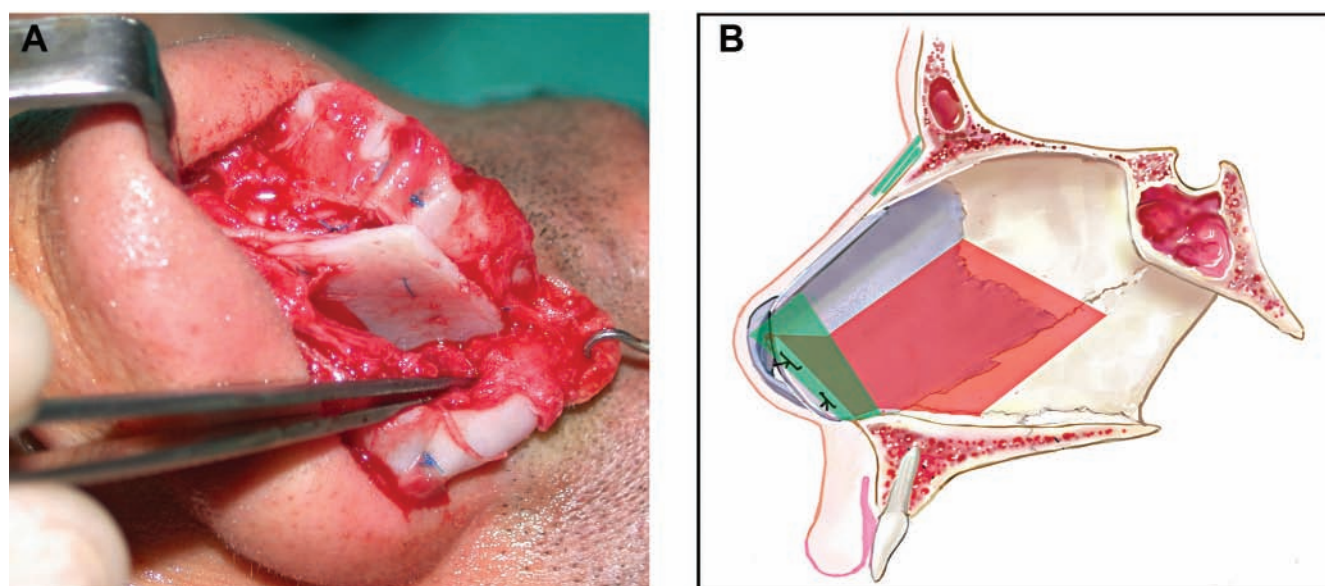
The patient shown in Figure 5A-F demonstrates the caudal septal resection and replacement described above. This 28-year-old man presented for correction of airway obstruction and removal of his dorsal hump. He had slight dorsal deviation, a wide bony pyramid, and a bifid and broad nasal tip. He also had a low radix and a drooping tip with a low nasolabial angle, along with a deviated caudal septum.

During the patient’s operation, the septal cartilage was exposed with an open technique. Deviated portions of septal cartilage and ethmoid bone were resected. The caudal portion of septum cartilage was also included in the resection, leaving a 20-mm intact dorsal strut. The caudal septum was constructed from the resected septal cartilage and fixed to the dorsal septum and anterior nasal spine (Figure 6A). The caudal strut was extended a few millimeters more caudally, thereby acting a septal extension graft (Figure 6B). The medial crura were then fixed to the caudal strut. No reduction of the dorsal hump was carried out. Medial and lateral osteotomies were executed internally for narrowing of bony pyramid and a double-layer, mildly crushed radix graft was placed in the glabella for augmentation. Transdomal sutures and an interdomal suture were placed for tip refinement.





**Figure 5.** (A-C) This 28-year-old man presented for correction of airway obstruction resulting from caudal septal deviation. The patient's anatomy showed slight dorsal deviation, a wide bony pyramid, and a bifid, broad nasal tip. The lateral view shows a dorsal hump with a low radix and a drooping tip, along with a low nasolabial angle. The deviated caudal septum can clearly be observed on the basal view. (D-F) Two years after open rhinoplasty with caudal septal resection and replacement with a straight strut. The patient's replacement graft was extended caudally for medial crural fixation and tip positioning.



**Figure 6.** Diagrams demonstrating the operative technique employed on the patient in Figure 5.

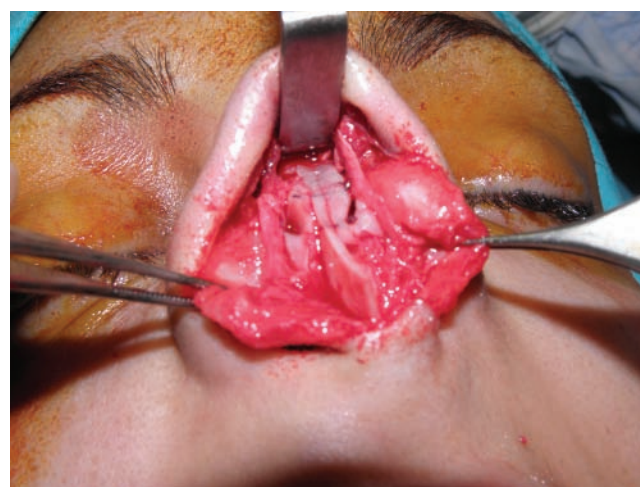Following the operation, the patient's bony pyramid and nasal tip were successfully narrowed and defined, and the radix was augmented and the drooping tip corrected. The caudal septal deviation was also corrected.

### Straightening of the Dorsal L-Strut

There are several alternative techniques for reconstruction of dorsal septal deviations. The author's experience with scorings and suture techniques has shown these to be unreliable in isolation; their efficacy can only be ensured when they are stented with grafts, thus achieving a more predictable correction of the deviation and minimizing of the risk of bending.

In patients with minimal irregularities on the dorsal L-strut, spreader flaps (with the ULC folding in) can be utilized to balance the deviation (Figure 7).<sup>10</sup> In dorsal deviations, the ULC on the opposite side is generally more developed and thicker than on the deviated side. In the spreader flap technique, ULC that are preserved during the dissection are folded in and fixed to the septal cartilage with 5-0 Vicryl or PDS mattress sutures. Normally, two or three sutures are required for this fixation. To achieve symmetry, trimming of the ULC can be performed after the fixation.

Patients with a cephalocaudal C-shaped deformity have a dorsal concavity on one side of the nose and a convexity on the opposite side. In patients who also have a weakened dorsal septum, dorsal curvatures can be best corrected through stenting with spreader grafts.<sup>11</sup> The spreader grafts can be placed unilaterally, bilaterally, or in an asymmetric fashion (with a thicker spreader on the concave side), depending on the deformity.<sup>12</sup> In the presence of dorsal septal deviation, a spreader graft is usually required on the concave side of the deformity, since the ULC on the

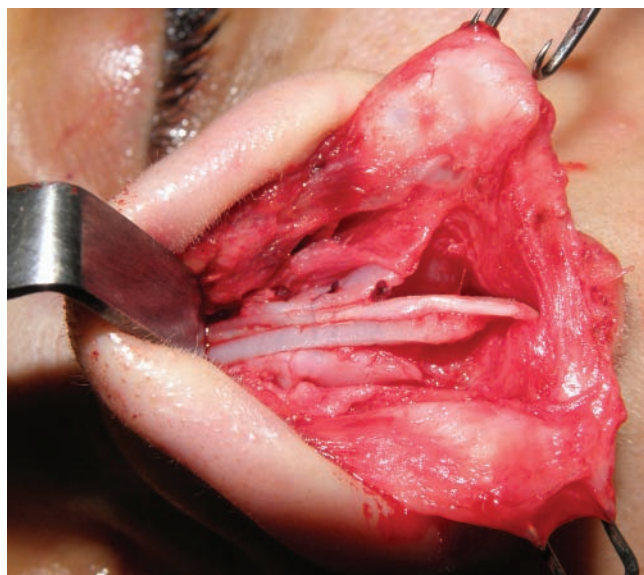


**Figure 7.** Spreader grafts are placed to equalize a dorsal asymmetry.

concave side will bow toward the deviation and will need to be displaced laterally to correct the concavity (Figure 8). Unilateral or asymmetric placement may allow for the equalization of a residual deviation on the dorsal septum. In these cases, spreader grafts are fixed to the septum and ULC with two or three mattress sutures. If the deviated dorsal L-strut is thick and not malleable, it must be scored with a blade—a few deep, parallel, vertical scorings—to prevent bending and to straighten it before stenting with spreader grafts.

If appropriate cartilage grafts are not available for buttressing the deviated dorsal septum, an ethmoid bone graft can be placed as an alternative. These grafts can be thinned with a power burr and cut into a rectangular shape. For placement, several holes should be punctured on the graft with a hand drill to allow for fixation (Figure 9).





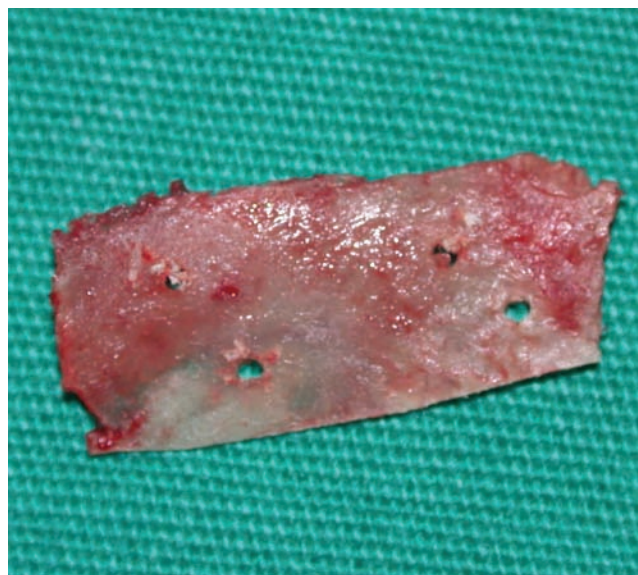
**Figure 8.** Unilateral spreader grafts are placed to balance dorsal asymmetry in a dorsal deviation.

After deep scorings are made to the dorsal septum in a vertical direction for straightening, the ethmoid bone graft is fixed to the septum as a stent with mattress sutures, which are threaded through the holes and septal cartilage.

After buttressing the dorsal septum with spreader grafts, the ULC are secured to the dorsal septum with two or three horizontal mattress sutures of 5-0 Vicryl or PDS. This fixation is an important process for the preventing the inferior collapse of the ULC with subsequent compromise of the nasal valve. Any remaining asymmetries can be addressed by trimming or folding in the ULC (as with a spreader flap).

Figure 10A-F demonstrates placement of spreader grafts for dorsal septal deviation and concavity correction. This 19-year-old woman had a history of deviated septum and nasal airway obstruction when she presented for primary rhinoplasty. She had a high, cephalocaudal, C-shaped dorsal deviation and a bulbous tip with a fairly thick skin. Her nasal bones were asymmetric—convex on the right side and concave on the left side. She had a dorsal bony and cartilaginous hump and slightly high tip projection, and her broad nasal tip had lateral alar convexities.

For this patient, an open rhinoplasty was performed with an inverted-V midcolumellar incision. After elevation of the skin flap, the ULC were separated from the septum and septal degloving was carried out. A septal resection—with removal of the deviated portions of septal cartilage, ethmoid bone, vomer, and maxillary crest—was performed, leaving an 2-cm-wide L-strut. A 2- to 3-mm cartilaginous and bony hump was resected and the ULC were preserved. In accordance with her asymmetry, less bone was removed from the left side. Deep, parallel, vertical septal scorings were made to strengthen the deviated dorsal L-strut. A 5-mm-wide spreader graft was placed on the right side to stent and balance the dorsal asymmetry. The



**Figure 9.** A rectangular ethmoid bone graft for stenting a dorsal deviation. Four holes are punctured on the graft for suture fixation.

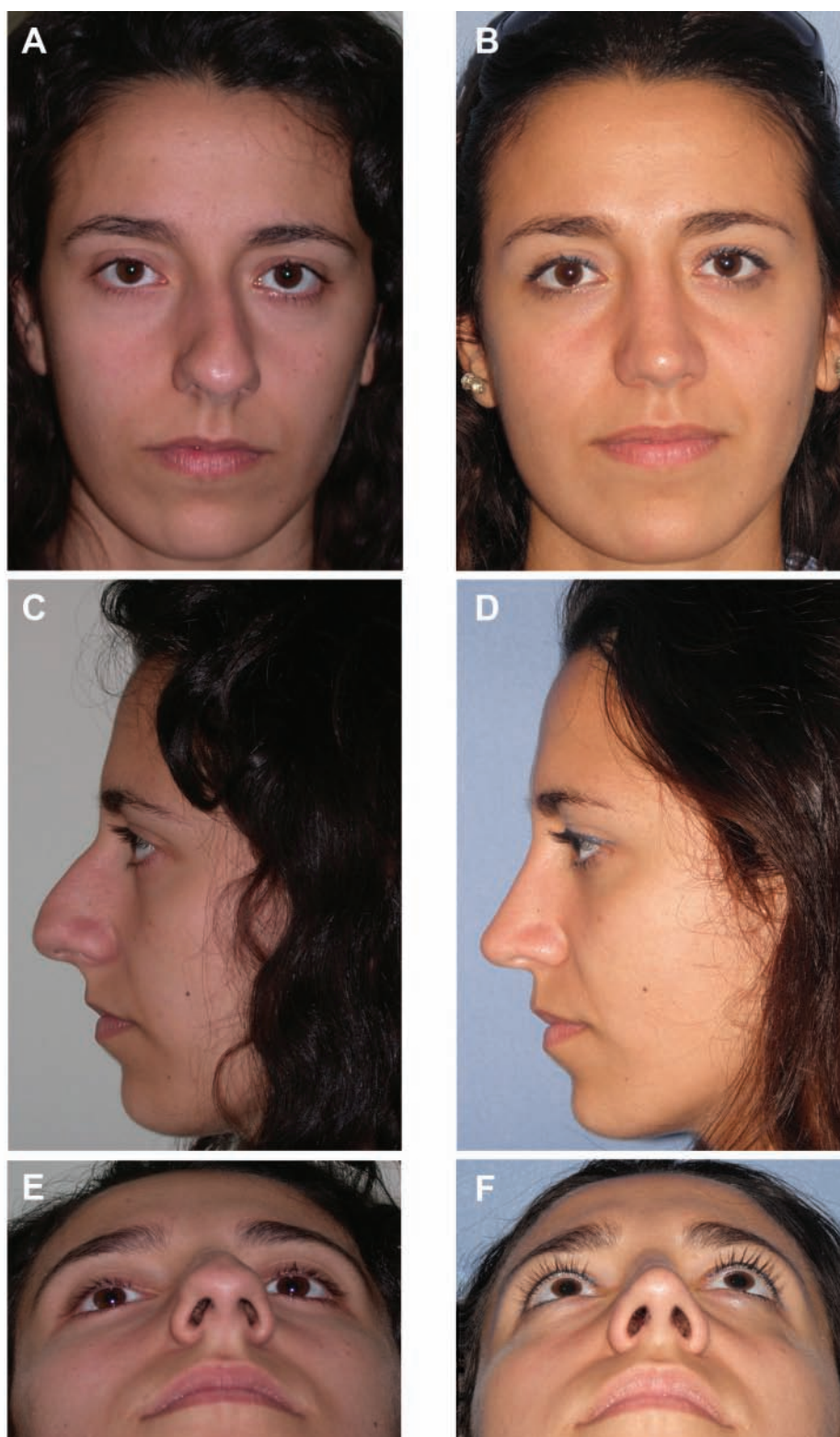ULC were folded in at the keystone area and sutured to the septal cartilage along the dorsal septum. Medial osteotomies, a low-to-low external lateral osteotomy on the right nasal bone, and double-level internal lateral osteotomies on the left side were performed. For nasal tip refinement, after cephalic resection of the lateral crura, transdomal sutures and an interdomal suture were placed. Nostril sill resections of 3 mm were also performed to narrow the patient's alar bases (Figure 11).

Postoperatively, the patient's dorsal deviation, dorsal hump, and broad nasal tip were corrected. She also noted improvement in her airway.

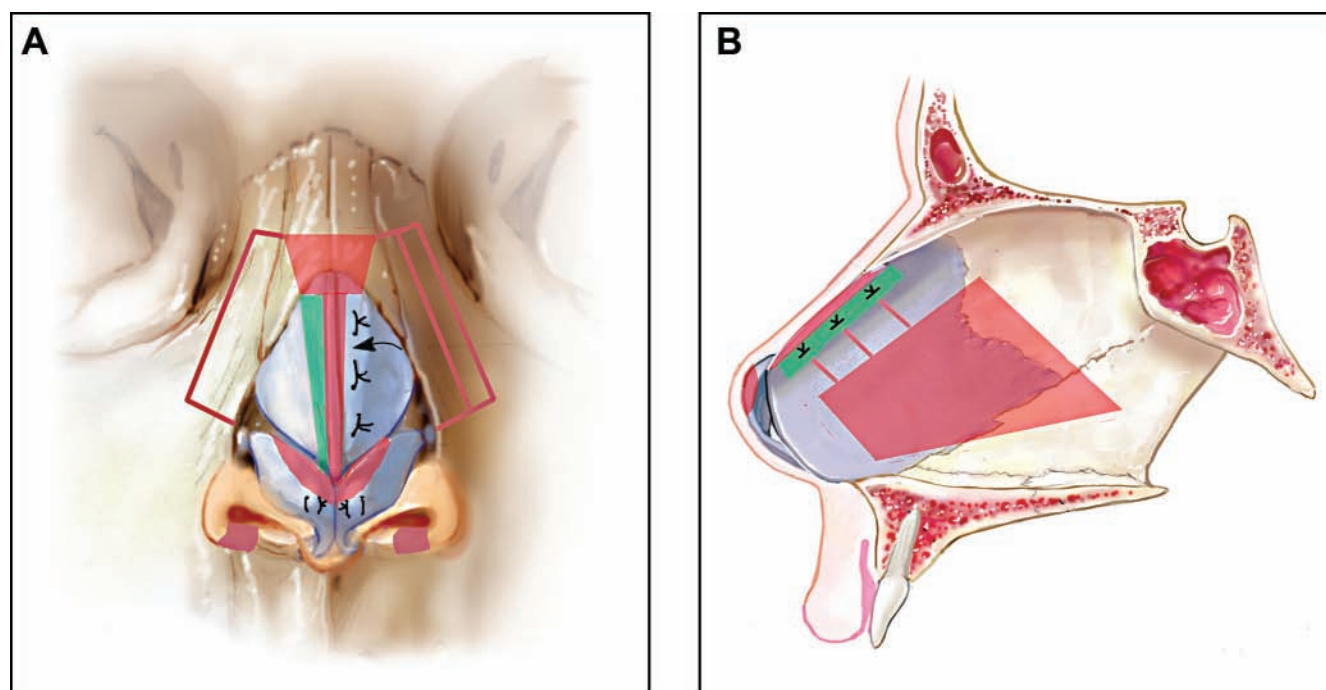
### Extracorporeal Reconstruction of the Nasal Septum

Severe anteroposterior dorsal L-strut deviations, S-shaped deviations, or fractured septal cartilages resulting from trauma may not be corrected adequately with the techniques mentioned above. For these deformities, extracorporeal reconstruction of the nasal septum cartilage should be performed.<sup>13,14</sup> This is achieved through resection of the septal cartilage together with a part of the ethmoid and vomer bone; reconstruction of the L-strut from the resected septum is performed outside of the operating field (Figure 12 A-C). The average length of the dorsal portion of L-strut is 30 to 32 mm and the caudal portion is 18 to 20 mm. The width of the L-strut should be at least 10 mm. In the construction of the L-strut, the straightest parts of resected septum should be utilized. If the cartilaginous portion of the resected septum is inadequate or insufficient, bony portions of the septum can be included in the L-strut. Thicker parts of the bone can be thinned with a power burr (Figure 13).





**Figure 10.** (A-C) This 19-year-old woman presented for primary rhinoplasty. She had a history of nasal airway obstruction and a high, cephalocaudal, C-shaped dorsal deviation. She also had a bulbous tip with fairly thick skin. Her nasal bones were asymmetric (convex on the right and concave on the left). A dorsal bony hump and slightly high tip projection can be seen on the lateral view; on the basal view, her broad tip and lateral alar convexities are evident. (D-F) Three years after open rhinoplasty with an inverted-V midcolumnellar incision. Septal resection was carried out, with less bone removed from the left side to enhance symmetry. The patient's correction was both functional and aesthetic—she noted postoperative improvement in her airway.



**Figure 11.** Diagrams demonstrating the operative technique employed on the patient in Figure 10.

In many cases, it is not possible to prepare a straight L-strut in a continuous single piece from the resected septum. In these instances, two pieces of cartilage can be combined to construct the L-strut and the pieces can be united with batten grafts (Figure 14). Along the dorsal edge of the L-strut, 3- to 5-mm-wide cartilage grafts can be placed unilaterally or bilaterally. These grafts provide additional support to the L-strut and may help to strengthen and equalize the curvatures on the dorsal portion. At the same time, they act as spreader grafts and have positive effects on the internal nasal valve and on the dorsal aesthetic lines. The constructed L-strut is fixed to the ULC with two or three 5-0 Vicryl horizontal mattress sutures and to the anterior nasal spine with a 4-0 polypropylene or Vicryl suture via a drill hole (Figure 15). In an overrotated nose or a retracted columella, the caudal length of the L-strut can be increased to lengthen the nose or to pull the columella downward. The caudal extension of the graft can be sutured between the medial crura, providing a stable structure to support the medial crura. Nasal tip position can also be adjusted with this suture.

The patient shown in Figure 16A-F demonstrates successful correction of traumatic deviation through extracorporeal reconstruction. This 30-year-old woman presented with a history of childhood nasal trauma and severe septal airway obstruction. She requested aesthetic nose improvement as well as nasal airway correction. She had an extreme bony and cartilaginous deviation, with a drooping nasal tip due to loss of tip support. She also had a dorsal nasal hump and low tip projection with a low nasolabial angle, along with the deviated septum.

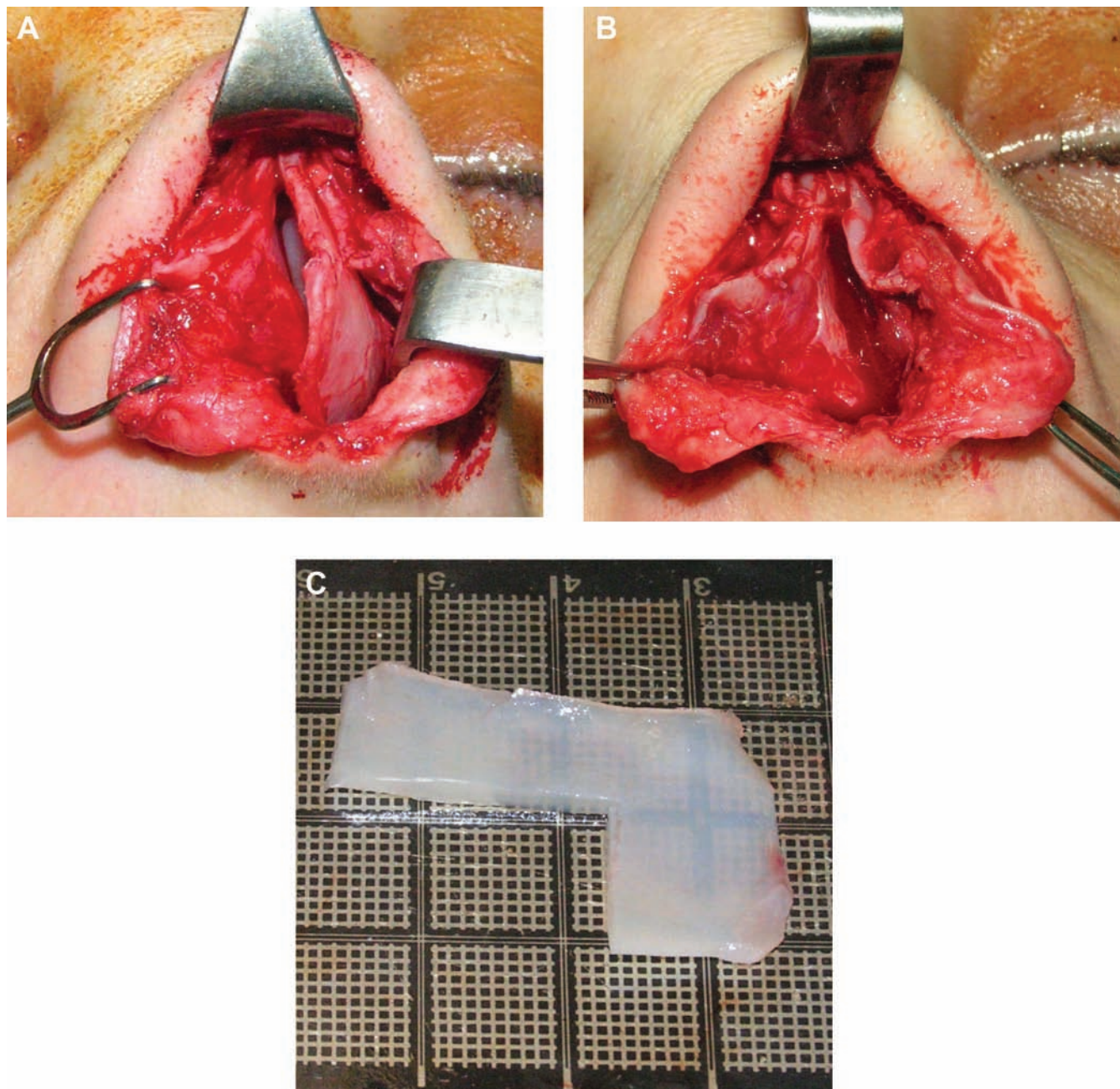
An open approach was selected to expose the nasal dorsum and septum. The septal cartilage was released

from the ULC and septal degloving was performed. For reconstruction of the severely deviated and deformed septal cartilage (Figure 17A), an extracorporeal septoplasty was the preferred option in this particular case. The septal cartilage was resected in total (Figure 17B), with deviated portions of the ethmoid and vomer bones. From the straightest portion of the resected septum, a new L-strut was prepared (Figure 17C). A spreader graft was placed to the right side of L-strut, to achieve the dorsal symmetry. The L-strut was fixed to the ULC on the nasal dorsum, and the caudal portion of the L-strut was fixed to the anterior nasal spine with a figure-of-eight suture via a drill hole. The bony dorsum was reduced minimally. Bilateral median and low-to-low internal lateral osteotomies were performed. Since the patient had thin dorsal skin, a rectangular-shaped temporal fascia graft was placed over the bony and cartilaginous dorsum to camouflage possible irregularities. Cephalic resection of the lateral crura was performed and transdomal sutures were placed for tip refinement. The medial crura of the alar cartilages were sutured to the caudal L-strut to achieve rotation and projection of the nasal tip. Skin resection from the nostril sills was performed to facilitate the narrowing of the nostrils.

Following reconstruction, the patient demonstrated improvement of her dorsal aesthetic lines and correction of dorsal deviation, along with functional correction of her septal deviation. Her dorsal hump was removed; satisfactory nasal tip projection and rotation were achieved.

Sometimes, if an adequate L-strut cannot be prepared from the resected septum due to severe deformation or collapse of the septal cartilage, or in cases where sufficient septal cartilage is not available due to resections from a





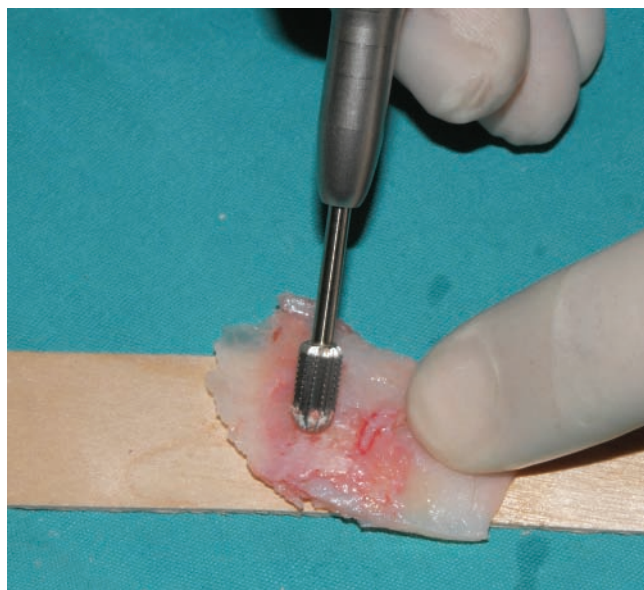
**Figure 12.** (A and B) In patients with severely deviated cartilaginous septa, total resection of septal cartilage should be performed. (C) A straight L-strut can then be prepared from the resected septal cartilage.

previous surgery, the L-strut can be reconstructed from rib cartilage. The rib offers the most abundant source of cartilage and straight struts can be prepared from the core of the rib cartilage for septal reconstruction.


The 26-year-old man shown in Figure 18A-F required this type of reconstruction. He, too, had experienced childhood nasal trauma. His main complaints were airway obstruction and external deviation of the nose. He had a severe bony pyramid and cartilaginous deviation was clearly observed. He also had low tip projection.

An open approach was employed to expose the septum, which was severely malformed and buckled. (Figure 19A) A total resection of the septal cartilage with deviated bony structures was performed (Figure 19B). Since the patient's septal cartilage was severely deformed, construction of a straight L-strut was not possible with the resected septal structures. Therefore, ninth-rib cartilage was harvested and straight struts were prepared from the core of the rib cartilage. (Figure 19C). Two dorsal struts were fixed to the ULC (Figure 19D), after which a caudal strut was placed between

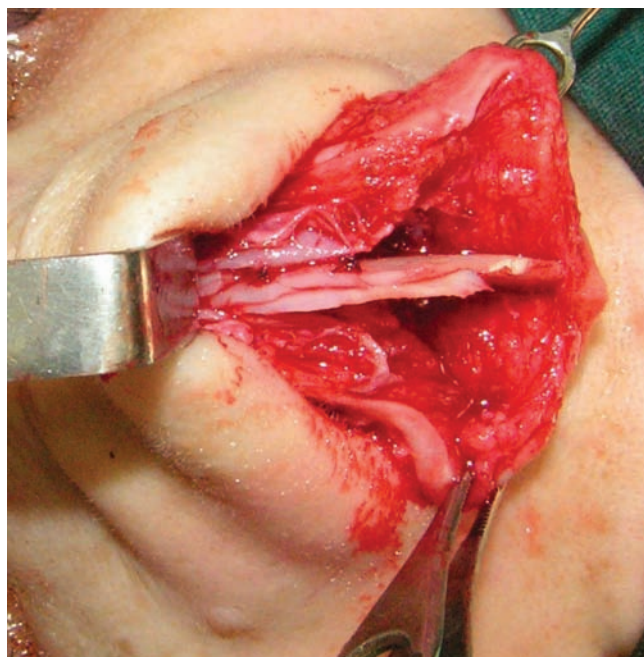




**Figure 13.** A power burr is a useful tool for thinning the bony portions of the resected septum.



**Figure 14.** An L-strut is constructed with two straight septal cartilage struts.



**Figure 15.** An L-strut is fixed to the upper lateral cartilages and anterior nasal spine. A spreader graft is placed to right side to equalize the dorsum.

the medial crura and fixed to the dorsal struts with sutures in order to achieve an L-strut (Figure 19E). The medial crura were sutured to the caudal strut to increase the tip projection (Figure 19F). For bony pyramid correction, medial and double-level internal lateral osteotomies were performed on the right nasal bone, and medial and low-to-low external osteotomies were performed on the left nasal bone. An onlay dorsal graft fashioned from the septal cartilage remnants was placed in the supratip area.

Postoperatively, the patient's nasal pyramid was straightened, his tip projection was increased, and the septal deviation was successfully corrected.

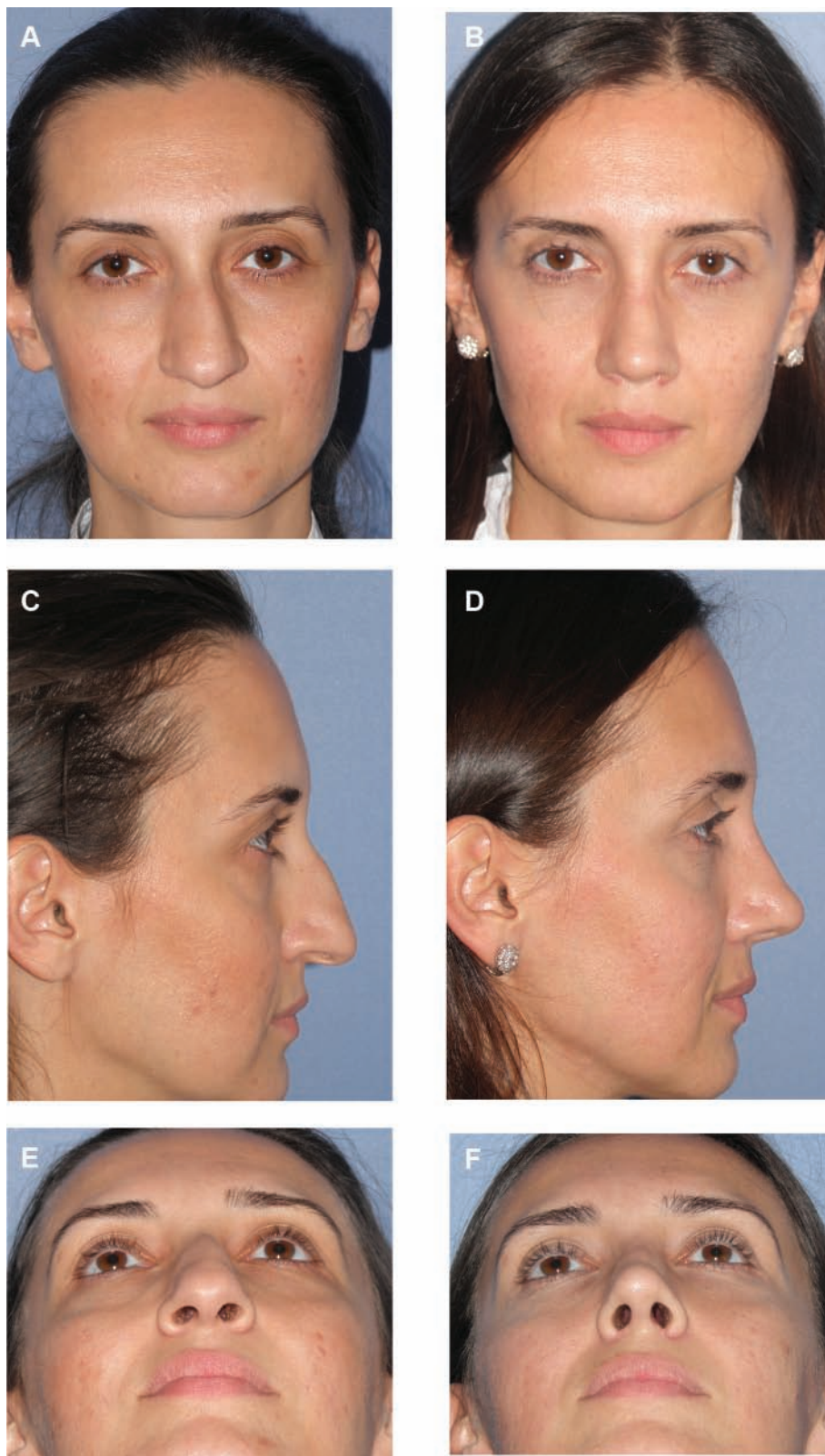### Dorsal Onlay Grafts

An anatomic reconstruction should always be the preferred method when deviation involves the dorsal and caudal septum. For a predictable aesthetic and functional outcome, reconstruction of a stable L-strut is mandatory before augmenting the nasal dorsum. Onlay grafts can be placed for sidewall depressions or asymmetries after septal reconstruction or as required for dorsal augmentation. If residual concavity exists after correction of a C-shaped dorsal septal deviation, an onlay graft can be placed on the dorsum for camouflaging. All onlay grafts have a tendency to become visible over the long term, particularly in patients with thin skin. To minimize visibility, the graft should be crushed mildly and the edges beveled precisely. The graft can also be covered with fascia to disguise edges. In patients who require a certain amount of augmentation, a layered cartilage graft from the septum or conchal cartilage can be placed as onlay graft. A block cartilage graft carved from the rib is the treatment of choice for dorsal augmentation in saddle nose deformities resulting from traumatic collapse or previous surgery. "Fascia-wrapped diced cartilage grafts" are also useful for dorsal augmentation.<sup>15</sup>

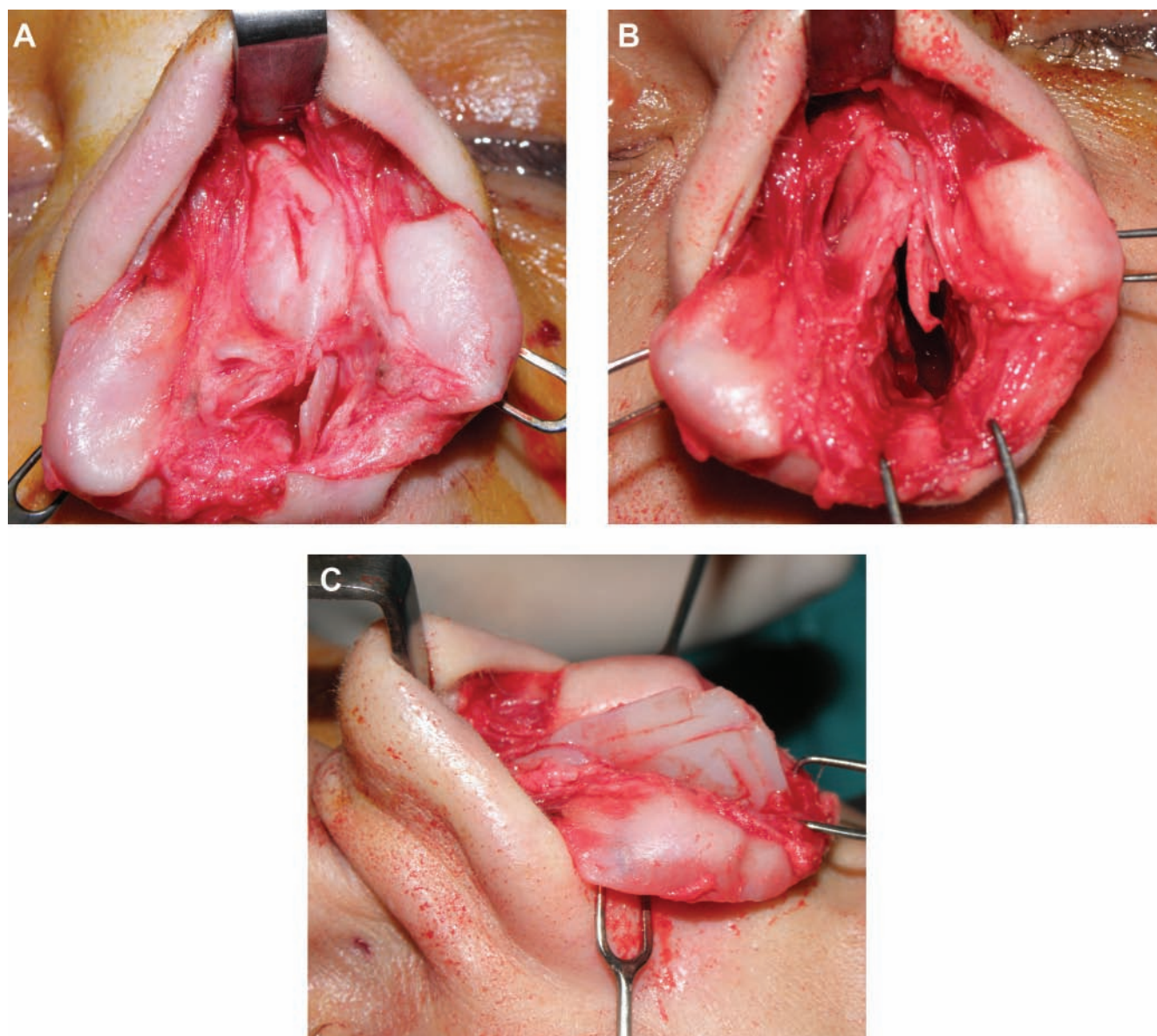
### Closure of the ULC Perichondrium, Tip Refinement, and Turbinate Surgery

After dorsal correction is complete, the perichondrium of the ULC (which were elevated at the beginning of surgery)





**Figure 16.** (A-C) This 30-year-old woman presented with severe septal airway obstruction resulting from childhood nasal trauma. She had an extreme bony and cartilaginous deviation, with a drooping nasal tip. The lateral view shows a dorsal nasal hump and low tip projection, along with a low nasolabial angle. The deviated septum can be clearly observed from the basal view. The patient also had thin dorsal skin. (D-F) Fourteen months after open rhinoplasty with extracorporeal septoplasty. Her dorsal aesthetic lines were improved, as was her septal deviation.



**Figure 17.** The patient in Figure 16 is shown intraoperatively. (A) After elevation of the skin flap, a severely deformed septal cartilage is immediately evident. (B) The septal cartilage is resected in total. (C) The L-strut is prepared from resected septum and replaced.

are approximated with 5-0 catgut sutures (Figure 20). This extra layer of connective tissue may camouflage the minimal irregularities on the nasal dorsum.

Depending on the deformity present on the patient's nasal tip, several maneuvers can be employed for tip refinement, including suture techniques, strut grafts, or tip grafts. For example, the medial crura can be sutured to the caudal L-strut, providing a stable structure and adjusting the nasal tip position. Tip rotation and projection also can be adjusted with this method. If correction of the nasal tip is unnecessary, the medial crura (which were separated in the beginning of the surgery) are approximated with an interdomal suture.

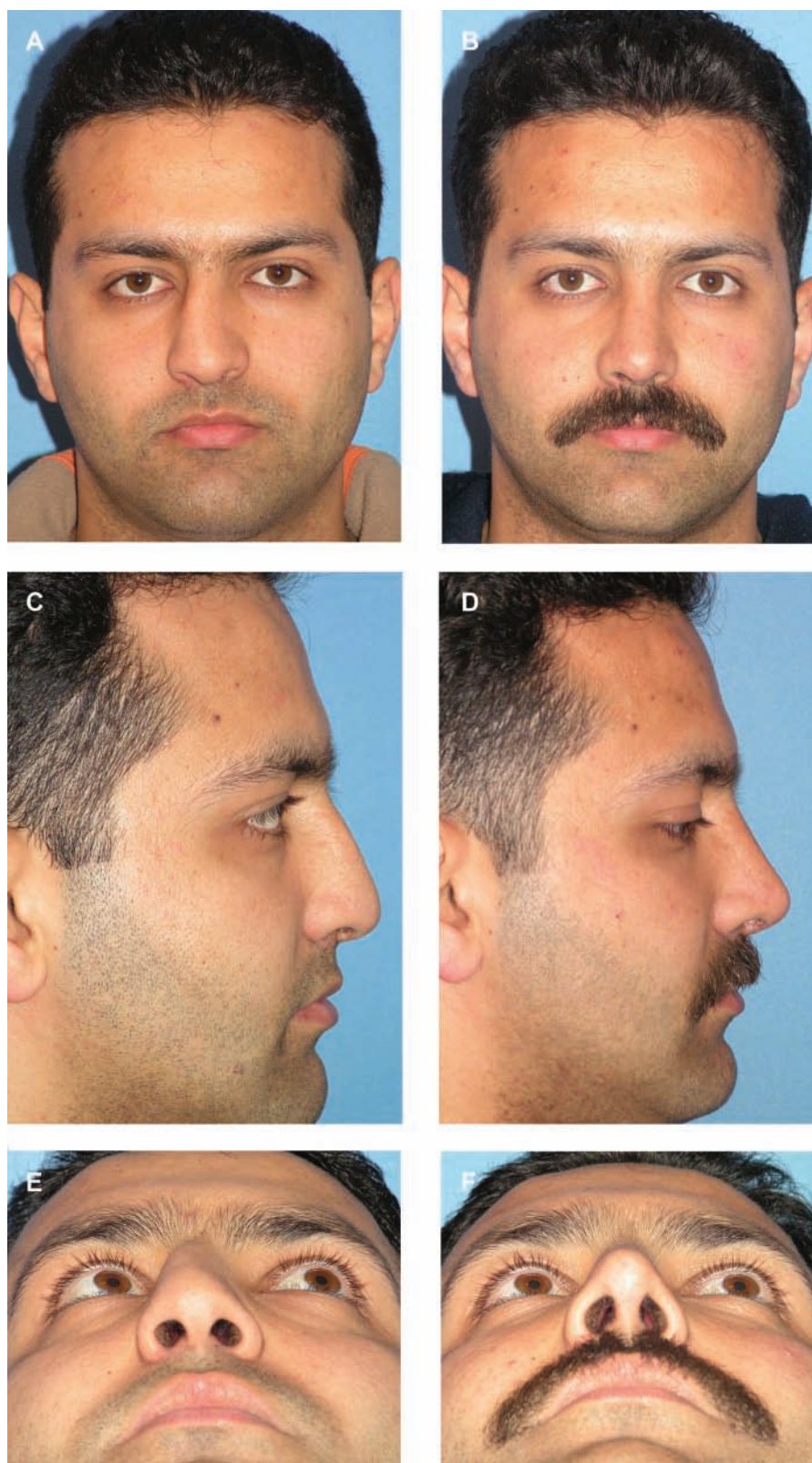On the opposite side of septal deviation, there is almost always some degree of compensatory inferior conchal hypertrophy. After correction of septal deviation, the

majority of these hypertrophies disappear over the long term. For this reason, the author elects to reserve turbinate surgery only for patients with severely hypertrophic inferior turbinates and does not resect the mucosa from the turbinates. Depending on the severity of the hypertrophy, radiofrequency, medial fracturing of the conchal bone, or submucosal resection of the conchal bone can be performed to reduce the size of turbinates.

### Operative Closure and Dressing

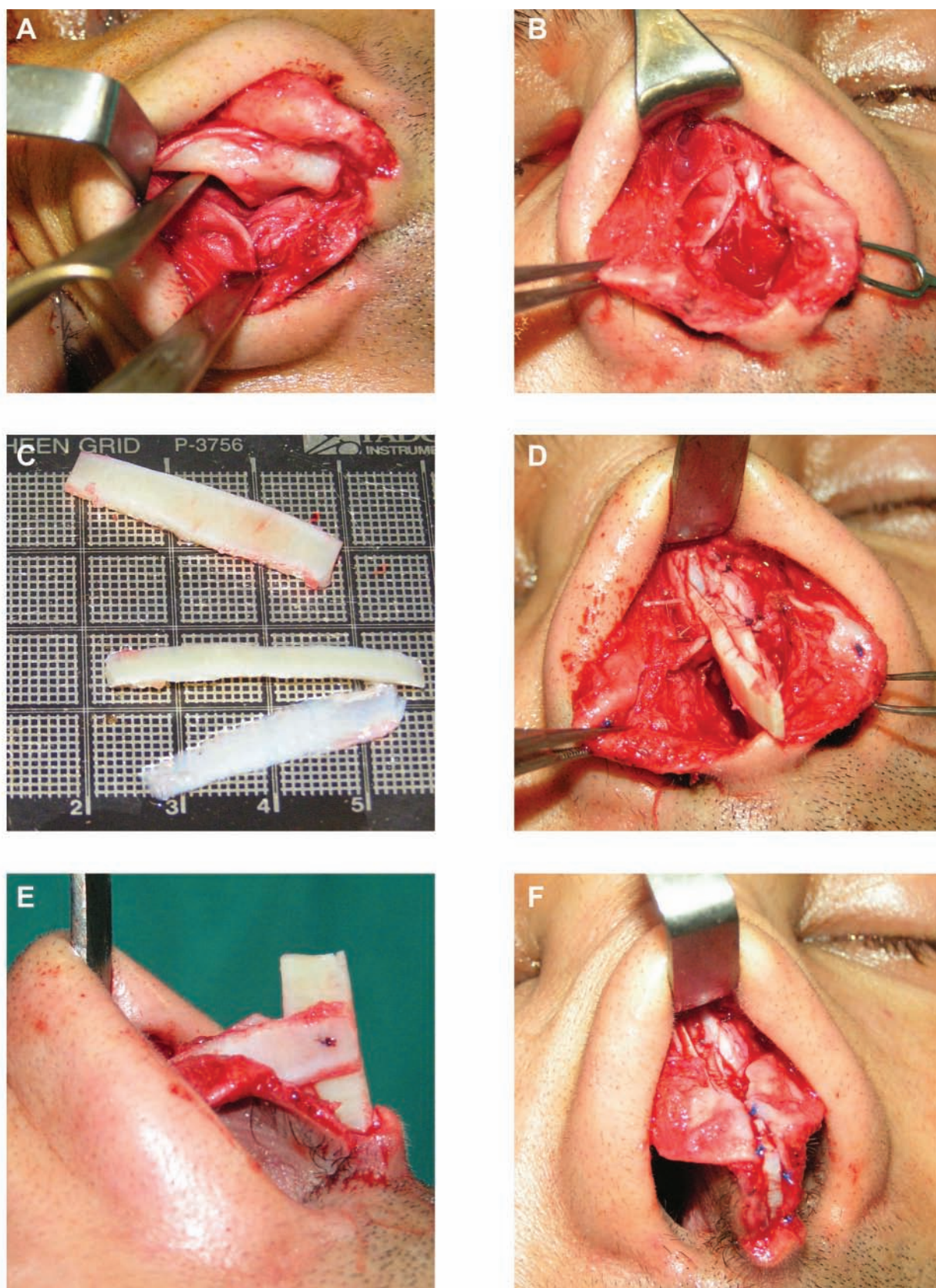
To complete the operation, the inverted-V and infracartilaginous incisions are closed with 6-0 fast-absorbing catgut sutures. After completion of the skin closure, the





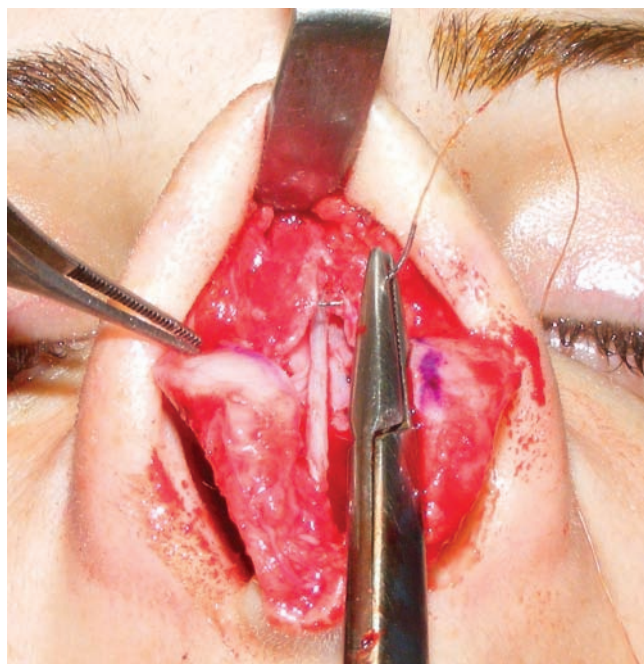
**Figure 18.** (A-C) This 26-year-old man had also experienced childhood nasal trauma. He had a deviated nose that was externally evident, as well as airway obstruction. He had a severe deviation of the bony pyramid, along with the cartilaginous deviation. On the lateral view, his low tip projection is evident. (D-F) One year after open rhinoplasty with extracorporeal septoplasty, this patient's nasal septum was so severely malformed and buckled that an L-strut could not be fashioned from the resected cartilage, so cartilage was harvested from the patient's ninth rib. Medial and double-level internal lateral osteotomies were performed on the right nasal bone; medial and low-to-low external osteotomies were performed on the left nasal bone. The patient's clinical results show straightening of the nasal pyramid, increased tip projection, and correction of the septal deviation.





**Figure 19.** The patient in Figure 18 is shown intraoperatively. (A) After septal degloving, a buckled septum is clearly evident. (B) The septum is resected in total. (C) Straight cartilage struts are prepared from cartilage harvested from the patient's ninth rib. (D) Two dorsal struts are fixed to the upper lateral cartilages. (E) A caudal strut is placed between the medial crura and sutured to dorsal struts. (F) The medial crura are sutured to the caudal strut to increase tip projection.





**Figure 20.** After completion of dorsal correction, the perichondrial flaps are approximated.

intranasal packs that were placed after suturing the mucosal layers are removed. Sterile tapes are placed on the nose, followed by a termoplastic splint. The splint should be removed six or seven days after surgery. If turbinate surgery was performed together with a septal reconstruction, the author prefers to place silicon sheets in the nose and leave them for five to seven days.

## CONCLUSIONS

In a crooked nose, anatomic reconstruction of a deviated septum and bony structure is mandatory to achieving a predictable aesthetic and functional result. The extrinsic and intrinsic forces influencing septal deviation must be diagnosed accurately and eliminated during the operation. The goal of the surgery is to achieve a straight and stable septal L-strut on the midline. Because of the inherent memory of cartilaginous tissues, it is advisable to stent the septal cartilage with cartilage or ethmoid bone grafts after straightening. The caudal L-strut should be fixed to the anterior nasal spine to prevent postoperative dislocations. If a portion of the septal L-strut is deformed and cannot be straightened by releasing the attachments and stenting with grafts, the best treatment is resection of deformed parts and replacement with straight cartilage grafts. In patients with severe septal deviations involving the dorsal and caudal L-strut, extracorporeal septoplasty is the method of choice. After reconstruction of the L-strut, if irregularity still remains on the nasal dorsum, spreader grafts or spreader flaps can be employed to balance the dorsal asymmetries. Onlay grafts can be

utilized for correcting sidewall depressions or asymmetries after septal reconstruction, or for dorsal augmentation.

## Disclosures

The author declared no potential conflicts of interests with respect to the authorship and publication of this article.

## Funding

The author received no financial support for the research and authorship of this article.

## REFERENCES

1. Dingman RO, Natvig P. The deviated nose. *Clin Plast Surg* 1977; 4:145.
2. Rohrich RJ, Gunter JP, Deuber MA, Adams WP. Management of the deviated nose. In: Gunter JP, Rohrich RJ, Adams WP, editors. *Dallas Rhinoplasty*. St. Louis: Quality Medical Publishing; 2002.
3. Byrd HS, Salamon J, Flood J. Correction of the crooked nose. *Plast Reconstr Surg* 1998; 102:2148.
4. Byrd HS, Burt JD. The crooked nose: an algorithm for repair. In: Gunter JP, Rohrich RJ, Adams WP, editors. *Dallas Rhinoplasty*. St. Louis: Quality Medical Publishing; 2002.
5. Toriumi DM, Watson D. Innovative surgical management of the crooked nose. In: Gunter JP, Rohrich RJ, Adams WP, editors. *Dallas Rhinoplasty*. St. Louis: Quality Medical Publishing; 2002.
6. Gunter JP, Rohrich RJ. Management of the deviated nose: the importance of septal reconstruction. *Clin Plast Surg* 1988; 15:43.
7. Briant TDR, Middleton WG. The management of severe nasal septal deformities. *J Otolaryngol* 1985; 14:120.
8. Byrd HS, Andochick S, Copit S, Walton KG. Septal extension grafts: a method of controlling tip projection, rotation and shape. *Plast Reconstr Surg* 1997; 100:999.
9. Gibson T, Davis B. The distortion of autogenous cartilage grafts: its cause and prevention. *Br J Plast Surg* 1958; 10:257.
10. Gruber RP, Park E, Newman J, Berkowitz L, Oneal R. The spreader flap in primary rhinoplasty. *Plast Reconstr Surg* 2007; 119:1903.
11. Sheen JH, Sheen AP. *Aesthetic Rhinoplasty*. 2nd ed. St. Louis: Quality Medical Publishing; 1998.
12. Toriumi DM, Johnson CM. The crooked nose. *Operative Tech Otolaryngol Head Neck Surg* 1990; 1:252.
13. Rees TD. Surgical correction of the severely deviated nose by extramucosal excision of the osseocartilaginous septum and replacement as a free graft. *Plast Reconstr Surg* 1986; 78:320.
14. Gubish W. Extracorporeal septoplasty for the markedly deviated septum. *Arch Facial Plast Surg* 2005; 7:218.
15. Daniel RK. *Mastering Rhinoplasty: A Comprehensive Atlas of Surgical Techniques*. 2nd ed. Springer-Verlag Berlin Heidelberg; 2010.