

The Breast: A Clean-Contaminated Surgical Site

Sophie Bartsich, MD; Jeffrey A. Ascherman, MD, FACS;
Susan Whittier, MD; Caroline A. Yao, MD; and
Christine Rohde, MD, FACS

Aesthetic Surgery Journal
31(7) 802–806
© 2011 The American Society for
Aesthetic Plastic Surgery, Inc.
Reprints and permission:
[http://www.sagepub.com/
journalsPermissions.nav](http://www.sagepub.com/journalsPermissions.nav)
DOI: 10.1177/1090820X11417428
www.aestheticsurgeryjournal.com


Abstract

Background: Capsular contracture is one of the most common complications associated with breast implants. While the cause of this process has not yet been elucidated, subclinical infection is a likely culprit.

Objectives: The authors assess the hypothesis that a probable source of contamination is endogenous breast bacteria, likely originating in the ducts themselves and most concentrated near the nipple.

Methods: Twenty-five healthy patients presenting for routine reduction mammoplasty were recruited as study participants. Tissue samples were taken intraoperatively from the periareolar, inframammary, and axillary regions of each sampled breast. Specimens were then processed in the microbiology laboratory, and quantitative bacterial counts were obtained.

Results: Of the 50 breasts sampled, 19 yielded positive culture results, for a rate of 38%. There was a significant difference in the positive culture rate among all three sites, with increasing quantitative bacterial counts in the axillary, inframammary, and periareolar regions, respectively. The most commonly-identified organisms in this study included various species of *Staphylococcus* and *Propionibacterium acnes*, with *S. epidermidis* being the most common.

Conclusions: The breast harbors significant endogenous bacteria that can become the source of spontaneous or postoperative infection. Positive intraoperative cultures with high quantitative counts suggest that breast tissue harbors more bacteria than normal skin flora. Routine perioperative antibiotic prophylaxis may be suboptimal for the prevention of foreign body seeding in this setting. Furthermore, bacterial concentrations are highest in areas with the most ductal tissue, namely the periareolar region. These findings may be helpful when considering which incision site to select for augmentation mammoplasty.

Keywords

antibiotic irrigation, breast enhancement, breast enlargement, capsular contracture, infection, periareolar, primary or secondary or revision breast augmentation, risks with implants

Accepted for publication April 26, 2011.

Capsular contracture (CC) is one of the most common and difficult-to-treat complications of breast augmentation. It affects between 20% and 50% of all patients who undergo this procedure.¹ While the causes of CC have yet to be definitively determined, bleeding and infection are two likely contributing factors. Current evidence suggests that infection may be a consistent culprit.²

Many patients who develop CC never exhibit the classical features of foreign body-related infection, which suggests a subclinical contamination, one that may develop at any postoperative time point and may go unidentified over the long term. Foreign body seeding in the form of a biofilm is not only difficult to diagnose but may be very difficult to treat, especially with routine antibiotics.³ As with any symptomatology, prevention trumps attempts at cure,

and finding the source of this contamination may provide the ultimate solution to the problem.

Dr. Bartsich is a resident, Dr. Ascherman and Dr. Rohde are Associate Clinical Professors of Surgery in the Division of Plastic Surgery, and Dr. Whittier is Director of Microbiology, Department of Microbiology at New York Presbyterian Hospital, Columbia University Medical Center, New York, New York. Dr. Yao is a resident in the Division of Plastic Surgery at the University of Southern California Keck School of Medicine, Los Angeles, California.

Corresponding Author:

Dr. Christine Rohde, Division of Plastic Surgery, New York Presbyterian Hospital, Columbia University Medical Center, 161 Fort Washington Avenue, Room 511, New York, NY 10032, USA.
E-mail: chr2111@columbia.edu

We hypothesized that the breast and its ducts may represent the source of bacterial contamination of foreign bodies placed around this glandular tissue. Endogenous breast bacteria and its role in CC may in part explain why patients undergoing breast reconstruction suffer higher rates of CC,⁴ as these procedures represent greater manipulation of the breast tissue. We further hypothesized that bacterial concentrations are likely highest in areas with the most concentrated ductal tissue, namely sites near the nipple. Therefore, significant bacterial concentrations found in breast tissue under standard sterile surgical conditions may demonstrate that the breast is indeed an inherently contaminated surgical site.

METHODS

Patients

This study was approved by the Institutional Review Board at New York Presbyterian Hospital, Columbia University Medical Center. Healthy female patients presenting for routine reduction mammoplasty were recruited for this study. Patients with any history of breast infection, abnormal mammography, or prior breast surgery were excluded. Twenty-five patients were recruited, for a total of 50 sampled breasts.

Sample Collection

Per routine, patients received one dose of preoperative antibiotics consisting of 1g of intravenous cefazolin. The skin was prepped with Betadine solution and draped in the standard surgical fashion. Intraoperative tissue samples were separately obtained for each breast during tissue excision from the three sites of interest (inframammary, axillary, and periareolar regions). Each tissue sample consisted of approximately 1 g of breast tissue. Samples were collected in sterile specimen containers and sent for routine culture and quantitative bacterial counts.

Note that, in this study, the axillary specimens were obtained through breast reduction incisions and not axillary incisions. As a result, the culture positivity rate may not reflect bacteria associated with the axillary skin and glands. However, for the purposes of obtaining endogenous breast bacteria, axillary samples are representative of the breast tissue in that area.

Data Processing

Tissue samples were analyzed for aerobic, anaerobic, and fungal elements. For samples with positive culture results, quantitative bacterial counts were performed and recorded as colony-forming units (CFU) per field in 1 g of breast tissue. Samples with no growth were recorded as 0 CFU per field.

Statistical Analysis

Kolmogorov-Smirnov criteria were used to establish the nonnormality of the data set. Statistical analysis was

completed with the Wilcoxon signed-rank and McNemar tests. A nonparametric test of significance, the Wilcoxon signed-rank test, was selected because it does not presuppose regular distribution for the studied variables for paired samples. In our sample, it was used to analyze the difference in bacterial counts among the three breast regions sampled. The McNemar test, which analyzes marginal frequencies of two binary outcomes for paired samples, allowed us to test for the significance of percentage positive bacteria cultures in each group. Statistical analyses were performed with Stata/SE 11.0 (StataCorp LP, College Station, TX). All *P* values reported are two-tailed, and significance levels were set to .05.

RESULTS

Culture Positivity and Bacterial Counts

The bacterial culture results of 150 breast tissue samples (three per breast for 50 breasts) were obtained and analyzed. Of the 50 breasts analyzed, 19 yielded positive results from at least one site, for a positive culture rate of 38%. Quantitative bacterial counts ranged from 212 to 36,000 CFU per field (Figure 1).

The periareolar region demonstrated a mean bacterial concentration that was, on average, five times higher than that at the inframammary site. The latter site demonstrated bacterial counts that were four times higher than those in the axillary region. These values were found to be statistically significant (Wilcoxon *P* value < .01 between the periareolar region and either of the other two; Wilcoxon *P* value < .02 between the inframammary and axillary regions). Similarly, the periareolar region was more likely than the other two sites to yield positive tissue cultures, with decreasing likelihood in the inframammary and axillary regions, respectively (McNemar χ^2 *P* < .01 between periareolar and either of the other two sites, and *P* = .05 between the inframammary and axillary regions; Table 1).

Bacterial Species Identified

The most commonly isolated organisms in this study were *Staphylococcus* species, with *S. epidermidis* present in 42% of positive cultures. *S. epidermidis* is a nonmotile gram-positive bacterium found in normal skin flora. A facultative anaerobe, this organism can thrive under many conditions.

The second-most commonly isolated organism was *Propionibacterium acnes*, present in 31% of positive cultures. In contrast to *S. epidermidis*, this bacteria is a facultative aerobe. Also present in normal skin flora, it is most commonly found in the sebaceous glands, where it lives on fatty acids. A member of the actinobacteria group, it is most commonly treated with macrolides or fluoroquinolones rather than cephalosporins.

Of the remaining culture specimens, one yielded both *S. epidermidis* and *Corynebacterium* sp. Other cultured bacteria included *Staphylococcus lugdunensis* and *Staphylococcus*

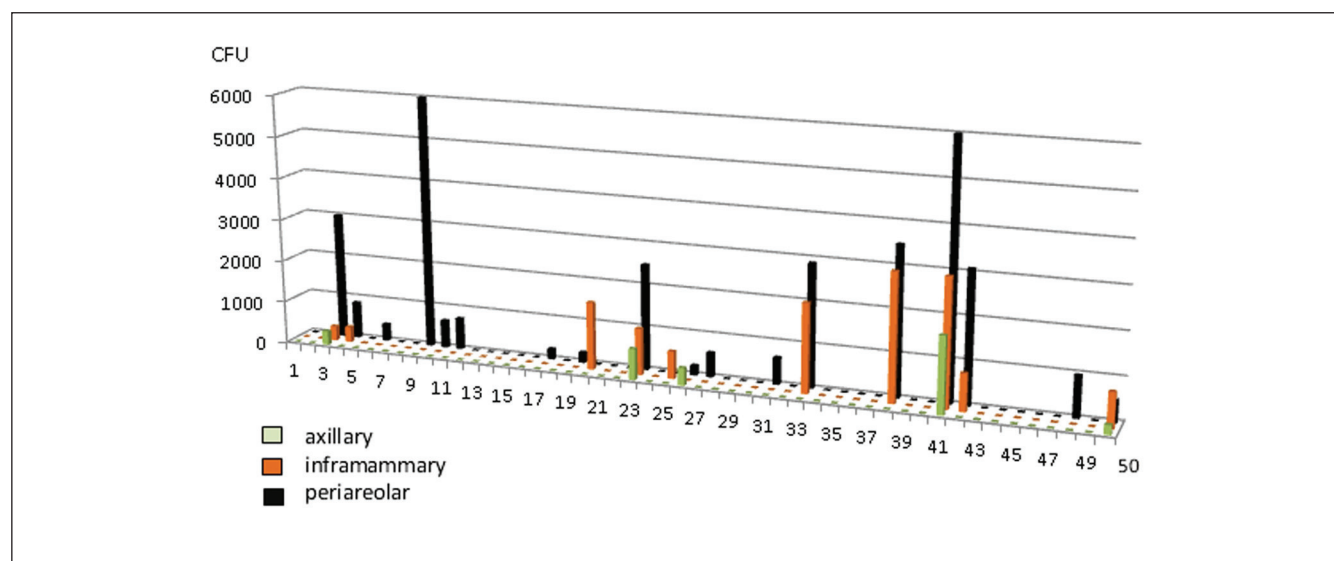


Figure 1. Quantitative culture results for all 50 breasts sampled, measured in CFU per field in 1 g of sampled tissue.

Table 1. Mean Bacterial Counts and Percentage of Positive Cultures per Sampled Site^a

	Axillary	Inframammary	Periareolar	Overall
Mean bacterial count, CFU/field	69	272	1238	401
Specimens with positive cultures, %	10	22	38	23

^aThe difference among the three groups was statistically significant, $P < .01$.

hominis. There were no fungal elements isolated in any of the specimens (Figure 2).

Again, note that the axillary specimens were obtained through breast reduction incisions and not axillary incisions. The examined axillary tissue was thus taken not from immediately below the axillary skin and associated glands but from the axillary tail of the breast. As a result, culture positivity rates may be artificially low with regard to our bacterial counts. A future study examining fat harvested just below the axillary skin would thus be helpful.

DISCUSSION

While most surgeons will agree that the breast likely harbors significant endogenous bacteria, few practitioners address this issue when performing routine breast surgery. There is, to date, minimal published data on the nature of this bacteria⁵ and none regarding its distribution within the breast tissue itself. Culture results from infected breast

abscesses or capsule specimens reveal different species of bacterial contamination, ranging from common skin flora to atypical *Mycobacteria*, but the most common culprit by far is *S. epidermidis*.^{6–10} In the setting of *S. epidermidis* contamination, foreign body seeding remains a difficult problem to prevent as well as treat. Surface proteins allow this bacterium to bind to foreign bodies. Once established, the resultant biofilm allows for the binding of other species of bacteria, as well as a decrease in metabolism that contributes to antibiotic resistance.

While there are few established criteria for predicting postoperative breast infections, certain risk factors have been associated with higher incidences of breast abscess formation. Obesity, race, and tobacco use have been implicated in certain breast infections,¹¹ as have prior radiation and extensive lymph node dissection.¹² Studies on the vulnerability of tissue expanders suggest that while the membrane is not permeable to bacteria, the port site is, which may contribute to an increase in bacterial contamination for breast reconstruction patients.¹³ Recurrent breast abscesses are also more likely to harbor gram-negative bacteria as opposed to normal skin flora,¹⁴ and these organisms are generally resistant to routine cefazolin antibiotics.

Routine perioperative antibiotics administered as single-dose, single-agent pharmacologic regimens have not been shown to be effective for preventing the development of biofilms on prosthetic materials.¹⁵ In fact, this type of seeding often requires a 1000-fold increase in medication potency for effective treatment,¹⁶ and routine antibiotics are largely ineffective.^{17,18} Once established, these bacterial coatings become effectively embedded on the implant itself, as opposed to the capsule.¹⁹ As a result, tissue cultures from capsulectomy specimens may remain negative

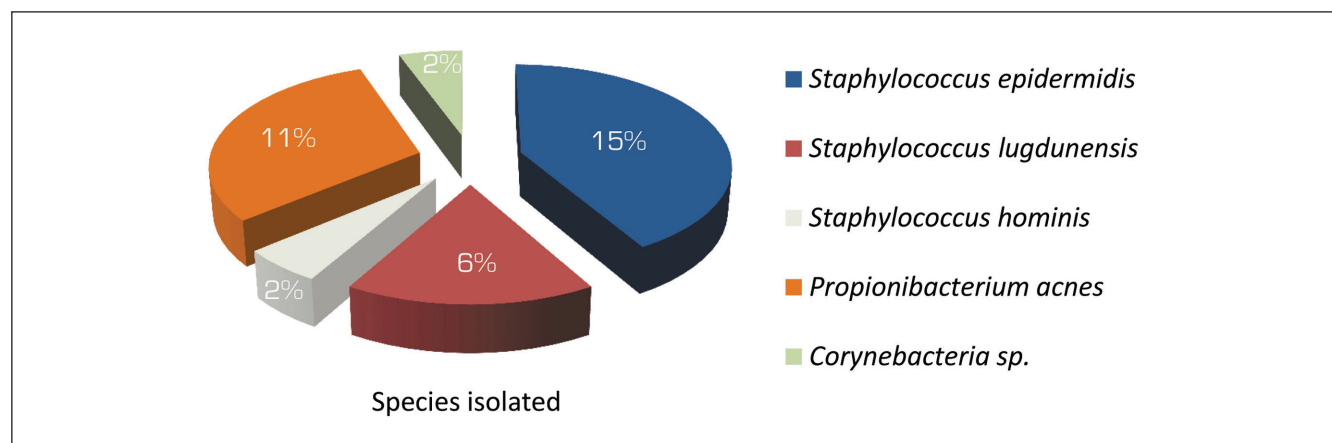


Figure 2. Results of culture speciation from all tissues sampled.

even in the presence of a significant subclinical infection of the foreign body.²⁰ With such a strong, constant, and elusive bacterial presence on the implant itself, patients are likely to endure long-term consequences of chronic inflammation.

Given that the management of a seeded implant is exponentially more difficult than the management of a routine postoperative infection, prevention is paramount. Many techniques have been suggested for short- and long-term decontamination of the breast pocket, including postoperative antibiotics administered for several days,²¹ redraping of the surgical field, and Betadine irrigation.²² Antimicrobial implant coatings and antibiotic-filled prostheses have also been attempted in the hopes of providing a continuous drug delivery system.²³ None of these methods have proven to significantly affect the rate of CC nor that of postoperative breast infections.

The only intervention to date that seems to decrease the risk of CC is the use of triple-antibiotic irrigation for the breast pocket. These data suggest that infection is the main culprit in this process and that the contamination is polymicrobial—or at least consists of a species that requires double coverage. This finding is consistent with studies of *S. epidermidis*, a common skin flora that cannot be effectively eradicated with a single pharmacologic agent. In their report, Adams et al noted that even with said irrigation, patients undergoing manipulation of the breast tissue itself (as in mastopexy) were still more likely to suffer CC.²⁴ This finding further supports our hypothesis that CC caused by infection in the breast implant pocket is likely due to bacteria present in the glandular tissue itself. Once violated, the ducts spill their contents into the field, rendering a contaminated surgical site.

The question then remains about how to prevent breast implant seeding. Patients undergoing procedures in known contaminated fields are more likely to be given broad-spectrum antibiotics, and foreign materials are less likely to be placed under such circumstances. We argue that this issue becomes most relevant when the breast tissue itself is manipulated during the procedure or when incisions are

made near the nipple. Nipple shields have been applied to protect the field from contamination with ductal bacteria,²⁵ but we suggest a more aggressive approach. For patients who are undergoing placement of a foreign body in the breast—and especially for those in whom a periareolar incision is planned—broader-spectrum antibiotics should be considered, along with triple-antibiotic irrigation of the implant pocket. Obtaining routine cultures of the glandular tissue nearest to the prosthetic device may also be considered. For patients with a history of breast infection, gram-negative coverage should be routinely included.

Today, most surgeons would categorize breast surgery as “clean” when asked or when documenting their cases. However, 80% of breast and plastic surgeons routinely prescribe perioperative antibiotics in the management of their surgical patients.²⁶ Perhaps protocol should more accurately reflect what experience has already demonstrated: The breast is not a clean surgical site.

CONCLUSIONS

The breast harbors significant concentrations of endogenous bacteria. Even under sterile operating conditions, this bacteria remains a concerning presence, one that may translate into the contamination of a foreign body placed around the breast. Routine preoperative antibiotic prophylaxis is likely inadequate to prevent the formation of biofilms on breast implants, and typical treatment regimens for identified infections are likely to be ineffective. Furthermore, as bacterial concentrations are highest near the nipple, breast implants placed through a periareolar incision may be more susceptible to this contamination and to subsequent infection-related complications.

Disclosures

The authors declared no potential conflicts of interest with respect to the research, authorship, and publication of this article.

Funding

The authors received a research grant from the Department of General Surgery at Columbia University Medical Center for the processing of the samples.

REFERENCES

- Gylbert L, Asplund O, Berggren A, Jurell G, Ransjö U, Ostrup L. Preoperative antibiotics and capsular contracture in augmentation mammoplasty. *Plast Reconstr Surg* 1990;86:260-267.
- Shah Z, Lehman JA Jr, Tan J. Does infection play a role in breast capsular contracture? *Plast Reconstr Surg* 1981;68:34-42.
- Sanger JR, Sheth NK, Franson TR. Adherence of microorganisms to breast prostheses: an in vitro study. *Ann Plast Surg* 1989;22:337-342.
- Pittet B, Montandon D, Pittet D. Infection in breast implants. *Lancet Infect Dis* 2005;5:94-106.
- Thornton JW, Argenta LC, McClatchey KD, Marks MW. Studies on the endogenous flora of the human breast. *Ann Plast Surg* 1988;20:39-42.
- Feldman EM, Ellsworth W, Yuksel E, Allen S. Mycobacterium abscessus infection after breast augmentation: a case of contaminated implants? *J Plast Reconstr Aesthet Surg* 2009;62:e330-e332.
- Haiavy J, Tobin H. Mycobacterium fortuitum infection in prosthetic breast implants. *Plast Reconstr Surg* 2002;109:2124-2128.
- Gnanadesigan N, Pechter EA, Mascola L. Listeria infection of silicone breast implant. *Plast Reconstr Surg* 1994;94:531-533.
- Hunter JG, Padilla M, Cooper-Vastola S. Late *Clostridium perfringens* breast implant infection after dental treatment. *Ann Plast Surg* 1996;36:309-312.
- Niazi ZB, Salzberg CA, Petro JA. *Paecilomyces variotii* contamination in the lumen of a saline-filled breast implant. *Plast Reconstr Surg* 1996;98:1323.
- Bharat A, Gao F, Aft RL, Gillanders WE, Eberlein TJ, Margenthaler JA. Predictors of primary breast abscesses and recurrence. *World J Surg* 2009;33:2582-2586.
- Nahabedian MY, Tsangaris T, Momen B, Manson PN. Infectious complications following breast reconstruction with expanders and implants. *Plast Reconstr Surg* 2003;112:467-476.
- Liang MD, Narayanan K, Ravilochan K, Roche K. The permeability of tissue expanders to bacteria: an experimental study. *Plast Reconstr Surg* 1993;92:1294-1297.
- Versluijs-Ossewaarde FN, Roumen RM, Goris RJ. Subareolar breast abscesses: characteristics and results of surgical treatment. *Breast J* 2005;11:179-182.
- Arciola CR, Campoccia D, Montanaro L. Effects on antibiotic resistance of *Staphylococcus epidermidis* following adhesion to polymethylmethacrylate and to silicone surfaces. *Biomaterials*. 2002;23:1495-1502.
- Uçkay I, Pittet D, Vaudaux P, Sax H, Lew D, Waldvogel F. Foreign body infections due to *Staphylococcus epidermidis*. *Ann Med* 2009;41:109-119.
- van Heerden J, Turner M, Hoffmann D, Moolman J. Antimicrobial coating agents: can biofilm formation on a breast implant be prevented? *J Plast Reconstr Aesthet Surg* 2009;62:607-610.
- Mukhtar RA, Throckmorton AD, Alvarado MD, et al. Bacteriologic features of surgical site infections following breast surgery. *Am J Surg* 2009;198:529-531.
- Pajkos A, Deva AK, Vickery K, Cope C, Chang L, Cossart YE. Detection of subclinical infection in significant breast implant capsules. *Plast Reconstr Surg* 2003;111:1605-1611.
- Rudolph R, Woodward M. Absence of visible bacteria in capsules around silicone breast implants. *Plast Reconstr Surg* 1983;72:32-37.
- Khan UD. Breast augmentation, antibiotic prophylaxis, and infection: comparative analysis of 1,628 primary augmentation mammoplasties assessing the role and efficacy of antibiotics prophylaxis duration. *Aesthetic Plast Surg* 2010;34:42-47.
- Burkhardt BR, Fried M, Schnur PL, Tofield JJ. Capsules, infection, and intraluminal antibiotics. *Plast Reconstr Surg* 1981;68:43-49.
- Nordström RE. Antibiotics in the tissue expander to decrease the rate of infection. *Plast Reconstr Surg* 1988;81:137-138.
- Adams WP Jr, Rios JL, Smith SJ. Enhancing patient outcomes in aesthetic and reconstructive breast surgery using triple antibiotic breast irrigation: six-year prospective clinical study. *Plast Reconstr Surg* 2006;117:30-36.
- Collis N, Mirza S, Stanley PR, Campbell L, Sharpe DT. Reduction of potential contamination of breast implants by the use of "nipple shields." *Br J Plast Surg* 1999;52:445-447.
- Ng D, Trivedi PM, Sharma AK, Banerjee D. Current use of antibiotic prophylaxis in breast surgery: a nationwide survey. *Breast* 2007;16:68-72.