

# The Inverted-V Chevron Umbilicoplasty for Breast Reconstruction and Abdominoplasty

Malcolm A. Lesavoy, MD; Kenneth Fan, BS; Dax A. Guenther, MD; Fernando Herrera, MD; and J. William Little, MD

Aesthetic Surgery Journal  
32(1) 110–116  
© 2012 The American Society for  
Aesthetic Plastic Surgery, Inc.  
Reprints and permission:  
[http://www.sagepub.com/  
journalsPermissions.nav](http://www.sagepub.com/journalsPermissions.nav)  
DOI: 10.1177/1090820X11430686  
[www.aestheticsurgeryjournal.com](http://www.aestheticsurgeryjournal.com)



## Abstract

The umbilicoplasty is a key component of abdominoplasty and closure of autologous abdominal wall donor sites in breast reconstruction (TRAM/DIEP). The aesthetically-pleasing umbilicus tends to be small and vertically-oriented in nature, with superior hooding and shadow, inferior retraction and slope, and positioning at the topmost level of the iliac crest. In this Featured Operative Technique, the authors describe their technique for performing an inverted-V chevron umbilicoplasty, which is their method of choice for restoring the umbilicus to an aesthetic and youthful appearance with minimal scarring.

## Keywords

abdominoplasty, umbilicoplasty, featured operative technique, body contouring

Accepted for publication July 5, 2011.

The umbilicus is unique in that it is a conspicuous scar, but one that is aesthetically essential. It is a reminder of our birth: the absence or deformation of an umbilical scar is as unsettling as it is inhuman. The navel is a vital aesthetic unit; deformities are immediately recognized due to its central position. Although repositioning of the umbilicus in abdominoplasty and abdominal wall donor-site closure (as with deep inferior epigastric perforator [DIEP] and transverse rectus abdominis myocutaneous [TRAM] flaps) is a minor component, it is a critical detail. Focus on aesthetic results can dramatically shift outcomes and patient satisfaction since an unnaturally scarred umbilicus may be the only visible scar revealing previous abdominoplasty.<sup>1</sup> Many techniques have been described for achieving aesthetic repositioning through horizontal incisions,<sup>2</sup> vertical incisions,<sup>3,4</sup> Scarpa's fascia,<sup>5</sup> deep suture lines,<sup>6-8</sup> single flaps,<sup>9-11</sup> multiple flaps,<sup>12-14</sup> de-epithelialized flaps,<sup>15,16</sup> dermabrasion,<sup>1</sup> and neoumbilical creation.<sup>17-20</sup> In designing an approach, malposition, scarring, cicatricial ring formation, and poor form should be avoided.

The aesthetically-pleasing umbilicus in thin females tends to be small, shallow, and vertically-oriented in nature, with superior hooding and shadow, inferior retraction and slope, and positioning at the level of the anterior superior iliac crest (Figure 1).<sup>4,21,22</sup> An umbilicus is usually no wider than 1.5 to

2 cm or longer than 3 cm (Figure 2),<sup>16,21</sup> and its size is proportionally decreased in smaller and thinner patients. However, with age and weight gain, fat accumulation can cause a deepening and widening of the umbilicus.<sup>11</sup> With an appropriately performed umbilicoplasty, these consequences may be reversed.

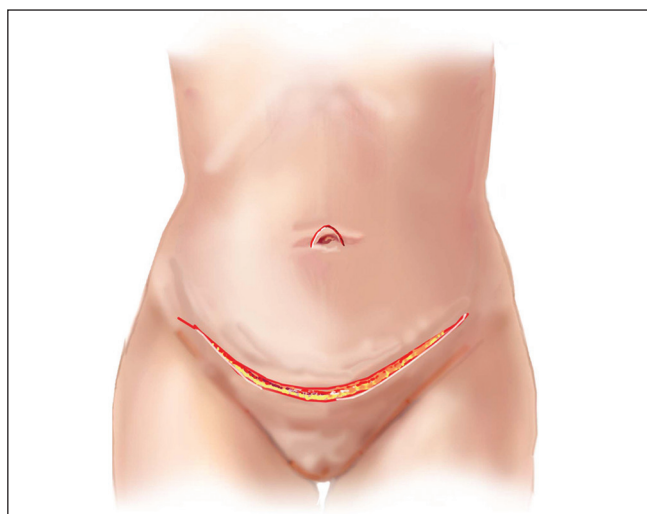
The senior surgeon's (MAL) method, the inverted-V chevron umbilicoplasty, satisfies the aesthetic concerns outlined above. The nuances of the technique support the restoration of a youthful umbilicus. In this Featured Operative Technique, the authors describe the senior

Dr. Lesavoy is Clinical Professor of Plastic Surgery and Dr. Herrera is Chief Resident on Plastic Surgery in the Division of Plastic and Reconstructive Surgery, David Geffen School of Medicine at UCLA, Los Angeles, California. Mr. Fan is a candidate for a medical degree at the University of Miami, Miller School of Medicine, Miami, Florida. Dr. Guenther is Instructor of Surgery in the Division of Plastic Surgery at Brigham and Women's Hospital, Boston, Massachusetts. Dr. Little is Clinical Professor of Plastic Surgery in the Department of Plastic Surgery, Georgetown University School of Medicine, Washington, DC.

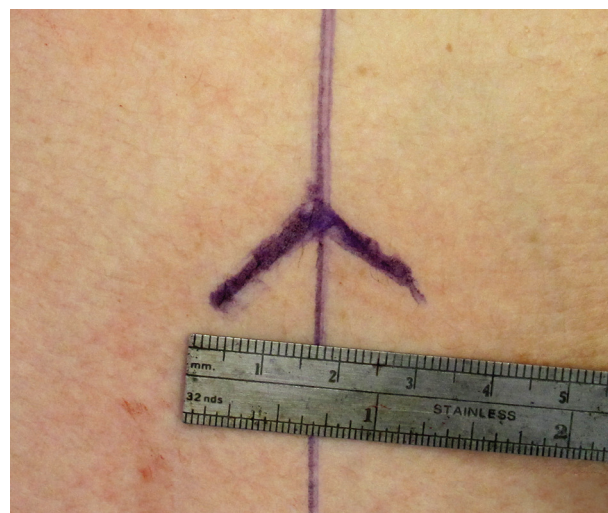## Corresponding Author:

Dr. Malcolm A. Lesavoy, 16311 Ventura Blvd, Suite 555, Encino, CA 91436-4314 USA.

E-mail: [drlesavoy@aol.com](mailto:drlesavoy@aol.com)



**Figure 1.** The ideal umbilicus sits at the topmost level of the iliac crest.



**Figure 2.** The limbs of the V-shaped incision are 1.5 to 2 cm on each side, separated by 3 cm at the base, adjusted to the patient's body habitus.

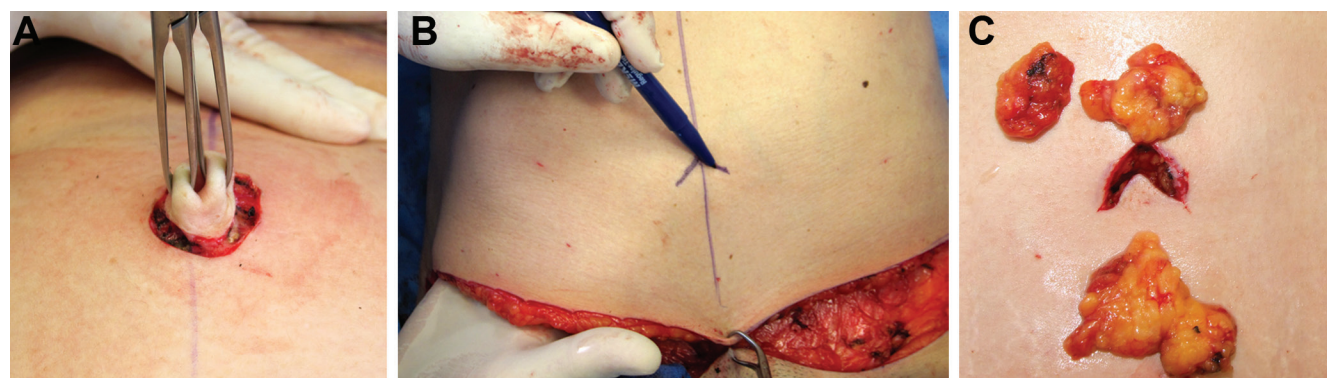
author's approach and his experience of more than 35 years with this novel technique.

## SURGICAL TECHNIQUE

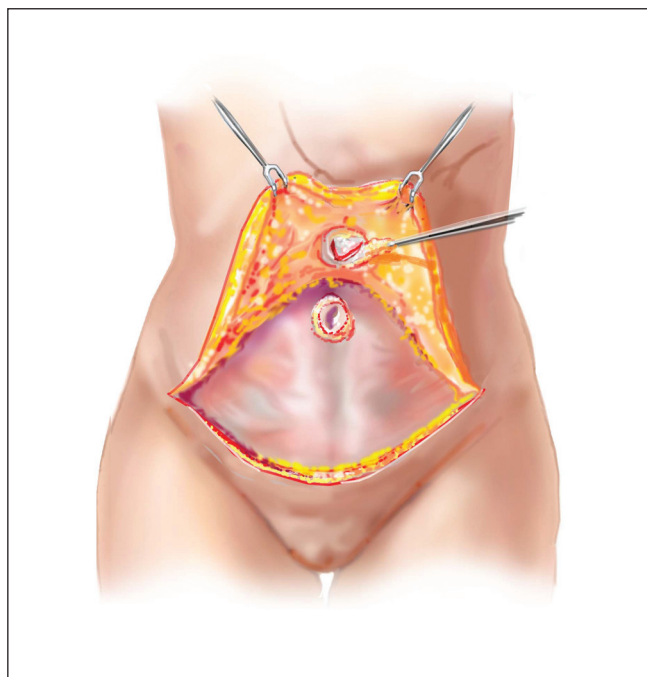
The umbilicoplasty is performed in conjunction with an abdominoplasty, under general anesthesia, with the patient in the supine position. After the abdominal flaps are dissected cephaladly, the operating table is placed in the flexed position (with the patient's hips flexed), so that proper assessment of skin resection can be performed.

Subsequently, partial closure of the abdominoplasty incision is accomplished, so proper marking of the umbilicoplasty can proceed.

To begin, the umbilicus is sharply circumscribed and separated from the abdominal flap (Figure 3A). Following the abdominoplasty or DIEP/TRAM harvest, the point of the new umbilical center is marked on the abdominal wall. The exact position is obtained by placing the surgeon's hand beneath the abdominal flap (obviously prior to closure) to determine where the native umbilicus is positioned (Figure 3B). The limbs of the V are approximately 1.5 to 2 cm each and separated by a distance of approximately 3



**Figure 3.** (A) The original umbilicus is sharply circumscribed and separated from the abdominal flap. (B) The exact location and mark of the neoumbilicus is determined by palpation of the native umbilicus under the abdominal flap. In 96% of nonobese individuals, the umbilicus sits at the highest level of the iliac crest. (C) The removed fat is placed in original positions above the skin for demonstration. Overzealous thinning can result in skin necrosis and must be avoided.



**Figure 4.** The chevron abdominal flap is raised and fat removed for inset preparation. The core of abdominal fat is removed beneath the abdominal flap to allow inset.

cm at the base (Figure 2). These parameters are tailored for the patient's body habitus. An inverted-V chevron-shaped skin flap is raised (Figure 3C) at the point of the predetermined and palpated umbilicus.

A core of abdominal fat is removed beneath the chevron abdominal flap to allow inset (Figure 4). The native umbilicus is exteriorized (Figure 5A,B) and incised vertically from its central bud to the inferior six o'clock position (Figure 5C-E). Closure is performed in two circumferential layers (Figure 6A). The first, made of 3-0 chromic captures the following: (1) the edge of the abdominal flap skin, (2) Scarpa's fascia, and (3) the umbilical stalk. Tying these sutures down effectively restores the dimpling of the abdominal skin around the umbilicus (Figure 6B,C). The superior tip of the inverted-V chevron skin flap is then inset into the central bud of the native umbilicus, and the skin flap and incisions are closed with 5-0 prolene (Figure 6B,C). The umbilicus is dressed with Xeroform (Covidien, Mansfield, Massachusetts). This maneuver, in effect, yields a half Z-plasty and interrupts a circumferential scar. After the inferiorly-based chevron inverted-V flap is cut, the remaining portion of the abdominoplasty incision is closed.

Clinical results can be seen in Figures 7 and 8.

## OUTCOMES

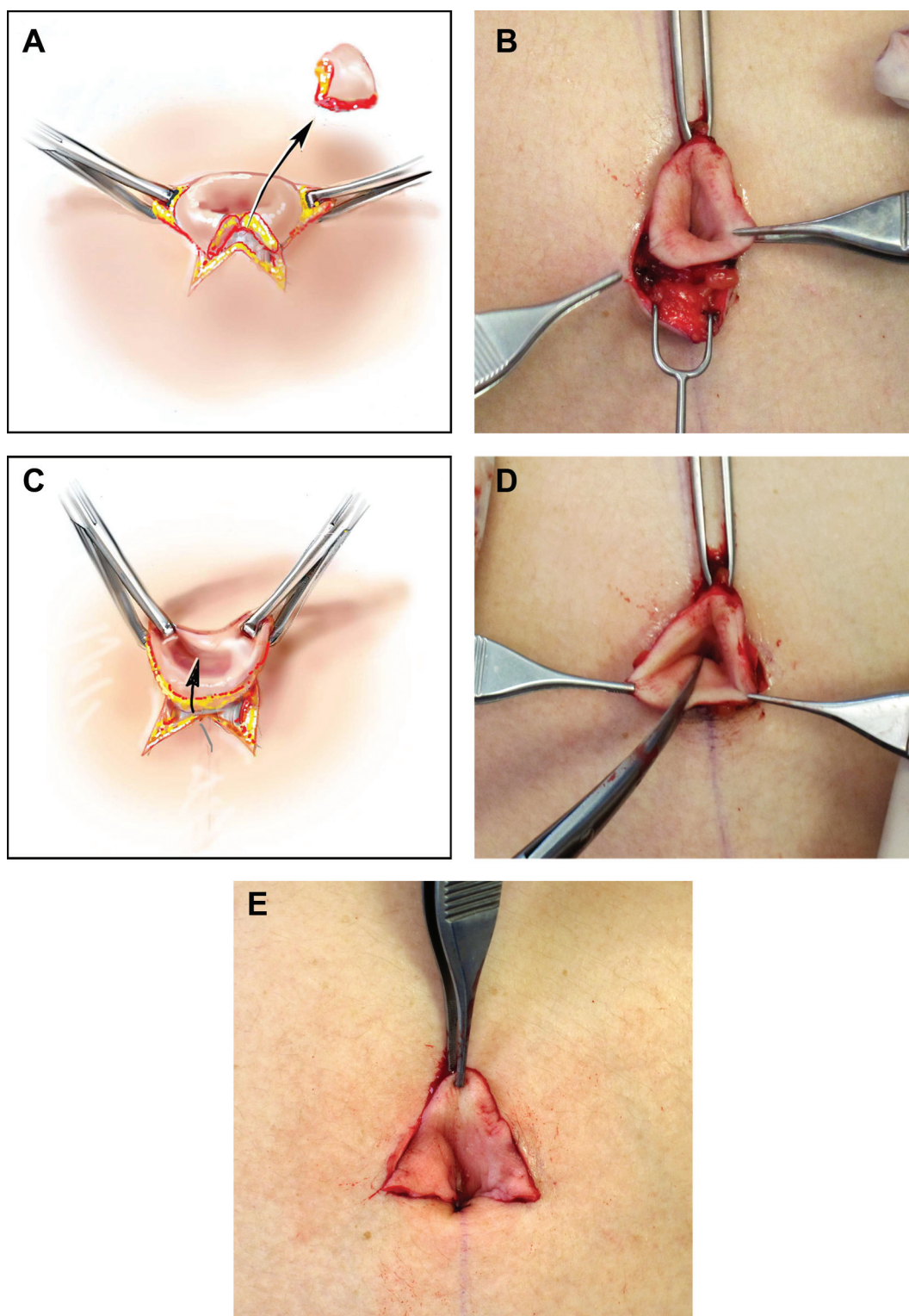
With this technique, we have experienced no cases of "misplaced umbilicus," since one is limited to the native umbilicus and its stalk. Additionally, poor blood supply or necrosis of the umbilicus has not been seen to date; however, if a patient's umbilicus had an unusually long stalk or pedicle (such as in a patient with massive weight loss), it is possible that the stalk could be telescoped, constricted, and vascularly compromised. In approximately 3% to 5% of our umbilicoplasty patients, we have observed mildly hypertrophied postoperative scarring, which can be addressed with steroid injections or scar revisions.

## DISCUSSION

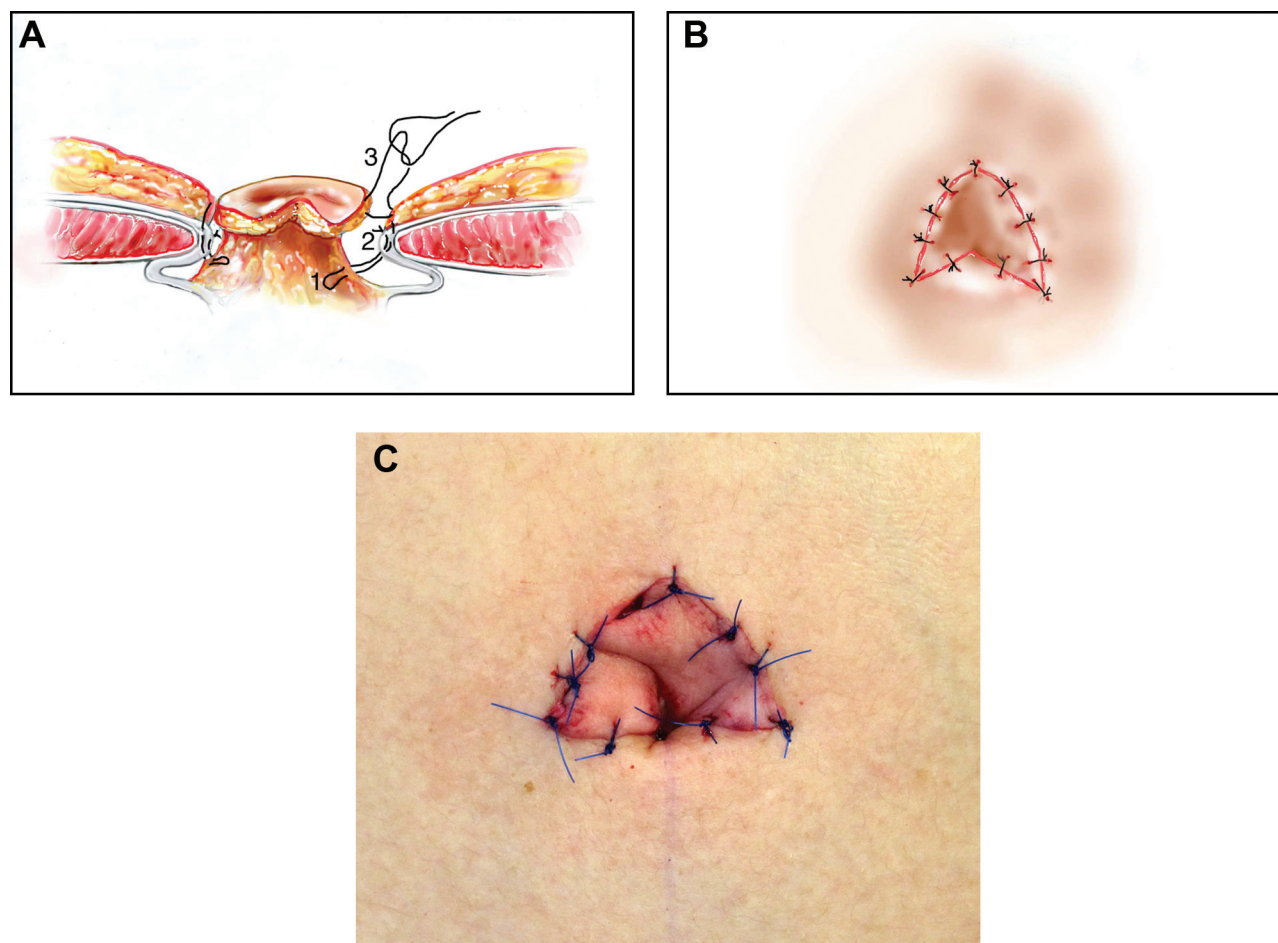
The first umbilical transposition performed during an abdominoplasty was reported by Vernon in 1957.<sup>23</sup> This technique involved circular excision of the umbilicus with reinsertion through a circular incision on the abdominal flap. Since then, various methods have been employed to achieve a natural, aesthetic umbilicus. Although the round incision is the most common mode,<sup>1,10</sup> Juri et al<sup>9</sup> described a superior-based triangular flap, Avelar<sup>24</sup> described a three-cutaneous flap, and Lee and Mustoe<sup>3</sup> described a purely vertical incision with tethering of the umbilical stalk. Other various techniques have included purse strings,<sup>1,25</sup> dermal flaps,<sup>16</sup> V-Y flaps,<sup>26</sup> and U incisions.<sup>11</sup> Ohana et al<sup>27</sup> advocated complete excision of the umbilicus and creation of a neoumbilicus rather than umbilical transposition.

The inverted-V umbilicoplasty is an advantageous technique for several reasons. The discontinuous incision prevents circumferential scar contraction. As changes occur through the effects of gravity, addressing the superior hood of the umbilicus is an essential factor in restoring a natural youthful appearance.<sup>6</sup> Through an extra incision (Figure 5C,D), the apex (in the arrowhead-shaped design of the original umbilicus) encourages natural retrusion, inferior slope, and a cranial fold, which are difficult to achieve with other techniques.<sup>11,16</sup> This superior fold, shadow, and retrusion bury the scar in an inconspicuous region, as shown with the patient in Figure 7. The V-shaped chevron incision creates the appearance of a small umbilicus with an appropriate opening. It is our opinion that other incisions, such as a small vertical one,<sup>3</sup> fail to recreate the natural shape and make the umbilicus seem contracted. Instead, the umbilicus is designed to be no greater than 1.5 to 2 cm on the borders and 3 cm at the base. Although advocated by





**Figure 5.** Exteriorization of the umbilicus. (A, B) The umbilicus is exteriorized. (C, D) The umbilicus is incised vertically from the center to the six o'clock position. (D, E) The vertical inferior umbilical incision creates a natural retrusion and cranial fold for a more aesthetically-pleasing umbilicus.



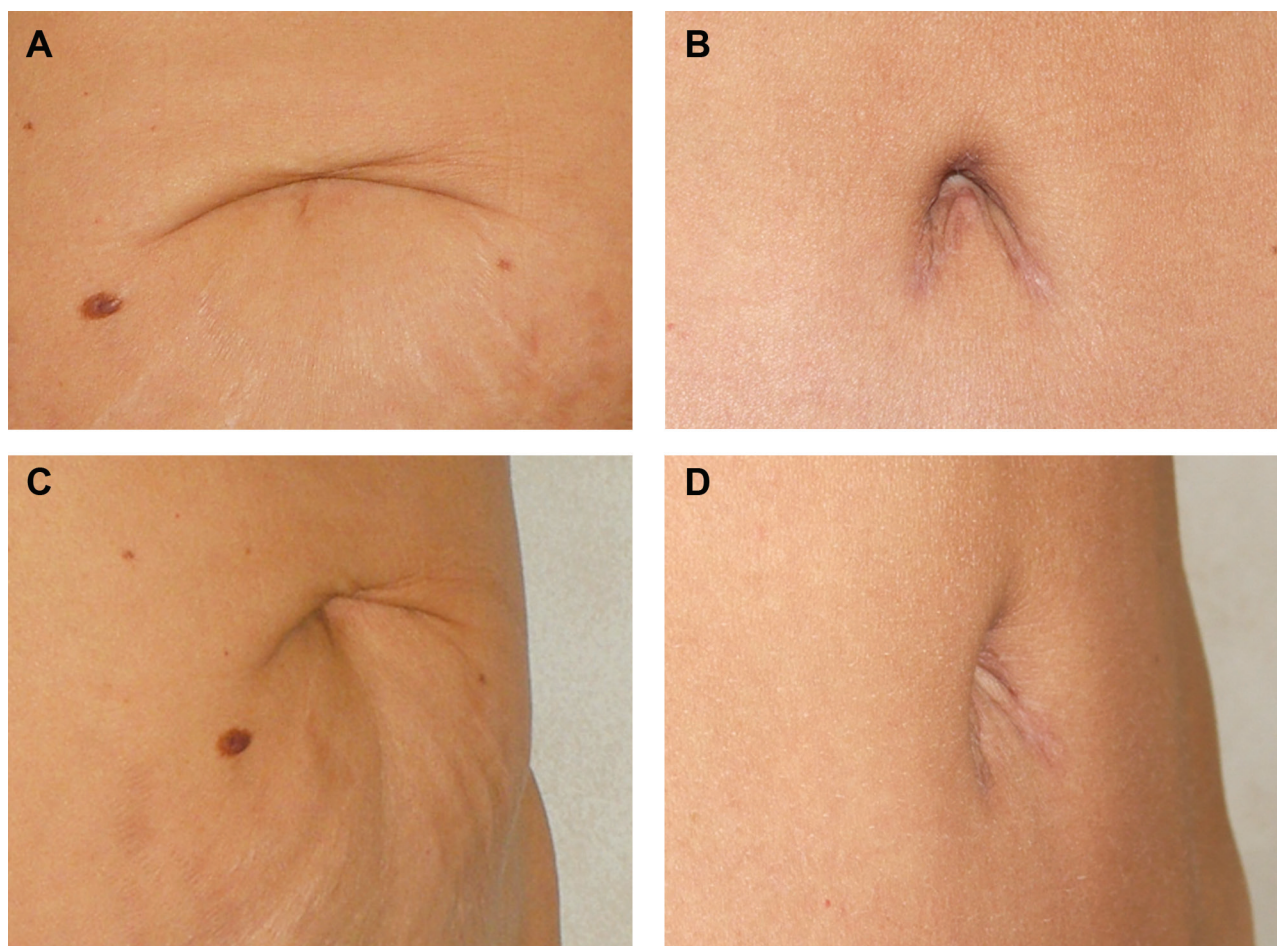
**Figure 6.** Closure proceeds in two circumferential layers. (A) 3-0 chromic sutures capture (1) the edge of the abdominal flap skin, (2) Scarpa's fascia, and (3) the umbilical stalk to recreate the dimpling of abdominal skin around the umbilicus. (B) The cephalad tip of the inverted-V chevron skin flap is inset first. (C) The skin of the flaps is sutured with 5-0 prolene.

some authors to increase depth,<sup>3,12</sup> an uncomfortable tethering sensation is experienced when the umbilicus is sutured to the abdominal fascia.<sup>5,16</sup> Instead, we suture to Scarpa's fascia to allow mobility of the umbilical stalk while still achieving a natural contour. Removal of fat from the surrounding abdominal area creates depth by accommodating the horizontal dimension of the umbilicus, hiding the scar toward the base.<sup>11,12</sup>

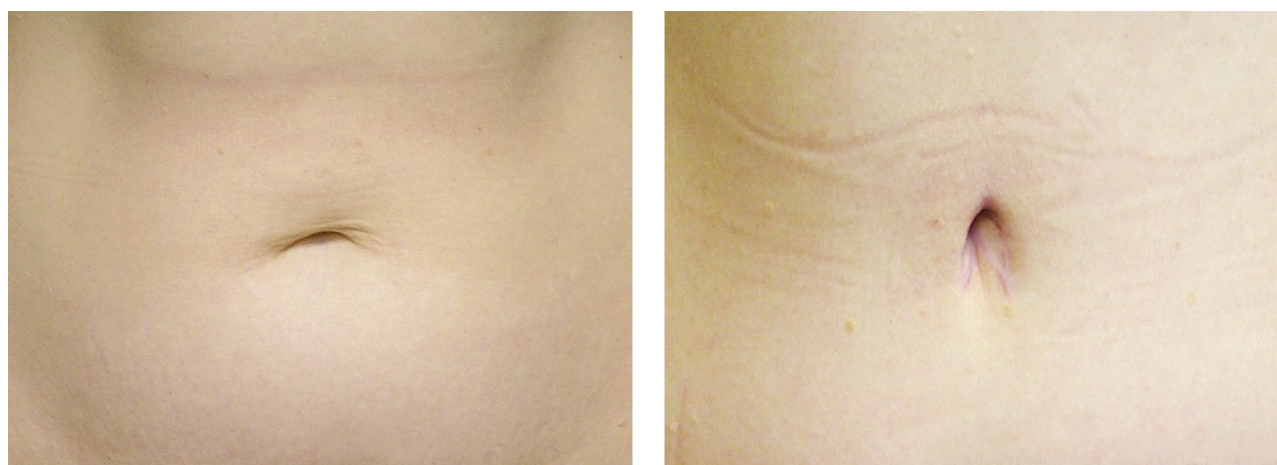Again, a small, vertically-oriented umbilicus with a superior hood and shadow is aesthetically pleasing.<sup>3,4,21,28</sup> A smooth, periumbilical contour and slope toward the base are desirable.<sup>16</sup> Lack of concavity leaves the illusion of a "floating" umbilicus. Although placement is usually at the surgeon's discretion, the umbilicus is at the highest level of the iliac crest in 96% of nonobese individuals.<sup>22</sup> Rohrich et al<sup>29</sup> identified only 1.7% of umbilicus actually in the midline.

Several pitfalls can occur during navel reconstruction. Certain techniques construct an umbilicus by modifying a continuous, circular defect with purse-stringing to the abdominal wall for creation of a concavity and fold.<sup>25,30</sup> A common result of umbilical reconstruction is a tight, cicatricial ring and hypertrophic scar, which cause flattening and umbilical stenosis, all of which can arise from an uninterrupted, round incision.<sup>1,16,31</sup> Such established stenosis may be corrected by an innovative technique described by Baack et al.<sup>32</sup> Using excessive tension when suturing skin edges can result in dehiscence and a circular scar, causing constriction as well.<sup>7,16</sup> When removing abdominal fat from the V-shaped skin flap, overzealous thinning can result in skin necrosis.<sup>5</sup> With careful and selective removal of fat, the senior author has not experienced this complication.





**Figure 7.** (A, C) This 45-year-old woman presented requesting profile improvement. She had subcutaneous fat in her abdomen, and the physical exam revealed parchment-like skin caudally (from the umbilicus down). A mild-to-moderate diastasis recti of 4 cm was identified. (B, D) Four months after abdominoplasty and inverted-V chevron umbilicoplasty. Two triangular, 10 × 11-cm abdominal flaps were excised, weighing a total of 280 g. With our technique, a superior hood and shadow, natural retrusion, and inferior retraction and slope were achieved. The shadows bury scars in inconspicuous regions.



**Figure 8.** (A) This 39-year-old woman presented with excess skin, subcutaneous fat, and abdominal weakness. She particularly expressed concern about her abdominal profile, as well as subcutaneous fat in her medial thighs, hips, and knees. She had undergone augmentation mammoplasty several years previously. She had a moderate amount of excess skin and subcutaneous fat in her upper and lower abdomen that would not necessarily be significantly improved with liposuction. (B) Four months after abdominoplasty and inverted-V chevron umbilicoplasty. Two 18 × 20-cm triangular abdominal flaps were excised, weighing a total of 1150 g. The patient's postoperative umbilicus is vertically-oriented in nature with superior hooding and shadow and shows natural retrusion, along with inferior retraction and slope.

## CONCLUSIONS

Optimum reconstruction of the umbilicus during abdominoplasty is essential. The umbilicus is the major aesthetic focus of the abdominal wall and potentially the only visual indicator that an abdominoplasty has been performed. Our method, the inverted-V umbilicoplasty, restores a natural, youthful umbilicus with minimal scarring. A superior hood, natural retrusion, and inferior retraction and slope are achieved, while avoiding umbilical stenosis with discontinuous incision. It is our procedure of choice during both abdominoplasty and closure following TRAM flap harvest.

## Disclosures

The authors declared no potential conflicts of interest with respect to the research, authorship, and publication of this article.

## Funding

The authors received no financial support for the research, authorship, and publication of this article.

## REFERENCES

- Schoeller T, Wechselberger G, Otto A, et al. New technique for scarless umbilical reinsertion in abdominoplasty procedures. *Plast Reconstr Surg* 1998;102:1720-1723.
- Baroudi R. Umbilicoplasty. *Clin Plast Surg* 1975;2:431-448.
- Lee MJ, Mustoe TA. Simplified technique for creating a youthful umbilicus in abdominoplasty. *Plast Reconstr Surg* 2002;109:2136-2140.
- Akbas H, Guneren E, Eroglu L, Uysal OA. Natural-looking umbilicus as an important part of abdominoplasty. *Aesthetic Plast Surg* 2003;27:139-142.
- Niranjan NS, Staiano JJ. An anatomical method for re-siting the umbilicus. *Plast Reconstr Surg* 2004;113:2194-2198.
- Choudhary S, Taams KO. Umbilicoplasty: a concept revisited. *Br J Plast Surg* 1998;51:538-541.
- Nahas FX. How to deal with the umbilical stalk during abdominoplasty. *Plast Reconstr Surg* 2000;106:1220-1221.
- Bruekers SE, van der Lei B, Tan TL, Luijendijk RW, Stevens HP. "Scarless" umbilicoplasty: a new umbilicoplasty technique and a review of the English language literature. *Ann Plast Surg* 2009;63:15-20.
- Juri J, Juri C, Raiden G. Reconstruction of the umbilicus in abdominoplasty. *Plast Reconstr Surg* 1979;63:580-582.
- Delerm A. Refinements in abdominoplasty with emphasis on reimplantation of the umbilicus. *Plast Reconstr Surg* 1982;70:632-637.
- Malic CC, Spyrou GE, Hough M, Fourie L. Patient satisfaction with two different methods of umbilicoplasty. *Plast Reconstr Surg* 2007;119:357-361.
- Massiha H, Montegut W, Phillips R. A method of reconstructing a natural-looking umbilicus in abdominoplasty. *Ann Plast Surg* 1997;38:228-231.
- Cannistra C, Pecorelli E. Umbilical restoration in abdominal dermolipectomy: a simple double-Y, double-M technique. *Aesthetic Plast Surg* 1999;23:364-366.
- Mazzocchi M, Dessy LA, Figus A. A versatile technique for repositioning of the umbilicus in abdominoplasty. *Plast Reconstr Surg* 2008;121:357e-358e.
- Castillo PF, Sepulveda CA, Prado AC, Troncoso AL, Vilaman JJ. Umbilical reinsertion in abdominoplasty: technique using deepithelialized skin flaps. *Aesthetic Plast Surg* 2007;31:519-520.
- Rozen SM, Redett R. The two-dermal-flap umbilical transposition: a natural and aesthetic umbilicus after abdominoplasty. *Plast Reconstr Surg* 2007;119:2255-2262.
- Lim TC, Tan WT. Managing the umbilicus during abdominoplasty. *Plast Reconstr Surg* 1996;98:1113.
- Santanelli F, Mazzocchi M, Renzi L, Cigna E. Reconstruction of a natural-looking umbilicus. *Scand J Plast Reconstr Surg Hand Surg* 2002;36:183-185.
- Ehrlich RM, Lesavoy MA, Fine RN. Total abdominal wall reconstruction in the prune belly syndrome. *J Urol* 1986;136(pt 2):282-285.
- Ehrlich RM, Lesavoy MA. Umbilicus preservation with total abdominal wall reconstruction in prune-belly syndrome. *Urology* 1993;41:231-232.
- Craig SB, Faller MS, Puckett CL. In search of the ideal female umbilicus. *Plast Reconstr Surg* 2000;105:389-392.
- Dubou R, Ousterhout DK. Placement of the umbilicus in an abdominoplasty. *Plast Reconstr Surg* 1978;61:291-293.
- Vernon S. Umbilical transplantation upward and abdominal contouring in lipectomy. *Am J Surg* 1957;94:490-492.
- Avelar J. Abdominoplasty systematization of a technique without external umbilical scar. *Aesthetic Plast Surg* 1978;2:141-151.
- Bartsich SA, Schwartz MH. Purse-string method for immediate umbilical reconstruction. *Plast Reconstr Surg* 2003;112:1652-1655.
- Jamra FA. Reconstruction of the umbilicus by a double V—Y procedure. *Plast Reconstr Surg* 1979;64:106-107.
- Ohana J, Illouz YG, Elbaz JS, Flageul G. New approach to abdominal plasties. Technical classification and surgical indications. Progress allowed by liposuction, neo-umbilicoplasty and use of biological glue [in French]. *Ann Chir Plast Esthet* 1987;32:344-353.
- Cavale N, Butler PE. The ideal female umbilicus? *Plast Reconstr Surg* 2008;121:356e-357e.
- Rohrich RJ, Sorokin ES, Brown SA, Gibby DL. Is the umbilicus truly midline? Clinical and medicolegal implications. *Plast Reconstr Surg* 2003;112:259-263; discussion 264-265.
- Marconi F. Reconstruction of the umbilicus: a simple technique. *Plast Reconstr Surg* 1995;95:1115-1117.
- Pfulg M, Van de Sijpe K, Blondeel P. A simple new technique for neo-umbilicoplasty. *Br J Plast Surg* 2005;58:688-691.
- Baack BR, Anson G, Nachbar JM, White DJ. Umbilicoplasty: the construction of a new umbilicus and correction of umbilical stenosis without external scars. *Plast Reconstr Surg* 1996;97:227-232.