

## Original Article

# The Lower Nasal Base: An Anatomical Study

Rollin K. Daniel, MD; Tibor Glasz, MD, PhD; Gyongyver Molnar, MD; Peter Palhazi, MD; Yves Saban, MD; and Bertrand Journal, MD

Aesthetic Surgery Journal  
33(2) 222–232  
© 2013 The American Society for  
Aesthetic Plastic Surgery, Inc.  
Reprints and permission:  
[http://www.sagepub.com/  
journalsPermissions.nav](http://www.sagepub.com/journalsPermissions.nav)  
DOI: 10.1177/1090820X12472695  
[www.aestheticsurgeryjournal.com](http://www.aestheticsurgeryjournal.com)



## Abstract

Currently, most rhinoplasty surgeons focus their analysis and operative techniques on the upper nasal base, with its alar cartilages. They tend to minimize the lower nasal base, composed of the columellar base, nostril sills, and alar lobules. The requisite operative techniques are often considered ancillary techniques. In this article, the authors describe anatomical composition of the columellar base, nostril sill, and alar lobule; discuss the presence of a distinct *lower nasal base*; and reevaluate the nasal musculature and the nasal superficial muscular aponeurotic system in an anatomical cadaver model. They also discuss the results of both a detailed literature review (for articles related to the levator labii superioris alaeque nasalis, orbicularis oris, depressor septi nasalis, myrtiliformis, and dilator naris) and the results of their own dissection of 45 fresh cadavers.

## Keywords

rhinoplasty, nasal base, alar cartilage, columella, nostril sill

Accepted for publication August 14, 2012.

On basilar photographs, the nasal base can be divided into an *upper* cartilaginous portion and a *lower* soft tissue portion. The lower nasal base can be subdivided into the columellar base, nostril sills, and alar lobules. Due to its noncartilaginous composition, the static shape and dynamic function of the lower nasal base are determined by skin, subcutaneous tissue, and nasal muscles. Surprisingly, there have been few in-depth anatomical studies of this area. Currently, most rhinoplasty surgeons focus their analysis and operative techniques on the upper nasal base, with its alar cartilages. They tend to minimize the importance of the lower nasal base, composed of the columellar base, nostril sills, and alar lobules. The requisite operative techniques are often considered ancillary techniques.

Because the lower nasal base is an important dynamic functional component of the nose and its composition is determined by numerous muscles that help to form the columellar base, nostril sills, and alar lobules, it deserves further study. Functionally, profound changes occur in the dilatation and compression of the nostrils due to the dynamic interplay of their muscles, subcutaneous tissue, and fibrous septa. Equally, the lower nasal base represents the interface of the intraface through its connections with the facial superficial musculoaponeurotic system (SMAS). In this article, we discuss the current literature and our findings from a dissection study of 45 fresh cadavers.

## AESTHETICS AND TERMINOLOGY

### Lower Nasal Base

The term *nasal base* refers to the bottom third of the nose as seen on upward view, when the head is tilted back.<sup>1</sup>

Dr Daniel is Clinical Professor, Division of Plastic Surgery, University of California, Irvine, Irvine, California. Dr Glasz is Associate Professor of Pathology in the Second Department of Pathology, Dr Molnar is a general surgery resident, and Dr Palhazi was a medical student at the time this article was written at Semmelweis University, Budapest, Hungary. Dr Saban and Dr Journal are both Faculte de Medicine, Laboratory of Anatomy, The University of Nice-Sophia Antipolis, Nice, France.

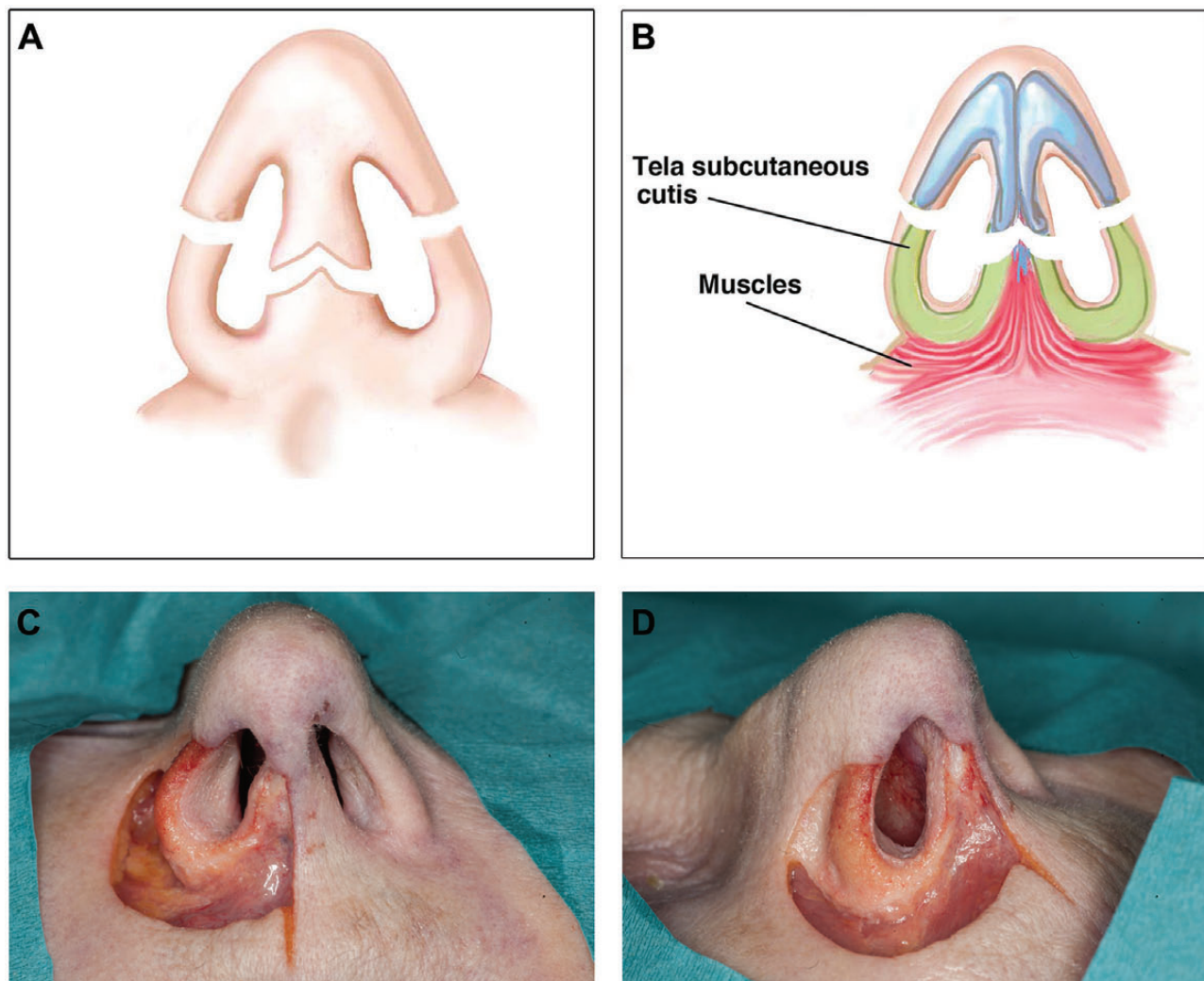
Presented in part at the Annual Meeting of the Rhinoplasty Society; May 3, 2012; Vancouver, Canada.

### Corresponding Author:

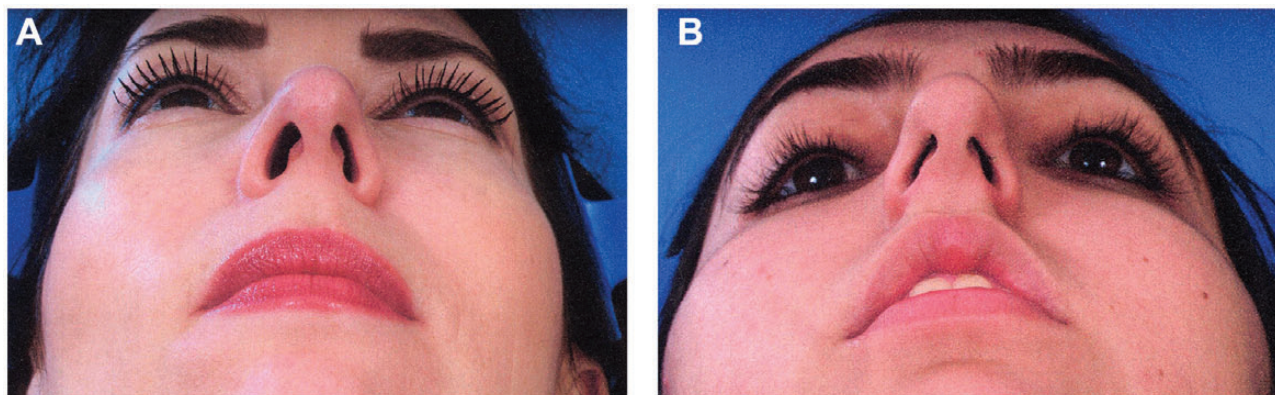Dr Rollin K. Daniel, 1441 Avocado Ave, Ste 398, Newport Beach, CA 92660, USA.  
E-mail: [rkdanielmd2@gmail.com](mailto:rkdanielmd2@gmail.com)



Scan this code with your smartphone to see the operative video. Need help? Visit [www.aestheticsurgeryjournal.com](http://www.aestheticsurgeryjournal.com).



**Figure 1.** (A, B) The nasal base can be divided into an *upper* portion, containing the alar cartilages, and a *lower* portion, composed of soft tissue. (C, D) Dissection shows the tela subcutaneous tissue and surrounding musculature.



**Figure 2.** (A) The lower nasal base comprises the columellar base, nostril sill, and alar lobule. (B) Clinically, one can see a wide range of aesthetic and functional deformities.

One can arbitrarily define the lower nasal base as the soft tissue component of the nasal base incorporating the

columellar base, nostril sills, and alar lobules (Figures 1 and 2). This structure is important based on the wide range of

presenting deformities and its anatomical composition, which is determined by fibromuscular tissues rather than cartilage. Obviously, the upper nasal base would be that portion of the base influenced by the alar cartilages.<sup>2</sup>

## Columellar Base

The columellar base can be arbitrarily defined as extending vertically from the divergence point of the medial crura down to the subnasale, or as a line drawn between the alar base-cheek junction point. Transversely, the columellar base slopes downward from the footplates to the nostril sills.

## Nostril Sill

The nostril sill is the floor of the nostril aperture. In most cases, it is a distinct segment with a “roll” border. One can arbitrarily define the nostril apices as superior and inferior. Often, there is a distinct alar base-nostril sill junction that corresponds to the inferior apex of the nostril.<sup>3</sup> This “base-sill junction” marks the lateral extent of the nostril sill. The medial border of the sill is marked by a vertical line drawn from the lateral border of the footplates. The nostril sill is often a vertical “roll,” which can be either defined or undefined.

## Alar Lobule

The alar lobule represents the side walls of the nasal base and is most visible on lateral view.<sup>4</sup> Essentially, the alar lobule is outlined by the alar groove, beginning at the nostril rim and then running in an almost circular shape down to the alar crease. The alar lobule is essentially a “sandwich” composed of subcutaneous tissue on top and muscles below, with interconnecting vertical septae.<sup>5</sup>

## CADAVER STUDY

To fully understand the anatomy of this region, we performed dissection studies in 45 fresh cadavers at the time of autopsy. These were not fresh-frozen cadavers, nor were there any storage distortions. All dissections were done under 2.5 × to 3.5 × loupe magnification. An initial 15 dissections were done to identify specific structures and areas of interest. Next, a definitive series of 15 cadavers totaling 30 hemi-nose dissections were done. Subsequently, an additional 15 dissections were completed to clarify specific points, and biopsies were taken for histological studies.

In an additional 3 cadavers, the entire nose was excised “en bloc” and the nostrils packed to avoid distortion during the fixation process. All specimens were immediately fixed in 10% formalin. After decalcification in 5% chlorhydric acid, the specimens were embedded in paraffin. Full-width cross sections were then done at 7 levels, stained

with Masson trichrome, and observed under light microscopy.

A video of these cadaver dissections and the muscular anatomy is available at [www.aestheticsurgeryjournal.com](http://www.aestheticsurgeryjournal.com). You may also use any smartphone to scan the code on the first page of this article to be taken directly to the video on [www.YouTube.com](http://www.YouTube.com).

## NASAL MUSCULATURE

As part of our study, we performed a literature review, searching for articles related to the levator labii superioris alaeque nasalis, orbicularis oris, depressor septi nasalis, myrtiformis, and dilator naris. The following review of our results is an attempt to simplify and reconcile the surgical anatomy of the nasal musculature that affects the lower nasal base, as derived from our own cadaver dissections and those in the literature. Due to differences in terminology, any discussion of the nasal musculature is fraught with confusion and conflict. As noted in sequential editions of *Gray's Anatomy*, the myrtiformis muscle was included as a nasal muscle, then deleted, and eventually restored.<sup>6</sup> The depressor septi nasalis is an example of a muscle whose composition, origin, and insertion can be arbitrarily redefined by surgeons with or without regard to prior anatomical terminology.

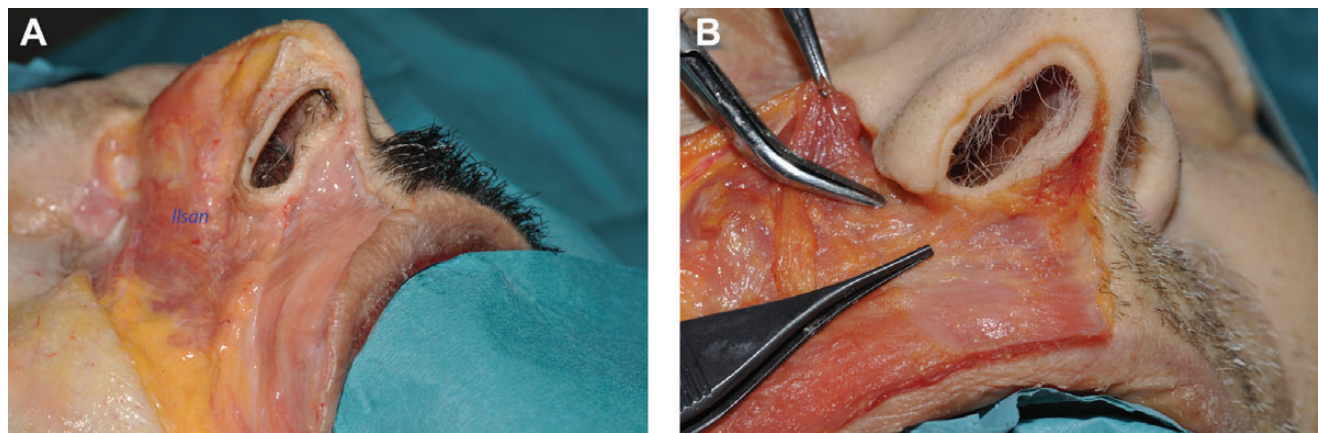
## Levator Labii Superioris Alaeque Nasalis

The levator labii superioris alaeque nasalis (LLSAN) has often been classified as one of the many muscles of the mouth, yet its impact on the nose is even greater (Figure 3). Its origin is on the frontal process of the maxilla, nasal bone, and medial canthus. It then descends in 2 parts: alaris and labiocolumellaris.<sup>7</sup> The *alaris portion* enters the upper edge of the lower lateral cartilage, then the skin of the alar base, and intertwines with the dilator naris. The *labial portion* continues around the nasal base toward the philtral column of the upper lip, intermingling with the fibers of the myrtiformis and orbicularis oris. The alaris portion lifts and expands the nostril, whereas the labial portion depresses the tip. The LLSAN was easily and consistently identified in all of our dissections. After its alaris portion inserts into the alar base, the medial border of the labial portion becomes the defining muscle of the alar crease, and the lateral border helps define the triangle area between the nasolabial line and alar base. The labial portion continues toward the columellar base with its inferior border joining the superficial portion of the orbicularis oris. Through its intermingling with the superficial orbicularis oris muscle, it acts as a significant depressor of the nostril tip.

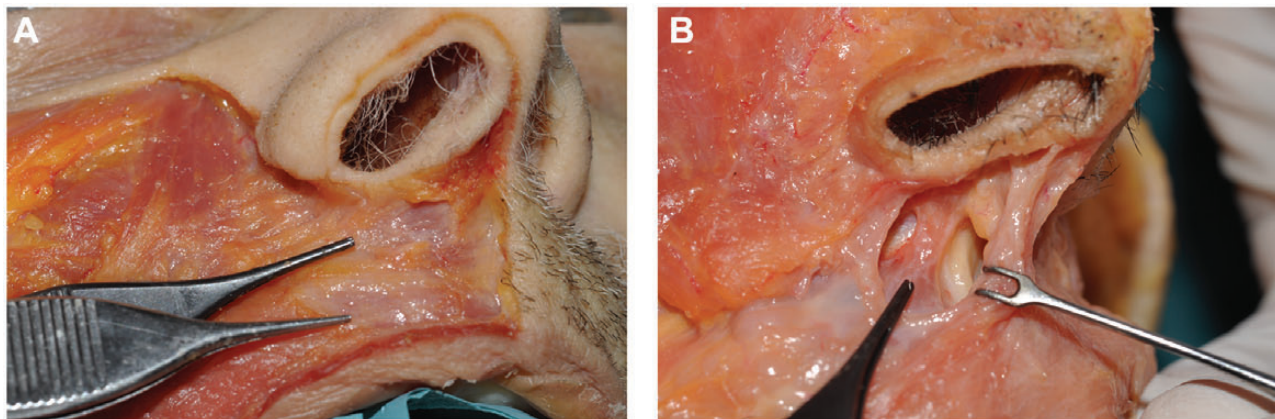
## Orbicularis Oris

Nicolau<sup>8</sup> has divided the orbicularis oris muscle into a deep and a superficial portion. The deep portion of the





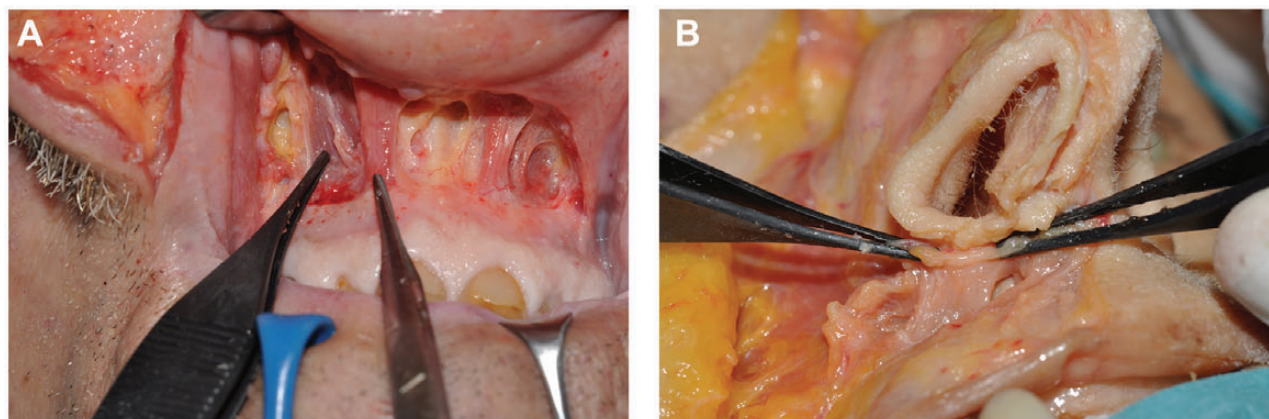
**Figure 3.** Levator labii superioris alaeque nasalis (LLSAN). (A) The interface between nasal and lip musculature. (B) The 3 portions of the LLSAN: muscle belly (clamp), alaris insertion into the alar crease (scissors), and the labialis continuation into the columellar base (forceps).



**Figure 4.** Superficial orbicularis oris. (A) The superficial orbicularis oris is divided into a labialis portion (superficial orbicularis oris labialis [SOOL])—lower forceps and a nasalis portion (superficial orbicularis oris nasalis [SOON])—upper forceps. (B) The SOON is the dominant component of the columellar base (double hook), whereas the depressor septi nasalis is located deeper (forceps) next to the anterior nasal spine.

orbicularis oris exists as long, continuous fibers from one modiolus to the other. It functions as an oral constrictor. The superficial portion of the orbicularis oris is divided into a lower nasolabial bundle (superficial orbicularis oris labialis [SOOL]) and an upper nasal bundle (superficial orbicularis oris nasalis [SOON]) whose function is both speech and facial expression (Figure 4). The SOOL is essentially a transverse muscle originating on each side from the modiolus, then running across the lip to insert into the skin as either short fibers (ipsilateral philtral column) or long fibers (contralateral philtral column). The SOON originates laterally from the 2 zygomaticus and 2 levator muscles on either side and then runs on an angle up into the columellar base. From our dissections, the superficial orbicularis oris was extensive and easily divided into SOOL and SOON based on the orientation of the muscle fibers. In contrast to the surgical literature, the nasal

portion of the superficial orbicularis oris (SOON) was found to be an integral and critical portion of the lower nasal base. As the SOON ascends medially, it defines the upper lip, whereas its fusion with the LLSAN sets off the paranasal triangle. Inferiorly, it is tempting to speculate that the skin expression of the “transverse line” that occurs on forceful smiling represents the junction between the SOOL and SOON. Most important, it is the midline fusion of the 2 SOON, which constitutes the bulk of the muscle tissue in the columellar base. In 14 of 15 cadavers in our study, the depressor septi nasalis was a paired deep muscle originating from the maxilla and did not provide the majority of the muscle mass to the columellar base. The insertion of the SOON was into the footplate of the medial crura and the continuation of the superficial medial SMAS within the membranous septum. Based on our dissections, the SOON is a powerful depressor of the nasal tip and



**Figure 5.** Myrtiformis muscle. (A) The muscle originates from the maxillary fossa of the premaxilla above the lateral incisor (forceps). The depressor septi nasi originates above the central incisor (scissors). (B) The myrtiformis muscle inserts into the floor of the nostril.

dilator of the nostrils, irrespective of its more commonly attributed roles in speech and facial expression. In contrast to most surgical illustrations, the entire paranasal and upper lip area is encircled by a continuous superficial layer of muscle composed of the LLSAN and superficial orbicularis oculi.

### Myrtiformis Muscle

As noted by Figallo and Acosta,<sup>6</sup> the myrtiformis muscle (MM) has been described and omitted by anatomists through the years and currently is absent from most surgical atlases of nasal surgery.<sup>9</sup> Classically, the myrtiformis was divided into inner (medial) fibers, which went to the mobile subseptum as the depressor septi nasalis, and outer (lateral) fibers, which surrounded the nostril base as the depressor alae nasi muscle. Because of their surgical relevancy, we will consider the depressor septi nasalis and myrtiformis as 2 separate muscles. The MM originates from the myrtiform fossa of the maxilla, just above the lateral incisor and canine teeth. It divides into an anterior labial part, which goes to the upper lip, and a posterior nostril part, which inserts on the nostril floor. Its fibers intertwine with the dilator naris and the alar portion of the LLSAN. Figallo<sup>10</sup> stated that the MM depresses and expands the nostril—hence the name *depressor alae nasi*—which counteracts the elevator of the nostril (the alar portion of the LLSAN). Based on our dissections, the myrtiformis was easily identified in all cadavers through a gingival incision just above the lateral incisor and canine (Figure 5). It had a broad origin (10–15 mm) along the maxilla and ran straight up to insert in the nostril sill and columellar base. Alternatively, we could easily expose the MM as it inserted into the nostril sill by separating the junction between the LLSAN and the superficial orbicularis oris. It was even possible to trace the insertion of the myrtiformis into the curved core of the nostril sill.

### Depressor Septi Nasalis

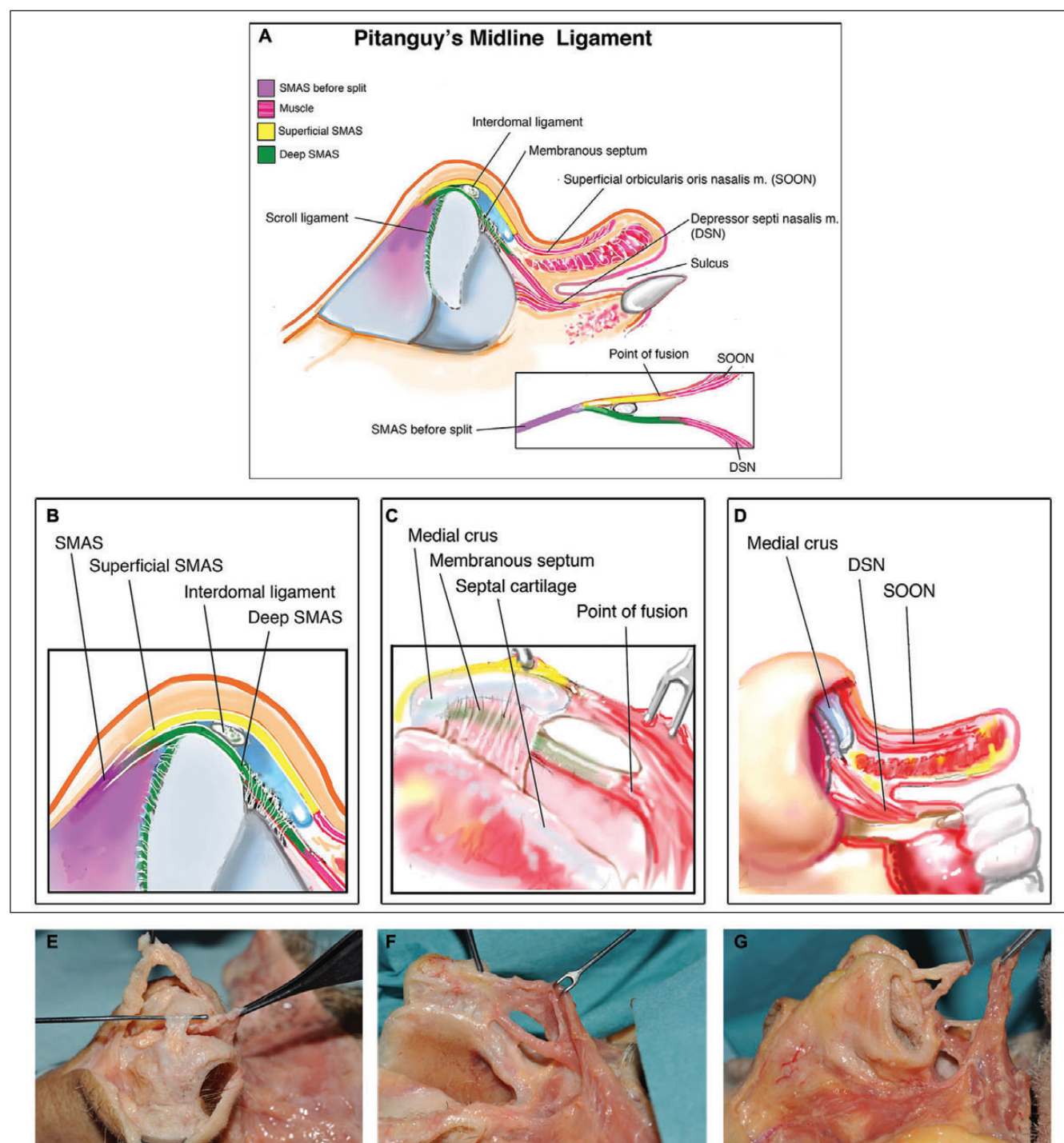
Few muscles have been as ignored or misrepresented as the depressor septi nasalis (DSN). Depending on the approach of the dissection, the origin of the muscle is considered to be at the maxilla, above the incisors, when a gingival approach is used but attributed to the orbicularis oris when a top-down dissection is used.<sup>11,12</sup> It is often considered a part of the myrtiformis or a small attachment of the orbicularis oris. In 1998, de Souza Pinto et al<sup>13</sup> discussed in detail the anatomy and surgical treatment of the DSN. The insertion of the DSN is extremely important, as de Souza Pinto et al state that the median part of the depressor septi nasalis passes through the membranous septum to connect with the distal part of Pitanguy's ligament.

On the basis of our dissections, we found distinct paired DSN muscles originating from the maxilla directly above the central incisor in 14 of 15 cadavers (Figure 6). In 1 case, the muscle appeared to originate from the orbicularis oris rather than the maxilla. In all cadavers, the midportion of the muscle was beneath and easily separated from the overlying superficial orbicularis oris. The DSN inserted into the anterior nasal septum, then the footplates of the medial crura, and continued into the membranous septum. In patients with a thicker skin envelope, it was possible to show a distinct continuation of DSN into the deep median SMAS, thus confirming the original observations of Pitanguy<sup>14</sup> and de Souza Pinto et al.<sup>13</sup> Due to the large cross-sectional diameter of the muscle and its broad insertion into the mobile columella and alar cartilages, its role as a depressor of the nasal tip was easily confirmed.

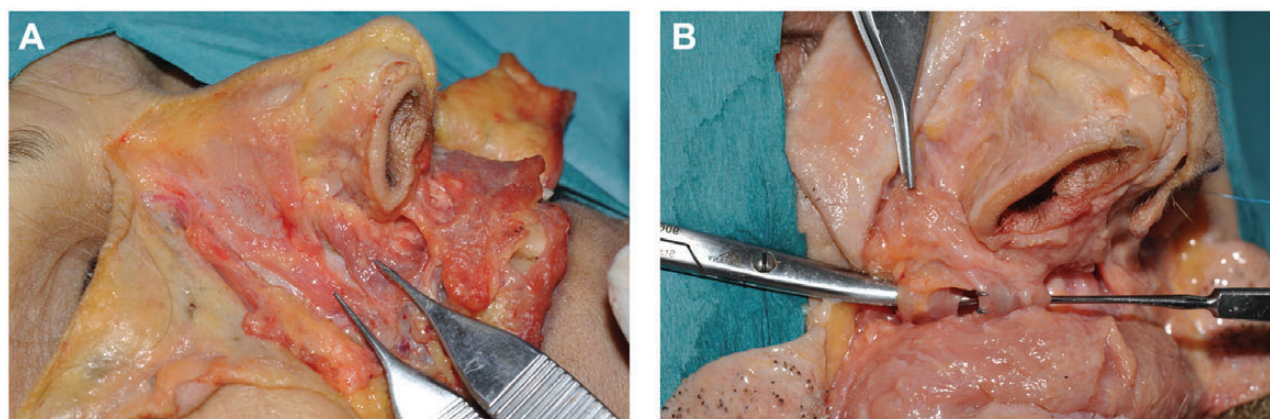
### Dilator Naris

Anatomists have always identified a “dilator naris” (DN), but they have also described multiple variations.<sup>15,16</sup> One





**Figure 6.** Depressor septi nasalis (DSN). (A) The relationship of the nasal muscles with the nasal superficial musculoaponeurotic system (SMAS). (B, C) The right superficial orbicularis oris labialis (SOOL) is being elevated (forceps) to expose the lower DSN (double hook) as it comes off the maxilla. The left superficial orbicularis oris nasalis (SOON) (forceps) runs into the columellar base. (D, E) The DSN entering the membranous septum. (F, G) The connection between the DSN and Pitanguy's midline ligament runs below the interdomal ligament, which is elevated on the probe. The superficial portion of Pitanguy's midline ligament interconnects with SOON above the interdomal ligament. The dynamics of this interconnection are clearly shown on the video.



**Figure 7.** Dilator naris and modiolus alae nasi. (A) The dilator naris (lower forceps) is shown running from the maxilla into the substance of the alar lobule, whereas the transversalis (upper forceps) courses superiorly. (B) The modiolus alae nasi is composed of multiple muscles, including the levator labii superioris alaeque nasalis (forceps), dilator naris (scissors), and myrtiliformis muscle (double hook). The modiolus alae nasi depresses and expands the nostril.

group defined it as the nasalis portion of the transverse nasalis,<sup>10</sup> another described it as the deep layer of the levator labii superioris,<sup>11</sup> and still others have considered it a separate muscle.<sup>17</sup> On the basis of our dissections, we consider it a distinct muscle with its origin from the maxilla at the level of the canine tooth, just lateral to the origin of the myrtiliformis muscle and medial to the origin of the transversalis muscle (Figure 7). It runs beneath the LLANS into the nasal base and constitutes the bulk of the alar base. It is considered the main dilator of the nostril.

## RESULTS OF THE CADAVER STUDY VS OTHER PUBLISHED LITERATURE

Although our dissections often focused on the detailed anatomy of individual muscles, it became obvious that collectively, these muscles comprised a larger anatomical entity—the “lower nasal base.” Furthermore, it was apparent that the lower nasal base is not an isolated structure but rather is integrated into the nasal SMAS and even the entire facial musculature. Functionally, it is not a static structure but is very dynamic with a critical physiological role in respiration, ranging from dilatation to narrowing to even collapse of the external valve. Therefore, it is essential to see the lower nasal base as it interacts with adjacent structures.

### Columellar Base

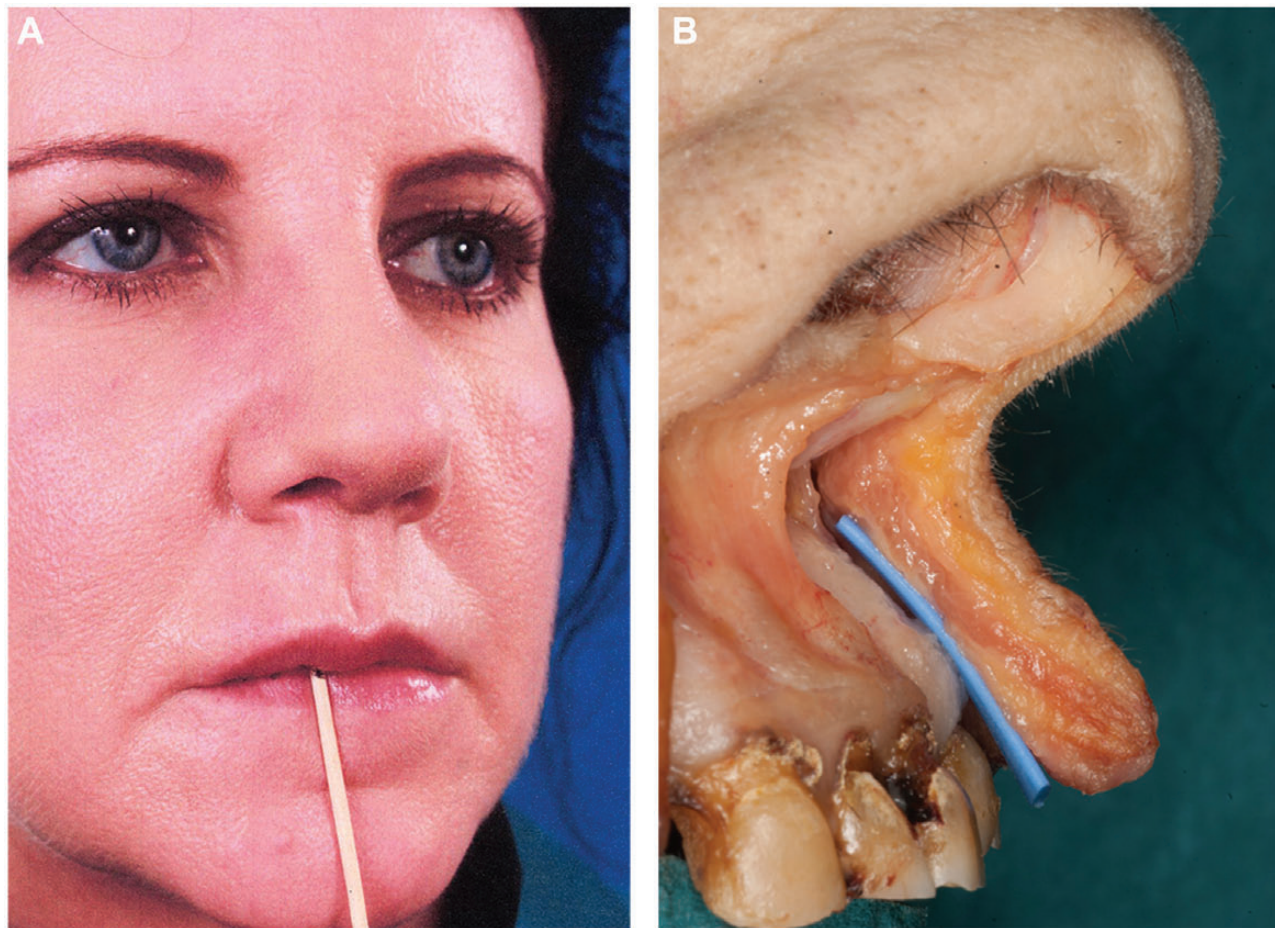We have arbitrarily defined the columellar base as extending vertically from the divergence of the medial crura footplates down to the level of the subnasale (SN).<sup>18</sup> Figallo and Acosta<sup>6</sup> state that 4 muscles join together in the columellar base to depress the tip and tense the membranous septum: depressor septi nasalis, dilator naris,

labial portion of the levator labii superioris alaeque nasi, and orbicularis oris. Our dissections indicate that the dominant muscle of the columellar base is the SOON. In addition, we found that the SOON continues in front of and between the crura to interdigitate with the superficial portion of the medial SMAS, which passes over the interdomal ligament.

### Depressor Septi Nasi and Pitanguy's Ligament

Our dissections indicated the presence of a distinct DSN in all cadavers. In 1 of 15 dissections, our top-down approach indicated that the DSN originated from the orbicularis oris rather than the maxilla. Subsequently, we evaluated patients using cotton Q-tips to determine the height of the gingival sulcus (Figure 8). Clinically, a Q-tip placed in the space between the upper lip and the maxilla easily reaches beneath the nostril sill. Thus, if the DSN originates from the maxilla, it cannot cross the gingival sulcus to become a part of the orbicularis oris. Therefore, we attribute our finding of an orbicularis oris origin to be a dissection error from a top-down approach. In an additional 5 dissections, we found that the DSN clearly originates from the maxilla just above the central incision, which does not agree with the findings of Rohrich et al<sup>12</sup> in assigning the origin of the DSN to the footplates of the medial crura (Figure 9). We found the DSN in all cadavers (20/20) in contrast to Rohrich et al,<sup>19</sup> who reported it absent in 16% of dissections. Equally, we found the DSN to be a distinct entity and separate from the MM. In most cases, the differences were as follows: (1) origin was above the central incisor for the DSN and above the lateral incisor for the MM; (2) the muscle bellies were different sizes, with the DSN narrow (5-7 mm) and the MM wide (10-15 mm); and (3) the 2 muscles were separated by soft tissue and neurovascular bundles.





**Figure 8.** Origin of depressor septi nasi (DSN). (A) The blue mark on the Q-tip indicates the height of the labial sulcus separating the premaxilla from the upper lip. (B) The blue silicone sheet is placed in the gingival sulcus, thus separating the premaxilla, with the origin of the DSN from the upper lip with its orbicularis oris.

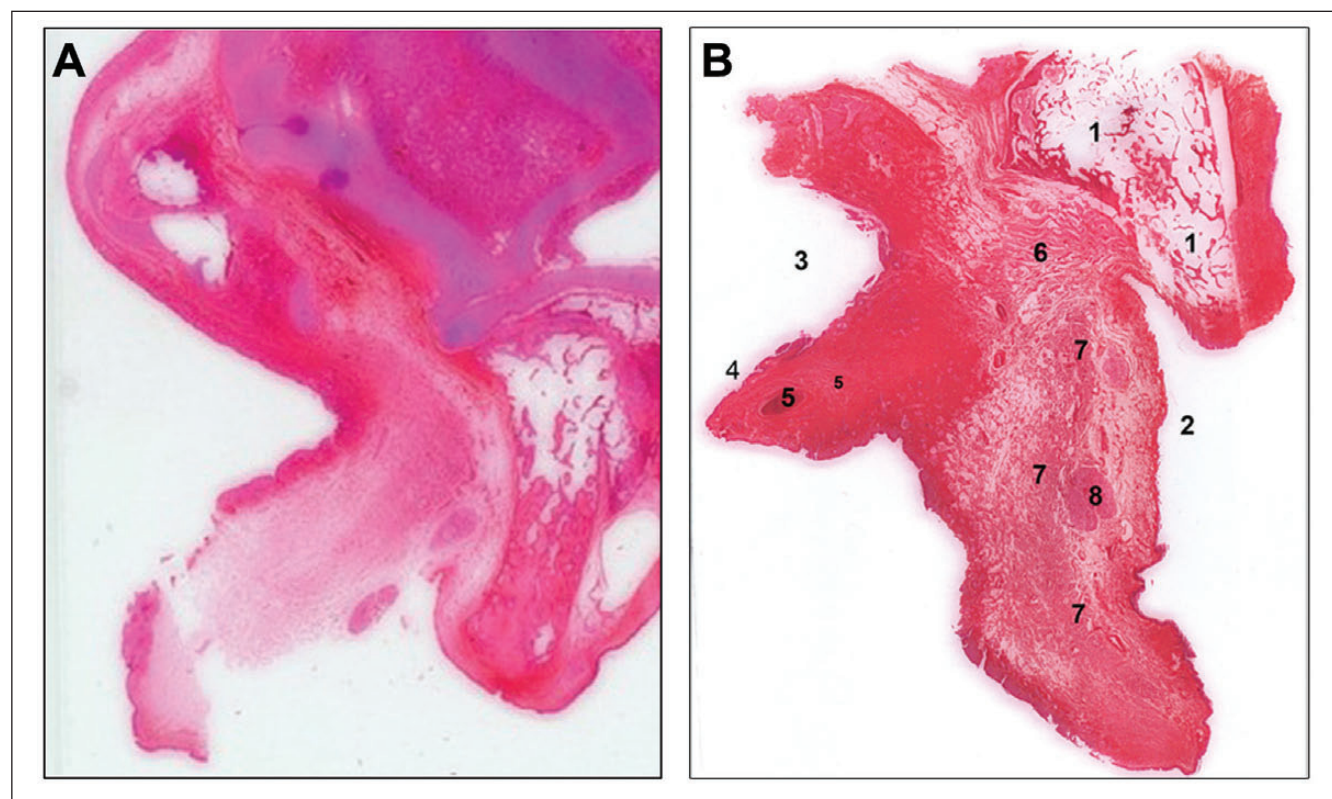
The connection between the DSN and Pitanguy's ligament was noted by Pitanguy<sup>20,21</sup> as well as de Souza Pinto.<sup>11</sup> However, it must be noted that recently Saban et al<sup>22</sup> have demonstrated that the medial SMAS at the level of the internal nasal valve divides into a superficial and a deep layer. The superficial medial layer runs caudally below the interdomal fat pad but above the interdomal ligament into the columella.<sup>23</sup> The deep medial layer of the SMAS runs beneath the interdomal ligament but above the anterior septal angle into the membranous septum and then downward toward the anterior nasal spine. Saban et al concluded that the deep medial SMAS could correspond to Pitanguy's ligament. Based on the accepted 5-layer laminate concept of the nasal soft tissue envelope,<sup>24</sup> Pitanguy's ligament cannot be a true dermocartilaginous ligament. Pitanguy described the ligament as originating on the undersurface of the dermis and running tangentially down to and in between the alar cartilages, thus violating the layer concept of the soft tissue envelope. To acknowledge the contributions of Pitanguy, we will use the term *Pitanguy's midline ligament*. Our dissections confirm these prior observations but emphasize that the

connection is between the DSN and the deep medial SMAS, which passes beneath the interdomal ligament. As demonstrated in the attached video (available at [www.aestheticsurgeryjournal.com](http://www.aestheticsurgeryjournal.com)), this is a distinct tether that allows the tip to be pulled down by muscle contracture.

### Tela Subcutanea Cutis

Perhaps the biggest surprise of our dissections was the reemergence of the concept of a tela subcutanea cutis. In the 29th edition of *Gray's Anatomy*, there is a drawing of the nasal base used to illustrate the cartilages of the nose.<sup>25</sup> The lower portion of the nasal base is labeled the *tela subcutanea cutis*. When we meticulously dissected the skin off the lower nasal base, it was obvious that the form of the nostril sill and alar lobules was maintained. Histological analysis showed that the curl of the nostril sill and shape of the alar lobule are due to fibrous septae running from the deep dermal surface into the underlying muscles. As shown in Figure 1C,D, the tela subcutanea cutis is a distinct self-supporting entity with important clinical implications.





**Figure 9.** Histological stains with hematoxylin and eosin. (A) Midline sagittal section through the lip and nasal tip. (B) Parasagittal section 4 mm from the midline. Note the origin of the depressor septi nasalis (6) off the maxilla (1). The depressor septi nasalis is not a lip muscle. Gingival sulcus (2), nostril sill (3), columellar base (4), medial crura (5), orbicularis oris muscle (7), and minor salivary glands (8).

## Nostril Sill

The nostril sill serves as a transverse bridge from the columellar base to the alar lobule and as a longitudinal bridge from the nasal vestibule to the upper lip. The transverse shape of the nostril sill can range from broad to a narrow cleft. Its curl shape can be highly variable from flat to round, approaching 8 to 10 mm in height from the alar crease to the nostril aperture. Histology of the nostril sill demonstrates fibrous septae running outward like spokes of a wheel from a central core of muscle, which is from the MM. In addition, transverse fibers represent part of the labialis portion of the LLSAN.

## Alar Lobule

Any discussion of the alar lobule must emphasize its borders and composition. Many surgeons have a misconception that the alar lobule is partially composed of cartilage, whether a continuation of the lateral crura or accessory cartilage. However, there is no cartilaginous tissue within the alar lobule. The alar groove and its continuation into the alar crease defines the borders of the alar lobule.<sup>26,27</sup> Wu<sup>5</sup> states clearly that the *alar groove* is created by attachments of the fibromuscular layer downward to the perichondrium of the

caudal border of the lateral crura and to the underlying mucosa. One can extend this concept in that similar attachments occur at the caudal border of the accessory cartilages. The alar crease (alar facial crease) is created by the alar portion of the nasalis, which inserts into the skin but then continues into the alar lobule, penetrating medial to the levator labii superioris muscle.<sup>28</sup> The muscular composition of the alar lobule comprises the alar portion of the nasalis, running posterior to anterior while the dilator naris anterior muscle runs cephalic to caudal. Additional fibers may come from the LLSAN. Hur et al<sup>28</sup> refer to it as “nasal skin folded on itself sandwiching a fibromuscular layer between.” They emphasize that its convex shape probably comes from the vertical columns of elastin and collagen fibers that hold it down to the underlying muscles.

## Modiolus Alae Nasi

Figallo and Acosta<sup>6</sup> introduced the concept of a modiolus alae nasi composed of multiple muscles that depress and expand the nostril, thus serving as a counterbalance to the lifting, narrowing muscles. Our dissections confirmed the existence of a modiolus alae nasi but as a 2-layer structure (Figure 7B). The *superficial layer* courses transversely and comprises the LLSAN, levator labii superioris, and superficial

orbicularis oris. Based on the course of the individual muscles, it is obvious that their contracture expands the nostril laterally, whereas the predominant levator muscles elevate the nostril base. Functionally, these muscles provide counter-tension to the depressor muscles. The *deep layer* courses vertically and comprises the MM and dilator naris. These fibers have a broad insertion around the entire alar base and up into the nostril sill.

## SURGICAL RELEVANCE OF THE LOWER NASAL BASE

This study began with several clinical questions. What is the anatomical composition of the columellar base? How do we narrow the columellar base? Why is there such a wide range of nostril sill shapes among patients? As the dissections continued, it became obvious that these structures collectively formed an important anatomical entity—the lower nasal base. Thus, we have defined the anatomical composition of this region and its relationship to adjacent structures. The next step will be to design surgical techniques to correct clinical deformities.

One example of how to utilize this information involves management of the dynamic plunging tip. For years, the recommended technique was to resect the belly of the DSN at the level of the anterior nasal spine. Then, Rohrich et al<sup>12</sup> emphasized that detaching the muscle through an intraoral approach and sewing the 2 muscles together was more effective. Yet, if one sees the etiology of the “dynamic” plunging tip as an interplay between the DSN and the deep portion of Pitanguy’s midline ligament, then there are other options. First, one can interrupt the continuity of this fibromuscular structure at either end. In thick-skinned patients, resection of the soft tissue overlying the alar cartilages effectively resects all of Pitanguy’s midline ligament and breaks the continuity.<sup>29</sup> An even more elegant solution may be to shorten the deep ligament, as demonstrated by Cakir et al.<sup>30</sup> Yet another issue will be to determine the most effective method of narrowing the alar base, not just statically but also dynamically. Certainly, the structural integrity of the tela subcutanea cutis and its position above the dynamic modiolus alae nasi leads one to question the existence of any tether effect and even the existence of any ligaments from the pyriform aperture to the alar lobule. It is our opinion that the dynamic role of the LLSAN in dilating the nostril bases has been underemphasized. Ultimately, it may be the injection of botulinum toxin to block this muscle laterally that offers the best solution for limiting dynamic widening of the alar base.<sup>31</sup>

## CONCLUSIONS

Our findings indicate that a distinct *lower nasal base* exists and it consists of the columellar base, nostril sills, and alar lobules. It is composed of soft tissue, including numerous nasofacial muscles, subcutaneous tissue, and fibrous septa. It is extremely dynamic. The interaction of these tissues

influences compression and dilatation of the nostrils and external valves. For too long, rhinoplasty surgeons have ignored the lower nasal base and focused their attention on the upper nasal base with its alar cartilages. It is our hope that a clear understanding of these anatomical findings will ultimately lead to new surgical procedures, which may well include techniques for narrowing the wide columellar base and minimizing the plunging nasal tip.

## Disclosures

Dr Daniel receives royalties from Springer Publishing and from Medicon Instruments. The other authors declared no potential conflicts of interest with respect to the research, authorship, and publication of this article.

## Funding

The authors received no financial support for the research, authorship, or publication of this article.

## REFERENCES

1. Daniel RK. The nasal base. In: Daniel RK, ed. *Aesthetic Plastic Surgery: Rhinoplasty*. Boston, MA: Little, Brown; 1991:283-318.
2. Daniel RK. Anatomy and aesthetics of the nasal tip. *Plast Reconstr Surg*. 1992;89:216.
3. Hwang TS, Kang HS. Morphometry of nasal bases and nostrils in Koreans. *Ann Anat*. 2003;185:189-193.
4. Sheen JH, Sheen AP. *Aesthetic Rhinoplasty*. 2nd ed. St Louis, MO: Mosby; 1987.
5. Wu WT. The oriental nose: an anatomical basis for surgery. *Arch Acad Med Singapore*. 1992;21:176-189.
6. Figallo EE, Acosta JA. Nose muscular dynamics: the tip trigonum. *Plast Reconstr Surg*. 2001;108:1118-1126.
7. Saban Y, Polselli R. *Atlas d'Anatomie Chirurgicale de la Face et du Cou*. Florence, Italy: SEE Editrice; 2009.
8. Nicolau PJ. The orbicularis oris muscle: a functional approach. *Br J Plast Surg*. 1983;36:141-153.
9. Tardy ME, Brown RJ. *Surgical Anatomy of the Nose*. New York: Raven; 1990.
10. Figallo EE. The nasal tip: a new dynamic structure. *Plast Reconstr Surg*. 1995;95:1178-1184.
11. de Souza Pinto EB. Relationship between tip nasal muscles and the short upper lip. *Aesthetic Plast Surg*. 2003;27:381-387.
12. Rohrich RJ, Huynh B, Muzaffar AR, et al. Importance of the depressor septi nasi muscle in rhinoplasty: an anatomic study and clinical application. *Plast Reconstr Surg*. 2000;105:376-383.
13. de Souza Pinto EB, Rocah RP, Filho WQ, et al. Anatomy of the median part of the septum depressor muscle in aesthetic surgery. *Aesthetic Plast Surg*. 1998;22:111-115.
14. Pitanguy I. Surgical importance of a dermocartilaginous ligament in bulbous noses. *Plast Reconstr Surg*. 1965;36:247-253.
15. Daniel RK, Lessard ML. Rhinoplasty: a graded aesthetic—anatomical approach. *Ann Plast Surg*. 1984;13:436-451.



16. Daniel RK, Letourneau A. Rhinoplasty: nasal anatomy. *Ann Plast Surg.* 1988;20:5-13.
17. Letourneau A, Daniel RK. The superficial musculoaponeurotic system of the nose. *Plast Reconstr Surg.* 1988;82:48-57.
18. Guyuron B. Footplates of the medial crura. *Plast Reconstr Surg.* 1998;101:1359-1363.
19. Rorhrich RJ, Adams WP, Huynh BH, Muzaffar AR. Importance of the depressor nasi septi muscle: an anatomic study and clinical application. In: Gunter JP, Rohrich RJ, Adams WP, eds. *Dallas Rhinoplasty.* 2nd ed. St Louis, MO: QMP Publishing; 2007:1071-1080.
20. Pitanguy I, Salagado F, Radwanski HN, Bushkin SC. The surgical importance of the dermocarilaginous ligament of the nose. *Plast Reconstr Surg.* 1995;95:790-794.
21. Pitanguy I. Revisiting the dermocarilaginous ligament. *Plast Reconstr Surg.* 2001;107:264-266.
22. Saban Y, Amodeo CA, Hammou JC, Polselli R. An anatomical study of the nasal superficial musculoaponeurotic system. *Arch Facial Plast Surg.* 2008;10:109-115.
23. Sun GK, Lee DS, Glasgold AI. Interdomal fat pad. *Arch Facial Plast Surg.* 2000;2:260-263.
24. Toriumi DM, Mueller RA, Grosch T, et al. Vascular anatomy of the nose and the external rhinoplasty approach. *Arch Otolaryngol Head Neck Surg.* 1996;122:24-34.
25. Goss CM. *Gray's Anatomy of the Human Body.* 29th ed. Philadelphia, PA: Lea & Febiger; 1973.
26. Ali-Alaam P, Kashgarian M, Davila J, Psersing MD. Anatomy of the Caucasian alar groove. *Plast Reconstr Surg.* 2002;110:261-266.
27. Patel JC, Fletcher JW, Singer D, et al. Anatomic and histologic analysis of the alar-facial crease and the lateral crus. *Ann Plast Surg.* 2004;52:371-374.
28. Hur MS, Hu KS, Song WC, et al. New anatomical profile of the nasal musculature. *Clin Anat.* 2011;24:162-167.
29. Daniel RK. *Mastering Rhinoplasty.* 2nd ed. Heidelberg, Germany: Springer; 2010.
30. Cakir B, Oreoglu AR, Dogan T, Akan M. A complete sub-perichondrial dissection technique for rhinoplasty with management of the nasal ligaments. *Aesthetic Surg J.* 2012;32:564-574.
31. Redaiwlli A, Braccini F. *Medical Rhinoplasty: Basic Principles and Clinical Practice.* Florence, Italy: Officinal Editoriale Oltrarno; 2010.