

Computer-Aided Analysis of the “Beautiful” Umbilicus

Shu Jin Lee, MD; Saurabh Garg, PhD; and Heow Pueh Lee, PhD

Aesthetic Surgery Journal
2014, Vol. 34(5) 748–756
© 2014 The American Society for
Aesthetic Plastic Surgery, Inc.
Reprints and permission:
[http://www.sagepub.com/
journalsPermissions.nav](http://www.sagepub.com/journalsPermissions.nav)
DOI:10.1177/1090820X14533565
www.aestheticsurgeryjournal.com


Abstract

Background: The position, shape, size, and depth of the umbilicus influence the overall aesthetics of the abdomen. Hence, umbilicoplasty is a common adjunct to aesthetic and reconstructive surgery of the abdominal wall. Delineation of the position and shape of the “beautiful” umbilicus can aid in the planning of abdominoplasty and lipoabdominoplasty.

Objectives: The authors aimed to identify key parameters of the beautiful umbilicus.

Methods: Previously, the authors developed software (the Aesthetic Analyzer) for marking and analyzing parameters from images of the nose, breast, and umbilicus. In the present study, the Aesthetic Analyzer was utilized to determine parameters of the beautiful umbilicus from images of 37 *Playboy* playmates. The vertical position, horizontal position, length, and shape of the umbilicus were assessed.

Results: Based on these images, the beautiful umbilicus possesses the following properties: a vertical ratio of 46:54 (with respect to the xiphoid process and lower limit of the vulvar cleft), a midline horizontal position, a length that is 5% of the length from the xiphoid process to the lower limit of the vulvar cleft, and an oval shape with no hooding (29.8%) or superior hooding (21.6%).

Conclusions: Awareness of the ideal position, shape, and size of the umbilicus can be useful for achieving successful reconstruction of the umbilicus during abdominoplasty and lipoabdominoplasty.

Keywords

aesthetic umbilicus, umbilicoplasty, abdominoplasty, lipoabdominoplasty

Accepted for publication November 18, 2013.

The position, shape, size, and depth of the umbilicus influence the overall aesthetics of the abdomen. Hence, umbilicoplasty is a common adjunct to aesthetic and reconstructive surgery of the abdominal wall. Delineation of the position and shape parameters of the “beautiful” umbilicus can aid in planning abdominoplasty^{1–4} and lipoabdominoplasty.⁵ Although the umbilicus is a key aesthetic feature of the abdomen, there have been few published reports of the parameters of an aesthetically pleasing umbilicus. The position^{6–10} and shape^{11,12} of the umbilicus have been measured in studies of healthy volunteers, but an objective template does not exist for establishing attractive norms for the position, shape, and length of the umbilicus. The aim of our study was to establish such a template—one that characterizes the parameters of an aesthetic umbilicus.

The study was performed using abdominal images of *Playboy* centerfold models, who are presumed to be attractive. *Playboy* was selected because it is the leading men’s magazine worldwide. Monthly circulation in the United

From the Department of Surgery, Yong Loo Lin School of Medicine, National University of Singapore, Singapore (Dr Shu Jin), and Department of Mechanical Engineering, National University of Singapore, Singapore (Dr Saurabh and Dr Heow Pueh).

Corresponding Author:

Dr Shu Jin Lee, Department of Surgery, Yong Loo Lin School of Medicine, National University of Singapore, c/o NUHS Tower Block, Level 8, 1E Kent Ridge Rd, Singapore 119228.
E-mail: surjsj@nus.edu.sg

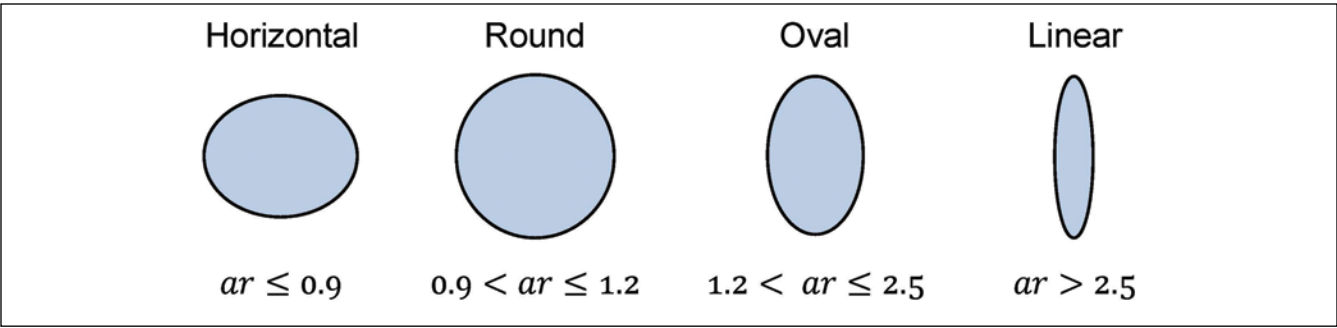


Figure 1. Various shapes of the umbilicus, defined by the aspect ratio (ar).

States is approximately 1.5 million. The magazine represents popular culture, and the “*Playboy* playmate of the year” competition reflects perceptions of female attractiveness.

METHODS

High-resolution frontal images of 132 female *Playboy* centerfold models (“playmates”), published from 2000 through 2011, were initially identified via Google image searches,¹³ the centerfold blog,¹⁴ and the *Playboy* blog.¹⁵ Among the 132 models considered, unobstructed frontal photographs were available for only 47. Ten of the 47 models were excluded because the xiphoid process was not clearly visible in their photographs. Thus, the study group comprised images of 37 *Playboy* playmates, from which the parameters of an aesthetic umbilicus were examined.

For each model, the following information was obtained from Wikipedia,¹⁶ as previously reported by the models to *Playboy*: age, height, weight, hip measurements, and waist measurements. The values were used to calculate body mass index (BMI) and waist-to-hip ratio for each model.

Four key features of the umbilicus were evaluated: vertical position, horizontal position, length, and shape (ie, hooding characteristics and geometric shape). Quantitative measurements of the various proportions were obtained from the images. Measurements included the following:

- vertical position of the umbilicus with respect to the xiphoid process and the lower limit of the vulvar cleft;
- horizontal position of the umbilicus in relation to the waist;
- length of the umbilicus with respect to the length of abdomen and width of waist;
- shape of the umbilicus (defined by its aspect ratio); and
- hooding of the umbilicus (superior, inferior, both superior and inferior, or no hooding).

Authors of previous studies assigned ad hoc names to classify the shape of the umbilicus. In our study, the shape of the umbilicus was standardized according to 2 features: geometric shape and hooding. Geometric shape was defined by aspect ratio (ar). The shape of the umbilicus was either horizontal ($ar \leq 0.9$), round ($0.9 < ar \leq 1.2$), oval ($1.2 < ar \leq 2.5$), or linear ($ar > 2.5$). These shapes are illustrated in Figure 1. The hooding of each umbilicus was classified as superior, inferior, both superior and inferior, or not present.

Previously, we developed custom software, the “Aesthetic Analyzer,” for marking and analyzing images to evaluate aesthetics. The Aesthetic Analyzer works in a general capacity and does not assume shape, size, or type of objects in the input images. Thus far, we have used it to analyze the nose, breast, and umbilicus. The input to the Aesthetic Analyzer consists of a set of images to be analyzed, a list of landmarks to be marked on the images, and a set of measurements to be computed from the landmarks. Figure 2 illustrates the workflow of the Aesthetic Analyzer for a selected view. The input images can be organized into various views, if appropriate. This is convenient for analyzing objects for which multiple views are required. (For example, both frontal and profile views are needed to analyze the shape of the nose.)

For each view, the user specifies a list of landmarks. Three types of landmarks are currently supported: positions, angles, and curves (B-spline). Each landmark can be easily specified and modified using intuitive controls. Once the landmarks have been marked on the images by the user, the Aesthetic Analyzer computes a set of measurements from them. Currently supported measurements include the distance between 2 position landmarks, the ratio of distances between 2 pairs of position landmarks, the angle generated by an angle landmark, and the B-spline curve. The distance, ratio of distances, and angles are saved as a comma-separated values (CSV) file that can be imported into Excel (Microsoft, Redmond, Washington) or other tools for further analysis. The B-spline curves are saved as images for visualization.

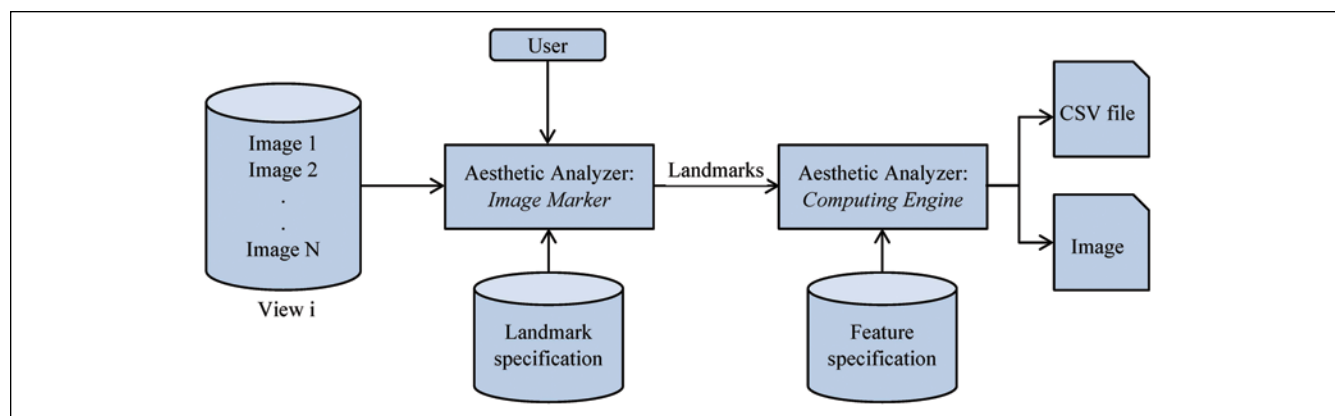


Figure 2. Workflow of the Aesthetic Analyzer for a single view.

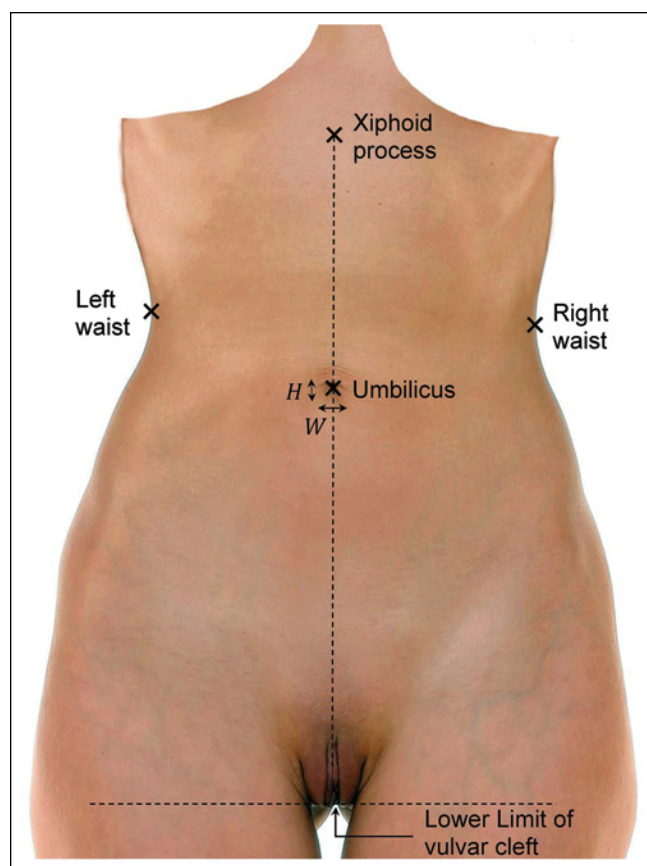


Figure 3. Landmarks for vertical position, horizontal position, length, and shape of the umbilicus. The lower limit (most inferior point) of the vulvar cleft is the point at which the vertical line of the vulva starts to bifurcate when viewed from the front. (Source: Image in public domain by Creative Commons CCO 1.0 Universal Public Domain Dedication.)

Full-sized frontal images of the 37 models were marked and analyzed via the Aesthetic Analyzer. Figure 3 shows the

landmarks. The xiphoid process was not clearly visible in some color images. In such cases, the images were processed with Adobe Photoshop (Adobe Systems, San Jose, California) to remove low-frequency details while enhancing high-frequency details. Figure 4A is a representative color image, and Figure 4B is an enhanced version of that image. Also documented for each model was the presence or absence of superior and inferior hooding of the umbilicus.

Collated values from the images of the 37 models were analyzed using MATLAB software (MATLAB and Statistics Toolbox; The MathWorks, Natick, Massachusetts) to produce the mean and standard deviation (SD) values for each parameter. MATLAB was also used to generate box plots showing the distribution of values for each parameter.

RESULTS

The mean age (\pm SD) of the 37 models in this study was 23.4 ± 2.8 years. Mean height was 169.2 ± 5.4 cm, mean weight was 53.0 ± 3.6 kg, and mean BMI was 18.5 ± 0.9 kg/m². Mean hip circumference was 24.6 ± 1.6 in, mean waist circumference was 23.4 ± 1.1 in, and mean waist-to-hip ratio was 0.70 ± 0.03 . Figure 5 shows box-plot distributions for these parameters.

Table 1 shows results of the analysis of umbilicus parameters obtained from study images. Abdomen length was defined as the distance between the xiphoid process and the lower limit of the vulvar cleft. The vertical distance from the umbilicus to the xiphoid process was 46% of the abdomen's length, and the distance from the umbilicus to the lower limit of the vulvar cleft was 54% of abdominal length, denoting a ratio of 46:54. Thus, the ideal umbilicus is high riding.

Horizontally, the aesthetic umbilicus was midline (ie, 50:50 ratio with respect to the waist). The length of the umbilicus was determined to be $5\% \pm 1\%$ of abdominal

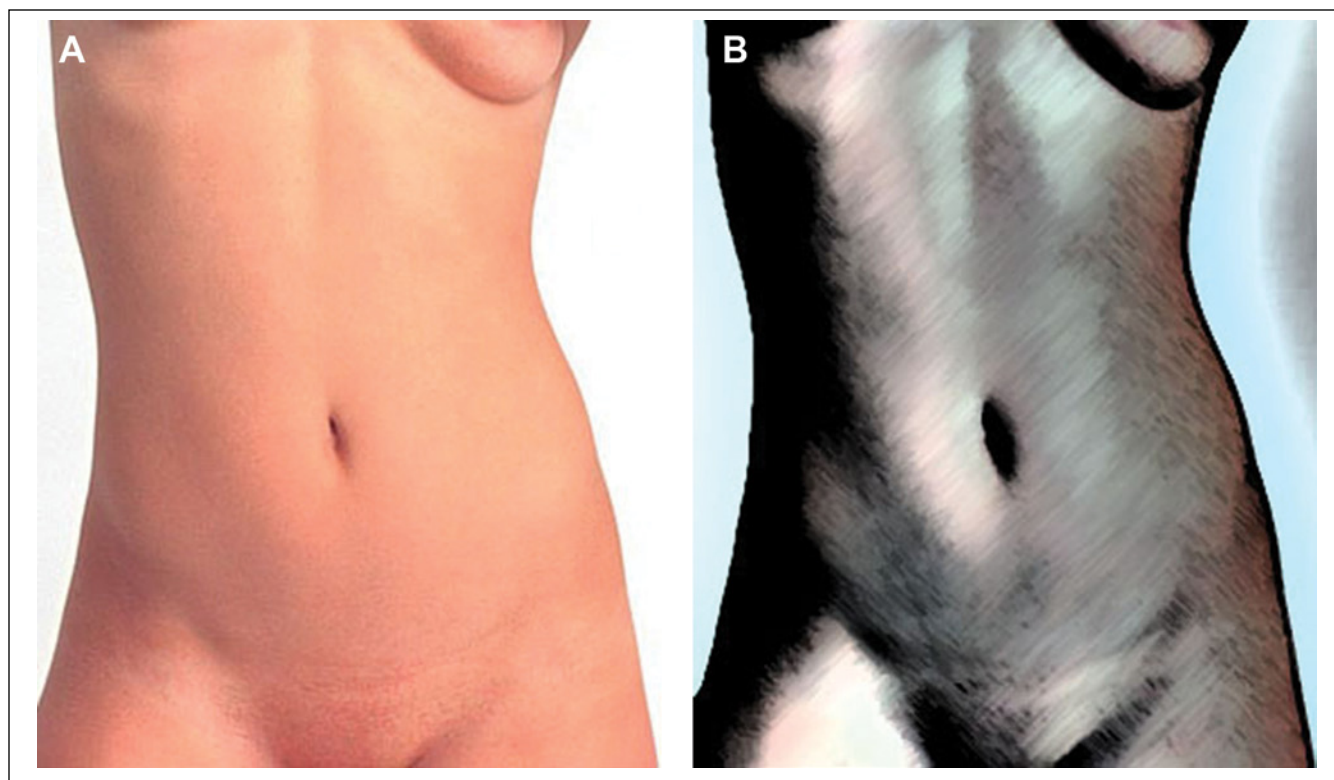


Figure 4. To reliably determine the xiphoid process, some color images required processing in Adobe Photoshop (Adobe Systems, San Jose, California) to remove low-frequency details and enhance high-frequency details. (A) Color image. (B) Enhanced image. (Source: <http://flickr.com/photos/48987737@N08/6079851155>, author David Whitehall, and license cc-by-sa-2.0.)

length. Figure 6 shows the distribution of parameters of the ideal umbilicus.

With respect to umbilical shape, 62% were oval and 24% were round. A linear (vertical) slit was present in 11% and a horizontal slit in 3%. Superior hooding was observed in 32.4%, and 54.1% had no hooding. The remaining 13.5% had umbilical piercings, and thus it was not possible to determine the presence or type of hooding. Figure 7 shows the incidence of the various geometric shapes and hooding features. The most common shape with hooding was oval with no hooding (29.8%), followed by oval with superior hooding (21.6%). The following 3 shapes occurred with equal frequency among the study population (10.8% for each type): round with no hooding, round with superior hooding, and linear (vertical) slit. A horizontal slit was present in 2.7% of umbilici. For the remaining 13.5%, the type of hooding could not be determined because of umbilical piercing.

DISCUSSION

We examined images of 37 *Playboy* playmates, presumed to be beautiful, to establish a template for the aesthetic umbilicus. Four parameters were used to analyze and summarize pertinent features of the aesthetic umbilicus: vertical position (from xiphoid process to lower limit of vulvar cleft), horizontal position, umbilicus length, and umbilicus shape (including hooding).

We found that the ideal umbilicus is oval shaped, relatively high riding, and centered horizontally. Its length is approximately 5% of the length from the xiphoid process to the lower limit of the vulvar cleft. The ideal umbilicus has either no hooding or superior hooding, a preference that may be subjective. These features, as well as patient preferences, can be discussed in advance of surgery in an effort to achieve an aesthetically desirable result for the umbilicus.

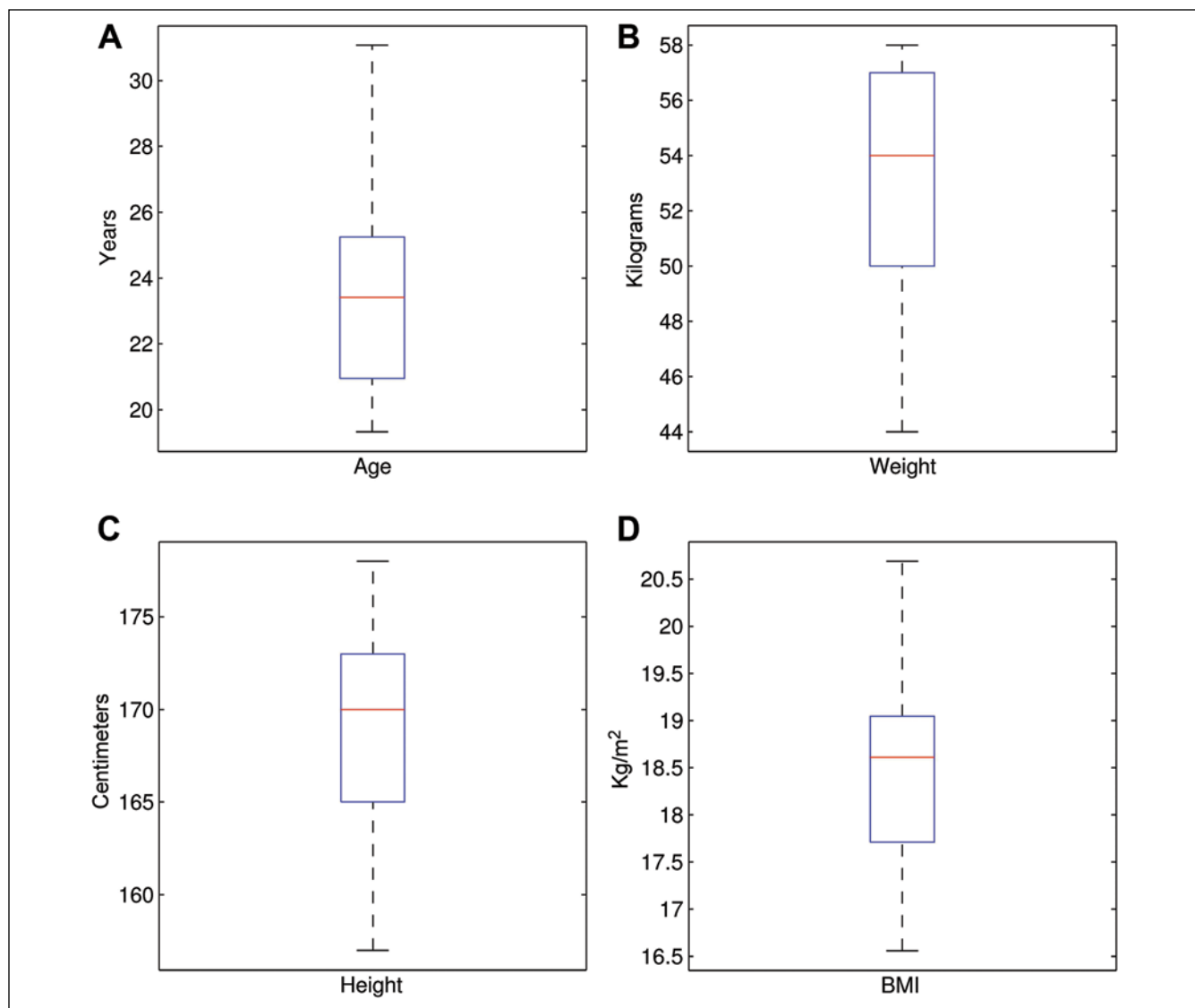


Figure 5. Box-plot distributions for the 37 models: (A) age, (B) weight, (C) height, (D) body mass index (BMI), (E) waist measurement, (F) hip measurement, and (G) waist-to-hip ratio.

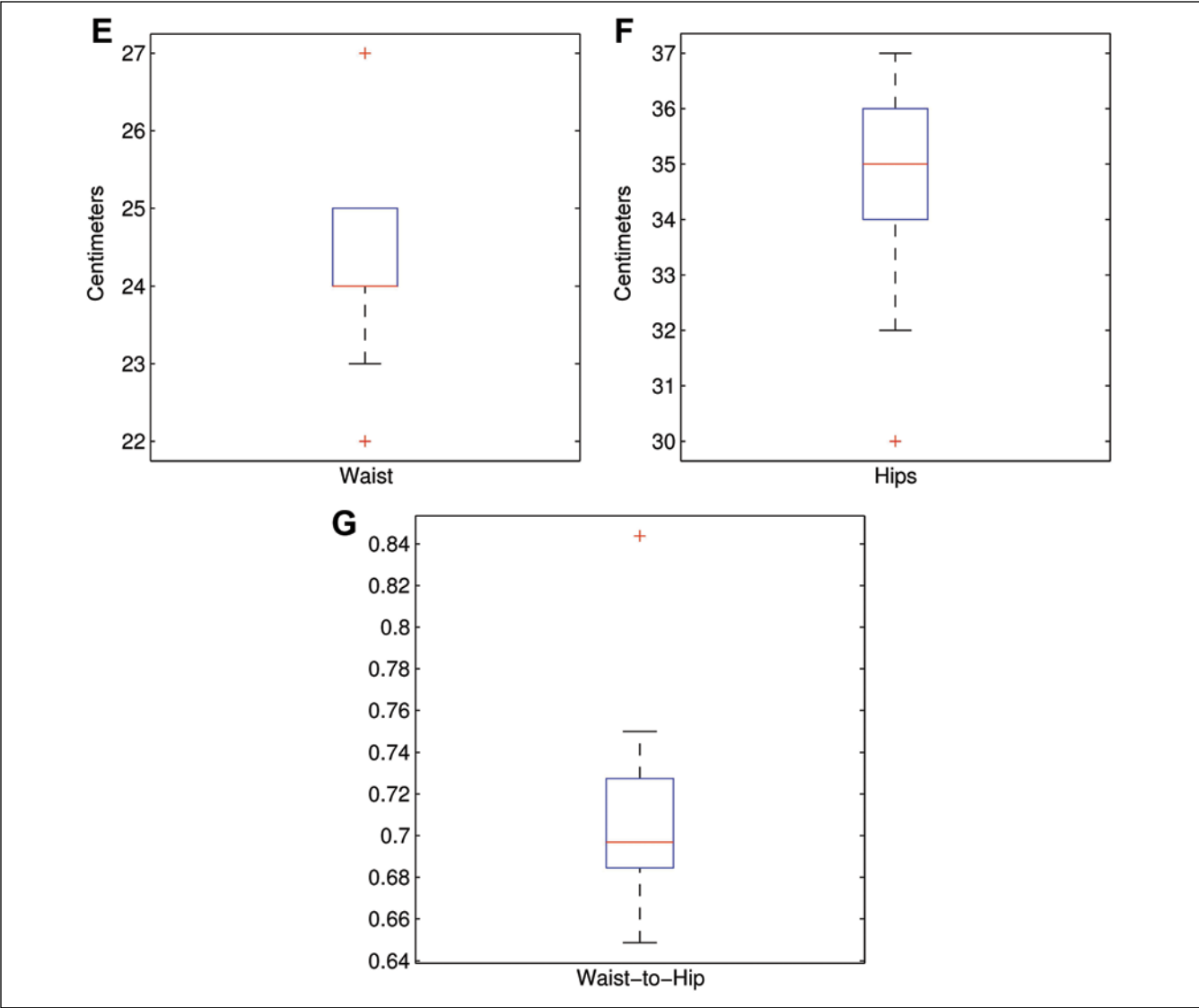


Figure 5. (continued) Box-plot distributions for the 37 models: (A) age, (B) weight, (C) height, (D) body mass index (BMI), (E) waist measurement, (F) hip measurement, and (G) waist-to-hip ratio.

The ideal vertical position of the umbilicus may vary depending on whether the patient is high waisted (short waist) or low waisted (long waist). In high-waisted bodies, the waist is closer to the xiphoid process; in low-waisted bodies, it is further from the xiphoid process. However, to our knowledge, there have been no studies of the vertical position of the umbilicus with respect to high- and low-waisted body types. This topic of interest warrants investigation.

In several studies,⁶⁻⁹ the vertical position of the umbilicus from the xiphoid process to the pubic symphysis was measured in healthy volunteers. Results of those studies demonstrated that the umbilicus is low riding, meaning

that the distance from the xiphoid process to the umbilicus is longer than the distance from the umbilicus to the pubic symphysis (Table 2).

In contrast to these studies, we used the lower limit of the vulvar cleft, rather than the pubic symphysis, as the landmark for vertical measurements. We chose this location because the pubic symphysis is not a “hard” landmark and can be difficult to mark on images. Moreover, the pubic symphysis is a *region*, and the authors of previous studies failed to mention the specific point in the symphysis that was used for vertical measurements. Thus, we opted for a landmark that could be marked easily and consistently on all images. Because of the difference in

Table 1. Results of Analysis of Parameters of the Umbilicus

Parameter	Value (N = 37)
Xiphoid process to umbilicus, mean \pm SD	46% \pm 5%
Umbilicus to lower limit of vulvar cleft, mean \pm SD	54% \pm 5%
Umbilicus to left midaxillary line, mean \pm SD	50% \pm 4%
Umbilicus to right midaxillary line, mean \pm SD	50% \pm 4%
Length of umbilicus, mean \pm SD	0.05% \pm 0.01% L / 0.32% \pm 0.07% W
Geometric shape (based on aspect ratio of umbilicus)	Oval: 62%
	Round: 24%
	Linear (vertical) slit: 11%
	Horizontal slit: 3%
Type of hooding	No hooding: 54.1%
	Superior hooding: 32.4%
	Indeterminate ^a hooding: 13.5%

L, length of the abdomen (from xiphoid process to lower limit of the vulvar cleft); W, width of the waist.

^aHooding was indeterminate because of umbilical piercing.

landmarks, it is not possible to compare our findings with those of studies in which the pubic symphysis was the measurement point. The distance from the umbilicus to the lower limit of the vulvar cleft is obviously longer than the distance from the umbilicus to the top of the pubic symphysis. Had we measured the distance from the umbilicus to the top of the vulvar cleft in our study, we would have found that the vertical position of the umbilicus would be at center (50:50) or slightly above center.

With respect to horizontal position, Rohrich et al¹⁰ analyzed photographs of 116 women and found that the umbilicus was midline in only 2 subjects. They also found that for 52% of their subjects, the umbilicus was more than 2% lateral to midline; in 13% of subjects, it was more than 4% lateral to midline. However, our study showed that the location of the aesthetic umbilicus is completely midline.

The shape and size of the umbilicus were measured in 2 previous studies.^{11,12} Craig et al¹¹ photographed 147 women (average BMI, 22.72 kg/m²). A round umbilicus with superior hooding (T-shaped) was present in 37%, oval shape in 22%, linear in 17%, and horizontal in 14%. The remaining 10% did not fall into one of these 4 categories and were classified as distorted. The photographs

obtained in their study were presented to a panel of 21 examiners who rated the attractiveness of the umbilicus. Results showed that the shape of the aesthetically pleasing umbilicus is small, vertical, and hooded superiorly (a T-shaped umbilicus). These features are typically associated with youth and low body weight. In contrast to the aesthetic umbilicus is the unattractive umbilicus, which is large, horizontal, protuberant, and associated with postpartum changes and weight gain.¹² Cavale and Butler¹² conducted an Internet survey to determine the general public's preference for umbilicus shape. The survey was completed by 251 people (84 men, 167 women). The authors found that both male (85.7%) and female (89.2%) participants favored the hooded oval (T-shaped) appearance. Similarly, our study showed that the most common umbilicus shapes among attractive women are oval without hooding (29.8%) and oval with superior hooding (21.6%).

Although we acknowledge that some *Playboy* images may be airbrushed and otherwise edited, such modifications would likely be imposed to coincide with current societal perceptions of attractiveness. Hence, even touched-up photographs would be appropriate for identifying parameters of the ideal umbilicus. We made a diligent effort to minimize the effect of variation among poses by selecting images in which the models were in a straight, standing pose.

A limitation of this study is the small sample size (37 models). Our initial goal was to include images of at least 50 models. Although 132 models were considered at the outset, high-quality frontal images were available for only 37, despite rigorous search efforts. Images of the other models were not suitable because body posture was not straight enough or the landmarks were not sufficiently visible to permit accurate measurements.

CONCLUSIONS

Aesthetic reconstruction of the umbilicus is an important part of abdominoplasty and lipoabdominoplasty. In this study, we delineated the position, shape, and size of the beautiful umbilicus from images of *Playboy* playmates. The findings may be useful in preoperative patient counseling and may help guide aesthetic and reconstructive surgery of the abdominal wall.

Disclosures

The authors declared no potential conflicts of interest with respect to the research, authorship, and publication of this article.

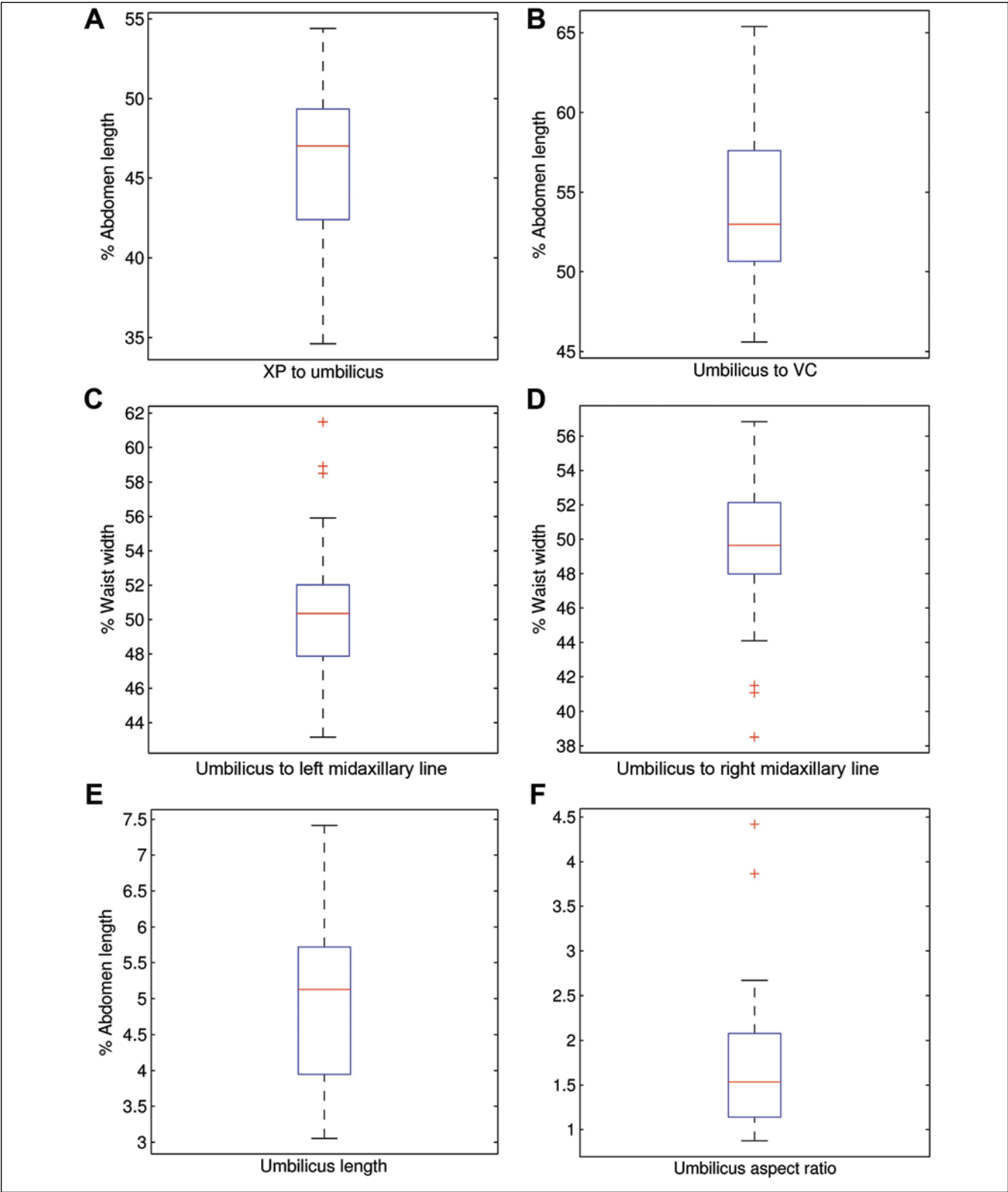
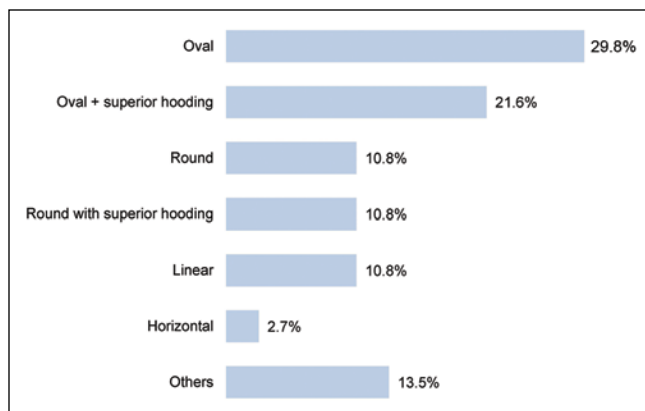


Figure 6. Box-plot distribution of umbilical parameters for the 37 models. Abdominal length was defined as the distance between the xiphoid process (XP) and the lower limit of the vulvar cleft (VC). (A) Ratio of distance between XP and umbilicus in relation to abdominal length. (B) Ratio of distance between umbilicus and lower limit of VC in relation to abdominal length. (C) Ratio of distance from umbilicus to left midaxillary line in relation to waist width. (D) Ratio of distance from umbilicus to right midaxillary line in relation to waist width. (E) Length of umbilicus expressed as a percentage of abdominal length. (F) Aspect ratio of the umbilicus.

Table 2. Vertical Position of Umbilicus in Relation to Xiphoid Process and Pubic Symphysis in Previous Studies

Author (year)	No. of Patients	Race	Average Age	Average BMI, kg/m ²	XP-U Distance, cm	U-PS Distance, cm	Ratio
El-Sharkawy et al ⁶ (2004)	40	Egyptian	23.7	23.1	17.50	14.60	1.20
Abhyankar et al ⁷ (2006)	75	Indian	19.6	29.9	25.69	16.18	1.59
Ambardar et al ⁸ (2009)	6	—	—	17.7	14.72	12.98	1.13
Ambardar et al ⁸ (2009)	96	—	—	22.2	16.63	14.87	1.12
Parnia et al ⁹ (2012)	65	Iranian	23.4	21.2	17.11	15.15	1.13

BMI, body mass index; PS, pubic symphysis; U, umbilicus position; XP, xiphoid process.

**Figure 7.** Incidence of geometric shapes and hooding features among the study group.

Funding

The authors received no financial support for the research, authorship, and publication of this article.

REFERENCES

1. Akba H, Güneren E, Ero lu L, Uysal O. Natural-looking umbilicus as an important part of abdominoplasty. *Aesthetic Plast Surg.* 2003;27(2):139-142.
2. Kurul S, Uzunismail A. A simple technique to determine the future location of the umbilicus in abdominoplasty. *Plast Reconstr Surg.* 1997;100(3):53-54.
3. Lesavoy M, Fan K, Guenther D, Herrera F, Little J. The inverted-V chevron umbilicoplasty for breast reconstruction and abdominoplasty. *Aesthetic Surg J.* 2012;32(1):110-116.
4. Omori M, Hashikawa K, Sakakibara S, et al. One-stage umbilicus reconstruction after resection of urachal cyst. *Ann Plast Surg.* 2013;71(1):93-95.
5. Saldanha O, Federico R, Daher P, et al. Lipoabdominoplasty. *Plast Reconstr Surg.* 2009;124(3):934-942.
6. El-Sharkawy A, Said T, Shafik I, Khalifa H. A study of the aesthetic patterns of the umbilicus among Egyptians with a new technique for umbilical reconstruction de novo. *Kasr El-Aini J Surg.* 2004;5(3):87-99.
7. Abhyankar S, Rajguru A, Patil P. Anatomical localization of the umbilicus: an Indian study. *Plast Reconstr Surg.* 2006;117(4):1153-1157.
8. Ambardar S, Cabot J, Cekic V, et al. Abdominal wall dimensions and umbilical position vary widely with BMI and should be taken into account when choosing port locations. *Surg Endosc.* 2009;23(9):1995-2000.
9. Parnia R, Ghorbani L, Sepehrvand N, Hatami S, Bazargan-Hejazi S. Determining anatomical position of the umbilicus in Iranian girls, and providing quantitative indices and formula to determine neo-umbilicus during abdominoplasty. *Indian J Plast Surg.* 2012;45(1):94-96.
10. Rohrich R, Sorokin E, Brown S, Gibby D. Is the umbilicus truly midline? Clinical and medicolegal implications. *Plast Reconstr Surg.* 2003;112(1):259-263.
11. Craig S, Faller M, Puckett C. In search of the ideal female umbilicus. *Plast Reconstr Surg.* 2000;105(1):389-392.
12. Cavale N, Butler P. The ideal female umbilicus? *Plast Reconstr Surg.* 2008;121(5):356e-357e.
13. Google image search. <http://www.google.com/imghp>. Accessed December 6, 2012.
14. Centerfold blog. <http://www.centerfoldblog.net>. Accessed December 6, 2012.
15. Playboy blog. <http://www.playboyblog.com>. Accessed December 6, 2012.
16. Wikipedia. List of playboy playmates of the month. http://en.wikipedia.org/w/index.php?title=List_of_Playboy_Playmates_of_the_Month. Accessed December 6, 2012.