



Nipple Reduction With the Chullo-Hat Technique

Hyung-Bo Sim, MD; and Sang-Hoon Sun, MD

Aesthetic Surgery Journal
2015, Vol 35(6) NP154–NP160
© 2015 The American Society for
Aesthetic Plastic Surgery, Inc.
Reprints and permission:
journals.permissions@oup.com
DOI: 10.1093/asj/sjv049
www.aestheticsurgeryjournal.com
OXFORD
UNIVERSITY PRESS

Abstract

Background: Although various techniques of nipple reduction have been described in the literature, many are difficult to design or have unreliable outcomes. For men, as well as women who do not plan to breastfeed, it is not necessary to apply a complicated technique that protects the lactiferous ducts.

Objectives: The authors introduce a simple technique for nipple reduction that has achieved consistent, reproducible results.

Methods: The desired nipple length is marked, and a chullo-hat excision pattern is drawn. After infiltration of a local anesthetic solution around the nipple, excision of the excess nipple tissue is performed, comprising 2 triangular flaps. The remaining 2 pillars are approximated with 5-0 Nylon simple interrupted sutures. However, the wound is not completely closed in the central area of the nipple, which promotes the drainage of discharge.

Results: Fifty-three women (106 nipples) underwent this surgery between December 2009 and December 2013. The follow-up period ranged from 6 months to 2 years (mean, 10 months). No major complications occurred, and the scars were very inconspicuous. The postoperative appearance of nipples was consistently similar in size and shape.

Conclusions: This simple technique was safe and effective in nipples of different sizes. The results were reliable and consistent with expectations. Although this study included only women, the authors believe that outcomes would be successful in men as well.

Level of Evidence: 4



Accepted for publication January 30, 2015.

Nipple hypertrophy can cause psychological and physical problems in men and women. Nipple hypertrophy often has a family history, occurs after adolescence, manifests during pregnancy, and does not subside even after menopause.^{1,2} Many patients feel a loss of self-confidence because of this condition and experience emotional distress in hot weather or when wearing tight shirts or swimsuits.¹⁻⁷

Although many nipple-reduction techniques have been described and performed,¹⁻¹² some have complicated design procedures and/or require numerous traumatic flap surgical procedures, resulting in unpredictable outcomes. Undesirable aesthetic results can occur, such as asymmetry, unnatural appearance, and scar problems. However, nipple reduction need not be so complicated in men or in women who have ceased childbearing and are not planning to breastfeed because preservation of ductal continuity is not necessary. Less-complicated procedures can optimize preservation of

nipple sensation, protection of the anatomic smooth muscle structure, and attainment of aesthetic goals.¹³

In this study, the authors describe a simple and safe nipple-reduction technique that consistently produced favorable aesthetic results.

METHODS

Fifty-three women (106 nipples) underwent nipple reduction with the chullo-hat technique at the authors' clinic

Dr Sim and Dr Sun are plastic surgeons in private practice in Seoul, Republic of Korea.

Corresponding Author:

Dr Hyung-Bo Sim, BR Clinic, Nonhyeon-ro 155 gil 5, Gangnam-gu, Seoul, Republic of Korea.
E-mail: wsimww@gmail.com

between December 2009 and December 2013. Nipple hypertrophy was bilateral in all patients. The age range at the time of surgery was 30 to 51 years (mean, 36 years). All patients had ceased childbearing or no longer planned to breastfeed. Excluded from the study were women who indicated an expectation to breastfeed in the future. Fourteen patients underwent breast augmentation simultaneously with nipple reduction; 9 of those patients received endoscopic transaxillary augmentation.

All patients were instructed to visit the authors' clinic for follow-up 3 days postoperatively, as well as 1 week, 1 month, and 1 year after the surgery. Measurements of nipple length and width were obtained preoperatively and 1 month postoperatively.

This study did not undergo review by an internal board and was not associated with any grant. Informed consent was obtained preoperatively from all patients.

The Chullo-Hat Technique

In accordance with each patient's expectations, a new nipple length was planned preoperatively. Most patients preferred a length of 1 cm or less, with an equivalent nipple width.

After identification of the nipple base, a chullo-hat design, which consists of a crown on top of the nipple and a triangular pattern on each side, was marked around the nipple (Figure 1). (A "chullo hat" is an Andean-style hat that includes ear flaps.)

First, the base of the crown was determined at a height of 1 cm from the nipple base, and a circumferential line was drawn along the entire perimeter of the nipple. In general, the 2 inverted triangular patterns were marked at the 3 o'clock and 9 o'clock positions on opposite sides, but the direction could be changed depending on the ellipticity of the nipple base. The width of the triangle base could be varied according to the width of each hypertrophied nipple base (distance $B-C = Y-X$). The lowest point of the triangular pattern at the base of the nipple must have been just above the nipple base—not on the areola.

A local anesthetic solution, containing 0.01 mL of 1:1000 epinephrine and 2 mL of 2% lidocaine, was infiltrated around the nipples, and a 4-0 Nylon traction suture was applied at the nipple apex. The chullo hat-like incision was made with a scalpel, and en-bloc excision of the excessive nipple tissue was performed (Figure 2). The 2 remaining pillars were approximated and secured with 5-0 Nylon simple interrupted sutures. Unlike other procedures, a 3-mm-long wound closure in the center of the nipple was not performed, thus encouraging the drainage of discharge and preventing the formation of a ductal cyst. Rather, this wound was dressed with gauze and Terramycin antibiotic ointment (Pfizer, New York, NY). The total operating time ranged from 10 to 15 minutes per nipple. Intraoperative views are shown in Figures 3 and 4. The sutures were removed 7 to 10 days postoperatively.

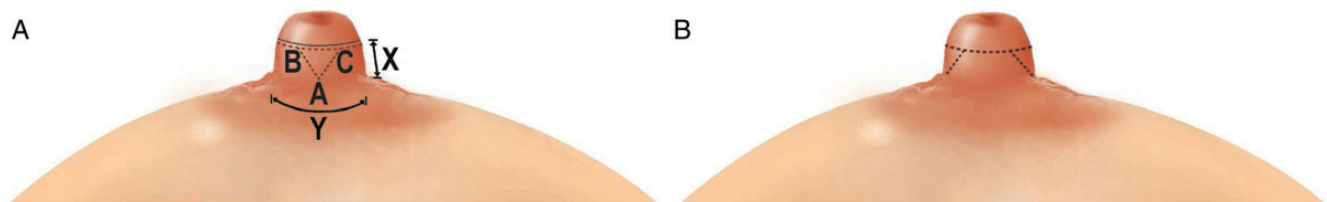


Figure 1. (A) The chullo-hat design. Y = base width of the nipple; X = planned length of the nipple; A = lowest point of the triangle. Distance $B-C$ denotes the difference between the base width (Y) and planned length (X) of the nipple. (B) Lateral view.

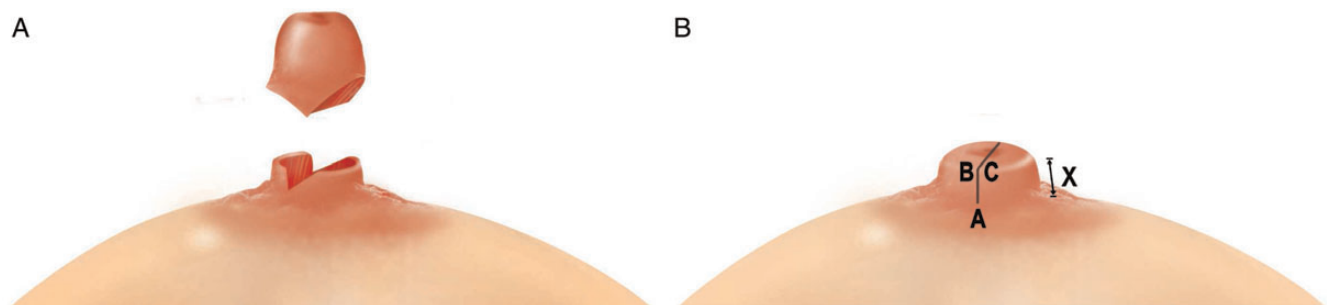


Figure 2. (A) En-bloc excision according to the chullo-hat design. (B) Closure.

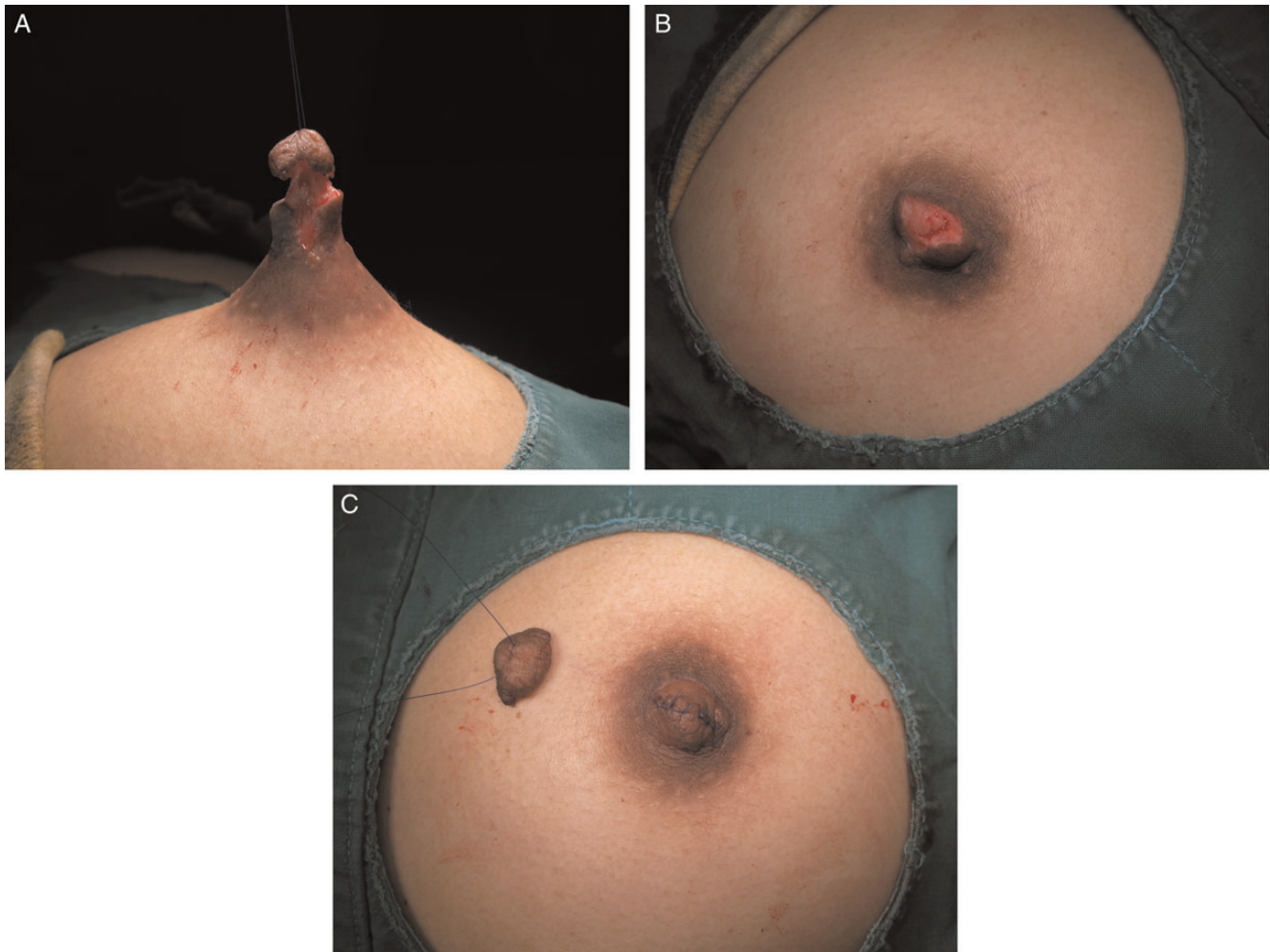


Figure 3. Intraoperative views of this 39-year-old woman. (A) Impending separation according to the chullo-hat design. (B) While the excess tissue was removed, considerable volume of the 2 pillars was maintained to build the new nipple. (C) Simple closure with 5-0 nonabsorbable sutures.

A video demonstrating the incision and resection techniques is available as a supplementary file.

RESULTS

The follow-up period ranged from 6 to 24 months (mean, 10 months). Preoperatively, the mean nipple length was 15 mm (range, 13-22 mm). Postoperatively, the mean nipple length was 7 mm (range, 5-9 mm). The mean nipple diameter was 14 mm (range, 13-22 mm) before surgery and 9 mm (range, 6-12 mm) after.

The postoperative course was uneventful for all patients; there were no occurrences of tissue necrosis, wound dehiscence, infection, galactocele, hypertrophic scarring, or sensory loss. During the follow-up period, no patient complained about sensory changes or the appearance of their nipples (Figures 5 and 6). Moreover, outcomes of the

nipple reduction appeared to be unaffected by simultaneous breast augmentation.

All excised specimens underwent pathologic examination, and none showed evidence of neoplasm.

DISCUSSION

Most nipples are approximately 1 cm in length and width, and the base width is usually slightly greater than the nipple length.¹⁴ Ideally, the nipple should be situated in the center of the breast. However, hypertrophic nipples typically are associated with a lack of harmony in aesthetic proportions and often are accompanied by asymmetry and a ptotic appearance.¹ Unfortunately, ptotic hypertrophic nipples detract from the results of successful breast augmentation.

Each nipple contains between 16 and 24 lactiferous ducts, which are 2 to 4 mm long and are arranged longitudinally and circumferentially in a network structure within

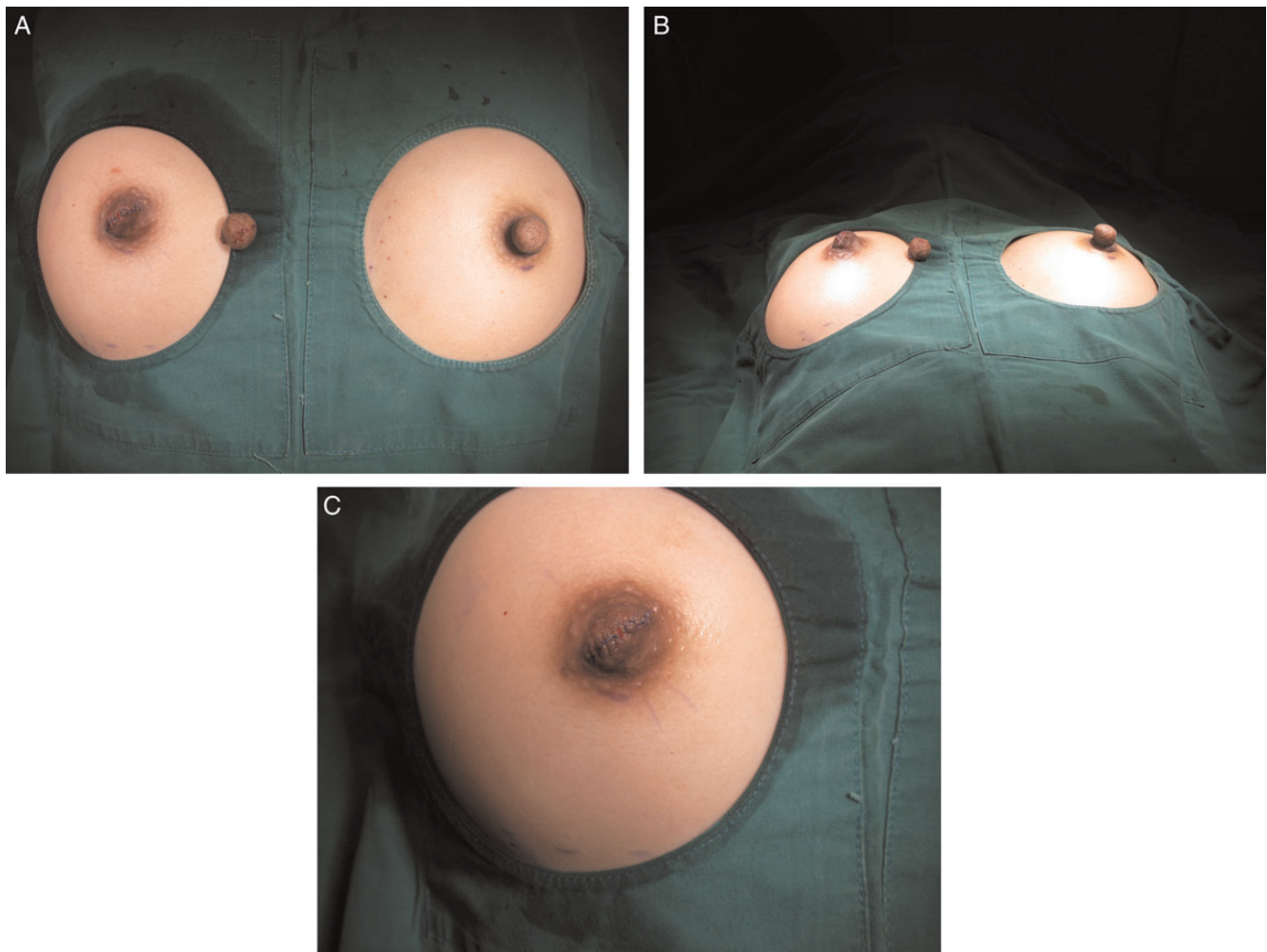


Figure 4. Additional views of the patient featured in Figure 3. (A) Immediately after closure of the right nipple, the change in dimension was apparent. (B) View from below. (C) At this stage, a small opening was left in the central part of the nipple apex to encourage the drainage of discharge.

smooth muscle.^{1,2} The nipple is innervated by the anterior and lateral cutaneous branch of the third, fourth, and fifth intercostal nerves, as well as the anterior cutaneous branch of the second intercostal nerve.^{5,15} The blood supply to the nipple is provided by the subdermal plexus, which receives most of its arterial flow from branches of the internal mammary artery. As specialized epidermis, it is dependent on the underlying stroma for development and maintenance in adult life. Lymphatic drainage from the nipple and the surrounding areola is provided by the subareolar plexus that drains into the anterior pectoral nodes.^{2,3,16}

The nipple is an important part of the body, not only for breastfeeding but also for sexual purposes. Preserving physiologic structures such as sensory nerves, smooth muscles, and lactiferous ducts is essential in the treatment of hypertrophic nipples.

Previously reported nipple-reduction methods focus on sparing the lactiferous ducts. In our experience, multiple flap elevations and wide dermal excision around the nipple base usually cause sensory disturbances. Although none of our patients complained of sensory change during follow-up, longer follow-up and a detailed investigative work-up for sensation is necessary to determine whether this is true long term.

When treating nipple hypertrophy for patients who plan to bear children and breastfeed, the lactiferous ducts must be preserved for the lactation function. However, in men, as well as women who have ceased childbearing and do not intend to breastfeed, it is not necessary to protect the continuity of these ducts. A less-traumatic procedure can be performed in such cases, optimizing the likelihood of preserving nipple sensation, protecting the anatomic smooth muscle structure, and achieving aesthetic goals.

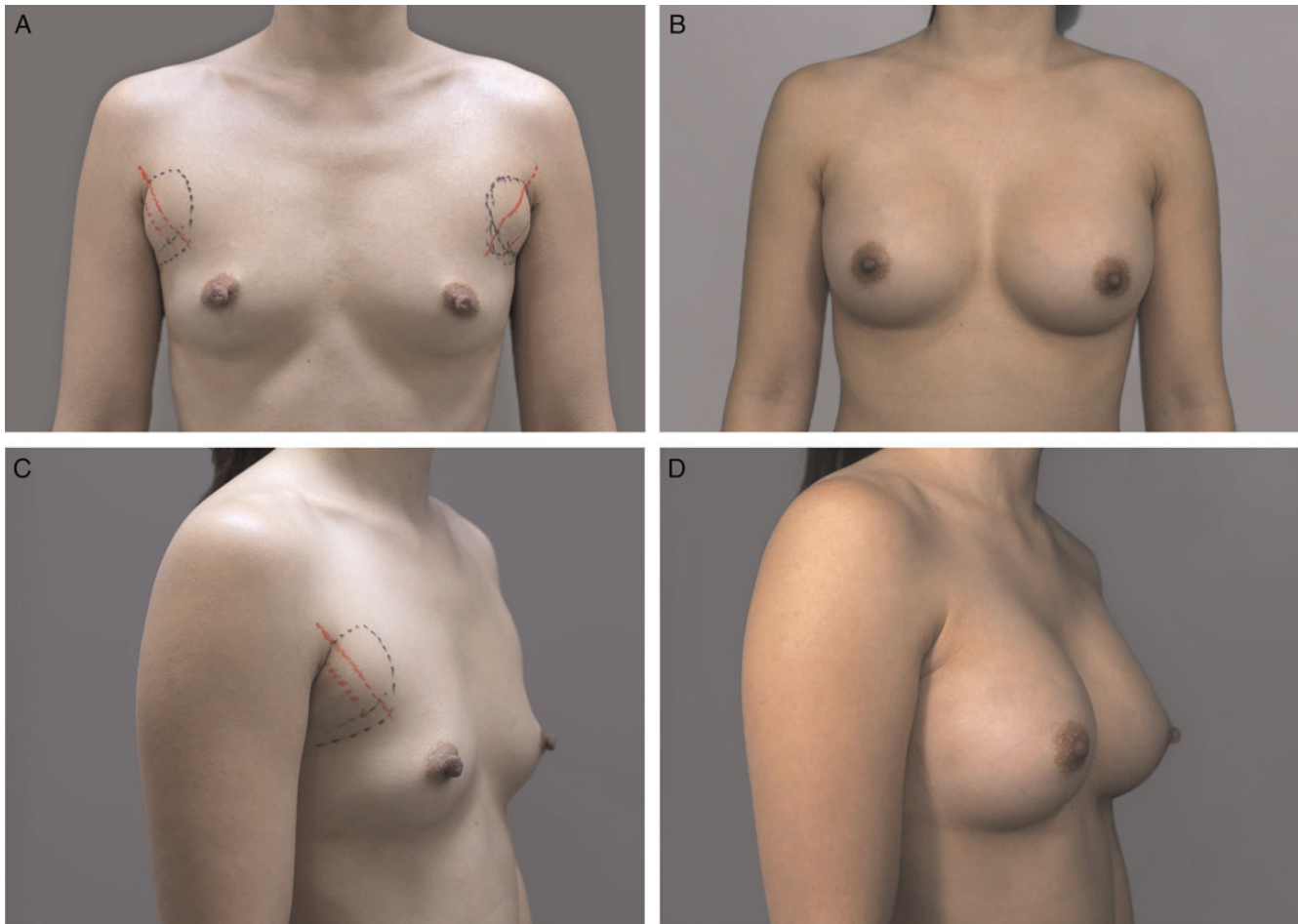


Figure 5. This 35-year-old woman underwent bilateral nipple reduction (chullo-hat technique) and simultaneous endoscopic transaxillary breast augmentation with anatomic implants (moderate, style 320/320; Sientra; Santa Barbara, CA). Liposuction was performed on the patient's accessory breast tissue. (A, C) Preoperative views. (B, D) Twenty-two months after surgery.

Although successful outcomes have been achieved with other simple nipple-reduction techniques, detailed descriptions of designs and procedures are often lacking. Our surgical technique is a modification of similar nipple-reduction techniques. However, we have proposed an excision pattern and guidelines to produce predictable and consistent results. In a study of a similar technique, it was not always feasible to wait for the secondary wound-healing process to occur¹⁷ which may result in substantial anxiety for the patient.

Our findings indicate that the chullo-hat technique is easy to design and produces reliable results, with rapid recovery and low morbidity. Although none of our patients experienced galactocele or symptoms of ductal blockade, longer follow-up will be necessary to ensure that such complications would not occur later in the postoperative course.

With respect to breastfeeding postoperatively, Moliver et al¹³ and Vecchione⁹ demonstrated that some patients who had undergone nipple reduction were able to breast-feed 1 year after surgery. However, in another study, this

function could not be confirmed by histologic reconnection of the divided ducts.¹⁸

With the chullo-hat technique, the resulting base width is slightly smaller than the final nipple length because the nipple base is left untouched. However, in typical nipples, the base width is greater than the nipple length. In the present study, we did not consider ethnic differences in nipple dimensions. Anthropometric research that takes into account such differences would be helpful for planning the final dimensions of the nipple.

We believe that the chullo-hat technique is easier and faster to perform than many other methods of nipple reduction and results in lower morbidity and earlier recovery. Moreover, the technique is predictable, reproducible, and allows for simultaneous reduction of the length and width of a nipple.

CONCLUSIONS

The chullo-hat technique appears to be an easy, safe, reliable, and effective treatment for hypertrophic nipples in

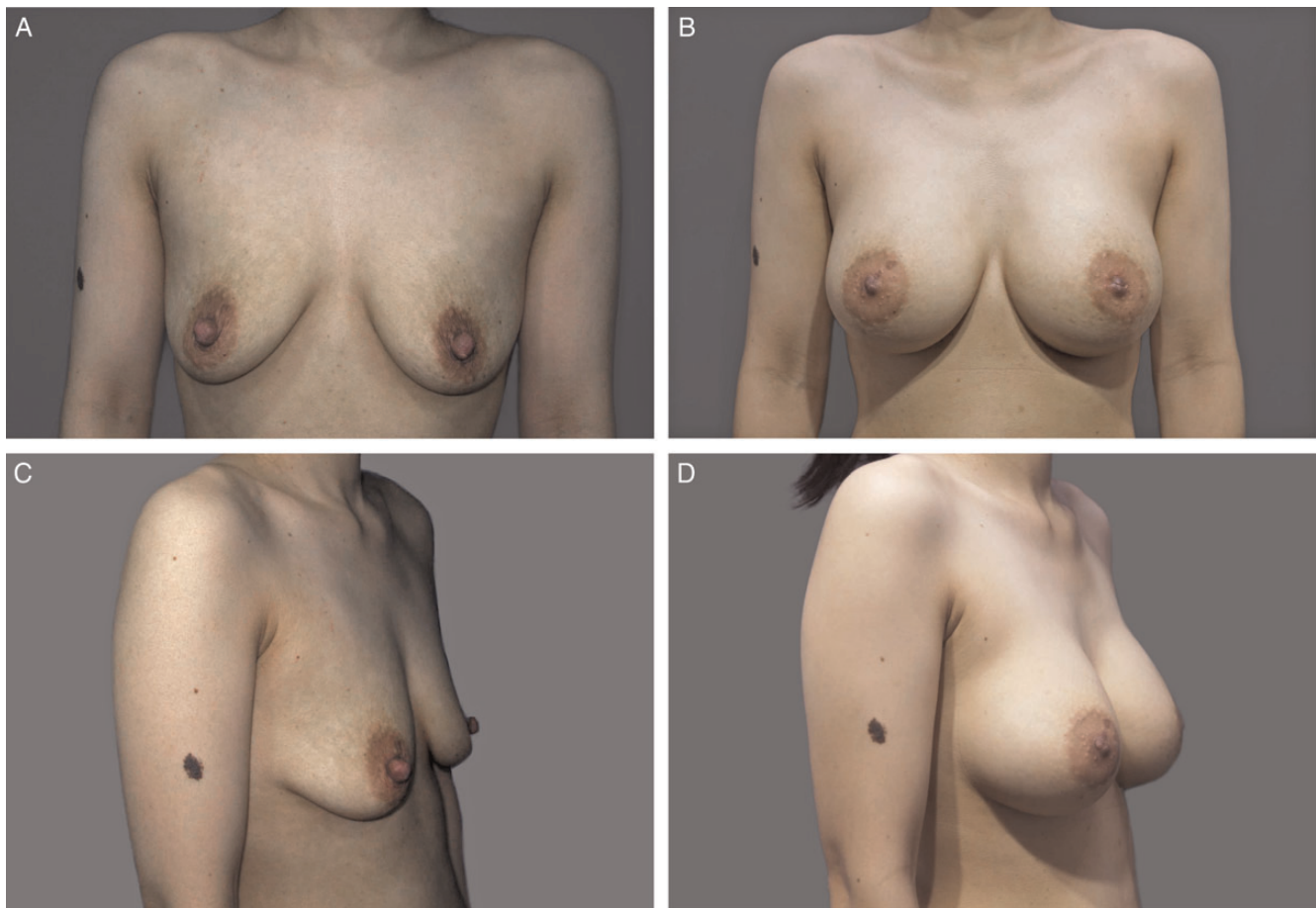

Figure 6. This 34-year-old woman underwent bilateral nipple reduction (chullo-hat technique) and simultaneous inframammary breast augmentation with round textured implants (style 115 290/290; Allergan, Irvine, CA). (A, C) Preoperative views. (B, D) Nineteen months after surgery.

select women. The technique may be appropriate for men as well. Outcomes were successful for nipples of various sizes.

Supplementary Material

This article contains supplementary material located online at www.aestheticsurgeryjournal.com.

Disclosures

The authors declared no potential conflicts of interest with respect to the research, authorship, and publication of this article.

Funding

The authors received no financial support for the research, authorship, and publication of this article.

REFERENCES

1. Regnault P. Nipple hypertrophy: a physiologic reduction by circumcision. *Clin Plast Surg*. 1975;2:391-396.
2. Lai YL, Wu WC. Nipple reduction with a modified circumcision technique. *Br J Plast Surg*. 1996;49:307-309.
3. Georgiade N, Georgiade G, Riefkohl R. Esthetic breast surgery. In: McCarthy J, ed. *Plastic Surgery*. vol 6. Philadelphia, PA: Saunders; 1990:3839-3896.
4. Marshall KA, Wolford FG, Cochran TC. Surgical correction of nipple hypertrophy in male gynecomastia: case report. *Plast Reconstr Surg*. 1977;60:277-279.
5. Ferreira LM, Neto MS, Okamoto RH, de Moura Andrews J. Surgical correction of nipple hypertrophy. *Plast Reconstr Surg*. 1995;95:753-754.
6. DeBono R, Rao GS. A simple technique for correction of male nipple hypertrophy: the "sinusoidal" nipple reduction. *Plast Reconstr Surg*. 1997;100:1890-1892.
7. Basile FV, Chang YC. The triple-flap nipple reduction technique. *Ann Plast Surg*. 2007;59:260-262.
8. Sperli AE. Cosmetic reduction of the nipple with functional preservation. *Br J Plast Surg*. 1974;27:42-43.
9. Vecchione TR. The reduction of the hypertrophic nipple. *Aesthet Plast Surg*. 1979;3:343-345.
10. Elsayh NI. Correction of abnormally high nipples after reduction mammoplasty. *Aesthet Plast Surg*. 1990;14:21-26.

11. Kwon JO, Lee TJ, Ock JJ. A new technique for surgical correction of nipple hypertrophy in male patients. *J Korean Soc Aesthet Plast Surg*. 2002;8: 155-158.
12. Baxter RA. Nipple or areolar reduction with simultaneous breast augmentation. *Plast Reconstr Surg*. 2003;112: 1918-1921.
13. Moliver C, Kargel J, Sullivan M. Treatment of nipple hypertrophy by a simplified reduction technique. *Aesthet Surg J*. 2013;33(1):77-83.
14. Sanuki J, Fukuma E, Uchida Y. Morphologic study of nipple-areola complex in 600 breasts. *Aesthet Plast Surg*. 2009;33(3):295-297.
15. Schlenz I, Kuzbari R, Gruber H, Holle J. The sensitivity of the nipple-areola complex: an anatomic study. *Plast Reconstr Surg*. 2000;105:905-909.
16. Koyama S, Wu HJ, Easwaran T, Thopady S, Foley J. The nipple: a simple intersection of mammary gland and integument, but focal point of organ function. *J Mammary Gland Biol Neoplasia*. 2013;18(2):121-131.
17. Cheng MH, Smartt JM, Rodriguez ED, Ulusal BG. Nipple reduction using the modified top hat flap. *Plast Reconstr Surg*. 2006;118:1517-1525.
18. Crestinu JM. The correction of the inverted nipples without scars: 17 years' experience, 452 operations. *Aesthet Plast Surg*. 2000;24:52-57.

Discover a wealth of knowledge

Oxford Journals Archive

- uncover backfiles of content dating from 1849
- instant access to 146 years of research
- seamless access from Volume 1, Issue 1
- access by IP range, Athens or Shibboleth
- COUNTER-compliant usage statistics