



A Muscular Etiology for Medial Implant Malposition Following Subpectoral Augmentation

Clayton L. Moliver, MD, FACS; Erick R. Sanchez, MD;
Kyle Kaltwasser, BS; and Ruston J. Sanchez, MD

Aesthetic Surgery Journal
2015, Vol 35(7) NP203–NP210
© 2015 The American Society for
Aesthetic Plastic Surgery, Inc.
Reprints and permission:
journals.permissions@oup.com
DOI: 10.1093/asj/sjv072
www.aestheticsurgeryjournal.com
OXFORD
UNIVERSITY PRESS

Abstract

Background: Implant malposition is becoming an increasingly recognized complication following subpectoral breast augmentation. Although several causes of medial malposition have been previously demonstrated, medial implant malposition secondary to unintended pectoralis muscle slips has not been previously described.

Objective: The goal of this study is to describe a form of medial implant malposition caused by pectoralis major and minor musculature vectors on the implant.

Methods: The primary investigator performed a retrospective review of all patients who underwent revisional breast surgery for the diagnosis of symmastia or medial implant malposition following subpectoral augmentation. Those patients with muscular-type etiology for medial implant malposition were identified.

Results: Five patients with pectoralis muscle slips causing medial implant malposition were identified. The pectoralis muscle slips were successfully diagnosed on preoperative exam and corrected with specific surgical procedures aimed at balancing surrounding forces and thus correcting malposition.

Conclusions: Pectoralis muscle slips contributing to medial malposition can be found in some patients after subpectoral breast augmentation. The etiology of this deformity is unknown, but theorized to be caused by anatomic predisposition, with slips inadvertently formed during subpectoral pocket formation arising from the pectoralis minor and/or incompletely released or accessory pectoralis major muscles.

Level of Evidence: 4



Accepted for publication March 26, 2015; online publish-ahead-of-print June 23, 2015.

Breast augmentation currently is the second-most common cosmetic surgical procedure in the United States, with approximately 313,327 procedures performed in 2013.¹ Large-scale studies have shown a revision rate for primary breast augmentation rate between 20 and 40%.^{2,3} Second only to capsular contraction, implant malposition has become an increasingly recognized reason for reoperation following primary breast augmentation.² Patients most often develop lateral or inferior malposition, with medial malposition occurring far less often.⁴ Due to the scarring and anatomic distortion seen with any reoperative surgery, revisional augmentation for malposition can be quite difficult.⁵ A thorough understanding of the diagnosis, mechanism, and treatment for malposition is of critical importance for successful revision. This

paper introduces a specific deformity seen in revision subpectoral augmentation not previously described, causing medial implant malposition.

Dr Moliver is a Clinical Professor of Plastic Surgery, Dr E. Sanchez is a Resident, and Mr Kaltwasser is a Medical Student, Department of Surgery, Division of Plastic Surgery, University of Texas Medical Branch, Galveston, Texas. Dr R. Sanchez is a Resident, Department of Surgery, Division of Plastic Surgery, University of Wisconsin Hospital and Clinics, Madison, Wisconsin.

Corresponding Author:

Dr Clayton L. Moliver, 575 East Medical Center Blvd., Webster, TX 77598.
E-mail: claymoliver@gmail.com

Medial malposition is a broad term describing any aesthetically unsatisfactory medial displacement of a breast implant. There exists a spectrum of severity with medial malposition ranging from mild displacement of the implant to malposition so significant that the implant can cross the midline. Medial malposition in which the implant crosses the midline is more specifically referred to as “symmastia.”⁴ Symmastia, or “uniboob,” can be a congenital finding in which breast tissue may be found between the breasts, but it is most commonly seen iatrogenically after breast augmentation.⁶ The prefixes sym- and syn- derive from Greek and mean “together,” as in symmastia. Although the term “synmastia” can be found in the literature, the correct orthographic rule dictates using the prefix sym- before labials such m, b, and p.⁷

Previous authors have described five primary causes of medial implant malposition: over-dissection of the medial pocket over the sternum in the subglandular plane, over-division of the pectoralis major muscle origin along the sternum in the submuscular plane, oversized implant diameter, oversized implant volume, and congenital symmastia.^{6,8} The senior author (Dr Moliver) has encountered another cause of medial malposition only found in subpectoral augmentation, in which aberrant pectoralis major or minor muscle fibers in the lateral submuscular plane displace the implant medially with muscle contraction. The etiology of these muscle bands is unknown, but anatomic variations in the pectoralis major and minor muscles described in a recent large-scale cadaveric study suggest that certain patients might be predisposed to this deformity following submuscular augmentation.⁹

The intent of this study is to introduce a new, not previously described muscular cause of medial implant malposition found in subpectoral augmentation in which aberrant muscle fibers restrict the lateral pocket, resulting in a medializing force pushing on the lateral aspect of the implant. Patients with this deformity may present with varying degrees of medial malposition, with some patients severe enough to earn the label of symmastia.

METHODS

A retrospective chart review was conducted, reviewing all patients who underwent revision augmentation for medial implant malposition by a single surgeon over a five-year period from January 2009 to December 2013. Patients with inferior and lateral types of malposition were not included in the data collection. All patients with medial implant malposition secondary to abnormal bands of pectoralis muscle were chosen for inclusion into this study. There were no exclusion criteria. All data was obtained by chart review and photographs from patients who signed written consent for the use of their medical information, including photos and video, for research and educational purposes.

Preoperative Patient Assessment

Surgical planning for medial malposition and symmastia correction begins with history, preoperative physical examination, and determination of causes of implant malposition. History includes a detailed account of breast surgical history, timeline of malposition, and previous attempts at correction. Previous implant characteristics, such as size, shape, and texture, as well as plane of implant placement, should be determined if possible. A detailed operative report of the initial augmentation procedure greatly aids patient assessment but unfortunately is not always available.

The preoperative physical exam begins with determining the severity of malposition by observing the implant location at rest in the sitting or standing position and then manually displacing the implant in the direction of reported malposition. Manual displacement determines the location and strength of resistance planes for preoperative planning and can also reveal malposition in patients who only have malposition when wearing a bra. Additionally, the examiner should pay close attention to nipple areolar complex asymmetry, which may reveal subtle findings. The implant edge distances from the midline and mid-axillary lines should be documented in the relaxed and flexed position with hands on hips. Pre-sternal skin adherence or lack of connection to the underlying fascia and sternum should also be investigated.

The patient should then be examined in the relaxed supine position. This allows gravity to lateralize the implant and shows the extent of the lateral implant pocket design. Implant influence from the pectoralis major muscle is tested by having the patient push anteriorly against resistance with their palms facing outward as they would during a bench press exercise or during push-ups. The pectoralis minor is then tested by asking the patient to lift their shoulder off the table towards the ceiling while maintaining their upper arm abduct and externally rotated. This position completely isolates the pectoralis minor. We refer to this test as the “pectoralis minor test,” as it isolates contraction of the pectoralis minor muscle while maintaining a relaxed pectoralis major muscle. The pectoralis major adducts and internally rotates the upper arm. In our initial maneuvers, we failed to fully abduct the arm, thus not fully isolating the pectoralis minor, in testing both pectoralis muscles (Figure 1, Supplementary Video 1). In subsequent patients with full abduction and supination of the ipsilateral arm, we were able to test for each muscle individually. Regardless, neither muscle on contraction should cause medial movement of the implant. If implant movement is found, we regard this as a medial force vector. Medialization of the implant during these maneuvers indicates a possible aberrant pectoralis minor, an intact slip of pectoralis major, or both, causing medial malposition.

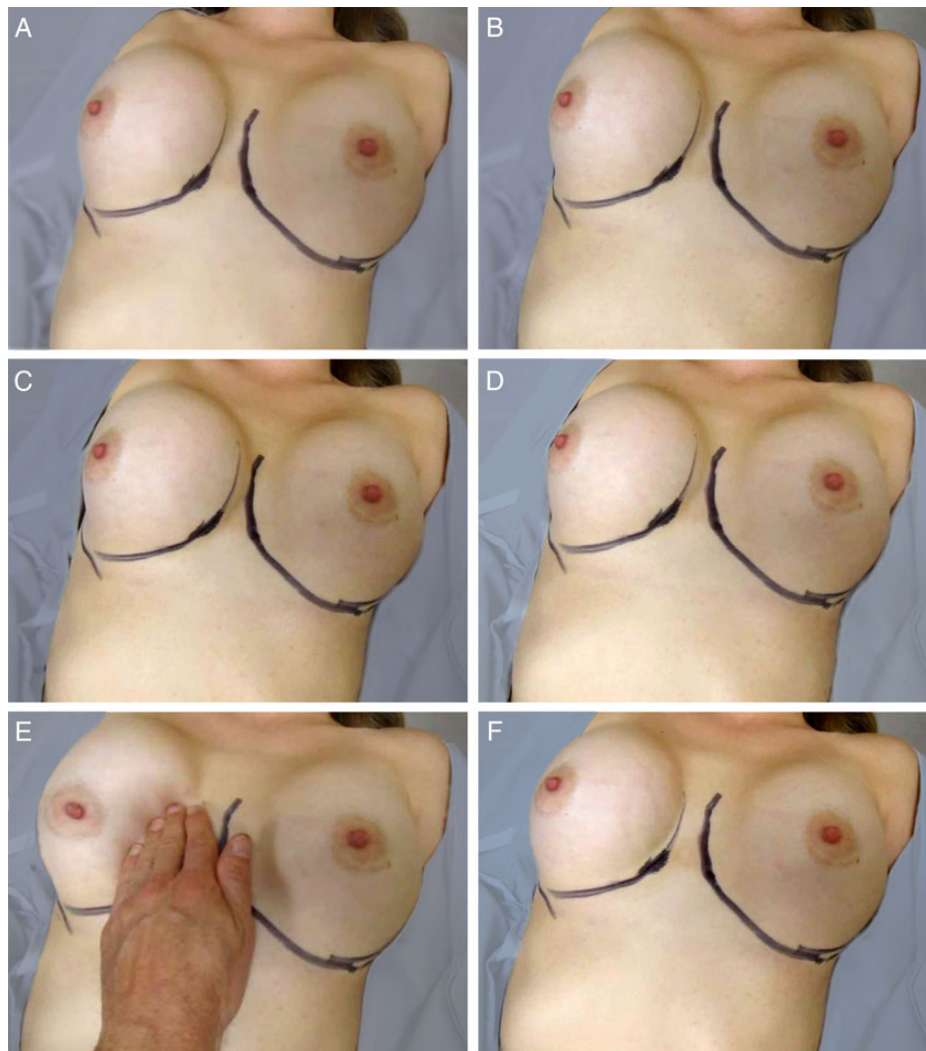


Figure 1. A 30-year-old woman (Patient 4) with right positive Pectoralis Minor Test. (A) At rest and supine, the implant rests in a normal position. (B) The patient flexes her pectoralis minor by lifting her right shoulder off the table, along with abduction and supination of the right arm. (C) The pectoralis minor muscle contraction pushes the implant medially. (D) After the maneuver at rest the implant is still medially displaced. (E) With manual force the implant easily moves into the lateral pocket. (F) After the implant is in the lateral pocket it stays there. Although not depicted here, with pectoralis major contraction the implant did not migrate medially.

Operative Technique

Approach for correction is typically through the previous augmentation incision with exception of axillary approach. The senior surgeon prefers correction through an inframammary or areolar approach. After capsulectomy, the lateral surrounding tissue is examined for any aberrant muscle fibers overlying the lateral capsule. Once a muscle band is isolated, the muscle of origin can be determined by following the muscle fibers back to their insertion. The fibers should continue to the humerus if they originate from the pectoralis major muscle or to the coracoid process if the fibers originate from the pectoralis minor. Electrocautery muscle stimulation

may help to determine the insertion and origin of the muscle but has not been helpful in recreating preoperative findings of malposition in our hands. The muscle fibers, if felt to be interfering with pocket design and contributing to implant position medially, can be divided, transected, or removed en bloc. As with all medial malposition cases, other factors contributing to the malposition, such as an over-dissected medial pocket or inadequately dissected lateral pocket, should be dealt with using the appropriate surgical technique. In addition to releasing muscle fibers causing malposition, the senior author employs a wide variety of techniques for medial malposition repair depending on the situation, such as capsulorrhaphy, pocket change, neosubpectoral pocket,

Table 1. Patients With Pectoralis Major or Minor Muscle Deformity Contributing to Medial Implant Malposition

Patient	Age (Years)	Sex	Problem	Pectoralis Minor Sign	Intraoperative Findings	Technique Used	Original Implant (Side and Size, Type, Placement, Manufacturer)	New Implant (Side and Size, Type, Placement, Manufacturer)	Complications	Additional Revision	Follow-up (Months)
#1	33	F	Left breast symmastia Sternal skin tenting	Positive left	Anomalous muscle fibers (left) PMM partially detached at sternum (left)	Transect fibers (left) Repair of PMM at w/ horizontal mattress sutures, <i>Belladerm</i> reinforcement	Unknown size; silicone; submuscular; unknown manufacturer	Right, 500 cc; left, 450 cc; silicone, submuscular, Mentor Moderate Plus	None	None	16
#2	51	F	Left breast medial malposition	Positive left	Anomalous muscle fibers (left) PMM partially detached at sternum inferiorly (left)	Transect fibers (left) Capsulorrhaphy, <i>Belladerm</i> reinforcement	Unknown size; saline; submuscular; unknown manufacturer	Right, 800 cc; left, 800 cc; silicone, submuscular, Mentor Moderate Plus	None	None	10
#3	28	F	Left breast medial malposition	Positive left	Anomalous muscle fibers	Transect fibers <i>Belladerm</i> reinforcement	Right, 431 cc; left, 488 cc; saline; submuscular, unknown manufacturer	Same implant used	None	None	6
#4	30	F	Bilateral Symmastia Sternal skin tenting	Positive bilaterally	Anomalous muscle strip bilaterally	Transect muscle strips <i>Belladerm</i> reinforcement	Right, 460 cc; left, 400 cc; saline; submuscular; unknown manufacturer	Right, 600 cc; left, 550 cc; silicone; submuscular; Mentor Moderate Plus	None	None	20
#5	33	F	Right breast symmastia Sternal skin tenting	Positive right	Anomalous muscle strip	Transect fibers (right) <i>Belladerm</i> reinforcement	Right, 300 cc; left, 275 cc; silicone, submuscular, Mentor Moderate Plus	Right, 450 cc; left, 400 cc; silicone; submuscular; Mentor Moderate Plus	Right malposition reoccurrence Tenting of skin at sternum persistent	Right neosubpectoral pocket	23

acellular dermal matrix (ADM) reinforcement, and reducing the size of the implant. Postoperatively, patients are advised to avoid any activities that will flex their pectoralis musculature, as this may add pressure to the implant and stress the repair. Direct pressure in the breast is also avoided, which includes sleeping in the prone position and intimacy that incurs a similar pressure. Typical sports bras should be avoided as they create anterior pressure as well, squashing the breasts rather than supporting them. Newer post-surgical bras and some new sports bras offer this type of upward support. Typically, the patient wears a thong bra under a support bra.

RESULTS

A retrospective review from January 2009 to December 2013 revealed 18 female patients who underwent secondary revision augmentation for pre-operative diagnosis of isolated medial malposition. Of these medial malposition patients, five were found to have muscle bands contributing to their medial malposition (Table 1). All five patients identified underwent previous subpectoral augmentation by an outside surgeon. Each patient underwent operative repair for medial malposition, which included identification and removal of any aberrant muscle slips contributing to medial displacement

of the implant, as well as any necessary medial malposition repair. A muscle component causing medial malposition was suspected in all patients preoperatively by history and physical exam, which was later confirmed intraoperatively. No false positive pectoralis muscle tests were noted. Patients' ages ranged from 28 to 51 years old (mean, 35 years old). The follow-up from time of repair ranged from 6 to 23 months (mean, 15 months). Representative cases are shown in Figures 1-4. All patients had long-term successful repair with the exception of one patient that had recurrence of medial implant malposition (Figure 3).

DISCUSSION

Medial malposition in submuscular augmentation occurs when there is an imbalance of directional forces acting on the implant. Normally, in the subpectoral plane gravity and the surrounding tissues, such as attachments at the inframammary fold, the overlying pectoralis major, the chest wall, lateral soft tissue, and muscle attachments at the sternum and clavicle all push on the implant, holding it in an aesthetically ideal position. The previously-described causes of medial malposition can all be explained by an alteration of these forces. Over-dissection of the medial

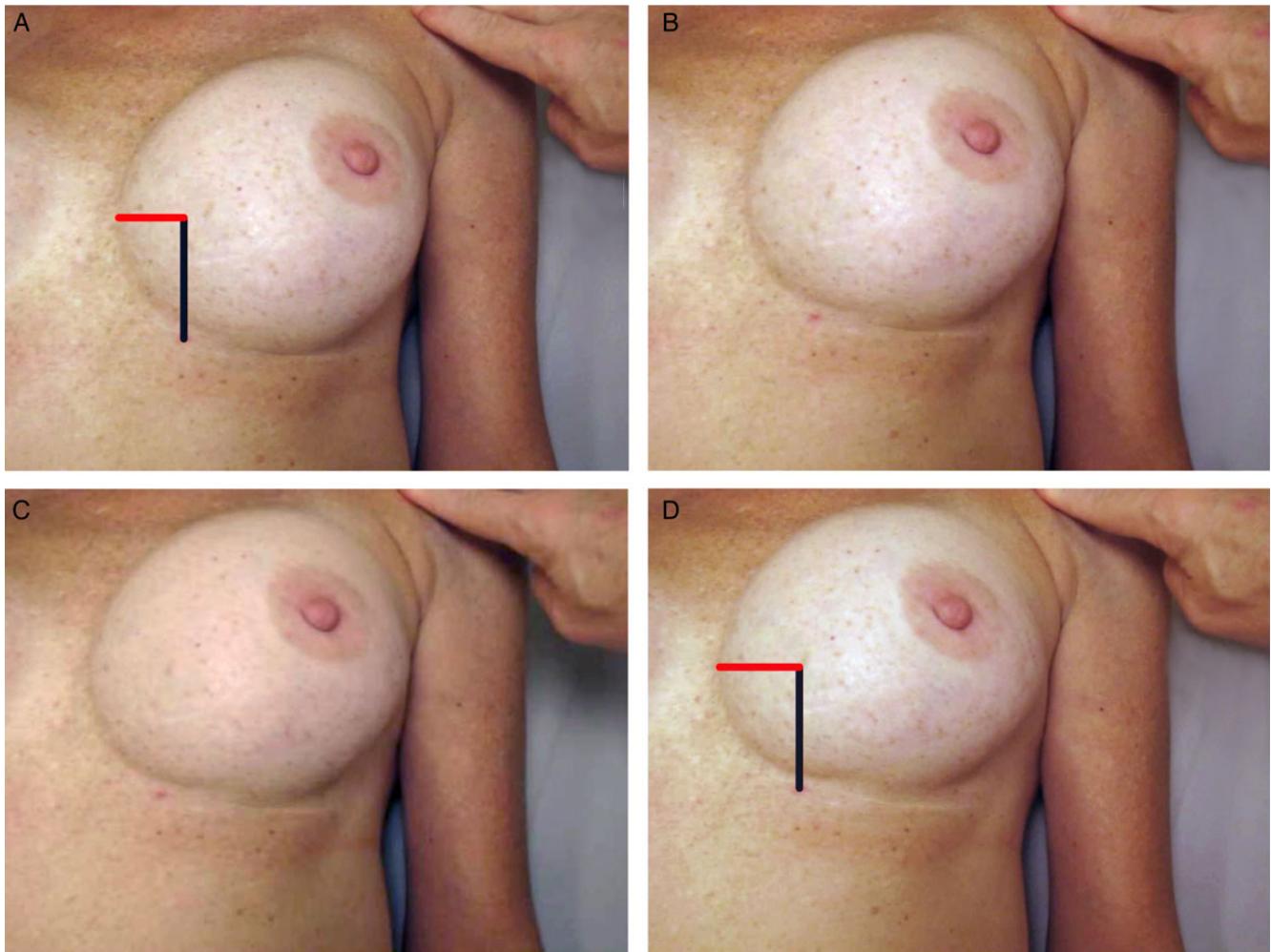


Figure 2. A 33-year-old woman (Patient 1) with left positive Pectoralis Minor Test. (A) Patient is at rest. (B) The pectoralis minor is flexed and the implant shifts medially. (C, D) With sustained flexion the implant continues to shift medially. The change in the red bar size included in (A, D) displays change in implant position.

pocket in the subglandular or submuscular plane damages medial resistance structures that normally prevent the implant from traveling towards the midline. An overly tight lateral pocket can push an implant into a medialized position. Using an oversized implant volume or diameter may, over time, break down surrounding tissues leading to malposition because of now-unopposed forces from the contralateral direction. We introduce a new cause of medial implant malposition in the subpectoral plane characterized by muscle bands in the lateral pocket and creating a medializing force upon the implant, which can worsen with contraction of the muscle fibers. These muscle bands traverse the subpectoral pocket, traveling between the overlying pectoralis major and the underlying pectoralis minor and wrapping around the lateral aspect of the capsule, which restricts the lateral pocket, creating a medializing force vector on the implant.

In medial malposition, the degree of displacement depends upon both the strength of the medializing vectors acting on the implant and the strength of the medial resistance structures. With intact medial resistance structures, the patient may only exhibit mild to moderate medial malposition as long as the medial resistance is intact. This was the case in Figure 2, in which the muscle slips only caused mild malposition, as intact medial resistance prevented further migration of the implant (Supplementary Video 2). However, if the medial structures are compromised then the unopposed medializing vectors may move the implant into the midline, signifying the development of severe medial malposition or even symmastia (Figures 3 and 4). The inherent medial resistance formed by the sternal origin of the pectoralis major muscle can be damaged by either an oversized implant or through the over-release of pectoralis fibers at the medial region. Previously, some surgeons

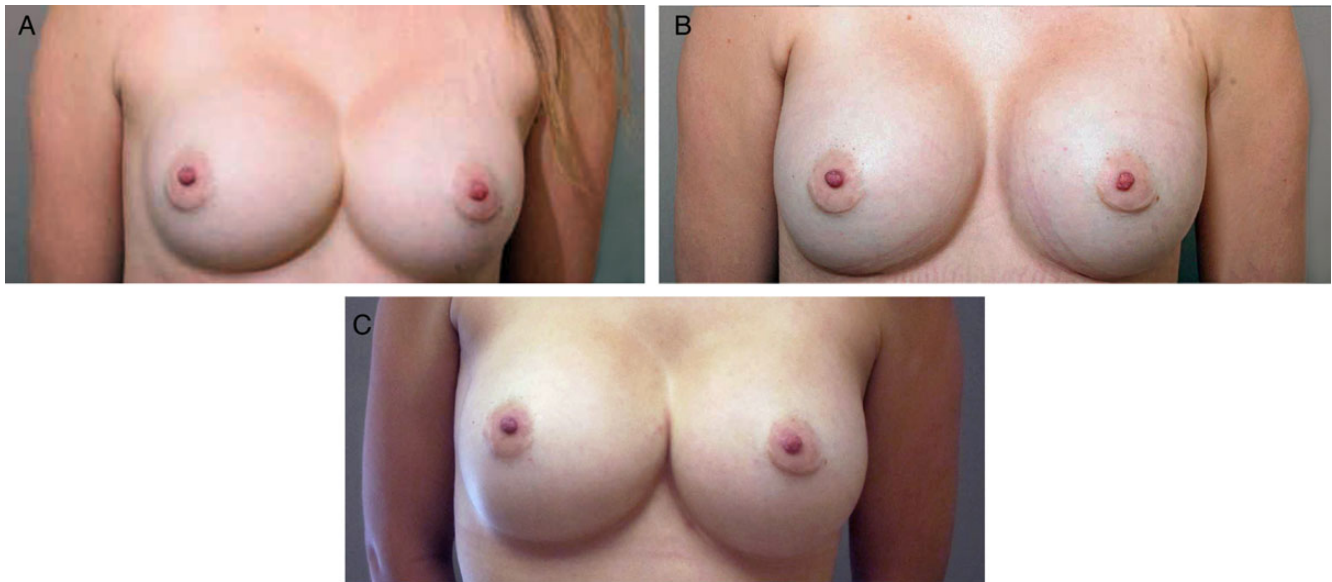


Figure 3. This 30-year-old woman (Patient 4) presented with symmastia and tenting of skin between the breast after undergoing an augmentation and a revision by an outside surgeon. Preoperatively, the patient had positive pectoralis minor sign bilaterally, and during surgery a portion of the pectoralis minor muscle was found on both sides, pushing the implants medially. The muscle slips were divided at the fifth rib on both sides and an ADM sling was used bilaterally to reinforce the medial implant pocket. The original saline implants (right, 460 cc; left, 400 cc) were exchanged for silicone implants (right, 600 cc; left, 550 cc). (A) Preoperative photograph. (B) Photograph obtained six months postoperatively shows resolution of symmastia. (C) Photograph obtained 20 months postoperatively shows recurrence of right malposition.

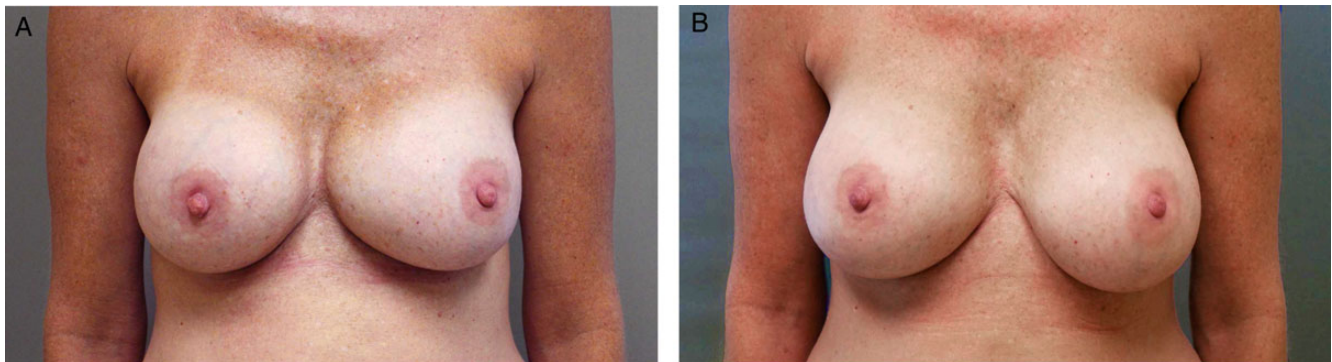


Figure 4. This 33-year-old woman (Patient 1) presented with left implant medial malposition after primary augmentation. Preoperatively, the patient had positive pectoralis minor sign on the left side. She underwent bilateral implant exchange, left medial capsulorrhaphy, and ADM reinforcement. The original silicone implants (unknown size) were exchanged for silicone implants (right, 500 cc; left 450 cc). (A) Preoperative photograph. (B) Photograph obtained 16 months postoperatively.

advocated partial and complete release of the pectoralis major at the sternal origin to achieve more cleavage, but others have begun arguing that this practice is unsafe and may have little to no benefit.¹⁰⁻¹⁶ A retrospective cohort by Lindsey¹⁷ comparing augmentations with sternal release to those without sternal release showed no difference in cosmetic outcomes. A recent anatomic study investigating the sternal origin of the pectoralis major muscle suggested that the purposeful partial-width release of sternal origin fibers is potentially unsafe and likely unnecessary.¹⁸

Though there are numerous techniques described in the literature for repairing medial malposition, few papers

address the etiology of the condition. Given that this new etiology of medial malposition has not yet been described, we can assume that this is a rare complication that probably goes undiagnosed, potentially resulting in unsuccessful revisions. We identified five patients with muscle causes for malposition, but it is difficult to comment on incidence as all of the patients came from an outside physician and several had already had at least one revision for malposition problems prior to coming to the senior author (Table 1).

The senior author first discovered these muscle slips in a patient with malposition of subpectoral implants and a previously unsuccessful revision. During the second revision,

pectoralis muscle slips were found wrapping around the lateral aspect of the implant. After examining other patients with this defect, we became suspicious that the fibers in these patients originated from the pectoralis minor muscle, and subsequently consulted with a physical therapist to determine how to properly isolate pectoralis minor contraction. When examining the patients we found that we could push the implant into the lateral aspect of the pocket on exam, demonstrating adequate lateral dissection. In fact, several patients presented with prior operative notes documenting opening of the lateral pocket as a means of correcting the medialization. Additionally, some patients complained on presentation of a strange lateral tightness similar to what might be expected in a patient with capsular contracture that subsequently resolved postoperatively. Given that we suspected a muscular component preoperatively and expressed this to patients, there could have been an unintentional bias in patient reporting of this sensation. Other than this tightness, patients have subjectively noted no difference other than implant position postoperatively. Postoperatively, we have found that this small series of patients have not had recurrence of their muscle slips.

Although we do not know how these pectoralis muscle slips form, we can speculate. After identifying these aberrant muscle fibers in a number of patients, we carried out a large-scale cadaveric investigation into the anatomic relationship of the pectoralis major and minor muscles.⁹ The analysis of 202 cadaveric pectoralis muscles showed large variability in the relationship of costal origins of the pectoralis major and minor muscles. In addition, rare connecting muscular bands between these muscles were found, which could potentially create a muscular sling lateral to the implant if not identified and released during pocket formation. Another possible explanation is that particular variations in pectoral muscle anatomy may predispose the patient to the inadvertent formation of these muscle slips when creating the subpectoral pocket. During formation of the submuscular pocket, dissection into the pectoralis minor muscle belly may lift a strip of muscle from the core muscle belly, which then becomes adherent to the overlying pectoralis major muscle. Figure 5 illustrates this concept, depicting how lifted pectoralis minor fibers could form a medializing force, thus contributing to medial malposition. At this point, we cannot say if this deformity is purely iatrogenic, if some patients are anatomically predisposed to this problem, or if it is a combination of the two.

We are unsure of the incidence of this muscle deformity or the degree that it contributes to malposition, but for revision cases for medial malposition in subpectoral augmentation patients we recommend preoperative screening using the pectoralis minor muscle test as well as flexing of the pectoralis major preoperatively to determine whether there is a muscular component to their malposition. A positive result can aid preoperative planning and subsequently can be

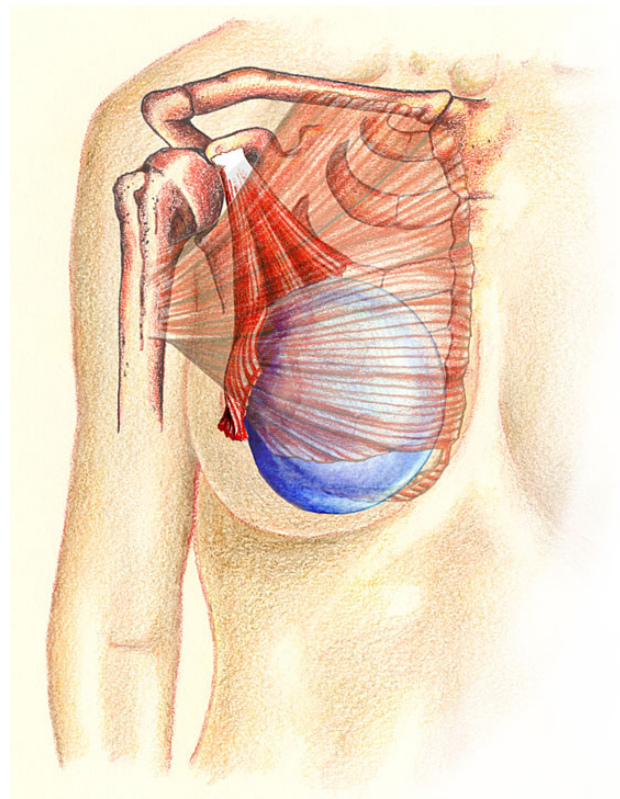


Figure 5. Illustration demonstrating the slip of the lateral pectoralis minor muscle raised above or lateral to implant, causing medial implant vector.

confirmed intraoperatively under direct vision. Since malposition is often multifactorial, other contributing factors to medial malposition, such as an inadequately dissected lateral pocket or oversized implant, will need to be addressed for a successful repair. If the implant is kept in the submuscular plane then the muscle fibers can successfully be transected to allow lateralization of the implant. Additionally, the pocket can be changed to a subglandular pocket or a neosubpectoral pocket can be created. In some cases of medial malposition and symmastia the medial resistance must also be reinforced to prevent implant migration. This need for medial reinforcement is demonstrated in the patient presented in Figure 3. This patient was found to have both a pectoralis minor muscle slip contributing to malposition, as well as over-dissection of the sternal origin of the pectoralis sternal origin. During our repair the aberrant muscle slip was released and a cellular dermal matrix was used to reinforce the medial breast pocket. Although at six months the repair remained intact and her preoperative breast tightness symptoms were resolved, she developed recurrence of implant malposition at the one-year follow-up. A follow-up pectoralis minor exam test was negative, demonstrating that the lateral muscle bands had been fully released. We attribute this recurrence to likely stretching of the ADM.

We have little insight into prevention, but recommend being aware that some patients may have predisposing anatomy, in which cases direct visualization of the subpectoral pocket may reveal connecting muscle fibers traversing the submuscular plane and prevent creation of such muscle bands.⁹

The limitations to this study are the small number of patients, inability to comment on possible incidence, and our failure to identify how exactly these muscle slips form. Additionally, since implant malposition is often multifactorial it is difficult to quantify the contribution of these muscle slips to medial malposition. Future research is needed to identify more patients with these muscle slips in order to determine their overall incidence and significance as a cause of medial malposition and symmastia.

CONCLUSION

We introduce a new muscular deformity contributing to medial malposition found in the subpectoral plane that imparts a medial directed vector on the implant following primary augmentation. Etiology of this deformity is unknown, but theorized to be caused by either anatomic predisposition or inadvertent muscle slip formation during subpectoral pocket formation. Although this deformity is likely rare, we feel that if missed it may contribute to recurrence of medial malposition after revisional augmentation.

Supplementary Material

This article contains supplementary material located online at www.aestheticsurgeryjournal.com.

Disclosures

The authors declare no potential conflicts of interest with respect to the research, authorship, and publication of this article.

Funding

The authors received no financial support for the research, authorship, and publication of this article.

REFERENCES

1. Cosmetic Surgery National Data Bank: Statistics 2013. *Aesthet Surg J*. 2014;34(Supp 1):1S-22S.
2. Spear SL, Murphy DK, Slicton A, Walker PS. Inamed silicone breast implant core study results at 6 years. *Plast Reconstr Surg*. 2007;120:8S-18S.
3. Cunningham B, McCue J. Safety and effectiveness of Mentor's MemoryGel implants at 6 years. *Aesthet Plast Surg*. 2009;33:440-444.
4. Spear SL, Bogue DP, Thomassen JM. Synmastia after breast augmentation. *Plast Reconstr Surg*. 2006;118:168S-171S; discussion 172S-174S.
5. Hammond DC, Hidalgo D, Slavin S, Spear S, Tebbetts J. Revising the unsatisfactory breast augmentation. *Plast Reconstr Surg*. 1999;104:277-283.
6. Selvaggi G, Giordano S, Ishak L. Synmastia: prevention and correction. *Ann Plast Surg*. 2010;65:455-461.
7. Spence RJ, Feldman JJ, Ryan JJ. Symmastia: the problem of medial confluence of the breasts. *Plast Reconstr Surg*. 1984;73:261-269.
8. Wong MT, Cheong EC, Lim J, Lim TC. Creation of an intermammary sulcus in congenital synmastia. *Singapore Med J*. 2007;48:e29-e31.
9. Sanchez ER, Sanchez R, Moliver C. Anatomic relationship of the pectoralis major and minor muscles: a cadaveric study. *Aesthet Surg J*. 2014;34:258-263.
10. Codner MA, Cohen AT, Hester TR. Complications in breast augmentation: prevention and correction. *Clin Plast Surg*. 2001;28:587-596.
11. Day CR, Nahai F. Transaxillary endoscopically assisted subpectoral augmentation mammoplasty. *Oper Tech Plast Reconstr Surg*. 2000;7:107-115.
12. Elliott LF. Breast augmentation with round, smooth saline or gel implants: the pros and cons. *Clin Plast Surg*. 2001;28:523-529.
13. Hedén P, Jernbeck J, Hober M. Breast augmentation with anatomical cohesive gel implants: the world's largest current experience. *Clin Plast Surg*. 2001;28:531-552.
14. Tebbetts JB. Dual plane breast augmentation: optimizing implant-soft-tissue relationships in a wide range of breast types. *Plast Reconstr Surg*. 2001;107:1255-1272.
15. Tebbetts JB. Patient evaluation, operative planning, and surgical techniques to increase control and reduce morbidity and reoperations in breast augmentation. *Clin Plast Surg*. 2001;28:501-521.
16. Tebbetts JB. Achieving a predictable 24-hour return to normal activities after breast augmentation: part I. Refining practices by using motion and time study principles. *Plast Reconstr Surg*. 2002;109:273-292.
17. Lindsey JT. The case against medial pectoral releases: a retrospective review of 315 primary breast augmentation patients. *Ann Plast Surg*. 2004;52:253-257.
18. Sanchez ER, Howland N, Kaltwasser K, Moliver C. Anatomy of the sternal origin of the pectoralis major and implications for subpectoral augmentation. *Aesthet Surg J*. 2014;34:1179-1184.