



Featured Operative Technique

Brachioplasty: A Personal Approach

Sepehr Egrari, MD, FACS

Aesthetic Surgery Journal
2016, Vol 36(2) 193–203
© 2015 The American Society for
Aesthetic Plastic Surgery, Inc.
Reprints and permission:
journals.permissions@oup.com
DOI: 10.1093/asj/sjv146
www.aestheticsurgeryjournal.com
OXFORD
UNIVERSITY PRESS

Abstract

Brachioplasty has become one of the most rapidly growing operations in plastic surgery. There are a variety of arm presentations, due to either weight loss or other reasons, and the extent of the defect can carry into the lateral chest wall and the back. In this featured operative technique article, the author describes indications, patient selection, and criteria for classifying brachioplasty, and illustrates the surgical techniques of this procedure. Markings, scar positioning, and the various operative steps are described along with the intricacies of postoperative care, including scar control. A personal experience, along with the limitations of brachioplasty, are discussed.

Accepted for publication June 29, 2015; online publish-ahead-of-print September 29, 2015.

Brachioplasty is one of the most rapidly growing operations in body contouring. In 2014, the American Society for Aesthetic Plastic Surgery's annual procedural statistics reported 22 829 arm lifts. In comparison to its frequency in 1997, brachioplasty had risen 807.4%.¹ A beautiful arm has always exuded a sense of fitness and anatomic prowess. From the early works of the Renaissance to our new popular culture, a fit arm has been an important part of the quest for beauty and health. In the literature of plastic surgery, the first description of brachioplasty was by Correa-Iturraspe in the *Argentinian Medical Press* in 1954.² Today, our literature is laced with descriptions of various techniques, the categorization of anatomy, and the outcomes of brachioplasty.^{3–5}

Recently, a tremendous body of knowledge has arisen on the heels of the well-established revolution of massive weight loss body contouring in plastic surgery. The ravages of weight loss are responsible for the production of myriad diverse and complex anatomic and structural changes to the skin and integrity of the arm. From a simple excess of skin to complex multifaceted lipodystrophy, the presentation of arm laxity has become an integral part of the practice of the body-contouring specialist. Along with the radial excess of arm skin, the upper body and lateral chest wall also present a relevant and connected comorbidity that can be addressed for a complete upper-body contouring.

In this featured operative technique article, the author describes a personal experience with brachioplasty. This includes patient selection, classification of excess arm skin,

and its relevance to the lateral chest wall and upper body. Operative techniques are described along with markings, scar positioning, and various intraoperative maneuvers. Postoperative care, especially attempts at scar control, is discussed, as well as a report of a series of consecutive patients with a description of outcome, complications, and limitations.

PATIENT SELECTION

The main indication for brachioplasty was either lipodystrophy or excess skin in the upper arms. The extent of the lipodystrophy or excess skin then determined the types of brachioplasty that these patients needed. The dramatic differences in body habit and weight loss translate to myriad presentations in arm recontouring (Figure 1). The extension of excess arm skin and lipodystrophy also carried toward the lateral chest wall and upper body (Figure 2). Some of these patients had a combination of brachioplasty and thoracoplasty. Some also had upper body lifts as a part of the constellation of strategies aimed at their upper truncal recontouring.

Dr Egrari is a plastic surgeon in private practice in Bellevue, WA.

Corresponding Author:

Dr Sepehr Egrari, 2950 Northup Way, Suite 100, Bellevue, WA 98004, USA.
E-mail: segrari@egrari.com

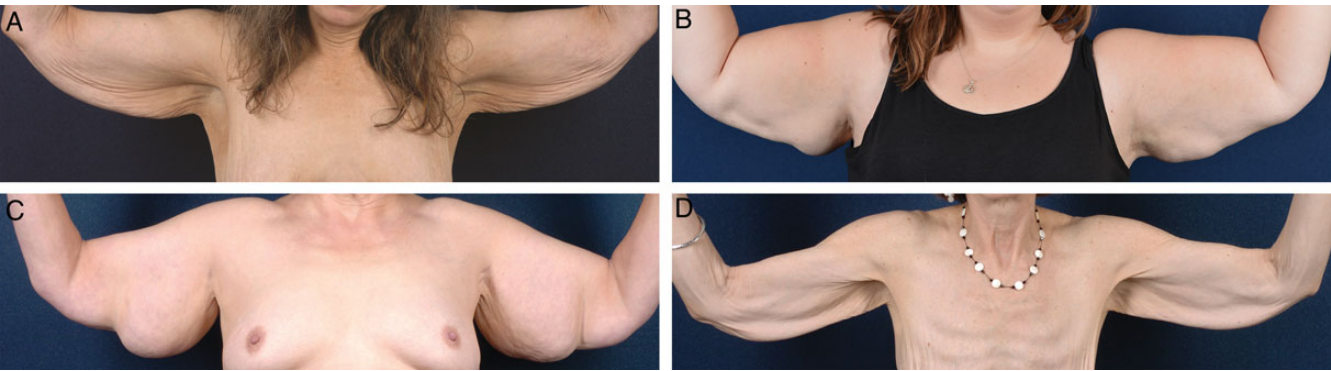


Figure 1. Different presentations of arm excess skin and lipodystrophy in (A) 60-, (B) 24-, (C) 62-, and (D) 59-year-old women.

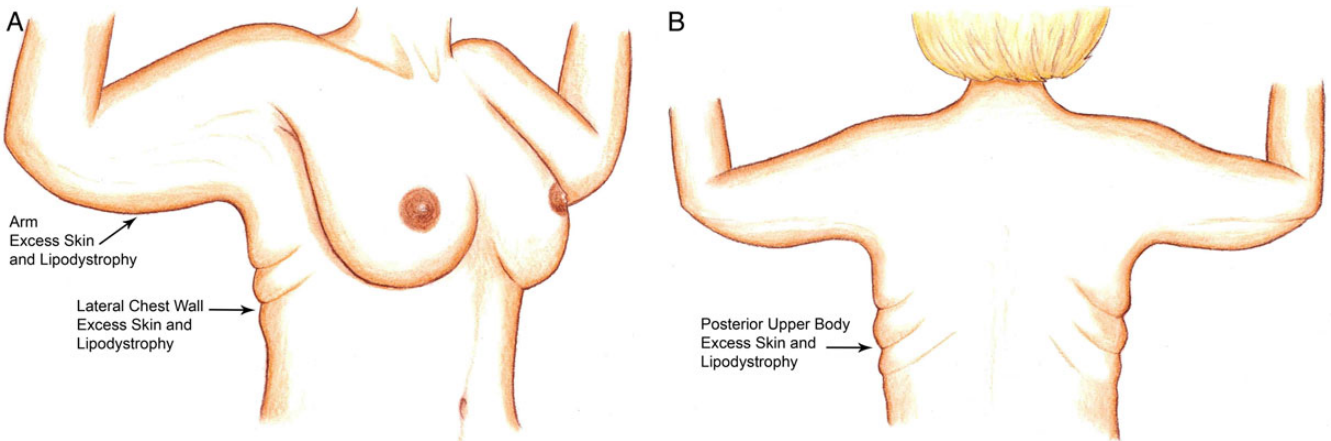


Figure 2. (A) The extent of lipodystrophy and excess of skin not only involves the arms, but also can extend to the lateral chest wall. (B) The posterior upper body can further be a part of the constellation of the presenting defect.

From this diverse group, four types of brachioplasty were determined and classified. Type I patients had very little excess skin, most of it occurring in the upper arms. These individuals were candidates for the less commonly used minimal incision brachioplasty. These patients had minimal lipodystrophy. Type II patients had moderate excess skin in the upper arms and underwent a standard brachioplasty. This was a common group that presented with the arm as their central complaint. Many of the non-weight loss patients fell into this category. Type III patients had both excess skin and lipodystrophy, and majority of this group had a combination of brachioplasty and suction-assisted lipectomy (SAL). Most of these patients also had involvement to some extent of the lateral chest wall. Many of the patients that did not have optimal weight resolution were in this category. Type IV patients had not only excess arm skin and lipodystrophy, but also significant involvement of the lateral chest wall and upper body. This group had a combination of brachioplasty along with thoracoplasty and/or an upper body lift (Table 1, Figure 3).

Table 1. Classification and Treatment of Various Presentations

Classification	Skin and Anatomic Involvement	Type of Brachioplasty
Type I	Minimal Excess Skin	Minimal Incision Brachioplasty
Type II	Excess Skin	Standard Brachioplasty
Type III	Excess Skin and Fat <ul style="list-style-type: none">• \pmLateral Chest Wall Involvement	Extensive Brachioplasty \pm SAL
Type IV	Excess Skin and Fat <ul style="list-style-type: none">• Lateral Chest Wall Excess• Upper Body Excess and Ptosis	Extensive Brachioplasty \pm SAL <ul style="list-style-type: none">• Thoracoplasty• Upper Body Lift

SAL, suction assisted lipectomy.

All patients underwent a rigorous preoperative evaluation that included consultations, medical evaluation, examination of appropriate laboratory and diagnostic parameters,

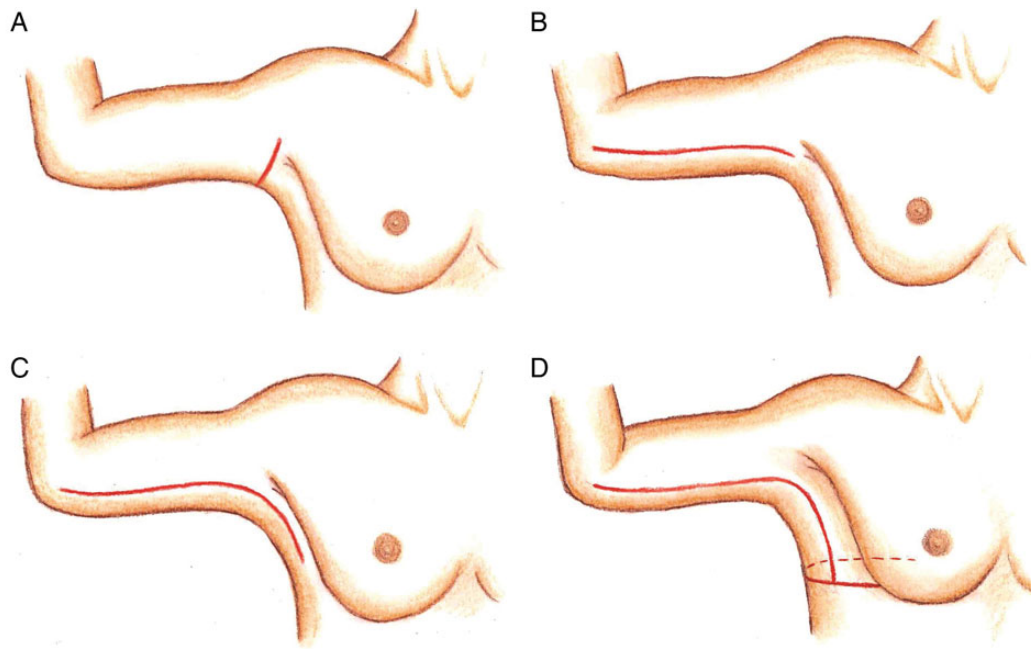


Figure 3. Illustration of different options of brachioplasty. (A) Minimal incision brachioplasty, (B) standard brachioplasty, (C) extensive brachioplasty, and (D) extensive brachioplasty with involvement of lateral chest and upper body.

and determination of general health and mental readiness. A complete informed consent, emphasizing some of the inherent limitations of this operation, was obtained.

OPERATIVE TECHNIQUE

Preoperative Markings

Accurate preoperative marking is a stepping-stone for an organized and efficient operative approach for brachioplasty. However, given the tremendous diversity that the patients present with, significant operative improvisation is also imperative. This not only addresses the tremendous variety of presentations, but also prevents over-resection, which is a fear in complex presentations. In body contouring, standardized approaches and preoperative markings must be looked at with caution. A complete video of the author's described technique can be viewed at www.aestheticsurgeryjournal.com.

In this article, the author describes two adaptable techniques of brachioplasty. All patients are marked in a standing position. A thorough evaluation of preoperative photos of arms in both adducted and abducted positions is a prelude to an accurate marking session. As the author's experience has evolved, the final scar is more commonly planned to lie in a posterior-medial position and not in the higher position, bicipital groove, or the lower line, posterior (Figure 4). This becomes an important guide and point of reference for the initiation of the marking. All marking begins by a manual

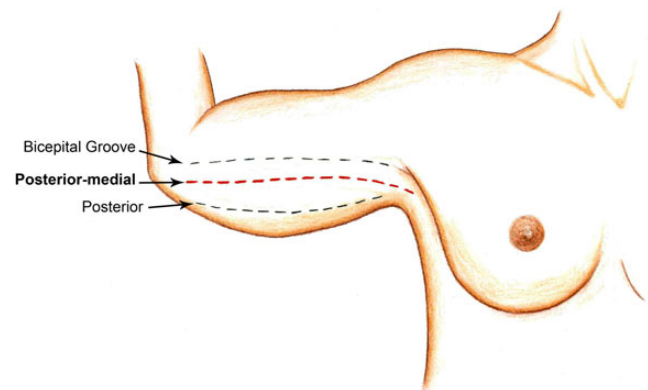


Figure 4. The strategy for the marking is based on using a posterior-medial position (red) for the eventual scar and not the higher bicipital groove or the lower posterior positions.

inspection and an overall approximation of the extent of resection. The two initial reference points are the medial epicondyle and the apex of the axillary fossa. Marks are placed in both of these points. The expected position of the scar, in the posterior-medial position, is forecasted and drawn in a red line. The line will carry on to the surface of the upper chest wall, making a sharp turn at the axilla. This maneuver often alleviates an unsightly and challenging excess of skin that is gathered near the axillary fossa. The author also feels that a sharp turn of this excision at the axillary fossa, and its continuation towards the chest wall can indeed replace a

z-plasty (Figure 5A). Z-plasties can disrupt the natural contour of the dome of the axilla, and hence make this linear technique more attractive. The extension into the chest is dependent on the excess of lateral chest wall skin. The committed upper incision is then placed slightly—1 cm—above the predicted incision line. This marking follows the general direction of the scar line and carries to the lateral chest wall as needed. The approximate predicted lower incision line is also placed, with the condition that operative “tailor tacking” might change its extent (Figure 5B). This line is often determined by pinching the skin and approximating the extent of the excision. As this line approaches the axilla, it is imperative to pull some of the proximal excess arm skin in order to create a sharper junction of the arm and lateral

chest wall. When all the markings are done (Figure 6A), it is helpful to ask the patient to raise their arms up high. This allows the determining of the geometric and linear proportion of the upper and lower scar. It is at this junction that adjustments are made to the distal aspect of the scar to avoid dog-ears and unequal scar approximation (Figure 6B).

Positioning

All cases are done under general anesthesia. Patients are placed in a well-padded supine position. Sequential compression garments are placed over the calves. The arms are abducted at 90 degrees and circumferentially prepped. Each arm is addressed, and during the resection each side is

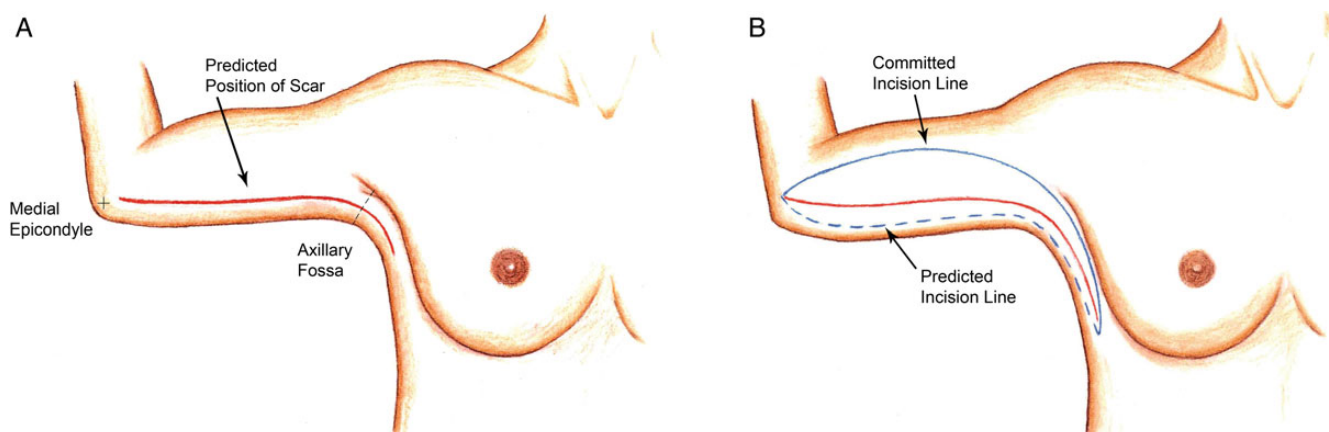


Figure 5. (A) The medial epicondyle and the apex of the axillary fossa are marked. The position of the predicted scar (in red) is also marked in a posterior-medial position. (B) A committed line is chosen above the scar and an approximate predicted line is chosen inferiorly.

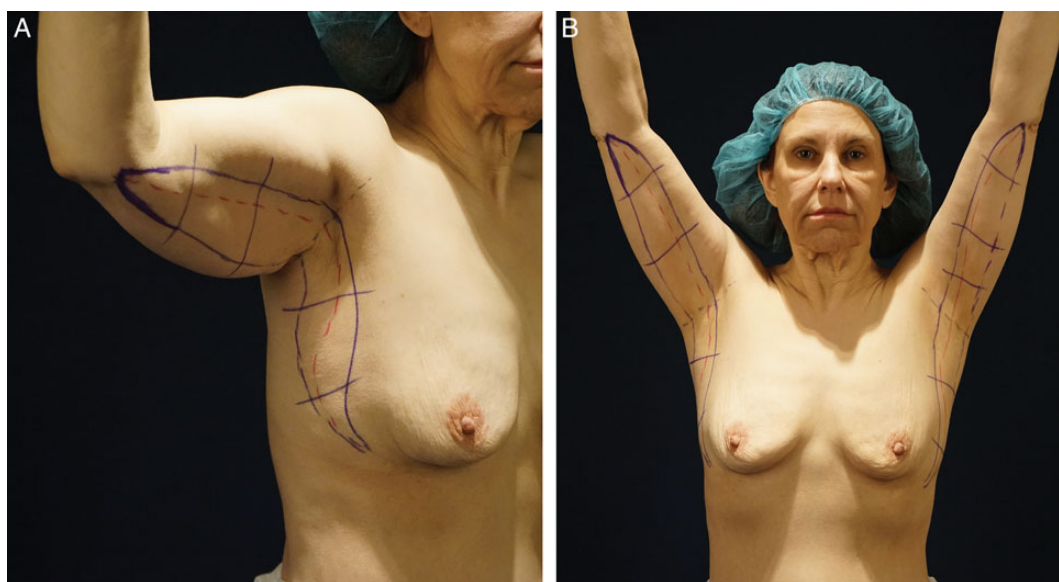


Figure 6. (A) Demonstration of the completed marking in a 52-year-old woman. (B) Symmetry, balance and linear relationship of the designed marking is inspected with the patient's arms in fully raised position.

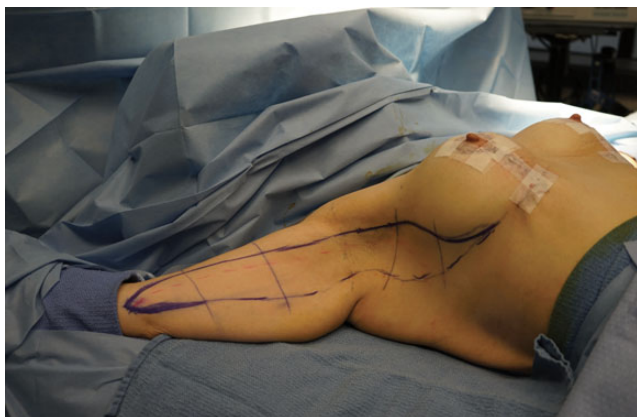

Figure 7. Operative positioning. In this 52-year-old woman, the arm is abducted to approximately 130 degrees during the resection in order to establish tension and ease excision.

rotated up to approximately 135 degrees. This maneuver is useful in establishing some tension for the eventual excision (Figure 7).

Tailor Tacking

The author discusses two essential brachioplasty techniques. They are both based on control and efficiency, and allow significant intraoperative choice. The intraoperative staple approximation technique is a method by which temporary staple closure, using the previous marking as guide, allows the determination of the amount of excision and the extension into the chest wall. This is ideal for thinner arms that have copious skin. The resection and closure technique is often used in conjunction with SAL for arms that have excess fat. This technique, in a stepwise manner, allows for a progressive and controlled segmental resection of the inferior line of the excision.

- **Intraoperative Staple Approximation Technique**

As the patient is positioned, the arm is further abducted and the excess skin is surveyed circumferentially. Starting from the elbow and moving toward the axilla, the excess skin is grasped with forceps and approximated at the levels of the marking, or more if the laxity allows (Figure 8A). A fair bit of tension is placed, recognizing that eventual resection of the included skin will ease the closure, and close stapling is carried from the elbow proximally toward the axilla. There, a sharp turn toward the apex of the fossa is then carried toward the lateral chest. The circumference of the arm is checked, and the amount of tension and the contour is noted. The marking pen is used to line the outside periphery of the temporary stapled closure (Figure 8B). This line should be placed comfortably outside the staple line. Crosshatchings are then done for approximation. Staples are removed.

Xylocaine with dilute epinephrine is injected into the new markings. The area of the axillary fossa is marked and distinguished. In this area, to protect the vital lymphatic structures (Figure 8C), a much more superficial dissection will be performed during the excision of the excess skin. The incisions are made and deepened past the superficial fascia system (SFS). The flap is elevated off the brachial fascia and some subcutaneous tissue from the elbow to the lateral chest. (Figure 8D) Care is taken to leave this floor, as this will not only serve as the bottom point of the 3-point closure, but also theoretically cover and hence protect the various lymphatic channels and sensory nerves. It is also important to maintain a more superficial level at the axillary fossa during this dissection (Figure 9).

- **Resection and Closure Technique**

In this technique, the arm is also abducted. The majority of the patients that undergo this technique will most likely have concomitant liposuction. An approximation of the excision is once again determined. A dilute standard wetting solution is injected through a small incision at the distal aspect of the scar. After proper elapsed time, a liposuction device of choice—in the author's case, a power-assisted liposuction device—is used to suction out the subcutaneous fat under the proposed area of resection (Figure 10A). Some advance is made past the lower proposed line into the posterior compartment of lipodystrophy. The area under the proposed resection is aggressively emptied to a point that the cannula is visible (Figure 10B). This will serve as the basis of a quick and bloodless dissection toward the proposed lower resection line. Once the amount and extent of liposuction is determined to be appropriate, attention is turned to the resection and closure technique.

The entire upper committed incision is made and deepened past the SFS. The pocket of liposuction under the proposed resection paddle is then approached. With inferior traction, a bloodless and loose fibrous remnant of the area of liposuction is opened inferiorly (Figure 10C), slightly past the lower line of resection. This is performed from the elbow to whatever extent of the lateral wall has been previously determined and marked. As with the other technique, care is taken to leave a healthy layer of brachial fascia and subcutaneous fat on the floor of the resection. At this point, the inferior flap is advanced systematically and segmentally (Figure 10D) up to the committed line, and excess skin is determined, marked, and incised. Each excised segment is temporarily closed with staples. (Figure 10E).

Closure

Once the basics of symmetry and hemostasis are confirmed to be appropriate, the closure of the arm is done to reduce tension on the scar and also to alleviate the need for

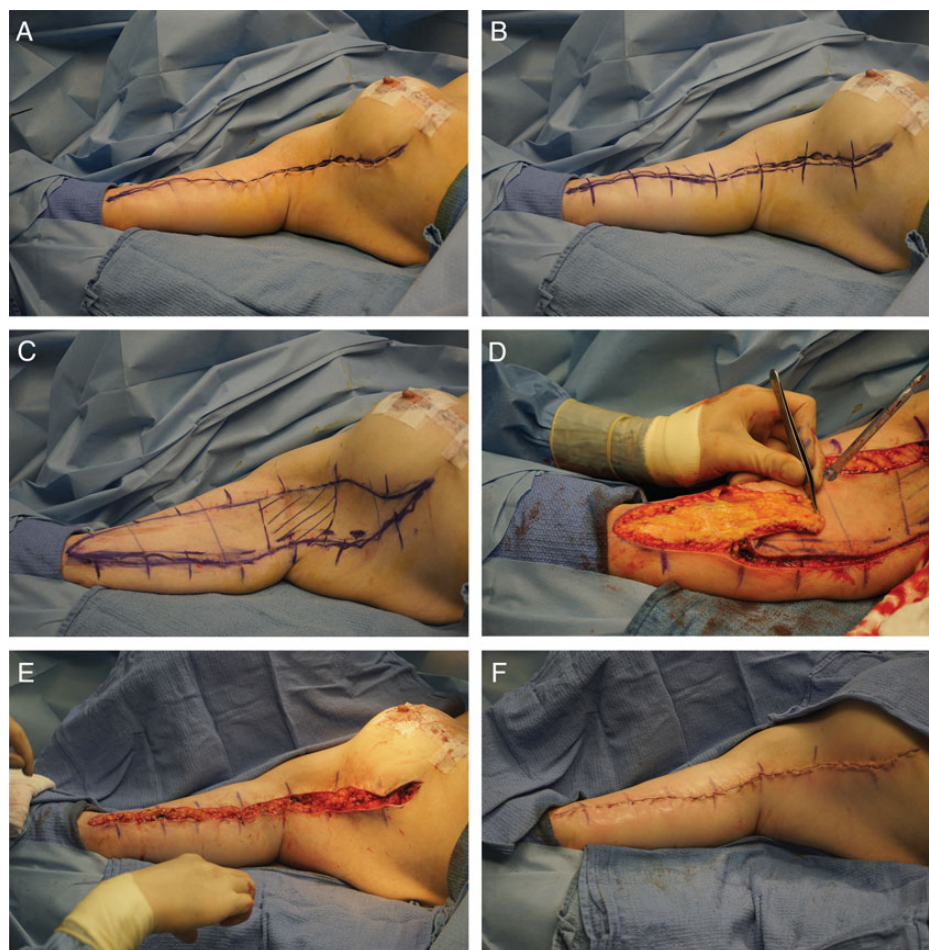


Figure 8. A 52-year-old woman undergoing intraoperative staple technique. (A) Using the proposed scar and committed line as reference, the excess skin is grasped and stapled from distal to proximal. (B) Marking lines are placed outside of the staple line. (C) Completed markings are inspected making certain that the axillary area (diagonal cross-hatching) is marked for a more superficial dissection. (D) The adipocutaneous paddle is elevated off the brachial fascia. (E) Superficial fascia and (F) skin are closed.

drains. The approximation of the SFS of the arm has long been considered as important,⁶ if not more so, as any other closure of an anatomic region of the body. This fascial layer can be thin, especially if there is significant lipodystrophy. It is imperative to use caution identifying, preserving, and using this layer in this closure. The 3-pointed closure is a technique that grabs the SFS of the upper and lower resection lines, and includes the floor of the brachial fascia to eliminate any dead space (Figure 11). Long-term absorbing polydioxanone sutures are used either in interrupted manner or in a running barbed suture of equivalent composition and size for a continuous closure (Figure 8E). The author has determined that by using this closure, drains become unnecessary. Also, the strength of this closure reduces the tension on the eventual reapproximation of the scar. The superficial layers are also closed with long-term absorbing polydioxanone sutures, and eventually a superficial layer of a running barbed Monocryl suture

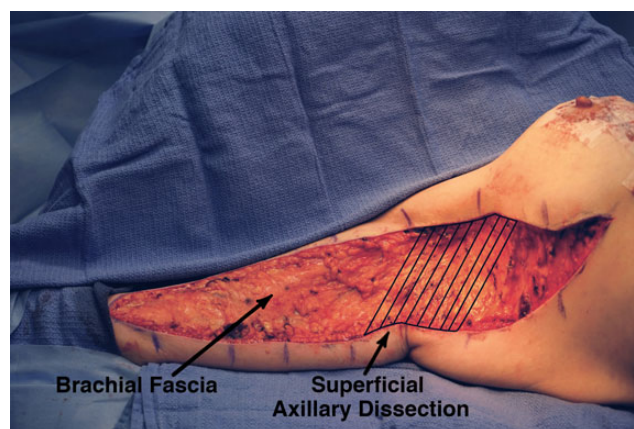


Figure 9. Completed resection in a 52 year-old-woman. The floor of the resection, the brachial fascia, is robust and uninterrupted. This protects the important sensory and lymphatic structures and serves as the base of the 3-point suture. The axillary fossa is maintained with a superficial dissection.

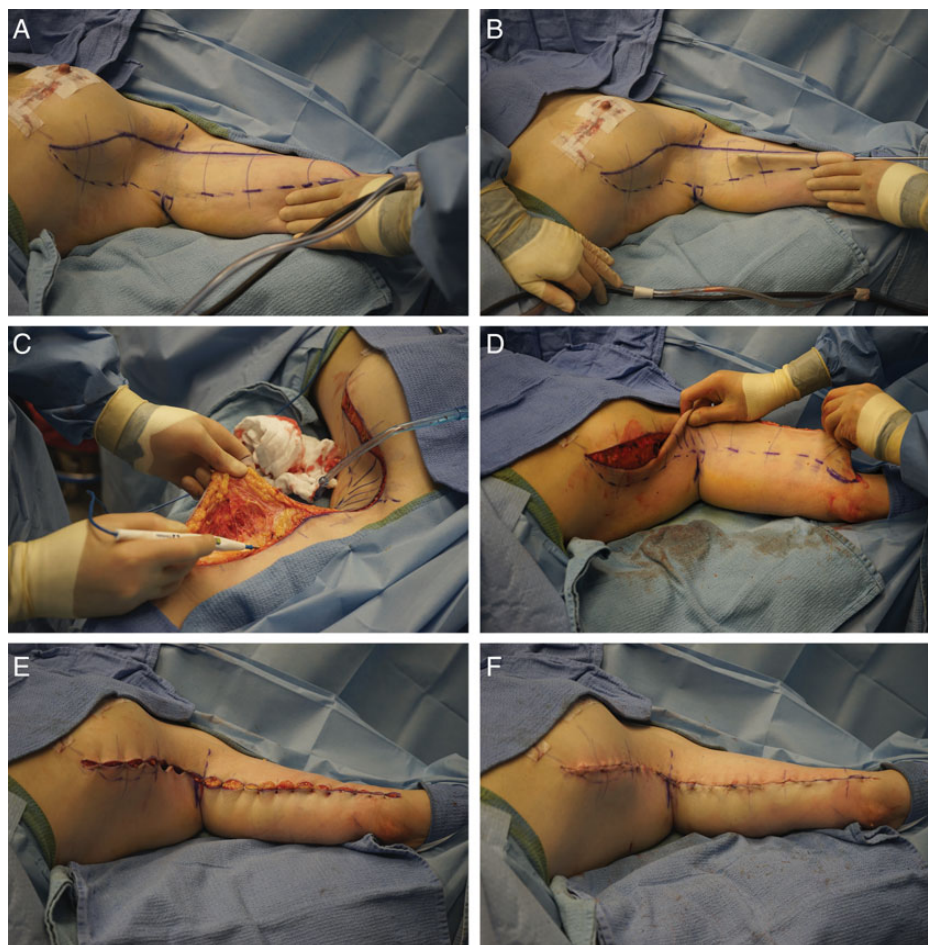


Figure 10. 52-year-old woman undergoing the resection and closure technique. This technique often involves suction-assisted lipectomy (SAL). (A) Standard wetting solution is infiltrated and SAL performed as deemed necessary. (B) The proposed area of excision, as deemed by our markings preoperatively, undergoes aggressive liposuction to a point that the cannula can be visible. (C) Once the committed line incision is deepened, an inferior retraction leads to the pocket of liposuction and allows for quick and bloodless dissection. (D) Segmental superior transfer of the inferior flap allows for determination an accurate extent of excision. (E) Superficial fascia is closed using the 3-point suture technique. (F) Skin closure.

(Figures 8F and 10F). As scar widening and thickening is a significant sequella of brachioplasty, meticulous low-tension closure is paramount to and a prerequisite of a good outcome. The strength of SFS closure and the use of long-absorbing sutures are important variables in the quest for adequate results.

Anatomy and Cutaneous Nerves

Avoiding the medial brachial cutaneous nerve (MBCN) and the medial antebrachial cutaneous nerve (MABCN) has been the subject of anatomic studies and a point of attention for brachioplasty performance.⁷ MBCN derives from T1-2, and MABCN takes its origin from C8-T1 (Figure 12). The course the nerve leads is superficial, as two to three branches are sent to the skin 7 cm proximal to the medial

epicondyle. Other branches innervate the skin at about 15 cm proximal to the medial epicondyle.⁷ The injury to these nerves can cause sensory disturbances of the mid arm to forearm and significant paresthesia and dysesthesia for the patient. It is important to understand the anatomy of this region and hence avoid injury to these nerves. Leaving a healthy and robust brachial fascia is imperative for avoiding these cutaneous nerves. Given its more anterior course, it is also prudent to avoid placing the scar anteriorly and using the already described posterior-medial position.

POSTOPERATIVE CARE

The immediate postoperative care includes placing Steri-Strips on the skin and compressing with a bolero garment. Patients are instructed not to bend at the elbow for the first

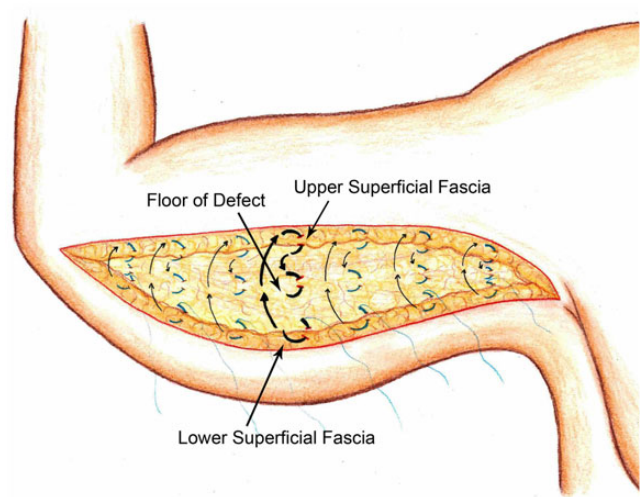


Figure 11. Illustration of the 3-pointed closure. The upper and lower superficial fascia are approximated with incorporating the floor of the defect as the third point. This is carried out through the entire closure and has alleviated the need for drain use.

24 hours and are highly encouraged not to engage in any strenuous activity for the first 2 weeks after the operation. They are all cautioned that edema is certain and are instructed to avoid wearing rings or any compressive ornaments for the first 2 weeks after the operation.

Regular postoperative visits start a regimented program of scar care. For the first 2 weeks, the scar is covered with Steri-Strips. This is then replaced with Micropore brown tape for another week. At this point, a rest period from any coverage will determine the integrity of the scar and lack of any wound separation or eschar formation. Once this is determined, silicon strips are placed on the incision and compressed. It is recommended that the patient continue with the silicone regimen for at least 4 months after the procedure. Patients who are not compliant with the silicone compression are given a commercially available silicone spray that has shown some promise in the group of patients treated.

Stretching the arm into a full arm raise and manual massage are also important instructions that are given to patients postoperatively.

RESULTS

During a 12-year period (2002-2014), the author performed 123 brachioplasties. All patients were females. The average age of the patient was 47.9 years (range, 23-73 years). Average BMI was 28.2 kg/m² (range, 18.9-46.9 kg/m²). The complication rate was 4.1%. The most common

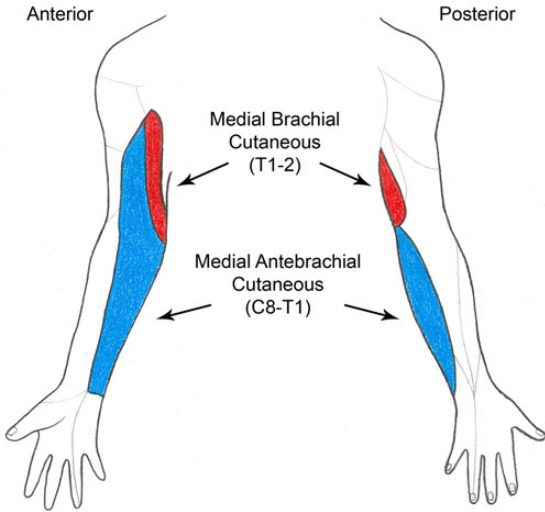


Figure 12. Schematic description of the important sensory nerves, medial brachial cutaneous nerve (MBCN) and medial antebrachial cutaneous nerve (MABCN). Understanding the origin and the anatomic course of these neural structures has underscored the importance of scar placement in a more posterior position, and preservation of the overlying and protective brachial fascia.

Table 2. Complications (n = 123)

Complication	Number
Wound Dehiscence	4 (3.3%)
Seroma	1 (0.8%)
Total	5 (4.1%)

complication was wound separation (Table 2). Reoperative rate was 5.7%. Four of these reoperations were scar revisions and 3 patients were operated on for recurrent laxity. Standard brachioplasty was the most common variant of the four classified procedures (Figures 13-15). Eighty-six patients (70%) underwent resection and closure technique, and 37 patients (30%) underwent intraoperative staple approximation technique. The mean follow-up time was 4.5 months (range, 4 weeks-5 years).

DISCUSSION

The extraordinary rise of brachioplasty continues to be an important part of addressing the total solution for massive weight loss patients. This also has trickled into non-weight loss patients who desire a more toned arm. The complexity of the position of arms and their proximity to the lateral chest wall, upper back, and even breast makes this an operation that requires proper patient selection, a thoughtful marking approach, and a safe and effective operative strategy.

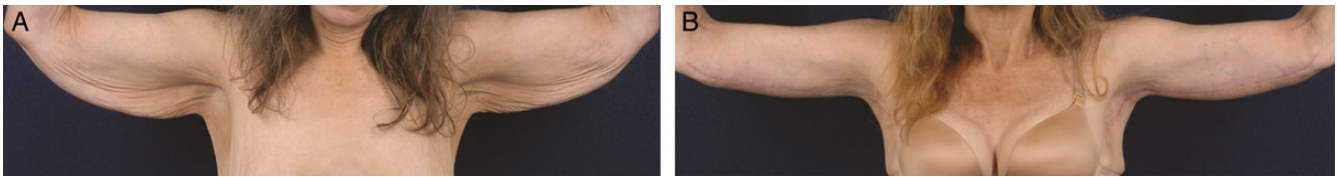


Figure 13. (A) This is a 58-year-old woman with a history of 150-pound weight loss. (B) She is shown 6 months after a standard brachioplasty with some extension into the axilla.

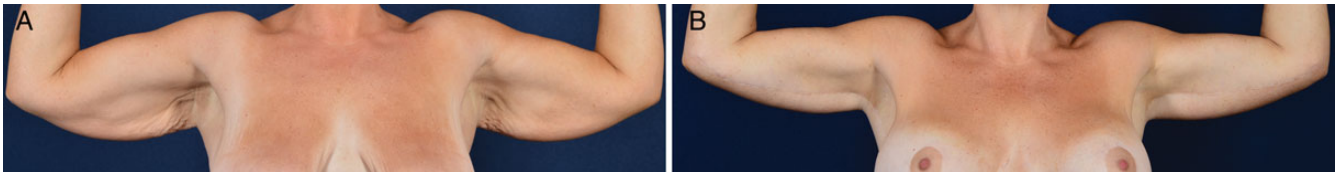


Figure 14. (A) This is a 46-year-old woman with a history of 150-pound weight loss. (B) She is shown 1 year after a brachioplasty with lateral chest wall extension.

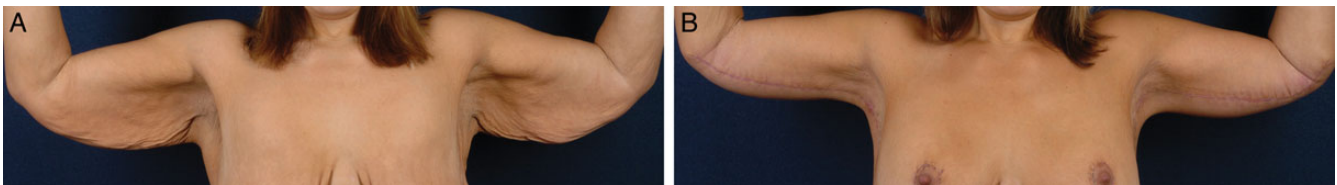


Figure 15. (A) This is a 36-year-old woman with a history of 250-pound weight loss. (B) She is shown 6 months after an extensive brachioplasty, involving the lateral chest wall.

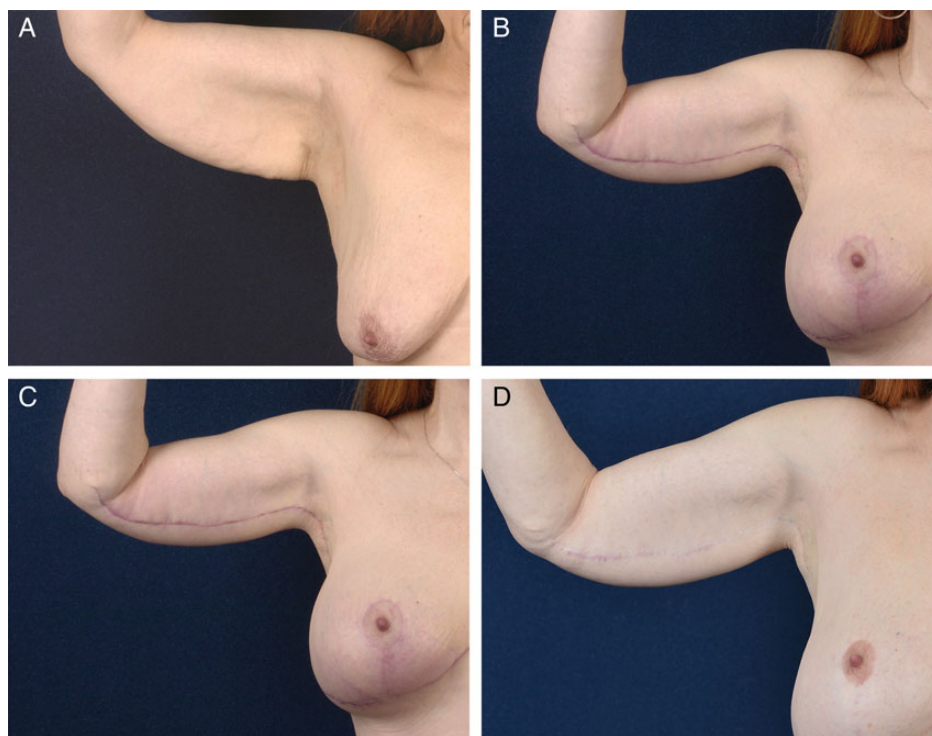


Figure 16. (A) This is a 47-year-old woman presented with massive weight loss. (B) Scar shown 3 months after an extensive brachioplasty. (C) Scar shown at 7 months. (D) She is now shown 3 years after the procedure with significant maturity and fading of the scar.

There have been myriad of different techniques described on the management of arm excess skin. From classical descriptions^{8,9} to some of the modern evolving methods, the goal has been to emphasize an appropriate contour, well-positioned scars, and management of the excess associated not only to the arm but also the chest wall. Hurwitz¹⁰ described the L brachioplasty that preserves the contour of the axilla by creating an exaggerated anteriorly projecting point to the turn into the chest wall. He also describes the importance of extension into the upper chest wall. This anteriorly oriented apex can however be more easily exposed than the turn that is described in this report. Gusenoff¹¹ described a similar technique, also emphasizing segmental rapid resection due to fear of progressive edema and difficulty of closure. They designed their resection so it ends up in the bicipital groove at a higher position to that which has been described in this report. They have also cautioned against injury to the sensory nerves and have suggested finding them in proximity to the basilic vein. Others have described the effectiveness of concomitant liposuction during arm recontouring. Bossert¹² analyzed a prospective experience and determined that liposuction can be performed safely at the time of brachioplasty, and has similar complication rate than the excisional-only group.

The techniques described in this report allow intraoperative adaptability and improvisation, and allow rapid closure. Aly and Soliman^{13,14} described a similar segmental resection closure technique and cautioned about the edema that can pose risk in closure. They also described the use of staple closure to assess the feasibility and appropriateness of the amount of excision. These techniques prevent unnecessary and prolonged manipulation of the skin and the flaps and permit rapid closure, and hence reduce the dangerous possibility of a difficult re-approximation due to such edema.

Even with the significant rise in frequency and experience that the field of plastic surgery has gained in regards

to this operation, there are limitations that are worthy of discussion. The scar of the brachioplasty is one that is prone to widening and hypertrophic transformation. The exposed area of the inner arm cannot be easily hidden and can be a source of significant dissatisfaction for the patient and the practitioner. It is imperative to warn the patient of the reality of an unsightly scar. It is also important to realize that time is an essential ally in the fight with the scar. The brachioplasty scar does not follow some of the usual patterns of scars in the face and body that start to mature and fade at 3 to 4 months. Patients are advised that this scar has a timeline that in the authors experience can run a year or so before evolving and maturing into a stable scar (Figure 16). Significant restraint against the use of steroid injections is advised as the scars can further widen and a subcutaneous thinning can occur under the scar. The previously mentioned use of taping, compression, and silicone sheeting with patience is recommended. Only in severe cases are the scars revised with no guarantee that similar deformity will not recur.

As with other approaches in body contouring, the longevity of results are limited. In arm recontouring, especially in the massive weight loss population, recurrence of laxity is yet another reality (Figure 17). The ever-moving arm and the dependent circular skin sleeve that covers it are prone to laxity and redundancy. Again, appropriate preoperative counseling with the patient, as well as the establishment of reasonable expectations, will prevent future dissatisfaction. Secondary operations and revisions must be an important part of the discussion.

Certain anatomic features of the arm are difficult to treat. Distal elbow lipodystrophy can be resistant and can linger after a well-executed brachioplasty (Figure 18A). Occasionally, resilient restrictive bands of the midline of the arm cannot be fully corrected, despite the best of attempts. These tend to linger after resection and closure (Figure 18B).

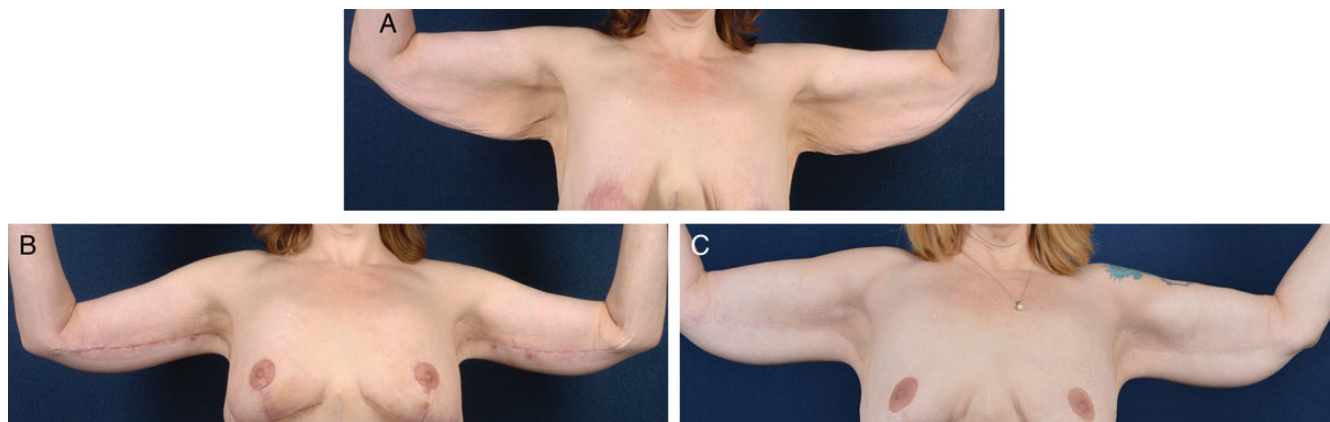


Figure 17. (A) This is a 40-year-old woman with history of 125-pound weight loss. (B) She is shown here at 4 months after the operation with adequate results and appropriate skin tightening. (C) At 3 years, the patient has a significant recurrence of her arm excess skin.

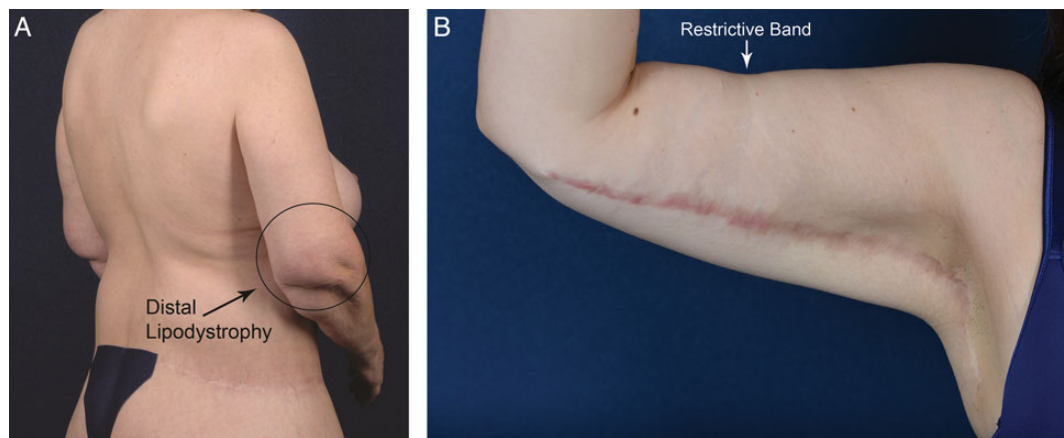


Figure 18. Demonstration of troublesome and resilient (A) posterior elbow distal lipodystrophy in a 62 year-old woman, and (B) mid arm restrictive bands in a 32-year-old woman.

Many of these are due to inherent presentation of the patient. Occasionally, a tight closure in one segment of the excision can simulate this constrictive band. As a result of the control that both described techniques provide, such iatrogenic banding rarely occurs. Such limitations must also be discussed with the patient.

CONCLUSION

The demand for brachioplasty continues to rise in the plastic surgery specialty. Knowledge of the anatomic translation of this procedure has made this a reproducible and effective operation. With appropriate planning, marking, and operative execution, along with knowledge of postoperative care, brachioplasty can be a gratifying operation despite some inherent limitations.

Supplementary Material

This article contains supplementary material located online at www.aestheticsurgeryjournal.com.

Acknowledgment

The author would like to acknowledge Norma Cervantes, CST, whose presence in the operating room is complemented by her artistry in medical illustrations.

Disclosures

The author declared no potential conflicts of interest with respect to the research, authorship, and publication of this article.

Funding

The author received no financial support for the research, authorship, and publication of this article.

REFERENCES

1. Cosmetic Surgery National Data Bank Statistics. *Aesthet Surg J*. 2015;35(suppl 2):1-24.
2. Correa-Iturraspe M, Fernandez JC. Brachial dermolipectomy [Article in Spanish]. *Prensa Med Argent*. 1954;41(34):2432-2436.
3. Appelt EA, Janis JE, Rohrich RJ. An algorithmic approach to upper arm contouring. *Plast Reconstr Surg*. 2006;118(1):237-246.
4. El Khatib HA. Classification of brachial ptosis: strategy for treatment. *Plast Reconstr Surg*. 2007;119(4):1337-1342.
5. Zomerlei TA, Neaman KC, Armstrong SD, et al. Brachioplasty outcomes: a review of a multipractice cohort. *Plast Reconstr Surg*. 2013;131(4):883-889.
6. Lockwood T. Brachioplasty with superficial fascial system suspension. *Plast Reconstr Surg*. 1995;96(4):912-920.
7. Chowdhry S, Elston JB, Lefkowitz T, Wilhelmi BJ. Avoiding the medial brachial cutaneous nerve in brachioplasty: an anatomical study. *Eplasty*. 2010;10:e16.
8. Regnault P. Brachioplasty, axilloplasty, and pre-axilloplasty. *Aesthetic Plast Surg*. 1983;7(1):31-36.
9. Pitangy I. Correction of lipodystrophy of the lateral thoracic aspect and inner side of the arm and elbow dermosenescence. *Clin Plast Surg*. 1975;2(3):477-483.
10. Hurwitz DJ, Holland SW. The L brachioplasty: an innovative approach to correct excess tissue of the upper arm, axilla, and lateral chest. *Plast Reconstr Surg*. 2006;117(2):403-411.
11. Gusenoff JA, Coon D, Rubin JP. Brachioplasty and concomitant procedures after massive weight loss: a statistical analysis from a prospective registry. *Plast Reconstr Surg*. 2008;122(2):595-603.
12. Bossert RP, Dreifuss S, Coon D, et al. Liposuction of the arm concurrent with brachioplasty in the massive weight loss patient: is it safe? *Plast Reconstr Surg*. 2013;131(2):357-365.
13. Aly A, Soliman S, Cram A. Brachioplasty in the massive weight loss patient. *Clin Plast Surg*. 2008;35(1):141-147.
14. Aly A, Pace D, Cram A. Brachioplasty in the patient with massive weight loss. *Aesthet Surg J*. 2006;26(1):76-84.