

Case report

## Laparoscopic cholecystectomy in a patient with an implantable left ventricular assist device

V. Kartha\*, W. Gomez, B. Wu and K. Tremper

Department of Anesthesiology, University of Michigan Hospitals, Ann Arbor, MI, USA

\*Corresponding author. E-mail: drvinda@yahoo.com

Left ventricular assist devices (LVADs) provide mechanical support for left ventricular ejection in the failing heart. We describe the anaesthetic management of a patient with an LVAD requiring laparoscopic cholecystectomy. A 51-yr-old female patient with severe heart disease had a Heartmate II LVAD implanted 4 months before this proposed elective surgery. Maintaining haemodynamic stability in the perioperative period is essential in such patients. The case was managed successfully using invasive monitoring and anaesthesia with sevoflurane and remifentanyl. The potential problems in management of patients with LVADs are highlighted and discussed. A team approach is essential.

*Br J Anaesth* 2008; **100**: 652–5

**Keywords:** anaesthesia, general; equipment, circulatory support devices; heart failure; heart-assist devices; surgery, abdominal

Accepted for publication: January 24, 2008

Left ventricular assist devices (LVADs) provide mechanical support for left ventricular ejection in the failing heart and have now become an accepted treatment for end-stage heart failure. This has now been proven to be a successful bridge to heart transplantation and as its popularity grows, the number of patients with LVADs presenting for non-cardiac surgery is increasing. We describe the anaesthetic management of a patient with an LVAD requiring laparoscopic cholecystectomy.

### Case report

A 51-yr-old ASA IV (65 kg, height 156 cm) female patient with an LVAD awaiting heart transplantation was undergoing an elective laparoscopic cholecystectomy. She had a significant medical history of hypertension, previous myocardial infarction, mitral, aortic and tricuspid valvular disease, paroxysmal atrial fibrillation, non-ischaemic cardiomyopathy, congestive heart failure, transient ischaemic attacks, and chronic renal insufficiency. She had a mitral valve replacement with a mechanical valve 9 yr previously and had a biventricular pacemaker–defibrillator implanted 1 yr ago.

Recently, the patient had developed congestive heart failure secondary to non-ischaemic cardiomyopathy. Transthoracic echocardiogram revealed bi-atrial and

bi-ventricular enlargement, severely impaired bi-ventricular systolic function, with a left ventricular ejection fraction of 15%. Aortic and tricuspid regurgitation were also present. She underwent an aortic and tricuspid valve replacement and a Heartmate II LVAD was implanted 4 months before this proposed elective surgery. Concurrent medical therapy included digoxin, lisinopril, metoprolol, spironolactone, furosemide, potassium chloride, magnesium oxide, warfarin, aspirin, dipyridamole, pentoxifylline, pantoprazole, and losartan.

After LVAD placement, she had marked improvement in her heart failure symptoms. Her exercise tolerance improved and she could walk up to 6 miles a day. Meanwhile, she was advised to undergo cholecystectomy for symptomatic cholelithiasis. Ultrasound scan of abdomen showed several calculi in the gall bladder without evidence of cholecystitis. Liver function tests demonstrated normal bilirubin and minimal elevation of enzymes. A preoperative transthoracic echocardiogram displayed a hypokinetic left ventricle associated with septal and wall akinesia and an ejection fraction of 10–15%.

The patient's cardiac surgeon was contacted before the surgery. He advised the general surgeons regarding the entry ports for laparoscopy so as to avoid disruption of the drive line which ran horizontally across the upper abdomen. She was started on i.v. heparin 3 days before

surgery and warfarin was discontinued. The planned anaesthetic management included an arterial line inserted before induction of anaesthesia, and central venous pressure (CVP) monitoring, even though uneventful laparoscopic procedures do not cause major shifts in the intravascular volume. Intraoperative echocardiography was available if needed, and a cardiothoracic anaesthetist who was aware of the case was on stand by.

On the day of surgery, the patient arrived at the pre-operative area accompanied by the LVAD nurse. The patient appeared comfortable, was not dyspnoeic, and was able to complete sentences without difficulty. The LVAD was checked and the battery back-up tested to counter intraoperative power failure. The non-invasive arterial pressure reading was 75 mm Hg systolic, 65 mm Hg diastolic with a mean arterial pressure (MAP) of 68 mm Hg and the oxygen saturation, 100% on room air. Good venous access was established with a 14 G cannula and she was given midazolam 2 mg for anxiolysis. Arterial cannulation was difficult as peripheral pulses were not palpable and Doppler guidance was required to cannulate the right radial artery. The arterial pressure recorded by invasive monitoring was 78/56 mm Hg (MAP 63 mm Hg) and heart rate was 76–80 beats  $\text{min}^{-1}$ . The LVAD was switched over to a fixed mode and connected to the mains supply on arrival to the operating room. The pump was run at a speed of 9600 rpm with a pulsatile index of 4.4 and a flow of 4.6 litre  $\text{min}^{-1}$ .

Before induction of anaesthesia, 1000 ml of Ringer's lactate solution was infused which increased her arterial pressure to 85/60 mm Hg (MAP 68 mm Hg). After adequate pre-oxygenation, anaesthesia was induced with fentanyl 200  $\mu\text{g}$ , lidocaine 60 mg, and propofol 20 mg followed by rocuronium, which induced skeletal muscle paralysis after confirming loss of response to verbal commands. After an atraumatic laryngoscopy (Grade 1), the trachea was intubated using a 7 mm cuffed oral endotracheal tube. There were no notable haemodynamic fluctuations after induction of anaesthesia. An oesophageal temperature probe was placed and a five lumen pulmonary artery catheter was placed via the right internal jugular vein with a 9 F introducer under ultrasound guidance and minimal Trendelenburg (CVP 8–10 cm of water). The skin incisions were made by the surgeons as planned. A staged and limited pneumoperitoneum (up to 15 mm Hg) was created to avoid haemodynamic fluctuations. Reverse Trendelenburg position was instituted gradually and was tolerated well by the patient. Bipolar cautery was used for the procedure and the grounding pad was placed on her right thigh. Anaesthesia was maintained with oxygen, air, and sevoflurane (VT 500 ml,  $f$  10  $\text{min}^{-1}$ ,  $I:E$  1:2) along with a titrated i.v. infusion of remifentanyl.

The surgery was uneventful and the patient remained haemodynamically stable throughout the procedure. After a smooth emergence from anaesthesia and reversal of

neuromuscular block, her trachea was extubated without any adverse events. The patient was then transferred to the post-anaesthesia recovery unit with the LVAD on battery back-up, accompanied by the LVAD nurse and the anaesthesia team. After 2 days of uneventful stay in the Surgical intensive care unit, the patient was discharged home with instructions to continue her medications till she gets called back in for the heart transplantation.

## Discussion

Mechanical support of the cardiovascular system has become an important tool in the treatment for patients with congestive heart failure. LVADs are used as a 'bridge to transplant' in patients with refractory end-stage heart failure<sup>1,2</sup> and as a 'bridge to recovery' in patients with cardiomyopathy.<sup>3</sup> A number of ongoing clinical trials are evaluating the efficacy of LVADs as an alternative to heart transplant ('destination therapy').<sup>1</sup> Randomized Evaluation of Mechanical Assistance for the Treatment of Congestive Heart failure (REMATCH) trial has shown that an implantable LVAD prolongs and enhances the quality of life in heart failure patients.<sup>4,5</sup> This haemodynamic restoration therapy has increased the 1 and 2 yr survival rates compared with pharmacological interventions alone.<sup>6–8</sup> There is also evidence that NYHA Class IV patients improve to NYHA

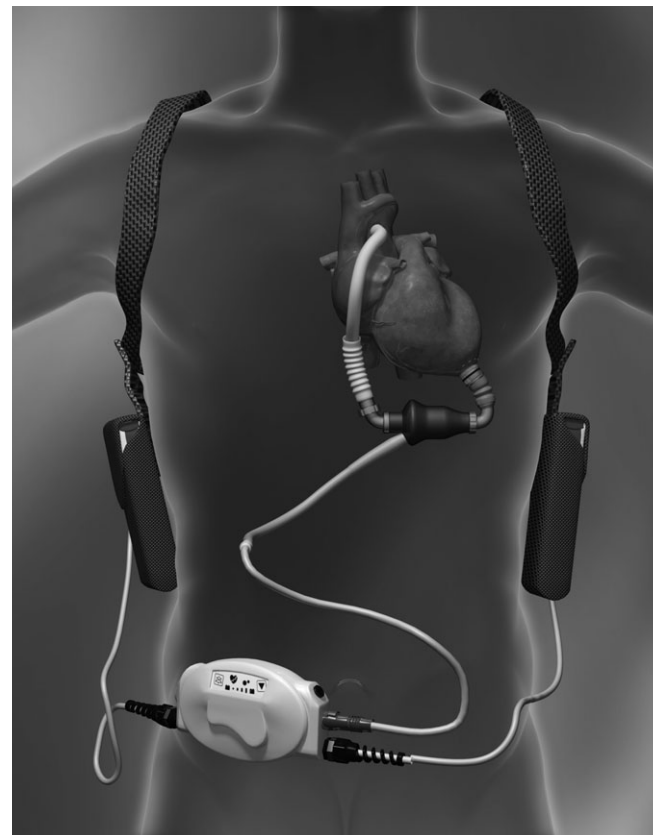


Fig 1 HeartMateII LVAD.

Class I or II post-LVAD treatment.<sup>9</sup> This turnaround will lead to an increase in the number of patients with LVADs coming in for non-cardiac elective or emergency surgery.<sup>10</sup>

The LVAD device used here (HeartMate II, Thoratec) is implanted below the heart (Fig. 1) and its functions are similar to that of the left ventricle. It drains blood from the left ventricle into a mechanical pump which then ejects the blood via a conduit that links to the ascending aorta.<sup>1</sup> The pump is driven by a small electric motor and the rotary action of the single moving part is capable of pumping up to 10 litre min<sup>-1</sup> of blood. The LVAD is normally powered electrically and can be connected to two rechargeable batteries worn in a waist pack, which could last for up to 3 h. The blood flow generated by the LVAD is non-pulsatile and for this reason these patients require anticoagulation. Although the heart continues to beat at its own rhythm, the left ventricle usually remains volume under-loaded and may not contribute significantly to the aortic outflow.<sup>1</sup>

Chronic LVAD therapy has been found to reverse the progression of heart failure. It restores both the arterial pressure and the cardiac output to near normal values and relieves the symptoms of heart failure.<sup>1 11 12</sup> It also improves hepatic and renal function, reflecting better end organ perfusion.<sup>1 11</sup> The left ventricular geometry improves and this favours 'reverse remodelling' which in turn increases the chamber compliance and reduces myocardial damage.<sup>1</sup> LVAD therapy also reverses the neuroendocrine and inflammatory responses to heart failure, markedly reducing plasma concentrations of renin, angiotensin II, epinephrine, norepinephrine, atrial natriuretic peptide, arginine vasopressin, and interleukin-6 and 8.<sup>1</sup> This has led to improved exercise tolerance and patients getting involved in active exercise programmes. As a result, these patients present for non-cardiac operations in a better physiological condition when compared with patients with severe heart failure who are not on LVAD therapy.

Four aspects have to be considered in the management of patients with LVADs presenting for non-cardiac surgery: (i) LVAD specialists, (ii) power supply and electromagnetic interference, (iii) haemodynamics, and (iv) anticoagulation.

The anaesthetist caring for the patient should identify the 'LVAD team' (cardiothoracic surgeons, nurses, engineers, and cardiopulmonary perfusionists).<sup>1 13 14</sup> They are responsible for the management of these patients and provide a valuable source of information. LVADs have to be connected to the mains supply once the patient reaches the operating room. The device is prone to alteration by electromagnetic interference such as electrocautery<sup>1 13 14</sup> or a defibrillator.<sup>13</sup> Bipolar cautery should be used when possible<sup>1</sup> and the grounding pad placed to facilitate current dispersion away from the device.

The pumping mechanism of the LVAD depends on both preload and afterload.<sup>1</sup> These devices do not obey Starling's law with respect to stroke volume or stroke work, and can only pump the delivered volume and

therefore inadequate filling leads to inadequate flow. Factors which lead to decreased preload such as drug-induced venodilatation, dehydration, lateral decubitus or reverse Trendelenburg positioning, and haemorrhage can decrease pump flow.<sup>1 13 14</sup> Therefore, invasive monitoring using a central venous or pulmonary artery catheter or transoesophageal echocardiography is indicated for procedures in which significant alterations in the intravascular volume is anticipated.

Elevation in afterload reduces the LVAD output<sup>1</sup> which promotes stasis of blood and thereby increases the risk of thrombus formation even when the patient is anticoagulated. Systemic responses to laryngoscopy and surgical stimulus should be attenuated and avoidance of hypertension should be the primary aim in the perioperative management of these patients. Maintenance of preload and afterload provides an adequate cardiac output and, in the absence of hypertension, most patients respond to volume expansion.<sup>1 13</sup>

Factors that increase pulmonary vascular resistance and reduce right ventricular output (e.g. hypoxia, hypercarbia, and acidosis) can cause low LVAD output. In addition, negative inotropic drugs (e.g. volatile anaesthetic agents, beta blockers, and calcium channel blockers) should be used with caution. Low LVAD output with progressive increase in CVP suggests right ventricular dysfunction which may require positive inodilators (e.g. milrinone) or selective pulmonary vasodilators (e.g. inhaled nitric oxide).

LVAD patients normally require long-term anticoagulation with warfarin which should be converted to i.v. heparin therapy before elective surgery.<sup>14 15</sup> Heparin should be discontinued on the day of surgery and then re-started after operation.

Cardiopulmonary resuscitation may dislodge or disturb the device causing bleeding, especially in the anticoagulated patient. It is also important to note that pulse pressure values are narrow when rotary devices are used and the pulse may not be palpable.

The significant improvement in effort tolerance and functional capacity induced by the use of LVADs means that patients can lead a near normal life in their own domestic surroundings. It is likely that anaesthetists will encounter patients with LVADs more frequently in the future and effective team work is the key to safe outcome.

## Acknowledgement

We thank Thoratec Corporation for providing technical information and permission to use the LVAD picture.

## References

- 1 Nicolosi AC, Pagel PS. Perioperative considerations in the patient with a LVAD. *Anesthesiology* 2003; **98**: 565–70
- 2 Morgan JA, John R, Rao V, et al. Bridging to transplant with the HeartMate left ventricular assist device: The Columbia

- Presbyterian 12-year experience. *J Thorac Cardiovasc Surg* 2004; **127**: 1309–16
- 3 Gaunt A. Anaesthesia for cardiothoracic transplantation and ventricular assist devices. *Anaesth Intensive Care Med* 2006; **7**: 317–20
  - 4 Stone ME, Soong W, Krol M, et al. The anesthetic considerations in patients with ventricular assist devices presenting for noncardiac surgery: a review of eight cases. *Anesth Analg* 2002; **95**: 42–9
  - 5 Koul B, Solem JO, Steen S, et al. HeartMate left ventricular assist device as bridge to heart transplantation. *Ann Thorac Surg* 1998; **65**: 1625–30
  - 6 Butler KC, Farrar DJ. Long-term reliability testing of the Heartmate II LVAD. *ASAIO J* 2005; **51**: 32A
  - 7 Rose EA, Gelijns AC, Moskowitz AJ, et al. Long-term mechanical left ventricular assistance for end-stage heart failure. *N Engl J Med* 2001; **345**: 1435–43
  - 8 Oz MC, Argenziano M, Catanese KA, et al. Bridge experience with long-term implantable left ventricular assist devices. Are they an alternative to transplantation? *Circulation* 1997; **95**: 1844–52
  - 9 Kormos RL, Strueber M, Frazier OH, et al. HeartMate II axial flow left ventricular assist device: suitability for advanced congestive heart failure. *ASAIO J* 2007; **53**: 310–5
  - 10 Eckhauser AE, Melvin WV, Sharp KW. Management of general surgical problems in patients with left ventricular assist devices. *Am Surg* 2006; **72**: 158–61
  - 11 McCarthy PM, Savage RM, Fraser CD, et al. Hemodynamic and physiologic changes during support with an implantable left ventricular assist device. *J Thorac Cardiovasc Surg* 1995; **109**: 409–17
  - 12 McCarthy PM, James KB, Savage R, et al. Implantable left ventricular assist device. Approaching an alternative for end-stage heart failure. Implantable LVAD study group. *Circulation* 1994; **90**: 1183–6
  - 13 Goldstein DJ, Mullis SL, Delphin ES, et al. Noncardiac surgery in long-term implantable left ventricular assist-device recipients. *Ann Surg* 1995; **222**: 203–7
  - 14 El-Magharbel I. Ventricular assist devices and anesthesia. *Semin Cardiothorac Vasc Anesth* 2005; **9**: 241
  - 15 Schmid C, Wilhelm M, Dietl KH, et al. Noncardiac surgery in patients with left ventricular assist devices. *Surgery* 2001; **129**: 440–4