

REGIONAL ANAESTHESIA

Effect of local anaesthetic volume (20 vs 5 ml) on the efficacy and respiratory consequences of ultrasound-guided interscalene brachial plexus block

S. Riazi¹, N. Carmichael¹, I. Awad¹, R. M. Holtby² and C. J. L. McCartney^{1*}

¹Department of Anesthesia and ²Department of Orthopedic Surgery, Sunnybrook Health Sciences Center, University of Toronto, 2075 Bayview Avenue, Toronto, Ontario, Canada M4N 3M5

*Corresponding author. E-mail: colin.mccartney@utoronto.ca

Background. Interscalene brachial plexus block (ISBPB) is an effective nerve block for shoulder surgery. However, a 100% incidence of phrenic nerve palsy limits the application of ISBPB for patients with limited pulmonary reserve. We examined the incidence of phrenic nerve palsy with a low-volume ISBPB compared with a standard-volume technique both guided by ultrasound.

Methods. Forty patients undergoing shoulder surgery were randomized to receive an ultrasound-guided ISBPB of either 5 or 20 ml ropivacaine 0.5%. General anaesthesia was standardized. Both groups were assessed for respiratory function by sonographic diaphragmatic assessment and spirometry before and after receiving ISBPB, and after surgery. Motor and sensory block, pain, sleep quality, and analgesic consumption were additional outcomes. Statistical comparison of continuous variables was analysed using one-way analysis of variance and Student's *t*-test. Non-continuous variables were analysed using χ^2 tests. Statistical significance was assumed at $P < 0.05$.

Results. The incidence of diaphragmatic paralysis was significantly lower in the low-volume group compared with the standard-volume group (45% vs 100%). Reduction in forced expiratory volume in 1 s, forced vital capacity, and peak expiratory flow at 30 min after the block was also significantly less in the low-volume group. In addition, there was a significantly greater decrease in postoperative oxygen saturation in the standard-volume group (-5.85 vs -1.50 , $P = 0.004$) after surgery. There were no significant differences in pain scores, sleep quality, and total morphine consumption up to 24 h after surgery.

Conclusions. The use of low-volume ultrasound-guided ISBPB is associated with fewer respiratory and other complications with no change in postoperative analgesia compared with the standard-volume technique.

Br J Anaesth 2008; **101**: 549–56

Keywords: anaesthetic techniques, regional, brachial plexus; analgesics, postoperative; complications, respiratory

Accepted for publication: July 4, 2008

Interscalene brachial plexus block (ISBPB) is one of the most reliable and commonly performed techniques for regional anaesthesia of the upper extremity. It anaesthetizes the caudal portion of the cervical plexus (C3, C4) and the superior (C5, C6) and middle (C7) trunks of the brachial plexus. ISBPB is associated with a number of

complications,¹ but the most common is phrenic nerve palsy, which occurs in 100% of patients using current techniques.² The phrenic nerve arises chiefly from the C4 root, with variable contributions from C3 and C5. It is formed at the upper lateral border of the anterior scalene muscle and courses caudally between the ventral surface

of the anterior scalene muscle and prevertebral fascial layer that covers this muscle, therefore separated from the brachial plexus only by a thin fascial layer. As a result, its block in ISBPB can be explained by the proximity to the brachial plexus or to the cephalad spread of local anaesthetic to the C3–5 roots of the cervical plexus before their formation of the phrenic nerve.

Phrenic nerve block is associated with significant reductions in ventilatory function including a 21–34% decrease in forced vital capacity (FVC), 17–37% decrease in forced expiratory volume in 1 s (FEV₁), and 15.4% decrease in peak expiratory flow rate (PEFR).³ Therefore, ventilation can be compromised by ISBPB which restricts the use of this block in patients with limited pulmonary reserve such as those with chronic obstructive pulmonary disease (COPD), the morbidly obese, or the elderly.

Previous efforts to determine the minimum effective local anaesthetic dose for ISBPB with the least decrease in hemidiaphragmatic function demonstrated a dose–response relationship. In a previous volunteer study, hemidiaphragmatic paresis occurred in 80% of subjects who received bupivacaine 0.5% (10 ml) and only in 17% of those who received bupivacaine 0.25%.⁴ Ultrasonography (US) can be used to identify brachial plexus anatomy, guide needle placement, and visualize local anaesthetic spread.⁵ This technique may improve correct placement of local anaesthetic and minimize complications because individual nerves can be more effectively located and lower volumes of local anaesthetic directed around the target structure. In turn, this may decrease the unintentional spread of local anaesthetic to the phrenic nerve. In this study, we hypothesized that by reducing local anaesthetic volume during ultrasound-guided interscalene block, it is possible to reduce the incidence, severity, or both of phrenic nerve block without sacrificing quality or duration of analgesia after shoulder surgery.

Methods

After institutional research ethics board approval and written informed consent, 40 patients undergoing right-sided shoulder surgery were recruited to this double-blind, randomized controlled trial. Inclusion criteria were age ≥ 18 and ≤ 80 yr, ASA I–III, and BMI < 35 . Exclusion criteria included pre-existing COPD, unstable asthma, psychiatric history, renal or hepatic impairment, allergy to ropivacaine, and opioid tolerance (> 30 mg oral morphine or equivalent per day).

Patients were randomized using a computer-generated randomization sequence and using sealed, opaque envelopes to two groups, receiving an ultrasound-guided posterior approach ISBPB of either 5 or 20 ml of ropivacaine 0.5%. The patients and research assistant assessing the block success and diaphragmatic function were blinded to the treatment allocation.

After applying routine monitors including electrocardiography (ECG), non-invasive arterial pressure, and pulse

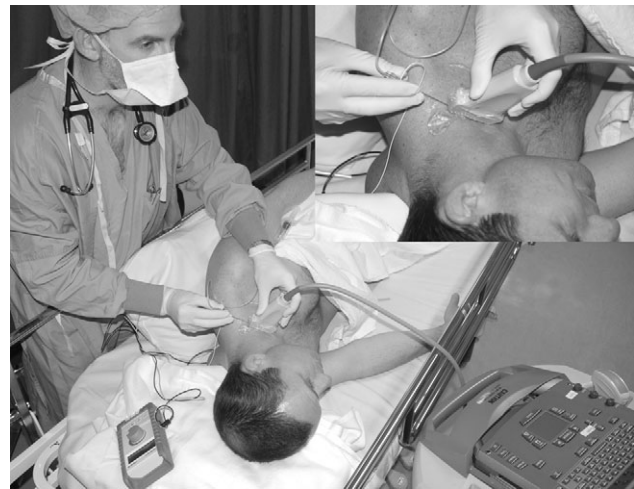

Fig 1 Patient and probe/needle position for ultrasound-guided ISBPB as used in the present study. The anaesthetist can stand or sit in a relaxed position facing the ultrasound screen with the arm holding the ultrasound probe resting on the patient's shoulder whereas the other hand is free either to position the needle or to inject local anaesthetic.

oximetry, i.v. access was established in the contralateral arm, with an infusion of saline 0.9% at a maintenance rate. Patients were given oxygen 6 litre min^{-1} via facemask, i.v. midazolam 0.03 mg kg^{-1} for sedation, oral celecoxib 400 mg, and oral acetaminophen 1000 mg as part of the standardized care for shoulder surgery patients.

Patients were positioned in the left semilateral position with the neck extended to facilitate performance of US ISBPB (Fig. 1). After sterile skin preparation with chlorhexidine and skin infiltration with lidocaine 1%, US ISBPB was performed. A 5 cm 22 G insulated needle (B. Braun Medical Inc., Bethlehem, PA, USA) was inserted in-line with the ultrasound probe in the transverse plane (Fig. 1). An Advanced Technology Lab (ATL) 2–13 MHz probe was used to visualize the brachial plexus (Fig. 2) using a Philips HD11 XE ultrasound machine (Philips Medical Systems, Bothell, WA, USA). The two outermost nerve roots (C5 and C6) between the anterior and the middle scalene muscles were further confirmed by identification with nerve stimulation (frequency 2 Hz, pulse width 0.1 ms, and increasing current from 0.1 to 1 mA or until motor stimulation of the deltoid or biceps muscle was noted) (Portex Tracer III, Keene, NH, USA). The local anaesthetic was then injected, so that spread was seen immediately posterior to or between the C5 and the C6 nerve roots.

After the performance of ISBPB and initial assessment, patients were taken to the operating theatre where they were given a general anaesthetic using a standardized protocol, consisting of propofol 2–2.5 mg kg^{-1} and fentanyl 1 $\mu\text{g kg}^{-1}$. Rocuronium 0.6–0.8 mg kg^{-1} was used for patients requiring endotracheal intubation. The airway was maintained either with a laryngeal mask airway or tracheal tube and the lungs were ventilated with oxygen–nitrous

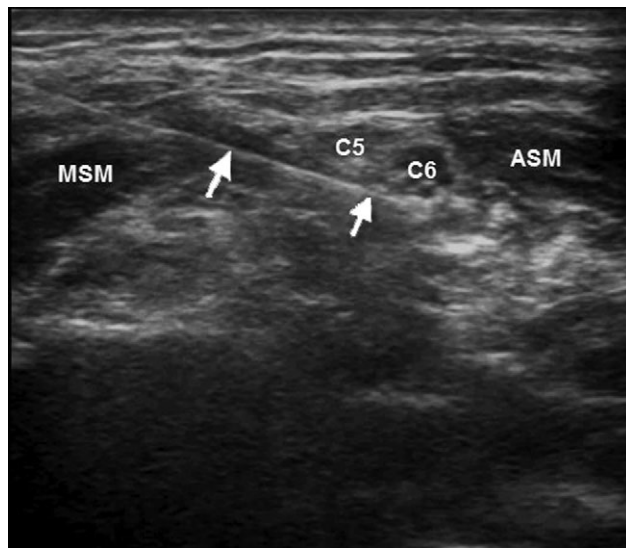


Fig 2 Sonogram of the interscalene area at the C7 level. The needle approach is from the lateral aspect through the middle scalene muscle (ASM, anterior scalene muscle; MSM, middle scalene muscle; C5, C5 nerve root; C6, C6 nerve root). At this level, the C5 and C6 roots can commonly be seen to join to form the superior trunk of brachial plexus.

oxide 40–60%. Anaesthesia was maintained with sevoflurane 1–2%. Residual paralysis was antagonized at the end of the procedure with neostigmine $40 \mu\text{g kg}^{-1}$, and glycopyrrolate $7 \mu\text{g kg}^{-1}$ if necessary. Patients were given further intraoperative i.v. fentanyl $25 \mu\text{g}$ if heart rate or arterial pressure increased more than 25% above pre-induction baseline values. No intra-articular local anaesthetics were injected.

Diaphragmatic excursion was assessed by real-time US of the ipsilateral hemidiaphragm at the cephalad border of the zone of apposition (Zap) of the diaphragm to the costal margin between the midclavicular and the anterior axillary lines. An ATL 2–5 MHz curvilinear probe was used to visualize the diaphragm using a Philips HD11 XE ultrasound machine (Philips Medical Systems). All assessments were performed with the patient in the supine position during quiet inspiration, deep inspiration, and forceful sniff. Diaphragmatic movement was assessed both in B mode and in M mode settings. Normal inspiratory caudad diaphragmatic excursion is designated as positive (+) motion, and paradoxical cephalad motion as negative (–) motion.³ Each test was performed three times. Bedside spirometry using a compact spirometer (Spirolab III, Medical International Research) was performed with patients lying in a 45° semi-recumbent position, and after instruction on how to perform the test, FVC, FEV₁, and PEFR measurements were performed three times and the values were averaged. Sensation of the upper extremity was assessed by pinprick using a 23 G needle testing from C4 to T1 dermatomes and scored as full sensation=1 and loss of sensation to touch or pinprick=0. Motor power assessment of the deltoid, biceps, triceps, finger flexion (median), finger

extension (radial), and finger abduction (ulnar) was scored as movement present=1 and no movement present=0. All of the above assessments (diaphragmatic excursion, spirometry, sensory, and motor assessment) were done at baseline (pre-block), 10, 20, and 30 min post-block, and 30, 60, 120, and 180 min after completion of surgery.

Patients were instructed to rate their pain using an 11-point verbal rating scale (VRS) ranging from 0 to 10 (0, no pain; 10, worst imaginable pain). VRS was measured at 30, 60, 120, and 180 min, at 22:00 on the evening of surgery and 24 h after surgery. Quality of sleep on the first postoperative night was also measured and assessed by difficulty sleeping (yes/no) and wake-up frequency. Patients in recovery room were allowed i.v. morphine 2–5 mg for pain or 1–2 tablets of a compound preparation of codeine 30 mg and acetaminophen 500 mg or oxycodone 5 mg and acetaminophen 500 mg. After discharge from recovery room, patients were allowed 1–2 tablets of a compound preparation of codeine 30 mg and acetaminophen 500 mg or oxycodone 5 mg and acetaminophen 500 mg every 4 h for pain if required. All opioid doses for total dose in recovery room and total dose in the first 24 h after discharge from recovery room were converted to oral morphine equivalents for ease of analysis.⁶ Analgesia was given on patient request or if VAS >3 (moderate–severe pain). Patients who were discharged the same day (37 patients) were given a diary to complete and were also contacted at home 24 h later to complete pain, analgesic consumption, sleep, and satisfaction data.

The primary outcome measure was diaphragmatic movement 30 min after ISBPB. Secondary outcomes included spirometric measures, motor/sensory block onset and duration, VRS for pain, other side-effects including Horner's syndrome, hoarseness, analgesic-related adverse effects, patient satisfaction with analgesia, and sleep quality on the first postoperative night.

Statistical comparison of baseline ipsilateral hemidiaphragmatic excursion with post-block excursion was tested using a χ^2 test. Baseline spirometric values with measures post-ISBPB were tested using one-way analysis of variance (ANOVA) and further defined using Student's *t*-test. VRS and other continuous variables were also analysed using one-way ANOVA and Student's *t*-test. Non-normally distributed and ordinal variables were analysed using non-parametric ANOVA and Mann–Whitney *U*-test. Other non-continuous variables were analysed using χ^2 tests.

The study sample size was estimated assuming a reduction in decrease of spirometric values using the proposed low-volume US ISBPB technique. Estimates from Al-Kaisy and colleagues⁴ demonstrated a reduction in decrease of FVC from 74.6% of normal to 86.6% of normal with reduction in dose from bupivacaine 0.5% (10 cc) to bupivacaine 0.25% (10 cc). We estimated a similar or larger reduction in diaphragmatic dysfunction with our lower dose of ropivacaine 0.5% (5 ml). In order to determine a reduction from normal in diaphragmatic

dysfunction as measured by FVC from 75% to 87% with $\alpha=0.05$ and $\beta=0.8$, we estimated that we required 19 patients per group.

Results

Between July and December 2007, 40 patients were randomized to Group 1 ($n=20$, low volume) or Group 2 ($n=20$, standard volume). The flow diagram of patients approached, consented, and recruited is shown in Figure 3. There were no differences in patient characteristics between Group 1 and Group 2 (Table 1).

Baseline diaphragmatic movement was similar and normal in all patients. Thirty minutes after ISBPB, paradoxical (negative) diaphragmatic movement was seen in all (100%) of the standard-volume group and 45% of the low-volume group ($P<0.05$). There was a significant reduction in lung volumes (FVC, FEV1, and PEF) at 30 min post-ISBPB in the standard-volume group when compared with the low-volume group (-1.59 vs -0.70 litre; -1.23 vs -0.60 litre; -2.50 vs -0.83 litre min^{-1}). Post-operative oxygen saturation decrease was also significantly greater (-5.85% vs -1.5%) in the standard-volume group (Table 2). One patient in the standard-volume group developed respiratory distress after ISBPB, with a decrease in oxygen saturation to 80% requiring high flow oxygen (50%) via Hudson mask. This patient was not able to perform bedside spirometric measurements after ISBPB.

Pain score (VRS) measured at 30, 60, 120 min, 12, and 24 h after surgery and also total morphine-equivalent consumption in the recovery room and in the first 24 h after surgery were similar in both groups. Sleep quality, wake-up frequency because of pain, and satisfaction scores were all similar in both groups (Table 3). One patient in the low-volume group required a supplementary superficial cervical plexus block after surgery for severe (VRS 10) pain in an incision in the C4 distribution. The postoperative analgesic data in this patient were excluded from further analysis after the rescue block. The patient had a VRS of 0 after the rescue block, which would have biased the pain scores in the low-volume group.

Sensory and motor block onset and extent of block is depicted in Figures 4 and 5. There was a significantly slower onset of loss of pinprick sensation in the C4 distribution in the low-volume group, but no other differences in sensory onset. Patients in the standard-volume group had significantly greater loss of pinprick sensation in C4 and C5 distribution at 30 and 60 min after surgery. In the standard-volume group, there was significantly faster onset of motor block in biceps and triceps. After surgery, significantly more patients in the standard-volume group experienced motor block of biceps, triceps, and median nerve function (finger flexion).

Eight patients in the standard-volume and no patients in the low-volume group developed post-block complications. In the standard-volume group, one patient suffered

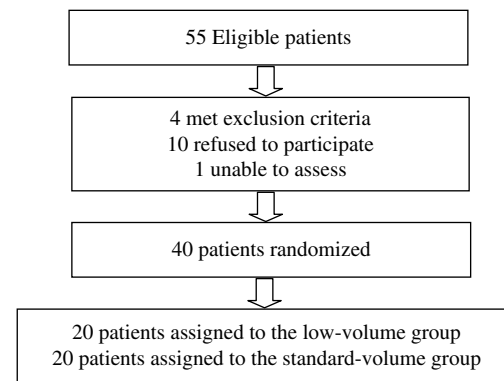


Fig 3 Patient flow through the study.

Table 1 Patient characteristics

	Group I: low volume	Group II: standard volume	Significance
Age, mean (range) (yr)	51.9 (18–68)	57.6 (41–80)	NS
Gender (F/M)	9/11	9/11	NS
Weight, mean (SD) (kg)	77.65 (20.40)	83.60 (19.35)	NS
Height, mean (SD) (cm)	168.65 (11.6)	171.30 (10.0)	NS
Surgical duration (min)	153.75 (44.3)	138.85 (56.5)	NS
ASA I/II/III	7/12/1	5/12/3	NS
Surgical procedures			
Acromioplasty	4	5	NS
Arthroscopic rotator cuff decompression	3	2	NS
Arthroscopic rotator cuff repair	9	9	NS
Open rotator cuff repair	4	4	NS

hypoxia and respiratory distress, three patients developed ipsilateral Horner's syndrome, three patients developed post-block hoarseness, and one patient developed hiccups lasting for 3 days.

Discussion

The results of this study demonstrate that administration of a low-volume ISBPB under ultrasound guidance decreases the incidence of hemidiaphragmatic paresis and preserves respiratory function while providing equivalent analgesia when compared with a standard-volume ultrasound-guided technique. In addition, other adverse effects related to interscalene block such as Horner's syndrome and voice hoarseness only developed in the standard-volume group. Therefore, a low-volume of local anaesthetic administered under ultrasound guidance can improve the overall safety without any decrease in the efficacy of ISBPB.

Ultrasound-guided nerve blocks allow direct visualization of target nerves, adjacent anatomical structures, and needle position. As a result, the spread of local anaesthetic around target nerves can be assessed and more precisely administered at the correct location. In this study, ultrasound allowed us to visualize the brachial plexus at the

Table 2 Respiratory function and adverse outcomes post-ISBPB

	Group I: low volume, mean (sd)	Group II: standard volume, mean (sd)	Significance
Paralysed diaphragm at 30 min post-block	9/20	20/20	$P<0.05$
Paralysed diaphragm at 60 min post-surgery	6/18	18/20	$P<0.05$
Change in FVC at 30 min post-block (litre)	-0.70 (0.70)	-1.59 (0.68)	$P<0.05$
Change in FEV ₁ at 30 min post-block (litre)	-0.60 (0.54)	-1.23 (0.61)	$P<0.05$
Change in PEF at 30 min post-block (litre min ⁻¹)	-0.83 (1.01)	-2.50 (1.61)	$P<0.05$
Oxygen saturation pre-block (%)	97.3 (0.92)	97.5 (1.58)	$P=0.3$
Oxygen saturation 30 min post-surgery (%) on air	95.8	91.7	$P=0.003$
Change in oxygen saturation	-1.50 (3.13)	-5.85 (3.78)	$P<0.0001$
Adverse outcomes	0	8 (Horner's syndrome: 3, hoarseness: 3, severe respiratory distress: 1, hiccups: 1)	$P<0.05$

Table 3 Pain scores, analgesic consumption, sleep quality, and satisfaction. Pain scores were from 0 to 10 (0, no pain), satisfaction scores were from 0 to 10 (0, not satisfied). *Including patient with pain in the C4 distribution (VAS10) requiring rescue superficial cervical plexus block. †Including patient who required rescue superficial cervical plexus block

	Group I: low volume	Group II: standard volume	Significance
Pain score 30 min post-surgery, mean (sd)*	1.1 (2.8) range: 0–10	0.3 (1.4) range: 0–6	NS
Pain score 60 min post-surgery, mean (sd)	1.1 (2) range: 0–6	1 (2.1) range: 0–6	NS
Pain score 120 min post-surgery	0.5 (1.1)	1.3 (2.2)	NS
Pain score 12 h post-surgery	3.4 (2.8) range: 0–8	3.1 (2.53) range: 0–6	NS
Pain score 24 h post-surgery	3.6 (2.3) range: 0–7	4.7 (2.9) range: 0–10	NS
Difficulty sleeping	7/20	10/20	NS
Wake-up frequency, mean (sd)	0.8 (1.4)	1.7 (1.9)	NS
Satisfaction score, mean (sd)	8.5 (1.6)	7.1 (2.9)	NS
Intraoperative fentanyl (µg)	140.3 (40.3)	107.5 (61.3)	NS
Total morphine (oral) equivalent consumption in recovery room (mg), mean (sd)	2.9 (6.9)	1.3 (4.6)	NS
Number of patients requiring analgesics in recovery room†	5	3	NS
Total morphine equivalent consumption (oral) in first 24 h after surgery (after discharge from recovery room) (mg), mean (sd)	23.3 (17.4)	26.5 (13.6)	NS

interscalene groove (lateral approach; needle insertion through the middle scalene) and administer a lower volume of local anaesthetic at the C5 and C6 nerve roots. This resulted in a lower incidence of phrenic nerve palsy (45% at 30 min post-block) and better preservation of respiratory function in terms of greater FEV₁, FVC, PEF, and oxygen saturation compared with the standard-volume group. Furthermore, analgesia was similar between the two groups indicating that ropivacaine 0.5% (5 ml) can spread sufficiently to anaesthetize the shoulder while sparing the phrenic nerve. Therefore, these findings provide evidence in support of the use of low-volume local anaesthetic for ISBPB for shoulder surgery.

Avoidance of diaphragmatic dysfunction after ISBPB is of benefit to all patients undergoing shoulder surgery, especially those with obesity or respiratory disease. Obese patients are predisposed to osteoarthritis and therefore may be overrepresented in patients presenting for shoulder surgery.⁷ If ISBPB is avoided, the postoperative opioid administration, pain, or both also place these patients at risk of respiratory complications. A low volume of local anaesthetic would allow ISBPB to be performed in these patients reducing compromise in lung function without decreasing analgesic effect. Reduction of total local anaesthetic dose also reduces risk of morbidity associated with intravascular injection. There has been at least one case report⁸ of local anaesthetic toxicity in ISBPB with injection

of ropivacaine 0.3% (25 ml) with epinephrine 2.5 µg ml⁻¹. Any dose reduction while maintaining analgesic properties would be valuable to all patients.

Although one patient in the low-volume group in this study required rescue analgesia, this was because the incision site was in the C4 distribution, which is outside the normal distribution of sensation for the shoulder joint (C5/6). Our recommendation is that if the surgeon intends to place an incision in the C4 area, then a superficial cervical plexus block should be performed in addition to an ISBPB. More easily, the surgeon could infiltrate the surgical incision site with local anaesthetic, preferably before incision.

This is the first randomized controlled trial demonstrating that a lower volume of local anaesthetic in an ultrasound-guided ISBPB is associated with improved respiratory function while providing effective analgesia compared with a standard-volume technique. We found that 100% of patients receiving standard volumes of local anaesthetic for ISBPB experienced hemidiaphragmatic paresis and reduced lung function. In this study, the decrease in respiratory function led to a significantly greater reduction in oxygen saturation (SpO₂) in the high-volume group. This finding is consistent with a previous study that also found 100% hemidiaphragmatic paresis and a 25% reduction in FVC and FEV₁ using mepivacaine 1.5% (34–52 ml) for ISBPB.³ Although our findings indicate that the incidence of hemidiaphragmatic paresis was

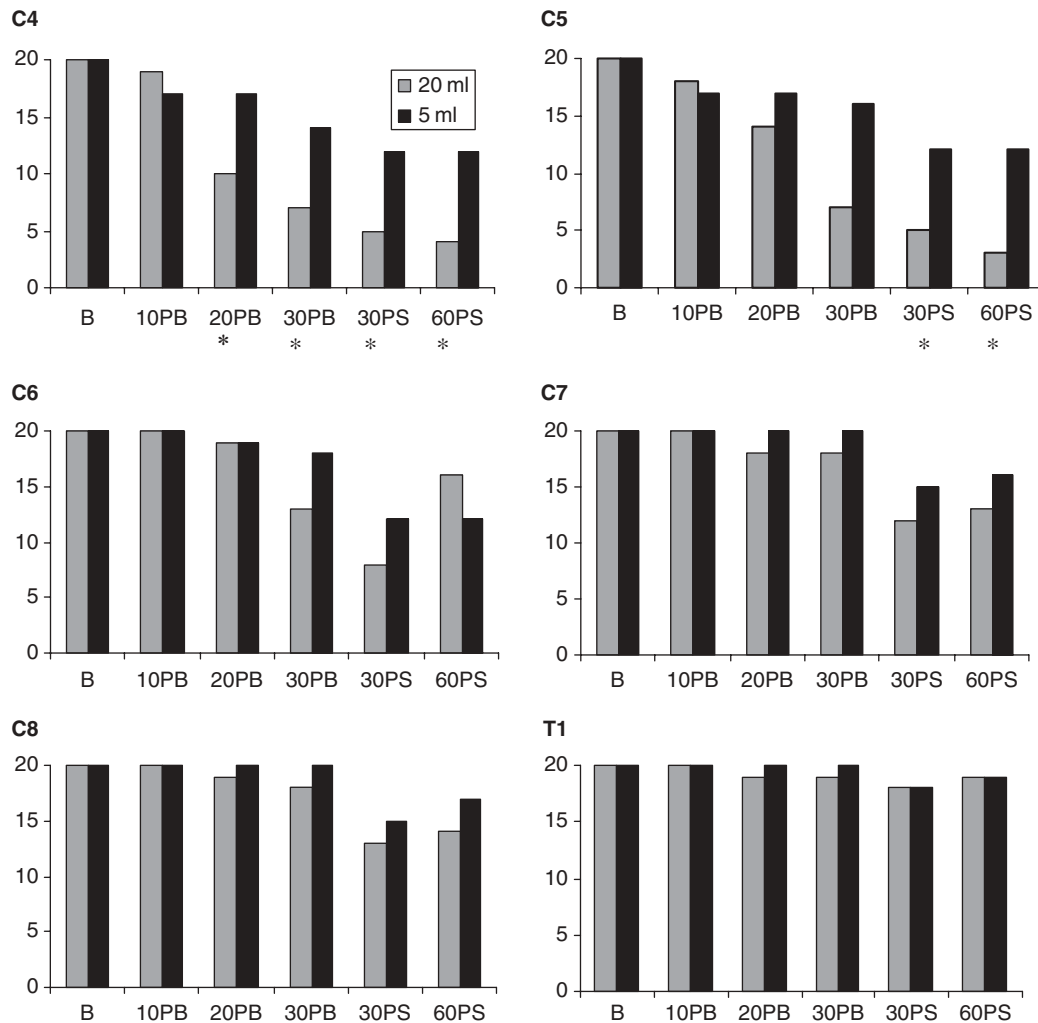


Fig 4 Number of patients with full sensation at baseline, after block placement, and after surgery. B, baseline; 10PB, 10 min post-block; 20PB, 20 min post-block; 30PB, 30 min post-block; 30PS, 30 min post-surgery; 60PS, 60 min post-surgery. *Significant difference in loss of sensation to pinprick between the groups.

significantly lower with ropivacaine (5 ml), it nevertheless can still occur. We found that 45% (9 out of 20) of the low-volume group still experienced phrenic nerve palsy 30 min after block completion.

This study adds to the data of Al-Kaisy and colleagues⁴ who documented a reduction in respiratory dysfunction in a volunteer population randomized to either 10 ml of 0.5% or 0.25% bupivacaine. Our results are distinguished by using a lower volume of local anaesthetic (aided by a precise ultrasound-guided technique) and also, in contrast to Al-Kaisy and colleagues, we have demonstrated these benefits in a population undergoing painful shoulder surgery. A further demonstrated benefit of the low-volume technique is a significant reduction in motor block in the forearm and hand after surgery. In our study, patients in the low-volume group had significantly increased power in biceps, triceps, and finger flexion after surgery. Although patients appreciate the profound analgesia from standard interscalene techniques, many also complain about the prolonged motor block after surgery. Though our

differences in patient satisfaction did not reach statistical significance, the trend towards greater satisfaction (mean 8.5 vs 7.1) in the low-volume group may have reflected the reduction in motor block. It is also interesting to note that despite the lack of difference in pain scores or analgesic consumption between the groups that patients in the standard-volume group had significantly reduced sensation to pinprick in the C4 and C5 distribution after surgery and that if anything these patients should have experienced less pain after surgery.

This study has a number of limitations. First, it should be noted that without ultrasound, we do not know if a 5 ml volume of local anaesthetic is sufficient for interscalene block. The ultrasound approach allowed for a precise deposition of local anaesthetic around the C5/6 nerve roots and the posterior approach through the middle scalene muscle may help to prevent anterior spread to the phrenic nerve. Secondly, although the incidence and duration of phrenic paresis can be reduced with a low-volume ultrasound-guided technique, it cannot be avoided entirely; therefore,

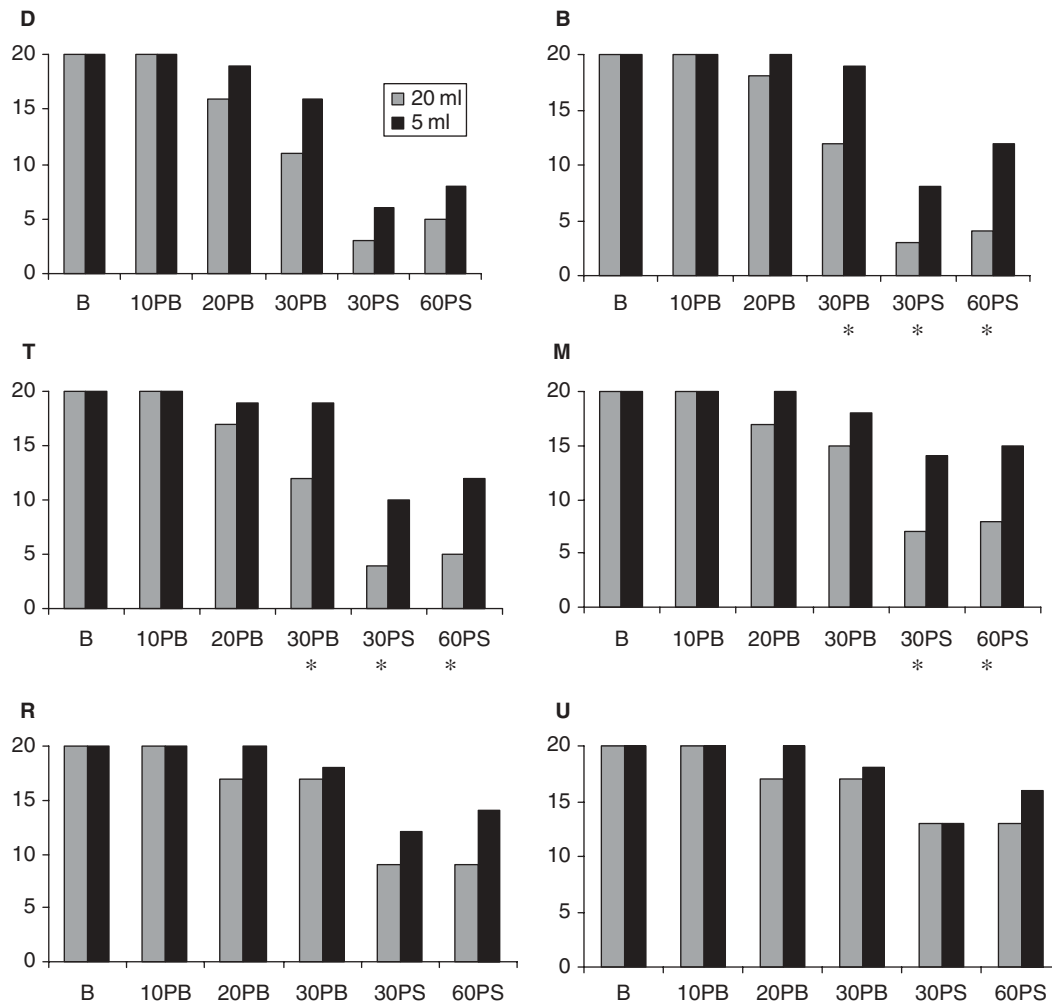


Fig 5 Number of patients with preservation of movement in each muscle group. D, deltoid; B, biceps; T, triceps; M, finger flexion (median); R, finger extension (radial); U, finger abduction (ulnar). B, baseline; 10PB, 10 min post-block; 20PB, 20 min post-block; 30PB, 30 min post-block; 30PS, 30 min post-surgery; 60PS, 60 min post-surgery. *Significant difference in ability to move between the groups.

caution should be used, especially if a patient has a contralateral pre-existing phrenic paresis. Some of our respiratory parameters may have been influenced both by the sedation administered before ISBPB placement and by the effect of recovery from general anaesthesia, including residual neuromuscular block after surgery. However, although 35 of 40 patients received rocuronium for endotracheal intubation, in this study, there were more patients with tracheal intubation in the low-volume group (19 vs 16) compared with the high-volume group. If anything, therefore, there would have been more tendency towards residual curarization in the low-volume group, even though no clinical evidence was seen of any skeletal muscle weakness (other than in the blocked arm) in any patient.

Finally, although the study randomization was blinded, both to patients and to assessor, the anaesthetist performing the block was not blinded to volume injected and this could arguably have influenced needle placement during the block. However, this effect, if anything, should favour the standard (20 ml) volume group because there would

have been much more opportunity in this group to correct any perceived maldistribution of local anaesthetic spread by moving the needle tip during the block.

In conclusion, this study found that the use of a low-volume ultrasound-guided ISBPB is associated with a lower incidence of phrenic nerve palsy and other block-related complications while maintaining effective analgesia compared with a standard-volume technique. This technique may allow patients at higher risk of postoperative respiratory complications to undergo ISBPB for shoulder surgery and benefit from the profound analgesia that it can provide with a significantly decreased risk of respiratory complications.

Funding

This study was supported by a Grant from the Physicians' Services Incorporated Foundation (PSI), Toronto, Ontario, Canada.

References

- 1 Brown AR, Weiss R, Greenberg C, Flatow EL, Bigliani LU. Interscalene block for shoulder arthroscopy: comparison with general anesthesia. *Arthroscopy* 1993; **9**: 295–300
- 2 Urmey WF, Talts KH, Sharrock NE. One hundred percent incidence of hemidiaphragmatic paresis associated with interscalene brachial plexus anesthesia as diagnosed by ultrasonography. *Anesth Analg* 1991; **72**: 498–503
- 3 Urmey WF, McDonald M. Hemidiaphragmatic paresis during interscalene brachial plexus block: effects on pulmonary function and chest wall mechanics. *Anesth Analg* 1992; **74**: 352–7
- 4 Al-Kaisy AA, Chan VWS, Perlas A. Respiratory effects of low-dose bupivacaine interscalene block. *Br J Anaesth* 1999; **82**: 217–20
- 5 Chan VWS. Applying ultrasound imaging to interscalene brachial plexus block. *Reg Anesth Pain Med* 2003; **28**: 340–3
- 6 Canadian Pharmacists Association. *Compendium of Pharmaceuticals and Specialties*, 9th Edn. Ottawa: Webcom Inc., 2008; 537
- 7 Wearing SC, Henning EM, Byrne NM, Steele JR, Hills AP. Musculoskeletal disorders associated with obesity: a biomechanical perspective. *Obes Rev* 2006; **7**: 239–50
- 8 Dhir S, Ganapathy S, Lindsay P, Athwal GS. Ropivacaine neurotoxicity at clinical doses in interscalene brachial plexus block. *Can J Anaesth* 2007; **54**: 912–6