

PAEDIATRICS

Practical anatomic landmarks for determining the insertion depth of central venous catheter in paediatric patients

H. S. Na¹, J. T. Kim^{2*}, H. S. Kim², J. H. Bahk², C. S. Kim² and S. D. Kim²

¹Department of Anesthesiology and Pain Medicine, Seoul National University Bundang Hospital, Seongnam, Gyeonggi, Republic of Korea. ²Department of Anesthesiology and Pain Medicine, Seoul National University Hospital, 101 Daehakno, Jongnogu, Seoul 110-744, Republic of Korea

*Corresponding author. E-mail: kimjintae73@dreamwiz.com

Background. Various methods have been recommended to decide a proper insertion depth of central venous catheter (CVC). The carina is recommended as a useful target level for the CVC tip position. We evaluated the sternal head of a right clavicle and the nipples as anatomic landmarks for determining the optimal depth of CVC in paediatric patients.

Methods. Ninety children, <5 yr, undergoing catheterization through the right internal jugular vein were enrolled. The insertion depth was determined as follows. The insertion point was designated as 'Point I'. The sternal head of the right clavicle was called 'Point A' and the midpoint of the perpendicular line drawn from Point A to the line connecting both nipples was called 'Point B'. The insertion depth of CVC was determined by adding the two distances (from I to A and from A to B) and subtracting 0.5 cm from this. A chest radiography was taken and the distance of the CVC tip from the carina level was measured by the Picture Archiving and Communicating System.

Results. The mean distance of the CVC tip from the carina level was 0.1 (1.0) ($P=0.293$) cm above the carina (95% CI 0.1 cm below the carina–0.3 cm above the carina). There was no specific relationship between the distance of the CVC tip from the carina level and the patients' age, height, and weight.

Conclusions. The CVC tip could be placed near the carina by using the external landmarks without any formulae, images, and devices in children in our study.

Br J Anaesth 2009; **102**: 820–3

Keywords: anaesthesia, paediatric; anatomy, jugular vein; veins, jugular, cannulation

Accepted for publication: February 26, 2009

A central venous catheter (CVC) is inserted to measure central venous pressure (CVP) and also to administer drugs or fluid in the perioperative period. The CVC tip has been recommended to be placed just above the superior vena cava–right atrium (SVC–RA) junction, parallel to the SVC to prevent complications such as arrhythmia, thrombosis, tricuspid valve damage, and cardiac tamponade.^{1–3}

Various methods using patient's characteristics, transoesophageal echocardiography (TOE), and ECG-guided CVC placement have been recommended to decide the proper depth of CVC.^{4–8} However, when the depth of CVC is decided based on patient's characteristics such as height or age, it does not make up for various puncture sites. The puncture site at the lower part of the neck may

lead to a dangerous deep insertion of the CVC, whereas the higher approach for the CVC insertion may produce a shallow insertion. Although TOE and ECG-guided CVC placements are known to be precise, they are not only cumbersome but also may not be always available.

The direct measurement of the estimated insertion length based on the puncture site and the external landmark could be more practical. The nipples are clearly seen and there is no need to palpate. The sternal head of the right clavicle is easily identified and lies over the path of the internal jugular vein (IJV). In addition, the carina is recommended as a useful target level for the CVC tip position.^{9 10} Therefore, it would be useful, if the CVC tip can be placed at the level of the carina by using the external landmark.

We evaluated the sternal head of the right clavicle and the nipples as external landmarks for inserting the CVC tip near the carina in children.

Methods

With institutional research board approval and parental informed consent, 90 paediatric patients undergoing congenital heart surgery were enrolled. Only the children, <5 yr, undergoing catheterization through the right IJV were included.

Patients with extracardiac vascular abnormality, dextrocardia, and gross deformity of the chest were excluded. Before the start of this study, to identify the relative positions of the sternal head of the right clavicle, the nipples, and the carina, chest radiography (CXR) were taken after attaching the radio-opaque material on the nipples in another 30 paediatric patients, <5 yr, who required a post-operative CXR in post-anaesthetic care unit. The mean (SD) age, weight, and height of pilot patients were 26.2 (16.5) month, 11.9 (3.8) kg, and 84.1 (16.8) cm, respectively. The data in the pilot study showed that the midpoint on the perpendicular line from the sternal head of the right clavicle to a line connecting both nipples was located 0.5 (0.6) cm below the carina.

In this study, after induction of anaesthesia, the patient was placed in the Trendelenburg position with the head slightly rotated (40°–45°) to the left and two points were marked on the patient's skin. Point A was marked at the sternal head of the right clavicle, one of the most prominent points. A line was drawn connecting both nipples, and then the midpoint of the perpendicular line drawn between Point A and the nipple line was designated as Point B (Fig. 1).

Using a sterile technique, the IJV was punctured and guide-wire was inserted. We chose the 4 or 5 Fr paediatric double-lumen CVC (ARROWgard Blue® Catheter, Arrow International, Inc., PA, USA) according to patient size. The distance between the insertion point of the needle (I) and Point A was measured using a sterile disposable paper ruler and the distance between Points A and B was also measured. To position the tip of the CVC at the level of the carina, the insertion depth of CVC was determined by adding the two measurements and subtracting 0.5 cm from this.

After insertion of the CVC, the presence of the CVC tip in the right atrium was checked using TOE and a clear CVP waveform. An antero-posterior CXR was obtained with the patient's head and neck in the neutral position after surgery. After drawing the horizontal line at the level of the carina and the CVC tip, the vertical distance between the two lines was measured using an electronic ruler on the CXR in the Picture Archiving and Communicating System (M-view™, Marotech, Inc., Seoul, Korea). This postoperative measurement was done by a single observer.

This study had a power of 80% and the significance level at 0.05, and an exclusion rate of 15% assuming that

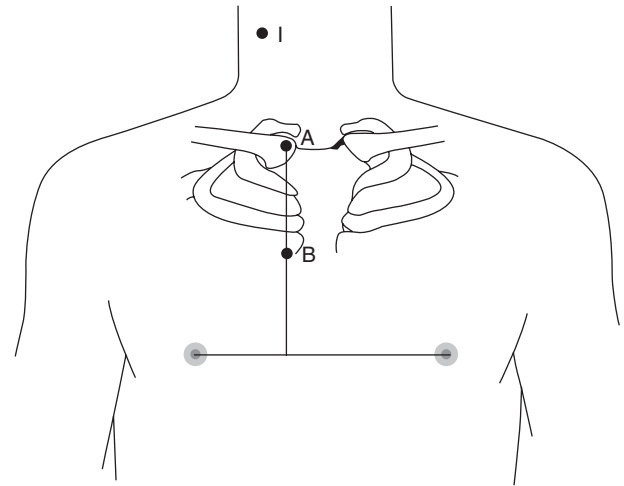


Fig 1 Method for determining the insertion depth of CVC. Two points are marked on the patient's skin during the IJV catheterization. Point A is marked at the sternal head of the right clavicle, most prominent point. Point B is marked at the midpoint of the perpendicular line from Point A to the line connecting both nipples. Point I is the insertion point of the needle. Distance from Point I to Point A and from Point A to Point B is measured. The depth of CVC is determined by adding the two measurements and subtracting 0.5 cm from this.

the patients would be drawn from the population that has a mean of 0.5 cm with an SD of 0.6 cm at the distance between the CVC tip and the carina from the pilot data. The null hypothesis is that the difference in the distance from the CVC tip to the carina is zero. All variables were expressed as mean (SD) and one sample *t*-test was performed for statistical analysis to prove the CVC position from the carina. In order to define the relationship between the distance of the CVC tip from the carina level and the patients' age, height, and weight, linear regression analysis was performed. Statistical data were analysed using SPSS package (version 15.0). A *P*-value of <0.05 was considered statistically significant.

Results

Patient characteristics and diagnoses are described in Tables 1 and 2, respectively. Two patients whose CXR image was unclear to identify the carina were excluded. Another patient in whom the CVC was pulled back accidentally during transferring to surgical intensive care unit (SICU) was also excluded. No other complications (cardiac tamponade and CVC-induced arrhythmia) related to the CVC were seen. No catheter tip was found in the

Table 1 Patient characteristics

	Mean (SD)	Range
Age (month)	16.9 (17.2)	0.1–60
Height (cm)	75 (18)	36–112
Weight (kg)	9.2 (4.3)	2.7–21.3

Table 2 Diagnoses of the patients. ASD, atrial septal defect; VSD, ventricular septal defect; TOF, tetralogy of Fallot; CoA, coarctation of aorta; DORV, double outlet of right ventricle; TGA, transposition of great arteries; SV, single ventricle; PS, pulmonary stenosis; EBA, Ebstein's anomaly; TAPVR, total anomalous pulmonary venous return; HLS, hypoplastic left heart syndrome; ECD, endocardial cushion defect; MS, mitral stenosis

Diagnoses Number	ASD	VSD	TOF	CoA	DORV	TGA	SV	PS	EBA	TAPVR	HLS	ECD	MS
	18	27	13	5	4	5	1	3	2	3	2	3	1

right atrium under the intraoperative TOE. The CVP waveform was clearly observed during the operation. The position of the CVC tip was 0.1 (1.0) ($P=0.293$) cm above the carina (95% CI 0.1 cm below the carina–0.3 cm above the carina). There was no specific relationship between the distance of the CVC tip from the carina level and the patients' age, height, or weight (Fig. 2).

Discussion

Central venous catheterization can be necessary for managing paediatric patients in the perioperative period. Because an erroneous position of the CVC can provide inaccurate CVP and cause fatal complication such as cardiac tamponade,² it is important to determine an appropriate CVC depth. However, there are no exact formulae or methods to predict it at the bedside.

In our study, the CVC tip could be reliably placed near the carina level by using the external landmarks, the sternal head of the right clavicle and the line connecting both nipples, in children without any previous CXR or any knowledge of patient's height and weight or any formulae.

To the best of our knowledge, there are two previous studies using only external landmarks to decide the CVC depth. In the first study, the right third intercostal space was used as an anatomical landmark in paediatric patients.¹¹ They developed a formula from the distance between the right third intercostal space and the skin puncture site for the right IJV catheterization. The proper position of the CVC was regarded as being above the SVC–RA junction in this study. In the second study, the puncture site at the thyroid notch level and manubrial–costal joint was used for determining the CVC depth in adults.¹² They could position the CVC tip within the acceptable range they regarded, up to 5 cm above and up to 1 cm below the carina, that is, repositioning of the CVC was not required. These two studies showed the efficacy of the external landmark for determining the insertion depth of CVC. However, the external landmarks they choose, third intercostal space, thyroid notch, and manubrial–costal joint, were difficult to determine by palpation. On the other hand, the external landmarks that we used in this study have a merit of being easier to palpate and instantly verifiable.

The carina has been recommended as a landmark to guide the CVC placement in recent studies.^{9–10} The carina was always located above the pericardial sac in adults and recommended as a landmark to guide the CVC placement.^{13–14} Yoon and colleagues⁹ concluded that the SVC–RA junction was located 1.5 cm below the carina. In

another study, Albrecht and colleagues¹⁵ also confirmed that the pericardial reflection was below the carina level in small children cadavers. Inagawa and colleagues¹⁶ concluded that the carina of neonate cadavers is not always located above the pericardium; however, they examined only nine specimens and the mean post-conceptual age at autopsy was only 33 weeks, which is much younger than our subjects. After considering the results of the previous studies, we took the carina as the target position for the CVC tip.

According to the cadaver studies in adults and children as stated above,^{13–15} the pericardium generally crosses over the SVC below the carina level and duplicated pericardium strengthens just the medial side of the SVC in both adults and paediatrics. Therefore, if the target position of the CVC tip is the carina, the CVC tip will be always positioned outside the pericardial sac and have little chance of perforating the intrapericardial SVC or RA causing cardiac tamponade.

The main advantage of our method is that the depth of CVC can be practically decided by external anatomical landmarks. First of all, no other equipment is needed and the procedure can easily be accomplished at the bedside. Although we measured the distances with a ruler in the study, in practice, the insertion depth can be determined by placing the graduated CVC over the sterilized skin from the insertion point to the midpoint of the perpendicular line joining the sternal head of the right clavicle and the line connecting both nipples. However, one should be cautious not to touch the skin with the graduated CVC, if possible, to minimize the risk of contamination, despite having sterilized the skin. This method is useful in children of <5 yr of age regardless of the puncture site, weight, and height.

In our study, the mean distance from the CVC tip was 0.1 cm above the carina, but the SD was 1.0 which seems a relatively wide distribution of the CVC tip position. In spite of this fact, we could obtain the clear CVP waveforms and the catheter tip was not found in the right atrium under intraoperative TOE in any of the patients. A recent study of Albrecht and colleagues¹⁵ made a reference that the carina was 0.5 cm above the pericardial reflection and the range is 0.2–1.0 cm in small children. They also stated that the intrapericardial part of SVC was 1.7 (0.1) cm and the range is 0.4–2.8 cm. Yoon and colleagues⁹ concluded that the SVC–RA junction was located 1.5 (0.7) (0.3–2.8 cm) cm below the carina. On the basis of these studies, our method has little chance of placing the CVC into the cardiac chamber.

Although our method just presents the guideline to decide proper CVC depth, it does not exclude the abnormal passage to a different vein or complication-related

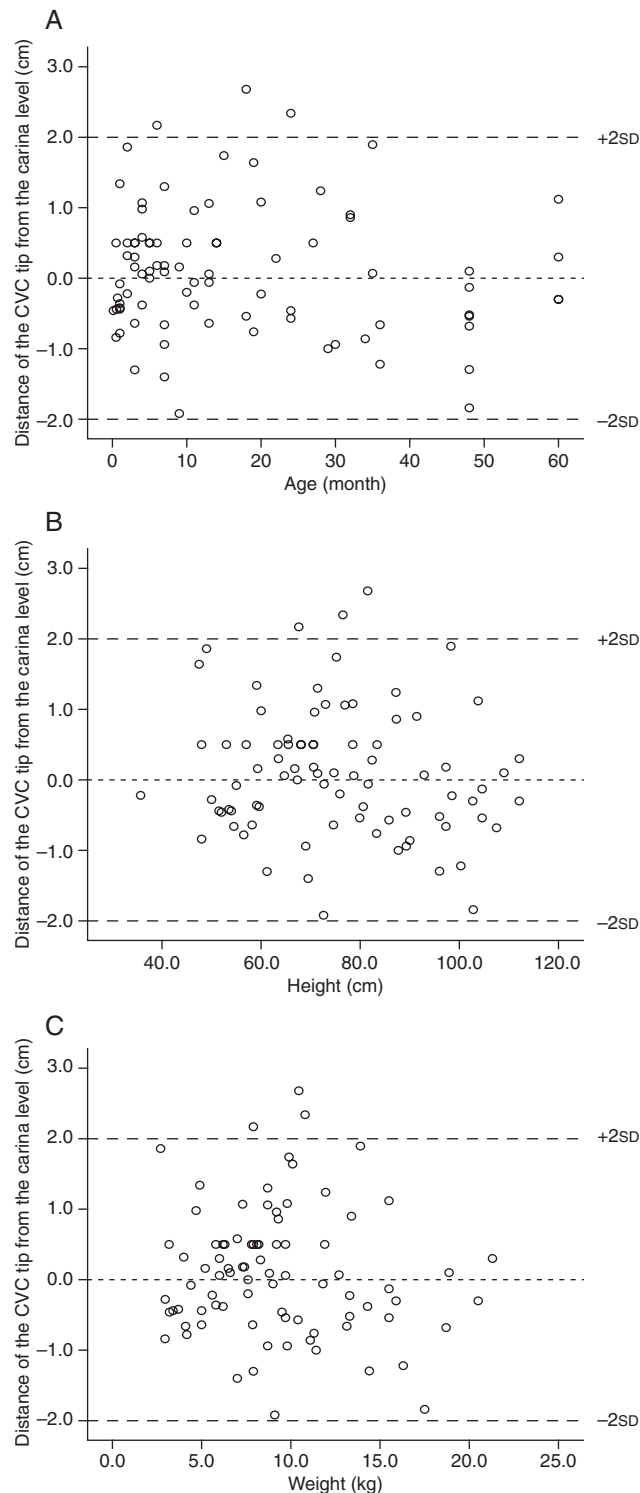


Fig 2 Simple scatter diagrams between the distance of the CVC tip from the carina level and the patients' age (A), height (B), and weight (C). The determination coefficients (r^2) of each diagram are 0.012 ($P=0.314$), 0.013 ($P=0.299$), and 0.008 ($P=0.408$). The tip positioned above the carina is manifested in positive values and below the carina in negative values.

CVC, so CXR confirmation is still needed. In addition, it is applied to only the right IJV catheterization in paediatric patients under 5 yr old; therefore, a similar investigation is required for subclavian vein or left side central vein catheterization and older children or adults.

In conclusion, the method for determining the CVC insertion depth guided by the external landmarks, sternal head of the right clavicle and line connecting both nipples, is helpful for placing the CVC tip near the carina in children under the age of 5 yr.

References

- 1 Fischer GW, Scherz RG. Neck vein catheters and pericardial tamponade. *Pediatrics* 1973; **52**: 868–71
- 2 Booth SA, Norton B, Mulvey DA. Central venous catheterization and fatal cardiac tamponade. *Br J Anaesth* 2001; **87**: 298–302
- 3 Taylor RV, Palagiri AV. Central venous catheterization. *Crit Care Med* 2007; **35**: 1390–6
- 4 Andropoulos DB, Bent ST, Skjonsby B, Stayer SA. The optimal length of insertion of central venous catheters for pediatric patients. *Anesth Analg* 2001; **93**: 883–6
- 5 Yoon SZ, Shin TJ, Kim HS, et al. Depth of a central venous catheter tip: length of insertion guideline for pediatric patients. *Acta Anaesthesiol Scand* 2006; **50**: 355–7
- 6 Ryu HG, Bahk JH, Kim JT, Lee JH. Bedside prediction of the central venous catheter insertion depth. *Br J Anaesth* 2007; **98**: 225–7
- 7 Hayashi Y, Maruyama K, Takaki O, Yamauchi J, Ohnishi Y, Kuro M. Optimal placement of CVP catheter in paediatric cardiac patients. *Can J Anaesth* 1995; **42**: 479–82
- 8 Chu KS, Hsu JH, Wang SS, et al. Accurate central venous port—a catheter placement: intravenous electrocardiography and surface landmark techniques compared by using transesophageal echocardiography. *Anesth Analg* 2004; **98**: 910–4
- 9 Yoon SZ, Hahn JH, Oh AY, Kim HS, Kim SD, Kim CS. Usefulness of the carina as a radiographic landmark for central venous catheter placement in paediatric patients. *Br J Anaesth* 2005; **95**: 514–7
- 10 Stonelake PA, Bodenham AR. The carina as a radiological landmark for central venous catheter tip position. *Br J Anaesth* 2006; **96**: 335–40
- 11 Kim KO, Jo JO, Kim HS, Kim CS. Positioning internal jugular venous catheters using the right third intercostal space in children. *Acta Anaesthesiol Scand* 2003; **47**: 1284–6
- 12 Ezri T, Weisenberg M, Sessler DI, et al. Correct depth of insertion of right internal jugular central venous catheters based on external landmarks: avoiding the right atrium. *J Cardiothorac Vasc Anesth* 2007; **21**: 497–501
- 13 Albrecht K, Nave N, Breitmeier D, Panning B, Troger HD. Applied anatomy of the superior vena cava—the carina as a landmark to guide catheter placement. *Br J Anaesth* 2004; **92**: 75–7
- 14 Schuster M, Nave H, Piepenbrock S, Pabst R, Panning B. The carina as a landmark in central venous catheter placement. *Br J Anaesth* 2000; **85**: 192–4
- 15 Albrecht K, Breitmeier D, Panning B, Tröger HD, Nave H. The carina as a landmark for central venous catheter placement in small children. *Eur J Pediatr* 2006; **165**: 264–6
- 16 Inagawa G, Ka K, Tanaka Y, et al. The carina is not a landmark for central venous catheter placement in neonates. *Paediatr Anaesth* 2007; **17**: 968–71