

# Analgesic efficacy of ultrasound-guided transversus abdominis plane block in patients undergoing open appendicectomy<sup>†</sup>

G. Niraj<sup>1\*</sup>, A. Searle<sup>2</sup>, M. Mathews<sup>3</sup>, V. Misra<sup>2</sup>, M. Baban<sup>2</sup>, S. Kiani<sup>2</sup> and M. Wong<sup>3</sup>

<sup>1</sup>Department of Anaesthesia, University Hospitals of Leicester NHS Trust, Leicester General Hospital, Gwendolen Road, Leicester LE5 4PW, UK. <sup>2</sup>Department of Anaesthesia, Derby Hospitals NHS Foundation Trust, Derby DE22 3NE, UK. <sup>3</sup>Department of Anaesthesia, Nottingham University Hospitals NHS Trust, Nottingham NG7 2UH, UK

\*Corresponding author. E-mail: nirajgopinath@yahoo.co.uk

**Background.** Transversus abdominis plane (TAP) block is a new regional anaesthetic technique that blocks abdominal neural afferents by introducing local anaesthetic into the neuro-fascial plane between the internal oblique and the transversus abdominis muscles. We evaluated its analgesic efficacy in patients undergoing open appendicectomy in a randomized controlled double-blinded clinical trial.

**Methods.** Fifty-two adult patients undergoing open appendicectomy were randomized to undergo standard care ( $n=26$ ) or to undergo a right-sided TAP block with bupivacaine ( $n=26$ ). In addition, all patients received patient-controlled i.v. morphine analgesia, regular acetaminophen, and non-steroidal anti-inflammatory drug, as required, in the postoperative period. All patients received standard anaesthetic, and after induction of anaesthesia, the TAP group received an ultrasound-guided unilateral TAP block. Each patient was assessed after operation by a blinded investigator at 30 min and 24 h after surgery.

**Results.** Ultrasound-guided TAP block significantly reduced postoperative morphine consumption in the first 24 h [mean (SD) 28 (18) vs 50 (19) mg,  $P<0.002$ ]. Postoperative visual analogue scale pain scores were also reduced in the TAP block group soon after surgery [median (IQR) 4.5 (3–5.3) vs 8.5 (7.5–10),  $P<0.001$ ] and at 24 h [5.2 (4–6.2) vs 8 (7–8.5),  $P<0.001$ ]. There were no complications attributable to the TAP block.

**Conclusions.** Ultrasound-guided TAP block holds considerable promise as a part of a balanced postoperative analgesic regimen for patients undergoing open appendicectomy.

*Br J Anaesth* 2009; **103**: 601–5

**Keywords:** anaesthetic techniques, regional; equipment, ultrasound; surgery, appendicectomy

Accepted for publication: April 14, 2009

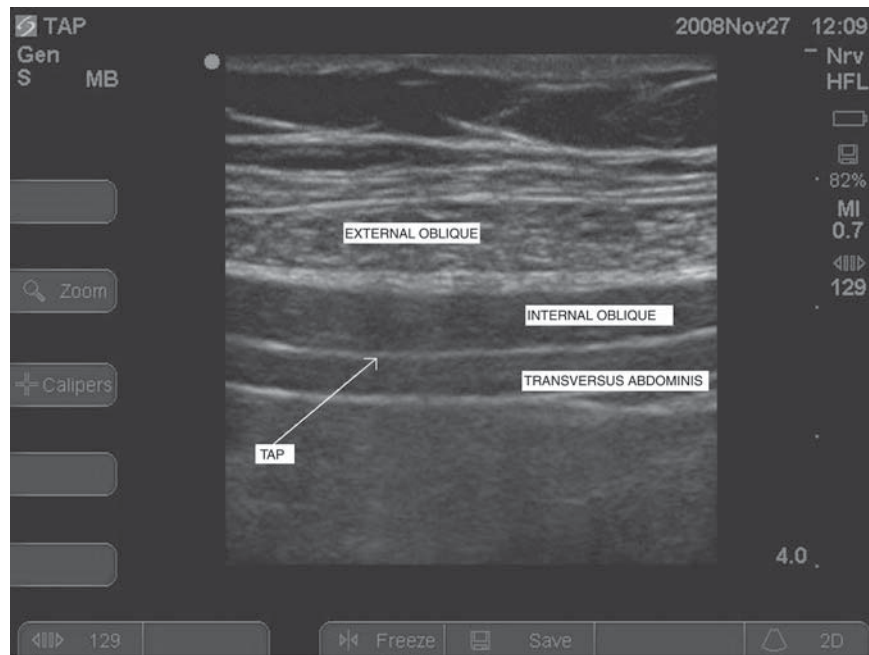
A substantial component of the pain experienced by patients after abdominal surgery is derived from the anterior abdominal wall incision.<sup>1</sup> The anterior abdominal wall is innervated by nerve afferents that course through the transversus abdominis neuro-vascular fascial plane.<sup>2</sup>

McDonnell and colleagues have recently described a promising approach called the transversus abdominis plane (TAP) block which blocks the sensory supply to the anterior abdominal wall. Their reports on this block using a landmark-based technique in patients after both lower midline abdominal laparotomy and in Caesarean section have found a significant reduction in postoperative morphine consumption in the first 24–36 h.<sup>3–5</sup>

Success with this block is dependent on correctly identifying the neuro-fascial plane between the internal oblique and the transversus abdominis muscles. The clinical studies on the block reported so far have used a landmark technique to identify the TAP. Ultrasound-based studies have shown poor accuracy of blind abdominal wall injections.<sup>6</sup>

The present study was designed to evaluate the analgesic efficacy of a unilateral ultrasound-guided TAP block in attenuating morphine consumption during the first 24 h

<sup>†</sup>This article is accompanied by Editorial II.



**Fig 1** Transversus abdominis plane.

after surgery in patients undergoing open appendectomy when compared with standard treatment.

## Methods

After obtaining approval from the regional Ethics Committee, and written informed consent from the patient, we studied 52 ASA I–III patients undergoing open appendectomy in a randomized double-blinded controlled clinical trial. Patients were excluded, if there was a history of allergy to bupivacaine or if they were undergoing laparoscopic appendectomy. Patients were also excluded if the surgery proceeded to laparotomy.

Patients were randomized by sealed envelopes to undergo TAP block ( $n=26$ ) or to receive standard care ( $n=26$ ). The patients and the staff providing postoperative care were blinded to the group assignment.

All the patients received a standard general anaesthetic with standard monitoring. Anaesthesia was induced by rapid sequence induction using thiopental  $5 \text{ mg kg}^{-1}$  and succinylcholine  $1.5\text{--}2 \text{ mg kg}^{-1}$ . Atracurium was used for muscle relaxation. Anaesthesia was maintained with oxygen, air, and isoflurane. All patients also received morphine  $0.1 \text{ mg kg}^{-1}$  and acetaminophen  $1 \text{ g i.v.}$  before the surgical incision. Prophylactic antiemetics were not given.

The patients randomized to undergo the TAP block had the block performed after the induction of anaesthesia by one of the three investigators (G.N., A.S., M.M.). The block was performed under ultrasound guidance on the right TAP.

After induction of anaesthesia, the skin was prepared with 2% chlorhexidine solution and a high-frequency (5–10 MHz) ultrasound probe (SonoSite Micromax, SonoSite,

Inc., Bothwell, MO, USA) was placed transversely on the anterolateral abdominal wall between the iliac crest and the subcostal margin on the right side. The three muscles (external oblique, internal oblique, and transversus abdominis) of the anterior abdominal wall were identified (Fig. 1). After identification of the neuro-fascial plane between the internal oblique and the transversus abdominis muscle, a 23 G 60 mm needle (TOP Neuropole needle, TOP Corp., Tokyo, Japan) was introduced anteriorly in the plane of the ultrasound beam. The needle was directed to approach the TAP and on entering the fascial plane, bupivacaine 0.5% (20 ml) was injected after negative aspiration. The injectate was seen spreading in the TAP as a dark oval shape.

After completion of the surgical procedure and emergence from anaesthesia, patients were transferred to the recovery suite. A standard postoperative analgesic regimen consisting of oral acetaminophen  $1 \text{ g}$  every 6 h and oral diclofenac  $50 \text{ mg}$ , as required, combined with patient-controlled morphine analgesia (bolus  $1 \text{ mg}$ , 5 min lockout) was used in both groups. The presence and severity of pain and nausea were assessed by an investigator blinded to group allocation. These assessments were performed in the recovery suite after 30 min and at 24 h after operation. All patients were asked to give scores for their pain at rest and on coughing and for the degree of nausea at each time point. Pain severity was measured using a visual analogue scale. Nausea was measured using a categorical scoring system (none, 0; mild, 1; moderate, 2; and severe, 3). Rescue antiemetics were offered to any patient who complained of nausea or vomiting.

Primary outcome measure in this study was the 24 h morphine consumption. The secondary outcome measures

included the VAS pain scores at rest and on coughing, the incidence of postoperative nausea and vomiting (PONV), the number of times rescue antiemetics were used, diclofenac use in 24 h, and the duration of postoperative stay. Both of these outcomes were systematically assessed by a member of the research team blinded to the group allocation.

The sample size was estimated on the basis of the 24 h morphine requirement of patients undergoing open appendectomy. A previous study on open appendectomy patients by Turner and Chalkiadis<sup>7</sup> reported a 24 h opioid consumption of 40–45 mg of morphine equivalents. For the purpose of sample size calculation, we considered that a clinically important difference in 24 h morphine consumption would be a 25% absolute reduction in the TAP group compared with the standard group. We calculated that 23 patients per group would be required for an experimental design incorporating two equal-sized groups, using an  $\alpha=0.05$  and  $\beta=0.2$ . To minimize any effect of data loss, we elected to recruit 26 patients in each group into our study assuming a 10% dropout rate.

Statistical analysis was performed using the statistical program (STATA v.10). The distribution of the continuous variables was assessed using the Shapiro–Wilk test. The amount of morphine requirement at 24 h and the duration of surgery were compared between the two groups using Student's *t*-test. The VAS scores, the PONV scores, and the duration of the postoperative stay were compared between the two groups by the Mann–Whitney *U*-test. Categorical variables were compared using Fisher's exact test. The  $\alpha$  levels for all analyses were set as  $P<0.05$ . The results were described as mean (SD) or median (IQR).

## Results

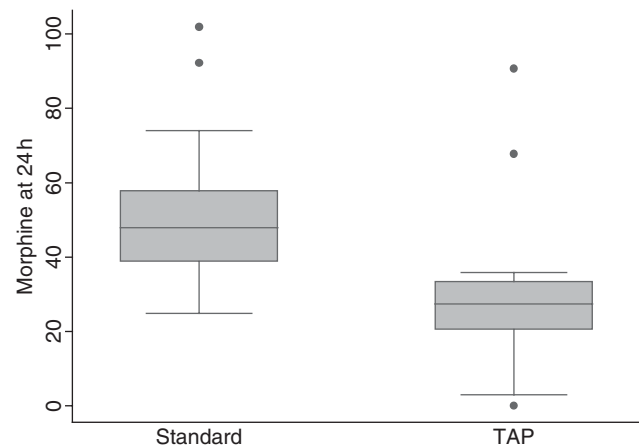
Fifty-two patients were entered into the study. Five patients were excluded from the study for protocol violations (three underwent laparoscopic appendectomy after inclusion into the study and in two, surgery proceeded to laparotomy).

Of the remaining 47 subjects, 24 were randomized to undergo unilateral TAP block with bupivacaine and 23 were randomized to receive standard care.

In all the patients randomized to receive TAP block, the TAP was easily visualized. Two patients in the TAP group apparently had a failed block as their 24 h morphine consumption and VAS pain scores were significantly higher than others in the TAP group and comparable with the standard group (Fig. 2).

The groups were comparable in terms of age, weight, ASA status, and duration of surgery. There were 39 male and six female patients in the study as the majority of female patients admitted with right iliac fossa pain during the study period underwent laparoscopic surgery (Table 1).

TAP block reduced morphine consumption (mg) at 24 h [28 (18) vs 50 (19),  $P<0.002$ ]. Pain scores at rest and on



**Fig 2** The 24 h morphine consumption in two patients who had a failed block is significantly higher than others in the TAP group and is comparable with the standard group.

**Table 1** Baseline patient characteristics. Data are given as median (IQR), mean (SD), or absolute numbers

Group	Standard (n=23)	TAP (n=24)
Age (yr)	25 (20–38)	29 (23–52)
Sex (M/F)	20/3	21/3
Weight (kg)	75 (66–80)	77 (68–86)
Duration of surgery (min)	64 (17)	62 (19)
Appendix perforated	5	7

coughing were significantly reduced at the two time points assessed after the TAP block. There was a significant difference in the incidence and severity of PONV in the two groups at 30 min after surgery but not at 24 h after surgery. The standard group required significantly more rescue antiemetics than the TAP group. There was no significant difference between the groups in diclofenac usage during the first 24 h after surgery. The difference in the duration of postoperative stay between the two groups was not significant (Table 2).

## Discussion

The use of ultrasound-guided sensory block of the anterior abdominal wall with local anaesthesia for postoperative pain relief is an attractive method because of its simplicity and safety. Effective analgesia has shown to reduce postoperative stress response and accelerate recovery from surgery.<sup>8</sup> TAP block is a promising technique with a potential for wide application in providing analgesia after surgery involving the anterior abdominal wall.<sup>9</sup>

The studies reported so far have utilized a bilateral TAP block for midline lower abdominal surgery and for Caesarean section using a landmark technique.<sup>3–5</sup> Hebbard and colleagues<sup>6</sup> subsequently described an ultrasound-guided technique for the TAP block which they named the posterior TAP block. This block provides

**Table 2** Postoperative VAS scores, PONV scores, rescue antiemetic use, and analgesic requirement. Data are given as median (IQR) or mean (SD)

	Standard (n=23)	TAP (n=24)	P-value
VAS scores at rest at 30 min	5 (3.5–8)	2 (1.5–3.2)	<0.001
VAS scores at rest at 24 h	4 (2.5–6)	2 (1–2.8)	<0.001
VAS scores on coughing at 30 min	8.5 (7.5–10)	4.5 (3–5.3)	<0.001
VAS scores on coughing at 24 h	8 (7–8.5)	5.2 (4–6.2)	<0.001
PONV scores at 30 min	0 (0–1)	0 (0–0)	<0.05
PONV scores at 24 h	0 (0–1)	0 (0–0)	NS
Frequency of diclofenac use in 24 h (50 mg)	1 (0–1)	1 (0–1)	NS
Frequency of rescue antiemetic use in 24 h	1 (0–2)	0 (0–1)	<0.05
24 h morphine consumption (mg)	50 (19)	28 (18)	<0.002

analgesia for lower abdominal surgery.<sup>9–11</sup> We studied the efficacy of unilateral, ultrasound-guided TAP block in patients with an anterolateral abdominal wall incision for open appendectomy.

The results of our study show that the patients who received TAP block had significantly reduced morphine consumption at 24 h after surgery. Pain scores at rest and on coughing were significantly lower in the TAP block group.

Pain after surgery for acute appendicitis has two sources, namely the somatosensory pain originating from the surgical wound on the anterior abdominal wall and the visceroperitonitic pain due to the inflammation and infection of the appendix.<sup>12</sup> TAP block ameliorates the pain from the surgical wound. In our study, the patients who received the TAP block had significantly reduced postoperative morphine consumption. However, this reduction is on a lesser scale (45% vs 60%) when compared with the previous clinical studies on TAP block in patients undergoing elective laparotomy and Caesarean section.<sup>3–5</sup> This could be explained by the probable absence of the visceroperitonitic inflammatory pain component in elective surgical patients. Twelve patients in the study had perforated appendicitis (Table 1). Morphine consumption at 24 h was significantly greater in the standard group patients with perforated appendicitis when compared with the TAP group patients with perforated appendicitis.

Local anaesthetic infiltration to the surgical wound can be an alternative to TAP block in patients undergoing open appendectomy; however, the duration of action is short-lived (2–6 h) and a systematic review has shown that there was no evidence for improved pain relief after appendectomy in adult patients.<sup>13</sup>

The success rate of TAP block in our study was 92%. The two TAP blocks that did not work were probably due to operator error as it is vital that the local anaesthetic agent is injected into the correct plane. Although ultrasound guidance improves accurate needle placement into the neuro-fascial plane, visibility can be impaired in the obese patient.

This study has the following limitations. The study assessments were limited to 24 h. McDonnell and

colleagues<sup>4, 5</sup> have recently shown the efficacy of TAP block in reducing postoperative morphine consumption to last for 36 h after a single-shot injection. We limited our study to 24 h because a majority of patients no longer require systemic opioid therapy after 24 h after open appendectomy, and there was clinical pressure to mobilize patients, which would have been hindered by the presence of the PCA apparatus. The frequency of the study assessments was limited to the immediate postoperative period and at 24 h after surgery. Surgery for acute appendicitis is usually performed on an urgent basis and a majority of the cases are done outside of normal work hours. Follow-ups at 6 and 12 h after surgery would have meant disturbing the patients during the early hours of the night after they had undergone urgent surgery. The study had a skewed gender ratio because a majority of female patients presenting with right iliac fossa pain had laparoscopic procedures performed during the recruitment period.

The pathophysiology of postoperative pain is complex and pain after open appendectomy is often undertreated. Opioids, which have been the mainstay of postoperative analgesia in appendicitis, inhibit only one component of the pain pathway. A multifaceted approach achieves synergy in drug actions offering better analgesia using smaller doses of individual drugs.<sup>14</sup> We conclude that ultrasound-guided TAP block holds considerable promise as a part of balanced postoperative analgesic regimen for patients undergoing open appendectomy.

## Funding

All funding was from departmental resources.

## References

- 1 Wall PD, Melzack R. Pain measurements in persons in pain. In: Wall PD, Melzack R, eds. *Textbook of Pain*, 4th Edn. Edinburgh, UK: Churchill Livingstone, 1999; 409–26
- 2 Netter FH. Back and spinal cord. In: Netter FH, ed. *Atlas of Human Anatomy*. Summit, NJ, USA: The Ciba-Geigy Corporation, 1989; 145–55
- 3 O'Donnell BD, McDonnell JG, McShane AJ. The transversus abdominis plane (TAP) block in open retropubic prostatectomy. *Reg Anesth Pain Med* 2006; **31**: 91
- 4 McDonnell JG, O'Donnell BD, Curley GCJ, et al. The analgesic efficacy of transversus abdominis block after abdominal surgery. *Anesth Analg* 2007; **104**: 193–7
- 5 McDonnell JG, Curley GCJ, Carney J, et al. The analgesic efficacy of transversus abdominis block after cesarean delivery. *Anesth Analg* 2008; **106**: 186–91
- 6 Hebbard P, Fujiwara Y, Shibata Y, Royse C. Ultrasound guided transversus abdominis plane (TAP) block. *Anaesth Intensive Care* 2007; **35**: 616–7
- 7 Turner GA, Chalkiadis G. Comparison of preoperative lignocaine infiltration on postoperative analgesic requirements. *Br J Anaesth* 1994; **72**: 541–3
- 8 Kehlet H. Surgical stress: the role of pain and analgesia. *Br J Anaesth* 1989; **63**: 189–95

- 9 Niraj G, Kelkar A, Fox A. Application of the transversus abdominis plane (TAP) block in the intensive care unit. *Anaesth Intensive Care* 2009; **37** (in press)
- 10 Shibata Y, Sato Y, Fujiwara Y, Komatsu T. Transversus abdominis plane block. *Anesth Analg* 2007; **105**: 883
- 11 Tran TMN, Ivanusic JJ, Hebbard P, Barrington MJ. Determination of spread of injectate after ultrasound-guided transversus abdominis plane block: a cadaveric study. *Br J Anaesth* 2009; **102**: 123–7
- 12 Aida S, Baba H, Yamakura T, Taga K, Fukuda S, Shimoji K. The effectiveness of pre-emptive analgesia varies according to the type of surgery: a randomized, double-blind study. *Anesth Analg* 1999; **89**: 711–6
- 13 Moinichie S, Mikkelsen S, Wetterslev J, Dahl JB. A qualitative systematic review of incisional local anaesthesia for postoperative pain relief after abdominal operations. *Br J Anaesth* 1998; **81**: 377–83
- 14 Horvath G, Joo G, Dobos I, Klimscah W, Toth G, Benedek G. The synergistic antinociceptive interactions of endorphin-1, with dexmedetomidine and/or S(+) ketamine in rats. *Anesth Analg* 2001; **93**: 1018–24