

REVIEW ARTICLE



Fifteen years of ultrasound guidance in regional anaesthesia: Part 1

P. Marhofer^{1*}, W. Harrop-Griffiths², S. C. Kettner¹ and L. Kirchmair³

¹Department of Anaesthesia, Intensive Care Medicine and Pain Therapy, Medical University of Vienna, Waehringer Guertel 18-20, A-1090 Vienna, Austria. ²Department of Anaesthesia, St Mary's Hospital, Praed Street, London W2 1NY, UK. ³Department of Anaesthesia, Intensive Care Medicine and Pain Therapy, Medical University of Innsbruck, A-6020 Innsbruck, Austria

*Corresponding author. E-mail: peter.marhofer@meduniwien.ac.at

Ultrasound guidance for regional anaesthesia has gained enormous popularity in the past decade. The use of ultrasound guidance for many regional anaesthetic techniques is common in daily clinical practice, and the number of practitioners using it is increasing. However, alongside the enthusiasm, there should be a degree of informed scepticism. The widespread use of the various techniques of ultrasound-guided regional blocks without adequate training raises the danger of malpractice and subsequent impaired outcome. Adequate education in the use of regional block techniques under ultrasound guidance is essential. This review article addresses ultrasound guidance for regional anaesthesia, and is divided into two parts because of the size of the topic and the number of issues covered. This first part includes a review and preview of ultrasound guidance in regional anaesthesia and discusses all aspects of ultrasound for regional anaesthesia with a focus on recent technical developments, the positive implications in economics, further potential advantages (e.g. detection of anatomical variants, painless performance of blocks) and education. It also attempts to define a 'gold standard' in regional anaesthesia with the most recent findings in adequate volumes of local anaesthetics for peripheral nerve blocks. This standard should include an extraneural needle position, a high success rate, and wide application of ultrasound guidance in regional anaesthesia. The second part describes the impact of ultrasound on the development of nerve block techniques in the past 5 yr.

Br J Anaesth 2010; 104: 538–46

Keywords: anaesthetic techniques, regional; equipment, ultrasound machines; nerve block

The role of ultrasound guidance in regional anaesthesia is increasing. After simple descriptions of ultrasound-guided block techniques appeared in the mid-1990s, it rapidly became evident that this technique offers many advantages, but also is not without its problems. A large number of different ultrasound-guided regional techniques have now been described, and there is widespread interest in using these techniques in clinical practice. This interest carries with it responsibilities for clinicians developing these techniques as it is evident that not all the block techniques described are clinically useful and, indeed, some are potentially dangerous. Although descriptions of intraneural injection of local anaesthetic provide the most obvious danger,⁹ some approaches are simply not useful.^{4 37 38}

Some important questions can better be answered with the recent use of volunteer studies than with clinical studies. Investigation of the lowest local anaesthetic volume necessary to block a peripheral nerve is an

example of a sophisticated volunteer-based study that has the long-term aim of increasing the safety of regional anaesthesia. This review article will serve as an 'update' of our 2005 review³⁵ and offers a critical view of this subject. The first part reviews the theoretical and scientific background of ultrasound guidance in regional anaesthesia; the second part describes recent developments in ultrasound-guided techniques.

Developments during the past 15 years

Ultrasound guidance has greatly influenced the practice of regional anaesthesia in the last 15 yr. Between 1884, the year when Carl Koller performed the first regional block for eye surgery in Vienna, and the late 1970s, the main developments were in new local anaesthetic drugs and the introduction of mainly anatomical methods for nerve identification. Unfortunately, anatomy is not exactly

predictable and the natural variability of human anatomy led to poor success rates for many peripheral nerve blocks. Much of the antipathy towards regional anaesthesia has its origins in those arguably 'hit and miss' times. Part of this may have been a lack of understanding of the anatomy. The description of Winnie's 'three-in-one' block, in which a single injection of local anaesthetic around the femoral nerve should also block both the obturator nerve and lateral cutaneous nerve of the thigh, led regional anaesthetists to believe that there was a contiguous fascial sheath that swept proximally under the inguinal ligament and towards the lumbar plexus, which could be filled with large volumes of local anaesthetic to achieve a reliable triple nerve block. The inability at the time to determine the spread of local anaesthetic objectively led to misinterpretation of the anatomy. Conventional X-ray technology using radio-opaque contrast in the local anaesthetic solution showed that the three nerves were blocked by lateral, and not proximal, spread. However, one drawback of X-rays is their inability to visualize neural structures, and therefore the relationship between the local anaesthetic injected and the nerves affected can only be inferred rather than directly seen.

The introduction of ultrasound into clinical practice brought a solution to this problem closer. The first paper in this field was published in 1978:³¹ a Doppler ultrasound blood flow detector was used to facilitate supraclavicular brachial plexus block. At this time, detailed knowledge of the ultrasonographic appearance of neural structures was poor, and the ultrasound technology was not suitable for visualization of nerves. The first direct use of ultrasound for a regional block was in 1994, again for supraclavicular brachial plexus block.²⁸

In the ensuing 10 yr, ultrasound technology advanced in parallel with the understanding of its use and the development of block techniques which suited the use of ultrasound. The increased interest and investment in ultrasound led manufacturers to design machines specifically for regional anaesthesia, and software to facilitate peripheral nerve blocks. Better quality images should produce better quality blocks. Recent studies have demonstrated the cost-effectiveness of ultrasound-guided regional anaesthesia in daily clinical practice.²⁵

The clinical science of ultrasound-guided regional anaesthesia has advanced as new approaches and techniques have been developed. However, some techniques have not proven to be clinically effective, practical, or safe,^{4 9 10 12} and it may be difficult for the anaesthetist to differentiate between those likely to enjoy widespread clinical use and those unlikely to do so. Open debate about new techniques is obviously to be encouraged, but only practical implementation of new techniques and clinical experience will show if a particular approach or technique is safe and effective in daily clinical practice. It is also evident that every paper published in this field reflects in large part the individual opinions of the authors, often expressed after the

performance of new blocks on a relatively small number of subjects. Therefore, large, multicentre studies are required to establish the advantages and disadvantages of new ultrasound-guided block techniques. Some of these larger studies may produce results that contradict earlier and smaller studies of a new technique, but even though large studies are expensive and difficult to perform, they are necessary in this important field. 'Ultrasound enthusiasts' tend to overestimate their manual skills and the success of their techniques, whereas sworn followers of a more 'conventional' technique tend to demonize ultrasound and neglect any potential usefulness of new techniques.^{1-3 14} There needs to be a balance between the evangelical fervour of the innovative enthusiast and the resistance of the clinical Luddite. Open minds, healthy scepticism, and a desire to work together are likely to benefit patients the most. Much has happened in the last 15 yr, but it is that which happens in the next 15 yr that is likely to be more important from the clinical standpoint.

Have we established the gold standard in regional anaesthesia?

Regional anaesthesia makes a simple demand on the clinician: that the right dose of the right drug is put in the right place.¹⁹ The argument for the widespread use of ultrasound is that direct visualization of the needle, the anatomy, the neural structures, and the spread of local anaesthetic can only enhance the anaesthetist's ability to satisfy this simple demand. However, there is still debate about the right place for the injection and the right dose of the drugs to be used.

Received wisdom accepts that an extraneural needle position during injection of local anaesthetic is safe and effective, whereas placement of the needle into the substance of a fascicle of a nerve, that is, sub-perineurally, is potentially dangerous. However, there is increasing evidence from studies using ultrasound that injections under the epineurium may be common and even safe. This evidence is controversial.^{9 11} At present, there are few data to support the routine performance of sub-epineural injections, and even with modern high-frequency ultrasound, it is not possible to exclude the intrafascicular (sub-perineural) placement of a needle that has been deliberately placed into a nerve.

The volume of local anaesthetic that is needed to provide a successful nerve block is also the subject of debate. Large volumes of local anaesthetic have been used in the past to compensate for inexact, traditional anatomical techniques of nerve identification. In spite of these sometimes potentially dangerously large volumes, success rates for some regional techniques were disappointing. The most likely reason for this is the inaccurate placement of local anaesthetic relative to the nerve structures. Recent studies indicate that peripheral nerve blocks can be

performed with much lower volumes of local anaesthetic than those described in the past. Successful ultrasound-guided ulnar nerve block is possible with <1 ml of local anaesthetic solution.²¹ This study used an up-and-down statistical study design and a novel method for calculating the volume of local anaesthetic used that was based on the nerve's measured cross-sectional area (Fig. 1). Thus, a reliable estimate of the ED₉₅ volume of local anaesthetic needed to block this particular nerve block was possible: 0.11 ml mm⁻², or about 0.7 ml for an adult patient. It is important to mention that such low-volume blocks can only be achieved with a multi-injection technique—even for single nerve blocks. With more sophisticated techniques such as interscalene or axillary brachial plexus blocks, a number of needle tip positions are required to produce a successful low-volume block. In fact, the spread of local anaesthetic during injection with a given needle tip position can never be predicted, and therefore adjustment of the needle tip after every injection is a prerequisite for the successful realization of this technique.

Similar results have been found for sciatic nerve block where a value for ED₉₉ of 0.10 ml mm⁻² cross-sectional nerve area was calculated.³² The median cross-sectional nerve area was 57 mm² in that volunteer study, resulting in a median volume of 5.7 ml of local anaesthetic for sciatic nerve block. The lowest volume for a successful sciatic nerve block in that study was 1.7 ml, despite complete circumferential spread of local anaesthetic around the nerve not being achieved (Fig. 2). Thus, we may have to re-evaluate our belief that local anaesthetic has to surround the entire nerve for a successful block (the so-called 'doughnut sign').³⁰ The described ED₉₉³² equates to a 99% success rate for peripheral nerve blocks and this could contribute to future considerations of a 'gold standard'.

The ultimate target of 100% success rate with no complications or side-effects has not yet been reached. A possible factor in this is that there are too many descriptions of scanning methods and block techniques. The scientific value of case reports or small observational studies is

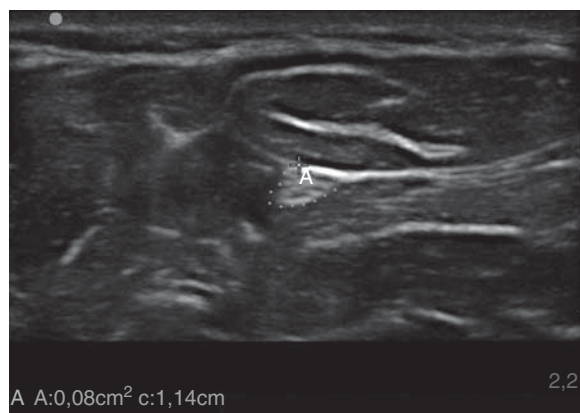

Fig 1 Measurement of the cross-sectional area of the ulnar nerve with ultrasound.

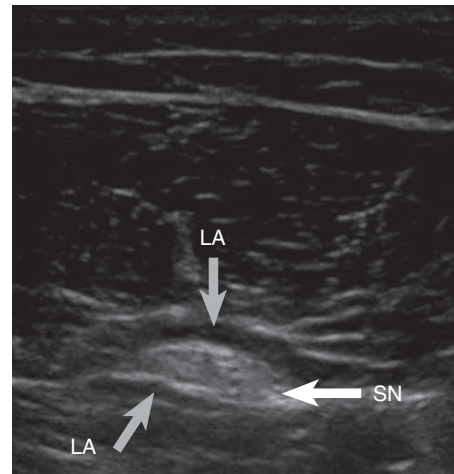


Fig 2 The sciatic nerve (SN) at the mid-femoral level partly surrounded by local anaesthetic, resulting in a successful block. The homogenous hypoechoic (dark) zone represents the local anaesthetic (LA).

limited, and may lead to confusion rather than enlightenment. The use of ultrasound in clinical practice must advance hand in hand with its scientific evaluation. The achievement of a true 'gold standard' in a particular field requires both excellent science and the responsible implementation of a technique into clinical practice. Techniques with a reported mean success rate of 80%^{7 8 26} can certainly not be described as being the 'gold standard'. However, the use of ultrasound for regional blocks has the potential to raise the standard and to drive forward success rates and safety. However, patient satisfaction is also an important factor in the clinical acceptability of a technique which will depend on whether it provides a pain-free and predictably successful outcome.

Does ultrasound increase the safety of regional blocks?

This question divides regional anaesthesia practitioners into three camps: those who support the view that direct visualization of anatomy is associated with increased safety, those who oppose this view, and those who argue that the evidence to support it is lacking. The incidence of complications from regional anaesthesia is described as being between 0.0004%⁵ and 14%.¹⁵ This huge range makes grounds for further discussion and debate.

An analysis of 1010 ultrasound-guided blocks found neurological symptoms in 8.2% of patients after 10 days, 3.7% after 1 month, and 0.6% after 6 months.²² The incidences of long-term neurological complications are similar to those seen with conventional techniques.^{5 6 13} A comparison of 200 interscalene blocks performed with either ultrasound or nerve stimulator guidance found, after 1 week, an incidence of neurological complications of 8% with ultrasound and 11% with nerve stimulation.³³ It is important to state that perioperative neurological

complications may be caused by a number of mechanisms such as positioning, tourniquets, and tissue swelling. Therefore, an evaluation of the true rate of neurological complications associated directly with regional anaesthesia is difficult. Even if the current literature does not support the safety of ultrasound guidance in regional anaesthesia, it seems to us obvious that the correct use of this technique should be associated with increased safety.

Technical developments, economical aspects, and education

Ultrasound for regional anaesthesia was not designed for exclusive use by a small number of experts. The aim should be to maximize the number of anaesthetists able to use this technique in their clinical practice. The main prerequisite for the widespread use of ultrasound in regional anaesthesia is high-quality education. Other important aspects are user-friendly and reliable ultrasound devices, and the use of scientifically validated techniques.

Ultrasound technology has evolved during the past decade, with developments in achieving higher ultrasound frequencies and thus better image resolution, and also in post-processing and user-friendliness. The current standard should be based on optimal two-dimensional (2D) ultrasound images. The interpretation of 3D or even 4D (real-time 3D ultrasound illustrations) ultrasound images is currently difficult and is therefore not yet suitable for everyday clinical practice.¹⁷ Beside the large size and weight of the ultrasound probes, the overall quality of 3D and 4D images is poor when compared with 2D scans. The correct interpretation of real-time 2D images is the most important prerequisite for successful performance of regional blocks in daily clinical practice. Having too many complex technical features may distract the anaesthetist from the key aspects of a simple and successful technique: identification of the anatomical structures, continuous visualization of both the needle tip and the spread of local anaesthetic. Technical features such as multidimensional sonography may be helpful in the future,^{23 24 39 47} but in current practice, all efforts should be focused on the optimal interpretation of high-quality 2D images.

The use of ultrasound will also be extended and simplified by the production of small, portable ultrasound devices. A reduction in costs may be observed that runs parallel to the downsizing of ultrasound equipment. Ten years ago, it was difficult to get a useful ultrasound machine for less than €80 000. Today, excellent equipment is available for less than €30 000. However, we should not consider only the costs of the capital purchase of ultrasound equipment. A recent study investigated the economic aspects of ultrasound-guided interscalene blocks for arthroscopic shoulder surgery.²⁵ The authors observed a decrease in the cost of greater than €170 per case when taking into account both direct costs (drugs,

disposables, etc.) and indirect, workflow-related costs. The most important prerequisites for achieving cost savings were high block success rates and an optimal anaesthesia-related workflow. It is important to highlight the fact that €15 min⁻¹ have to be allowed for every minute in the operating theatre, and therefore shorter anaesthesia induction and emergence times are the significant factors for cost reduction. Under appropriate conditions, greater than €100 000 per year per operating theatre can be saved without compromising care with the use of ultrasound-guided regional blocks.

The beneficial effects on cost and patient satisfaction can only be realized with an overall success rate for regional blocks of >98%. Good education and training is necessary to achieve this both laudable and achievable aim. Many anaesthesia meetings provide basic workshops that aim to arouse the interest of potential users of this technique. These basic workshops should be followed by advanced workshops. The anaesthesia community is at a very early stage in the development of guidelines for structured education in ultrasound. Recently, the American and European Societies of Regional Anaesthesia (ASRA and ESRA) published initial guidelines on the basic orientation and education for potential users of ultrasound in regional anaesthesia.⁴⁶ However, a universal agreement on how to teach ultrasonography for regional blocks is still lacking. A combination of basic and advanced workshops, and ongoing supervised practice, leads to the safe and effective performance of ultrasound-guided blocks.

Independent of the methods of education and training, each institution and anaesthetist involved in the use of regional anaesthesia should undertake critical reflection on: what is the overall success rate and complications of their regional anaesthesia? Is there room for improvement by changing the technique of nerve location? What need to be seen, learned, and done before introducing ultrasound safely into practice? How can any problems associated with the new technique be monitored and reviewed? Can problems that are inherent to the system be avoided?

Complex healthcare systems may not provide an environment for ready answers to the above questions. However, it is an important step in personal development for potential users of ultrasound in regional anaesthesia at least to ask themselves the above questions. A lot has already been achieved with regard to education and initiating a change in the mind of anaesthetists and those charged with funding anaesthesia, but there is still a long way to go to achieve a high level of the use of ultrasound guidance in regional anaesthesia.

What are the real advantages of ultrasound guidance in regional anaesthesia?

The potential advantages of ultrasound guidance in regional anaesthesia are still a source of some debate.

Hard evidence in this area is sadly lacking. However, we should be able to make a reasonable attempt at describing the clinically relevant points.

Direct visualization of neural and adjacent anatomical structures and the spread of local anaesthetic

Without any doubt, direct visualization of neural and adjacent anatomical structures is the main advantage of the use of ultrasound for regional block techniques.¹⁹ A recent investigator-blinded study of ilioinguinal/iliohypogastric nerve blocks in children translates these theoretical considerations into clinical practice.⁴⁹ The authors used the conventional ‘fascial click’ method and observed the spread of local anaesthetic with ultrasound and found that the local anaesthetic was injected into the correct anatomical plane between the internal oblique and transversus abdominis muscles in only 14% of the cases. This study is a good example of the difficulties associated with landmark-based techniques.

Current ultrasound equipment allows much easier identification of very small neural structures than was possible with machines introduced only a few years ago (Fig. 3). In addition, adjacent anatomical structures can be identified. Identification of the cervical pleura, which is close to the brachial plexus at the peri-clavicular level, is an example of the importance of adequate anatomical orientation during regional anaesthetic techniques (Fig. 4).

An important objective for ultrasound is visualization of the spread of local anaesthetic during injection. Confirmation of the correct disposition of local anaesthetic avoids any maldistribution, such as epineural, perineural, or intravascular injection. In addition, an ability to perform blocks with small volumes of local anaesthetic is mainly based on an ability to observe the spread of the local anaesthetic directly.^{20 21 32 50}

Detection of anatomical variants

Anatomical variation is one of the main reasons for block failure. A discussion of all the anatomical variations that

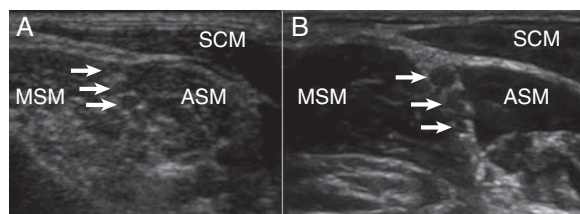


Fig 3 Comparison of an ultrasound image of the interscalene brachial plexus (the arrows indicate the C5–7 nerve roots; SCM, sternocleidomastoid muscle; ASM, anterior scalene muscle; MSM, median scalenus muscle) with two different qualities. (A) Illustration from 2004; (B) most recent illustration with improved image quality due to speckle suppression.

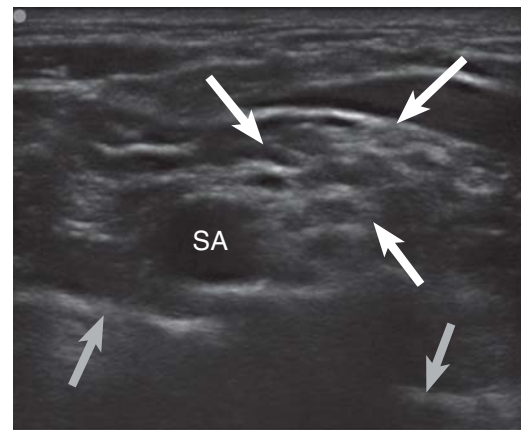


Fig 4 Ultrasonographic illustration of the brachial plexus (indicated by white arrows) at the supraclavicular level, adjacent to the cervical pleura (indicated by grey arrows). SA, Subclavian artery.

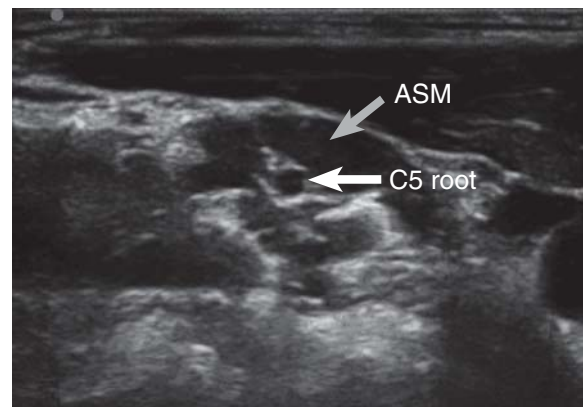


Fig 5 Cross-sectional ultrasound view of the brachial plexus at the interscalene level in which the C5 root is located within the anterior scalene muscle (ASM; right side, medial).

lead to block failure is beyond the scope of this review. However, it is important to highlight ultrasound’s ability to detect anatomical variations, for it is the only bedside method that can accurately determine local anatomy before the performance of regional blocks, such as the ultrasound appearance of variations of the brachial plexus at the interscalene level (Figs 5 and 6).

Reduction of the volume of local anaesthetic

Low-volume regional blocks are only possible if nerve structures are directly visualized and a multi-injection technique is used. Minimum effective volumes have been determined for the ulnar²¹ and sciatic nerves.³² The minimum effective volume for brachial plexus block at the axillary level has been described as 1 ml per nerve.⁴¹ These studies that describe very low local anaesthetic volumes for blocks were performed by experts in ultrasound-guided regional anaesthesia and the purpose of the reports of these blocks is to show the minimum volumes that can be used. In clinical practice, a reasonable

minimum volume to use might be two to three times these published volumes (Table 1).

Improvement in block quality

The method used for nerve location is only one factor that affects block quality. Other factors include the local anaesthetic drug itself, in addition to the volume and concentration given. Although it is likely that direct visualization will be shown to be associated with better quality blocks, this may be dependent upon the absolute quality of the 2D ultrasound images.

Most comparative studies have shown faster onset times^{27 36 42 44} and longer duration^{27 36 40} of blocks when using ultrasound in comparison with other nerve location techniques. These observations are of particular interest in relation to economical considerations related to short induction and recovery times and a lesser need for analgesic drugs,²⁵ and patient satisfaction, for example, less

postoperative pain and fewer side-effects due to systemic analgesic drugs. There are currently few published data on patient satisfaction and its relation to the method of nerve location.

Painless performance of blocks

Patient comfort is an important issue. Effective regional anaesthesia can provide painless surgical procedures. Unfortunately, some regional block techniques are painful to perform because of large needle size, blunt needle tip, or identification of nerves with electrical stimulation. Only a few studies have investigated pain during the performance of regional blocks. A reduction in procedural pain during popliteal block has been shown when ultrasound is used,¹⁸ and ultrasound-guided brachial plexus blocks in children are associated with less pain when compared with nerve stimulator guidance.³⁶ Despite limited evidence in this area, it seems that ultrasound-guided regional blocks are likely to be associated with less pain for our patients.

Patient satisfaction

Patient satisfaction during a surgical procedure is an important issue. Patient satisfaction can be achieved by painless performance of the block and excellent block qualities providing long-lasting perioperative analgesia. Only a few studies have investigated patient satisfaction, but ultrasound guidance appears to be associated with an increase in patient satisfaction.^{18 33 48}

Needle visualization and needle guidance techniques

The single greatest benefit of the use of ultrasound for peripheral nerve blocks is often said to be the ability to visualize of the needle throughout the performance of the

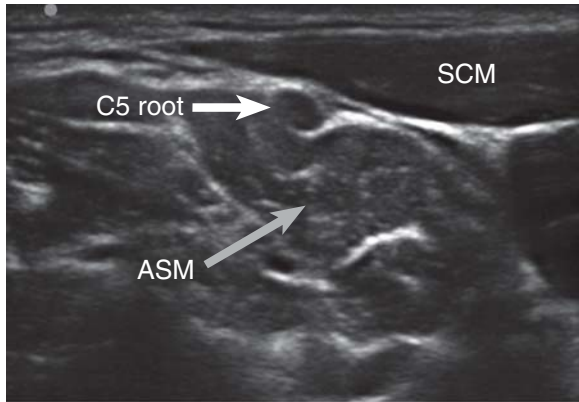


Fig 6 Cross-sectional ultrasound view of the brachial plexus at the interscalene level in which the C5 root is located outside the interscalene groove (SCM, sternocleidomastoid muscle; ASM; right side, medial).

Table 1 List of publications on volume reduction of local anaesthetic in peripheral nerve blocks

Publication	Nerve structure	Minimum effective volume	Statistical method	Additional description
Willschke and colleagues (2006) ⁵⁰	Ilioinguinal/iliohypogastric nerves	0.075 ml kg ⁻¹	Clinical setting, modified step-up/step-down approach	Children
Casati and colleagues (2007) ¹⁶	Femoral nerve	ED ₅₀ 22 ml (95% CI, 13–36 ml)	Clinical setting, up-and-down staircase method	Relatively large volume despite the use of ultrasound
Riazi and colleagues (2008) ⁴⁵	Interscalene brachial plexus block	5 ml	Clinical setting, comparative study design (5 vs 20 ml)	5 ml equi-effective with 20 ml
Eichenberger and colleagues (2009) ²¹	Ulnar nerve	ED ₅₀ 0.11 ml mm ⁻² nerve area	Experimental setting, up-and-down procedure according to the Dixon average method	Evaluation of the minimum effective volume of local anaesthetic based on the cross-sectional nerve area
O'Donnell and colleagues (2009) ⁴¹	Axillary plexus	1 ml per nerve	Clinical setting, step-up/step-down study model	
Duggan and colleagues (2009) ²⁰	Supraclavicular plexus	ED ₅₀ 23 ml, ED ₉₅ 42 ml	Clinical setting, up-and-down procedure according to the Dixon average method	No difference to conventional methods of nerve identification
Latzke and colleagues (2010) ³²	Sciatic nerve at the mid-femoral level	ED ₉₉ 0.10 ml mm ⁻² cross-sectional nerve area	Experimental setting, up-and-down procedure according to the Dixon average method	Evaluation of the minimum effective volume of local anaesthetic based on the cross-sectional nerve area

block and adequate visualization of the needle is mandatory for safe and effective blocks. Close observation of the spread of the local anaesthetic is equally important for the performance of regional blocks.

The ultrasound visibility of different needles has been investigated in two media (a water bath and an animal model) with three different ultrasound machines and two different angles (0° and 45°).³⁴ This observational study found differences in the visibility of the needles and defined the following requirements for the 'ideal echogenic needle':

- (i) good needle visibility, in particular its tip;
- (ii) suitability for all kinds of tissue;
- (iii) good visualization at all angles;
- (iv) sharp depiction of the bevel of the needle;
- (v) low artifact formation;
- (vi) no shadowing;
- (vii) extremely good detection and differentiation from the surrounding area.

However, no studies have investigated success rates with different needle types, so there is as yet no 'ideal needle', or any evidence that this will improve success rates or safety. There are continuing developments of new needles aimed at facilitating block performance and needle visibility. Piezoelectric vibrating needles are one example of recent potential developments.²⁹ Only the future will show if the evolution of such high-tech equipment is beneficial.

Needle visibility is only one aspect of the safety of block performance. From the first descriptions of ultrasound-guided regional techniques, most authors favoured in-plane techniques, in which the entire needle is visualized as it passes parallel to the long axis of the scanning head and directly under the ultrasound beam. A good example of such a technical controversy relates to the posterior approach to the interscalene brachial plexus—the 'Pippa approach'.^{4 37 38} It is important to know that two nerves pass through the middle scalene muscle: the long thoracic and dorsal scapular nerves. These nerves can be damaged by a needle passing through the middle scalene muscle during an in-plane technique for interscalene brachial plexus block, with the possible consequence of paralysis of the serratus anterior muscle. The out-of-plane technique, in which the needle is passed in alignment with the interscalene groove and across the short axis of the ultrasound probe, is perhaps more logical from an anatomical point of view.²⁷ On the other hand, an in-plane needle guidance technique should definitely be used for the supraclavicular approach to the brachial plexus, both for technical reasons, to obtain the correct angle with the needle passing from medial to lateral, and safety reasons, to allow visualization of the needle and cervical pleura at the same time.⁴³ However, for many techniques, it does not really matter whether an out-of-plane or in-plane needle guidance technique is used. Peripheral nerve blocks can be performed in a safe and effective way with either

technique. However, for some particular techniques, it is more sensible, from both anatomical and safety points of view, to use one technique in preference to another. Some may argue that these considerations are not supported by the literature, but clinical experience may sometimes guide practice where no hard scientific data exist.

What of the future?

Much has happened in the last 15 yr and if experience in other technological fields is to be used as a yardstick of the pace of development, the next 15 yr will see an exponential increase in the quality of both 2D images and 3D ultrasound images. However, the safety of any practical technique depends upon the training, experience, and skills of the operator, and we should be wary of believing that smarter technology will translate to better and safer blocks. It is also important that technology remains affordable. This will be an important factor of the wide implementation of ultrasound in regional anaesthesia.

Only high-quality training and careful supervision of trainees and novices in the art of ultrasound-guided blocks will ensure that we can put the burgeoning technology to safe and effective use for our patients. In addition, well-designed clinical studies with the main focus on outcome parameters are required for the definitive implementation of ultrasound-guided regional anaesthesia in everyone's clinical practice.

Conflict of interest

None declared.

References

- 1 Aguirre J, Blumenthal S, Borgeat A. Ultrasound guidance and success rates of axillary brachial plexus block—I. *Can J Anaesth* 2007; **54**: 583
- 2 Aguirre J, Ruland P, Ekatodramis G, Borgeat A. Ultrasound versus neurostimulation for popliteal block: another vain effort to show a non-existing clinical relevant difference. *Anaesth Intensive Care* 2009; **37**: 665–6
- 3 Aguirre J, Valentin Neudorfer C, Ekatodramis G, Borgeat A. Ultrasound guidance for sciatic nerve block at the popliteal fossa should be compared with the best motor response and the lowest current clinically used in neurostimulation technique. *Reg Anesth Pain Med* 2009; **34**: 182–3
- 4 Antonakakis JG, Sites BD, Shiffrin J. Ultrasound-guided posterior approach for the placement of a continuous interscalene catheter. *Reg Anesth Pain Med* 2009; **34**: 64–8
- 5 Auroy Y, Benhamou D, Bagues L, *et al.* Major complications of regional anesthesia in France: The SOS Regional Anesthesia Hotline Service. *Anesthesiology* 2002; **97**: 1274–80
- 6 Auroy Y, Narchi P, Messiah A, Litt L, Rouvier B, Samii K. Serious complications related to regional anesthesia: results of a prospective survey in France. *Anesthesiology* 1997; **87**: 479–86

- 7 Bartussek E, Fatehi S, Motsch J, Grau T. Survey on practice of regional anaesthesia in Germany, Austria, and Switzerland. Part 1: quality assurance and training concepts. *Anaesthesist* 2004; **53**: 836–46
- 8 Bartussek E, Fatehi S, Motsch J, Grau T. Survey on practice of regional anaesthesia in Germany, Austria, and Switzerland. Part 3: methods in obstetric anaesthesia. *Anaesthesist* 2004; **53**: 993–1000
- 9 Bigeleisen PE. Nerve puncture and apparent intraneural injection during ultrasound-guided axillary block does not invariably result in neurologic injury. *Anesthesiology* 2006; **105**: 779–83
- 10 Bigeleisen PE. Ultrasound-guided infraclavicular block in an anticoagulated and anesthetized patient. *Anesth Analg* 2007; **104**: 1285–7
- 11 Bigeleisen PE, Moayeri N, Groen GJ. Extraneural versus intraneural stimulation thresholds during ultrasound-guided supraclavicular block. *Anesthesiology* 2009; **110**: 1235–43
- 12 Borgeat A, Aguirre J, Neudorfer C, Jutzi H. Severe brachial plexopathy after an ultrasound-guided single-injection nerve block for total shoulder arthroplasty in a patient with multiple sclerosis: what is the likely cause of this complication? *Anesthesiology* 2008; **109**: 750–1
- 13 Borgeat A, Blumenthal S. Nerve injury and regional anaesthesia. *Curr Opin Anaesthesiol* 2004; **17**: 417–21
- 14 Borgeat A, Capdevila X. Neurostimulation/ultrasonography: the Trojan war will not take place. *Anesthesiology* 2007; **106**: 896–8
- 15 Borgeat A, Ekatodramis G, Kalberer F, Benz C. Acute and nonacute complications associated with interscalene block and shoulder surgery: a prospective study. *Anesthesiology* 2001; **95**: 875–80
- 16 Casati A, Baciarello M, Di Cianni S, et al. Effects of ultrasound guidance on the minimum effective anaesthetic volume required to block the femoral nerve. *Br J Anaesth* 2007; **98**: 823–7
- 17 Clendenen SR, Riutort K, Ladlie BL, Robards C, Franco CD, Greengrass RA. Real-time three-dimensional ultrasound-assisted axillary plexus block defines soft tissue planes. *Anesth Analg* 2009; **108**: 1347–50
- 18 Danelli G, Fanelli A, Ghisi D, et al. Ultrasound vs nerve stimulation multiple injection technique for posterior popliteal sciatic nerve block. *Anaesthesia* 2009; **64**: 638–42
- 19 Denny NM, Harrop-Griffiths W. Location, location, location! Ultrasound imaging in regional anaesthesia. *Br J Anaesth* 2005; **94**: 1–3
- 20 Duggan E, El Beheiry H, Perlas A, et al. Minimum effective volume of local anesthetic for ultrasound-guided supraclavicular brachial plexus block. *Reg Anesth Pain Med* 2009; **34**: 215–8
- 21 Eichenberger U, Stockli S, Marhofer P, et al. Minimal local anesthetic volume for peripheral nerve block: a new ultrasound-guided, nerve dimension-based method. *Reg Anesth Pain Med* 2009; **34**: 242–6
- 22 Fredrickson MJ, Kilfoyle DH. Neurological complication analysis of 1000 ultrasound guided peripheral nerve blocks for elective orthopaedic surgery: a prospective study. *Anaesthesia* 2009; **64**: 836–44
- 23 Fronheiser MP, Light ED, Idriss SF, Wolf PD, Smith SW. Real-time, 3-D ultrasound with multiple transducer arrays. *IEEE Trans Ultrason Ferroelectr Freq Control* 2006; **53**: 100–5
- 24 Fronheiser MP, Wolf PD, Idriss SF, Nelson RC, Lee W, Smith SW. Real-time 3D color flow Doppler for guidance of vibrating interventional devices. *Ultrason Imaging* 2004; **26**: 173–84
- 25 Gonano C, Kettner SC, Ernstbrunner M, Schebesta K, Chiari A, Marhofer P. Comparison of economical aspects of interscalene brachial plexus blockade and general anaesthesia for arthroscopic shoulder surgery. *Br J Anaesth* 2009; **103**: 428–33
- 26 Grau T, Fatehi S, Motsch J, Bartussek E. Survey on current practice of regional anaesthesia in Germany, Austria, and Switzerland. Part 2: use, success rates and techniques. *Anaesthesist* 2004; **53**: 847–55
- 27 Kapral S, Greher M, Huber G, et al. Ultrasonographic guidance improves the success rate of interscalene brachial plexus blockade. *Reg Anesth Pain Med* 2008; **33**: 253–8
- 28 Kapral S, Krafft P, Eibenberger K, Fitzgerald R, Gosch M, Weinstabl C. Ultrasound-guided supraclavicular approach for regional anaesthesia of the brachial plexus. *Anesth Analg* 1994; **78**: 507–13
- 29 Klein SM, Fronheiser MP, Reach J, Nielsen KC, Smith SW. Piezoelectric vibrating needle and catheter for enhancing ultrasound-guided peripheral nerve blocks. *Anesth Analg* 2007; **105**: 1858–60
- 30 Kumar P, Brooks Gentry W. Ultrasound guidance in regional anaesthesia. *J Anesth Clin Pharmacol* 2007; **23**: 121–8
- 31 la Grange P, Foster PA, Pretorius LK. Application of the Doppler ultrasound bloodflow detector in supraclavicular brachial plexus block. *Br J Anaesth* 1978; **50**: 965–7
- 32 Latzke D, Marhofer P, Zeitlinger M, et al. Minimal local anaesthetic volumes for sciatic nerve blockade: evaluation of ED₉₉ in volunteers. *Br J Anaesth* 2010; **104**: 239–44
- 33 Liu SS, Zayas VM, Gordon MA, et al. A prospective, randomized, controlled trial comparing ultrasound versus nerve stimulator guidance for interscalene block for ambulatory shoulder surgery for postoperative neurological symptoms. *Anesth Analg* 2009; **109**: 265–71
- 34 Maecken T, Zenz M, Grau T. Ultrasound characteristics of needles for regional anaesthesia. *Reg Anesth Pain Med* 2007; **32**: 440–7
- 35 Marhofer P, Greher M, Kapral S. Ultrasound guidance in regional anaesthesia. *Br J Anaesth* 2005; **94**: 7–17
- 36 Marhofer P, Sitzwohl C, Greher M, Kapral S. Ultrasound guidance for infraclavicular brachial plexus anaesthesia in children. *Anaesthesia* 2004; **59**: 642–6
- 37 Mariano ER, Afra R, Loland VJ, et al. Continuous interscalene brachial plexus block via an ultrasound-guided posterior approach: a randomized, triple-masked, placebo-controlled study. *Anesth Analg* 2009; **108**: 1688–94
- 38 Mariano ER, Loland VJ, Ilfeld BM. Interscalene perineural catheter placement using an ultrasound-guided posterior approach. *Reg Anesth Pain Med* 2009; **34**: 60–3
- 39 Noble JR, Fronheiser MP, Smith SW. Real-time stereo 3D ultrasound. *Ultrason Imaging* 2006; **28**: 245–54
- 40 Oberndorfer U, Marhofer P, Bosenberg A, et al. Ultrasonographic guidance for sciatic and femoral nerve blocks in children. *Br J Anaesth* 2007; **98**: 797–801
- 41 O'Donnell BD, Iohom G. An estimation of the minimum effective anesthetic volume of 2% lidocaine in ultrasound-guided axillary brachial plexus block. *Anesthesiology* 2009; **111**: 25–9
- 42 Perlas A, Brull R, Chan VW, McCartney CJ, Nuica A, Abbas S. Ultrasound guidance improves the success of sciatic nerve block at the popliteal fossa. *Reg Anesth Pain Med* 2008; **33**: 259–65
- 43 Perlas A, Lobo G, Lo N, Brull R, Chan VW, Karkhanis R. Ultrasound-guided supraclavicular block: outcome of 510 consecutive cases. *Reg Anesth Pain Med* 2009; **34**: 171–6
- 44 Redborg KE, Antonakakis JG, Beach ML, Chinn CD, Sites BD. Ultrasound improves the success rate of a tibial nerve block at the ankle. *Reg Anesth Pain Med* 2009; **34**: 256–60
- 45 Riaz S, Carmichael N, Awad I, Holtby RM, McCartney CJ. Effect of local anaesthetic volume (20 vs 5 ml) on the efficacy and respiratory consequences of ultrasound-guided interscalene brachial plexus block. *Br J Anaesth* 2008; **101**: 549–56
- 46 Sites BD, Chan VW, Neal JM, et al. The American Society of Regional Anesthesia and Pain Medicine and the European Society

- of Regional Anaesthesia and Pain Therapy Joint Committee recommendations for education and training in ultrasound-guided regional anesthesia. *Reg Anesth Pain Med* 2009; **34**: 40–6
- 47** Smith SW, Ivancevich NM, Lindsey BD, *et al.* The ultrasound brain helmet: feasibility study of multiple simultaneous 3D scans of cerebral vasculature. *Ultrasound Med Biol* 2009; **35**: 329–38
- 48** Tedore TR, YaDeau JT, Maalouf DB, *et al.* Comparison of the transarterial axillary block and the ultrasound-guided infraclavicular block for upper extremity surgery: a prospective randomized trial. *Reg Anesth Pain Med* 2009; **34**: 361–5
- 49** Weintraud M, Marhofer P, Bosenberg A, *et al.* Ilioinguinal/iliohypogastric blocks in children: where do we administer the local anesthetic without direct visualization? *Anesth Analg* 2008; **106**: 89–93
- 50** Willschke H, Bosenberg A, Marhofer P, *et al.* Ultrasonographic-guided ilioinguinal/iliohypogastric nerve block in pediatric anesthesia: what is the optimal volume? *Anesth Analg* 2006; **102**: 1680–4