

RESPIRATION AND THE AIRWAY

Changes in airway configuration with different head and neck positions using magnetic resonance imaging of normal airways: a new concept with possible clinical applications

K. B. Greenland^{1,2,3*}, M. J. Edwards¹, N. J. Hutton¹, V. J. Challis⁴, M. G. Irwin³ and J. W. Sleight⁵

¹ Department of Anaesthesia and Perioperative Medicine, Royal Brisbane and Women's Hospital Brisbane, Butterfield Street, Herston, Brisbane, Queensland, Australia

² Burns, Trauma and Critical Care Research Centre, School of Medicine, The University of Queensland, Herston, Brisbane, Queensland, Australia

³ Department of Anaesthesiology, University of Hong Kong, Room 424, K Block, Queen Mary Hospital, Pokfulam Road, Hong Kong SAR

⁴ School of Mathematics and Physics, The University of Queensland, Brisbane, Queensland, Australia

⁵ Waikato Clinical School of the University of Auckland, Waikato Hospital, Hamilton, New Zealand

* Corresponding author. E-mail: french9a@yahoo.co.uk

Key points

- A new paradigm, considering the airway as a composite of two curves, is presented.
- This MRI study evaluated the effect of different head and neck positions on airway configuration.
- The optimum position for laryngoscopy is neck flexion of 35° and face plane extension of 15°.
- This provides objective evidence to support traditional teaching for sniffing position during laryngoscopy.

Background. The sniffing position is often considered optimal for direct laryngoscopy. Another concept of airway configuration involving a laryngeal vestibule axis and two curves has also been suggested. We investigated whether this theory can be supported mathematically and if it supports the sniffing position as being optimal for direct laryngoscopy.

Methods. Magnetic resonance imaging scans were performed in 42 normal adult volunteers. The airway passage was divided into two curves—primary (oro-pharyngeal curve) and secondary (pharyngo-glottis-tracheal curve). Airway configuration was evaluated in the neutral, extension, head lift, and sniffing positions. The airway passage, point of inflection (where the two curves meet), its tangent, and the line of sight were plotted on each scan.

Results. The point of inflection lay within the laryngeal vestibule in all positions. The head lift and sniffing positions caused the tangent to the point of inflection to approximate the horizontal plane. The sniffing, extension, and head lift positions caused a reduction in the area between the line of sight and the airway curve compared with the neutral position.

Conclusions. A two-curve theory is proposed as a basis for explaining airway configuration. The changes in these curves with head and neck positioning support the sniffing position as optimal for direct laryngoscopy. Application of this new concept to other forms of laryngoscopy should be investigated.

Keywords: anaesthetic techniques, laryngoscopy; equipment, airway; intubation, tracheal, position

Accepted for publication: 1 July 2010

In 1936, Magill¹ formally described the 'sniffing position' as elevation of the occiput and extension of the head at the atlanto-occipital joint. It is generally accepted as the best position for direct laryngoscopy. Bannister and Macbeth² refined direct laryngoscopy positioning by proposing a need for alignment of the mouth, pharyngeal, and laryngeal axes; later to be called the 'three axes alignment theory'. Horton and colleagues³ further developed this concept by determining 'ideal angles' for upper cervical flexion and lower cervical extension as 15° and 35°, respectively. These angles were a compromise of various values from the previous work and later validated by Horton's study.

Adnet and colleagues contested the validity of the sniffing position and of the three axes alignment theory in a series of papers.^{4–7} Their initial study⁴ examined eight healthy volunteers with normal airways using magnetic resonance imaging (MRI). They concluded that alignment of the three axes was impossible as shown in Figure 1 where the three axes are superimposed on one of the author's MRI scans. A follow-up study⁶ of 456 patients in both the sniffing and the extended positions during direct laryngoscopy found that there was no significant improvement with the sniffing position over simple extension of the head and neck, unless the patient was obese or had reduced neck mobility.

Criticisms of Adnet's studies were numerous and varied. An accompanying editorial⁸ did support Adnet's attempt to appraise the three axes alignment theory and called for a 'new conceptual framework to understand the mechanisms of laryngoscopy, a framework that moves beyond the three axes alignment theory'.

One of the authors (K.B.G.) has proposed an airway concept,⁹ relating different head and neck positions to changes in airway configuration. The airway passage may be considered as a Bézier spline (a parametric curve used to model smooth paths that can be controlled by adjusting a selection of points on the curve and the tangents to these points) rather than the alignment of three straight lines or axes. Although this curve is complex, we propose

for clinical applications that it may be divided into primary (oro-pharyngeal) and secondary curves (pharyngo-glotto-tracheal). According to Figure 2, the point where these curves meet (i.e. the point of inflection) appears to be within the laryngeal vestibule—the space from the epiglottis to the glottis. First, successful direct laryngoscopy requires that the primary curve and the laryngeal vestibule align with the line of sight.¹⁰ This may be achieved by reducing the area between the line of sight and the airway curve. Secondly, tracheal intubation with a Magill-shaped tube is facilitated by aligning the direction of the laryngeal vestibule with the trachea. We will examine how various head and neck positions cause changes to the two curves, the tangent to the point of inflection, the line of

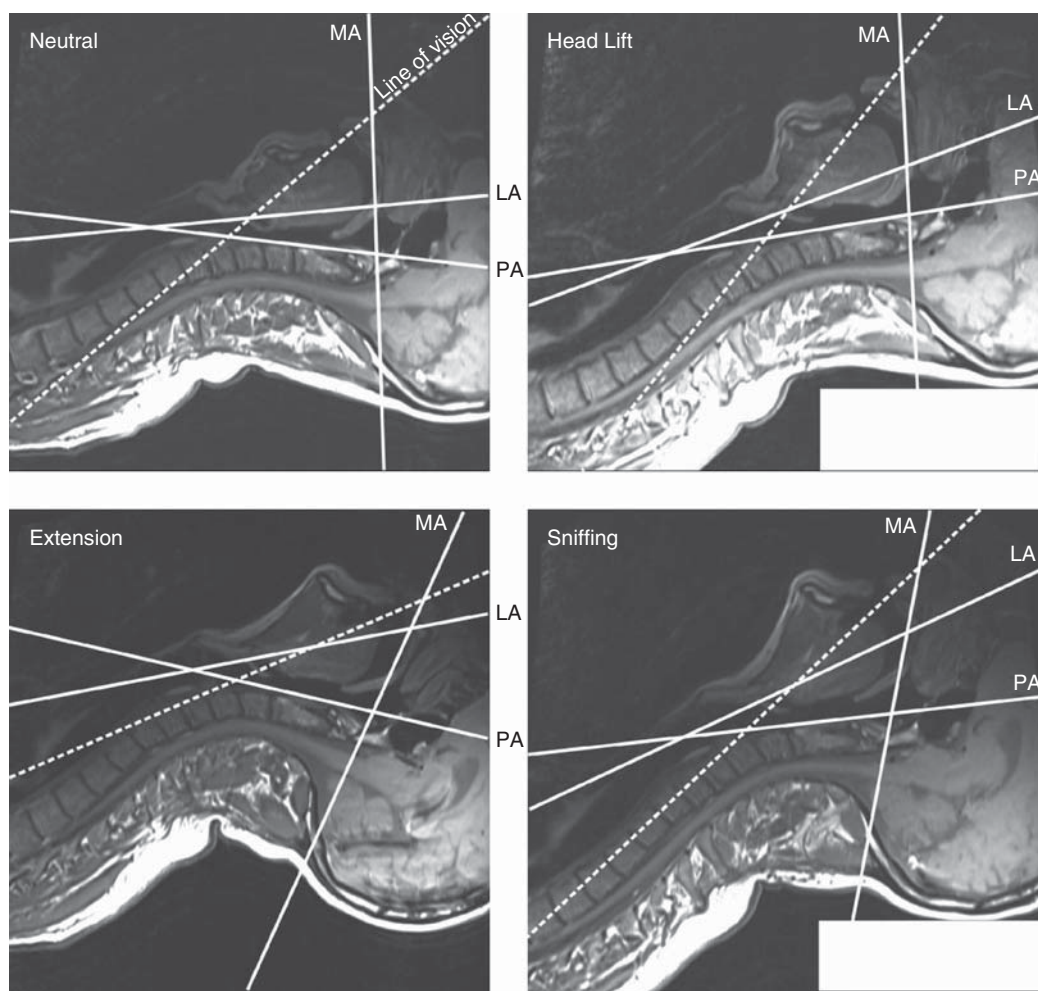


Fig 1 The MRI scans of one of the authors (K.B.G.) in different head and neck positions—neutral (no head elevation and vertical gaze), head lift (neck flexion to 35° and vertical gaze), head extension (no head elevation and face plane extension), and sniffing (flexion of the lower neck to 35° and extension of the face plane to 15°). The following axes are superimposed on the MRI scans. Mouth axis (MA) is defined as a straight line drawn parallel to the hard palate; pharyngeal axis (PA) is defined as a line passing through the anterior edge of the atlas and of the second cervical vertebra; laryngeal axis (LA) is defined as a straight line passing through the centres of the inferior (cricoid cartilage) and superior (base of epiglottis) orifices. The line of vision is defined as a straight line passing through the inferior extremity of the superior incisors and the posterior extremity of the superior portion of the cricoid cartilage as shown by the dotted line. The descriptions for the different axes by Adnet and colleagues⁴ were used to govern their positions on the scans.

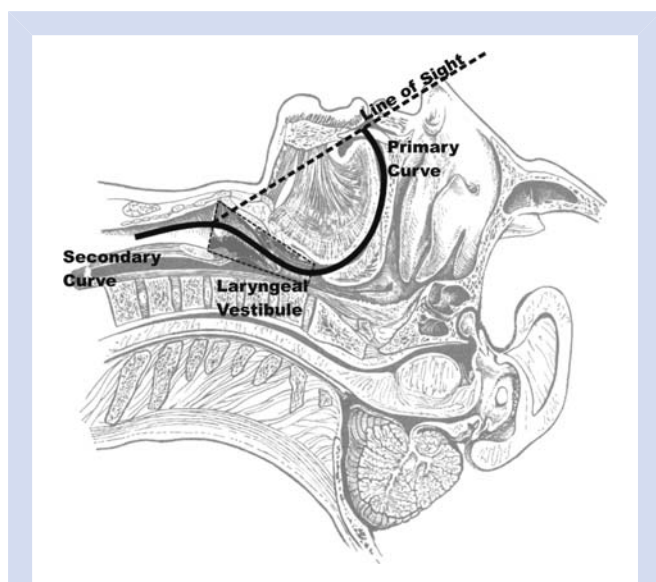


Fig 2 For clinical applications, the airway passage is divided into two curves—primary and secondary curves. The point where these curves meet appears to be within the laryngeal vestibule. Successful laryngoscopy and tracheal intubation requires alignment of both curves with the line of sight and the trachea.

sight, and the area between the line of sight and the curves.

Methods

After local institutional ethics committee approval, informed consent was obtained from 45 adult volunteers. Standard preoperative examination was used to exclude anatomical factors consistent with difficult airway management. Participants with either a past history or clinical signs of potentially difficult direct laryngoscopy, tracheal intubation (a modified Mallampati score of 3 or 4, mouth opening <30 mm, thyromental distance <65 mm, limited neck movement with <80° movement by the Wilson test,^{11 12} or upper airway disease), or both were excluded.

The following variables were recorded.

- (i) BMI (body weight in kilograms divided by the square of the height in metres; obesity was defined as a BMI of >30 kg m⁻²).
- (ii) Mouth opening (as the inter-incisor gap measured in millimetres, with the mouth fully open).
- (iii) Modified Mallampati classification (class I—soft palate, fauces, uvula, and pillars seen; class II—soft palate, fauces, and uvula seen; class III—soft palate and base of uvula seen; and class IV—soft palate not visible) performed without phonation.
- (iv) Thyromental distance was measured along a straight line from the thyroid notch to the lower border of the mandibular mentum with the head in full extension (a value of <65 mm is associated with difficult intubation).

- (v) The amplitude of neck and head movement, measured as described by Wilson and colleagues.^{11 12} This requires that the subject fully extends the head and neck. A pencil is placed flat on the forehead and the patient is asked to fully flex while the observer measures the change of angle in reference to a fixed point. This is then divided into >80° or <80°.
- (vi) Pathological conditions associated with difficulties in laryngoscopy, such as malformation of the face, cervical spondylosis, tumours of the airway, long-standing diabetes, sleep apnoea syndrome, limitation of mandibular anterior–posterior movement, and prominent upper incisors, were also recorded and these participants were excluded.

Fully conscious volunteers had MRI scans of the head and neck region. Four head and neck positions were studied:

- (i) the subject lying on a flat surface (MRI stretcher) without head extension or neck flexion with a vertical gaze (the neutral position);
- (ii) no head elevation and active flexion of the lower neck and head extension (the head extension position);
- (iii) head elevation only on a cushion producing neck flexion of 35° (the head lift position);
- (iv) neck flexion of 35° and face plane extension of 15° measured using a protractor³ outside the MRI scanning (the sniffing position).

The MRI scans were performed with a Magnetom 3.0 Tesla MRI scanner (Siemens Trio, Medical Solutions, Erlangen, Germany) with an anterior flex receive and posterior part of the head matrix. The acquisition technique was a spin echo sequence with a repetition time of 750 ms and an echo time of 11 ms. T1-weighted images were obtained in the sagittal plane.

Copies of the MRIs were imported as jpeg images into a graphic design software program (Inkscape, version 0.46). The sagittal slice at the centre of the airway passage was chosen. A Bézier spline starting at the tip of the top front incisors was drawn through the middle of the airway passage at the level of the junction of the hard and soft palates, at the level of the tip of the epiglottis, at the glottis, and the trachea at the level of the seventh cervical vertebra. The seventh cervical vertebra was chosen for the distal endpoint of the line to ensure that at least 2–3 cm of the distal portion of the curve corresponded to the subglottic axis. A second investigator verified the accuracy of these points and the airway curve.

The airway curve was divided into the oro-pharyngeal airway, which was designated as the primary curve, and the pharyngo-glotto-tracheal airway or secondary curve. The point of inflection (Fig. 3) where the primary and secondary curves met in each scan was calculated using a numerical software package (MatlabTM, version R14, Service Pack 3). When tracing the airway curve starting from the tip of the top front incisors, the primary curve is always curving towards the right, whereas the secondary one curves to the

left. The point of inflection is the point of zero curvature—where the line is temporarily straight between the primary and secondary curves. The scalable vector graphics (svg) file format utilized by Inkscape allows extraction of the curve data for numerical manipulation and calculation of the point of inflection in Matlab™. A tangent to the point of inflection (Fig. 3) was also calculated in Matlab™ and drawn for each scan. A proposed line of sight was drawn from the tip of the top front incisors to the middle of the glottis.

Changes in the angle between the tangent to the point of inflection and the horizontal plane (angle α in degrees) and the area between the line of sight and the section of the two curves from the incisors to the glottis (measured as

total pixel count and then normalized to the neutral curve) were calculated to reflect changes in the morphology of the curves with different head and neck positions (Fig. 4). Angle α and the calculated area were calculated using Matlab™ software. We wished to determine whether the reduction of these two values in the sniffing position explains why this position is good for direct laryngoscopy. In addition, the same values in other positions, namely head lift and extension, were examined to delineate how these positions may impact on direct laryngoscopy.

Power analysis was based on initial work⁹ performed on observation of the changes in airway configuration during MRIs of one of the investigators (K.B.G.). If a significant change in angle α is assumed to be 5°, then the estimated

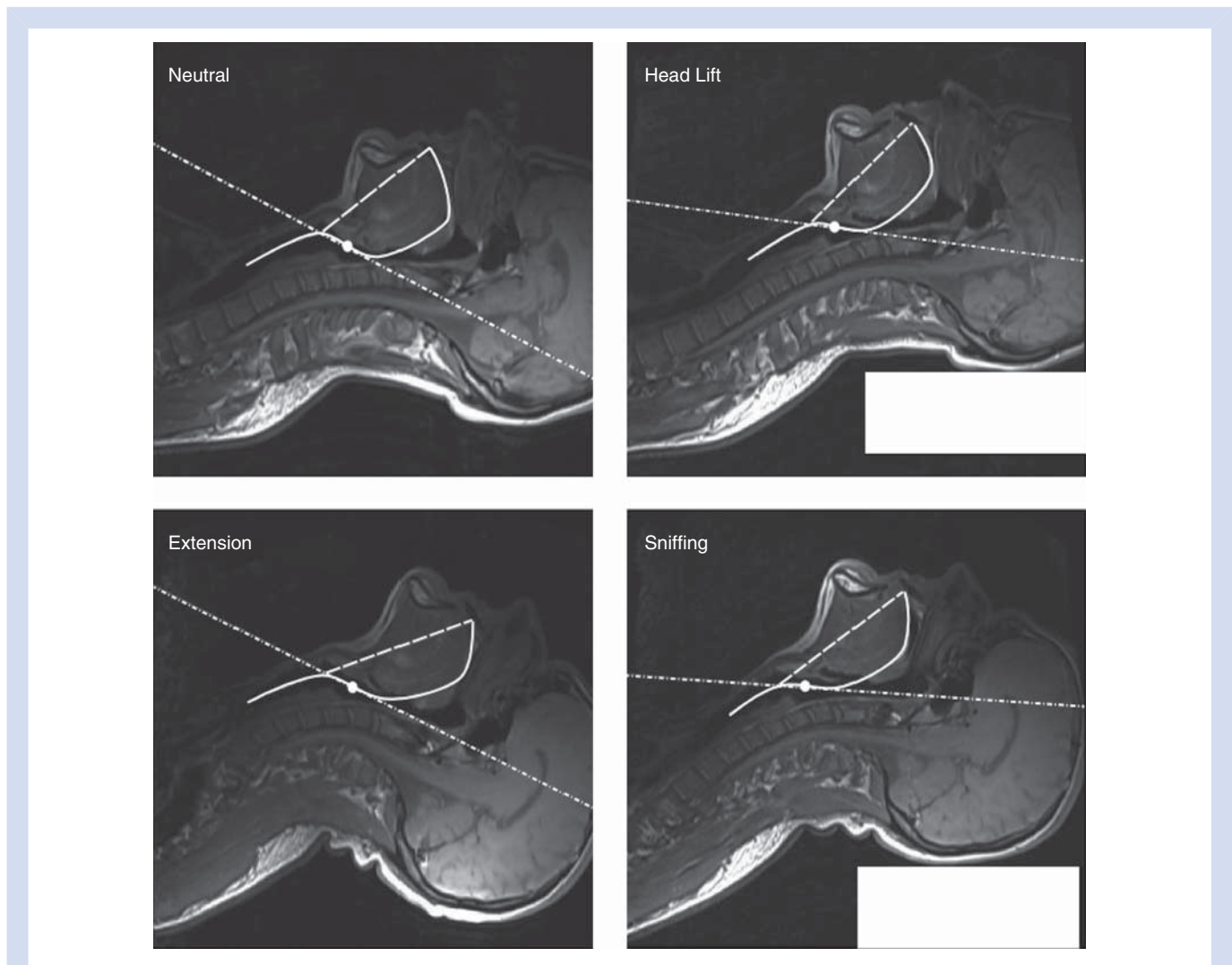


Fig 3 Changes in the airway passage configuration (solid curved line) in four positions: neutral (no head elevation and vertical gaze), head lift (neck flexion to 35° and vertical gaze), head extension (no head elevation and face plane extension), and sniffing (flexion of the lower neck to 35° and extension of the face plane to 15°). Line of sight (dashed line) is drawn from the upper front incisors to the middle of the glottic opening. The point of inflection (white dot) and its tangent (dash-dotted line) of the primary and secondary curves are plotted on each MRI scan. The sniffing position has the smallest area between the line of sight and the airway curve, therefore favouring successful direct laryngoscopy. This same position causes an anticlockwise rotation of the tangent to the point of inflection towards the tracheal axis which will assist passage of the tracheal tube during intubation (Fig. 5).

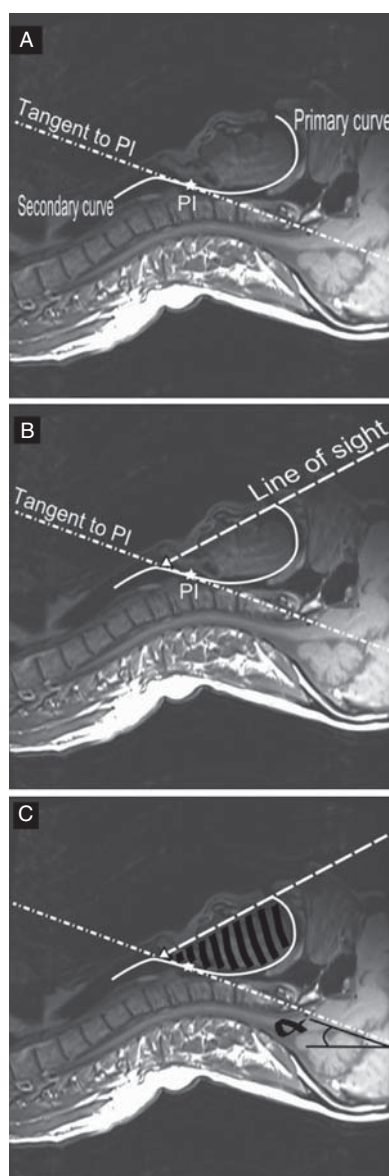


Fig 4 (A) Head and neck in the neutral position. The airway passage is shown as a solid line through the middle of the airway passage with the primary and secondary curves marked. The point of inflection where the primary and secondary curves meet is marked with a star. The tangent to the point of inflection (dash-dotted line) is marked. (B) The proposed line of sight from the tip of the top front incisors to the middle of the glottic opening (dashed line). (C) The values measured (angle α and shaded area). Angle α , the angle between the tangent to the point of inflection and the horizontal. Shaded area, the area between the line of sight and the section of the two curves from the incisors to the glottis.

standard deviation (SD) difference between the neutral and the sniffing positions is 6.9. A sample size of 44 participants would then provide 80% power at the 5% significance level to detect a difference of 5° in angle α between the neutral and sniffing positions. The data from the two groups were

Table 1 Patient characteristics expressed as mean (SD) (range) or number

Characteristics	n=42
Sex (F:M)	7:35
ASA (I:II)	39:3
Age (yr)	36.2 (7.1) (28–55)
Weight (kg)	76.4 (13.4) (47–110)
Height (m)	1.77 (0.08) (1.56–1.96)
BMI (kg m ⁻²)	24.4 (3.5) (17.1–33.2)
Mallampati's score (1:2)	31:11
Inter-incisor distance (mm)	45.0 (7.9) (30–60)
Mandibular length (mm)	109.5 (8.8) (85–128)
Thyromental distance (mm)	96.2 (13.4) (70–125)
Thyrosternal distance (mm)	95.7 (12.4) (70–134)

compared by paired Student's *t*-test using the Statistical Analysis System for Windows Release 9.2 (SAS Institute Inc., Cary, NC, USA). A *P*-value of <0.05 was considered statistically significant.

Results

Of the 45 participants scanned, three were excluded because they failed to maintain their head and neck position in the MRI scanner. The baseline characteristics of the remaining 42 adult volunteers are shown in Table 1.

The values in mean (95% CI) of angle α and the area between the line of sight and the airway curve in each position (i.e. neutral, extension, head lift, and sniffing) are shown in Tables 2 and 3. We used the neutral position as the control and compared all values produced by other positions with the neutral position.

The point of inflection always occurred somewhere between the base of the epiglottis and the tip of the arytenoids but was most commonly closer to the base of the epiglottis (Fig. 3). The tangent to the point of inflection rotated anticlockwise with head lift and with the sniffing position. These positions caused a mean reduction in angle α by 21.26° and 19.59°, respectively. In contrast, the extension position produced a reduction of only -0.27° in angle α , which was not statistically significant (Table 2).

The area between the line of sight and the airway curve was significantly reduced in both the extension and the sniffing positions. Head lift also significantly reduced this value (Table 3). However, when comparing the mean of the percentage difference in area for extension (5.8%), sniffing (8.7%), and head lift (3.8%) against the neutral position, the greatest reduction occurred with the extension and sniffing positions. Head lift caused an anticlockwise rotation of the line of sight and the tangent to the point of inflection: the latter being greater and leading to a resultant overall reduction in this area. The reduction in the area in the extension position was due to clockwise rotation of the line of sight. In contrast, the sniffing position caused a reduction in this area due to both clockwise rotation of the line of sight and

Table 2 Angle α , angles between the tangent to the point of inflection and the horizontal using the neutral position as the control. Values in mean (95% CI). **Indicates statistical significance

Position	Angles (°)	Difference from neutral (°)	P-value
Neutral position	23.04 (20.79, 25.29)	—	—
Head extension position	23.32 (21.52, 25.11)	-0.27 (-2.44, 1.89)	0.80
Head lift position	1.78 (-0.77, 4.34)	21.26 (18.55, 23.96)	<0.0001**
Sniffing position	3.45 (0.75, 6.16)	19.59 (16.64, 22.53)	<0.0001**

Table 3 Area between the line of sight and the airway curve using total pixel count and then subtracted from the neutral position value. Values in mean (95% CI). **Indicates statistical significance

Position	Area as per cent of neutral position area	Per cent difference in area compared with neutral position	P-value
Neutral position	100	—	—
Head extension position	94.2 (91.3, 97.0)	5.8 (3.0, 8.7)	<0.0002**
Head lift position	96.2 (93.4, 98.9)	3.8 (1.1, 6.6)	0.0075**
Sniffing position	91.3 (87.9, 94.8)	8.7 (5.2, 12.1)	<0.0001**

anticlockwise rotation of the tangent to the point of inflection (Fig. 5).

Discussion

The three axes alignment theory for direct laryngoscopy, proposed in 1944,² remains a common airway concept theory. Since the development of this theory, other studies^{4 6 7} have provided little objective evidence for the sniffing position being optimal for direct laryngoscopy. Alexopoulos and colleagues¹³⁻¹⁵ have previously used lateral X-rays to show the curvature of the upper airway from the epiglottis to the proximal part of the trachea. They related this curvature to pressure of tracheal tubes on the wall of the airway passage. The rest of the upper airway configuration (in particular, the pharyngeal section) was not included in their study nor were the differences in airway configuration examined with different head and neck positions.

One of the authors (K.B.G.) has previously described two phases of direct laryngoscopy and tracheal intubation.¹⁶ The static phase is positioning the head and neck to straighten the airway passage as much as possible before laryngoscopy. In the dynamic phase, the laryngoscope blade lifts the mandible and submandibular space contents to provide a line of sight to the glottis.

In this study, we focused on the static phase by examining the airway passage configuration in different head and neck positions. The geometric shape is represented as a composite of two Bézier splines (primary and secondary) orientated in opposite directions about their point of inflection. The mathematical formula for these curves is complex for both normal and abnormal airways. We have focused on certain important reproducible aspects of these curves

to describe a new airway concept, which is clinically useful and relevant to direct laryngoscopy and intubation.

For successful laryngoscopy, head and neck positioning should bring the line of sight as close as possible to all parts of the primary curve and the proximal section of the secondary curve between the point of inflection and the glottis. Therefore, the position with the smallest area between these two lines may be considered the optimal position, as it requires the least amount of tissue displacement during the dynamic phase of laryngoscopy. The laryngoscope blade will flatten the primary curve completely reducing the area to zero and a line of sight to the glottis is created. Successful tracheal intubation is facilitated by the alignment of line of sight, the laryngeal vestibule, and the tracheal axis. This configuration should produce a relatively straight passage through which a tracheal tube may pass. We have also assessed the effect of the anticlockwise rotation of the tangent to the point of inflection by measuring its angle to the horizontal plane (i.e. angle α) to see if this correlates with difficulty of laryngoscopy.

Head lift caused an anticlockwise rotation of (i) the line of sight and (ii) the tangent to the point of inflection on the MRI scans (Fig. 5), the latter being greater led to a resultant overall reduction in the area of the primary curve. The extension position leads to a clockwise rotation of the tangent to the point of inflection and a reduction in the primary curve area. The sniffing position countered the shift in the line of sight that occurred with head lift. This causes a further reduction in the area. These results support the sniffing position as the most favourable for direct laryngoscopy followed by extension, then head lift only, and finally the neutral position.

Head lift and sniffing positions caused a reduction in angle α due to an anticlockwise rotation of the tangent to the point

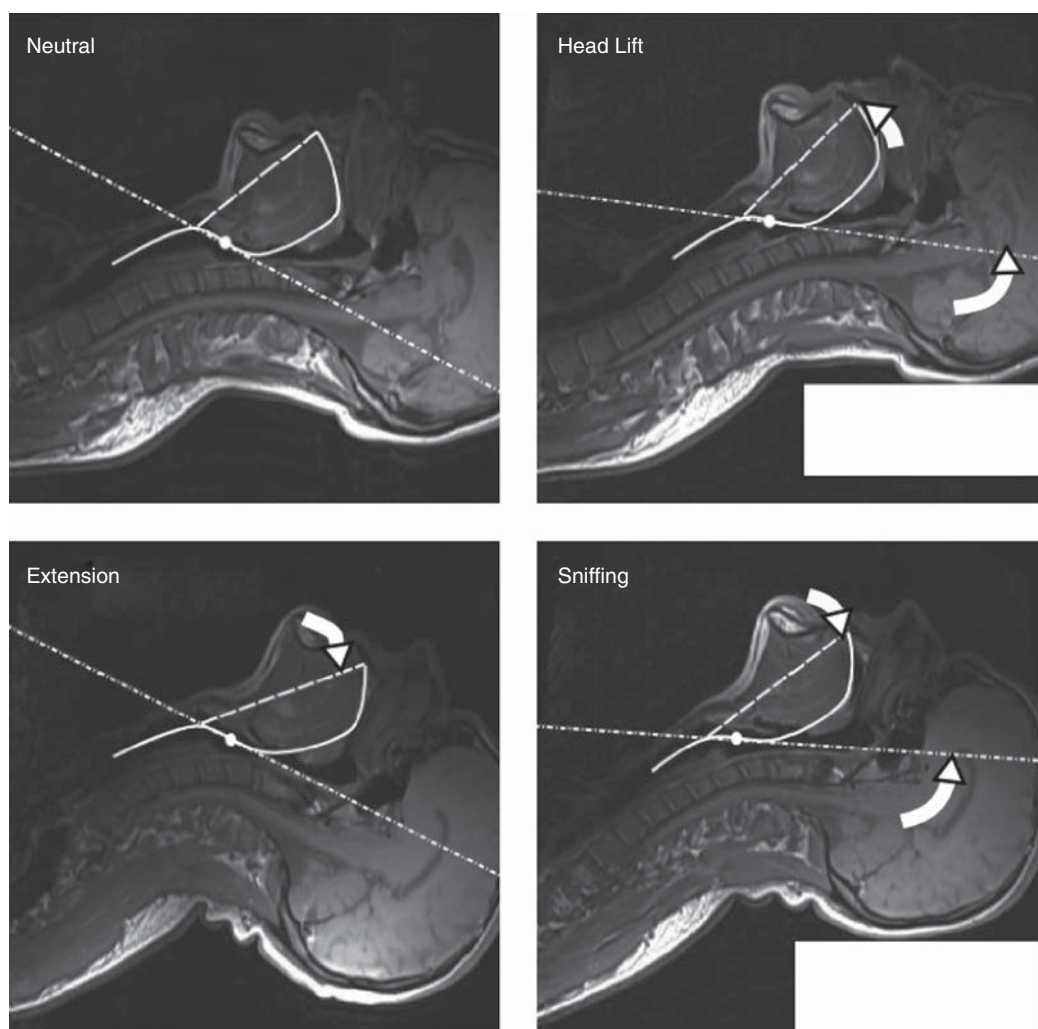


Fig 5 When the different head and neck positions are compared with the neutral position, the following occurs: Head lift—anticlockwise rotation of the line of sight and the tangent to the point of inflection (since the latter was greater, this causes an overall reduction in the primary curve). Extension—clockwise rotation of the tangent to the point of inflection and a reduction in the primary curve. Sniffing—a resultant clockwise rotation of the line of sight and an anticlockwise rotation of the tangent to the point of inflection. This creates the smallest primary curve and supports the sniffing position as the most favourable for direct laryngoscopy followed by extension, head lift only, and then the neutral position.

of inflection. In these positions, therefore, a curved tracheal tube is more likely to pass from the supraglottic airway into the trachea without impacting on the anterior wall of the subglottic space. In the neutral and extension positions without head lift, this angle is not reduced and the upper part of the laryngeal vestibule is well below the glottis. These positions would predictably be associated with some difficulty performing tracheal intubation without the use of aides such as a bougie^{17 18} to negotiate the secondary curve.

This theory may also predict the optimal position for the operator during direct laryngoscopy. In the extension position, the line of sight is close to the horizontal and the operator takes a lower position relative to the patient's head (e.g.

when otorhinolaryngologists perform suspension laryngoscopy with the patient in the extended position). In contrast, the sniffing position requires a more erect posture during laryngoscopy because of the anticlockwise rotation of the line of sight.

Practitioners involved in airway management now have a plethora of tools often purported as rescue devices after failed direct laryngoscopy. The strengths and weaknesses of these devices, and of various laryngoscope blades, may be more easily explained with a better understanding of airway morphology. For example, the GlideScope videolaryngoscope™ blade (Saturn Biomedical Systems, Burnaby, BC, Canada) has been shown to improve laryngoscopy views in both C&L grades 3 and 4.^{19 20} These devices

move the eye along the primary curve and provide a line of sight through the laryngeal vestibule to the glottis.

One weakness of this study is the use of awake, non-paralysed subjects without a laryngoscopy device (direct or indirect) *in situ*. These would cause changes in airway configuration. The use of MRI scanning avoided exposure of volunteers to potentially harmful radiation but meant that we were unable to use ferro-metallic laryngoscopy devices in this environment or in the confined space of the scanner. Another shortcoming was the use of an airway configuration that follows the midline. Direct laryngoscopy often uses laryngoscope blades that are inserted along the floor of the mouth and displace the tongue and submandibular tissues antero-laterally.

This study should be viewed as early supportive evidence for a new theory, which requires further development using a methodology that reflects the dynamic components of laryngoscopy. The use of computed tomography scans of anaesthetized subjects with airway devices *in situ* could be helpful but may be unethical in view of the radiation exposure involved.

In conclusion, we have attempted to provide a better understanding of the changes in normal airway morphology, which occur with various positions of the head and neck. Considering the airway passage as two curves with a point of inflection within the laryngeal vestibule provides operators with a new concept in airway management that may be applicable to both direct and indirect laryngoscopy devices. Future work using this MRI methodology in subjects with anatomical variations such as retrognathia and in those with cervical spine abnormalities may help clarify abnormal airway morphology and provide a clearer understanding of how various airway devices function during laryngoscopy and intubation.

Acknowledgements

The authors would like to thank all staff members who volunteered to be participants in this study. Thanks to Dr P. Allen and Dr D. Belavy (Department of Anaesthesia and Perioperative Medicine, Royal Brisbane and Women's Hospital) for their support. We also like to thank Ms J.S.F. Man (Department of Anaesthesiology, University of Hong Kong) for the statistical analysis and Raymond Buckley (Senior Radiographer—MRI, Department of Radiology, Royal Brisbane and Women's Hospital) for his assistance with the MRI scans.

Conflict of interest

None declared.

Funding

Funding for this project was provided by the following organizations: (i) Department of Anaesthesia and Perioperative

Medicine, Royal Brisbane and Women's Hospital; and (ii) Australian and New Zealand College of Anaesthetists.

References

- Magill IW. Endotracheal anesthesia. *Am J Surg* 1936; **34**: 450–5
- Bannister F, Macbeth R. Direct laryngoscopy and tracheal intubation. *Lancet* 1944; **244**: 651–4
- Horton WA, Fahy L, Charters P. Defining a standard intubating position using 'angle finder'. *Br J Anaesth* 1989; **62**: 6–12
- Adnet F, Borron SW, Dumas JL, et al. Study of the 'sniffing position' by magnetic resonance imaging. *Anesthesiology* 2001; **94**: 83–6
- Adnet F, Borron SW, Lapostolle F, Lapandry C. The three axis alignment theory and the 'sniffing position': perpetuation of an anatomic myth? *Anesthesiology* 1999; **91**: 1964–5
- Adnet F, Baillard C, Borron SW, et al. Randomized study comparing the 'sniffing position' with simple head extension for laryngoscopic view in elective surgery patients. *Anesthesiology* 2001; **95**: 836–41
- Adnet F. A Reconsideration of three axes alignment theory and sniffing position. *Anesthesiology* 2002; **97**: 754
- Isono S. Common practice and concepts in anesthesia: time for reassessment: is the sniffing position a 'gold standard' for laryngoscopy? *Anesthesiology* 2001; **95**: 825–7 (editorial)
- Greenland K. The sniffing and extension-extension position: the need to develop the clinical relevance. *Anaesthesia* 2008; **63**: 1013–4
- Marks RRD, Hancock R, Charters P. An analysis of laryngoscope blade shape and design: new criteria for laryngoscopic evaluation. *Can J Anaesth* 1993; **40**: 262–70
- Wilson ME. Predicting difficult intubation. *Br J Anaesth* 1993; **71**: 333–4
- Wilson ME, Spiegelhalter D, Robertson JA, Lesser P. Predicting difficult intubation. *Br J Anaesth* 1988; **61**: 211–6
- Alexopoulos C, Larsson SG, Lindholm CE. The anatomical shape of the airway during endotracheal intubation. *Acta Anaesthesiol Scand* 1983; **27**: 331–4
- Alexopoulos C, Larsson SG, Lindholm CE. Anatomical shape of the airway. *Acta Anaesthesiol Scand* 1983; **27**: 185–92
- Dimopoulos PA, Yarmenitis SD, Nikiforidis G, Alexopoulos CG. Anatomical shape of the airways in two different European populations. A radio-anatomical study of the airways. *Acta Radiol* 1995; **36**: 448–52
- Greenland K. A proposed model of direct laryngoscopy and tracheal intubation. *Anaesthesia* 2008; **63**: 156–61
- Nolan JP, Wilson ME. Orotracheal intubation in patients with potential cervical spine injuries. *Anaesthesia* 1993; **48**: 630–3
- Thiboutot F, Nicole P, Trepanier C, Turgeon A, Lessard M. Effect of manual in-line stabilization of the cervical spine in adults on the rate of difficult orotracheal intubation by direct laryngoscopy: a randomized controlled trial. *Can J Anaesth* 2009; **56**: 412–8
- Cooper RM. Use of a new videolaryngoscope (GlideScope) in the management of a difficult airway. *Can J Anaesth* 2003; **50**: 611–3
- Cooper RM, Pacey JA, Bishop MJ, McCluskey SA. Early clinical experience with a new videolaryngoscope (GlideScope) in 728 patients. *Can J Anaesth* 2005; **52**: 191–8