

## REGIONAL ANAESTHESIA

# Comparison between ultrasound-guided transversus abdominis plane and conventional ilioinguinal/iliohypogastric nerve blocks for day-case open inguinal hernia repair

C. Aveline<sup>1\*</sup>, H. Le Hetet<sup>1</sup>, A. Le Roux<sup>1</sup>, P. Vautier<sup>1</sup>, F. Cognet<sup>1</sup>, E. Vinet<sup>2</sup>, C. Tison<sup>2</sup> and F. Bonnet<sup>3</sup>

<sup>1</sup> Department of Anaesthetics and <sup>2</sup> Department of Surgery, Polyclinique Sévigné, 35510 Cesson-Sevigne, France

<sup>3</sup> Hopital Tenon, Department of Anesthesiology, Université Pierre and Marie Curie Paris VI, Assistance Publique-Hôpitaux de Paris, 75020 Paris, France

\* Corresponding author. E-mail: caveline@club-internet.fr

### Editor's key points

- This randomized, single-blinded study compared two different local anaesthetic blocks for hernia repair.
- Patients received either US-guided transversus abdominis plane (TAP) block or blinded ilioinguinal/iliohypogastric nerve (IHN) blocks.
- Ultrasound-guided TAP block produces less pain until 24 h with an opioid-sparing effect without differences at 3 and 6 months after surgery.
- Although the results are in some respects unsurprising, this is the first study to compare US-guided TAP block with IHN block in adult males undergoing inguinal hernia repair.

**Background.** Transversus abdominis plane (TAP) block has been reported to provide effective analgesia after lower abdominal surgery, but there are few data comparing ilioinguinal/iliohypogastric nerve (IHN) block with ultrasound-guided TAP block in patients undergoing inguinal hernia repair.

**Methods.** Two hundred and seventy-three patients undergoing day-case open inguinal hernia repair with a mesh were randomly allocated to receive either ultrasound-guided TAP block or blind IHN block with levobupivacaine 0.5%, before surgery. Patients were monitored for visual analogue scale (VAS) scores at rest (in the post-anaesthesia care unit, and at 4 and 12 h) and at rest and during movement (at 24, 48 h, 3 and 6 months). Pain at 6 months was also assessed using the DN4 questionnaire for neuropathic pain.

**Results.** Median VAS pain scores at rest were lower in the ultrasound-guided TAP group at 4 h (11 vs 15,  $P=0.04$ ), at 12 h (20 vs 30,  $P=0.0014$ ), and at 24 h (29 vs 33,  $P=0.013$ ). Pain after the first 24 h, at 3 and 6 months after surgery, and DN4 scores were similar in both groups ( $P=NS$ ). The proportion of patients with VAS >40 mm on movement at 6 months was comparable [18.2% [95% CI (12.2–26.1%)] vs 22.4% (15.8–30.6%)] in the TAP and IHN groups, respectively,  $P=0.8$ . Postoperative morphine requirements were lower during the first 24 h in the TAP block group ( $P=0.03$ ).

**Conclusions.** Ultrasound-guided TAP block provided better pain control than 'blind' IHN block after inguinal hernia repair but did not prevent the occurrence of chronic pain.

**Keywords:** anaesthesia, regional; anaesthetic techniques: transversus abdominis plane block, ilioinguinal nerve block, iliohypogastric nerve block; surgery, day case; surgery, inguinal herniorrhaphy; pain, postoperative

Accepted for publication: 8 November 2010

Inguinal hernia repair is commonly performed under sedation or general anaesthesia combined with an ilioinguinal/iliohypogastric nerve (IHN) block or surgical field infiltration with a long-acting local anaesthetic (LA) agent.<sup>1–3</sup> Preoperative and immediate postoperative pain is associated with the occurrence of chronic pain with reported frequency from 0% to 54%.<sup>4–6</sup> LA infiltration improves acute postoperative pain management, decreases postoperative visual analogue scale (VAS) scores, opioid demand, and time to first rescue analgesic administration.<sup>3–7</sup> A blind injection of LA solution is usually performed after perception of a loss of resistance,

between the external and internal oblique muscles fascia or between the internal oblique muscle and the transversus abdominis muscle.<sup>8–9</sup> Recently, the transversus abdominis plane (TAP) block has been described as an effective technique to reduce postoperative pain intensity and morphine consumption after lower abdominal surgery.<sup>10–11</sup> The TAP block is easily performed under ultrasound guidance.<sup>12</sup> The real-time assessment of the LA injection between internal oblique and transversus abdominis muscles guarantees distribution of the LA solution to the nerves lying under the fascia of the transversus abdominis muscle, including IHN.

There are no data on the use of TAP block in patients undergoing inguinal hernia repair in comparison with conventional IHN block. We thus conducted a prospective randomized study to compare the efficacy of the ultrasound-guided TAP block and conventional IHN block on both immediate post-operative pain and chronic pain after inguinal hernia surgery performed in day-case patients.

## Methods

After local ethical committee approval (*Comité de Protection des Personnes soumises à une Recherche Biologique du Centre Hospitalo-Universitaire de Rennes*) and written informed consent, 275 consecutive adult male patients of ASA physical status I–III undergoing elective primary unilateral open inguinal hernia repair under combined general anaesthesia and ultrasound-guided TAP or IHN blocks were enrolled in the study between September 2007 and December 2008. All surgical procedures were performed by the same two trained surgeons (E.V. and C.T.), using the Lichtenstein's technique (open repair of inguinal hernia with a mesh). Patients were discharged home on the same day. Patients were allocated randomly by sealed envelopes, according to a computer-generated sequence of random numbers, to undergo ultrasound-guided TAP block (TAP group) or IHN block by the loss-of-resistance technique (IHN group). Exclusion criteria were: inability to consent to the study, age  $\leq 18$  yr, BMI  $\geq 40$  kg m $^{-2}$ , skin infection at the puncture site, contra-indication to ketoprofen, paracetamol, or LA agents, chronic hepatic or renal failure, and pre-operative opioid or non-steroidal anti-inflammatory drugs treatment for chronic pain. Patients were also instructed how to make use of a 100 mm VAS graded from 0 (no pain) to 100 (most severe pain). On the day of the surgery, patients presented to the ambulatory surgery unit at 7.15 a.m. They were premedicated with oral 1 mg alprazolam 1 h before surgery. All the blocks were performed before operation by three anaesthetists (C.A., H.H., and A.L.) experienced in locoregional anaesthesia and who had each completed more than 500 ultrasound-guided blocks. Locoregional analgesia procedures were performed using full aseptic technique. Heart rate (three-lead ECG), non-invasive arterial pressure, and oxygen saturation were continuously monitored during the procedure; supplemental oxygen (2–3 litre min $^{-1}$ ) was administered via nasal prongs.

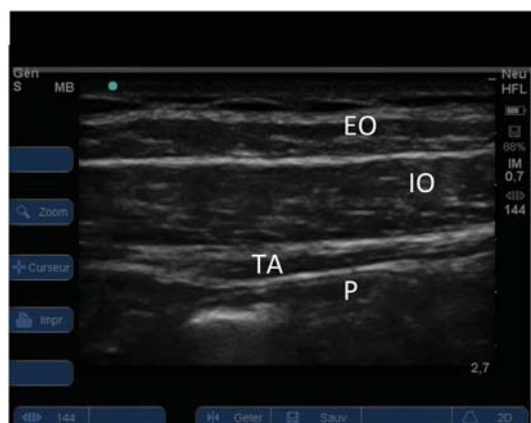### Conventional IHN block (IHN group)

Patients were placed in the supine position. The skin of the anterior and lateral parts of the abdominal wall was disinfected with 5% alcoholic povidone-iodine. A total of levobupivacaine 0.5% (1.5 mg kg $^{-1}$ ) w/v (Chirocaine®, Abbott, France) were divided into two equal doses. The first dose was injected with a needle entry point localized at one-third of a distance along a line from the anterior superior iliac spine to the umbilicus, and after detection of the second loss-of-resistance when the needle tip crosses the internal oblique muscle aponeurosis. The second dose of levobupivacaine was injected after

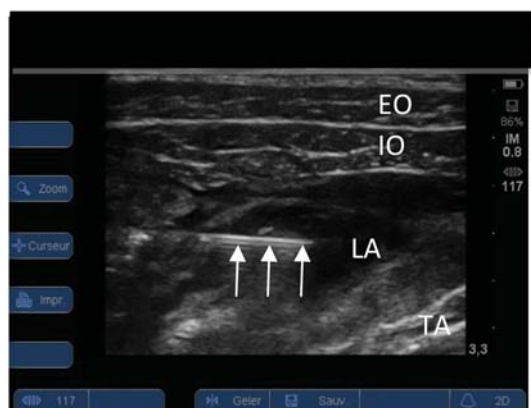obtaining the first fascial click with a needle entry point localized at one-third of a line joining the pubic tubercle and the anterior superior iliac spine. Patients were blinded to the block technique by a 'sham' ultrasound probe placed immediately cephalad to the needle entry point with the screen facing away from the patient. US equipment was in the stand-by mode and was not used to optimize injection during the procedure in this group.

### Ultrasound-guided TAP block (TAP group)

Patients were positioned in the supine position. After skin disinfection with 5% alcoholic povidone-iodine solution, the abdominal wall was scanned using a linear array transducer probe (6–13 MHz) in the multibeam mode, connected to a portable ultrasound unit (S-Nerve®, SonoSite™, Bothell, WA, USA). The edge of the probe was covered by a sterile plastic transducer sheath (Intercover®, Microtek Medical, USA) and a sterile gel (Asept®, Asept Inmed, Quint Fonsegrives, France) was applied on the skin. The ultrasound probe was initially positioned on the anterior wall with the medial head of the probe at the level of umbilicus. Adjustments were made to obtain optimal images until rectus abdominis muscle was observed. Then, the probe was replaced laterally towards the anterolateral part of the abdominal wall between the iliac crest and the subcostal margin. The orientation of the probe was perpendicular to a line joining the anterior superior iliac spine and the inferior rib to obtain a transverse view of the abdominal layers. The probe was tilted, rotated, or both to improve visualization of the three layers of the lateral abdominal wall, respectively, from superficial to the depth, external oblique, internal oblique, transversus abdominis, and, most deeply, peritoneal cavity (Fig. 1). After LA infiltration with lidocaine 2% (2 ml) w/v, an 80 mm, 22 G short-bevel needle (Uniplex Nanoline®, Pajunk, Germany) was advanced from an anterolateral to a medial direction using the in-plane insertion with ultrasound real-time assessment. The entry point was distant of the lateral side of the probe to obtain a needle-beam angle of more than 45° insuring visibility of the entire needle during the procedure. The progression of the needle, visible as a bright hyperechoic line, was assessed under direct ultrasonography. The injection site was defined between aponeurosis of internal oblique and transversus abdominis muscles (Fig. 2). During insertion, the transducer was moved with careful manipulation to continuously visualize the shaft and the tip of the needle and the aforementioned structures. If necessary, saline 0.9% (1 ml) was injected to optimize the tip location with small in-and-out movements. When the tip was correctly located in the targeted plane, levobupivacaine 0.5% (1.5 mg kg $^{-1}$ ) w/v was injected with intermittent aspiration and the correct placement of the needle was confirmed by expansion of the LA solution as a dark shadow between aponeurosis of the internal oblique (which moved anteriorly) and the transversus abdominis muscles pushing the muscle deeper. In this group, a second injection of saline 0.9% was performed s.c. at the level of the second puncture site to ensure blinding of the process.



**Fig 1** Sonographic view of the three lateral abdominal muscles layer obtained with a 13–6 MHz linear transducer. The orientation of the probe was perpendicular to a line joining the anterior superior iliac spine and the inferior rib to obtain a transverse view of the abdominal layers. EO, external oblique; IO, internal oblique; TA, transversus abdominis; P, peritoneum.



**Fig 2** Sonographic view of a TAP block injection with the needle (arrows) advanced using an in-plane approach with the tip introduced between the aponeurosis of transversus abdominis (TA) and internal oblique (IO) muscles. LA, local anaesthetic.

### General anaesthesia and postoperative analgesia

Just after locoregional procedure, all patients received a single-dose antibiotic prophylaxis (cefazoline 2 g). After a 30 min delay, general anaesthesia was induced with propofol ( $1.5\text{--}2\text{ mg kg}^{-1}$ ) and sufentanil ( $0.3\text{ }\mu\text{g kg}^{-1}$ ) without neuromuscular block, and the patient's airway was maintained using a laryngeal mask. Anaesthesia was maintained with sevoflurane ( $0.8\text{--}1\%$ ) in a 50% mixture of oxygen in air. Patients were allowed to receive a bolus of sufentanil  $0.1\text{ }\mu\text{g kg}^{-1}$  to maintain heart rate or systolic arterial pressure within 30% of baseline values. All patients received paracetamol 1 g and ketoprofen 100 mg i.v. and droperidol 1.25 mg i.v. as antiemetic prophylaxis after induction of anaesthesia.

In the post-anaesthetic care unit (PACU), patients received 3 mg i.v. morphine boluses at 5 min intervals, until VAS score at rest was  $\leq 30$  mm. After discharge from the PACU, they received a combination of paracetamol 1 g at 6 h intervals and ketoprofen 150 mg 12 hourly. Patients were given four tablets a day of immediate release oral morphine (Actiskenan<sup>®</sup> 20 mg, Bristol-Myers, Paris, France) for use as a rescue analgesia. Patients were discharged home from the ambulatory surgical unit on the day of surgery when they were pain free (VAS score  $\leq 40$  mm on coughing), without postoperative nausea and vomiting (PONV), and when they completed all discharge criteria. Before leaving the unit, patients were instructed for completion of the DN4 questionnaire for evaluation of the neuropathic components of pain.<sup>13</sup>

### Measures and outcomes

Pain assessments were scored at rest (VASr) before discharge from the PACU, and 4 and 12 h after surgery, by an anaesthetist unaware of the patient's randomization. Patients were systematically evaluated by an independent observer (patients' physician), on the first postoperative day (POD) at home, for VAS scores at rest and on movement (VASm). PONV occurring in the ambulatory unit was treated with ondansetron 4 mg i.v. and at home with orally dispersible ondansetron 8 mg. Other variables recorded were: intra-operative dose of sufentanil, amount of i.v. morphine used in the PACU, oral morphine requirement on the first two PODs, LA complication, leg weakness, urinary retention, and quality of sleep using a 10-point scale (0, worst sleep quality; 10, no sleep disturbance, on POD1, and 3 and 6 months after surgery).

A telephone interview was performed at 3 and 6 months after surgery to assess the persistence of pain. Patients were asked whether they had pain at rest and on movement (VAS scores) at the site of hernia repair, in the testis, or both. Patients were also asked to assess interaction of pain with their daily activities and to fill up the DN4 questionnaire to estimate the probability of neuropathic pain.<sup>13</sup> The DN4 questionnaire was established by patients and their physicians with a total of 10 items (seven evaluated with question and three obtained with examination). The total score was noted, counting 1 for each yes and 0 for each no, with high probability of neuropathic pain if the patients score is  $\geq 4$ .

### Statistical analysis

The primary endpoint was the incidence of VAS scores  $\geq 40$  mm during movement 6 months after surgery. On the basis of previous studies<sup>1</sup> assuming a significant difference of 40% in the incidence of VAS  $\geq 4$  at 6 months after surgery with a type I error of 0.05 and a power of 0.8, a sample size of 130 patients per group was required. We decided to include 275 patients to take into account possible loss of follow-up at 6 month evaluation. Data were analysed using the Statistical Package for the Social Science Version (SPSS for Windows, release 10.0; SPSS, Chicago, IL, USA). A



Kolmogorov–Smirnov test was used, and stratified distribution plots were examined to verify the normality of distribution of continuous variables. Baseline characteristics (age, duration of surgery, ASA scores, BMI, Apfel scores, and preoperative VAS scores) were compared across treatment groups using two-way analysis of variance (ANOVA) or Fisher's exact test. The total amount of oral morphine (until POD2) and i.v. titrated morphine in PACU were analysed by using an ANOVA. Repeated-measures (VASr, VASm) were evaluated using two-way ANOVA and *post hoc* comparisons at various times using Bonferroni's type I error correction for multiple comparisons. VAS scores, morphine requirement, sufentanil requirement, and DN4 scores were expressed as median and 25th–75th percentiles. Quantitative variables, such as anthropometric parameters, duration of surgery, and sleep disturbance scores, were expressed as mean (SD). Side-effects and the proportion of patients with VASm score  $\geq 4$  and with DN4 score  $\geq 4$  were assessed using Fisher's exact test and expressed as percentages with 95% confidence interval (95% CI). No interim analysis was planned during the study and  $P=0.05$  was set as the threshold for statistical significance.

## Results

Among the 275 selected patients, two were withdrawn after they withdrew their consent for study continuation. Patient characteristic, preoperative pain score, intraoperative sufentanil, and duration of surgery were similar in the groups (Table 1). Three months after hernia repair, two patients in the TAP group and one in the IHN group could not be contacted by telephone. At 6 months, data were complete for 132 of the 134 and 134 of the 139 patients in the TAP and IHN groups, respectively.

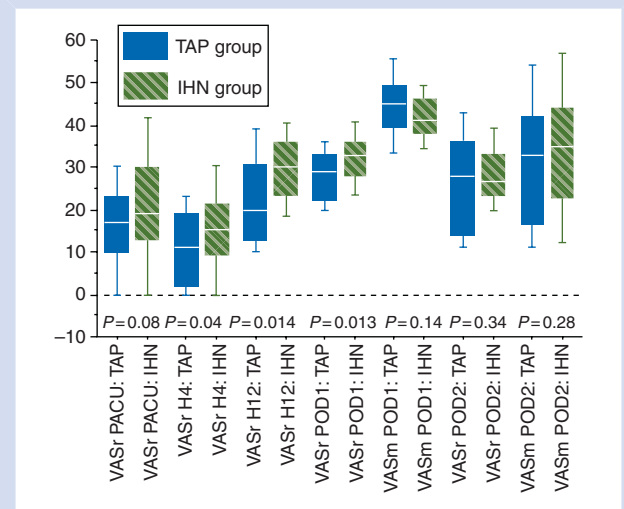
Patients who received a TAP block expressed significantly less pain at rest on VAS scores at 4, 12, and 24 h (Fig. 3). No significant differences were noted between the two groups for VAS scores at rest in the PACU and on movement at POD1 and POD2 (Fig. 3). During stay in the PACU, i.v. morphine titration doses were low and comparable in the two groups [median 0 (0–3) mg and 0 (0–0) mg in the IHN and TAP groups, respectively,  $P=0.15$ ]. However, patients in the TAP group required less oral morphine tablets during the two PODs (Table 2).

Three months after surgery, pain scores at rest were comparable in the two groups and also pain during movement (Fig. 4). At the same time, the median (IQR) DN4 scores were 4 (1–6) in the TAP group and 4 (1–7) in the IHN group ( $P=0.24$ ). Ten patients in the TAP group and 11 patients in the IHN group reported that pain interfered with their daily activities ( $P=0.23$ ).

Six months after inguinal hernia repair, the proportion of patients with VAS scores  $\geq 4$  on movement was 18.2% [95% CI (12.2–26.1%)] in the TAP group and 22.4% [95% CI (15.8–30.6%)] in the IHN group ( $P=0.8$ ). At 6 months, VAS scores at rest and during movement were comparable

**Table 1** Patients' characteristics and clinical features. Values are reported as mean (SD; range), median (25th–75th percentiles), or number of subjects, as indicated. BMI, body mass index. There were no significant differences between the groups

	TAP group (n=134)	IHN group (n=139)
Age (yr)	58 (13; 31–84)	60 (12; 41–83)
BMI ( $\text{kg m}^{-2}$ )	26 (4; 22–37)	27 (3; 18–38)
ASA scores (I/II/III)	82/33/19	74/51/14
Apfel scores	1 (1–2)	1 (1–2)
Preoperative pain score (0–100 mm)	9 (5–21)	11 (5–19)
Duration of surgery (min)	48 (12)	51 (13)
Intraoperative sufentanil ( $\mu\text{g}$ )	26 (25–28)	26 (23–28)



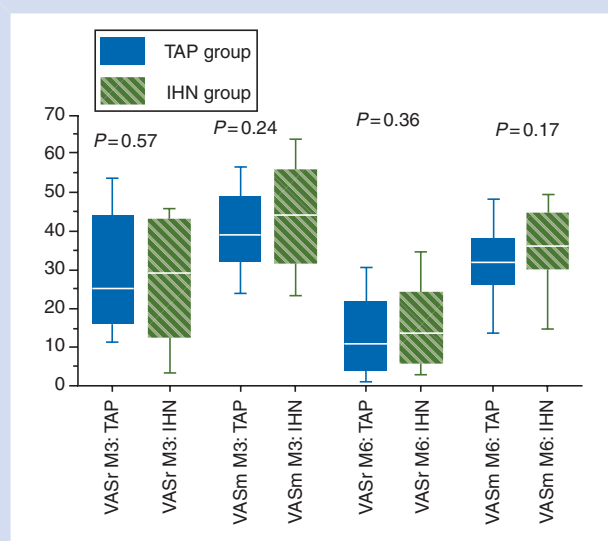
**Fig 3** Median pain intensity scores (y-axis, VAS in mm) at rest (VASr) in the PACU and ambulatory unit, and at rest and on movement (VASm) on POD1 and POD2. Data expressed as median (horizontal bar) with 25th–75th (boxes) and the 10th–90th (whiskers) percentiles. Patients in the TAP group had lower VAS scores at rest than those in the IHN group at 4 h ( $P=0.04$ ), 12 h ( $P=0.0014$ ), and 24 h ( $P=0.0013$ ). No differences were noted in the PACU, after POD1 and on deambulation.

between the groups (Fig. 4). Only two patients in each group had VAS scores during movement higher than 6.

No difference was noted for DN4 questionnaire scores, 6 months after surgery [3 (1–7) vs 4 (2–7) in the TAP and IHN groups, respectively,  $P=0.46$ ]. The proportion of patients with a DN4 score  $\geq 4$  was 13.6% [95% CI (8.8–20.5%)] in the TAP group and 15.7% [95% CI (10.2–23.2%)] in the IHN group,  $P=0.64$ . The incidence of PONV until POD1 was not different between the groups (Table 2) with no differences in ondansetron use at home (5.9% vs 9.3% in the TAP and IHN groups, respectively,  $P=0.69$ ). The sleep quality score

**Table 2** PONV, DN4 scores, oral opioid requirements, and sleep quality. <sup>†</sup> $P=0.03$  between the groups. Values are reported as mean (sd), median (25th–75th percentiles) or percentages (95% CI), as indicated. Data for PONV and oral morphine requirement were analysed for the entire cohort (134 in the TAP group and 139 in the IHN group) whereas for sleep quality (\*) analysis was complete for 132 of the 134 patients in the TAP group at M3 and M6, and in 138 of the 139 patients and 134 of the 139 patients at M3 and M6, respectively, in the IHN group. PONV, postoperative nausea and vomiting; POD, postoperative day. Morphine doses were reported in tablets of oral morphine (Actiskenan<sup>®</sup>) containing 20 mg of immediate release morphine sulphate

Parameter	TAP group	IHN group
PONV (POD0–POD1) (%)	8.2 (4.6–14.1)	10.1 (5.8–16.6)
Oral morphine requirement (POD0–POD2)	3 (1–4)	4 (2–7) <sup>†</sup>
Sleep quality POD1	7 (3)	5 (3)
Sleep quality M3*	8 (5)	7 (3)
Sleep quality M6*	9 (2)	8 (2)



**Fig 4** Median VAS scores (y-axis, VAS in mm) at rest (VASr) and on movement (VASm) 3 (M3) and 6 months (M6) after surgery. Data expressed as median (horizontal bar) with 25th–75th (boxes) and the 10th–90th (whiskers) percentiles. No differences were noted at rest and movement between the TAP and IHN groups. Data are complete for 132 of the 134 patients at M3 and M6 in the TAP group. At 6 months, data were complete for 132 of the 134 and 134 of the 139 patients in the TAP and IHN groups, respectively.

was slightly lower during the first postoperative night in the IHN group but not statistically different ( $P=0.07$ ) and was similar at 3 and 6 months after surgery (Table 2). No septic complication occurred in the two groups, and no urinary retention was noted during the postoperative course. Only one patient in the IHN group could not be discharged on the day of surgery. This patient presented with a femoral

extension of the LA block and was admitted to the surgical ward and discharged the next day after complete recovery. One patient in the IHN group required re-operation for an inguinal haematoma 1 week after the initial procedure. Two patients complained of pain during sexual intercourse (ejaculation) at 6 months. In the TAP group, pain interfered with daily activity (climbing stairs and/or standing longer than 45 min) in six patients at 6 months after surgery and nine patients in the IHN group ( $P=0.45$ ).

## Discussion

Several studies have documented that the TAP block provided effective analgesia during the first 24 h after surgery in a series of lower abdominal or pelvic surgical procedures.<sup>10 12 14–16</sup> Up to now, these studies included a limited number of patients for each surgical procedure, and comparisons were performed with a control group receiving systemic analgesia. Complementary information is still required concerning the TAP block compared with other techniques of regional anaesthesia in terms of efficacy and side-effects. Hernia repair induces parietal pain depending on IHN distribution. Parietal nerves infiltration, usually performed blindly, has been documented to provide pain relief during the first postoperative hours.<sup>17</sup> However, after IHN block, the duration of the block is not prolonged enough to allow pain control during all the postoperative period,<sup>17</sup> and pain relief can also be incomplete.

In the current study, pain intensity at rest was lower during the first 24 h after an ultrasound-guided TAP block compared with an IHN block. The difference in pain scores was not observed for pain on movement on the first POD and this could be explained by the duration of the block in both groups that did not extend until 24 h. Morphine demand was decreased in patients who benefited from a TAP block, but the difference in morphine consumption between the two groups was not important enough to account for a difference in the incidence of PONV. The systematic use of droperidol and non-steroidal anti-inflammatory and the lack of use of  $N_2O$  are probably implicated in the absence of a difference in PONV. A more cephalad extension of sensory block with the ultrasound-guided TAP block also probably accounted for the lower postoperative VAS scores and opioid requirements. There was also a trend to an improvement in sleep quality on the first postoperative night in the TAP block group, but the difference was not statistically significant.

In the control group, IHN block was performed blindly and it is likely that in some patients, LA solution could have been distributed into the s.c. layer or within muscle planes explaining less efficient anaesthesia.<sup>18 19</sup> In agreement, Weintraud and colleagues<sup>20</sup> have reported in children that suitable diffusion of the LA solution between the internal oblique and transversus abdominis muscles occurred only in 14% when the block was performed blindly. They documented an 80% incidence of failed block when LA was injected deeper than the transversus abdominis muscle and 100% when injected

superficially to the internal oblique muscle.<sup>20</sup> In addition, the location of the IHN varies with frequent division of the nerves at the level of the iliac crest.<sup>21</sup> The site of penetration of the two nerves towards the abdominal wall muscles also varies, so that the more proximal the nerves are blocked, the more effective the block could be. Nerve endings anaesthetized by the TAP block originate from T7 to L1 and include the IHN.<sup>11</sup> Although the TAP block can be performed blindly,<sup>10 11</sup> based on the click or loss of resistance perceived when the needle passes through the fascia of the external and internal oblique muscles, ultrasound guidance is likely to improve the reliability of the block. Ultrasound allows to precisely visualize the three muscle layers, the peritoneum and intraperitoneal visceral structures, and also the real-time assessment of the LA distribution characterized by an anechoic image below the aponeurosis of the internal oblique and transversus abdominis muscles.

Our study included enough patients (134 and 139 in the TAP and IHN groups, respectively) with low loss to follow-up at 6 months (two and five in the TAP and IHN groups, respectively) to obtain information about the most frequent side-effects and complications induced by the ultrasound-guided TAP block. No such complications were observed, especially any extension of the block to the femoral nerve, urinary retention, or puncture of intraperitoneal viscera. Noteworthy, no such complications occur in the IHN group except one case of extension of the block to the femoral nerve. This complication is related to an extension of LA solution deep to the transversus abdominis and the fascia transversalis.<sup>23</sup> Liver puncture has been occasionally documented after a blind TAP block<sup>24</sup> and colon injury after a blind IHN block<sup>25</sup> and the use of ultrasound may also reduce these risks.

Chronic pain after inguinal hernia repair has multiple causes and mechanism.<sup>4</sup> Postoperative risk factors include pain intensity and analgesic management.<sup>26</sup> In the current study, the incidence of chronic pain was comparable in the two groups at 6 months, and ~20% of the patients had VAS score on movements higher than 4. These results are in agreement with those of previous studies.<sup>4-6 27</sup> The sensitivity and the specificity of the DN4 questionnaire to detect the neuropathic component of pain are, respectively, 82.9% and 89.9%.<sup>13</sup> Chronic pain after hernia repair had the features of neuropathic pain (DN4 score >4) in more than 10% of the patients included in the study. Others have documented that hypoesthesia and tactile allodynia were observed in half of the patients suffering from chronic pain after hernia repair.<sup>28</sup> Another study reports more than 30% incidence of numbness on the site of incision, correlating with pain.<sup>29</sup> Nerve injury could be a leading cause of chronic pain after hernia repair. The incidence and type of nerve injured vary according to the surgical procedure. Open surgical procedures are potentially associated with damage of the iliohypogastric nerve, although nerve preservation does not guarantee the lack of pain. In a 1 yr evaluation study, there was no difference between laparoscopic and Lichtenstein's procedures for chronic pain.<sup>5</sup> The current study did not document any improvement in the occurrence

of chronic pain after hernia repair with TAP block when compared with IHN block.

Our study has several limitations. The anaesthetist in charge of the patient was not blinded for the block technique. However, patients were blinded for the type of block and anaesthetists and surgeons conducting postoperative assessments were unaware of the randomization. We did not include a control group without block, but the aim was mainly to compare the two block techniques knowing that each of them had documented analgesic effect vs placebo.<sup>10 12 19 20</sup> We did not use quantitative sensory testing for assessment of sensory dysfunction but a study previously demonstrated the low specificity of these tests with differences only in brush allodynia and mechanical pain response between patients with or without chronic pain after open hernia repair and no relationship between pain and hypoesthesia or tactile allodynia.<sup>28</sup> The DN4 questionnaire used in the current study is a validated evaluation to determine the probability of neuropathic pain<sup>13</sup> and was easily performed in the postoperative period.

In conclusion, after open inguinal hernia repair in ambulatory patients, ultrasound-guided TAP block provided better immediate postoperative pain relief and reduced opioid demand, when compared with conventional loss-of-resistance IHN blocks. Nevertheless, ultrasound-guided TAP block did not reduce the occurrence of chronic pain after hernia repair.

## Conflict of interest

None declared.

## Funding

The study was provided solely from departmental sources (both Department of Anaesthetics and Surgery, Polyclinique Sévigné, Cesson-Sévigné, France).

## References

- Callesen T, Bech K, Kehlet H. One-thousand consecutive inguinal hernia repairs under unmonitored local anesthesia. *Anesth Analg* 2001; **93**: 1373–6
- Song D, Greilich NB, White PF, Watcha MF, Tongier WK. Recovery profiles and costs of anesthesia for outpatient inguinal herniorrhaphy. *Anesth Analg* 2000; **91**: 876–81
- White PF, Kehlet H. Improving postoperative pain management. *Anesthesiology* 2010; **112**: 220–5
- Perkins FM, Kehlet H. Chronic pain as an outcome of surgery. *Anesthesiology* 2000; **93**: 1123–33
- Bay-Nielsen M, Perkins FM, Kehlet H. Pain and functional impairment 1 year after inguinal herniorrhaphy: a nationwide questionnaire study. *Ann Surg* 2001; **233**: 1–7
- Poobalan AS, Bruse J, Smith WC, King PM, Krulowski ZH, Chambers WA. A review of chronic pain after inguinal herniorrhaphy. *Clin J Pain* 2003; **19**: 48–54
- Ong CKF, Lirk P, Seymour RA, Jenkins BJ. The efficacy of preemptive analgesia for acute postoperative pain management: a meta-analysis. *Anesth Analg* 2005; **100**: 757–73

- 8 Pettersson N, Emanuelsson B, Reventlid H, Hanh RG. High-dose ropivacaine wound infiltration for pain relief after inguinal hernia repair. *Reg Anesth Pain Med* 1998; **23**: 189–96
- 9 Narchi P, Carry P, Catoire P, et al. Postoperative pain relief and recovery with ropivacaine infiltration after inguinal hernia repair. *Ambul Surg* 1998; **6**: 221–6
- 10 McDonnell JG, O'Donnell B, Curley G, Heffernan A, Power C, Laffey JG. The analgesic efficacy of transversus abdominis plane block after abdominal surgery: a prospective randomized controlled trial. *Anesth Analg* 2007; **104**: 193–7
- 11 McDonnell JG, O'Donnell B, Farrel T, et al. Transversus abdominis plane block: a cadaveric and radiological evaluation. *Reg Anesth Pain Med* 2007; **32**: 399–404
- 12 El-Dawlatly Turkistani A, Kettner SC, et al. Ultrasound-guided transversus abdominis plane block: description of a new technique and comparison with conventional systemic analgesia during laparoscopic cholecystectomy. *Br J Anaesth* 2009; **102**: 763–7
- 13 Bouhassira D, Attal N, Alchaar H. Comparison of pain associated with nervous somatic lesions and development of a new neuropathic pain diagnosis questionnaire (DN4). *Pain* 2005; **114**: 29–36
- 14 McDonnell JG, Curley G, Carney J, et al. The analgesic efficacy of transversus abdominis plane block after cesarean delivery: a randomized controlled trial. *Anesth Analg* 2008; **106**: 186–91
- 15 Carney J, McDonnell JG, Ochana A, Bhinder R, Laffey JG. The transversus abdominis plane block provides effective postoperative analgesia in patients undergoing total abdominal hysterectomy. *Anesth Analg* 2008; **107**: 2056–60
- 16 O'Donnell BD, McDonnell JG, McShane AG. The transversus abdominis plane (TAP) block in open retropubic prostatectomy. *Reg Anesth Pain Med* 2006; **31**: 91
- 17 Moiniche S, Mikkelsen S, Wettersley J, et al. A qualitative systematic review of incisional local anaesthesia for postoperative pain relief after abdominal operation. *Br J Anaesth* 1998; **81**: 377–83
- 18 Yndgaard S, Holst P, Bjerre-Jepsen K, Thomsen CB, Struckmann J, Mogensen T. Subcutaneously versus subfascially administered lidocaine in pain treatment after inguinal herniotomy. *Anesth Analg* 1994; **79**: 324–7
- 19 Willschke H, Marhofer P, Bosenberg A, et al. Ultrasonography for ilioinguinal/iliohypogastric nerve blocks in children. *Br J Anaesth* 2005; **95**: 226–30
- 20 Weintraud M, Marhofer P, Bosenberg A, et al. Ilioinguinal/iliohypogastric blocks in children: where do we administer the local anesthetic without direct visualization? *Anesth Analg* 2008; **106**: 89–93
- 21 Whiteside JR, Barber MD, Walters MD, Falcone T. Anatomy of ilioinguinal and iliohypogastric nerves in relation with trocar placement and low transverse section. *Am J Obstet Gynecol* 2003; **189**: 1574–8
- 22 Tran TMN, Ivanusic JJ, Hebbard P, Barrington MJ. Determination of spread of injectate after ultrasound-guided transversus abdominis plane block: a cadaveric study. *Br J Anaesth* 2009; **102**: 123–7
- 23 Rosario DJ, Jacob S, Luntley J, Skinner PP, Raftery AT. Mechanism of femoral nerve palsy complicating percutaneous ilioinguinal field block. *Br J Anaesth* 1997; **78**: 314–7
- 24 Farooq M, Carey M. A case of liver trauma with a blunt regional anesthesia needle while performing transversus abdominis plane block. *Reg Anesth Pain Med* 2008; **33**: 274–5
- 25 Jöhr M, Sossai R. Colonic puncture during ilioinguinal nerve block in a child. *Anesth Analg* 1999; **88**: 1051–2
- 26 Callesen T, Bech K, Kehlet H. Prospective study of chronic pain after groin hernia repair. *Br J Surg* 1999; **86**: 1528–31
- 27 Aasvang E, Kehlet H. Chronic postoperative pain: the case of inguinal herniorrhaphy. *Br J Anaesth* 2005; **95**: 69–76
- 28 Mikkelsen T, Werner MU, Lassen B, Kehlet H. Pain and sensory dysfunction 6 to 12 months after inguinal herniotomy. *Anesth Analg* 2004; **99**: 146–51
- 29 Cunningham J, Temple WJ, Mitchell P, Nixon JA, Preshaw RM, Hagen NA. Cooperative hernia study. Pain is the postrepair patient. *Ann Surg* 1996; **224**: 598–602