

GENTAMICIN, TUBOCURARINE, LIGNOCAINE AND NEUROMUSCULAR BLOCKADE

A Case Report

D. R. HALL, D. H. MCGIBBON, C. C. EVANS AND G. A. MEADOWS

SUMMARY

A patient with impaired renal function following aortic valve replacement developed prolonged neuromuscular paralysis during treatment with tubocurarine, gentamicin and lignocaine but recovered after peritoneal dialysis. The potential neuromuscular blocking properties of these three drugs are discussed.

In the following case report we relate how a patient when first treated with intermittent positive pressure ventilation required regular high dosage of tubocurarine. Gentamicin and lignocaine were added and when renal failure developed a state of paralysis resulted which lasted for more than four days.

CASE REPORT

A 54-year-old male clerical worker was admitted to the unit on May 27, 1971, with intractable pulmonary oedema secondary to aortic regurgitation associated with bacterial endocarditis. Five years previously he had undergone a homograft valve replacement for calcific aortic stenosis. His treatment on admission consisted of cephaloridine 1 g 6-hourly intravenously, digoxin 0.25 mg 8-hourly, frusemide 80 mg 12-hourly and potassium chloride supplements (Slow K) 1200 mg 6-hourly. The aortic homograft was successfully replaced by a No. 9 Starr-Edwards prosthesis on the following day. Pancuronium 20 mg was used during the procedure (0.26 mg/kg weight) and its effect was fully reversed after injection of atropine 1.2 mg and neostigmine 5 mg intravenously. The early postoperative course was very satisfactory. Parenteral cephaloridine was continued and small doses of diazepam (5–10 mg i.v.) and morphine (5 mg i.v.) were necessary for sedation and analgesia.

On the 5th postoperative day he suddenly developed ventricular fibrillation and was successfully resuscitated by d.c. defibrillation after a short period of closed chest cardiac massage. Further bouts of ventricular tachyarrhythmia occurred and it was then decided to assist ventilation until the haemodynamic situation was more stable. Intermittent positive pressure ventilation was maintained with the aid of regular doses of tubocurarine and morphine (averaging 30 mg (0.39 mg/kg) and 5 mg respectively 3-hourly intravenously). No biochemical cause for the arrhythmia was found and lignocaine therapy was commenced, 1.5 g per 24 hours being administered by constant infusion. This treatment was continued until the 14th postoperative day. On the 10th postoperative day the antibiotic was changed to gentamicin in a dose of 80 mg 8-hourly i.v., because of persistent pyrexia, deterioration in the appearance of the chest radiogram, and the isolation of *E. Coli* from the sputum. The blood urea was then 94 mg/100 ml (see fig. 1). That same evening the development of rigors, tachycardia, and arterial hypotension suggested Gram-negative bacteraemia.

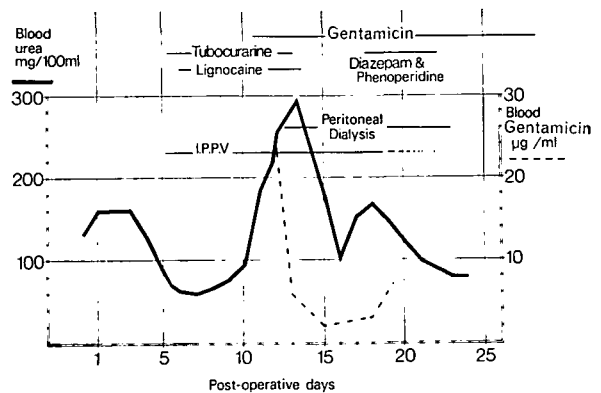


FIG. 1. The time course and interrelationship of drug treatment to artificial ventilation and dialysis with superimposition of the blood levels of urea and gentamicin.

On the following day there was deterioration in renal function with a fall in urinary output and urinary urea concentration, and a rise in blood urea. The dose of gentamicin was therefore reduced to 60 mg 8-hourly. On the 12th postoperative day the blood gentamicin level, estimated by standard tube dilution technique using the Oxford staphylococcus, was found to be 25 µg/ml. As the blood urea was now over 200 mg/100 ml and the serum potassium 6.2 m.equiv/l., peritoneal dialysis was commenced using the standard proprietary solution and continued for 11 days. No antibiotics were added to the dialysate. Gentamicin dosage was then calculated according to the blood levels and averaged 90 mg per day. The lignocaine infusion was stopped. At this time the patient did not require

D. R. HALL,* M.B., M.R.C.P.(UK), D.OBST.R.C.O.G.; D. H. MCGIBBON,† M.B., CH.B.; C. C. EVANS,‡ M.B., M.R.C.P.; G. A. MEADOWS, M.B., F.F.A.R.C.S.; Liverpool Regional Cardio-Thoracic Unit, Broadgreen Hospital, Thomas Lane, Liverpool.

Present addresses:

*Sefton General Hospital, Liverpool L15 2HE.

†Walton Hospital, Rice Lane, Liverpool 9.

‡Department of Anaesthesia, Uppsala University, Sweden.

further tubocurarine to facilitate artificial ventilation whereas on the previous 8 days fairly high doses had been necessary. (From the 5th to the 13th day, the total amount of tubocurarine injected was 1.74 g.) As he was now completely unresponsive to stimuli, we feared that he had sustained cerebral damage from hypoxia and infection. An electroencephalogram, however, showed an essentially normal record. A state of prolonged neuromuscular blockade was suspected and confirmed by the use of a peripheral nerve stimulator (Churchill-Davidson, 1965). For the next 4 days neither relaxant nor sedation was needed but repeated testing of neuromuscular function with the nerve stimulator suggested gradual improvement. By the 16th postoperative day the patient was obviously conscious and able to move his limbs. Intermittent positive pressure ventilation was slowly withdrawn over a period of 6 days. Small doses of intravenous diazepam 5-10 mg and phenoperidine 2 mg were necessary for sedation. With progressive improvement in renal function peritoneal dialysis was discontinued. Gentamicin therapy ceased on the 28th postoperative day and the patient's progress from then on was uneventful.

At no time during the illness was the serum calcium or magnesium level significantly altered and the potassium levels quickly fell to normal after starting dialysis. Plasma protein analysis revealed a low albumin (2 g/100 ml) and raised globulin (3.8 g/100 ml).

DISCUSSION

Experience with renal transplantation has shown that even in the complete absence of renal function there is no danger of prolonged paralysis when tubocurarine is used during the operation (Churchill-Davidson, Way and de Jong, 1967; Dhunér, Lundberg and Peterhoff, 1968; Samuel and Powell, 1970). In dogs Cohen, Brewer and Smith (1967) using radioactive labelled tubocurarine showed that up to 40% of a dose could be excreted in the bile. Marsh (1952), however, suggested that tissue depots may become saturated by repeated doses of curare. Furthermore Foldes (1959) predicted that a prolonged therapeutic effect might occur in the presence of impaired renal function. Dykes (1967) and Riordan and Gilbertson (1971) reported cases where this appeared to have happened.

Gibaldi, Levy and Hayton (1972), in their theoretical study, help to support and explain these differing experiences with tubocurarine in renal failure. By using computer simulation and a 3-compartment model, they conclude that absence of renal function should have little effect on the duration of action of a small single dose of tubocurarine, but that prolonged effect would be likely to result from the exhibition of large single and multiple doses.

Other factors which may affect the response to tubocurarine are idiosyncrasy to the drug, racial differences (Sellick, 1970), electrolyte abnormality (Foldes, 1959), dehydration (Cohen, 1959), low serum globulin concentration (Baraka and Gabali,

1968), and coincidental muscle disease (Wise, 1963). None of these appear to be relevant to our case.

Gentamicin is an aminoglycoside antibiotic related to streptomycin and neomycin. Antibiotics of this group known to cause neuromuscular blockade in animals and man include neomycin (Pridgen, 1956), streptomycin (Brazil and Corrado, 1957), and colistin (Perkins, 1964). The neuromuscular blocking effect of gentamicin was predicted by Finland (1969) and investigated in animals by Barnett and Ackerman (1969) and by Brazil and Prado-Franceschi (1969a, b). Gentamicin is almost entirely excreted by glomerular filtration (Black et al., 1963). Warner and Sanders (1971) reported that gentamicin 80 mg given 8-hourly intramuscularly to a patient with renal impairment resulted in respiratory failure lasting about 2 days. No blood levels of gentamicin were recorded. In our case the very high level of 25 µg/ml occurred at a time when renal function deteriorated at the onset of a Gram-negative bacteraemia.

Lignocaine is an amide-linked local anaesthetic with properties similar to its predecessor procaine. Harvey in 1939 showed the latter to have neuromuscular blocking effects in cat muscle, and warned that in patients with myasthenia gravis local anaesthesia might increase the weakness. De Jong (1970) stated that local anaesthetics were unlikely to affect neuromuscular transmission in men when given intravenously because of the low concentration attained at the neuromuscular junction. He did, however, warn that, in the presence of other blocking agents there could be danger of a prolonged paralysis. Usubiaga and Moya (1968) experimented with intra-arterial injection of local anaesthetics in anaesthetized patients and reached similar conclusions. Lignocaine is partly metabolized by the liver and then slowly excreted in the urine (de Jong, 1970). In our patient, because of impaired elimination, high levels of lignocaine may have occurred and contributed to the paralysis.

It is interesting to note that these three drugs, tubocurarine, gentamicin and lignocaine have been shown to interact in the past. Barnett and Ackerman (1969) demonstrated potentiation of tubocurarine by gentamicin in animals. Harvey (1939) showed how procaine and tubocurarine were additive in their effects on cat muscle. Foldes (1959) in his excellent review article mentions the work of Ellis and associates (1952) in which procaine was shown to intensify the blocking effect of tubocurarine in cats and sheep. Lowenstein, Goldfine and Werner (1970) described a case of prolonged paralysis which they

attributed to the effects of gallamine. Streptomycin and lignocaine were also being administered, however, and may have played some part in the paralysis.

Little information is available on how these drugs are affected by peritoneal dialysis. Schreiner (1971) mentions that gallamine and streptomycin are dialysable. Vachon and associates (1970) investigated the effect of peritoneal dialysis on gentamicin therapy and devised combined intramuscular and intraperitoneal dosage schedules to allow for loss into the dialysate.

We believe, as did Lowenstein, Goldfine and Werner in relation to their case, that the dialysis may have speeded recovery by causing a rapid lowering of the blood concentration of the neuromuscular blocking agents.

In conclusion we suggest that prolonged muscular paralysis in the present case could have resulted from the action of tubocurarine, lignocaine or gentamicin, or by an interaction between the three; and that this effect was precipitated by renal failure and relieved by peritoneal dialysis.

ACKNOWLEDGEMENTS

The authors wish to thank Mr D. I. Hamilton for permission to publish details of his patient, Dr C. M. Ogilvie and Dr I. C. Geddes for helpful advice in preparation of the paper, and Mrs F. J. Hall. and Mrs B. D. Worthington for secretarial assistance.

REFERENCES

- Baraka, A., and Gabali, F. (1968). Correlation between tubocurarine requirements and plasma protein pattern. *Brit. J. Anaesth.*, **40**, 89.
- Barnett, A., and Ackerman, N. E. (1969). Neuromuscular blocking activity of gentamicin in cats and mice. *Arch. int. Pharmacodyn.*, **181**, 1 109.
- Black, J., Calesnick, B., Williams, D., and Weinstein, M. J. (1963). Pharmacology of gentamicin, a new broad spectrum antibiotic. *Antimicrobial Agents and Chemotherapy*, **3**, 138.
- Brazil, O. V., and Corrado, A. P. (1957). The curariform action of streptomycin (1951). *J. Pharmacol. exp. Ther.* **120**, (4), 452.
- Prado-Franceschi, J. (1969a). The neuromuscular blocking action of gentamicin *Arch. int. Pharmacodyn.* **179**, 1, 65.
- (1969b). The nature of neuromuscular block produced by neomycin and gentamicin. *Arch. int. Pharmacodyn.* **179**, 1, 78.
- Churchill-Davidson, H. C. (1965). A portable peripheral nerve stimulator. *Anesthesiology*, **26**, 224.
- Way, W. L., and de Jong, R. H. (1967). The muscle relaxants and renal excretion. *Anesthesiology*, **28**, 540.
- Cohen, E. N. (1959). *Proceedings of the International Symposium on Curare and Curare-like Agents*. 1st edn., p. 382. Amsterdam: Elsevier.
- Brewer, H. W., and Smith, D. (1967). The metabolism and elimination of d-tubocurarine H³. *Anesthesiology*, **28**, 309.

- Dhunér, K. G., Lundberg, H., and Peterhoff, V. (1968). Anaesthesia in renal transplantation. *Scand. J. Urol. Nephrol.*, **2**, 31.
- de Jong, R. H. (1970). *Physiology and Pharmacology of Local Anesthesia*. Springfield: Thomas.
- Dykes, M. H. M. (1967). Prolonged anesthesia, overcurarisation and resection of the abdominal wall. *Anesthesiology*, **28**, 231.
- Ellis, C. H., Wnuck, A. L., De Beer, E. J., and Foldes, F. F. (1952). Modifying actions of procaine on the myoneural blocking actions of succinylcholine, decamethonium and d-tubocurarine in dogs and cats. *Amer. J. Physiol.*, **174**, 277.
- Finland, M. (1969). The symposium on gentamicin. *J. infect. Dis.*, **119**, 537.
- Foldes, F. F. (1959). Factors which alter the effects of muscle relaxants. *Anesthesiology*, **20**, 464.
- Gibaldi, M., Levy, G., and Hayton, W. L. (1972). Tubocurarine and renal failure. *Brit. J. Anaesth.*, **44**, 163.
- Harvey, A. M. (1939). The actions of procaine on neuromuscular transmission. *Bull. Johns Hopk. Hosp.*, **65**, 223.
- Lowenstein, E., Goldfine, C., and Werner, E. F. (1970). Administration of gallamine in the presence of renal failure—reversal of neuromuscular blockade by peritoneal dialysis. *Anesthesiology*, **33**, 556.
- Marsh, D. F. (1952). The distribution, metabolism, and excretion of d-tubocurarine chloride and related compounds in man and other animals. *J. Pharmacol. exp. Ther.*, **105**, 3, 299.
- Perkins, R. L. (1964). Apnea with intramuscular colistin therapy. *J. Amer. med. Ass.*, **190**, 421.
- Pridgen, J. E. (1956). Respiratory arrest thought to be due to intraperitoneal neomycin. *Surgery*, **40**, 571.
- Riordan, D. D., and Gilbertson, A. A. (1971). Prolonged curarization in a patient with renal failure. *Brit. J. Anaesth.*, **43**, 506.
- Samuel, J. R., and Powell, D. (1970). Renal transplantation. Anaesthetic experience of one hundred cases. *Anaesthesia*, **25**, 2, 165.
- Schreiner, G. E. (1971). Dialysis of poisons and drugs—annual review. *Trans. Amer. Soc. artif. intern. Org.*, **17**, 520.
- Sellick, B. A. (1970). Anglo-American differences in response to muscle relaxants. *Med. Annual*, **88**, 93. Bristol: Wright.
- Usabiaga, J. E., and Moya, F. (1968). Neuromuscular effects of six local anaesthetics on anaesthetised subjects. *Canad. Anaesth. Soc. J.*, **15**, 56.
- Vachon, F., Witchitz, J., Marsac, J., and Vic-Dupont, V. (1970). Dialyse péritonéale et antibiothérapie. *Sem. Hôp. Paris*, **46**, 40, 2529.
- Warner, W. A., and Sanders, E. (1971). Neuromuscular blockade associated with gentamicin therapy. *J. Amer. med. Ass.*, **215**, 7, 1153.
- Wise, R. P. (1963). Muscle disorders and the relaxants. *Brit. J. Anaesth.*, **35**, 558.

GENTAMYCINE, TUBOCURARINE, LIGNOCAINE ET BLOCAGE NEURO-MUSCULAIRE: A PROPOS D'UNE OBSERVATION

SOMMAIRE

Chez un malade ayant présenté une altération de la fonction rénale consécutive à la mise en place d'une prothèse valvulaire aortique, est apparu une paralysie neuro-musculaire prolongée au cours d'un traitement à base de tubocurarine, gentamycine et lignocaïne. Les propriétés potentielles de ces trois substances, dans le sens d'un blocage neuro-musculaire, font l'objet d'une discussion.

GENTAMICIN, TUBOCURARIN, LIGNOCAIN
UND NEUROMUSKULÄRE BLOCKADE

ZUSAMMENFASSUNG

Bei einem Patienten mit ungenügender Nierenfunktion nach Ersatz der Aortenklappen stellte sich eine Verlängerung der neuromuskulären Paralyse unter Behandlung mit Tubocurarin, Gentamicin und Lignocain ein. Der Patient erholte sich jedoch nach einer Peritonealdialyse. Die potentiellen Eigenschaften dieser drei Substanzen im Bezug auf eine neuromuskuläre Blockade werden diskutiert.

GENTAMICINA, TUBOCURARINA, LIGNOCAINA
Y BLOQUEO NEUROMUSCULAR:
COMUNICACION DE UN CASO

RESUMEN

Un paciente con trastorno de la función renal después de reemplazamiento de la válvula aórtica desarrolló una prolongada parálisis neuromuscular durante el tratamiento con tubocurarina, gentamicina y lignocaina, pero se restableció después de una diálisis peritoneal. Son discutidas las propiedades potenciales de bloqueo neuromuscular de estos tres medicamentos.

CORRESPONDENCE

CARDIOVASCULAR COLLAPSE AFTER PROPANIDID

Sir.—Referring to the contribution by Drs Spreadbury and Marrett (*Brit. J. Anaesth.* (1971), **43**, 925), I would like to describe a case recently experienced by us.

The patient was a 27-year-old healthy female having her first anaesthetic for stripping of varicose veins. Her weight was 55.5 kg. She was premedicated with one ampoule of Pamergan SP50 1 hour before the start of the operation.

Induction of anaesthesia started at 8.05 with propanidid 400 mg followed by suxamethonium chloride 100 mg, hyperventilation with oxygen, and intubation. She was ventilated with nitrous oxide 6 l./min, oxygen 3 l./min and halothane 2%.

At 8.07 a general redness of the skin had developed, the patient seemed slightly difficult to ventilate, but there was no obvious bronchospasm. The heart beat at this time was normal. At 8.08 the radial pulse was no longer palpable and the patient was in cardiac arrest.

Resuscitation was started immediately, with external cardiac massage, ventilation with 100% oxygen, i.v. hydrocortisone 200 mg, rapid infusion of 150 ml sod. bicarbonate 4.2% and Ringer lactate solution.

At 8.13 the peripheral pulse was palpable again, blood pressure being 40 mm Hg systolic. A sinus rhythm was indicated by the e.c.g. monitor, connected at the time of resuscitation. The patient started to wake up and was then ventilated with oxygen 5 l./min, nitrous oxide 5 l./min and relaxed with several repeated doses of suxamethonium chloride.

At 8.20 the systolic blood pressure was 70 mm Hg. The operation was started at 8.40 under nitrous oxide 6 l./min, oxygen 4 l./min, halothane 0.5%, trichloroethylene 0.5%, and spontaneous respiration.

At 9.05 the patient was extubated and returned to the ward. The systolic blood pressure was steady at 80 mm Hg, the pulse rate between 90 and 110 beats/min and the redness of skin was fading.

Visiting the ward at 10.00, the patient had awakened and pulse and blood pressure had remained steady. The i.v. infusion was continued with 5% dextrose and sips of water were given to drink.

As no urine had been passed, 60 ml Mannitol 20% was given i.v. at 15.00 and 40 mg frusemide i.v. at 18.00; the first 500 ml urine was passed at 19.30.

Further recovery was uneventful except for a complaint of dizziness during the first 48 hours.

I. ROZENKRANZ
Mufulira