

CORRESPONDENCE

Visceral pain during Caesarean section

Sir,—In their article on visceral pain during Caesarean section, Hirabayashi and colleagues [1] stated that “The spread of analgesia in all patients was almost comparable”. However, although the upper limit of spread of spinal amethocaine was measured, no attempt was made to define the lower limit of spread. Exteriorization of the uterus may lead to traction on the pelvic viscera, and pain in this region can be conveyed via the pelvic splanchnic nerves (S2, 3, 4 nerve roots) [2]. A more extensive block in the sacral nerve roots, when using higher doses of spinal amethocaine, is a possible explanation for the differences in quality of intraoperative conditions found in their study.

When presenting their data on the maximum spread of analgesia, the authors quoted a range for the upper level of the block which included non-integer values. I fail to see how they can be so accurate, especially when the dermatomal nerve supply varies between subjects and, in fact, the dermatomal chart differs immensely in description among medical books [2, 3].

M. C. FAIRFIELD
Department of Anaesthesia
Leicester Royal Infirmary
Leicester

1. Hirabayashi Y, Saitoh K, Fukuda H, Shimizu R. Visceral pain during Caesarean section: effect of varying dose of spinal amethocaine. *British Journal of Anaesthesia* 1995; 75: 266–268.
2. Snell RS. *Clinical Anatomy for Medical Students*, 2nd Edn. Boston: Little, Brown and Company, 1981.
3. Kumar PJ, Clark ML. *Clinical Medicine*, 2nd Edn, London: Baillière Tindall, 1990.

Sir,—We took no account of the lower limit of spread of spinal amethocaine and our conclusion was indeed derived from the data on the upper limit of analgesia. Although we had no opportunity to examine if the second, third and fourth sacral nerves were blocked during operation, none of our parturients had any sensation in the perineum during and immediately after operation, indicating that these sacral nerves were totally blocked. In contrast with extradural anaesthesia, spinal amethocaine injected at the midlumbar region usually blocks every sacral nerve. From this, we can surmise that there were no differences in the extent of block of the sacral nerves in the parturients.

Visceral pain may be transmitted via pathways as high as the coeliac plexus [1]. The coeliac plexus receives its primary innervation from the greater, lesser and least splanchnic nerves, which arise from T5 to T12 [2]. Hyperbaric anaesthetic solutions, migrating cephalad, pool in the thoracic hollow [3]. A more potent block in this region, when using higher doses of spinal amethocaine, may be a possible reason for the differences in the incidence of visceral pain found in our study.

In our article, data on maximum spread of analgesia were presented as median with range, because data on dermatomal spread are non-parametric. We assessed the spread of analgesia in the left and right sides of the body according to a dermatomal chart given in a standard textbook of neural block [4]. We believe that this female dermatomal chart is one of the most reliable for obstetric and gynaecological patients. If the analgesic levels obtained in both sides differed, the average value was used for analysis, and therefore non-integer values were provided.

Y. HIRABAYASHI
K. SAITOH
H. FUKUDA
R. SHIMIZU
Department of Anaesthesiology
Jichi Medical School
Tochigi, Japan

1. Brown DL. Spinal, epidural, and caudal anesthesia; Anatomy, physiology, and technique. In: Chestnut DH, ed. *Obstetric Anesthesia. Principles and Practice*. St Louis: Mosby, 1994; 181–201.

2. Brown DL. *Atlas of Regional Anesthesia*. Philadelphia: WB Saunders Company, 1992; 247.
3. Kitahara T, Kuri S, Yoshida J. The spread of drugs for spinal anesthesia. *Anesthesiology* 1965; 17: 205–208.
4. Cousins MJ, Bridenbaugh PO. *Neural Blockade in Clinical Anesthesia and Management of Pain*, 2nd Edn. Philadelphia: JB Lippincott, 1988; 344.

Cannabis as a medicine

Sir,—We read with great interest the editorial by Doyle and Spence [1]. This was a step in the right direction and provides a concise presentation of the more recent research and concepts on the therapeutic potential of *Cannabis sativa*.

The Departments of Pharmacology and Ophthalmology of the University of the West Indies at the Mona Campus in Kingston, Jamaica have performed extensive research with *Cannabis sativa*, focusing on its possible therapeutic potential. Of course we would not advocate smoking cannabis as this could lead to some of the adverse effects described [1]. On the other hand, with regard to the gestational effects, in a long-term study in Jamaica by Dr Milaine Dreher from the University of Massachusetts and Dr Ronald Lampart in Morant Bay, Jamaica, no unusual fetal effects or growth retardation were observed. This study included mothers in early pregnancy, smoking *Cannabis sativa* through pregnancy and delivery, and their offspring were followed-up for 5 years.

Furthermore, with regard to mortality, intensive search of the literature has, to our knowledge, reported no deaths from cannabis *per se*, although the CNS effects may result in “fatalities” of one type or another.

In support of cannabis as a medicine, West and Lockhart [2, 3] from the University of the West Indies have developed an ethical preparation, an eye drop for topical administration of *Cannabis sativa*. This preparation has been marketed since 1987 and several thousand 5-cc phials have been used in some parts of the world in the management of glaucoma, particularly in the Caribbean region and some parts of North America. The drug is marketed under the tradename Canasol eye drops. In Jamaica it is manufactured by Ampec Chemicals Limited and marketed by Medigrace Limited, Kingston. Canasol is comparable with timolol maleate and is compatible with the commonly used anti-glaucoma medication. The use of Canasol eye drops has also been reported by Gutierrez and Gutierrez [4].

We agree entirely that further research is required into the use of *Cannabis sativa* or its derivatives as an analgesic and antiemetic in the postoperative period and also in the hospice setting. Even if it were to be shown that cannabis is no more useful than existing drugs, it remains a significantly cheaper and more accessible alternative in those developing countries where the newer preparations marketed by the large multinational pharmaceutical companies are unaffordable and unavailable to the general population.

M. E. WEST
Department of Pharmacology
J. HOMI
Department of Anaesthetics and
Intensive Care
University of the West Indies
Kingston, Jamaica

1. Doyle E, Spence AA. Cannabis as a medicine. *British Journal of Anaesthesia* 1995; 74: 359–361.
2. West ME, Lockhart AB. The treatment of glaucoma using a non-psychoactive preparation from *Cannabis sativa*. *West Indian Medical Journal* 1978; 27: 16–25.
3. West ME, Lockhart AB. The synergistic effect of Canasol and timolol maleate eye drops in glaucoma patients. *World Conference on Clinical Pharmacology and Therapeutics* (Paper No. 0100). London, 1980.
4. Gutierrez AM, Gutierrez DL. Ocular hypertension treatment with *Cannabis sativa* 1990; Paper presented at the Annual Congress of Ophthalmology, Cali, Colombia, August 1995.

Naproxen after day-case laparoscopic sterilization

Sir,—The recent article by Dunn, Clark and Jones [1] on the analgesic efficacy of a single preoperative dose of naproxen in patients undergoing day-case laparoscopic tubal ligation yet again demonstrates that pain after this procedure can rarely be treated by non-steroidal anti-inflammatory drugs (NSAID) alone. There is no doubt that pain is a very significant factor in the morbidity after laparoscopic tubal ligation [2–4]. On repeated occasions, previously published work has shown NSAID to be only partially successful in treating this pain when administered as the sole analgesic [2, 5–8].

Although there is evidence that prostaglandins mediate the pain associated with tubal ligation [9], it seems, as observed by Dunn, Clark and Jones, that this particular pain is multimodal in origin with subphrenic and shoulder tip pain originating from the persistence of irritating intraperitoneal insufflating gas [10] and cephalad tracking of blood or free fluid from the operative site via the paracolic gutters [11], and pelvic pain originating from the use of rings, clips or diathermy to occlude or interrupt the Fallopian tubes [10]. It is therefore not surprising that administration of NSAID as the lone therapeutic manoeuvre to treat this pain has proved unsuccessful. It is surely more sensible to consider NSAID as an integral component of "balanced analgesia" under such circumstances as opposed to the sole analgesic agent. It is probable that there is a proportion of patients undergoing laparoscopic tubal ligation whose postoperative pain will necessitate administration of opioid analgesia and who may, indeed, go on to require overnight hospital admission.

P. I. WILLIAMS

Department of Anaesthesia
Alder Hey Children's Hospital
Liverpool

1. Dunn TJ, Clark VA, Jones G. Preoperative oral naproxen for pain relief after day-case laparoscopic sterilization. *British Journal of Anaesthesia* 1995; 75: 12–14.
2. Edwards ND, Barclay K, Catling SJ, Martin DG, Morgan RH. Day case laparoscopy; a survey of postoperative pain and an assessment of the value of diclofenac. *Anaesthesia* 1991; 46: 1077–1080.
3. Davis A, Millar JM. Postoperative pain: a comparison of laparoscopic sterilisation and diagnostic laparoscopy. *Anaesthesia* 1988; 43: 796–797.
4. Fraser RA, Hotz SB, Hurtig JB, Hodges SN, Moher D. The prevalence of pain after day-care tubal ligation surgery. *Pain* 1989; 39: 189–201.
5. MacLennan AH, Rodrigues LV, Krutli DR, Klomp A. Postoperative discomfort after ring or clip tubal ligation—is there any difference and do indomethacin suppositories help? *Contraception* 1990; 42: 309–313.
6. Crocker S, Paech M. Preoperative rectal indomethacin for analgesia after laparoscopic sterilisation. *Anaesthesia and Intensive Care* 1992; 20: 337–340.
7. Shapiro MH, Duffy BL. Intramuscular ketorolac for postoperative analgesia following laparoscopic sterilisation. *Anaesthesia and Intensive Care* 1994; 22: 22–24.
8. Higgins MS, Givogre JL, Marco AP, Blumenthal PD, Furman WR. Recovery from outpatient laparoscopic tubal ligation is not improved by preoperative administration of ketorolac or ibuprofen. *Anesthesia and Analgesia* 1994; 79: 274–280.
9. Brodie BL, Casper RF. Prostaglandins mediate postoperative pain in Falope ring sterilisation. *American Journal of Obstetrics and Gynecology* 1985; 151: 175–177.
10. Dobbs FF, Kumar V, Alexander JI, Hull MGR. Pain after laparoscopy related to posture and ring versus clip sterilisation. *British Journal of Obstetrics and Gynaecology* 1987; 94: 262–266.
11. Boheimer NO, Thomas JS, Bowen-Simpkins P. Pain after laparoscopy. *Anaesthesia* 1990; 45: 253–254.

Sir,—As Dr Williams correctly points out, it would be inappropriate to treat the pain of laparoscopic tubal ligation with NSAID alone because of the multimodal nature of the pain. We therefore added NSAID to our normal practice of giving i.v. diamorphine during operation to extend the number of pain

mechanisms being targeted. Before this study our patients commonly required additional diamorphine for postoperative pain relief, with its increased risks of nausea, vomiting and sedation, and subsequent increased likelihood of overnight stay. Our bimodal approach, using diamorphine and naproxen, decreased the need for extra postoperative diamorphine (naproxen group 21:37 = 54 %; placebo group 27:35 = 77 %). However, our conclusion was that a trimodal approach was required, which included a third component, local anaesthesia.

T. J. DUNN

V. A. CLARK

G. JONES

Department of Anaesthesia,
Eastern General Hospital
Edinburgh

Systolic pressure variation—a way to recognize dynamic hyperinflation

Sir,—I read with interest the article by Myles, Maddar and Morgan [1], the similar case presented by Mercer [2], and the reply of Myles [3], concerning cardiac arrest after unrecognized dynamic hyperinflation. The potential fatality of dynamic hyperinflation often stems from lack of recognition. I would therefore suggest that analysing the respiratory variations in the arterial pressure waveform may serve as an early warning sign of such hyperinflation. The arterial pressure waveform responds normally in a biphasic manner to a mechanical breath [4]. This response starts with an early increase in systolic pressure, termed by us delta up (dUp), which denotes transient augmentation of left ventricular (LV) stroke output caused mainly by squeezing down of pulmonary blood into the LV. The dUp is followed normally by a decrease in systolic pressure, termed delta down (dDown), which is caused by the inspiratory decrease in venous return. The difference between maximal and minimal systolic pressures during one mechanical breath is termed the systolic pressure variation (SPV) [4]. SPV and dDown (the difference between systolic pressure during a short apnoea and the minimal systolic value) are sensitive indicators of reduction in preload [4–7]. A build up of positive intrathoracic pressure during dynamic hyperinflation reduces venous return and effective preload, and therefore leads to exaggerated depressions of LV output (and arterial pressure) with each mechanical breath.

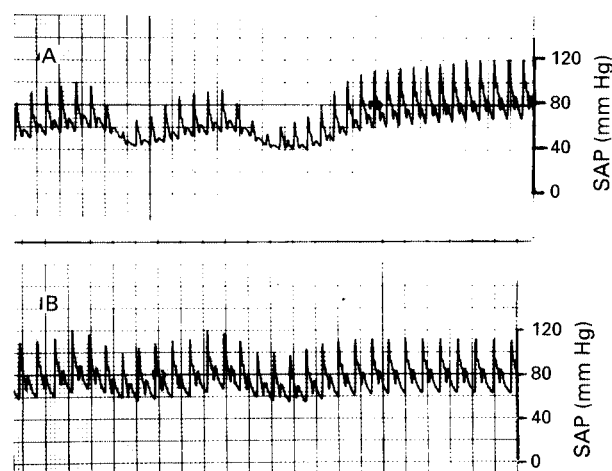


Figure 1 Systolic arterial pressure (SAP) waveform indicating hyperinflation (A), caused by the tip of the tracheal tube abutting on the tracheal wall. Withdrawing the tracheal tube resulted in lung deflation and a normal wave form variation (B).

Such a case is described in figure 1, where hyperinflation (A) was caused by the tip of the tracheal tube abutting on the tracheal wall and causing a one-way valve mechanism. Excessive airway pressure caused the appearance of pronounced SPV with every breath. A short apnoea caused systolic pressure to increase significantly and to be characteristically higher than peak systolic pressure during mechanical ventilation. Withdrawing the tracheal

tube resulted in lung deflation and a normal arterial pressure waveform variation (B).

Hence, the appearance of excessive SPV and dDown should indicate frank hypovolaemia or any other mechanism that reduces preload, such as dynamic hyperinflation. The significant increase in systolic pressure during introduction of a short apnoea is indicative of such hyperinflation. In the absence of a direct arterial pressure trace, variations in the plethysmographic signal of the pulse oximeter may reflect the same phenomenon.

A. PEREL
E. SEGAL
Department of Anaesthesia
and Intensive Care
Sheba Medical Center
Tel Hashomer, Israel

1. Myles PS, Madder H, Morgan EB. Intraoperative cardiac arrest after unrecognized dynamic hyperinflation. *British Journal of Anaesthesia* 1995; 74: 340–342.
2. Mercer M. Cardiac arrest after unrecognized dynamic inflation. *British Journal of Anaesthesia* 1995; 75: 252.
3. Myles PS. Cardiac arrest after unrecognized dynamic inflation. *British Journal of Anaesthesia* 1995; 75: 252.
4. Perel A, Pizov R, Cotev S. The systolic pressure variation is a sensitive indicator of hypovolemia in ventilated dogs subjected to graded hemorrhage. *Anesthesiology* 1987; 67: 498–502.
5. Pizov R, Ya'ari Y, Perel A. Systolic pressure variation is greater during hemorrhage than during sodium nitroprusside induced hypotension in ventilated dogs. *Anesthesia and Analgesia* 1988; 67: 170–174.
6. Coriat P, Vrillon M, Perel A. A comparison of systolic blood pressure variations and echocardiographic estimates of end-diastolic left ventricular size in patients after aortic surgery. *Anesthesia and Analgesia* 1994; 78: 46–53.
7. Rooke GA, Schwid HA, Shapira Y. The effect of graded hemorrhage and intravascular volume replacement on systolic pressure variation in humans during mechanical and spontaneous ventilation. *Anesthesia and Analgesia* 1995; 80: 925–932.

Sir,—I appreciate the interesting comments of Perel and Segal who highlight the possible detection of dynamic hyperinflation (DHI) by changes in the arterial waveform with respiratory excursions. Pulse oximetry has also recently been suggested [1], although electronic adjustment of some pulse oximeters makes direct arterial pressure measurement more reliable [2]. Nevertheless, as suggested by Perel and Segal, there are other causes of exaggerated systolic pressure variation (vasodilatation, hypovolaemia) which often coexist after induction of anaesthesia and commencement of positive pressure ventilation. This is when DHI usually manifests. I therefore strongly recommend that DHI is best diagnosed with an apnoeic period, which not only accurately diagnoses the problem, but can quantify the extent of DHI (by measuring the expired gas volume during this period) while offering expeditious treatment. Such an apnoeic period should include insufflation with 100% oxygen and may require more than 90 s for a response [3].

Incidentally, because of the mechanism outlined by Perel and Segal, an apnoeic period may also transiently relieve some of the adverse haemodynamic effects of intravascular volume depletion in patients with obstructive lung disease.

P. S. MYLES
Alfred Hospital
Melbourne
Australia

1. Conacher ID, McMahon CC. Pathognomonic pulse oximetry paradox. *Lancet* 1995; 346: 448.
2. Myles PS, Ryder I. Pulse oximetry. *Lancet* 1995; 346: 850.
3. Myles PS, Weeks AM. Alpha 1-antitrypsin deficiency: circulatory arrest following induction of anaesthesia. *Anaesthesia and Intensive Care* 1992; 20: 358–362.

Intrathecal insertion of an extradural catheter during combined spinal–extradural anaesthesia

Sir,—I read with interest the recent report by Robbins, Fernando and Lim on accidental intrathecal insertion of an extradural

catheter during combined spinal–extradural anaesthesia for Caesarean section [1]. Clearly, it is important to report on complications associated with new anaesthetic techniques, such as combined spinal–extradural anaesthesia. I also fully concur with the authors' conclusion that an appropriate test dose be administered through an extradural catheter to exclude intrathecal placement.

However, I believe that the phenomenon of submission bias and publication bias be considered in the interpretation of this report. It is well known that intrathecal migration of an extradural catheter can occur at any time, even without obvious dural puncture. Had such an event occurred during routine extradural anaesthesia (i.e. without combined spinal–extradural anaesthesia), it is unlikely that such a case would have been submitted, and if submitted, it would be unlikely to be accepted for publication. To the authors of this report, and to any others who claim that intrathecal catheter migration is a specific risk of combined spinal–extradural anaesthesia, I challenge that the onus is upon you to prove that this event occurs with any greater frequency during combined spinal–extradural anaesthesia than during routine extradural anaesthesia. In fact, the available evidence in the literature, including large clinical studies [2–4] and laboratory investigations [5], would support the claim that the incidence of intrathecal catheter migration is *not increased* when combined spinal–extradural anaesthesia is used. Even outspoken opponents [6] of the needle-through-needle combined spinal–extradural anaesthesia technique have not provided any evidence that this approach increases the risk of intrathecal catheter migration, nor is there any evidence that alternative needle designs decrease the incidence of this occurrence.

When new techniques, such as combined spinal–extradural anaesthesia, are used it is important that complications are documented. However, old, well-known, but infrequent complications of extradural anaesthesia, such as catheter migration, should not be ascribed improperly to new techniques on the basis of isolated case reports. Unfortunately, much of the dogma by which we practise is based on isolated case reports, when large-scale studies would seem to indicate otherwise.

W. CAMANN
Department of Anesthesia
Brigham and Women's Hospital
Boston, MA, USA

1. Robbins PM, Fernando R, Lim GH. Accidental intrathecal insertion of an extradural catheter during combined spinal–extradural anaesthesia for Caesarean section. *British Journal of Anaesthesia* 1995; 75: 355–357.
2. Morgan B, Kadim MY. Mobile regional anaesthesia in labour. *British Journal of Obstetrics and Gynaecology* 1994; 101: 839–841.
3. Collis RE, Davies DWL, Aveling W. Randomized comparison of combined spinal–epidural and standard epidural analgesia in labour. *Lancet* 1995; 345: 1413–1416.
4. Norris MC, Grieco WM, Borkowski M. Complications of labor analgesia: Epidural versus combined spinal–epidural techniques. *Anesthesia and Analgesia* 1994; 79: 529–537.
5. Holmstrom B, Rawal N, Axelsson K, Nydahl PA. Risk of catheter migration during combined spinal epidural block: Percutaneous epiduroscopy study. *Anesthesia and Analgesia* 1995; 80: 747–753.
6. Eldor J, Guedj P. Aseptic meningitis due to metallic particles in the needle-through-needle technique. *Regional Anesthesia* 1995; 20: 360.

Sir,—In a recent case report, Robbins, Fernando and Lim described the presumptive placement of an extradural catheter through the hole made by a 26-gauge Whitacre needle [1].

The authors are correct in stating that only diagnostic studies (MRI or x-ray contrast) can definitively confirm that diagnosis. It is not impossible that bupivacaine 12.5 mg could provide analgesia and increased motor block even if it were injected into the extradural space. We have now seen several cases where CSF could be aspirated from an extradural catheter after a spinal block was made with a 24- or 26-gauge pencil point needle passed through the extradural needle before catheter placement. In one instance, we were so concerned that the catheter was subarachnoid that it was removed and a new catheter was placed one interspace cephalad, at which time some CSF appeared in the hub of the

extradural needle (*not* a gush!) and a small amount of CSF could be aspirated through the catheter after it was placed.

After careful evaluation, this catheter was treated as if it were in the extradural space and a continuous infusion of 0.0625% bupivacaine and sufentanil was started. Based on spread and density of block, the catheter appeared to be in the extradural space rather than subarachnoid. This leads us to believe that a small percentage of patients may develop a clinically detectable and immediate CSF leak even when subarachnoid puncture is made with a small gauge pencil point needle. Interestingly, none of our patients developed a clinically detectable post-lumbar puncture headache.

As an aside, we also wonder whether Caesarean should be spelled with a capital C, as it was in this case report. We believe the word derives from the Latin verb for cut and is, in fact, often spelled cesarean, at least on this side of the Atlantic.

J. S. LEE
T. ABBOUD

Department of Anesthesiology
University of Southern California
Los Angeles, CA, USA

1. Robbins PM, Fernando R, Lim GH. Accidental intrathecal insertion of an extradural catheter during combined spinal-extradural anaesthesia for Caesarean section. *British Journal of Anaesthesia* 1995; 75: 355-357.

Sir,—Thank you for the opportunity to reply to the letters of Dr Camann, and Dr Lee and Professor Abboud regarding our case report [1].

Camann suggests that the risk of migration of an extradural catheter is no greater with combined spinal-extradural anaesthesia than with extradural anaesthesia alone. We have two points to raise on the matter. First, we claimed that the catheter was placed intrathecally and did not migrate to this position. Second, we believe that an extradural catheter will not migrate through intact dura at any time. Holmstrom and colleagues [2] make the point that it is unlikely that an extradural catheter enters a hole made by a spinal needle. By implication such an occurrence is even more unlikely to occur if there is *no* hole made in the dura. We feel that many of these reports may have occurred when the dura was punctured accidentally at some moment by the extradural needle. Even small movements of the needle might cause unintentional damage [3].

We are also not implying that extradural catheter migration is increased with the combined spinal-extradural technique, and agree with Dr Camann that isolated case reports should not prevent its acceptance into practice. However, we do feel that this safe technique is improved by the knowledge that intrathecal catheter placement could occur, and the obvious complications of such placement could be avoided by aspiration and a test dose. In our obstetric unit not only are all elective Caesarean sections performed using combined spinal-extradural anaesthesia, but 75% of all regional blocks for labour analgesia are initiated using the same technique.

Dr Lee and Professor Abboud state that bupivacaine 12.5 mg could have caused the increase in motor and sensory block that we observed after operation, even if it were administered extradurally. We cannot agree with this comment. We gave a 12.5-mg (2.5 ml) injection which, after allowing for the deadspace of the catheter and filter, delivered 7.5 mg (1.5 ml) to the patient. Fink [4] makes the point that it is the length of nerve exposed to local anaesthetic solution that is important. Therefore, it is unlikely that a 12.5-mg (2.5 ml) bolus, let alone a 7.5-mg (1.5 ml) bolus, will have a significant effect if administered into the extradural space, even if sufficient time was allowed.

We agree that some CSF may be seen in the catheter or extradural needle after the spinal needle is removed. This is caused by pressure (especially if the patient is in the sitting position during the combined spinal-extradural anaesthesia) causing CSF to leak out of the spinal needle hole and is not a result of dural puncture with the extradural needle. Based on our continuous positive aspiration and on the speed and density of the block with bupivacaine 7.5 mg, we believe that our catheter was subarachnoid.

Caesarean was spelt with a capital C by the editors of the *British Journal of Anaesthesia*. We have found numerous derivations, including the mechanism of Caesar's birth, and from *Lex Caesarea*

(the law of removing a fetus from a dead mother before burying her). Also, the Latin to cut is caedere (with ae) or scalpere. Caesarean may be spelt cesarean in the USA together with anaesthesia, pediatrics, labor, and color, but on our side of the Atlantic we believe that we are correct.

P. M. ROBBINS
R. FERNANDO
Royal Free Hospital
London
G. LIM
Whittington Hospital
London

1. Robbins PM, Fernando R, Lim GH. Accidental intrathecal insertion of an extradural catheter during combined spinal-extradural anaesthesia for Caesarean section. *British Journal of Anaesthesia* 1995; 75: 355-357.
2. Holmstrom B, Rawal N, Axelsson K, Nydahl PA. Risk of catheter migration during combined spinal epidural block: Percutaneous epiduroscopic study. *Anesthesia and Analgesia* 1995; 80: 747-753.
3. Meiklejohn BH. The effect of rotation of an epidural needle. *Anaesthesia* 1987; 42: 1180-1182.
4. Fink BR. Mechanisms of differential axial blockade in epidural and subarachnoid anaesthesia. *Anesthesiology* 1989; 71: 851-858.

Editor's Note

We also believe that we are correct in ascribing the derivation of Caesarean to the famous Roman gentleman.

EDITOR

RAE tube obstruction during tonsil dissection

Sir,—A 41-kg, 9-yr-old boy was admitted for adenotonsillectomy after recurrent attacks of tonsillitis and frequent bouts of snoring. Penicillin allergy was the only other history of note. Premedication included oral diazepam 6 mg, atropine 0.6 mg and topical EMLA.

A spontaneous breathing technique was planned using incremental injected isoflurane into a low-flow circle system. The trachea was intubated with an RAE 6.5-mm, preformed uncuffed orotracheal tube, and the patient attached to a Datex monitor for full non-invasive cardiorespiratory monitoring. The ENT surgeon inserted a Boyle-Davis gag using an 8.8-cm tongue plate, and examination revealed bilateral hypertrophic tonsils, but absence of enlarged adenoid tissue, and therefore adenoidectomy was unnecessary. Initial surgery and anaesthesia were uneventful but prolonged because of difficult dissection and haemostatic control of the left inferior tonsillar pole. To facilitate easier access and better haemostatic control, the tongue plate used initially was removed and a 10-cm blade inserted. After a few minutes, several events occurred simultaneously; oximetric saturation decreased rapidly, the reservoir bag became partially collapsed, while the surgeon noticed that the RAE tube had herniated through the gap of the tongue plate. Oxygen 100% was administered and a diagnosis of partial tracheal tube obstruction was made. Examination demonstrated that at the point of maximum convexity, the RAE tube had herniated through the gap of the blade, had become kinked and produced flaring of the edges which prevented removal of the tube, but had not caused complete lumen obstruction (fig. 1). Despite several attempts to extricate the RAE tube, it remained jammed in the blade. Therefore, although pulse oximetry returned to normal and tonsillar haemorrhage remained a problem, both RAE tube and gag were removed after pharyngeal suction and cricoid pressure were applied. Re-intubation was performed successfully with the same sized RAE tube, but using an 8.8-cm tongue plate. Subsequent surgery and anaesthesia proved uneventful, and the patient made an uncomplicated postoperative recovery.

The literature describes two reports; Shirley, Kulkarni and Frost [1], and Sen and Gupta [2] both communicated an episode of tube herniation through the Doughty blade during a similar procedure and noted remarkable difficulty in separating the RAE tube from the tongue plate. Contributory factors to tube herniation may have included: the use of a 6.5-mm RAE tube with a 10-cm blade, prolonged surgery causing tube softening and frequent repositioning of the Boyle-Davis gag because of surgical technical difficulties. Prevention of such herniation may include

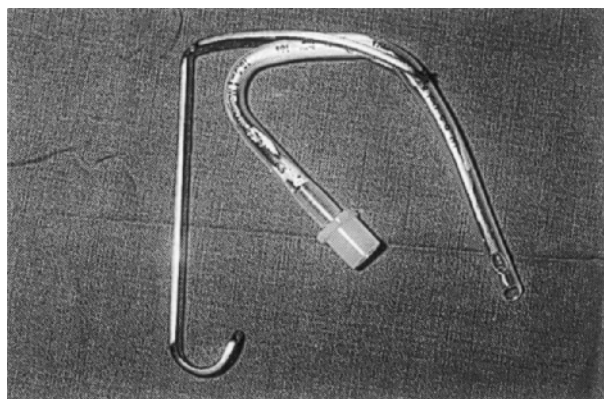


Figure 1 The RAE tube. At the point of maximum convexity, the RAE tube herniated through the gap of the blade, became kinked and produced flaring of the edges.

the use of a more rigid or reinforced tracheal tube [1], a bridge bar, as suggested by Oliver and Rao [3], or the use of a smaller Boyle–Davis gag, as suggested by Baigent and Dunn [4]. This case report not only highlights the need for vigilance during routine elective surgery, but also the value of surgical opinion and communication in helping to alert the anaesthetist to problems during upper airway surgery.

D. GRAHAM
H. S. KADDOUR
Department of Anaesthesia
Leeds General Infirmary
Leeds

1. Shirley PJ, Kulkarni V, Frost N. A problem with the Boyle–Davis gag following difficult intubation. *Anaesthesia* 1994; **49**: 551–552.
2. Sen K, Gupta B. Herniation of RAE tube through split Boyle–Davis gag. *Anaesthesia and Intensive Care* 1990; **18**: 577–578.
3. Oliver JJ, Rao J. Modification of the Doughty blade for the Boyle–Davis gag. *Anaesthesia* 1994; **49**: 89.
4. Baigent DF, Dunn B. Possible hazards with RAE preformed tracheal tubes. *Anaesthesia* 1984; **39**: 714–715.

Extradural clonidine for postoperative pain relief

Sir,—I read with interest the article by Lee and Rubin [1] which showed that caudal clonidine $2 \mu\text{g kg}^{-1}$ with 0.25 % bupivacaine 1 ml kg^{-1} improved postoperative analgesia in paediatric patients undergoing lower limb orthopaedic surgery compared with caudal 0.25 % bupivacaine alone. Although their results are consistent with another recent report [2], I have recently observed better postoperative analgesia using thoracic extradural clonidine with morphine than morphine alone in adults after gastrectomy [3].

In our study the intensity of pain was assessed by a member of staff who was blinded to the treatment, while each patient received i.v. morphine via a patient-controlled analgesia system as supplementary analgesia. Clinical evaluation of pain is possible in both an objective and subjective manner in adults, but that is not always the case in small children. Based on these considerations, I cannot exclude the possibility that intense sedation induced by extradural clonidine (with local anaesthetics) [4] would make estimation of pain intensity impossible. I also believe that some bias is likely to be introduced in the quantitative assessment of analgesia, especially in paediatric patients, if the patients receive analgesics only when the attending staff judges its requirement.

T. NISHIKAWA
Department of Anaesthesiology
Institute of Clinical Medicine
University of Tsukuba
Tsukuba City, Ibaraki, Japan

1. Lee JJ, Rubin AP. Comparison of a bupivacaine–clonidine mixture with plain bupivacaine for caudal analgesia in children. *British Journal of Anaesthesia* 1994; **72**: 258–262.
2. Jamali S, Monin S, Begon C, Dubousset A-M, Ecoffey C. Clonidine in pediatric caudal anesthesia. *Anesthesia and Analgesia* 1994; **78**: 663–666.

3. Anzai Y, Nishikawa T. Thoracic epidural clonidine and morphine for postoperative pain relief. *Canadian Journal of Anaesthesia* 1995; **42**: 292–297.
4. Nishikawa T, Dohi S. Clinical evaluation of clonidine added to lidocaine solution for epidural anesthesia. *Anesthesiology* 1990; **73**: 853–859.

Porphyria, propofol and rats

Sir,—I read with interest the study of Böhrer and colleagues [1] investigating the porphyrinogenicity of propofol in an induced rat model. I was somewhat surprised by aspects of their study design and subsequent attempts to extrapolate their results to the human anaesthetic state.

In a statement in their summary, an acute porphyric attack was described as largely a dose-dependent phenomenon. Yet, in their study, they chose to induce a state of prolonged sedation (the rats were readily rousable), rather than anaesthesia. This would have obvious inferences on blood propofol concentrations and potential porphyrinogenic effect. The reliance on the i.p. route of drug administration, while technically more convenient than the i.v. route, would imply that blood propofol concentrations were less controllable, and may explain why in the pilot study to establish the dose of propofol, they found it difficult to induce anaesthesia without the problems of irregular respiration and hypothermia. In a similar study, Harrison, Moore and Meissner [2] induced anaesthesia by the i.p. route, followed by maintenance by the i.v. route; this would seem to be a better model to parallel anaesthesia.

While successfully demonstrating another *in vivo* model for biochemical assessment of drug porphyrinogenicity, the study fails to recognize the difficulties of extrapolating such data to the human state. Harrison, Moore and Meissner stated that the behaviour of a drug in an animal model to assess porphyrinogenicity was far removed from proof that it was potentially safe or dangerous to a human sufferer with genetic porphyria. It simply serves to show that in that particular animal model, the drug either displays or fails to display properties known to characterize drugs that do precipitate crises in susceptible humans. Drug metabolism differs profoundly between species; even animals so apparently similar as rats and mice show marked variation in the response of their haem biosynthetic pathway to the effects of various drugs. Disler and colleagues [3] placed this type of work in context, by devising a simple classification of drugs to guide clinicians in the assessment of a drug's porphyrinogenicity.

To attempt to extrapolate such data would be to assume a simple relationship between a drug's ability to induce increased levels of porphyrin precursors in an *in vivo* animal model and its ability to induce a clinical attack. This is clearly not the case. The situation is far more complex, as illustrated by Mustajoki and Heinonen [4] who reported several cases where patients with acute porphyria received various porphyrinogenic drugs (including thiopentone) without clinical effect. This has led to the suggestion that sensitivity to a particular drug may depend on whether or not the patient is in the latent or acute phase of the disease, and on other factors, including endocrine and carbohydrate status at the time of administration.

Finally, the suggested caution regarding the use of propofol for total i.v. anaesthesia and cumulative dosing must also be viewed with some degree of scepticism. Apart from the reasons indicated above, I also suggest a closer review of the case reports used as references. Of the 10 cases, the majority received either repeated boluses or propofol infusions. One patient [5] admitted to the ITU because of neurological sequelae from an acute attack of porphyria received propofol at a dose of $150\text{--}200 \text{ mg h}^{-1}$ for 32 days without adverse biochemical or clinical effects. Where measured, urinary porphyrin precursors in these studies tended to decrease rather than increase.

M. D. TIDMARSH
Department of Anaesthesia
Leicester Royal Infirmary
Leicester

1. Böhrer H, Schmidt H, Martin E, Lux R, Bolsen K, Goerz G. Testing the porphyrinogenicity of propofol in a primed rat model. *British Journal of Anaesthesia* 1995; **75**: 334–338.
2. Harrison GG, Moore MR, Meissner PN. Porphyrinogenicity of etomidate and ketamine as continuous infusions. Screening in the DDC-primed rat model. *British Journal of Anaesthesia* 1985; **57**: 420–423.

3. Disler PB, Blekkenhorst GH, Eales L, Moore MR, Straughan J. Guidelines for drug prescription in patients with the acute porphyrias. *South African Medical Journal* 1982; **61**: 656–660.
4. Mustajoki P, Heinonen J. General anesthesia in “inducible” porphyrias. *Anesthesiology* 1980; **53**: 15–20.
5. Harrison JC, McAuley FT. Propofol for sedation in intensive care in a patient with an acute porphyric attack. *Anaesthesia* 1992; **47**: 355–356.

Sir,—The safety of propofol as an anaesthetic agent in human acute porphyrias is well established clinically. With such rare disorders, it is inevitable that most evidence should have been acquired by favourable single case reports (e.g. references [24–32], cited in reference [1]). A prospective study involving 13 patients represents a major confirmation of its safety [2].

Various models of the porphyrinogenicity of drugs in rats, chick embryo or chick embryo liver systems have been devised as a guide to the safety in porphyria of newly introduced therapeutic agents. Direct extrapolation of the findings to humans is not always possible, although some degree of correlation has been obtained with many agents. Before a new drug which has been shown to be highly porphyrinogenic in such a model system is used in a porphyric subject, there would have to be an overwhelming clinical need, not satisfied by available safe drugs. In a similar way, drugs apparently devoid of porphyrinogenic effects in model systems cannot be assumed to be innocuous to porphyric subjects. The gold standard remains careful human evaluation with facilities for early intervention.

Böhrer and colleagues [1] reported a study testing the porphyrinogenicity of propofol in a primed rat model and concluded that “it is a safe agent in the porphyric patient when given as a single bolus dose. Caution may be necessary, however, when large cumulative doses are administered”. The logic of this conclusion is difficult to understand, as are the reasons justifying the work: even if their model had shown propofol to be highly porphyrinogenic (as was the case in the primed chick embryos, which they reject as “too sensitive”), this would not have affected its established clinical use. When an anaesthetist has to make a choice, the precedents available from patients would surely prevail over results obtained with 48, or even 48 000 rats.

A. GORCHEIN
Imperial College of Science, Technology
and Medicine
London

1. Böhrer H, Schmidt H, Martin E, Lux R, Bolsen K, Goerz G. Testing the porphyrinogenicity of propofol in a primed rat model. *British Journal of Anaesthesia* 1995; **75**: 334–338.
2. Meissner PN, Harcison GG, Hift RJ. Propofol as an i.v. anaesthetic induction agent in variegate porphyria. *British Journal of Anaesthesia* 1991; **66**: 60–65.

Sir,—We appreciate Tidmarsh’s and Gorchein’s comments on our article which was published recently in *British Journal of*

Anaesthesia. We agree with both that there is no straightforward extrapolation of laboratory findings to the clinical setting which can be summarized by the simple expression “humans are not rats”.

However, it has been known for many decades that laboratory data may be relevant to the clinical situation. Drugs showing toxic effects in animal models may be used with caution in humans. When applied to porphyria, a drug which caused porphyrinogenic effects in the animal model may be used with more reluctance in the patient. Non-clinical assessment of the porphyrinogenicity of drugs has been made in the chick embryo liver cell culture, in the chick embryo *in ovo* and in rats with experimentally induced porphyria. In our study, we have chosen the *in vivo* rat model which may be more relevant to the clinical situation than the other systems mentioned. In Disler’s article quoted by Tidmarsh, the authors categorized drugs according to clinical experience and animal experiments; category A is based on human experience reported by three or more authors, B on human experience reported by one or two authors, C on experiments in rats and D on experiments in cell culture or *in ovo*. In our study, we used spontaneously breathing rats to avoid the hepatic effects of 6 h of mechanical ventilation, and at the end of this 6-h period, blood concentrations of propofol and phenobarbitone were measured to ensure significant levels.

In humans, acute hepatic porphyria is a complex disease. It is a pharmacogenetic disorder with variable penetrance, and acute attacks may be precipitated by a multitude of factors, including stress, infection, starvation, hormone changes and drugs. Variable penetrance implies that there is considerable intra- and inter-individual variability in the response to drugs. One porphyric patient may tolerate a continuous drug infusion over 32 days [1], while others may react adversely to doses of 1225 mg [2] or 1300 mg [3] of propofol. Thus when closely reviewing the case reports quoted and other data available, we believe that propofol can be considered safe when given as a single bolus or even as a double-bolus technique. With regard to the variable penetrance of the disease and the unpredictable occurrence of acute attacks, however, we would not use continuous infusions with total doses greater than 1000 mg in our patients. Moreover, for patients in the latent stage of acute hepatic porphyria, it may be better to avoid general anaesthesia and to offer a regional anaesthetic technique [4] in spite of the occurrence of neuropathological lesions.

H. BÖHRER
Department of Anaesthesia
University of Heidelberg
Heidelberg, Germany

1. Harrison JC, McAuley FT. Propofol for sedation in intensive care in a patient with an acute porphyric attack. *Anaesthesia* 1992; **47**: 355–356.
2. Bichel T, Joris J, Jacquet N, Lamy M. Total intravenous anaesthesia in South-African genetic porphyria (variegate porphyria). *Acta Anaesthesiologica Belgica* 1993; **44**: 25–29.
3. Elcock D, Norris A. Elevated porphyrins following propofol anaesthesia in acute intermittent porphyria. *Anaesthesia* 1994; **49**: 957–958.
4. Böhrer H, Schmidt H. Regional anesthesia as anesthetic technique of choice in acute hepatic porphyria. *Journal of Clinical Anesthesia* 1992; **4**: 259.