

## CLINICAL INVESTIGATIONS

## The carina as a landmark in central venous catheter placement†

M. Schuster<sup>1</sup>, H. Nave<sup>2</sup>, S. Piepenbrock<sup>1</sup>, R. Pabst<sup>2</sup> and B. Panning<sup>1\*</sup><sup>1</sup>Department of Anaesthesiology and <sup>2</sup>Department of Anatomy, Medical School Hannover, D-30623 Hannover, Germany

\*Corresponding author

Location of the tip of a central venous catheter (CVC) within the pericardium has been associated with potentially lethal cardiac tamponade. Because the pericardium cannot be seen on chest x-ray (CXR), an alternative radiographic marker is needed for correct placement of CVCs. The anatomy of the region was studied in 34 cadavers. The carina was a mean (SEM) distance of 0.4 (0.1) cm above the pericardial sac as it transverses the superior vena cava (SVC). In no case was the carina located below the pericardial sac. The carina is a reliable, simple anatomical landmark for the correct placement of CVCs. In almost all cases, the carina is radiologically visible even in poor quality, portable CXRs. CVC tips should be located in the SVC above the level of the carina in order to avoid cardiac tamponade.

Br J Anaesth 2000; 85: 192–4

**Keywords:** catheters, venous; complications, cardiac tamponade; heart, pericardium

Accepted for publication: February 7, 2000

Cardiac tamponade is a life-threatening complication of central venous catheter (CVC) placement. Current guidelines strongly advise that the CVC tip lies in the superior vena cava (SVC) and outside the pericardial sac.<sup>1</sup> This is difficult to achieve as the exact location of the pericardium cannot be seen on a normal chest x-ray (CXR). Various radiographic landmarks have been described to ensure extrapericardial location of the CVC tip in a safe position,<sup>2–4</sup> but none of these has achieved general acceptance. In addition, the awareness of physicians regarding the risks of malpositioned CVCs is still limited.<sup>4</sup>

We are unaware of any anatomical studies to verify the exact location of the pericardial sac in relation to other radiographically visible anatomical structures. Some clinicians use the carina as a landmark for the correct location of CVC tips, but this has not been investigated systematically. The aim of our study was to determine whether the carina can be used as a landmark below which no catheter tip should be located.

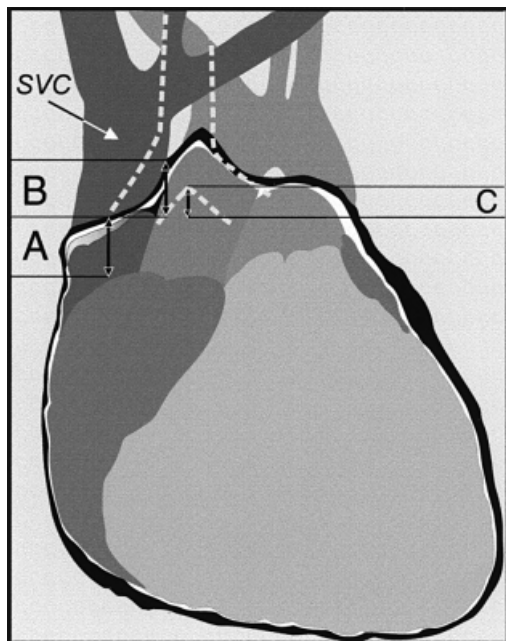
**Material and methods**

Thirty-four cadavers [11 male, 23 female, mean age 78 ((SEM) 1.7) (range 49–98) yr; length 166 (1.7) cm, range 144–186 cm] which were used for first year medical

students were examined in the dissecting room. After opening the chest, the lungs were removed by cutting the main bronchi and the accompanying vessels ~5 cm distal to the carina. The pericardial sac was cut open with a lambda-shaped wide incision. The aorta, the superior and inferior vena cava, and the pulmonary trunk were cut in the intrapericardial section of the vessels 2–3 cm away from the heart, so that the heart could be removed. The anatomy of the pericardial sac and its reflection were preserved with great care. The carina, located medially and posteriorly to the level of the great vessels, was palpated after removal of the heart. The sagittal distance was measured between the middle of the carina and the middle of the SVC.

In this university hospital with 1400 beds, several thousand CVCs are inserted each year. To assess whether the carina is visible in CXRs taken in the intensive care units, we studied 100 consecutive newly placed CVCs in seven intensive care units (cardiac surgery, abdominal surgery, transplantation surgery, trauma, anaesthesiology, cardiology and respiratory). All CXRs were taken as portable antero-posterior CXRs with the patient lying supine.

†This article is accompanied by Editorial II.



**Fig 1** The heart, the great vessels and the pericardial sac. The carina, which is anatomically located dorsally to the view shown, is indicated by dotted lines. The pericardial sac is depicted in black and white around the heart. All numbers are arithmetic mean (SEM). (A) The intrapericardial part of the SVC (3.0 (0.2) cm; range 1.0–5.0 cm). (B) The medial side of the SVC where a duplication of the pericardium fortifies the vessel wall (2.4 (0.1) cm; range 1.6–4.0 cm). (C) The longitudinal distance between the carina and the pericardium as it transveres the SVC (0.4 (0.1) cm; range 0.0–2.1 cm). SVC denotes superior vena cava.

## Results

The pericardium transveres the SVC almost horizontally (Fig. 1). At the medial side of the SVC, the pericardium is attached to the SVC wall and ascends with the SVC (Fig. 1) up to the beginning of the aortic arch. It then leaves the SVC and follows the aortic arch. The carina was a mean (SEM) distance of 0.4 (0.1) cm (range 0.0–2.1 cm) above the pericardium as it transveres the SVC (Fig. 1). The distance did not correlate with the length of the patient. In no case was the carina located below the pericardial reflection. The intrapericardial part of the SVC was 3.0 (0.2) cm (range 1.0–5.0 cm) long. The sagittal distance of the carina to the middle of the SVC was 3.0 (0.1) cm (range 1.5–4.1 cm).

Reviewing the post-insertion CXRs, we found that the carina could be identified in 96%. In 58% the catheter tip was located below the carina.

## Discussion

Since the first report in 1956,<sup>5</sup> cardiac tamponade following CVC placement has been reported in patients of all ages and with different types of catheters.<sup>167</sup> The mortality from cardiac tamponade following CVC placement was very high

in all the series,<sup>189</sup> but the real incidence is unknown. However, it is likely that this condition is under-reported.<sup>48</sup> In recent years, there have been modifications in catheters to reduce the risk of catheter-induced perforation, but there is no evidence that these new catheters reduce the incidence of cardiac tamponade.<sup>4</sup> Indeed, there are several reports of cardiac tamponade caused by soft silastic CVCs.<sup>11011</sup>

To prevent cardiac tamponade, various safe location criteria have been suggested, but all have major drawbacks. Greenall and colleagues suggested that the catheter tip should be no more than 2 cm inferior to a line drawn between the lower borders of the clavicles on an erect posterior-anterior CXR.<sup>2</sup> However, in the portable antero-posterior CXR used in intensive care units with the patient lying supine, the film is located much closer to the beam source than in posterior-anterior CXRs taken with the patient standing upright. As a consequence, anatomical structures located anteriorly and more peripherally, such as the clavicles, can be augmented on the film by more than 20%. This parallax effect makes the criteria suggested by Greenall less reliable. To circumvent the parallax problem, Rutherford and colleagues suggested that the angle formed between the right main bronchus and the trachea, which is located closer to the SVC, is a more appropriate landmark.<sup>3</sup> However, their work was not based on anatomical studies and it remained unclear whether it really guarantees an extrapericardial location of the CVC tip. Collier and colleagues suggested avoiding any location of the CVC tip which can be seen inside the cardiac silhouette on CXR,<sup>4</sup> but the border between the SVC and the right atrium is often indeterminable on CXRs. Moreover, the cardiac silhouette does not match the anatomical location of the pericardial sac, as our data show that the intrapericardial part of the SVC is 3.0 (0.2) cm (range 1.0–5.0 cm). A correctly placed catheter according to the criterion suggested by Collier and colleagues could still cause a cardiac tamponade by vascular erosion of the intrapericardial SVC, which has been reported previously.<sup>812</sup>

Our study shows that the carina is a reliable landmark for the placement of CVCs. In all cases, the pericardial sac ends below the level of the carina. The longitudinal distance between the level of the carina and the level of the upper end of the pericardial sac has a relatively small variability and does not correlate with the length of the patient. Our study also explains why CVC tips abutting the lateral wall of the SVC are especially dangerous:<sup>13</sup> the lateral side of the SVC is much weaker than the medial side, where the pericardial sac fortifies the vessel wall.

The carina as an anatomical landmark has several advantages; due to its fixation with connective tissue, its location is preserved even in pulmonary pathology. The central location and the small sagittal distance between it and the SVC (range 1.5–4.1 cm in our study) limit any parallax effect. Most importantly, the carina is easily visible even in a poor quality portable antero-posterior CXR.

In conclusion, cardiac tamponade is a potentially life-threatening complication of CVC placement which can be avoided if all catheter tips are located above the carina on CXR.

## References

- 1 Collier PE, Blocker SH, Graff DM, Doyle P. Cardiac tamponade from central venous catheters. *Am J Surg* 1998; **176**: 212–4
- 2 Greenall MJ, Blewitt RW, McMahon MJ. Cardiac tamponade and central venous catheters. *BMJ* 1975; **2**: 595–7
- 3 Rutherford JS, Merry AF, Occleshaw CJ. Depth of central venous catheterization: an audit of practice in a cardiac surgical unit. *Anaesth Intens Care* 1994; **22**: 267–71
- 4 Collier PE, Goodman GB. Cardiac tamponade caused by central venous catheter perforation of the heart: a preventable complication. *J Am Coll Surg* 1995; **181**: 459–63
- 5 Brown CA, Kent A. Perforation of right ventricle by polyethylene catheter. *South Med J* 1956; **49**: 466–7
- 6 Engelenburg KCA, Festen C. Cardia tamponade: a rare but life-threatening complication of central venous catheters in children. *J Pediatr Surg* 1998; **33**: 1822–4
- 7 Murray BH, Cohle SD, Davison P. Pericardial tamponade and death from Hickman catheter perforation. *Am Surg* 1996; **62**: 994–7
- 8 Defalque RJ, Campbell C. Cardiac tamponade from central venous catheters. *Anesthesiology* 1979; **50**: 249–52
- 9 Karnauchow PN. Cardia tamponade from central venous catheterization. *Can Med Assoc J* 1986; **135**: 1145–7
- 10 Greenspoon JS, Masaki DI, Kurz CR. Cardiac tamponade in pregnancy during central hyperalimentation. *Obstet Gynecol* 1989; **73**: 465–6
- 11 Kalen V, Medige TA, Rinsky LA. Pericardial tamponade secondary to perforation by central venous catheters in orthopaedic patients. *J Bone Joint Surg* 1991; **73**: 1503–6
- 12 Aldridge H, Jay A. Central venous catheters and heart perforation. *Can Med Assoc J* 1986; **135**: 1083–4
- 13 Ellis LM, Vogel SB, Copeland EM. Central venous catheter vascular erosions. *Ann Surg* 1989; **209**: 475–8