

# The lumbar epidural space in pregnancy: visualization by ultrasonography

T. Grau\*, R. W. Leipold, J. Horter, R. Conradi, E. Martin and J. Motsch

*Department of Anaesthesiology, University of Heidelberg, Im Neuenheimer Feld 110, D-69120 Heidelberg, Germany*

*\*Corresponding author*

Epidural anaesthesia is an important analgesia technique for obstetric delivery. During pregnancy, however, obesity and oedema frequently obscure anatomical landmarks. Using ultrasonography, we investigated the influence of these changes on spinal and epidural anatomy. We examined 53 pregnant women who were to receive epidural block for vaginal delivery or Caesarean section. The first ultrasound imaging was performed immediately before epidural puncture; the follow-up scan was done 9 months later. The ultrasound scan of the spinal column was performed at the L3/4 interspace in transverse and longitudinal planes, using a Sonoace 6000 ultrasonograph (Kretz®, Marl, Germany) equipped with a 5.0-MHz curved array probe. We measured two distances from the skin to the epidural space: the minimum (perpendicular) and the maximum (oblique) needle trajectory. The quality of ultrasonic depiction was analysed by a numerical scoring system. An average weight reduction of 12.5 kg had occurred by the follow-up examination. During pregnancy, the optimum puncture site available on the skin for epidural space cannulation was smaller, the soft-tissue channel between the spinal processes was narrower, and the skin–epidural space distance was greater. The epidural space was narrower and deformed by the tissue changes. The visibility of the ligamentum flavum, of the dura mater and of the epidural space decreased significantly during pregnancy. Nevertheless, ultrasonography offered useful pre-puncture information. Thus far, palpation has been the only available technique to facilitate epidural puncture. Ultrasound imaging enabled us to assess the structures to be perforated. We anticipate that this technique will become valuable clinically.

*Br J Anaesth* 2001; **86**: 798–804

**Keywords:** pregnancy; measurement techniques, Doppler ultrasound

Accepted for publication: February 14, 2001

Since Pages<sup>1</sup> took the first steps to introducing epidural block over 80 yr ago, the technique of epidural anaesthesia has steadily been improved upon. Major advances have been achieved in needle design and drug combinations, but identifying the epidural space still relies solely on a loss of resistance technique. Nevertheless, the accurate identification of the epidural space is the most vital part of the technique. For epidural block, correctly identifying the location of the space not only determines the success or failure of the epidural space procedure,<sup>2</sup> but may also influence the onset of action and rate of absorption of the drugs.<sup>3</sup>

Ultrasound imaging is widely used in medicine, but identification of the epidural space by ultrasonography is hampered by the surrounding bony structures.<sup>4</sup> The great improvement in ultrasound technology in recent years has

increased the possibility of it becoming a valuable tool before the performance of neuraxial anaesthesia. The first successful studies in the field of ultrasonic measurement of the epidural space date back 20 yr, when Cork and colleagues<sup>5</sup> and Currie<sup>6</sup> observed a strong relationship between the epidural space depth seen on ultrasonic images and the distance to the point of the epidural needle. Wallace<sup>7</sup> confirmed that needle depth is predictable from ultrasound depth measurement. In a more recent study, Bonazzi and de Gracia<sup>8</sup> were the first to identify the lumbar ligamentum flavum. They established the usefulness of ultrasound examination before epidural space puncture.

However, detailed knowledge of the pregnancy-related variability of the anatomy of the lumbar spinal column and its flanking ligaments is not available. In our clinic, parturients often present with abnormal anatomical condi-

tions such as scoliosis, hyperlordosis or kyphosis of the lumbar spine, severe obesity or local oedema, which can obscure anatomical landmarks. Additionally, hormonal changes during pregnancy result in an alteration in tissue consistency. Collagen concentration and organization, relative molecular proportions and the water content of the tissue are altered.<sup>9–10</sup> Subsequently, the structure of the inter-spinous ligament becomes softer and inhomogeneous. This often causes false loss of resistance, which can lead to malplacement of the epidural catheter.

Our aim was to investigate the influence of the tissue alterations of pregnancy on epidural technique. We scanned the lumbar epidural space of women during and after pregnancy. Variability in size of the L3/4 intervertebral space and changes in the localization of the ligamentum flavum and dura mater were recorded. We also graded how well the main anatomical landmarks were visualized by ultrasonography.

## Materials and methods

The ethics committee of Heidelberg University granted approval for this prospective follow-up study. We used a standardized study procedure, and written informed consent was obtained from all of the participating parturients, whose age, height, weight, and ASA index were noted. We examined 60 pregnant women who had been admitted to the university clinic to give birth and were to receive epidural block for vaginal delivery or Caesarean section. The first examination was performed immediately before epidural puncture and childbirth; the follow-up scan was done after a 250–300-day period.

Parturients who did not require epidural anaesthesia or in whom it was impossible for medical reasons were excluded

from the study, as were obstetric emergencies. None of the patients had a history of spinal surgery or trauma, or evidence of congenital spinal abnormalities. In a short clinical examination, we looked for signs of scoliosis, kyphosis or hyperlordosis, and local oedema (Table 1). The time taken for ultrasonic measurement was noted.

The scan of the spinal column was performed at the L3/4 interspace with the patient in the sitting position. The different transmission velocities of the ultrasonic beam through soft tissue and bone causes intense reflection and refraction at the soft tissue/bone interfaces.<sup>11</sup> A high percentage of ultrasound energy in epidural scans is lost on bone structures, which causes acoustic shadows on the resulting image. Each spinal process accounts for one shadow and the adjacent intervertebral space for one acoustic window. We performed scans in transverse and longitudinal planes. A Sonoace 6000 ultrasonograph (Kretz®, Marl, Germany) equipped with a 5.0-MHz curved array probe was used. Angles and distances were measured (mm) by the built-in software.

The needle length for epidural space puncture is shortest when the needle is advanced perpendicularly to the skin surface. This distance was measured in the transverse scanning plane. The distance is longest in a maximal oblique trajectory, which is the path along the spinal process. This distance was assessed in the longitudinal scanning plane. We also measured the angle between these trajectories.

The quality of ultrasonic depiction of the epidural space and the surrounding landmarks was analysed by a numeric scoring system (Table 2). The extent of the acoustic shadows was evaluated similarly (Table 2). In both scanning planes, the diameter of the intrathecal space (i.e. the distance between ligamentum flavum and vertebral body)

**Table 1** Physical characteristics of patients and pregnancy-related alterations. Data are mean (SD) [range]

	Pregnant	Not pregnant	Significance
Age (yr)	32.3 (4.4) [20–40]	33.0 (4.4) [21–41]	
Weight (kg)	81.0 (19.1)	68.5 (20.2)	<i>P</i> <0.001
Height (cm)	166.5 (7.5)	166.6 (7.4)	n.s.
Body Mass Index (kg m <sup>-2</sup> )	29.2 (6.5)	24.7 (7.1)	<i>P</i> <0.001
Dubois Index (cm <sup>2</sup> )	21057.1 (2500.0)	19472.9 (2634.6)	<i>P</i> <0.001
ASA Index (median)	2	2	n.s.
Pregnancy duration (days)	269 (16.4)		
Time passed to second scan (days)		272 (8.5)	

**Table 2** Synopsis of the scales of evaluation. All findings from the physical examination were numerically scored (0–3). The visibility of landmarks and the effect of acoustic shadows on the picture quality in the ultrasound examination, were evaluated in the same way

		0	1	2	3
Deviation from the longitudinal axis	<i>sagittal</i>	none	<2 cm	2–4 cm	>4 cm
	<i>lateral</i>	none	<2 cm	2–4 cm	>4 cm
Oedema		none	slight	moderate	severe
Ultrasonic visibility	<i>detectable</i>	not	hardly	well	very well
Acoustic shadow		none	small	intermediate	no ultrasound penetration

**Table 3** The number of patients with lumbar scoliosis, kyphosis, hyperlordosis and oedema during and after the pregnancy. For explanation of the scaling see Table 2

	Scoliosis		Kyphosis		Lordosis		Oedema	
P=pregnant, N=not pregnant	P	N	P	N	P	N	P	N
Degree [0]	42	43	45	46	49	49	39	44
Degree [1]	2	5	6	6	2	4	6	8
Degree [2]	6	5	2	1	2	0	7	1
Degree [3]	3	0	0	0	0	0	1	0
Significance	$P<0.29$ (n.s.)		$P<0.84$ (n.s.)		$P<0.26$ (n.s.)		$P<0.14$ (n.s.)	

**Table 4** Visibility of the key structures and influence of the acoustic shadows on the picture quality during and after pregnancy. For explanation of the scaling see Table 2

		Pregnant	Not pregnant	Significance
Visibility	Spinous process	1.5 (0.5)	1.7 (0.5)	n.s.
	Interarticular process	2.0 (0.7)	2.5 (0.6)	$P<0.001$
	Costal process	2.6 (0.5)	2.7 (0.5)	n.s.
	Ligamentum flavum	2.7 (0.5)	2.9 (0.3)	$P<0.005$
	Epidural space	1.4 (0.5)	1.7 (0.5)	$P<0.004$
	Dura mater	1.0 (0.4)	1.4 (0.5)	$P<0.001$
	Intrathecal region	0.9 (0.4)	1.0 (0.3)	n.s.
	Vertebral bodies	2.2 (0.6)	2.8 (0.4)	$P<0.008$
	Vertebral disks	0.1 (0.3)	0.3 (0.5)	n.s.
Acoustic shadow effects	Spinous process	1.1 (0.8)	0.9 (0.6)	n.s.
	Interarticular process	1.2 (0.7)	1.1 (0.8)	n.s.
	Costal process	1.3 (0.6)	1.5 (0.6)	n.s.
	Vertebral bodies	1.7 (0.7)	2.1 (0.5)	n.s.

was measured. We assessed the visible part of the ligamentum flavum between the vertebral arches (longitudinal extent) as the size of the ‘target area’.

Follow-up scan was performed 250–300 days after the first examination. A total of 53 patients (88.3%) presented for re-examination. Once again, sonotopography of the epidural structures was performed as described above.

### Statistics

We recorded all data on standardized forms using tick boxes. Data were analysed using the chi-squared test with Yates correction where appropriate, or using Student’s *t*-test. Excel 97™ Microsoft™, SPSS 7.5™ and Primer Biostatistik 4.04™ (S. A. Glantz) software were used for statistical analysis. Data are given as mean (SD) unless stated otherwise.

### Results

From the 60 parturients participating in the study, 53 women presented for follow-up examination. Only their data were evaluated. There were no premature births in this group. All ultrasound scans were performed in the 38th week of pregnancy or later. On average, the follow-up scan was performed 272 days after childbirth. At this time, no

participant was pregnant. The physical characteristics of the patients and changes in body indices are listed in Table 1. The first ultrasonic examination and documentation took 8.4 (4.1) min, so that analgesia onset time was not substantially delayed by participating in the study.

At the first clinical examination, 11 patients (20.8%) presented with axis deviation of the spine and 14 (26.4%) showed lumbar oedema. One parturient suffered from pre-eclampsia and presented with severe oedema. The number of pathological findings decreased at the follow-up examination, but no significant difference could be established (Table 3).

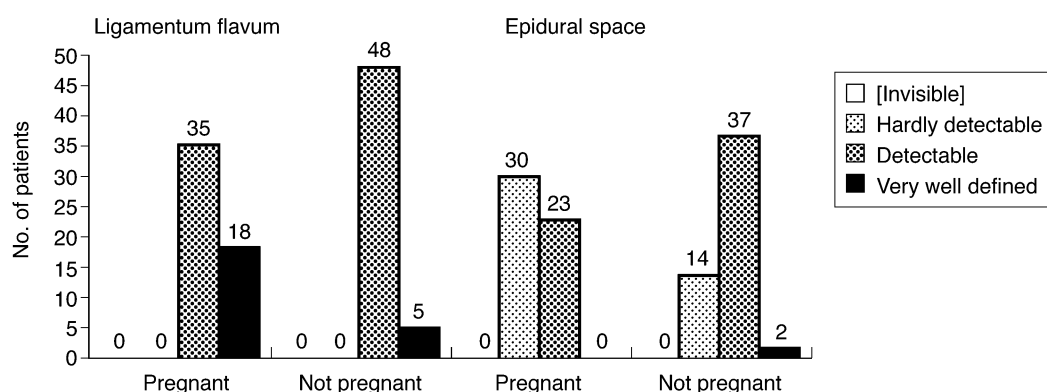
In the first examination, the visibility of the ligamentum flavum, the major target of epidural space ultrasonography, was scored as ‘very well detectable’ (2.7 (0.5); for all numerical scoring see Table 2). The visibility of the epidural space was scored as relatively poor (1.4 (0.5)) (Fig. 1), and the visibility of the dura mater (1.0 (0.4)) and intrathecal space (0.9 (0.4)) (Fig. 2).

The vertebral body in the pregnancy state caused a strong signal on ultrasound images (2.2 (0.6)), whereas the vertebral discs could hardly be demonstrated at all (0.1 (0.3)). The visibility of the spinous process was rated as 1.5 (0.5) (Table 4). Figure 3 shows the typical findings.

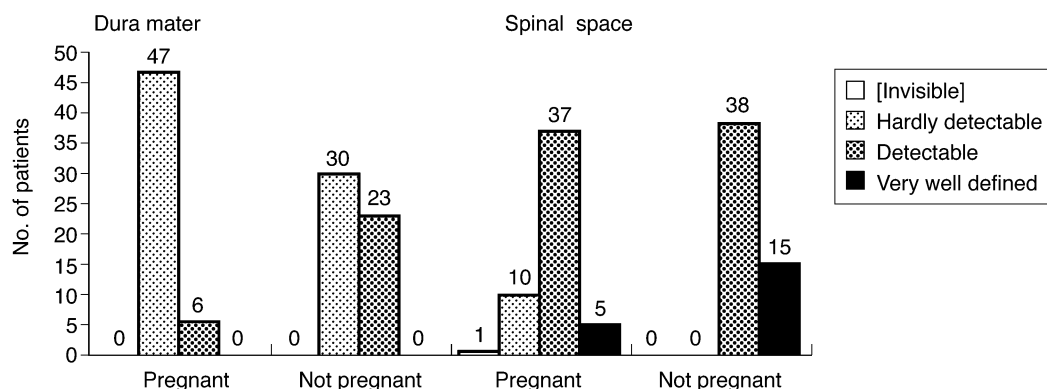
The follow-up examination 9 months post-partum showed noticeable improvements in visibility. The liga-

**Table 5** Comparison of ultrasonic measurements during and after pregnancy. The minimal distance was measured perpendicularly, the maximal distance in an oblique trajectory along the spinal process. The angles given were measured between the diagonal and the perpendicular trajectory. The height of the flaval ligament corresponds to the size of the target area. \*'distance'=distance between skin surface and lig. flavum

Measured values	Trajectory	Units	Pregnant	Not pregnant	Significance
Minimum distance*	Horizontal	(mm)	49.5 (8.1)	44.6 (7.3)	$P<0.001$
Maximum distance*	Diagonal	(mm)	53.6 (8.5)	48.3 (7.3)	$P<0.001$
Puncture angle	Diagonal	(degree)	17.5 (2.5)	19.8 (3.7)	$P<0.001$
Height of lig. flavum		(mm)	9.1 (1.4)	8.7 (1.0)	n.s.
Diameter of the intervertebral space		(mm)	10.7 (1.7)	11.6 (1.6)	$P<0.006$



**Fig 1** Comparison of the visibility of the ligamentum flavum and the epidural space in pregnant and non-pregnant patients ( $P<0.01$ ).



**Fig 2** Comparison of the visibility of the dura mater and of the spinal space in pregnant and non-pregnant patients ( $P<0.001$ ).

mentum flavum could easily be recognized (mean score of 2.9 (0.3);  $P<0.005$ ). The epidural space itself (1.7 (0.5);  $P<0.004$ ) and the dura mater (1.4 (0.5);  $P<0.001$ ) were identified without difficulty more frequently.

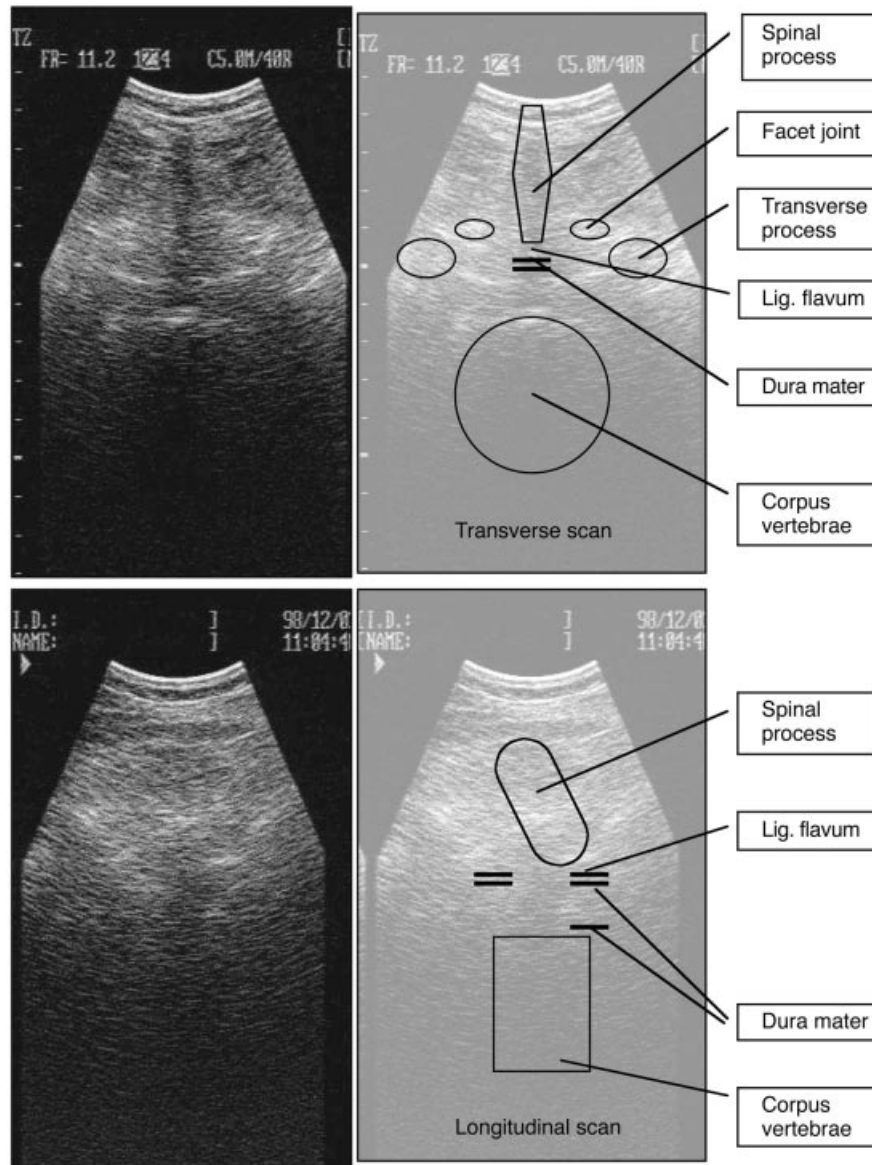
Figures 1 and 2 indicate that the ligamentum flavum was detectable by ultrasound in both the pregnant and non-pregnant states. But the epidural space was hardly detectable in 57% of pregnant patients yet was detectable in 75% of those who were not pregnant (Fig. 1). The dura was hardly detectable in 88% of the pregnant and 56% of the non-pregnant group (Fig. 2).

The visibility of the intrathecal space post-partum was rated as 1.0 (0.3; n.s.) (Table 4). The visibility of the vertebral body was significantly better (2.8 (0.4);  $P<0.008$ ),

and the visibility of the spinous process was 1.7 (0.5; n.s.). As in pregnancy, the vertebral discs could not be detected satisfactorily (0.3 (0.5)). The intensity of the acoustic shadows showed no significant alteration post-partum (Table 4). Figure 4 shows typical findings.

During pregnancy, the average length of the perpendicular trajectory from the skin surface to the ligamentum flavum was 49.5 (8.1) mm. The maximum distance was 53.6 (8.5) mm with an angle of 17.5 (2.5)° to the horizontal trajectory. The height of the spinal interspace was 10.7 (1.7) mm (Table 5).

In the follow-up examination, the minimum distance from the skin to the flaval ligament was reduced to 44.6 (7.3) mm ( $P<0.001$ ). The angle along the spinous process



**Fig 3** Perpendicular ultrasound scans of a pregnant patient transected longitudinally with an additional graphic for the explanation of the localization.

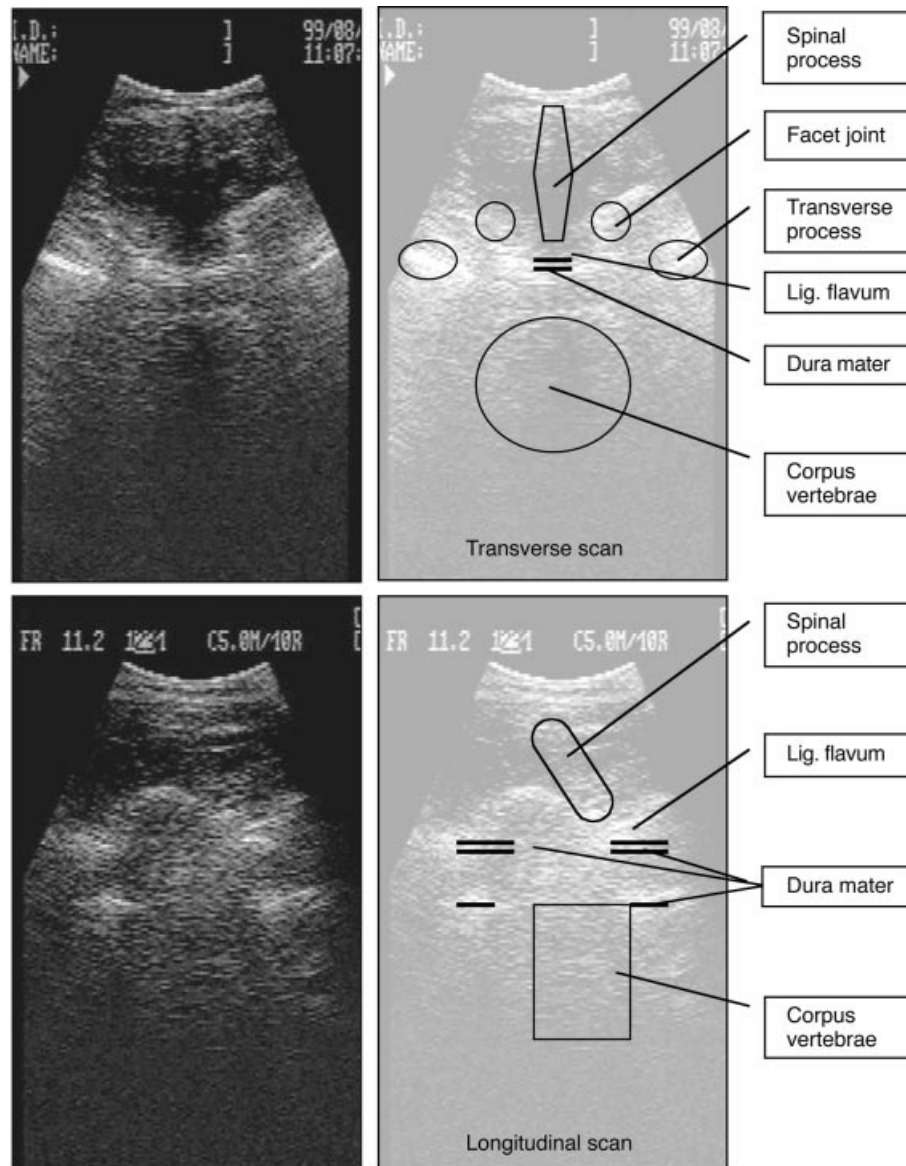
was wider ( $19.8 (3.7)^{\circ}$ ;  $P < 0.001$ ) and the maximum distance was smaller ( $48.3 (7.3) \text{ mm}$ ;  $P < 0.001$ ). The height of the spinal interspace increased significantly to  $11.6 (1.6) \text{ mm}$  ( $P < 0.006$ ) (Table 4).

## Discussion

Even under normal anatomical conditions, the performance of neuraxial regional anaesthesia is technically demanding. It has been recommended that it should only be performed by experienced practitioners after adequate training.<sup>12</sup> The importance of a meticulous technique for the avoidance of complications has been emphasized repeatedly.<sup>13 14</sup> During pregnancy, obesity and oedema frequently obscure anatomical landmarks,<sup>7</sup> the interspinous ligament is hormonally softened, and inhomogeneous tissue can cause false loss of

resistance. These changes may make neuraxial anaesthesia technically more difficult with more complications.

In this study, pregnancy-associated weight gain and tissue changes resulted in significant changes in spinal anatomy. These alterations were readily observed by the use of ultrasound imaging. During pregnancy, the epidural space was located deeper under the skin surface in all patients. The upward gradient of the space between the spinal processes was steeper and, hence, so was the angle of epidural space puncture. The size of the ligamentum flavum 'target area' did not seem to alter yet the diameter of the L3/4 intervertebral space was reduced. The explanations for these findings are probably oedema and loosening of connective tissue, causing an increase in the bone volume of the spinal processes. Thus, the optimum puncture area on the skin for epidural space cannulation was smaller and the



**Fig 4** Perpendicular ultrasound scans of the same women 270 days after pregnancy with a graphic for the explanation of the localization.

soft-tissue channel between the spinal processes was narrower by the end of pregnancy. The distance from the skin to the epidural space was longer and the epidural space was narrower. Therefore, the 'safety zone' between transfixation of the ligamentum flavum and inadvertent dural puncture was smaller.

The quality the sonographic depiction of the key structures was reduced by pregnancy. Nevertheless, ultrasonography can be a valuable guide to epidural space puncture in parturients. The average quality of depiction is diminished in pregnancy 50–70% from the non-pregnant state, but was sufficient to identify the flaval ligament and the epidural space in all cases.

Segal and colleagues were one of the more recent groups attempting to relate the depth of the epidural space to the physical characteristics of the patients.<sup>15</sup> Like the preceding

studies in this field,<sup>16 17</sup> their findings did not prove adequate for clinical use. Palpation is the only diagnostic method established for use during epidural puncture. Distance measurements other than by ultrasonography can only be obtained from a lateral radiograph of the lumbar spine or by computerized axial tomography, but radiography is an inappropriate diagnostic tool in pregnancy. Magnetic resonance imaging has expanded the diagnostic capabilities,<sup>18 19</sup> but is impractical in labour.

Ultrasonography is a promising technique for the assessment of spinal anatomy.<sup>4 20</sup> It is widely used during pregnancy, so parturients are familiar with it. The technique is free from adverse effects to mother and fetus. It is a mobile tool, which is readily available, even in the delivery room. There have been many advances in ultrasound imaging technology since earlier studies in this field were

reported.<sup>5-7</sup> By the use of an advanced sonographic system we were able to identify the flaval ligament in nearly all cases, and the dura mater and, subsequently, the epidural space in many cases. Often, a three-dimensional impression could be acquired using two perpendicular scanning planes; thereby, enabling us to preview the anatomy of the lumbar spine. Thus, modern ultrasonography can be a valuable support before performing regional anaesthesia.

## References

- 1 Herrera A, de las Mulas M. In memoriam Fidel Pages Mirave (1886–1923) on the 75th anniversary of the publication of 'Anesthesia metamerica'. *Rev Esp Anesthesiol Reanim* 1996; **43**: 59–66
- 2 Reynolds A, Roberts P, Pollay M, Stratemeier P. Quantitative anatomy of the thoracolumbar epidural space. *Neurosurgery* 1985; **17**: 905–7
- 3 Blomberg RG. The dorsomedian connective tissue band in the lumbar epidural space of humans: An anatomical study using epiduroscopy in autopsy cases. *Anesth Analg* 1986; **65**: 747–52
- 4 Grau T, Leipold RW, Conradi R, Martin E, Motsch J. Ultraschall und Periduralanästhesie: Technische Möglichkeiten und Grenzen einer diagnostischen Untersuchung des Periduralraumes. *Anaesthesist* 2001; **50**: 54–101
- 5 Cork R, Kryc J, Vaughan R. Ultrasonic localization of the lumbar epidural space. *Anesthesiology* 1980; **52**: 513–6
- 6 Currie J. Measurement of the depth to the extradural space using ultrasound. *Br J Anaesth* 1984; **56**: 345–7
- 7 Wallace DH, Currie JM. Indirect sonographic guidance for epidural anaesthesia in obese pregnant patients. *Reg Anesth* 1992; **17**: 233–6
- 8 Bonazzi M, de Gracia LB. Individuazione ecoguidata dello spazio epidurale lombare. *Minerva Anesthesiol* 1995; **61**: 201–5
- 9 Kelly RE, Verhage HG. Hormonal effects on the contractile apparatus of the myometrium. *Am J Anat* 1981; **161**: 375–82
- 10 Aspden RM. The theory of fibre-reinforced composite materials applied to changes in the mechanical properties of the cervix during pregnancy. *J Theor Biol* 1988; **130**: 213–21
- 11 Cittadini G, Martinoli C. Ultrasound and the bone: a difficult relationship. *Radiol Med (Torino)* 1995; **89**: 12–7
- 12 Cook TM. Combined spinal-epidural techniques. *Anaesthesia* 2000; **55**: 42–64
- 13 Auroy Y, Narchi P, Messiah A, Litt L, Rouvier B, Samii K. Serious complications related to regional anesthesia: results of a prospective survey in France. *Anesthesiology* 1997; **87**: 479–86
- 14 Horlocker TT, McGregor DG, Matsushige DK, Schroeder DR, Besse JA. A retrospective review of 4767 consecutive spinal anesthetics: central nervous system complications. *Anesth Analg* 1997; **84**: 578–84
- 15 Segal S, Beach M, Eappen S. A multivariate model to predict the distance from the skin to the epidural space in an obstetric population. *Reg Anaesth* 1996; **21**: 451–455
- 16 Palmer SK, Abram SE, Maitra AM, von Colditz JH. Distance from the skin to the lumbar epidural space in an obstetric population. *Anesth Analg* 1983; **62**: 944–6
- 17 Harrison GR, Clowes NWB. The depth of the lumbar epidural space from the skin. *Anaesthesia* 1985; **40**: 685–7
- 18 Crighton IM, Barry BP, Hobbs GJ. A study of the anatomy of the caudal space using magnetic resonance imaging. *Br J Anaesth* 1997; **78**: 391–5
- 19 Westbrook JL, Renowden SA, Carrie LES. Study of the anatomy of the extradural region using magnetic resonance imaging. *Br J Anaesth* 1993; **71**: 495–8
- 20 Grau T, Leipold RW, Conradi R, Martin E, Motsch J. Ultrasound imaging facilitates localization of the epidural space during combined spinal-epidural anesthesia. *Reg Anaesth* 2001; **26**: 64–7