

Non-fatal amniotic fluid embolism after cervical suture removal

J. Haines* and R. G. Wilkes

Department of Anaesthesia, Liverpool Women's Hospital, Crown Street, Liverpool L8 7SS, UK

*Corresponding author. E-mail: jez@drhaines.freemove.co.uk

We describe a case of pulmonary oedema occurring at 37 weeks gestation, following the attempted removal of a cervical suture under general anaesthesia. The use of an ultrasound technique to demonstrate the patient's fluid status is described. Signs of amniotic fluid embolism and how it exerts its influence on the circulation are discussed.

Br J Anaesth 2003; **90**: 244–7

Keywords: anaesthesia, obstetric; complications, embolism

Accepted for publication: September 10, 2002

A 28-yr-old patient, gravida 10 and para 3, had suffered recurrent miscarriages and each pregnancy that she had carried to term had been assisted with a cervical suture. Each had been delivered vaginally. During this pregnancy, the suture had been inserted at 13 weeks gestation under general anaesthesia, which had been uneventful. The rest of the pregnancy had been mostly uneventful, apart from three self-referrals to the labour ward complaining of abdominal pains and fluid loss vaginally at 26, 33, and 36 weeks gestation. Following careful examination on each occasion she had been reassured and discharged home.

At 37 weeks gestation she was admitted onto the delivery suite for removal of cervical suture. One knot was identified, divided, and the suture pulled through; a second knot was apparently identified and divided but the suture would not pull through. With the patient becoming increasingly distressed, it was decided to complete the procedure in theatre under anaesthetic. The patient was offered a spinal anaesthetic, which she declined, preferring a general anaesthetic.

She had undergone anaesthesia previously without complication, and had no medical history of note other than taking paroxetine for depression. She had no known allergies and a Mallampatti score of 2. The procedure was delayed for 2 h to allow an appropriate period of starvation. Ranitidine 150 mg and sodium citrate 0.3 M, 30 ml were administered orally.

Following preoxygenation, the patient was anaesthetized with a rapid sequence induction, using thiopental 450 mg and succinylcholine 100 mg. The trachea was intubated easily with a 7.5 mm cuffed oral endotracheal tube and IPPV instituted with isoflurane in oxygen and nitrous oxide. A brief episode of straining on the tracheal tube occurred

after 30 min, which was accompanied by a drop in oxygen saturation to 85%. This was resolved within 30 s by the administration of atracurium 25 mg and hand ventilation with $F_{I_{O_2}}$ 1.0. Oxygenation of 98% was subsequently maintained with $F_{I_{O_2}}$ of 0.5.

The procedure lasted over 1 h and it was found that the 'suture' was in fact a ring of fibrous tissue. It was decided to wake the patient, and discharge her home the next day. She was to return and be examined in early labour, and if cervical dilatation occurred appropriately, she would be allowed to progress to normal vaginal delivery.

At the end of the procedure neostigmine 2.5 mg and glycopyrrolate 0.5 mg were administered. The patient's lungs were hand ventilated with oxygen 100% until the return of adequate spontaneous ventilation. Soon after the onset of spontaneous respiration the patient's oxygen saturation dropped to 85%, respiration was noisy and there were bilateral coarse crepitations on auscultation. A small amount of pink sputum was aspirated by soft suction catheter from the tracheal tube and oxygen saturation improved with hand ventilation. Soon after this, a copious amount of pink frothy fluid exited the tracheal tube and the oxygen saturation dropped to 80%. The patient was re-anaesthetized with a small amount of isoflurane, and a decision was made to perform Caesarean section. The fetal heart was assessed with a sonicaid device and found to be at an appropriate rate. Arterial pressure dropped to a low of 90 mm Hg systolic, and heart rate of 135 beats min^{-1} .

The patient received 2000 ml crystalloid before delivery. It was noted that the patient's face had become acutely oedematous. At this stage the internal jugular vein was imaged with a 'SiteRite II' ultrasound machine and was seen to be very full (Fig. 1).

Blood taken at this stage revealed haemoglobin of 7.4 g dl⁻¹, platelets 391 × 10⁹ litre⁻¹, leucocytes 21.5 × 10⁹ litre⁻¹, prothrombin time 14.7 s and activated partial thromboplastin time 25.3 s. D-dimers were elevated (Table 1). Urea and electrolytes were all within normal limits as was a blood tryptase. A live male baby was delivered 2 h 15 min into the anaesthetic (1 h 15 min attempting to remove suture, 45 min attempting to recover and stabilize the patient, and 15 min to prepare for Caesarean section). Post-delivery, syntocinon 10 units slowly i.v., morphine 10 mg i.v. and augmentin 1.2 g i.v. were administered. Apgar scores were 3 at 1 min and 8 at 5 min, and the baby did not require treatment on the special care baby unit. At Caesarean section, the placenta, which was not a praevia, was found to have abrupted and 2000 ml of blood was present in the uterus. Blood transfusion was commenced. Throughout the operation, the patient had required 100% oxygen to maintain an oxygen saturation >90%. At the end of the operation the neck veins were again assessed with the 'SiteRite II', with the patient in the same position. They were found to have

collapsed (modes of ventilation were the same in each assessment of the veins) (Fig. 2).

The patient's chest at this stage was clear to auscultation and oxygen requirement had decreased to 60%. The facial swelling was also decreasing. She was sat up and, when adequate spontaneous breathing was established her trachea was extubated. Chest x-ray showed diffuse pulmonary infiltrates bilaterally. ECG was normal. A sample of pulmonary oedema fluid was sent to identify fetal squames, but unfortunately this was inappropriately fixed in formalin and was unsuitable for examination. The patient received 4 units of packed red cells over an 8-h period after surgery. She was nursed in an HDU area for 48 h during which time her oxygen requirement decreased to room air and serial chest x-rays showed progressive resolution of the pulmonary oedema. She was reviewed at an anaesthetic follow up clinic 6 weeks later, and had made a complete recovery. The baby was also doing well.

Discussion

We diagnosed amniotic fluid embolism and in this case it explained the association of the abruption with acute

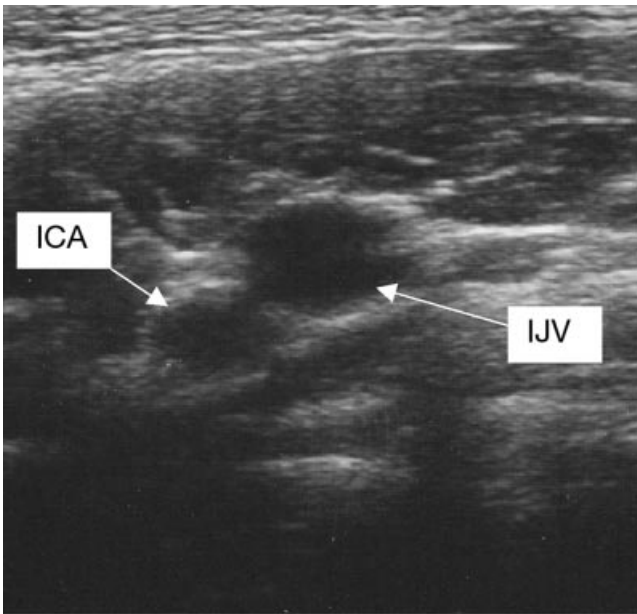


Fig 1 The internal jugular vein viewed with a 'SiteRite II' ultrasound machine at the time when the patient's face had become acutely oedematous. ICA=internal carotid artery; IJV=internal jugular vein (distended).

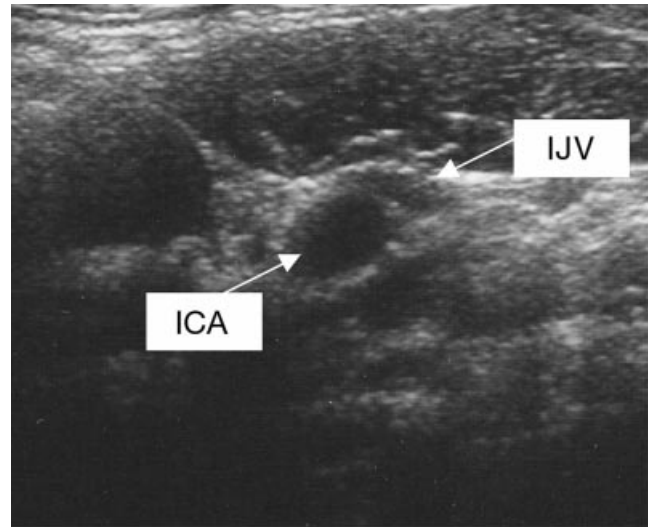


Fig 2 The internal jugular vein viewed with a 'SiteRite II' ultrasound machine after surgery. ICA=internal carotid artery; IJV=internal jugular vein (collapsed).

Table 1 Time course of blood investigations

Timing	Haemoglobin (g dl ⁻¹)	WCC (×10 ⁹ litre ⁻¹)	Platelets (×10 ⁹ litre ⁻¹)	PT (s)	APTT (s)	D-dimer (µg ml ⁻¹)	Fibrinogen (g litre ⁻¹)
Pre-op	7.4	21.5	391	14.7	25.3	3.20	3.04
+2 h	6.7	20.0	358	14.5	25.4	3.10	5.96
+6 h	7.5	13.6	271	13.8	29.0	2.11	
+14 h	8.8	10.8	249	14.8	30.9	2.74	4.21
+24 h	9.0	13.3	227	14.4	29.8	2.48	3.70
+36 h	9.2	14.3	278	14.4	30.1	1.12	4.65

APTT=activated partial thromboplastin time; PT=prothrombin time; WCC=white cell count.

hypoxaemia and pulmonary oedema. We believe it is the first reported case of suspected amniotic fluid embolism following attempted cervical suture removal. Although there is no definite proof for amniotic fluid embolism in this case, we believe that there is strong circumstantial evidence.

Amniotic fluid embolism was first described by Meyer¹ in 1926 and became an established clinical entity with the publication of Steiner and Lushbaugh's paper in 1941.² Their description of the clinical presentation states, 'Profound shock coming on in a woman who is in unusually severe labour or who has just finished such a labour, especially if she is an elderly multipara with an excessively large, perhaps dead fetus, and with meconium in the amniotic fluid, should lead to the suspicion of this possibility. If, also, the shock is introduced by a chill which is followed by dyspnoea, cyanosis, vomiting, restlessness and the like, and is accompanied by a pronounced fall in blood pressure and a rapid weak pulse, the picture is more complete. If *pulmonary oedema* now develops in the absence of previously existing heart disease, the diagnosis is reasonably certain.' Anderson³ and Peterson⁴ have published a series of amniotic fluid embolism cases, and Morgan⁵ published a review of 272 cases that demonstrated the frequency of initial presentation of symptoms in amniotic fluid embolism.

These showed that the most commonly encountered presentation is one of dyspnoea and hypoxaemia, as in our case. Pulmonary oedema is a common feature. Hypotension and coagulopathy, although common, are not invariably present.⁶ It has been suggested that there is a maternal neutrophilic response to amniotic fluid embolism with the neutrophils covering the fetal squame cells,⁷ and this is compatible with our case. The chest x-ray in our patient clearly showed pulmonary oedema and ECG was normal apart from a sinus tachycardia.

Predisposing factors that have previously been thought to make amniotic fluid embolism more likely and/or more severe include increasing maternal age, increasing parity, tumultuous labour, particulate matter in the amniotic fluid,⁸ large fetus or stillbirth,² and premature placental separation.⁴ However, other reviews have cast doubt on all except multiparity as a risk factor for amniotic fluid embolism⁵ or been able to find no associations at all for maternal risk factors.⁹

Amniotic fluid embolism is most commonly seen in labouring mothers. However, there are several case reports of amniotic fluid embolism occurring during Caesarean sections¹⁰ and terminations of pregnancy.¹¹ There is no report in the literature of amniotic fluid embolism having occurred during removal of cervical suture.

Our patient was certainly multiparous, but she was only 28, and the only comment on the liquor was that it was heavily blood stained. While she had not been in labour, she had undergone multiple examinations of a constricted, fibrous cervix. Also, there was premature placental separation, thus creating a portal of entry of the amniotic fluid

into the maternal circulation. Once the fluid is present in the maternal circulation, it progresses to the right side of the heart and into the pulmonary artery and capillaries.

There are a number of theories as to how the amniotic fluid exerts its influence on the circulation.¹² First, it can cause a mechanical obstruction, leading to pulmonary hypertension, decreased left sided filling and consequently systemic hypotension.⁵ This would cause an increase in pulmonary capillary wedge pressure, pulmonary artery pressure, and consequently right-sided filling pressure and elevated central venous pressure as was seen initially in our case with the SiteRite II. A mechanical obstruction would also cause V/Q mismatch with resultant hypoxaemia. This obstruction to venous drainage could also be the cause of the rapid accumulation of facial oedema, which we saw in our patient. There may also be vaso active components in the amniotic fluid, possibly prostaglandin F₂α,¹³ which cause an intense pulmonary vascular constriction. The alveolar capillary leak causing the pulmonary oedema may be a result of extensive microembolic insult, or following a localized or more generalized anaphylactoid reaction mediated by leukotrienes in the amniotic fluid.¹⁴ This could also explain the facial oedema. However, there was no other evidence for an immunologically mediated reaction (rash, bronchospasm, cardiovascular collapse) and plasma trypase was normal.

Diagnosing amniotic fluid embolism in life is notoriously difficult, and most are diagnosed at post-mortem by finding amniotic fluid debris in the pulmonary vasculature. Pulmonary oedema fluid has been analysed in previous cases and been shown to contain lanugo and squames in women with suspected amniotic fluid embolism. Unfortunately in our case the specimen sent to the laboratory was preserved in an inappropriate medium, and any potential information was lost. Pulmonary microvascular cytology is a technique of collecting pulmonary capillary blood with a balloon tipped flow directed pulmonary artery catheter and subsequently analysing the sample using Papanicolaou's method looking for fetal squames, mucin, and hair.⁶ However, we chose not to site a central line or pulmonary artery catheter, given the potential for coagulopathy, the rapidity of the patient's recovery, and the satisfactory observation of the patient's fluid status using the SiteRite II.

Our case report highlights the need for extreme vigilance and high index of suspicion for amniotic fluid embolism in any pregnant individual, even when not in labour, especially if the patient is undergoing a procedure such as cervical suture removal.

References

- 1 Meyer JR. Embolia pulmonar amnio-caseosa. *Brasil Medico* 1926; 2: 301-3
- 2 Stienner PE, Lushbaugh CC. Maternal pulmonary embolism by amniotic fluid, as a cause of obstetric shock and unexpected deaths in obstetrics. *JAMA* 1941; 117: 1245-54, 1341-5

- 3 Anderson DG. Amniotic fluid embolism. A re-evaluation. *Am J Obstet Gynecol* 1967; **98**: 336–48
 - 4 Peterson EP, Taylor HB. Amniotic fluid embolism. An analysis of 40 cases. *Obstet Gynecol* 1970; **35**: 787–93
 - 5 Morgan M. Amniotic fluid embolism. *Anaesthesia* 1979; **34**: 20–32
 - 6 Vanmaele L, Noppen M, Vincken W, De Catte L, Huyghens L. Transient left heart failure in amniotic fluid embolism. *Intensive Care Med* 1990; **16**: 269–71
 - 7 Masson RG. Amniotic fluid embolism. *Clin Chest Med* 1992; **13**: 657–65
 - 8 Mulder JI. Amniotic fluid embolism: an overview and case report. *Am J Obstet Gynecol* 1985; **152**: 430–5
 - 9 Clark SL, Hankins GD, Dudley DA, Dildy GA, Porter TF. Amniotic fluid embolism: analysis of the national registry. *Am J Obstet Gynecol* 1996; **175**: 749
 - 10 Fletcher SJ, Parr MJ. Amniotic fluid embolism: a case report and review. *Resuscitation* 2000; **43**: 141–6
 - 11 Lawson HW, Atrash HK, Franks AL. Fatal pulmonary embolism during legal induced abortion in the United States from 1972 to 1985. *Am J Obstet Gynecol* 1990; **162**: 986–90
 - 12 Davies S. Amniotic fluid embolus: a review of the literature. *Can J Anaesth* 2001; **48**: 88–98
 - 13 Price TM, Baker VV, Cefalo RC. Amniotic fluid embolism. Three case reports with a review of the literature. *Obstet Gynecol Surv* 1985; **40**: 462–75
 - 14 Azegami M, Mori N. Amniotic fluid embolism and leukotrienes. *Am J Obstet Gynecol* 1986; **155**: 1119–24
-