

Appropriate placement of intubation depth marks in a new cuffed paediatric tracheal tube[†]

M. Weiss*, A. C. Gerber and A. Dullenkopf

Department of Anaesthesia, University Children's Hospital Zurich, Steinwiesstrasse 75,
CH-8032 Zurich, Switzerland

*Corresponding author. E-mail: markus.weiss@kispi.unizh.ch

Background. The aim of this study was to evaluate the appropriateness of intubation depth marks on the new Microcuff paediatric tracheal tube.

Methods. With local Institutional Ethics Committee approval and informed parental consent, we included patients from birth (weighing ≥ 3 kg) to 16 yr who were undergoing general anaesthesia requiring orotracheal intubation. Tracheal intubation was performed using direct laryngoscopy, the intubation depth mark was placed between the vocal cords, and the tube was taped to the lateral corner of the mouth. The distance between the tube tip and the tracheal carina was assessed by flexible bronchoscopy with the patients in supine, and their head in neutral positions. Tube sizes were selected according to the formula: internal diameter (ID; mm) = (age/4) + 3.5 in children ≥ 2 yr. In full-term newborns (≥ 3 kg) to less than 1 yr ID 3.0 mm tubes were used and in children from 1 to less than 2 yr ID 3.5 mm tubes were used. Endoscopic examination was performed in 50 size ID 3.0 mm tubes, and in 25 tubes of each tube size from ID 3.5 to 7.0 mm. Tracheal length and percentage of the trachea to which the tube tip was advanced were calculated.

Results. 250 patients were studied (105 girls, 145 boys). The distance from the tube tip to the carina ranged from 1.4 cm in a 2-month-old infant (ID 3.0 mm) to 7.7 cm in a 14-yr-old boy (ID 7.0 mm). Mean tube insertion into the trachea was 53.2% (6.3) of tracheal length with a minimum of 40% and a maximum of 67.6%.

Conclusions. The insertion depth marks of the new Microcuff paediatric tracheal tube allow adequate placing of the tracheal tube with a cuff-free subglottic zone and without the risk for endobronchial intubation in children from birth to adolescence.

Br J Anaesth 2005; **94**: 80–7

Keywords: children; equipment, cuffs tracheal; intubation, tracheal; monitoring, depth mark

Accepted for publication: June 26, 2004

Correct insertion depth of tracheal tubes in children is essential to avoid accidental bronchial intubation, irritation of the carina, and accidental extubation. The length of the trachea in neonates and infants (39.4–60.5 mm) is short, leaving little margin for error.¹ Thus, intubation depth marks at the tube tip have been introduced for optimal placement of the tube tip in the mid-tracheal position.²

However, as reviewed recently by Goel and Lim, a large disparity exists in the position and the presence of depth marks, bands, and lines between different types of uncuffed and cuffed tracheal tubes.³ Similarly, the lack of intubation depth marks and inappropriately high positioned depth marks in cuffed paediatric tubes have been reported.^{3–6} In the latter, the tube tip will become positioned critically deep in the trachea, when placed according to the depth marks. Further, even with the upper cuff border positioned directly below the vocal cords, a small margin of safety regarding

endobronchial intubation has been reported in cuffed paediatric tubes because of long tube cuffs and Murphy eyes.⁷ If placed with the tip in the mid-tracheal position, in many tracheal tubes the cuff will lie within the larynx, again particularly in those with long cuffs and a Murphy eye.⁴

Recently, a new cuffed paediatric tracheal tube (Microcuff Paediatric Tracheal Tube, Microcuff GmbH, Weinheim, Germany) with a high volume-low pressure cuff has been introduced. The thin-walled cuff is made

[†]*Declaration of interest.* In the authors' institution cuffed tracheal tubes have been routinely used in children from birth to adolescence since 2000. Dr Weiss and Dr Gerber are involved in the design and evaluation of a new cuffed tracheal tube in co-operation with Microcuff GmbH, Weinheim, Germany. No agreements or financial benefits arise from this co-operation. Dr A. Dullenkopf has been supported by a Clinical Research Grant provided from Microcuff GmbH, Weinheim, Germany for this study.

from polyurethane, which is thought to improve sealing characteristics, allowing shorter cuffs.⁸ The short cuff and the avoidance of a Murphy eye allows appropriate intubation depth with a cuff-free subglottic tube shaft.

The aim of the present study was to evaluate the appropriateness of the intubation depth marks in the new Microcuff paediatric tracheal tube in a large population of patients ranging from neonates to adolescence.

Methods

The intubation depth marks in the Microcuff paediatric tracheal tube are based on tracheal dimensions published by Griscom,¹⁹ potential tube tip displacement distances as reported in the literature,^{10–13} and the formula described by Motoyama for selection of cuffed tracheal tubes in children aged ≥ 2 yr (internal diameter [ID, in mm]=[age in yr/4]+3.5).¹⁴ For patients below 2 yr of age tubes were chosen according to the recommendations of Steward and Khine, respectively (Table 1).^{15 16}

The depth marks are placed so that the tube tip can be advanced to 60–65% of the shortest trachea of the related age group (Table 1). This results in a safe margin for caudal tube displacement during head flexion of at least 15 mm in a neonate, and of 32 mm in a 14-yr-old child (smallest child considered for an ID 7.0 mm tube) (Table 1).^{10 13} The short cuff allows a cuff-free subglottic tube shaft (distance between intubation depth mark and upper border of the cuff) of 9 mm in a 3.0-mm ID tracheal tube and of 22 mm for a 7.0-mm ID tracheal tube.^{17 18} The semi-circular glottic intubation depth mark, placed on the concave side of the tube, is placed between the vocal cords during direct laryngoscopy (Fig. 1). Four points proximal to the semi-circular mark indicate the distance to it (in total 8 mm) and are useful in adjusting the placement of a tube.

After obtaining local Institutional Ethics Committee approval and informed parental consent, paediatric patients from birth (weighing ≥ 3 kg) up to 16 yr of age undergoing general anaesthesia requiring oro-tracheal intubation were included in this study. Children with known airway

Table 1 Tube sizes and age-related anatomical and technical measures^{8 9}

Internal diameter (mm)	Intended age group (yr)	Cuff-free subglottic tube shaft (mm)	Length of cuff (mm)	Distance from depth marking to tube tip (mm)	Shortest (95% CI) tracheal length in the youngest child of age group (mm)	Percentage of tube tip advancement into trachea %	Distance from tube tip to carina in the shortest trachea of age group (mm)
3	Newborns (≥ 3 kg) to <1 yr	9	10	24	39.4	60.9	15.4
3.5	1 to <2 yr	10	12	27	43	62.8	16.0
4	2 to <4 yr	12	12	30	46.6	64.4	16.6
4.5	4 to <6 yr	12	15	34	53.8	63.2	19.8
5	6 to <8 yr	16	15	39	61	63.9	22.0
5.5	8 to <10 yr	16	20	45	68.2	66.0	23.2
6	10 to <12 yr	18	20	50	75.4	66.3	25.4
6.5	12 to <14 yr	19	22	54	82.5	65.5	28.5
7	14 to <16 yr	22	22	58	89.7	64.7	31.7

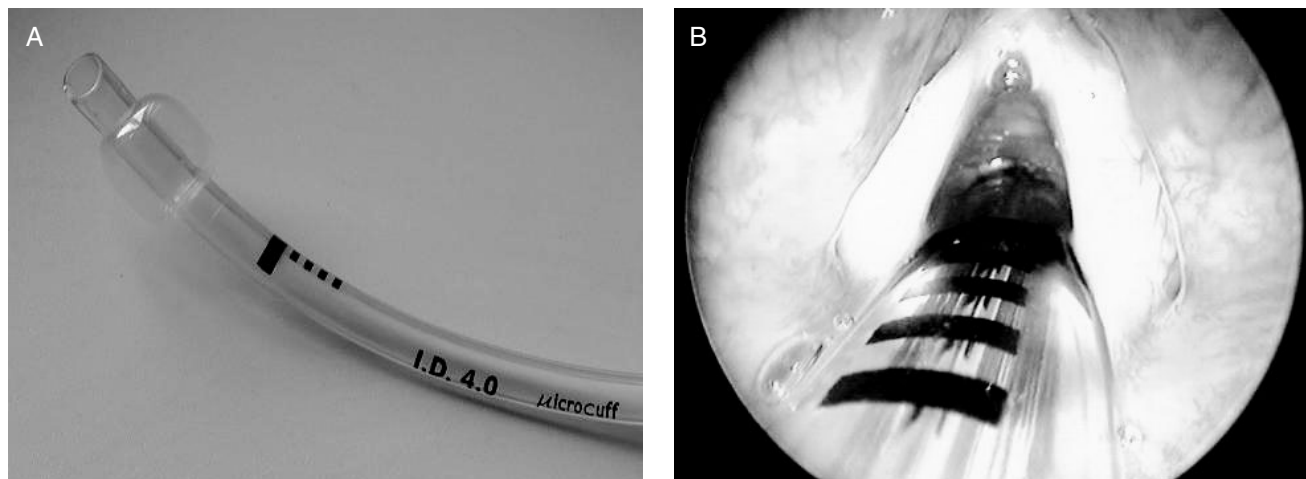


Fig 1 (A) Microcuff paediatric tracheal tube with high volume-low pressure cuff, semi-circular intubation depth mark, cuff-free subglottic tube shaft. (B) Glottic intubation depth mark placed between the vocal cords. The four points can be used to estimate the distance to the intubation depth mark in case of an obstructed view to the vocal cords or correction of too deep tracheal tube insertion.

anomalies, expected or previous difficult intubation, and an ASA physical status of more than III were excluded. Pre-medication and induction of anaesthesia (inhalation or i.v.) depended upon the patient's medical condition and preference. Monitoring included precordial stethoscope, pulse oximetry, ECG, and non-invasive blood pressure recording. After adequate mask ventilation was achieved, a non-depolarizing neuromuscular blocking agent was administered and anaesthesia was maintained with sevoflurane in oxygen. The tracheal tube size was selected according to Table 1. Tracheal intubation was performed by direct laryngoscopy, the glottic intubation depth mark placed between the vocal cords, and the tube taped at the right corner of the mouth. The correct tube position was initially confirmed by capnography and auscultation of the lungs. Adequate size of the tracheal tube was tested by the presence of air leakage at a maximum of 20 cm H₂O airway pressure with the cuff not inflated. If no air leakage was obtained, the tube was exchanged. The cuff was inflated to prevent audible air leakage with the cuff pressure not exceeding 20 cm H₂O, using a cuff manometer (Cuff Pressure Manometer, Mallinckrodt, Athlone, Ireland). The correct position of the intubation depth mark was confirmed by one of the two investigators using direct laryngoscopy, and adjusted if required. Subsequently, the distance from the tube tip to the tracheal carina was assessed by means of flexible video-endoscopy (Flexible Airway Endoscopes, Acutronic Medical Systems, Baar, Switzerland) using the drawback technique. A clip was placed on the fibrescope at the level of the swivel adapter as the crest of the tracheal carina

was just visualized on the monitor. Then the endoscope was drawn back until the proximal tube tip was visualized, and the distance between the clip and the level of the swivel adapter measured (Fig. 2).

Endoscopic examination was performed in 50 patients receiving a 3.0 mm ID tube and in 25 patients receiving a tube varying from ID 3.5 to 7.0 mm, with the patients in supine and their head in a neutral position. Neutral position of the head was defined as a vertical line from the external ear channel to the superior orbital margin (ear-eye-line). In addition, patient characteristics, tracheal tube insertion depth at the lateral corner of the mouth, and minimal cuff pressure required to seal the trachea were noted.

Statistical analysis

Data are presented as mean (SD) and/or median and range as appropriate. Tracheal length (vocal cords to carina distance) was calculated by adding the distance from depth mark to tube tip to the measured distance from tube tip to carina. The percentage of the trachea to which the tracheal tube tip was advanced within the trachea was calculated. Linear and/or logarithmic regression models were calculated for the relationship of the distance from the tube tip to the carina, calculated tracheal length and tube insertion depth to age, weight, and length. In patients ≥ 2 yr of age, the distances from the tube tip to carina were compared with those derived from standard formulae for oral tube insertion (insertion depth [cm] = $11.5 + [\text{age}(\text{yr}) \times 0.5]$ and $12 + [\text{age}(\text{yr}) \times 0.5]$, respectively).¹⁹ 95% confidence intervals (CI) were

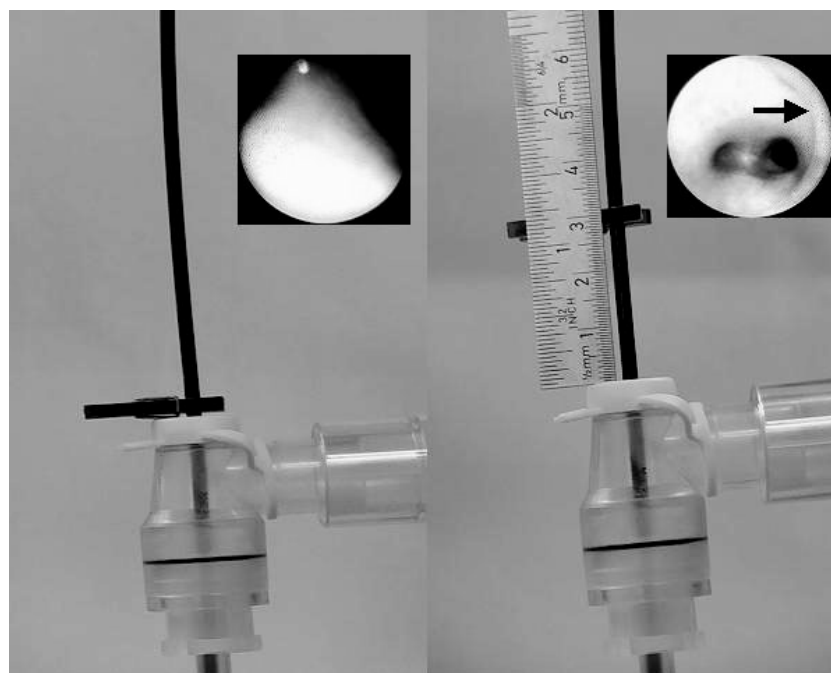


Fig 2 Measurement of the distance from tube tip to carina is performed using the fiberoptic drawback technique: a clip is placed on the fibrescope at the level of the swivel adapter as the crest of the carina is just visualized on the monitor (left). Then the endoscope is drawn back until the proximal tube tip (arrow) is just visualized, and the distance between the clip and the level of the swivel adapter is measured (right).

calculated for tracheal length and compared with those reported from radiological examination.^{1 9}

Results

250 patients (105 female, 145 male) were studied. Median height percentile was 43.1% (IQR 11.9–72.9%)²⁰ (Table 2). In two patients the selected tube (ID 3.5 mm and ID 5.5 mm) had to be replaced because of no air leakage at more than 20 cm H₂O airway pressure (height and weight in both patients below the third percentile).²⁰ In the remaining 248 patients, sufficient tracheal sealing was achieved with the cuff inflated to a pressure of ≤ 20 cm H₂O (median 10 cm H₂O [4–18]). The distance from the tube tip to the tracheal carina ranged from 1.4 cm in a 2-month-old infant to 7.7 cm in a 14-yr-old boy (Table 3). Calculated tracheal length ranged from 3.8 to 13.5 cm and demonstrated a good correlation with age ($r=0.923$), height ($r=0.926$), and less so with weight ($r=0.890$) (Fig. 4).

Mean tube tip advancement into the trachea was 53.2% (SD 6.3) of the tracheal length, with a minimum of 40% in a 3.5-yr-old boy and a maximum of 67.6% in a 10-yr-old boy (Table 3). Overall tube insertion depth from the lateral corner of the mouth correlated well with age (insertion [cm]=10.6+[age (yr)×0.5]; $r=0.956$), height ($r=0.960$), and less so with weight ($r=0.887$) for all patients (Fig. 3). For children ≥ 2 yr oral tube insertion depth (cm) corresponded to 11.5+[age (yr)×0.5] ($r=0.870$).

With correction of the distances the from the tube tip to the tracheal carina in children ≥ 2 yr according to an oral tube insertion depth (cm) of 11.5+(age [yr]×0.5) or 12+(age [yr]×0.5), the cuffs would have become placed within the larynx or even between the vocal cords in 56 and 20 patients, respectively. Furthermore, with the 12+(age [yr]×0.5) formula, 10 tubes would have been advanced below the margin of safety for caudal tube tip displacement during head-neck flexion (Fig. 3).

Calculated 95% CIs for measured trachea length, and those reported from radiological examination¹⁹ are presented in Table 4. Our data are comparable with those reported by Griscom.¹

Discussion

In this study, we evaluated the appropriateness of the intubation depth marks of the new Microcuff paediatric tracheal tube with regard to the distance from tube tip to the tracheal carina, and with regard to the tracheal insertion depth. The main finding was that the intubation depth marks provided a safe margin regarding inadvertent endobronchial intubation and were an improvement over a theoretical formula for oral tube insertion depth (Fig. 3). The mean tube tip position corresponded to a mid-tracheal position.

Intubation depth marks in paediatric tracheal tubes were introduced for safe positioning of tracheal tubes, particularly in the emergency situation when tracheal

Table 2 Patient characteristics. Data are mean (SD) [range]. ($n=250$ patients)

Tube size ID (mm)	<i>n</i>	Intended age group (yr)	Age (yr)	Height (cm)	Weight (kg)
3	50	Birth to <1	0.4 (0.3) [0.0–0.9]	62.1 (8.4) [48.0–84.0]	6.4 (2.1) [3.2–11.1]
3.5	25	1 to <2	1.5 (0.3) [1.1–1.9]	79.4 (5.4) [67.0–88.5]	10.5 (1.6) [7.7–14.6]
4	25	2 to <4	2.9 (0.6) [2.0–3.9]	93.9 (4.7) [87.5–102.0]	13.7 (2.1) [10.5–19.2]
4.5	25	4 to <6	4.8 (0.5) [4.0–5.9]	107.0 (6.6) [93.0–121.0]	17.1 (1.9) [12.5–20.0]
5	25	6 to <8	6.8 (0.6) [6.0–7.9]	122.0 (8.6) [104.0–139.5]	24.5 (5.6) [16.2–39.5]
5.5	25	8 to <10	9.0 (0.7) [8.0–9.8]	131.6 (8.6) [115.0–147.0]	27.0 (6.2) [18.6–45.5]
6	25	10 to <12	11.0 (0.6) [10.0–11.8]	144.3 (9.1) [125.0–163.0]	37.1 (8.6) [25.3–58.0]
6.5	25	12 to <14	12.9 (0.5) [12.0–13.9]	153.0 (6.4) [142.0–164.0]	42.3 (8.1) [31.0–65.7]
7	25	14 to <16	14.9 (0.8) [14.1–15.9]	163.1 (11.7) [132.0–187.0]	54.3 (12.9) [31.0–83.8]

Table 3 Endoscopically measured distance from tube tip to tracheal carina, calculated tracheal length, and percentage of the trachea to which the tube tip was advanced. Data are mean (SD) [range]. ($n=250$ patients)

Tube size ID (mm)	<i>n</i>	Intended age group (yr)	Distance from tube tip to tracheal carina (cm)	Calculated tracheal length (cm)	Percentage of the trachea to which the tube tip is advanced
3	50	Birth to <1	2.3 (0.6) [1.4–3.5]	4.7 (0.6) [3.8–5.9]	51.5 (6.0) [40.7–63.2]
3.5	25	1 to <2	2.8 (0.6) [1.8–4.0]	5.5 (0.6) [4.5–6.7]	49.9 (5.8) [40.3–60.0]
4	25	2 to <4	3.1 (0.8) [2.0–4.5]	6.1 (0.8) [5.0–7.5]	49.7 (6.4) [40.0–60.0]
4.5	25	4 to <6	3.2 (0.8) [1.9–4.5]	6.6 (0.8) [5.3–7.9]	52.3 (6.7) [43.0–64.2]
5	25	6 to <8	3.3 (0.8) [2.0–4.7]	7.2 (0.8) [5.9–8.6]	54.4 (6.1) [45.3–66.1]
5.5	25	8 to <10	3.7 (0.8) [2.4–5.6]	8.2 (0.8) [6.9–10.1]	55.4 (5.1) [44.6–65.2]
6	25	10 to <12	3.9 (0.7) [2.4–5.5]	8.9 (0.7) [7.4–10.5]	56.4 (4.6) [47.6–67.6]
6.5	25	12 to <14	4.2 (1.0) [2.8–6.6]	9.6 (1.0) [8.2–12.0]	56.8 (5.7) [45.0–65.9]
7	25	14 to <16	5.2 (1.4) [2.8–7.7]	11.0 (1.4) [8.6–13.5]	53.6 (6.7) [43.0–67.4]

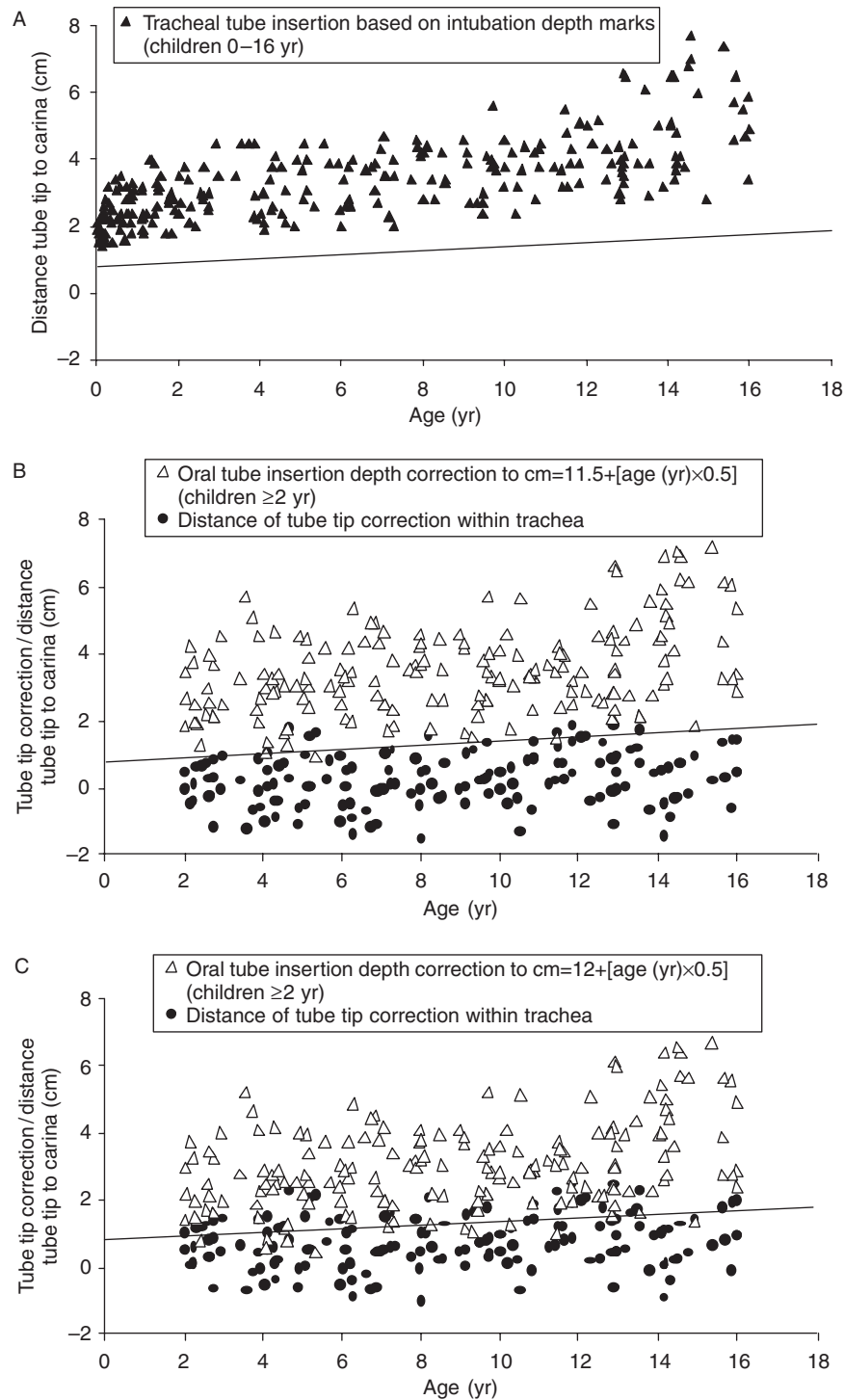


Fig 3 Fibrebronchoscopically measured tube tip to carina distances with indicated margin of safety for endobronchial intubation during head–neck flexion. The thin line indicates caudal tube tip displacement in case of head–neck flexion (neonate 8 mm; adult patient 19 mm).^{10–13} (A) Tracheal tube tip position above the tracheal carina based on intubation depth markings ($n=250$). (B and C) Formula-based corrected tube tip position above the carina in children aged ≥ 2 yr ($n=175$). (B) Oral tube insertion depth (cm) = $11.5 + (\text{age [yr]} \times 0.5)$; (c) oral tube insertion depth (cm) = $12.0 + (\text{age [yr]} \times 0.5)$. Negative correction values indicate a new cuff position in the subglottic area or even between the vocal cords.

intubation often has to be performed by inexperienced personnel. Correctly positioned intubation depth marks on tubes should allow a cuff-free subglottic tube shaft,^{4–7,21} appropriate tracheal tube insertion depth to avoid

endobronchial intubation,²² and inadvertent extubation during manipulation of the head.^{10–13} Unfortunately, there are no British, European, or American standards for tracheal tube markings^{23,24} and each manufacturer

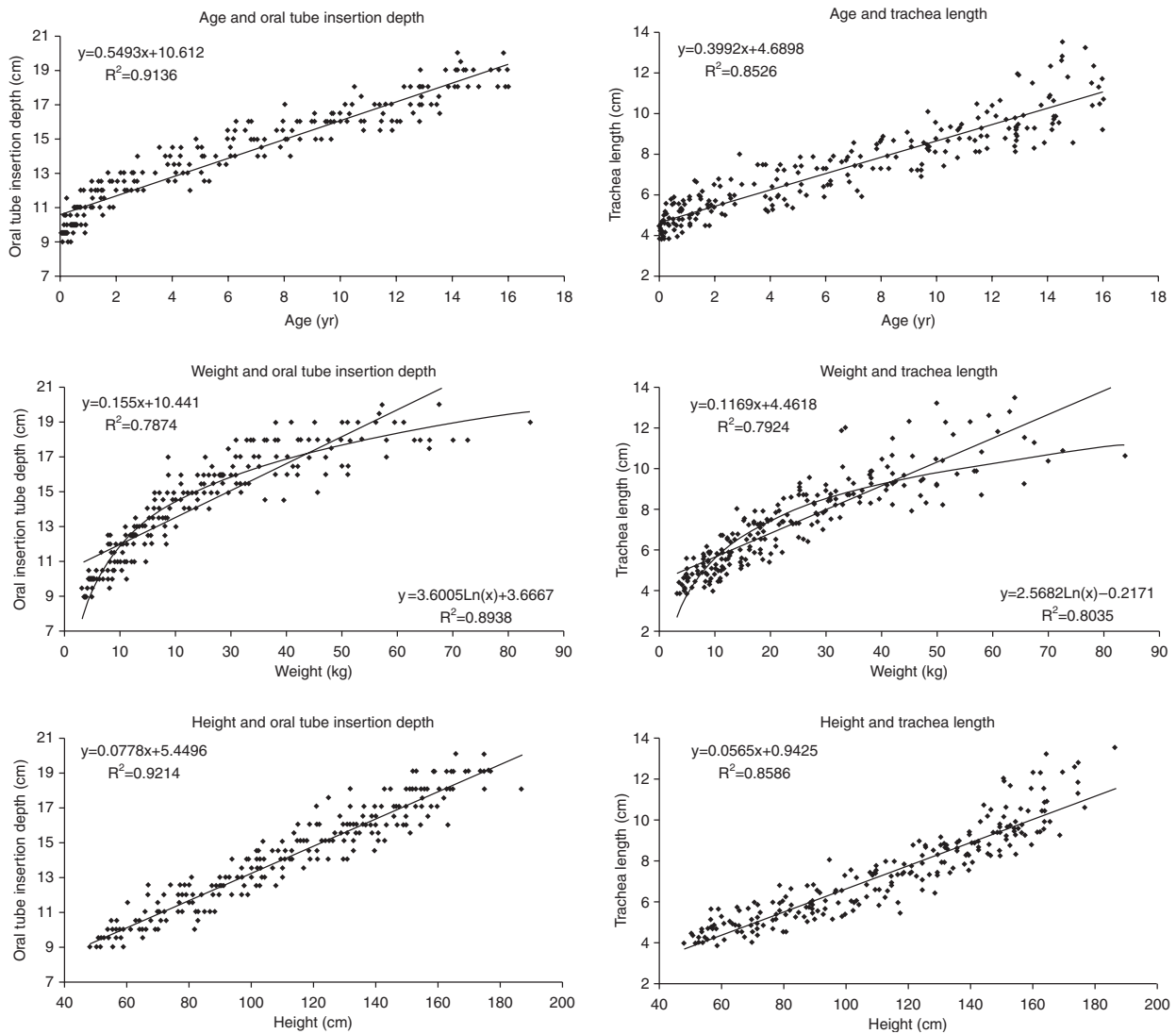


Fig 4 Linear/logarithmic regression plots for the comparison of tube insertion depth at the lateral corner of the mouth based on intubation depth marks and calculated tracheal length with age, height, and weight ($n=250$).

Table 4 Tracheal length assessed by fiberoptic endoscopy and chest radiography. ($n=250$ patients)

Age group (yr)	n	Endoscopically measured tracheal length			Radiologically measured tracheal length ¹⁸⁹		
		Age (mean) (yr)	Height percentile (mean) (%)	Tracheal length (95% CI) (mm)	Age (mean) (yr)	Height percentile (mean) (%)	Tracheal length (95% CI) (mm)
0 to <2	75	0.9	38	3.8–6.4	1	40	4.0–6.8
2 to <4	25	2.9	44	4.3–8.1	3.2	47	5.4–7.4
4 to <6	25	4.8	39	5.0–8.3	4.9	57	5.6–8.8
6 to <8	25	6.8	53	5.5–8.9	6.5	54	6.8–9.6
8 to <10	25	9.0	40	6.7–9.6	9.2	54	7.4–10.2
10 to <12	25	11.0	48	7.3–10.4	11.2	49	8.2–11.8
12 to <14	25	12.9	39	7.3–12.0	13.2	58	7.8–13.8
14 to <16	25	14.9	47	8.2–13.5	15.1	67	8.8–13.6

has its own intubation depth marks.^{3,4,25} Based on our measurements, the intubation depth marks of the Microcuff paediatric cuff tracheal tube guarantee a cuff-free subglottic area, allow adequate placing of the tracheal tube and

minimize the risk of endobronchial intubation or accidental extubation, even with caudal and cranial tube tip displacement because of head–neck flexion and extension (Fig. 3).^{10–13}

The age-related formula for oral tube insertion depth in children ≥ 2 yr of age calculated on the basis of our data resulted in an overall tube insertion depth of 0.5 cm less than the conventionally used formula for children aged more than 2 yr (insertion depth [mm] = $12 + (\text{age [yr]} \times 0.5)$).^{14,19} The main reason for this is, that the intubation depth marks of the Microcuff tracheal tube were placed so that the tube tip becomes situated at 60–65% of the shortest trachea of the intended age group while still leaving a safe margin for caudal tube displacement with head flexion (Table 1). Consequently, in a larger patient receiving a similar sized tube, the tube would be advanced to a shorter percentage of the trachea, resulting in a reduced oral insertion depth (compared with standard formulae) and an increased distance from tube tip to carina. This is not a shortcoming of the intubation depth marks, but reflects a consistent problem with paediatric tracheal tubes, that outer diameter, pre-formed bend, and depth marks will not be appropriate for each individual in an age range of 2 yr. Multiple intubation depth marks could be used to indicate age-dependent insertion depth. However, multiple markings on the distal end of a tube could be confusing during intubation. Nevertheless, the proposed intubation depth marks allowed safe placement of the cuffed tracheal tube in all children in our study (Fig. 3).

Several techniques, other than depth marks, have been proposed for determining the appropriate tube insertion depth: palpation of the tube tip or the cuff in the jugular fossa,^{26,27} endobronchial intubation followed by tube draw-back until bilateral breath sounds are heard or inspiratory pressure decreases,²⁸ endoscopic control²⁹ or lighted stylet,³⁰ chest X-ray, and formula-based insertion depth.^{14,19} These techniques may be appropriate for uncuffed tubes; however, in many conventional cuffed tubes, the subglottic and the intra-glottic position of the tube cuff still can occur.^{3–7} Thus, cuffed paediatric tubes should be initially inserted according to an appropriately placed intubation depth mark to guarantee a cuff-free subglottic airway.

In conclusion, intubation depth marks are useful in cuffed paediatric tubes to guarantee adequate tracheal tube placement with a cuff-free subglottic airway and a sufficient margin for preventing inadvertent endobronchial intubation, or tracheal extubation. Based on our findings, the intubation depth marks of the Microcuff paediatric tracheal tube allowed the safe placement of a cuffed tracheal tube in children from a wide age range and were an improvement on the age-based formulae for oral tube insertion depth.

References

- Griscom NT, Wohl MEB. Dimensions of the growing trachea related to age and gender. *Am J Roentgenol* 1986; **146**: 233–7
- Loew A, Thibeault D. A new and safe method to control the depth of endotracheal intubation in neonates. *J Pediatr* 1974; **54**: 506–8
- Goel S, Lim SL. The intubation depth marker: the confusion of the black line. *Paediatr Anaesth* 2003; **13**: 579–83
- Weiss M, Dullenkopf A, Gysin C, Dillier C, Gerber AC. Shortcomings of paediatric cuffed endotracheal tubes. *Br J Anaesth* 2004; **92**: 78–88
- Holzki J. Tuben mit cuff im neugeborenen- und kleinkindesalter ein risiko. *Anaesthesist* 2002; **51**: 321–3
- Dillier CM, Trachsel D, Baulig W, Gysin C, Gerber AC, Weiss M. Laryngeal web due to an inappropriately designed cuffed paediatric endotracheal tube. *Can J Anaesth* 2004; **51**: 72–5
- Ho AMH, Aun CST, Karmakar MK. The margin of safety associated with the use of cuffed paediatric tracheal tubes. *Anaesthesia* 2002; **57**: 169–82
- Dullenkopf A, Schmitz M, Gerber AC, Weiss M. Sealing characteristics of pediatric cuffed tracheal tubes. *Pediatr Anesth* 2004; **14**: 825–30
- Pettersson H, Ringertz H. *Measurements in Pediatric Radiology*. London: Springer, 1991
- Todres ID, deBros F, Kramer SS, Moylan FMB, Shannon DC. Endotracheal tube displacement in the newborn. *J Pediatr* 1976; **89**: 126–7
- Donn SM, Kuhns LR. Mechanism of endotracheal tube movement with change of head position in the neonate. *Pediatr Radiol* 1980; **9**: 37–40
- Sugiyama K, Yokoyama K. Displacement of the endotracheal tube caused by change of head position in pediatric anesthesia. Evaluation of fiberoptic bronchoscopy. *Anesth Analg* 1996; **82**: 251–3
- Conrady PA, Goodman LR, Lainge F, Singer MM. Alteration of endotracheal tube position. *Crit Care Med* 1976; **4**: 8–12
- Motoyama EK. Endotracheal intubation. In: Motoyama EK, Davis PJ, eds. *Smith's Anesthesia for Infants and Children*, 5th Edn. St Louis: CV Mosby Co., 1990; 272–5
- Steward DJ, Lerman J. Techniques and procedures of pediatric anesthesia. In: Steward DJ, Lerman J, eds. *Manual of Pediatric Anesthesia*, 5th Edn. New York: Churchill Livingstone, 2001; 69–127
- Khine HH, Corrdry DH, Kettrick RG, et al. Comparison of cuffed and uncuffed endotracheal tubes in young children during general anesthesia. *Anesthesiology* 1997; **86**: 627–31
- Schild JA. Relationship of laryngeal dimensions to body size and gestational age in premature neonates and small infants. *Laryngoscope* 1984; **94**: 1284–92
- Kahane JC. Growth of the human prepubertal and pubertal larynx. *J Speech Hear Res* 1982; **25**: 446–55
- Hatch DJ. Paediatric anaesthetic equipment. *Br J Anaesth* 1985; **57**: 672–84
- Prader A, Largo RH, Molinari L, Issler C. Physical growth of Swiss children from birth to 20 years of age. *Helv Paediat Acta* 1989; (Suppl.) 52
- Cavo JW. True vocal cord paralysis following intubation. *Laryngoscope* 1985; **95**: 1352–9
- Kuhns LR, Poznanski AK. Endotracheal tube position in the infant. *J Pediatr* 1971; **78**: 991–6
- British Standard. British Standard BS EN 1782. 1998; ISBN 0 580 29716 0:8
- American Society for Testing and Materials. Standard specifications for cuffed and uncuffed tracheal tubes (ASTM F1242–89). Philadelphia: ASTM, 1989
- Wallace CJ, Bell Graham TB. Tracheal tube markings. *Pediatr Anesth* 2004; **14**: 283–5

- 26** Bednarek FJ, Kuhns LR. Endotracheal tube placement in infants determined by suprasternal palpation: a new technique. *Pediatrics* 1975; **56**: 224–9
- 27** Pollard RJ, Lobato EB. Endotracheal tube location verified reliably by cuff palpation. *Anesth Analg* 1995; **81**: 135–8
- 28** Bloch EC, Ossey K, Ginsberg B. Tracheal intubation in children: a new method for assuring correct depth of tube placement. *Anesth Analg* 1988; **67**: 590–2
- 29** Heller RM, Cotton RB. Early experience with illuminated endotracheal tubes in premature and term infants. *Pediatrics* 1985; **75**: 664–6
- 30** Dietrich KA, Strauss RH, Cabalka AK, Zimmerman JJ, Scanlan KA. Use of flexible fiberoptic endoscopy for determination of endotracheal tube position in the pediatric patient. *Crit Care Med* 1988; **16**: 884–7