

Case Report

Experience with the Arndt paediatric bronchial blocker

S. H. Wald*, A. Mahajan, M. B. Kaplan and J. B. Atkinson

Departments of Anesthesiology and Surgery at the David Geffen School of Medicine at UCLA,
Los Angeles, CA 90095, USA

*Corresponding author. E-mail: swald@mednet.ucla.edu

Previously reported techniques for single lung ventilation in children have failed to provide consistent, single lung ventilation with relative ease and reliability. We report our experience with the use of a new device, the Arndt 5 French (Fr) paediatric endobronchial blocker, for single lung ventilation in a series of 24 children. We were able to achieve single lung ventilation in 23 of the 24 patients (aged 2–16 yr). Placement required approximately 5–15 min. Attempts at placement were aborted in one patient who was unable to tolerate even short periods of apnoea because of lung pathology. Although it has some limitations, our experience suggests that the paediatric bronchial blocker can be used as a consistent, safe method of single lung ventilation in most young children.

Br J Anaesth 2005; **94**: 92–4

Keywords: children; equipment, tubes endobronchial; lung, bronchus; surgery, thoracic; ventilation, one-lung

Accepted for publication: August 26, 2004

Paediatric surgeons are increasingly using video-assisted thoracoscopy (VATS) during thoracic surgery in children.^{1,2} VATS usually requires deflation of the lung on the surgical side and single lung ventilation on the non-surgical side. One obstacle to good surgical exposure in paediatric patients is providing consistent, single lung ventilation with relative ease and reliability.

Techniques for single lung ventilation in children have included the use of double lumen endobronchial tubes or Univent tubes, endobronchial intubation with a standard tracheal tube, use of a Fogarty catheter as a bronchial blocker, collapse of the surgical lung by insufflation of carbon dioxide (during thoracoscopy), or lung retraction. These options all have their individual limitations and none is entirely satisfactory.^{3–6}

We report our experience with the use of a new device, the Arndt 5 French (Fr) paediatric endobronchial blocker, for single lung ventilation in the first large series of children.

Case series

Twenty-four patients aged 2–16 yr and weighing 15–54 kg received general anaesthesia for thoracotomy or thoracoscopy requiring single lung ventilation (Table 1). Thirteen of the patients were aged 5 yr or less and the mean age was 6 yr. Under general anaesthesia, a standard tracheal tube

ranging from 5.0 to 7.0 mm I.D. was inserted into the trachea. A 2.2- or 2.8-mm O.D. fiberoptic scope was used for placement and confirmation of the tracheal tube.

The Arndt paediatric bronchial blocker is a 5 Fr catheter with a removable string that loops over the fiberoptic scope. The distal end of the catheter has a 2-ml spherical high-volume, low-pressure balloon. The paediatric endobronchial blocker was inserted into either the right or left mainstem bronchus of each patient to block ventilation to either the right or left lung depending on the site of surgery.

In each case, the blocker and the fiberoptic scope were placed through their respective ports in the multi-port airway adapter provided. The inner filament at the end of the blocker was then looped over the fiberoptic scope and the adapter was connected to the tracheal tube and breathing circuit. The fiberoptic scope was advanced under videoscopic guidance into the desired mainstem bronchus and then the blocker was advanced past the fiberoptic scope. The balloon was then inflated under fiberoptic visualization, the scope removed, and the bronchial port was tightened (Fig. 1).

Lung isolation and proper positioning were confirmed by auscultation and fiberoptic visualization of the blocker in the correct mainstem bronchus, before and after lateral positioning of the patient. Correct position was reconfirmed with fiberoptic bronchoscopy and upon surgical exposure.

We were able to achieve single lung ventilation in 23 of the 24 patients. Seven bronchial blockers were placed in the

right mainstem bronchus and 16 were placed in the left. Placement required approximately 5–15 min. In one patient the insertion was aborted because of rapid desaturation during attempts at placement. The patient was a 3-yr-old boy with a bilateral pneumonia undergoing lung decortication who was unable to tolerate any period of apnoea.

In three cases during surgical manipulation of the tracheo-bronchial tree, the blocker became dislodged into the trachea. This malpositioning caused an immediate increase in peak inspiratory pressure and decrease in end-tidal carbon dioxide. The blocker was simply advanced under fiberoptic guidance back into a mainstem bronchus.

Except for the child noted above, there were no immediate complications from blocker placement.

Discussion

Bronchial blockade is a useful method for achieving lung isolation^{7,8} in order to provide good surgical exposure. This is the first presentation of the use of this 5 Fr bronchial blocker in a large series of paediatric patients including small and young children. Tobias described previously the use of the adult 9 Fr bronchial blocker in two children aged 9 and 10 yr.⁹ Yun and colleagues reported successful

single lung ventilation in a 14-yr-old using the paediatric 5 Fr bronchial blocker¹⁰ and Hammer and colleagues published a case report involving a 4-yr-old and a 17-month-old patient.¹¹

We have found several benefits in using the Arndt 5 Fr paediatric bronchial blocker and we were able to achieve consistent lung isolation using standard tracheal tubes in a short period of time. It has been useful in small children with a balloon designed for bronchial blockade and can easily be directed to either bronchus. Use of this bronchial blocker in young children may require a fiberoptic scope of less than 2.0 mm for use with a 4.5-mm I.D. tracheal tube; alternatively, a 2.2- or 2.8-mm scope may be used with larger tracheal tubes.

This paediatric bronchial blocker has its limitations. There may be a period of decreased ventilation during placement. The fiberoptic port is larger than the scope to allow easy advancement, however, this results in a significant leak during positive pressure ventilation. We suggest tightening the blocker port slightly during fiberoptic advancement to decrease any additional loss of tidal volume. To lessen the need for re-placement, the blocker may be inserted after the child is in the lateral position.

It may be difficult to block the right upper lobe with a right-sided blocker. The early take-off of the right upper lobe bronchus may be so high that the balloon would have to be partially in the trachea to block ventilation to that lobe and require a left mainstem bronchus intubation, instead.

Finally, the smallest tracheal tube recommended for use with this paediatric bronchial blocker is 4.5-mm ID, limiting the use of this technique in the very young (<1 yr). Some children may have an intrapulmonary disease process, which may not allow for any period of hypoventilation during blocker insertion or single lung ventilation.

Existing methods for single lung ventilation are either impossible to use in small children (double lumen endobronchial tubes) or inconsistently successful (Fogarty catheter, endobronchial intubation).⁴ The narrow airways of children under 8 yr old or less than 30 kg in weight preclude

Table 1 Surgical procedures

Thoracotomy (19)
Pulmonary artery unifocalization (3)
Repair aortic coarctation (6)
ASD closure (2)
Mitral valve replacement (1)
PDA ligation (1)
Revision oesophagojejunostomy (1)
Right upper lobectomy (1)
Lung biopsy (1)
Decortication (2)
Colonic interposition (1)
Thoracoscopy (5)
Pleurodesis and decortication (2)
Pulmonary biopsy (2)
Mediastinal biopsy (1)

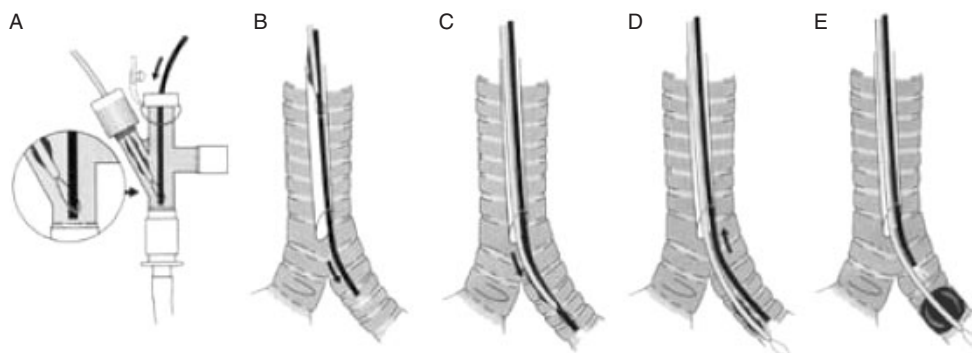


Fig 1 Placement of pediatric bronchial blocker. (A) The fiberoptic scope and bronchial blocker are inserted into their respective ports on the multiport airway adapter. The bronchial blocker is looped onto fiberoptic scope. The adapter is attached between the anaesthesia circuit and tracheal tube. (B) The fiberoptic scope is advanced into the desired mainstem bronchus. (C and D) Bronchial blocker is advanced over the fiberoptic scope into the mainstem bronchus. (E) The bronchial cuff is inflated and confirmed with fiberoptic visualization. Modified and used by permission of Cook Critical Care, Bloomington, IN.

placement of a double lumen endobronchial tube as the smallest size available is a 26 Fr. The smallest Univent tube has a large outer diameter (8 mm OD) and narrow inner diameter (3.5 mm ID) limiting its use to an older age group. Endobronchial intubation may only inconsistently provide lung isolation, may only provide partial lung isolation, or may require re-adjustment to the trachea, risking extubation.³ A Fogarty catheter is not designed for use in the airway, as it is equipped with a high-pressure, low-volume balloon; it may be difficult to secure and does not have a lumen for application of continuous positive airway pressure.

Our experience suggests that the paediatric bronchial blocker can be used as a consistent, safe method of single lung ventilation in most young children.

References

- 1 Huang EY, Acosta JM, Gardocki RJ, *et al.* Thoracoscopic anterior spinal release and fusion: evolution of a faster, improved approach. *J Pediatr Surg* 2002; **37**: 1732–5
- 2 Cohen G, Hjortdal V, Ricci M, *et al.* Primary thoracoscopic treatment of empyema in children. *J Thorac Cardiovasc Surg* 2003; **125**: 79–83
- 3 Lammers CR, Hammer GB, Brodsky JB, *et al.* Failure to separate and isolate the lungs with an endotracheal tube positioned in the bronchus. *Anesth Analg* 1997; **85**: 944–9
- 4 Hammer GB, Fitzmaurice BG, Brodsky JB. Methods for single-lung ventilation in pediatric patients. *Anesth Analg* 1999; **89**: 1426–9
- 5 Nino M, Body SC, Hartigan PM. The use of a bronchial blocker to rescue an ill-fitting double-lumen endotracheal tube. *Anesth Analg* 2000; **91**: 1370–1
- 6 Frolich MA, Janelle GM. Postoperative atelectasis after one-lung ventilation with the Univent tube in a child. *J Clin Anesth* 2003; **15**: 159–63
- 7 Arndt GA, Kranner PW, Rusy DA, *et al.* Single-lung ventilation in a critically ill patient using a fiberoptically directed wire-guided endobronchial blocker. *Anesthesiology* 1995; **90**: 1484–6
- 8 Arndt GA, DeLessio ST, Kranner PW, *et al.* One-lung ventilation when intubation is difficult—presentation of a new endobronchial blocker. *Acta Anaesthesiol Scand* 1999; **43**: 356–8
- 9 Tobias JD. Variations on one-lung ventilation. *J Clin Anesth* 2001; **13**: 35–9
- 10 Yun ES, Saulys A, Popic PM, *et al.* Single-lung ventilation in a pediatric patient using a pediatric fiberoptically-directed wire-guided endobronchial blocker. *Can J Anesth* 2002; **49**: 256–61
- 11 Hammer, GB, Harrison, TK, Vricella, LA, *et al.* Single lung ventilation in children using a new paediatric bronchial blocker. *Paediat Anaesth* 2002; **12**: 69–72