

Ultrasonography for ilioinguinal/iliohypogastric nerve blocks in children[†]

H. Willschke¹, P. Marhofer^{1*}, A. Bösenberg², S. Johnston², O. Wanzel³, S. G. Cox²,
C. Sitzwohl¹ and S. Kapral¹

¹Department of Anaesthesia and Intensive Care Medicine, Medical University of Vienna, A-1090 Vienna, Austria. ²Department of Anaesthesia, University Cape Town, Red Cross Children Hospital, Klipfontein Rd, Rondebosch 7700, South Africa. ³Division of Anaesthesia and Intensive Care Medicine, Orthopaedic Hospital Gersthof, A-1180 Vienna, Austria

*Corresponding author: Department of Anaesthesia and Intensive Care Medicine, Medical University of Vienna, Währinger Gürtel 18–20, A-1090 Vienna, Austria. E-mail: peter.marhofer@meduniwien.ac.at

Background. The ilioinguinal/iliohypogastric nerve block is a popular regional anaesthetic technique for children undergoing inguinal surgery. The success rate is only 70–80% and complications may occur. A prospective randomized double-blinded study was designed to compare the use of ultrasonography with the conventional ilioinguinal/iliohypogastric nerve block technique.

Methods. One hundred children (age range, 1 month–8 years) scheduled for inguinal hernia repair, orchidopexy or hydrocele repair were included in the study. Following induction of general anaesthesia, the children received an ilioinguinal/iliohypogastric block performed either under ultrasound guidance using levobupivacaine 0.25% until both nerves were surrounded by the local anaesthetic or by the conventional 'fascial click' method using levobupivacaine 0.25% (0.3 ml kg⁻¹). Additional intra- and postoperative analgesic requirements were recorded.

Results. Ultrasonographic visualization of the ilioinguinal/iliohypogastric nerves was possible in all cases. The amount of local anaesthetic used in the ultrasound group was significantly lower than in the 'fascial click' group (0.19 (SD 0.05) ml kg⁻¹ vs 0.3 ml kg⁻¹, $P < 0.0001$). During the intra-operative period 4% of the children in the ultrasound group received additional analgesics compared with 26% in the fascial click group ($P = 0.004$). Only three children (6%) in the ultrasound-guided group needed postoperative rectal acetaminophen compared with 20 children (40%) in the fascial click group ($P < 0.0001$).

Conclusions. Ultrasound-guided ilioinguinal/iliohypogastric nerve blocks can be achieved with significantly smaller volumes of local anaesthetics. The intra- and postoperative requirements for additional analgesia are significantly lower than with the conventional method.

Br J Anaesth 2005; **95**: 226–30

Keywords: anaesthesia, paediatric; monitoring, ultrasonography; nerve block, ilioinguinal/iliohypogastric

Accepted for publication: March 24, 2005

The ilioinguinal/iliohypogastric nerve block is a popular regional anaesthetic technique for surgical procedures in the sensory area of the ilioinguinal and iliohypogastric nerves. For inguinal surgery (inguinal hernia repair or orchidopexy), the ilioinguinal/iliohypogastric nerve block is as effective as a caudal block.¹ The usual description of the nerve block a puncture site about 1 cm medial to the anterior superior iliac spine is used and a fascial 'click' is detected before injecting 0.3 ml kg⁻¹ of local anaesthetic.² The failure rate with this 'blind' technique is a disappointing 20–30%,³ even in experienced hands. In addition, complications

such as colonic or small bowel punctures and pelvic haematoma have been described.^{4–6}

Ultrasonographic guidance of peripheral nerve blocks of both the upper and lower extremities in adults^{7,8} reduces the number of complications and improves the quality of the blocks. Recently, direct ultrasonographic visualization of the brachial plexus in children was shown to improve sensory and motor block, as well as the speed of onset and

[†]This study was performed at the Red Cross Children Hospital, Klipfontein Road, Rondebosch 7700, Cape Town, South Africa.

duration of sensory blockade, in lateral infraclavicular brachial plexus blocks when compared with those performed using a nerve stimulator.⁹

Direct ultrasonographic visualization of the inguinal and iliohypogastric nerves might improve the quality of the block and reduce the risk of complications. Therefore we designed a randomized prospective double blinded clinical study to compare the efficacy of ultrasound-guided ilioinguinal/iliohypogastric nerve blocks with the conventional 'blind' technique.

Methods

The study was approved by the ethics committee of the University of Cape Town and the Red Cross Children's War Memorial Hospital. Informed consent was obtained from the parents of all children and, where appropriate, assent was obtained from the child. A total of 100 children up to 8 years of age who were scheduled for inguinal hernia repair, orchidopexy or hydrocele repair were included in this study. Those with a history of seizures or neurological, neuromuscular, psychiatric or blood clotting disorders were excluded.

Before induction of anesthesia children were randomized into two groups. The randomization was performed outside the study centre and delivered in sealed opaque envelopes which were numbered sequentially. According to the randomization children received an ilioinguinal block using the traditional fascial click method (fascial click group) or an ultrasound-guided ilioinguinal block (ultrasound group).

Premedication was given at the discretion of the anaesthesiologist and consisted of oral midazolam 0.5 mg kg^{-1} . General anaesthesia was induced with 8% sevoflurane via a facemask. After establishing venous access, a laryngeal mask was placed and anaesthesia was maintained with 1 MAC halothane in nitrous oxide and oxygen. Intraoperative monitoring included ECG, heart rate, pulse oximetry, non-invasive blood pressure and end tidal carbon dioxide concentration.

In the ultrasound group, a SonoSite 180plus portable ultrasound unit (SonoSiteTM, Bothell, WA, USA) and a 5–10 MHz linear hockey stick probe were used to identify the targeted nerves and surrounding anatomical structures. Adjustments (depth, probe frequency, low and far gain) were performed in order to achieve optimal ultrasonographic figures of the nerves and the surrounding anatomical structures (muscles, peritoneum). Figure 1 shows the position of the probe and the needle relative to the skin, Figure 2 shows an example of the ultrasonographic views of the ilioinguinal nerve and the muscles of the anterior abdominal wall in a cross-sectional view, and Figure 3 shows the ultrasonographic view of the tip of the needle relative to the ilioinguinal nerve.

Once the target nerves had been identified in a cross-sectional view, the following measurements were

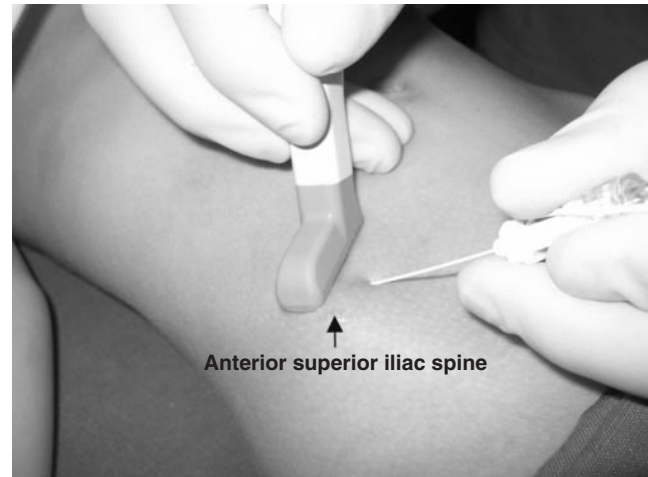


Fig 1 Position of the ultrasound probe relative to the cannula for an optimal view of the ilioinguinal/iliohypogastric nerves.

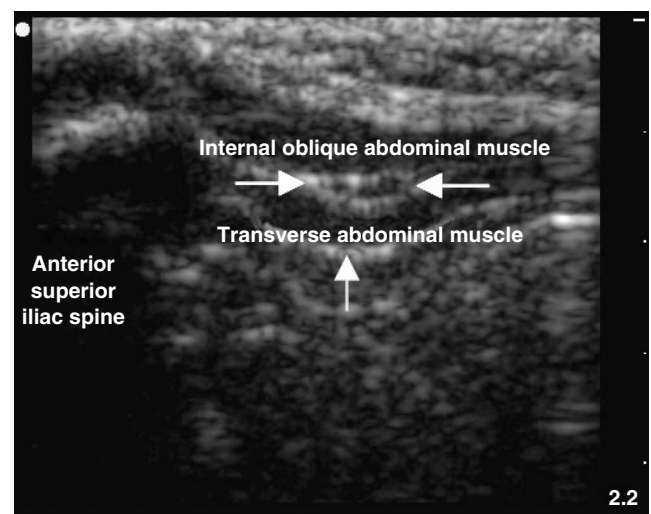


Fig 2 Cross-sectional ultrasonographic view of the ilioinguinal nerve (indicated by the white arrows) between the internal oblique and transverse abdominal muscles. The peritoneum (indicated by the grey arrow) is at a distance of 3 mm in this 10-kg child.

made: distance from the anterior superior iliac spine to the ilioinguinal nerve; distance between the ilioinguinal and iliohypogastric nerves; depth of the ilioinguinal and iliohypogastric nerves relative to the skin; distance from the ilioinguinal nerve to the peritoneum.

Following aseptic preparation of both the puncture site and the ultrasonographic probe, the nerve block was performed using an insulated 22-gauge 40-mm needle with a facette tip and an injection line (PajunkTM, Geisingen, Germany). Once the needle had been visualized by ultrasound and placed in an optimal position relative to the nerves, a single injection of levobupivacaine 0.25% (ChirocaineTM, Abbott, Roscrea, Ireland) was administered under real-time ultrasound control until both nerves were surrounded by the local anaesthetic (Fig. 4). The amount administered was recorded.

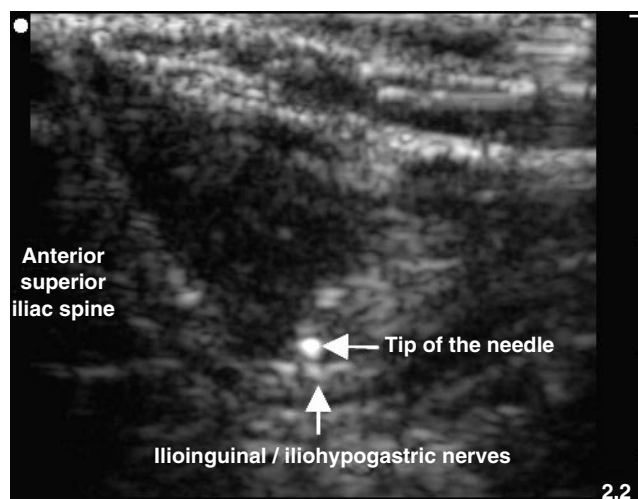


Fig 3 Ultrasonographic view of the relationship of the tip of the needle to the ilioinguinal/iliohypogastric nerves.

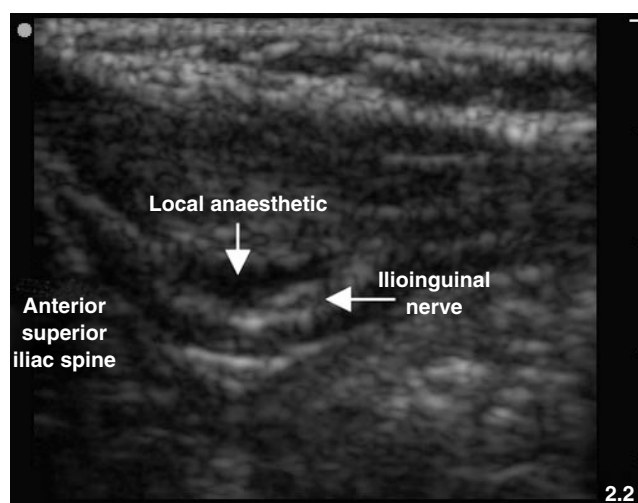


Fig 4 Ultrasonographic view of the ilioinguinal nerve surrounded by 1.2 ml of local anaesthetic.

In the fascial click group the ilioinguinal/iliohypogastric nerve block was performed using the same needle type as described for the ultrasound group. The needle was inserted vertically through the 'tented' skin, 1–2 cm medial and 1–2 cm inferior to the anterior superior iliac spine. After detecting the first 'fascial click', and following a negative aspiration, levobupivacaine 0.25% (0.3 ml kg^{-1}) was injected. After completion of the nerve block an ultrasonographic examination was performed to determine whether the nerves were surrounded by the local anaesthetic.

In both groups skin incision was performed 15 min after the block. On completion of skin closure, the laryngeal mask was removed and the general anaesthesia discontinued. Heart rate, Sp_{O_2} and the OPS score (see below) were monitored in the recovery room.

An intraoperative decrease in mean arterial pressure and heart rate $>30\%$ from baseline was defined as hypotension or bradycardia, respectively, and were treated with a

bolus infusion of fluid. If this was unsuccessful, a vasoconstrictor (etilefrine [EffortilTM] 0.02 mg kg^{-1} or atropine 0.01 mg kg^{-1}) was administered as indicated. Respiratory depression was defined as a decrease in Sp_{O_2} to $<93\%$ and requiring supplementary oxygen. An increase in heart rate or mean arterial pressure of $>10\%$ following skin incision and during surgery was defined as insufficient analgesia and treated with fentanyl $3 \mu\text{g kg}^{-1}$ i.v.

The efficacy of postoperative analgesia was measured using the OPS score, in which objective behavioural variables (crying, facial expression, position of torso and legs, motor restlessness) are assessed. Each pain variable is scored on a three-point scale (1=none, 2=moderate, 3=severe) to give a maximum cumulative score of 15. If the OPS score was ≥ 11 in two subsequent measurements, the child received acetaminophen 40 mg kg^{-1} rectally. Duration of the local analgesia was defined as the time from completion of the ilioinguinal/iliohypogastric nerve blocks to the first administration of rescue analgesia. The time to discharge from the hospital was also recorded.

Statistical analysis

All values are expressed as mean (SD). Differences in demographics, surgical time, time to discharge and amount of local anaesthetic used were evaluated using an independent *t*-test. To detect intergroup differences in haemodynamic changes ANOVA for repeated measurements was used. Intergroup differences in the frequency of postoperative acetaminophen use, the need for additional systemic analgesia at skin incision and the frequency of the nerve being found within the local anaesthetic were evaluated using the χ^2 -test. Based on preliminary data we expected a 50% difference between the two groups in block sufficiency. Therefore we calculated an $n=100$ to detect this difference with $P<0.05$ and a power of 90%. Correlations were calculated using the Pearson correlation coefficient (SPSS 11.1.2, SPSS Inc., Chicago, IL). The level of statistical significance was set at $P\leq 0.05$.

Results

Patient characteristics were equally distributed in the two study groups. The duration of surgery was ~ 5 min longer in the fascial click group than in the ultrasound-guided group but this was not considered clinically significant. The types of surgery and discharge times were no different (Table 1). All surgical procedures were performed by the same surgeon (SGC), and all blocks were performed by the same two anaesthetists (HW and OW), both experienced in ultrasonographic-guided regional anaesthetic techniques in children. Ultrasound visualization of the ilioinguinal and the iliohypogastric nerves was successful in all cases in the ultrasound group. All anaesthetic procedures were uneventful and there was no clinical evidence of complications such

Table 1 Characteristics of the 100 children undergoing ilioinguinal/iliohypogastric nerve block by either ultrasound guidance or the traditional fascial click method. Data are presented as mean (range) or mean (SD). * $P=0.015$ compared with ultrasound-guided group

	Ultrasound-guided	Fascial click
Age (months)	40 (2–96)	43 (2–96)
Weight (kg)	13 (8)	14 (6)
Height (cm)	89 (29)	93 (21)
Type of surgery		
Hernia repair	30	27
Orchidopexy	17	20
Hydrocele repair	3	3
Duration of surgery (min)	25 (10)	30 (12)*
Time to discharge (min)	163 (64)	171 (53)

as small bowel or major vessel puncture. No vasoactive drugs were required at any stage in either group.

In all cases the nerves were found by ultrasound lying between the internal oblique and transverse abdominal muscles, and in 50% of the cases only two muscle layers could be identified. The measured distances from the anterior superior iliac spine to the ilioinguinal nerve, from the skin to the ilioinguinal nerve, from the ilioinguinal nerve to the iliohypogastric nerve and from the ilioinguinal nerve to the peritoneum were 6.7 (SD 2.9) mm, 8.0 (2.2) mm, 3.5 (1.5) mm and 3.3 (1.3) mm, respectively. The r values of the correlations between the weight and the distances measured from the anterior superior iliac spine to the ilioinguinal nerve, from the skin to the ilioinguinal nerve and from the ilioinguinal nerve to the peritoneum were 0.58, 0.44 and 0.56, respectively. The range of distances measured for children in relation to weight are shown in Table 2. There was a weak correlation ($r=0.44$) between weight and the depth of the ilioinguinal nerve.

The heart rate increased at skin incision in 13(22)% of the fascial click group compared with 1(6)% in the ultrasound group ($P<0.001$). Additional fentanyl on skin incision was deemed necessary in 13 children (26%) in the fascial click group compared with two children (4%) in the ultrasound-guided group ($P=0.004$). All targeted nerves were surrounded by the local anaesthetic in the ultrasound-guided group as per protocol, whereas the local anaesthetic surrounding the target nerves could be detected by ultrasonography in only 50% of the fascial click group ($P<0.0001$). In the remainder of the group, the local anaesthetic was misdirected. The amount of local anaesthetic in the ultrasound group was significantly lower than that in the fascial click group (0.19 [0.05] vs 0.3 ml kg⁻¹; $P<0.0001$).

Only three children (6%) in the ultrasound-guided group needed postoperative rectal acetaminophen compared with 20 children (40%) in the fascial click group ($P<0.0001$).

Discussion

There are a number of reasons why ultrasonography may be of value in paediatric regional anaesthesia. Most nerves are relatively superficial, particularly in small children, and

therefore high resolution imaging is possible even with portable ultrasound equipment. Direct visualization of the nerve or neuraxial structures, vessels, tendons and bones allows optimal placement of the local anaesthetic and thereby reduces the risk of intraneuronal, intravascular or, more pertinent in this study, intraperitoneal injection.

In this study the precise administration of lower volumes of local anaesthetic under ultrasound guidance resulted in effective ilioinguinal/iliohypogastric nerve blocks in children, with a reduced failure rate and no complications. Despite its popularity, when conventional methods are used, the ilioinguinal/iliohypogastric nerve block only has a success rate of 70–80% in some published series.³ Several complications such as colonic or small bowel puncture,^{4,5} pelvic haematoma,⁶ femoral nerve palsy and quadriceps muscle paresis^{10–12} have been described. Possible reasons for the relatively poor success rate of the fascial click method include imprecise description of the landmarks (e.g. ‘1–2 finger breadths’ medial to the anterior superior iliac spine, quarter of the distance along the line from the anterior superior iliac spine to the umbilicus). Insufficient understanding of the anatomical landmarks may also be a factor and an explanation for some complications.¹³

The relationship of the ilioinguinal/iliohypogastric nerves to the abdominal muscles varies relative to the anterior superior iliac spine.^{13,14} At the lateral border of the quadratus lumborum muscle, the two nerves pierce the lumbar fascia to reach a plane between the internal oblique abdominal muscle and the transverse abdominal muscle. The iliohypogastric nerve is situated superiorly and continues ventrally between the internal and external oblique abdominal muscles.

High-resolution imaging of the ilioinguinal/iliohypogastric nerves with the high-frequency linear probe was possible in all our patients. The nerves were found in close proximity to one another between the internal oblique and transverse abdominal muscles. Importantly, in 50% of the patients only two muscle layers could be identified by ultrasound in this area where the external oblique abdominal muscle is only aponeurosis. There was no correlation between the position of the nerves in relation to the anterior superior iliac spine, the depth of the nerves or the distance from the nerves to the peritoneum. An important finding in our study is the close proximity of the nerves to the peritoneum, i.e. a distance of 3.3 (1.3) mm (shortest distance, 1 mm). This emphasizes the risk of undetected peritoneal puncture when using the fascial click method. This may contribute to failed blocks and is a strong argument for the use of ultrasound guidance in young children.

By using real-time imaging, as in previous studies,¹⁵ the precise location of the needle tip between the ilioinguinal and iliohypogastric nerves and within the correct fascial plane could be detected and the spread of the local anaesthetic around both nerves could be observed. In this way significantly smaller amounts of local anaesthetics were used and clinically effective blocks were still achieved.

Table 2 The range of distances measured from the anterior superior iliac spine and the skin to the iliohypogastric and ilioinguinal nerves and from the ilioinguinal nerve to the peritoneum in children of three different weights

Weight (kg) (no. of patients)	Anterior superior iliac spine–ilioinguinal nerve (mm)	Skin–ilioinguinal nerve (mm)	Skin–iliohypogastric nerve (mm)	Ilioinguinal nerve–peritoneum (mm)
5 (8)	5–10.3	5–9	3.9–7.8	1–4
13 (5)	6.3–13	4.8–8.9	5.4–8.9	1.7–4
16 (4)	11.3–13	5.4–12	5.5–11	3–4.6

This is particularly relevant for neonates and infants who are at risk of local anaesthetic toxicity and higher free plasma concentrations of local anaesthetic agents in view of their lower plasma concentration of the binding protein alpha-1 acid glycoprotein.¹⁶ The results of this study are encouraging and demonstrate a further application of the use of ultrasonography in paediatric regional anaesthesia. Recently, other investigators have used ultrasound to elucidate sciatic nerve anatomy¹⁷ and neuraxial anatomy,¹⁸ and for infraclavicular brachial plexus blocks.⁹ Ultrasound guidance of ilioinguinal/iliohypogastric nerve blocks proved easy to perform using the portable Sonosite 180plus ultrasound unit.

In summary, ultrasound guidance of ilioinguinal/iliohypogastric nerve blocks offers the advantage of direct visualization of the nerves and the adjacent anatomical structures. The real-time imaging of the local anaesthetic spread around the nerves maintains the quality of the block whilst significantly reducing the amounts of local anaesthetic required compared with the recommended dose for the conventional methods. We recommend the use of ultrasonography for ilioinguinal/iliohypogastric nerve blocks, particularly in small infants and children.

Acknowledgements

The authors would like to thank Energieversorger Niederösterreich (EVN) for the free provision of a SonoSite 180plus transportable ultrasonographic machine in order to conduct this study and others.

References

- 1 Markham SJ, Tomlinson J, Hain WR. Ilioinguinal nerve block in children. A comparison with caudal block for intra and postoperative analgesia. *Anaesthesia* 1986; **41**: 1098–103
- 2 Dalens B. Regional anesthetic techniques. In: Bissonnette BDB (ed) *Pediatric Anesthesia—Principles and Techniques*. New York: McGraw Hill, 2002; 563–5
- 3 Lim SL, Ng Sb A, Tan GM. Ilioinguinal and iliohypogastric nerve block revisited: single shot versus double shot technique for hernia repair in children. *Paediatr Anaesth* 2002; **12**: 255–60
- 4 Johr M, Sossai R. Colonic puncture during ilioinguinal nerve block in a child. *Anesth Analg* 1999; **88**: 1051–2
- 5 Amory C, Mariscal A, Guyot E, *et al.* Is ilioinguinal/iliohypogastric nerve block always totally safe in children? *Paediatr Anaesth* 2003; **13**: 164–6
- 6 Vaisman J. Pelvic hematoma after an ilioinguinal nerve block for orchialgia. *Anesth Analg* 2001; **92**: 1048–9
- 7 Kapral S, Krafft P, Eibenberger K, *et al.* Ultrasound-guided supraclavicular approach for regional anesthesia of the brachial plexus. *Anesth Analg* 1994; **78**: 507–13
- 8 Marhofer P, Schrogendorfer K, Koinig H, *et al.* Ultrasonographic guidance improves sensory block and onset time of three-in-one blocks. *Anesth Analg* 1997; **85**: 854–7
- 9 Marhofer P, Sitzwohl C, Greher M, Kapral S. Ultrasound guidance for infraclavicular brachial plexus anaesthesia in children. *Anaesthesia* 2004; **59**: 642–6
- 10 Notaras MJ. Transient femoral nerve palsy complicating preoperative ilioinguinal nerve blockade inguinal for herniorrhaphy. *Br J Surg* 1995; **82**: 854
- 11 Ghani KR, McMillan R, Paterson-Brown S. Transient femoral nerve palsy following ilio-inguinal nerve blockade for day case inguinal hernia repair. *J R Coll Surg Edinb* 2002; **47**: 626–9
- 12 Erez I, Buchumensky V, Shenkman Z, *et al.* Quadriceps paresis in pediatric groin surgery. *Pediatr Surg Int* 2002; **18**: 157–8
- 13 Van Schoor A, Boon K, Bosenberg A, *et al.* Anatomical considerations of the paediatric ilioinguinal/iliohypogastric nerve block. *Paediatr Anaesth* 2005; **15**: 371–7
- 14 Jamieson RW, Swigart LL, Anson BJ. Points of parietal perforation of the ilioinguinal and iliohypogastric nerves in relation to optimal sites for local anaesthesia. *Q Bull Northwest Univ Med Sch* 1952; **26**: 22–6
- 15 Marhofer P, Greher M, Kapral S. Ultrasound guidance in regional anaesthesia. *Br J Anaesth* 2005; **94**: 7–17
- 16 Smith T, Moratin P, Wulf H. Smaller children have greater bupivacaine plasma concentrations after ilioinguinal block. *Br J Anaesth* 1996; **76**: 452–5
- 17 Schwemmer U, Markus CK, Greim CA, *et al.* Sonographic imaging of the sciatic nerve and its division in the popliteal fossa in children. *Paediatr Anaesth* 2004; **14**: 1005–8
- 18 Marhofer P, Bösenberg A, Sitzwohl C, *et al.* A pilot study of neuraxial imaging by ultrasound in infants and children. *Paediatr Anaesth* 2005; in press