

Case report

Fatal cardiac tamponade as a result of a peripherally inserted central venous catheter: a case report and review of the literature

R. M. L'E. Orme¹*, M. M. McSwiney² and R. F. O. Chamberlain-Webber³

¹Intensive Care Unit, ²Department of Anaesthetics and ³Department of Cardiology, Cheltenham General Hospital, Sandford Road, Cheltenham GL53 7AN, UK

*Corresponding author. E-mail: robert.orme@glos.nhs.uk

We present a case of fatal cardiac tamponade that occurred in association with a peripherally inserted central catheter (PICC) inserted from the right antecubital fossa. Migration of the catheter from the right atrium within 24 h of insertion lead to the administration of a potassium-enriched sodium chloride solution into the pericardial space with the development of ST-segment elevation and progression to pulseless electrical activity and, subsequently, ventricular fibrillation. Although signs of tamponade were seen on echocardiography, we propose that myocardial hyperkalaemia from the diffusion of potassium through the epicardium accounted for some of the clinical picture. PICC lines carry a greater risk of migration because of the tip movement associated with arm abduction and, therefore, care must be taken to ensure that the catheter tip is correctly positioned to reduce this risk. When such catheters are used for intra-operative central venous access, we believe chest radiography is mandatory before fluid administration through the catheter, but that this is unnecessary when the catheter is being used solely for central venous pressure monitoring. The use of softer catheters may reduce the risk of vessel perforation. Once tamponade is suspected, all drugs and infusions administered via the catheter should be reviewed, the catheter aspirated and echocardiography performed urgently. This may be facilitated by the greater availability of limited bedside echocardiography within critical care units and theatre complexes.

Br J Anaesth 2007; **99**: 384–8

Keywords: complications, catheter migration; complications, death; equipment, cannulae intravascular; heart, tamponade; ions, potassium

Accepted for publication: May 17, 2007

Central venous access is normally obtained by cannulation of either the internal jugular, the subclavian, or the femoral veins. Central venous access may also be obtained from more distal sites, typically the antecubital veins, using a peripherally inserted central catheter (PICC). Such catheters are used widely for the long-term administration of chemotherapy, parenteral nutrition, and antibiotics. In anaesthetic practice, they can be used for short-term central venous access when more central access is limited, for instance, during major head and neck surgery. Cardiac tamponade has been reported in association with PICC lines, especially in neonatal medicine, but seems rare in adults, although it has been reported in a 14-yr-old female during surgery for scoliosis.¹ We report a case of fatal cardiac tamponade that developed in an adult after the administration of a solution containing potassium chloride for correction of postoperative hypokalaemia.

Case report

A 20-yr-old female presented for an elective bimaxillary osteotomy for facial disproportion and malocclusion, which were causing both functional and cosmetic concerns. Her past medical history was unremarkable apart from mild asthma, which was well controlled with inhaled salbutamol. After the insertion of a 22-G cannula, general anaesthesia was induced with fentanyl 100 µg, propofol 180 mg, and vecuronium 10 mg, a 6.0-mm cuffed nasotracheal tube was inserted and the patient's lungs were ventilated. Anaesthesia was maintained with isoflurane 0.5–1.0% in oxygen-enriched air and an infusion of remifentanyl at 0.1–0.3 µg kg⁻¹min⁻¹. A 20-G arterial cannula was inserted in the right ulnar artery followed by a 16-G peripheral venous cannula. In order to monitor the central venous pressure during surgery, a 710-mm long, 1.7-mm external diameter polyurethane PICC line

(Drum-Cartridge[®], Abbott Ireland, Sligo, UK) was then inserted through a 13-gauge introducer in the right basilic vein in the antecubital fossa and advanced without difficulty. Once inserted, the guidewire was withdrawn and used to estimate the position of the tip and the catheter position was adjusted accordingly and secured with an occlusive dressing. The patient was then transferred to the operating theatre. Venous blood was aspirated from the PICC line, which was connected to a pressure transducer and monitor with a characteristic waveform being displayed throughout surgery.

Surgery lasted 8 h and was uneventful. During surgery, the patient received a total of 3.5 litres of Hartmann's solution and 1.5 litres of hydroxyethyl starch 6% solution (Voluven[®], Fresenius Kabi Ltd, Cheshire, UK) via the 16-G peripheral venous cannula. No fluids were infused through the PICC line other than 3 ml h⁻¹ of sodium chloride 0.9% by the pressure transducer. The patient was transferred to the intensive care unit (ICU) and after discussion between the surgeon and the intensive care consultant, it was decided to keep the patient sedated and ventilated overnight using infusions of propofol 50–150 mg h⁻¹ and alfentanil 1–2 mg h⁻¹. Routine biochemical and haematological profiles and a portable chest radiograph were performed (Fig. 1). The tip of the PICC line was identified within the right atrium, but it was elected not to withdraw it.

After review by the maxillo-facial surgical team the next morning, sedative infusions were discontinued and the tracheal tube was removed at 09.05. At 09.15, the patient's haemoglobin measured 7.3 g dl⁻¹; therefore, it was decided to commence a single unit packed red cell transfusion, which was infused via the 16-G peripheral cannula. Her serum potassium was 3.5 mmol litre⁻¹ and according to our ICU's practice, it was decided to correct this mild hypokalaemia via the central i.v. route. Therefore, 40 mmol of potassium chloride was diluted in

100 ml of sodium chloride 0.9% and administered over 2 h via the PICC line. Half an hour after the infusion finished, ST-segment elevation was noted on the ECG. The patient complained of dull left shoulder pain at this time. Arterial pressure was 110/60 mm Hg and heart rate 90 beats min⁻¹. A 12-lead ECG demonstrated ST-segment elevation in leads II, III, and V₁–V₂ consistent with myocardial infarction, and a consultant cardiologist was called urgently. A further half an hour later (1 h after the infusion), arterial pressure had fallen to 80/50 mm Hg and urgent coronary angiography was considered. A bolus of 200 ml of hydroxyethyl starch 6% (Voluven[®], Fresenius Kabi Ltd, UK) was given over 15 min via the PICC line. The arterial pressure then fell suddenly to a systolic pressure of 40 mm Hg and the patient became unconscious. Epinephrine 700 µg in increments was administered over 90 s, resulting in a prompt, but transient restoration of arterial pressure, which subsequently fell back to a systolic pressure of 40 mm Hg and formal resuscitation commenced. Ventilation was achieved using a bag-valve-mask, but we proceeded rapidly to endotracheal intubation, this necessitating the administration of suxamethonium 100 mg after the intermaxillary fixation wires had been removed. Initial management was for pulseless electrical activity, but after 8 min ventricular fibrillation developed and a single 200 J monophasic shock was delivered, which was followed by bradycardia that was treated with atropine 3 mg. I.V. epinephrine 1 mg was given every 3–5 min. A further episode of ventricular fibrillation occurred 18 min into the cardiac arrest, which was again treated with a single 200 J shock. Possible reversible causes were considered and a blind pericardiocentesis, which yielded 20 ml of clear fluid, was performed by the consultant cardiologist. Urgent transthoracic echocardiography demonstrated a large pericardial effusion with diastolic collapse of the free wall of the right ventricle, consistent with cardiac tamponade. Further pericardiocentesis yielded 200 ml of clear fluid, a sample of which was kept for biochemical analysis and resulted in almost immediate return of spontaneous circulation. At this point, it was suspected that the cardiac arrest had been caused by migration of the PICC line and therefore methylene blue 10 ml was administered via the PICC line. However, aspiration of the line after the arrest resulted in free aspiration of blood and no methylene blue appeared in the pericardial drain, suggesting that the catheter was intravascular at this particular time. The cardiac arrest lasted for approximately 35 min with continuous chest compressions, which were only interrupted briefly to allow the echocardiogram and pericardiocentesis to be performed. Continued care post-cardiac arrest included the insertion of a pericardial drain, and a right subclavian central venous catheter, following which a chest radiograph was performed where the tip of the PICC line appeared to be adjacent to that of the central venous catheter. Mild therapeutic hypothermia was induced to minimize secondary brain injury.

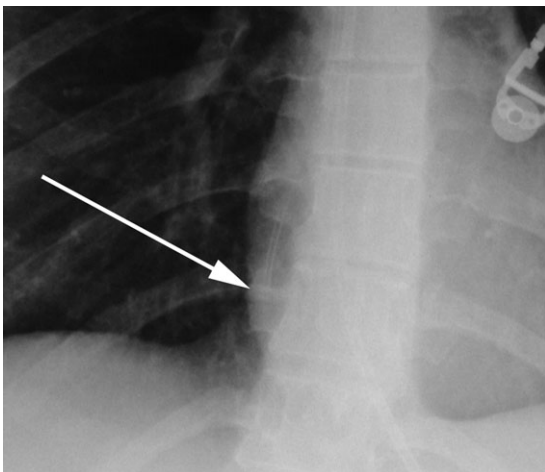


Fig 1 Immediate postoperative chest radiograph. The tip of the catheter is seen to lie within the right atrium (arrow).

The next day, the pericardial drain was removed and a repeat echocardiogram performed, which showed normal left ventricular function and minimal pericardial effusion. After restoration of normothermia, the patient was noted to have persistently fixed and dilated pupils and to be unresponsive to painful stimuli. A computed tomography scan of the brain was performed which demonstrated signs of severe hypoxic brain injury. The PICC line was removed at this time and retained for further investigation. The patient did not regain consciousness and subsequently developed acute respiratory distress syndrome, which prevented brainstem death tests from being performed. Treatment was withdrawn and the patient died on the fourth postoperative day.

Post-mortem examination confirmed the cause of death as cerebral hypoxia as a result of cardiac arrest, but failed to identify signs of cardiac perforation by the PICC. Subsequent analysis of the pericardial fluid demonstrated a composition of sodium $140 \text{ mmol litre}^{-1}$, chloride $166 \text{ mmol litre}^{-1}$, and potassium $36.4 \text{ mmol litre}^{-1}$. Thus, it was concluded that migration of the PICC line had occurred, resulting in the administration of potassium-rich fluid into the pericardium, which in turn led to cardiac arrest. At inquest, a verdict of accidental death was recorded. Examination of the PICC line showed no evidence of any manufacturing defect or damage to the catheter.

Discussion

Cardiac tamponade is a recognized complication of central venous catheterization. Classically, a variety of symptoms and signs can occur, including dyspnoea, chest pain, tachycardia, hypotension and, specifically, pulsus paradoxus. However, their non-specific nature makes the diagnosis difficult and accounts for the high mortality associated with the condition. When the diagnosis is suspected in association with a central venous catheter, all infusions through the catheter must be stopped and the catheter aspirated. In this case, it is clear that the composition of the fluid causing the tamponade complicated the clinical picture significantly and we believe this is the first report of its type. It seems likely that had the diagnosis been suspected earlier, either before or immediately after circulatory collapse, the patient would have made a full recovery. Known risk factors for the development of tamponade include line tip position, catheter material, and the infusion of hyperosmolar fluids. In addition, the tip of a PICC line can move significantly with arm movements, which makes the risk of migration greater than for centrally inserted catheters.

The optimal position of central venous catheter tips is controversial and opinions are divided. In North America, the Food and Drug Administration and some experts recommend that 'catheter tips should not be placed in or

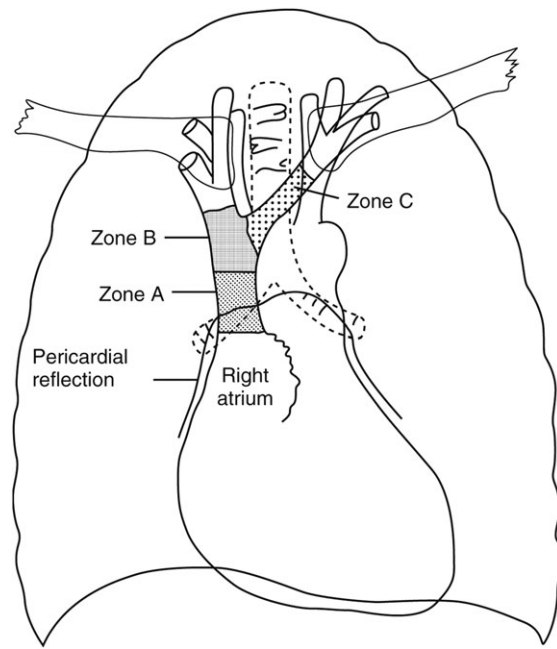


Fig 2 Diagram of the heart and great veins showing suggested areas for catheter tip location. Zone A is appropriate for all access points, zone B is suitable for catheters placed via the right internal jugular vein, while zone C should be considered for all catheters inserted from either the left internal jugular or subclavian veins. (©The Board of Management and Trustees of the *British Journal of Anaesthesia*. Reproduced with the permission of Oxford University Press/*British Journal of Anaesthesia*).

allowed to migrate into the heart'.^{2,3} Based upon this guidance, both radiographic⁴ and anatomical⁵ studies in cadavers have recommended the carina as a suitable landmark, which invariably lies outside of the pericardial reflection, thus avoiding the risk of tamponade as a result of catheter migration. However, a more sensible approach would seem to be the one presented by Fletcher and Bodenham,⁶ and Stonelake and Bodenham,⁷ who argued that this does not take into account the risk posed by inappropriate position in the proximal superior vena cava or left brachiocephalic vein, which increases the risk of thrombosis, subsequent embolization, and perforation if the catheter impinges against a vessel wall. They recommended that the catheter tip should be placed in as large a vein as possible, and in particular, that 'catheter tips can safely be sited within the upper right atrium provided they do not abut the atrial wall end-on or pass through the tricuspid or into the coronary sinus'. They also described three ideal sites for tip position, dependent upon the site of insertion (Fig. 2).

The PICC lines have been in use for many years, often when medium to long-term venous access is required for the administration of total parenteral nutrition, chemotherapy, or antibiotics. Cardiac tamponade has been reported with PICC lines, particularly in neonates, after the administration of parenteral nutrition. In a review of four cases, tip position within the right atrium was identified as a major contributory factor.⁸ In adults, this would appear to be an extremely rare complication; however, a case was

recently reported in a 14-yr-old girl undergoing major scoliosis surgery who had a Drum-Cartridge[®] catheter advanced from her left antecubital fossa.¹ Refractory hypotension developed in the immediately postoperative period and a large pericardial effusion was diagnosed with bedside echocardiography. Pericardiocentesis yielded 300 ml of fluid of similar biochemical composition to the crystalloid infused during surgery and resulted in prompt recovery. It was concluded that cannulation of the right pericardiophrenic vein led to cardiac tamponade. This seems unlikely in our case, as the course of the vein makes this complication unlikely from central venous catheters inserted from the right side.⁹ A particular problem with PICC lines that increases their risk of perforation is the amount of movement that can occur with movement of the arm. A cadaver study showed that the antecubital PICC lines can advance up to 7 cm with elevation and abduction of the arm.¹⁰ An *in vivo* study has suggested that this is excessive but found that 58% of PICC lines advanced 20 mm or more with arm abduction.¹¹

In anaesthesia, the use of PICC lines is mostly limited to short-term access when more central access is difficult or undesirable, such as major head and neck surgery or neurosurgery. They are advanced from the antecubital fossa and an estimation of catheter tip location is made using a tape measure or the guide wire. We chose to insert a Drum-Cartridge[®] catheter because of the prolonged nature of surgery and potential risk of haemorrhage, and the perceived safety of the catheter. While an acceptable position for central venous pressure measurement is usually achieved, a radiologically acceptable position is less likely.¹² If being used for monitoring purposes, we believe it is acceptable to rely on the observation of an appropriate central venous pressure waveform and aspiration of venous blood, but that a chest radiograph is mandatory before using the catheter for fluid administration. Although the Drum-Cartridge[®] catheter has been in use for more than 30 yr, with few reports of major complications, we believe its design may increase the risk of vessel perforation as it is made of polyurethane, which appears relatively stiff when compared with catheters made from softer materials such as silastic. This observation has been confirmed *in vitro*.¹³ Although the Drum-Cartridge[®] catheter has a good safety profile, we suggest that softer catheters should be used in preference to reduce the risk of perforation. In addition, we believe that other catheters have superior methods of skin fixation, which may reduce tip movement with abduction of the arm.

We believe that the high concentration of potassium in the infusion accounted for the ECG changes observed, with the development of widespread ST-segment elevation and rapid resolution after pericardiocentesis. This 'pseudo-infarction' pattern has been reported in patients with

hyperkalaemia¹⁴ and also in anaesthetized dogs when potassium was applied to the epicardium.¹⁵ We suggest that the potassium diffused through the epicardium leading to local hyperkalaemia within the myocardium, resulting in ST elevation and subsequent ventricular fibrillation. Although the infused fluid was hyperosmolar (approximately 750 mosmol litre⁻¹), a factor known to increase the risk of erosion and subsequent tamponade,¹⁶ it seems unlikely that this contributed to catheter migration as this almost certainly requires a longer period of infusion. The catheter was almost certainly within the pericardial sac before starting the infusion but, as with previous reports, no erosions or perforations of either the heart or the superior vena cava were seen at post-mortem. However, after the cardiac arrest, the catheter was certainly intravascular, as we were able to aspirate blood freely through it and the injected methylene blue did not appear in the pericardial drain. It is interesting to note that the tip of the PICC line was in the superior vena cava on the post-arrest chest radiograph, in contrast to the postoperative film, despite the catheter not having been withdrawn.

The diagnosis of cardiac tamponade is best made with echocardiography, which can also be used to guide pericardiocentesis. While portable systems lack some of the functionality of a full echocardiography system, they can provide sufficient information in a critical care environment to make an accurate diagnosis.¹⁷ Intensivists can successfully perform and interpret a limited bedside transthoracic study to assess left ventricular function and filling within 10 h of training.¹⁸ In a cardiac arrest scenario, a limited examination may identify a potentially reversible cause and allow for intervention.¹⁹ We support the view that bedside echocardiography should be more widely used in the management of acutely ill patients and that a formal competency-based training programme should be developed.²⁰

This report highlights the potential risk of cardiac tamponade with PICCs. This should be balanced against intended benefits when deciding to insert a PICC line. When positioning the tip, it is vital to allow for movement of the catheter that will occur with arm abduction and we therefore recommend chest radiography to confirm the location of the catheter tip before the infusion of any fluid. While correction of mild hypokalaemia is routine on many critical care units, this case demonstrates that this is not without risk and other routes of administration should be considered where possible. Clinicians should consider the possibility of cardiac tamponade in any patient that deteriorates with a central venous catheter *in situ*. If this is suspected, the aspiration of the catheter should be performed and blind pericardiocentesis may be required if bedside echocardiography is not available.

References

- 1 Colomina MJ, Godet C, Pellisé F, González-P MA, Bagó J, Villaneuva C. Cardiac tamponade associated with a peripheral vein central venous catheter. *Paediatr Anaesth* 2005; **15**: 988–92
- 2 Scott WL. Central venous catheters: an overview of Food and Drug Administration activities. *Surg Oncol Clin N Am* 1995; **4**: 377–92
- 3 Collier PE, Blocker SH, Graff DM, Doyle P. Cardiac tamponade from central venous catheters. *Am J Surg* 1998; **176**: 212–4
- 4 Schuster M, Nave H, Piepenbrock S, Pabst R, Panning B. The carina as a landmark in central venous catheter placement. *Br J Anaesth* 2000; **85**: 191–3
- 5 Albrecht K, Nave H, Breitmeier D, Panning B, Tröger HD. Applied anatomy of the superior vena cava—the carina as a landmark to guide central venous catheter placement. *Br J Anaesth* 2004; **92**: 75–7
- 6 Fletcher SJ, Bodenham AR. Safe placement of central venous catheters: where should the tip of the catheter lie? *Br J Anaesth* 2000; **85**: 188–91
- 7 Stonelake PA, Bodenham AR. The carina as a radiological landmark for central venous catheter tip position. *Br J Anaesth* 2006; **96**: 335–40
- 8 Department of Health. Review of the deaths of four babies due to cardiac tamponade associated with the presence of a central venous catheter. London: Department of Health, 2001
- 9 van Haeften TW, van Pumpus EC, Boot H, Strack van Schijndel RJ, Thijs LG. Cardiac tamponade from misplaced central venous line in pericardiophrenic vein. *Arch Intern Med* 1988; **148**: 1649–50
- 10 Krog M, Berggren L, Brodin M, Wickborn G. Pericardial tamponade caused by central venous catheters. *World J Surg* 1982; **6**: 138–43
- 11 Forauer AR, Alonzo M. Change in peripherally inserted central catheter tip position with abduction and adduction of the upper extremity. *J Vasc Interv Radiol* 2000; **1**: 1315–8
- 12 Ng SW, Rosen M. Positioning central venous catheters through the basilic vein. *Br J Anaesth* 1973; **45**: 1211–4
- 13 Gravenstein N, Blackshear RH. *In vitro* evaluation of relative perforating potential of central venous catheters: comparison of materials, selected models, number of lumens and angles of incidence to simulated membrane. *J Clin Monit* 1991; **7**: 1–6
- 14 Wang K. Pseudoinfarction pattern due to hyperkalemia. *N Engl J Med* 2004; **351**: 593
- 15 Aronova GN. The effect of potassium on the coronary circulation. *Biull Eksp Biol Med* 1965; **59**: 119–23
- 16 Booth SA, Norton B, Mulvey DA. Central venous catheterization and fatal cardiac tamponade. *Br J Anaesth* 2001; **87**: 298–302
- 17 Vignon P, Chastagner C, Francois B, et al. Diagnostic ability of hand-held echocardiography in ventilated critically ill patients. *Crit Care* 2003; **7**: R84–91
- 18 Manasia AR, Nagaraj HM, Kodali RB, et al. Feasibility and potential clinical utility of goal-directed transthoracic echocardiography performed by noncardiologist intensivists using small hand-carried device (SonoHeart) in critically ill patients. *J Cardiothorac Vasc Anesth* 2005; **19**: 155–9
- 19 Tayal VS, Kline JA. Emergency echocardiography to detect pericardial effusion in patients in PEA and near-PEA states. *Resuscitation* 2003; **59**: 315–8
- 20 Ashrafian H, Bogle RF, Rosen SD, Henein M, Evans TW. Portable echocardiography. *Br Med J* 2004; **328**: 300–1