OXFORD

Revalidation FOR ANAESTHETISTS RCA Revalidation matrix
Matrix reference ID02, 2E02, 3A08

BJA Education, 16 (1): 26–32 (2016)

doi: 10.1093/bjaceaccp/mkv011
Advance Access Publication Date: 8 June 2015

Rib fracture management

L May MBChB FRCA MAcadMEd[1], C Hillermann MBChB FRCA DA(SA)[1,*] and S Patil MS MSc FRCSEd (T&O)[2]

[1]Department of Anaesthesia, University Hospitals Coventry and Warwickshire NHS Trust, Coventry, UK, and [2]Department of Trauma and Orthopaedics, UHCW NHS Trust, Coventry, UK

*To whom correspondence should be addressed. E-mail: chillermann@yahoo.co.uk

Downloaded from https://academic.oup.com/bjaed/article/16/1/26/2463139 by guest on 19 April 2024

Key points

- Traumatic rib fractures are common, resulting from significant forces impacting on the chest, and are associated with significant morbidity and mortality.
- Respiratory complications, including pneumonia, are common occurring in up to 31% of patients.
- Prompt multi-modal analgesia incorporating regional analgesia, i.v. opioids, and oral adjuncts are essential to reduce complications.
- Operative fixation is indicated in some instances.

Trauma is a major cause of morbidity and mortality worldwide, and the leading cause of death in the first four decades of life. Rib fractures are very common and are detected in at least 10% of all injured patients, the majority of which are as a consequence of blunt thoracic trauma (75%) with road traffic collisions being the main cause. The remaining 25% are due to penetrating injuries. Rib fractures are associated with significant morbidity, with patients frequently requiring admission to the intensive care unit (ICU), and mortality rates as high as 33%.[1]

Pathophysiology

This morbidity and mortality associated with rib fractures is caused by three main problems: hypoventilation due to pain, impaired gas exchange in damaged lung underlying the fractures, and altered breathing mechanics.

Pain associated with rib movement reduces the tidal volume and predisposes to significant atelectasis. This can further lead to retention of pulmonary secretions and pneumonia.

An injury severe enough to fracture ribs, especially if so significant as to cause a flail segment, will invariably cause a substantial contusion to the underlying lung. The lung becomes oedematous with varying degrees of haemorrhage and necrosis. The damaged lung is poorly compliant and will not take part in gas exchange, leading to intrapulmonary shunting and a decrease in Pa_{O_2}.

In the presence of a flail segment, the generation of negative intrapleural pressure produces paradoxical movement of the flail, causing it to move inward, while the rest of the ribcage moves outward. This means that the underlying lung does not expand and as a result, the tidal volume decreases; this has been demonstrated clinically, although an increase in the respiratory rate means that Pa_{CO_2} remains normal. This inefficient breathing results in higher oxygen consumption and has been shown to reduce Pa_{O_2}.

Ventilatory management

Ventilatory management of patients with rib fractures begins with supplementary oxygen. This should be humidified to loosen secretions and help sputum clearance improving patient comfort. Nebulized saline may also help reduce sputum retention. Respiratory physiotherapy can also be useful, but the patient's ability to cooperate will often be limited by discomfort.

If, despite supplementary oxygen, the Pa_{O_2} cannot be maintained, continuous positive airway pressure can be useful. Positive pressure will act to reduce atelectasis, reduce intrapulmonary shunting, and will reduce the paradoxical movement of a flail segment, if present. However, it can be uncomfortable for the patient and may make expectoration more difficult.

Ultimately, if other measures fail, sedation and invasive ventilation may be necessary. This is extremely undesirable and should be avoided where possible in patients without other injuries. Pain management therefore plays a key role in managing these patients. Once ventilated, early weaning from a ventilator is paramount.

Rib fracture scoring

The number of ribs fractured correlates with the severity of the injury and together with age, they are the most important

© The Author 2015. Published by Oxford University Press on behalf of the British Journal of Anaesthesia. All rights reserved.
For Permissions, please email: journals.permissions@oup.com

determinants of morbidity and mortality.[2,3] Four or more fractured ribs are associated with higher mortality rates and seven or more have a mortality rate of 29%.[4] The presence of a flail chest alone has a reported mortality rate of 33%, since the paradoxical chest movement further inhibits effective ventilation.[5]

The elderly are particularly susceptible to rib fractures and the associated complications, with pneumonia rates as high as 31%.[6] Ribs fracture more easily and are often a result of only moderate trauma. This is as a consequence of osteoporosis, cartilage degeneration, and reduced elasticity. Respiratory mechanics are affected due to a reduced muscle mass, a weakened diaphragm, and intercostal muscles, along with a loss of alveoli. These changes culminate in a reduced lung volume, decreased lung function, and impaired gas exchange with a poor respiratory reserve. All these alterations, along with other co-morbidities, make the elderly patient with rib fractures at increased risk of hypoventilation, atelectasis, pneumonia, and subsequent ventilation.

With these factors in mind, Easter created a formula to determine which adult patients are at higher risk and therefore in need of a higher level of care:[4]

$$\text{Rib fracture score} = (\text{breaks} \times \text{sides}) + \text{age factor}$$

'Breaks' is the total number of fractures to the ribs and not the number of ribs fractured, for example, two fractures in one rib scores 2. For 'sides', unilateral fractures scores 1 and bilateral 2. Age is factored into the equation due to the aforementioned increased risk of complications, with different age groups scoring between 0 and 4.

In a study by Maxwell and colleagues,[7] they found the scoring system did not have a strong statistical validity as a predictor, but it was a useful screening tool to heighten awareness of increased risk. We have used the scoring system as a decision-making tool to decide on the appropriate level of analgesia required for each patient (Fig. 1).

Analgesia for rib fractures

The associated pain is notoriously difficult to manage, but effective analgesia started promptly prevents hypoventilation, enables deep breathing, adequate coughing with clearance of pulmonary secretions, and compliance with chest physiotherapy. Overall, this reduces secondary pulmonary complications, including atelectasis, pneumonia, respiratory failure, and the need for respiratory support.

Patients presenting to the emergency department after blunt chest wall trauma may require urgent intervention, including intubation and ventilation, but others may show little or no respiratory compromise. However, pulmonary complications often only become evident 48–72 h after the injury.

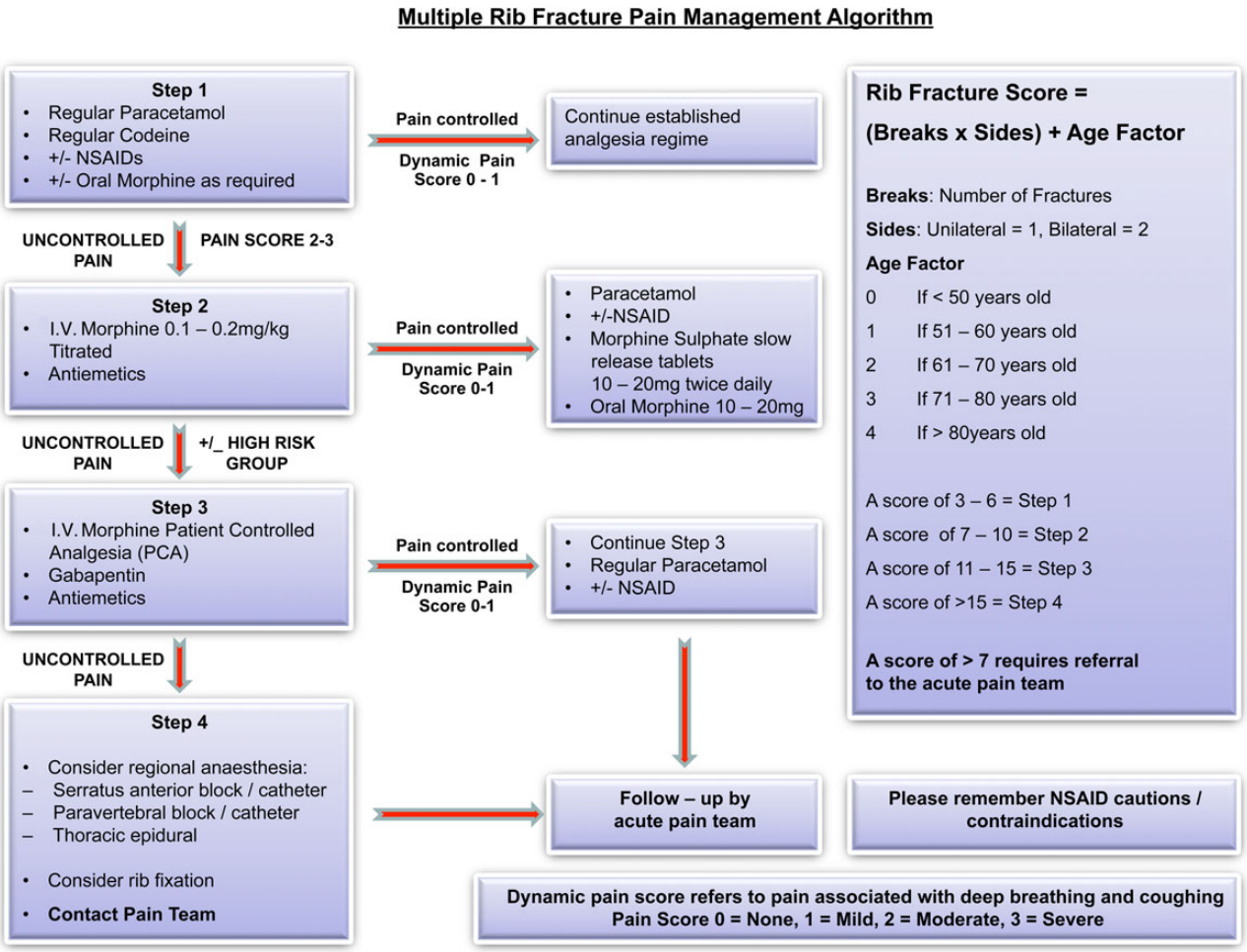

Fig 1 Multiple rib fracture pain management algorithm.

Downloaded from https://academic.oup.com/bjaed/article/16/1/26/2463139 by guest on 19 April 2024

It is therefore imperative that effective analgesia is started promptly, preferably in the emergency department upon admission, not just for analgesia and patient comfort, but also to try and prevent the complications that ensue over the subsequent days.

Opioids were previously the mainstay of treatment, but with significant side-effects, including respiratory depression, depressed cough reflex, and delirium; multi-modal analgesia is now more commonly used, which incorporates regional nerve blocks and thoracic epidural analgesia.

Figure 1 is our current working rib fracture algorithm that incorporates Easter's scoring system to help identify those patients at greatest risk for morbidity and mortality and provide an analgesic pathway to most suit their needs.

Step 1: simple analgesics

The analgesia prescription for a patient should include regular simple analgesia, for example, paracetamol, a weak opioid, a non-steroidal anti-inflammatory drug (if not contraindicated), and a strong opioid for breakthrough pain. If adequate analgesia is achieved then the patient can be continued on this regime.

Step 2: opioids

If the pain is not controlled with the interventions in Step 1, then i.v. morphine can be titrated to effect with slow boluses of up to 0.1–0.2 mg kg^{-1}. Once adequate analgesia is achieved, a strong opioid (e.g. a slow-release morphine sulphate or oxycodone) can be added to the regular prescription in place of the weak opioid in Step 1. Side-effects of strong opioids such as nausea and vomiting and constipation need to be addressed with the relevant antiemetic and laxative prescriptions.

Step 3: i.v. patient-controlled analgesia

If the pain remains uncontrolled, or multiple morphine boluses are required, then a morphine i.v. patient-controlled analgesia should be started, providing the patient can successfully operate one. The addition of gabapentinoids should be considered due to their analgesic properties and opioid-sparing effects.

Step 4: regional anaesthetic techniques and operative fixation

Thoracic epidural

Epidural analgesia has become the standard of care when opioid analgesia is inadequate or initial presentation requires it, although it is an underutilized resource. Patients with higher rib fractures, multilevel or bilateral fractures, flail chests, intercostal drains, and functional respiratory compromise secondary to pain benefit most from epidurals.[8]

Multiple retrospective reviews and prospective trials have demonstrated improved pulmonary function, including tidal volume and maximal inspiratory force, enhanced analgesia, with overall better clinical outcomes when compared with treatment with systemic opioids.[8] The improved pulmonary function reduces the incidence of pneumonia, number of ventilator days, and mortality, especially those sustaining five or more rib fractures.[2,9]

When performing a thoracic epidural to provide analgesia for multiple rib fractures, the vertebral level of insertion should ideally be that of the middle fractured rib. Choice of local anaesthetic and loading doses, along with the infusion regime, are very much down to the operator and local policy. Our local policy is described in Table 1. The addition of opioids, for example, diamorphine, can prove highly beneficial, especially in an inadequate epidural. However, number of ribs fractured, co-existing injuries, age, co-morbidities, and haemodynamic status will all have an impact on the volume of local anaesthetic used, addition of opioids, and the starting rate of the infusion. Throughout the duration of the thoracic epidural, the extent of the block (both sensory and motor) need to be monitored and the patient requires regular (4 h) nursing observations, including arterial pressure and pulse and oxygen saturations.

Table 1 Local thoracic epidural regime

Loading dose	0.25% bupivacaine, 7.5–12 ml
Infusion	0.1% bupivacaine+2 μg ml^{-1} fentanyl, 5–15 ml h^{-1}
Breakthrough pain	Bolus infusion mixture, 5–10 ml, or Bolus 0.25% bupivacaine, 5–10 ml Consider bolus of epidural diamorphine 2–3 mg, once daily only

Although thoracic epidurals provide excellent analgesia for the management of rib fractures, they are limited to a certain population due to patient factors and side-effects. Many trauma patients have other injuries which contraindicate the use of epidurals, or which prevent positioning for insertion.

Contraindications[6]

Absolute

- Patient refusal
- Spinal cord injury
- Epidural or spinal cord haematoma
- Thoracic vertebral body fracture
- Spinal injury awaiting assessment
- Coagulopathy (platelets <50×10^9 $litre^{-1}$, INR>1.5)
- Local infection or sepsis
- Allergy to local anaesthetic

Relative

- Inability to position patient due to associated injuries
- Severe traumatic brain injury
- Unstable lumbar or cervical spinal fractures
- Anticoagulant therapy
- Platelet count 50–100 × 10^9 $litre^{-1}$
- Hypotension
- Hypovolaemia

There are disadvantages to thoracic epidural analgesia. They are technically challenging to insert, with a risk of dural puncture or spinal cord injury. Adverse effects include hypotension, and if opioids used, urinary retention and pruritus. Patients can develop a motor block and are unable to mobilize with an epidural *in situ*.

Paravertebral block

Injection of local anaesthetic into the thoracic paravertebral space produces unilateral sensory, motor, and sympathetic block. The spinal nerves are not initially bound by a fascial sheath, therefore enhancing uptake of local anaesthetic. The paravertebral space communicates with the epidural space medially and the intercostal space laterally, but with adequate volume, the majority spreads caudally and cranially covering at least five sensory dermatomes.[10] One catheter can cover up to

Downloaded from https://academic.oup.com/bjaed/article/16/1/26/2463139 by guest on 19 April 2024

six consecutive fractured ribs, but a second catheter can be inserted for more than six levels, or for bilateral fractures, if a thoracic epidural is contraindicated. The vertebral level of insertion should ideally be at the height of the middle fractured rib.

Ensuring not to exceed the maximum local anaesthetic dose, we recommend a bolus of 40 ml of 0.25% levobupivacaine, followed by an infusion of 0.1% levobupivacaine at 5–10 ml h^{-1} via an elastomeric pump. The infusion can be continued for up to 7 days. Multiple or bilateral blocks can be performed, but ensure local anaesthetic doses are within safe limits.

Evidence suggests that paravertebral blocks are as effective as thoracic epidurals without many of the contraindications, complications, and side-effects seen with epidurals.[11] A relatively safe and technically easy procedure that is ideally performed under ultrasound guidance, it can be inserted in the unconscious patient. Sympathetic blockade is not seen when compared with thoracic epidurals due to limited epidural spread. Importantly, patients can also mobilize with a catheter *in situ*.

Contraindications

Absolute

- Patient refusal
- Allergy to local anaesthetic
- Local infection or sepsis

Relative

- Inability to position the patient
- Transverse process fractures at the level of the intended block
- Unstable vertebral fractures
- Anticoagulated patients/deranged clotting

Complications

- Failure
- Inadvertent epidural or intrathecal injection
- Epidural spread and hypotension
- Pneumothorax
- Intrapleural injection
- Vascular puncture
- Local anaesthetic toxicity

Serratus plane block

A regional anaesthetic technique first described in 2013 by Blanco and colleagues[12] for surgery performed on the anterolateral chest wall, serratus plane blocks aim to provide anaesthesia of the hemithorax. It has been used in patients with rib fractures as an alternative to thoracic paravertebral blocks and thoracic epidurals.[13,14]

Anatomy

The serratus anterior muscle originates on the anterior surface of ribs 1–8 and inserts on the medial border of the scapula. A potential space exists both superficial and deep to the serratus anterior muscle. The latissimus dorsi muscle lies superficial to serratus anterior, with the ribs and thoracic intercostal nerves lying deep to, but also piercing the serratus muscle. This therefore enables the thoracic intercostal nerves to be blocked when injecting local anaesthetic in the potential space around the serratus muscle, providing analgesia to the anterolateral part of the thorax, with paraesthesia from T2 to T9.[12] Local anaesthetic can be infiltrated either superficial or deep to serratus anterior, but Blanco and colleagues found a greater duration of action from superficial placement.

Indications/contraindications

Suitable for all rib fractures, there are very few contraindications to inserting a serratus plane block, with patient refusal, allergy to local anaesthetics, and local infection the only standard absolute reasons.

Relative contraindications are associated with distorted anatomy making landmarks difficult to identify by ultrasound, for example, surgical emphysema, intercostal drain placement, and previous surgery at the insertion site.

Recommended technique

Preparation

Informed consent should be obtained from the patient, and the block performed with a trained assistant in an area where full resuscitation equipment is available. Standard non-invasive monitoring should be applied and an i.v. cannula inserted. Aseptic precautions should be maintained throughout the procedure.

Procedure

As described by Blanco and colleagues, the block is performed with the patient in the supine position and the arm abducted. Using a high-frequency linear ultrasound probe set between 6 and 13 MHz, place the probe in the sagittal plane and identify the fifth rib in the mid-axillary line. Latissimus dorsi and serratus anterior muscles are now easily identifiable overlying the fifth rib (Fig. 3). The planes can be found between a depth of 1–2 cm from the skin, with the thoracodorsal artery passing in the superficial plane to serratus anterior (Fig. 2).

After local anaesthetic infiltration, using a 50 mm 18 G Tuohy catheter needle, insert the needle in-plane superficial (recommended and demonstrated in Figs 3 and 4) or deep to the serratus anterior muscle (Figs 5 and 6). Inject local anaesthetic and confirm good spread between latissimus dorsi and the serratus muscle, or deep to serratus. Ensuring not to exceed the maximum local anaesthetic dose, we recommend a bolus of 40 ml of 0.25% levobupivacaine. Immediately insert a catheter 2–3 cm into the space, tunnel, and secure in place. Correct catheter placement can be confirmed by demonstrating further local anaesthetic spread under ultrasound visualization. Commence an infusion of local anaesthetic, again weight dependent, but 0.1%

Fig 2 Ultrasound probe and needle orientation.

Downloaded from https://academic.oup.com/bjaed/article/16/1/26/2463139 by guest on 19 April 2024

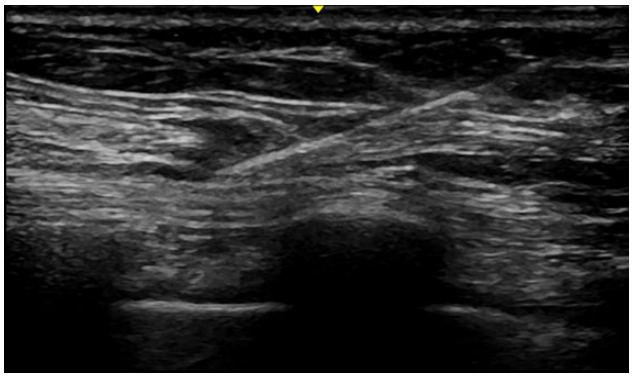

Fig 3 Ultrasound image of a superficial serratus plane block.

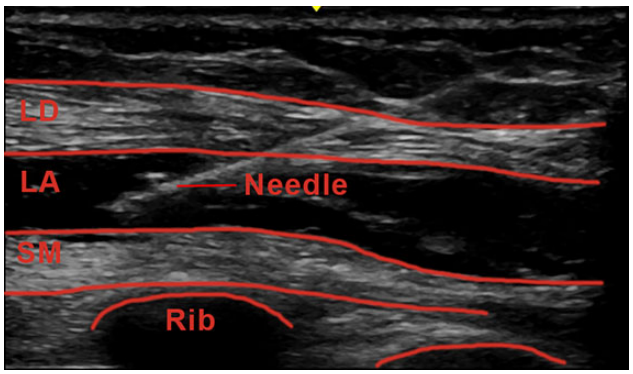

Fig 4 On injection of local anaesthetic (LA), good separation is demonstrated between latissimus dorsi (LD) and the serratus muscle (SM).

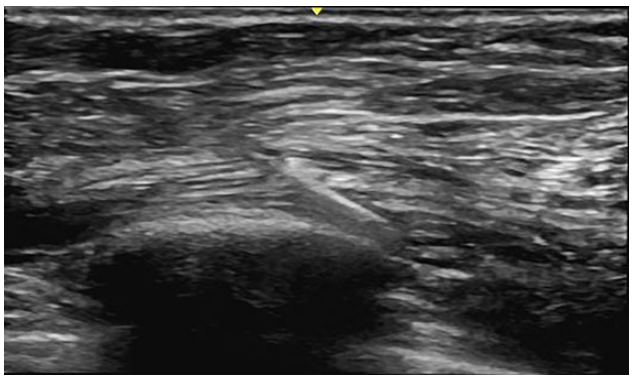

Fig 5 Ultrasound image of a deep serratus plane block.

levobupivacaine at 5–10 ml h^{-1} via an elastomeric pump is optimal, and can be kept running for up to 7 days if no signs of infection. Bilateral blocks can be performed, but ensure the maximum dose of local anaesthetic is not exceeded.

Static and dynamic pain scores, along with incentive spirometry and patient satisfaction, can confirm the adequacy of the block.

Advantages

- Technically easy and superficial block
- Performed with patients supine, therefore particularly useful when other injuries prevent patients rolling laterally or sitting to perform either a thoracic epidural or paravertebral block

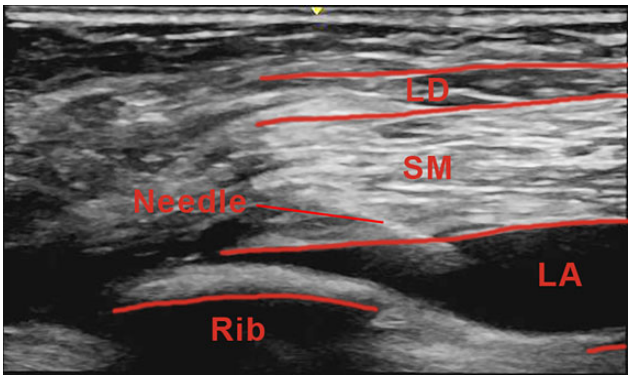

Fig 6 Good spread of LA is seen deep to SM, above ribs 4 and 5.

- Suitable for rib fracture patients with associated spinal trauma or head-injuries where paravertebral and epidural blocks are contraindicated
- Can be inserted in anticoagulated or thrombolysed patients
- Patients can mobilize with catheter *in situ*

Complications

- Pneumothorax
- Vascular puncture
- Nerve damage
- Failure/inadequate block
- Local anaesthetic toxicity
- Infection

Interpleural block

This has fallen out of favour as it provides suboptimal pain relief for patients with rib fractures.[11] Local anaesthetic can be injected via the chest drain, however, before absorption, it can drain out via the chest tubing. Large volumes are required and with rapid absorption, local anaesthetic toxicity is a risk. The distribution of the local anaesthetic is influenced by gravity and therefore patient positioning may prevent the correct intercostal nerves being targeted leading to an inadequate block. Blood or fluid in the pleural cavity will also dilute the local anaesthetic. Occluding the drain before and after injection can cause its own complications and may not be clinically safe. Infection can be introduced into the pleural cavity and an empyema can develop.

Intercostal block

Although correctly placed intercostal blocks can be very effective, providing effective analgesia for 4–24 h, reducing morbidity and length of stay, they involve multiple injections with a risk of pneumothorax and intravascular injection with every injection (http://www.trauma.org/archive/thoracic/CHESTflail.html).[11] The risk of local anaesthetic toxicity increases with every injection due to its rapid absorption. Palpation to determine the appropriate site for injection causes patient discomfort. Catheters have been placed in the intercostal space which provides spread of local anaesthetic to adjacent intercostal spaces providing analgesia to several dermatomes.

Operative fixation

Management of rib fractures by stabilizing the chest has been around for centuries, but has gone in and out of fashion.

Downloaded from https://academic.oup.com/bjaed/article/16/1/26/2463139 by guest on 19 April 2024

Fig 7 Three-dimensional CT reconstruction showing unilateral fractures to ribs 2–8 on the right, with a flail segment involving ribs 4–8.

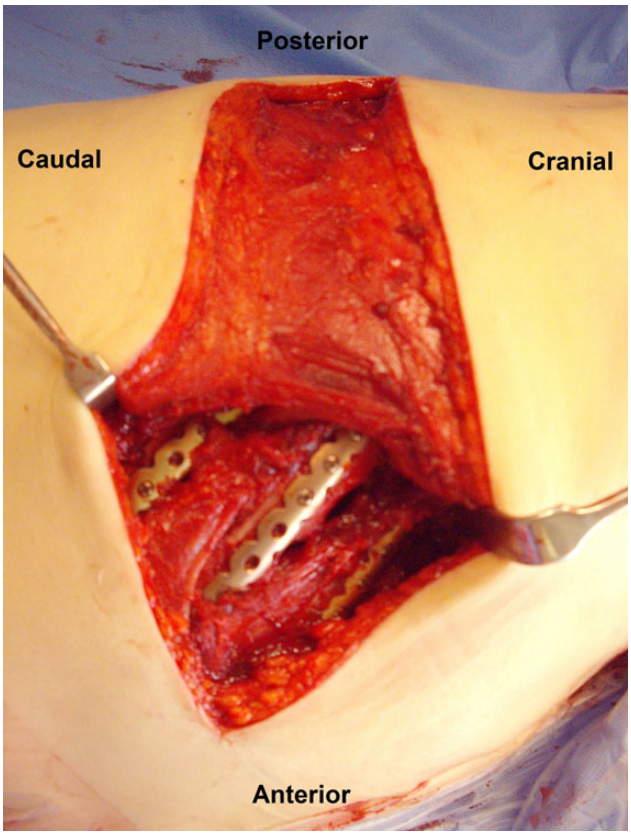

Fig 8 Subsequent operative fixation of ribs 4–8 with plates and locking screws.

However, more recently, rib fracture fixation has made a resurgence with evidence suggesting it is beneficial for a certain group of patients. Intubated patients with a flail chest, respiratory failure, and prolonged ventilation, or non-intubated patients with a flail with deteriorating pulmonary function, are now considered for operative fixation.[15] The aim is to stabilize the chest to restore pulmonary mechanics and reduce pain. Other indications include rib fractures refractory to conventional pain management, rib fracture non-union, and during a thoracotomy performed primarily for other injuries.[5]

Surgical repair is technically challenging due to the nature of the ribs. They have a conical and twisted shape with a thin cortex and often fracture obliquely. This results in poor cortical screw purchase. Individual ribs do not tolerate stress well and each fixation must tolerate the repetitive movement of at least 20 000 breaths day^{-1}.

A 3D CT reconstruction of the chest wall is necessary before surgery to plan the incision (Fig. 7). Although the skin incision is very similar to that of a thoracotomy, most centres have started using a muscle-sparing approach which avoids incising the latissimus dorsi muscle. Some centres are also practising minimally invasive surgery where small incisions are strategically placed to provide access to at least two or more rib fractures. Ultrasound can be used to mark the fracture site and subsequent incision before the operation.

The procedure is usually performed in the lateral position under general anaesthesia with a thoracic epidural, paravertebral, or serratus block for postoperative analgesia. Standard monitoring is applied as per AAGBI guidelines with invasive monitoring in the form of an arterial line, and a central venous catheter if required. The use of a double-lumen tube enables inspection of the lung at the time of rib fracture fixation, although not all centres opt for this. Intercostal drains inserted before the operation in close proximity to the surgical incision should be removed to prevent infection.

Anterior, anterolateral, and posterolateral rib fractures can be fixed with plates, although intramedullary splints are available for posterior fractures. The first aim of fracture fixation is to address the flail segment. Most surgeons aim to fix both ends of the flail segment. However, some posterior rib fractures are difficult to access without causing significant muscle stripping.

Once accessed, the fracture is reduced and a plate of appropriate length, usually 6–10 holes, is applied. The majority of plates are pre-contoured for different rib levels, although sometimes additional moulding is required. Two to three locking screws are then inserted on either side of the fracture (Fig. 8). At all times, the underside of the rib is avoided to prevent damage to the intercostal neurovascular bundle. No imaging is required intraoperatively, but an AP X-ray should be performed after the operation to demonstrate fracture fixation and lung expansion. A separate chest drain is inserted before closure.

In 2010, the National Institute for Health and Clinical Excellence (NICE) produced guidance on the insertion of metal rib reinforcements to stabilize a flail chest wall. Recognizing the evidence for operative stabilization lacks quantity, but consistently shows efficacy, NICE recommend a multidisciplinary approach to patient selection by critical care specialists, chest physicians, and thoracic surgeons, with appropriate training and experience.

Downloaded from https://academic.oup.com/bjaed/article/16/1/26/2463139 by guest on 19 April 2024

Randomized control trials report significantly reduced rates of pneumonia in surgical fixation compared with those treated with mechanical ventilation. Overall critical care stay is less with fewer ventilator days, and reduced mortality.[1,16] Studies show opioid requirements are reduced and operative fixation is cost-effective.[1]

Chronic pain and disability

Chronic pain and disability are significant contributors to diminished quality of life after trauma. Little is known about the prevalence of chronic pain and disability after rib fractures, but a recent prospective follow-up of 203 patients with rib fractures found a prevalence of chronic pain of 22% and disability of 53%.[17] Acute pain intensity in the first 2 weeks predicted chronic pain; however, associated injuries, bilateral fractures, number of fractures, and injury severity score were not predictive of the development of chronic pain. Only acute pain intensity and bilateral fractures predicted disability. With operative fixation, forced vital capacity at 12 months is greater, more people return to work, and the incidence of chronic pain reduced.[15]

Conclusion

Rib fractures are common in trauma and associated with significant morbidity and mortality. The key to managing these patients is early recognition of those at risk of deterioration, prompt and effective analgesia, early mobilization, and respiratory support where indicated. This will enable deep breathing, coughing, and compliance with chest physiotherapy to try and prevent the associated complications that ensue.

Local pathways and scoring systems help to determine an appropriate initial analgesic plan with subsequent options if suboptimal. Regional analgesia should be considered, and although thoracic epidurals have previously been the gold standard, ultrasound-guided paravertebral and serratus plane blocks are possible alternatives. Operative fixation plays a role in patients with a flail chest and respiratory compromise, especially those un-intubated with deteriorating pulmonary function, or if there is difficulty weaning patients from a ventilator. Overall, results demonstrate reduced morbidity and mortality.

Declaration of interest

None declared.

MCQs

The associated MCQs (to support CME/CPD activity) can be accessed at https://access.oxfordjournals.org by subscribers to *BJA Education*.

References

1. Pressley C, Fry W, Philp A, Berry S, Smith R. Predicting outcome of patients with chest wall injury. *Am J Surg* 2012; **204**: 910–4
2. Easter A. Management of patients with multiple rib fractures. *Am J Crit Care* 2001; **10**: 320–9
3. Flagel B, Luchette F, Reed L *et al*. Half-a-dozen ribs: the breakpoint for mortality. *Surgery* 2005; **138**: 717–25
4. Holcomb J, McMullin N, Kozar R, Lygas M, Moore F. Morbidity from rib fractures increases after age 45. *J Am Coll Surg* 2003; **196**: 549–55
5. Nirula R, Diaz J, Trunkey D, Mayberry J. Rib fracture repair: indications, technical issues, and future directions. *World J Surg* 2009; **33**: 14–22
6. Bulger E, Edwards W, Pinto M, Klotz P, Jurkovich G. Indications and contraindications for thoracic epidural analgesia in multiply injured patients. *Acute Pain* 2008; **10**: 15–22
7. Maxwell C, Mion L, Dietrich M. Hospitalised injured older adults; clinical utility of a rib fracture scoring system. *J Trauma Nurs* 2012; **19**: 168–74
8. Yeh D, Kutcher M, Knudson M, Tang J. Epidural analgesia for blunt thoracic injury—which patients benefit most? *Injury* 2012; **43**: 1667–71
9. Ahn Y, Gorlinger K, Alam H, Eikermann M. Case scenario: pain-associated respiratory failure in chest trauma. *Anaesthesiology* 2013; **118**: 701–8
10. Ho A, Karmakar M, Critchley L. Acute pain management of patients with multiple fractured ribs: a focus on regional techniques. *Curr Opin Crit Care* 2011; **17**: 323–7
11. Wharden R. Assessment and management of rib fracture pain in geriatric population: an *ode to old age*. *Curr Opin Anaesthesiol* 2013; **26**: 626–31
12. Blanco R, Parras T, McDonnell J, Galino A. Serratus plane block: a novel ultrasound-guided thoracic wall nerve block. *Anaesthesia* 2013; **68**: 1107–13
13. Millerchip S, May L, Hillermann C. Continuous serratus anterior block: an alternative regional analgesia technique in patients with multiple rib fractures. *Reg Anaesth Pain Med* 2014; **39**: ESRA-10758
14. Lopez-Matamala B, Fajardo M, Estebanez-Montiel B, Blancas R, Alfaro P, Chana M. A new thoracic interfascial plane block as anaesthesia for difficult weaning due to rib-cage pain in critically ill patients. *Med Intensiva* 2013; **38**: 463–5
15. Hasenboehler E, Bernard A, Bottiggi A *et al*. Treatment of traumatic flail chest with muscle sparing open reduction and internal fixation: description of a surgical technique. *J Trauma* 2011; **71**: 494–501
16. Battle C, Hutchings H, Evans P. Blunt chest wall trauma: a review. *Trauma* 2013; **15**: 156–75
17. Gordy S, Fabricant L, Ham B, Mullins R, Mayberry J. The contribution of rib fractures to chronic pain and disability. *Am J Surg* 2014; **207**: 659–62

Downloaded from https://academic.oup.com/bjaed/article/16/1/26/2463139 by guest on 19 April 2024