

# Anaesthesia for shoulder surgery

Christina L Beecroft FRCA, FDS RCS  
David M Coventry FRCA

There is a wide variety of patients who present for shoulder surgery, ranging from the fit, robust patient with a sports injury requiring a stabilization procedure, to the frail, elderly rheumatoid patient requiring joint decompression or arthroplasty. Recent surgical advances have resulted in the development of minimal access arthroscopic procedures with resulting improvements in speed of convalescence. However, the management of severe postoperative pain remains a major challenge for many anaesthetists.

Regional anaesthetic techniques have the ability to control pain effectively both at rest and on movement, reduce muscle spasm, and allow earlier mobilization and co-operation with physiotherapy. Therefore, these techniques have the potential to improve both patient recovery and outcome after both open and arthroscopic surgeries. Management of these patients requires thorough preoperative assessment, careful intraoperative management, and appropriate use of regional anaesthetic techniques to provide adequate dynamic pain relief in the initial postoperative period.

## Anatomy

Sound anatomical knowledge is essential in both planning and executing regional anaesthetic techniques for the shoulder, whether using peripheral nerve stimulation or ultrasound. The shoulder area is innervated by nerves of both cervical and brachial plexuses (Fig. 1). The former supplies the skin above the clavicle, shoulder tip, and first two intercostal spaces anteriorly through the superficial cervical plexus and supraclavicular nerves (C3–C4). The brachial plexus innervates the skin over the deltoid muscle through the upper lateral cutaneous branch of the axillary nerve, and the medial side of the arm and axilla through the medial cutaneous nerve of the arm and the intercostobrachial nerve (T2). In addition, the shoulder joint has rich innervation from the brachial plexus, which must be adequately blocked to allow surgery to proceed in the

awake patient and also to provide adequate dynamic pain relief in the postoperative period. The acromioclavicular joint is largely supplied by the suprascapular nerve, which also provides some innervation to the capsule and the glenohumeral joint. The inferior aspect of the capsule and glenohumeral joint are supplied by the axillary nerve. There may, in addition, be a small variable contribution from the musculocutaneous and subscapular nerves.

## Surgical procedures

### Open surgery

The most commonly performed open surgical procedures include repairs for instability, acromioplasty, subacromial decompression, fracture fixation, and hemi- and total shoulder arthroplasty. The main surgical approach is through an anterior incision starting just lateral to the tip of the coracoid, running down into the axillary crease. A more extended approach is used for shoulder arthroplasty, when the incision is continued past the axilla to the deltoid insertion. A posterior approach is rarely used.

### Arthroscopic surgery

In recent years, shoulder arthroscopy has been increasingly popular both as a diagnostic tool and for surgical procedures, including acromioplasty, stabilization of the glenohumeral joint, arthroplasty of the acromioclavicular joint, rotator cuff repairs, and chondroplasties. The patient is either in the deck chair or lateral position, depending on surgical preference. Port placement is crucial in shoulder arthroscopy and the main port sites are posterior (2 cm inferior and medial to the posterolateral corner of the acromium) and lateral (1–2 cm posterior, 2–3 cm lateral to the anterolateral corner of the acromium). The posterior port site may require some additional local anaesthetic infiltration if surgery is performed under interscalene block alone.

## Key points

Severe pain following shoulder surgery is common and remains a major challenge.

Regional anaesthetic techniques have the ability to control pain effectively, both at rest and on movement, allowing earlier mobilization.

Sound anatomical knowledge is the key to planning and executing successful regional anaesthesia.

Interscalene block should be considered as the regional technique of choice.

The perineural infusion of local anaesthetic can successfully prolong postoperative analgesia.

Christina L Beecroft FRCA, FDS RCS

Department of Anaesthetics  
Ninewells Hospital and Medical School  
Dundee DDI 9SY  
UK

David M Coventry FRCA

Department of Anaesthetics  
Ninewells Hospital and Medical School  
Dundee DDI 9SY  
UK

E-mail: david.coventry@nhs.net  
(for correspondence)

doi:10.1093/bjaceaccp/mkn040

Continuing Education in Anaesthesia, Critical Care & Pain | Volume 8 Number 6 2008

© The Board of Management and Trustees of the British Journal of Anaesthesia [2008].

All rights reserved. For Permissions, please email: journals.permissions@oxfordjournals.org

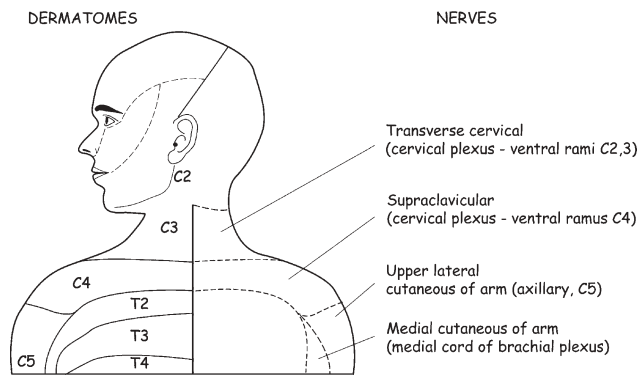


Fig 1 Innervation of the shoulder.

## Preoperative assessment

### General considerations

A full preoperative anaesthetic assessment is essential before choosing the most appropriate anaesthetic technique. Although many of the patients are fit and healthy, another group exists in whom coexisting medical problems have not only contributed to the development of shoulder ailments but also make anaesthetizing the patient for surgery challenging. Besides patient factors influencing anaesthetic technique, surgical factors also need to be considered. Minor surgical procedures can usually be carried out with regional anaesthesia alone, whereas, with more major surgery of longer duration, a combination of regional and general anaesthesia may be more appropriate. Patient selection and psychological preparation are essential for awake shoulder surgery, as aspects of the procedure are often less well tolerated even with excellent anaesthesia due to the proximity of surgical instruments to the face and head.

### Rheumatoid disease

Patients with rheumatoid arthritis merit special consideration,<sup>1</sup> as this multisystem disorder is associated with atlantoaxial instability in ~25% of sufferers. Therefore, regional anaesthesia as the sole technique is always worth considering to avoid intubation or other airway manoeuvres. Whichever anaesthetic technique is chosen, it is important to ensure that the airway is secure before positioning and surgery; emergency airway manipulation in patients with such a high incidence of problems should certainly be avoided. Block insertion may also be technically challenging, due to the difficulties in patient positioning and disruption of the normal anatomical landmarks. Patients with rheumatoid arthritis may have respiratory involvement; the degree of impairment should be established with pulmonary functions tests where appropriate, as interscalene block may cause a further 25–30% reduction in spirometric measures of pulmonary function. There may also be pre-existing neurological deficits and these should be documented before anaesthesia and surgery. Finally, these patients are more prone to skin and pressure

area damage and nerve compression injuries; care must be taken when positioning the patient for surgery.

## Interscalene blockade

When planning an anaesthetic for shoulder surgery, surgical and patient factors need to be considered. An interscalene approach to the brachial plexus is the most appropriate block to provide analgesia for the area; whether this is combined with general anaesthesia is influenced both by the type of surgery and patient factors. Many shoulder procedures can be carried out with regional anaesthesia alone, but a combination of regional and general anaesthesia may be more appropriate for prolonged major procedures or where discomfort in other areas may limit comfortable positioning on the operating table.

A modified Winnie technique remains the most straightforward approach to the brachial plexus in the interscalene region. With monitoring in place and i.v. access established in the non-operative side, the patient lies supine with the head turned slightly away from the side to be blocked. The posterior border of sternocleidomastoid is identified at the level of the cricoid cartilage (C6). The groove between scalenus anterior and medius is palpated slightly postero-lateral to this: the groove can be confirmed by palpation above the clavicle and then by tracing it cranially to the C6 level. After infiltration of the skin with local anaesthetic, a 5-cm short bevelled insulated nerve block needle attached to a peripheral nerve stimulator is inserted at an angle of 30° to the skin, aiming for the contralateral elbow (Fig. 2). Horizontal placement should be avoided as this may result in the needle passing between adjacent transverse processes with the possibility of entering the intervertebral foramen, dural cuff or vertebral artery. The plexus is often very superficial (<1.5 cm deep to the skin), and the appropriate end-point for the location of the plexus is stimulation of muscles distal to the acromium,<sup>2</sup> that is, usually stimulation of the upper trunk (deltoid or biceps muscle). A more peripheral response is not necessary for successful block. Ultrasound location allows direct visualization of both plexus and local anaesthetic spread and is being increasingly used for this purpose. Other approaches such

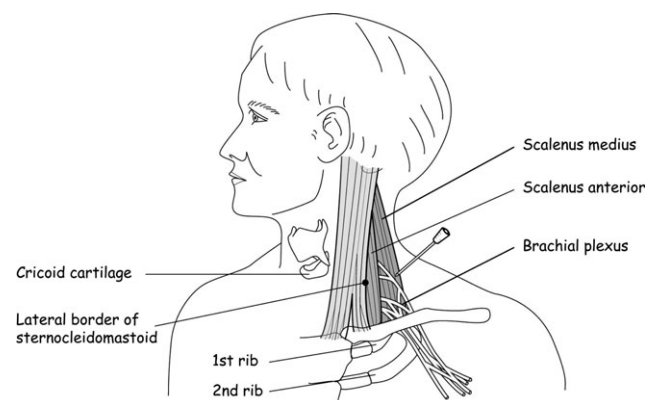


Fig 2 Anatomical landmarks for interscalene block.

as the Meier modification<sup>3</sup> may facilitate catheter placement due to a more favourable needle direction. The needle insertion site is a further 2 cm cranially (level of thyroid notch), with the needle directed along the interscalene groove towards the junction of the middle and lateral third of the *ipsilateral* clavicle, caudad and slightly dorsal to the horizontal.

Initial block assessment should be made 10 min after insertion; earlier evaluation when the block is unlikely to be working will only endanger patient confidence, which is an essential part of any regional technique. The three components of the block should be tested: (i) motor by asking the patient to abduct and flex the arm from the shoulder; (ii) cutaneous sensation to cold over the relevant dermatomes; and (iii) joint sensation by demonstrating the loss of pain (when present) during passive movement. Cutaneous anaesthesia alone is not a reliable indicator of block success. After the insertion of the block and the demonstration of its efficacy, general anaesthesia is induced if required. Alternatively, the patient is sedated, usually with midazolam or a target-controlled propofol infusion as appropriate. The judicious use of an opioid may be useful to help with generalized discomfort during the more prolonged cases.

We believe that the interscalene block should only be performed before the induction of general anaesthesia, as it is associated with potentially serious complications. Accidental i.v. injection of local anaesthetic can be more easily diagnosed in an awake patient and we advise, following aspiration, injecting only 1–2 ml of local anaesthetic to allow detection of inadvertent injection into the vertebral artery, before continuing with the slow injection of 5 ml increments to a total volume of 25–30 ml. Other major complications include subarachnoid/epidural injection, stellate ganglion block, and pneumothorax. Benumof<sup>4</sup> described four cases in which interscalene block performed after induction of anaesthesia led to total spinal anaesthesia and subsequently to extensive permanent cervical spinal cord damage. Magnetic resonance scans showed syrinx or cavity formation in the cervical spinal cord as a result of direct injection of local anaesthetic solution into the spinal cord.

The phrenic nerve, with associated ipsilateral hemidiaphragmatic paresis, is nearly always blocked; therefore, bilateral interscalene blocks should never be performed. It is also important to be cautious when performing this block on patients with co-existing respiratory disease as it may cause respiratory embarrassment or failure, particularly in the supine patient. A combination of COPD with a high BMI is particularly problematic, although most patients will tolerate a unilateral block if maintained in the deck chair or seated positions. Each case should be assessed on an individual basis and an alternative analgesic strategy sought if there is significant concern (see below).

Choice of local anaesthetic agent is usually determined by the duration and magnitude of surgery. Lidocaine is appropriate for short procedures (e.g. relocation of a dislocated shoulder) and for those patients with pre-existing respiratory compromise in whom shorter block duration is desirable. However, for most surgery, a long-acting agent such as levobupivacaine or ropivacaine is more appropriate given the significant postoperative discomfort involved.

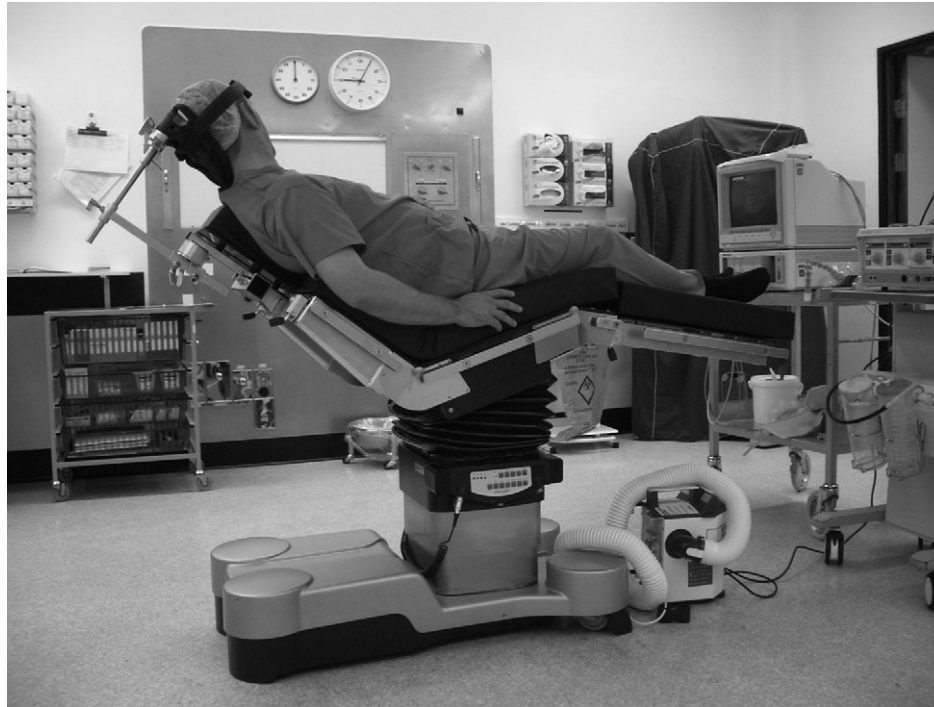A perineural catheter may be inserted while performing the interscalene block, allowing analgesia to be extended longer into the postoperative period. If a catheter is to be inserted, the initial block should be performed using one of the available proprietary catheter kits, and the catheter inserted to a depth of approximately 2–3 cm. Once the catheter is secured to the skin with an occlusive dressing, this should be covered with gauze to prevent the surgical drapes from sticking to the dressing, with the catheter then being inadvertently dislodged or cut at the end of the procedure. Alternatively, the catheter can be tunneled medially. This has three advantages: it improves catheter security in the perioperative period; it lessens the likelihood of infection; and the more medial placement removes the catheter further from the surgical field.

The brachial plexus is a relatively superficial structure in the interscalene region, and other techniques can be used to aid location of the plexus. These include ultrasound guided techniques and percutaneous electrode guidance of the block needle. Ultrasound guided block placement allows the plexus to be visualized at different levels in the neck. The path of the needle as it approaches the plexus can be visualized, allowing vital structures to be avoided, potentially reducing the incidence of complications. Using ultrasound as an aid to block placement is an exciting development; the technique was described in a recent review article.<sup>5</sup>

Percutaneous electrode guidance<sup>6</sup> uses a transcutaneous stimulating probe with the nerve first located by eliciting the desired motor response at a current of 5 mA at an increased pulse width of 1 ms. The needle insertion point can then be mapped on the skin and the block needle introduced.

## Intraoperative management

Adequate i.v. access should be obtained as blood loss can be significant, especially during arthroplasty. The deck chair (modified sitting) position is used for most anterior approaches to the shoulder joint (Fig. 3). The trunk and head are raised to an angle of approximately 20–30° to the horizontal to reduce venous pressure at the shoulder level; raising the legs will help maintain venous return and cardiac output. The legs should be flexed at the knees with a pillow to avoid discomfort from over-stretching of the hamstrings. Pressure points, especially the heels, must be carefully padded, as must the ulnar nerve at the elbow. The head and neck should be secure while care should be taken throughout the procedure to ensure that excessive stretching of the brachial plexus does not occur as a result of the excessive surgical traction. The eyes should be taped and padded in the anaesthetized patient as they are in close proximity to the surgical site and instruments. Performing surgery under peripheral nerve block alone allows the patient to assist with comfortable positioning on the operating table. However, shoulder surgery is often prolonged and patients may find parts of the procedure (e.g. reaming of the humerus during arthroplasty) unpleasant, even with sedation. A warm-air blanket system should be used to maintain patient temperature.



**Fig 3** The modified deck-chair position.

Patients in the deck chair position are prone to hypotension, mainly due to venous pooling in the extremities and lack of surgical stimulation with an effective block. The angle of elevation from the waist should be increased slowly in the compromised patient, thus allowing time for haemodynamic equilibration. Intra-operative cerebral ischaemia has been reported, probably through changes in cerebral blood flow from a combination of postural hypotension and excessive head and neck manipulation.<sup>7</sup> The Bezold-Jarisch reflex may be activated during shoulder surgery in the deck-chair position, especially when surgery is performed under interscalene block. This presents as sudden, profound bradycardia and hypotension, which can rapidly progress to cardiac arrest. However, the role of the reflex in these dramatic haemodynamic changes has recently been called into question.<sup>8</sup>

Neurological injuries are not uncommon during shoulder surgery; they are reported to occur in 1–4% of patients undergoing prosthetic arthroplasty or repairs for anterior instability. The axillary nerve is particularly vulnerable due to its close proximity to the inferior shoulder capsule. Surgical injury by direct laceration is rare while injury from traction (arthroscopic surgery), arm manipulation and nerve contusion are more common. Long-term neurological problems resulting from brachial plexus block are likely to occur in <0.2% of patients.<sup>9</sup>

### Postoperative analgesia

Shoulder surgery is associated with significant postoperative pain, but mobilization and physiotherapy often begin on the first

postoperative day. Therefore, excellent postoperative analgesia is essential to provide a good functional recovery. A multimodal approach is required to achieve this. Analgesic options include: conventional oral and parenteral analgesia; interscalene analgesia or intra-articular analgesia with or without continuous infusion; or suprascapular nerve block combined with local anaesthetic wound infiltration.

### Oral and parenteral analgesia

Paracetamol (acetaminophen) should always regularly be prescribed as part of a multimodal approach; this can be started intraoperatively as a parenteral preparation is now available. Non-steroidal anti-inflammatory drugs are relatively contraindicated in the first 24 h after surgery due to the increased risk of bleeding associated with this group of drugs. However, they can be considered after this period if there is no other contraindication to their use. A strong opioid should be prescribed for the postoperative period, patient-controlled analgesia using morphine is entirely appropriate when regional techniques are not used. A useful alternative is oral oxycodone commenced on the first postoperative day.

### Single-shot nerve block techniques

A single-shot interscalene block is associated with shorter anaesthetic and surgical time, decreased blood loss, shorter stay in the recovery room, decreased postoperative opioid requirements

and faster discharge from hospital. An interscalene block with bupivacaine provides analgesia for ~15 h. Rescue analgesia, usually a strong opioid, must be available when the block regresses; as this is likely to occur overnight, a straightforward i.m. injection of opioid at this stage is appropriate.

### Catheter techniques

Perineural interscalene brachial plexus catheters with local anaesthetic infusions are becoming increasingly popular in the management of postoperative pain after shoulder surgery. Not only do they prolong postoperative analgesia, they are opioid-sparing and may reduce the unwanted side effects associated with these drugs. Patients can be fully ambulant while using the simple elastomeric balloon pumps.<sup>10</sup> The most commonly used local anaesthetic agents for infusion are levobupivacaine and ropivacaine, infused at low concentrations to avoid prolonged motor block, for example, ropivacaine 2 mg ml<sup>-1</sup> at 5 ml h<sup>-1</sup>. An additional patient controlled component (2.5 ml bolus every 20–30 min) may be useful to increase efficacy further and improve patient satisfaction,<sup>11</sup> although this requires a more sophisticated infusion pump. Until recently, patients were required to stay in hospital for the duration of the infusion; however, recent work from specialist centres has shown that patients may be safely discharged from hospital with the catheters *in situ*, connected to simple, disposable elastomeric or electronic pumps. This requires excellent and easily accessible support after discharge.

### Intra-articular analgesia

Intra-articular injection with bupivacaine and morphine at the end of surgery provides useful pain control and reduces morphine consumption in the first 24 h after major shoulder surgery.<sup>12</sup> A standard epidural kit can be used by the surgeon to insert a catheter into the subacromial bursa at the end of the procedure. A continuous postoperative intra-articular infusion of local anaesthetic can then be used to provide analgesia of the joint, particularly after arthroscopic surgery. However, analgesia can be disappointing compared with other techniques and dilution of local anaesthetic may be a significant factor in the reduced efficacy. The technique may be more effective if prilocaine and epinephrine are injected into the subacromial bursa before operation and then maintained after operation with a ropivacaine infusion.<sup>13</sup>

### Suprascapular nerve block

Suprascapular nerve block can be a useful local analgesic supplement where interscalene block is either not technically possible or contraindicated. The technique only blocks a proportion of the afferent input from the shoulder joint and is therefore substantially inferior to the interscalene block.<sup>14</sup> In addition, it will not provide any cutaneous analgesia; therefore, it is usually combined with local anaesthetic infiltration of the incision site. The nerve is easily blocked, usually with the patient in the sitting position, with

needle insertion site ~1 cm above the mid point of the scapular spine, at an angle perpendicular to the skin. It is best performed with a peripheral nerve stimulator that will elicit contraction of muscles in the scapular area (supraspinatus, infraspinatus). The nerve is blocked with 10 ml of local anaesthetic solution and a catheter for continuous postoperative infusion can also be inserted if required.

### Choice of technique

Whichever option is chosen, regional anaesthesia techniques can significantly reduce postoperative pain, which is often severe and limits early rehabilitation.<sup>15</sup> They reduce opioid requirements, increase patient satisfaction and has the potential to improve functional outcome. Interscalene block, particularly when continued as an infusion, is superior to other regional techniques, and i.v. PCA, and should be considered the technique of choice for the large majority of patients having shoulder surgery.

### Acknowledgements

With grateful thanks to Dr Robert Whitaker for producing the illustrations to accompany this paper.

### References

1. Fombon FN, Thompson JP. Anaesthesia for the adult patient with rheumatoid arthritis. *Contin Edu Anaesth Crit Care Pain* 2006; **6**: 235–9
2. Silverstein WB, Moin US, Brown AR. Interscalene block with a nerve stimulator: a deltoid motor response is a satisfactory endpoint for successful block. *Reg Anaesth Pain Med* 2000; **25**: 356–9
3. Meier G. Interscalene techniques of interscalene blocks. In: *Peripheral Regional Anesthesia, Chapter 2*. Germany: Georg Thieme Verlag, 2006; 14–6
4. Benumof JL. Permanent loss of cervical spinal cord function associated with interscalene block performed under general anaesthesia. *Anesthesiology* 2000; **93**: 1541–4
5. Marhofer P, Greher M, Kapral S. Ultrasound guidance in regional anaesthesia. *BJA* 2005; **94**: 7–17
6. Urmev WF, Grossi P. Percutaneous electrode guidance: a non-invasive technique for prelocation of peripheral nerves to facilitate peripheral plexus or nerve block. *Reg Anaesth Pain Med* 2002; **27**: 261–7
7. Pohl A, Cullen DJ. Cerebral ischaemia during shoulder surgery in the upright position: a case series. *J Clin Anesth* 2005; **17**: 463–9
8. Campagna JA, Carter C. Clinical relevance of the Bezold-Jarisch reflex. *Anesthesiology* 2003; **98**: 1250–60
9. Borgeat A, Ekatothramis G, Kalberer F, Benz C. Acute and nonacute complications associated with interscalene block and shoulder surgery: a prospective study. *Anesthesiology* 2001; **95**: 875–80
10. Klein SM, Grant SA, Greengrass RA et al. Interscalene brachial plexus block with a continuous catheter insertion system and disposable infusion pump. *Anaesth Analg* 2000; **91**: 1473–8
11. Borgeat A, Tewes E, Biasca N, Gerber C. Patient-controlled interscalene analgesia with ropivacaine after major shoulder surgery: PCIA vs PCA. *BJA* 1998; **81**: 603–5

12. Tetzlaff JE, Brems J, Digler J. Intraarticular morphine and bupivacaine reduces postoperative pain after rotator cuff repair. *Reg Anaesth Pain Med* 2000; **25**: 611–4
13. Axelsson K, Nordenson U, Johanson E, Rawal N, Ekback G, Lidegran G, Gupta A. Patient-controlled regional analgesia with ropivacaine after arthroscopic subacromial decompression. *Acta Anaesthesiologica Scandinavica* 2003; **47**: 993–1000
14. Singelyn F, Lhotel L, Fabre B. Pain relief after arthroscopic shoulder surgery: a comparison of intra-articular analgesia, suprascapular nerve block and interscalene brachial plexus block. *Anesth Analg* 2004; **99**: 589–92
15. Ilfeld BM, Wright TW, Enneking FK, Morey TE. Joint range of motion after total shoulder arthroplasty with and without a continuous interscalene nerve block: a retrospective, case-control study. *Reg Anaesth Pain Med* 2005; **30**: 429–33

Please see multiple choice questions 1–3