

# Prophylactic nipple-sparing mastectomy with immediate breast reconstruction: results of a French prospective trial

G. Houvenaeghel<sup>1,\*</sup>, M. Cohen<sup>2</sup>, M. A. Dammacco<sup>3</sup>, F. D'Halluin<sup>4</sup>, C. Regis<sup>5</sup>, M. Gutowski<sup>6</sup>, O. Acker<sup>7</sup>, M. Fournier<sup>8</sup>, M. Bannier<sup>2</sup>, A. Lusque<sup>9</sup>, and E. Jouve<sup>10</sup>, on behalf of the MAPAMc trial group

<sup>1</sup>Department of Surgical Oncology, Paoli Calmettes Institute and Centre de Recherche en Cancérologie de Marseille (CRCM), Aix-Marseille University, Marseille, France

<sup>2</sup>Department of Surgical Oncology, Paoli Calmettes Institute, Marseille, France

<sup>3</sup>Department of Surgical Oncology, Centre Léon Bérard, Lyon, France

<sup>4</sup>Surgery Department, L'Établissement Rennais du Sein, Centre Hospitalier Privé St Grégoire, St Grégoire, France

<sup>5</sup>Department of Surgical Oncology, Centre Oscar Lambret, Lille, France

<sup>6</sup>Department of Surgical Oncology, Institut du Cancer de Montpellier Val d'Aurelle, Montpellier, France

<sup>7</sup>Surgery Department, Pôle Santé Léonard de Vinci, Chambray les Tours, France

<sup>8</sup>Department of Surgical Oncology, Institut Bergonie, Bordeaux, France

<sup>9</sup>Department of Biostatistics, Institut Claudius Regaud, Institut Universitaire du Cancer de Toulouse – Oncopole, Toulouse, France

<sup>10</sup>Department of Surgical Oncology, Institut Claudius Regaud, Institut Universitaire du Cancer de Toulouse – Oncopole, Toulouse, France

Other members of the MAPAMc trial group are co-authors of this study and are listed under the heading Collaborators

\*Correspondence to: Department of Surgical Oncology, Paoli Calmettes Institute and CRCM, CNRS, INSERM, Aix-Marseille University, 232 Boulevard de Sainte Marguerite, 13009 Marseille, France (e-mail: houvenaeghel@ipc.unicancer.fr)

## Abstract

**Background:** Nipple-sparing mastectomy (NSM) with immediate breast reconstruction (IBR) is used increasingly when performing a prophylactic mastectomy. Few prospective studies have reported on complication rates. This complementary trial to the French prospective multicentre MAPAM trial aimed to evaluate the nipple–areola complex (NAC) necrosis rate in prophylactic NSM with IBR.

**Methods:** Patient characteristics and surgical data were recorded. Morbidity after prophylactic NSM with a focus on NAC necrosis was analysed.

**Results:** Among 59 women undergoing prophylactic NSM, 19 (32 per cent) of the incisions were partly on the NAC. Reconstructions were performed with 46 definitive implants and 13 expanders. The crude rate of postoperative complications was 25 per cent (15 patients). Complete NAC necrosis was reported in two women (3 per cent) and partial or total necrosis in nine (15 per cent). No NAC resection was necessary. Median BMI was lower in women with total or partial NAC necrosis compared with the others (20.0 versus 21.3 kg/m<sup>2</sup> respectively;  $P = 0.034$ ).

**Conclusion:** Results of this prospective study confirm that prophylactic NSM with IBR is associated with a low risk of total NAC necrosis.

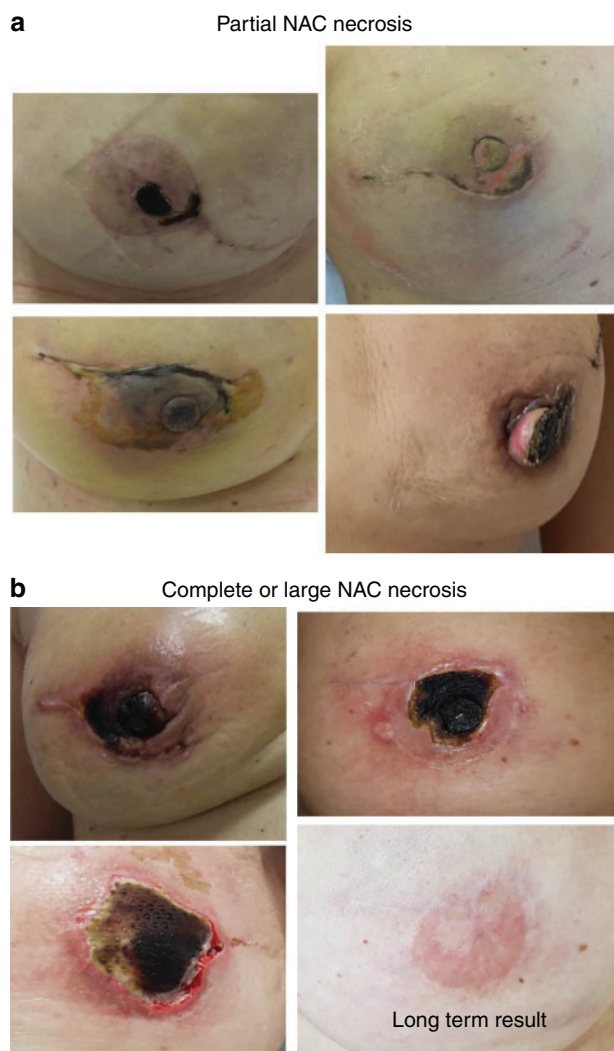
## Introduction

Several publications have shown the benefit of prophylactic or risk-reducing nipple-sparing mastectomy (NSM) in high-risk patients<sup>1–4</sup>, with a 90 per cent reduction in breast cancer risk<sup>1</sup>. Studies of NSM have in general reported better aesthetic results and quality of life than that observed after skin-sparing mastectomy<sup>5–7</sup>. NSM with immediate breast reconstruction (IBR) is used increasingly as a procedure for prophylactic mastectomy, and is also an acceptable option for breast cancer surgery<sup>8–11</sup>. Consequently, the demand for NSM by patients is increasing, and the procedure is frequently offered by surgeons, for both risk reducing and therapeutic mastectomy<sup>12,13</sup>. Few prospective studies have, however, evaluated the complication rates and oncological outcomes of NSM<sup>14</sup>, and therapeutic NSM remains even more controversial than prophylactic NSM.

The MAPAM trial is a French multicentre prospective study evaluating the local recurrence rate for therapeutic NSM (clinical trial registration number NCT02311959). Here, in a complementary study of the MAPAM trial (MAPAMc) the aim was to evaluate the nipple–areola complex (NAC) necrosis rate following prophylactic NSM.

## Methods

Patients planned for prophylactic NSM with IBR were included prospectively in this multicentre prospective cohort study. Prophylactic NSM was proposed for patients with gene mutations (BRCA1, BRCA2, PALB2) or considered at high risk of breast cancer according to family history. Included patients underwent a physical examination and imaging (mammography and



**Fig. 1** Nipple-areola complex complications

**a** Partial and **b** complete or large nipple-areola complex (NAC) necrosis.

ultrasonography and/or MRI) and showed no signs of invasive cancer or ductal carcinoma *in situ* (DCIS) within 6 months preceding surgery.

Patient characteristics, including bodyweight and length, BMI, breast size (cup), menopausal status, history of diabetes, obesity, hypertension, tobacco use, mutation status (*BRCA1/2* or *PALB2*) were collected. Surgical data collected included duration of surgery, length of hospital stay, locoregional anaesthesia, incision localization for NSM, retroareolar thickness after biopsy, breast weight and type of IBR. Pathological analyses of breast and nipple biopsies were also recorded, as were specific 90-day postoperative complications. NAC complications were classified as follows: no necrosis, partial necrosis and complete necrosis with NAC resection (Fig. 1). The National Cancer Institute (NCI) Common Terminology Criteria for Adverse Events version 4.0 classification was used to evaluate complications.

### Statistical analysis

The main objective was to demonstrate that the NAC complete necrosis rate was lower than 15 per cent in NSM with IBR. A sample size of 60 women undergoing prophylactic NSM would be necessary for 80 per cent power to demonstrate this hypothesis at a one-sided  $\alpha$  level of 5 per cent exact method) if the true rate was

**Table 1** Patient characteristics

	No. of patients (n=59)
<b>Age at inclusion (years)*</b>	42 (24–66)
<40	23 (39)
≥40	36 (61)
<b>Imaging</b>	
Mammography	40 (68)
Ultrasonography	40 (68)
MRI	42 (71)
<b>Tobacco use</b>	
Never smoked	25 (54)
Former smoker	8 (17)
Current smoker	13 (28)
Missing	13
<b>Diabetes</b>	1 (2)
<b>Previous cancer</b>	
Breast	19 (32)
Ovary	2 (3)
<b>Previous breast surgery</b>	6 (10)
<b>Reason for surgery</b>	
BRCA mutation	42 (74)
High risk	17 (30)
Missing	2
<b>Bodyweight (kg)*</b>	57 (47–80)
BMI (kg/m <sup>2</sup> )*	20.8 (17.3–30.9)
Missing	1
<b>Breast size (cup)</b>	
A–B	26 (59)
C–D	18 (41)
Missing	15
<b>Breast weight (g)*</b>	240 (127–907)
Missing	22

Values in parentheses are percentages unless indicated otherwise; \*values are median (range).

5 per cent. Descriptive statistics were presented as median (range) values for quantitative variables, and as frequencies with percentages for qualitative variables. The number of missing observations are shown, but not included in the percentage calculation. Comparisons between groups were assessed using  $\chi^2$  or Fisher's exact tests for qualitative variables and the Mann-Whitney *U* test for quantitative variables. The number and percentage of NAC complete necrosis was calculated, and its upper one-sided 95 per cent confidence limit was estimated using the binomial exact method.

All statistical analyses were performed using Stata<sup>®</sup> software version 13 (StataCorp, College Station, TX, USA).

## Results

Between March 2015 and November 2017, 61 prophylactic NSM procedures were included from 13 French centres; two patients were subsequently excluded (retraction of consent with no surgery performed in both cases). Patients and surgical characteristics of the 59 prophylactic NSM operations included are reported in Tables 1 and 2. Median age was 42 (range 24–66) years and 23 women (39 per cent) were aged less than 40 years. *BRCA* mutation status was recorded for 42 women, and 17 were at high risk.

All except four women (7 per cent) had radiological breast examinations (mammography, ultrasonography and/or MRI) 6 months before inclusion, including MRI for 42 patients.

## Surgery

### Duration of surgery

Median duration of surgery was 211 min (Table 2). Factors significantly associated with long duration of surgery (median or above)

**Table 2 Surgical details**

	No. of patients (n=59)
<b>Type of incision</b>	
NAC	14 (24)
Radial	12 (20)
NAC + radial	5 (8)
Previous scar	2 (3)
Inferior mammary fold	2 (3)
Circular NAC + graft	1 (2)
Axillar	3 (5)
External mammary fold	12 (20)
Other	8 (14)
<b>Type of implant</b>	
Definitive	46 (78)
Expander	13 (22)
<b>Muscular coverage</b>	
Complete	36 (71)
Missing	8
<b>Duration of surgery (min)*</b>	211 (42–390)
Missing	4
<b>NAC biopsy taken</b>	36 (61)
<b>Length of stay (days)*</b>	6 (3–13)
<b>Locoregional anaesthesia</b>	23 (43)
Missing	6
<b>Antibiotics</b>	15 (29)
Missing	1
<b>NAC necrosis</b>	
Partial	7 (12)
Total	2 (3)
<b>Cicatrization complication</b>	6 (10)
Missing	1
<b>Pain</b>	19 (33)
Missing	1

Values in parentheses are percentages unless indicated otherwise; \*values are median (range). NAC, nipple–areola complex.

were breast cup size A–B versus C–D ( $P=0.047$ ), age under 40 years ( $P=0.001$ ), definitive breast implant versus expander ( $P=0.003$ ), no partial NAC incision ( $P=0.033$ ) and total muscular coverage of implant ( $P=0.003$ ) (Table 3).

### Type of incision

Incisions for prophylactic NSM were partly on the NAC for 19 of the 59 women (32 per cent) and outside the breast or in the periphery of the breast in 17 (29 per cent) (12 external mammary fold, 3 axillar, 2 inferior mammary fold incisions) (Table 2). Radial breast incisions were used for 17 patients (29 per cent), and included 12 radial incisions alone and 5 combined with partial NAC incision.

### Type of implant

All reconstructions were implant-based: 46 definitive implants (78 per cent) and 13 with expanders (22 per cent). Implant sizes were 280 (range 180–470) and 150 (100–400) ml for definitive implants and expanders respectively. Complete coverage of implant was possible in 70.6 per cent of patients (36 of 51) (Table 2). Mastectomy specimen weight was significantly higher in patients with expanders compared with those with definitive implants: median 343 (range 194–907) versus 227.5 (127–736) g respectively ( $P=0.003$ ).

### Histology

No cancers were found on final pathology of retro-NAC biopsies. Final pathology of the surgical specimen showed breast cancer in three women: one DCIS (grade 2, multifocal) and two ductal invasive cancers (10 and 5 mm in size, both grade 2, without lymphovascular invasion and with positive endocrine receptors, 1 with a

Her2 amplification and 1 without a Her2 amplification, respectively).

### Length of stay

Median length of hospital stay was 6 days. Factors associated with a longer length of stay were higher breast weight ( $P=0.075$ ), lower age ( $P=0.018$ ) and high rate of complete muscular coverage of implant ( $P=0.001$ ) (Table 4).

### Complications

The crude rate of postoperative complications was 25 per cent (15 of 59 women). Five haematomas (2 grade 1, 2 grade 2, and 1 grade 3), five infectious complications (3 grade 1, 1 grade 3, and 1 grade 4), nine NAC necrosis (7 partial, 2 complete), and two patients with skin flap problems. For six patients (10 per cent), impaired wound healing was observed (Table 2). The only factor significantly associated with a wound-healing complication was breast cup size C–D versus A–B ( $P=0.019$ ). Nineteen patients (33 per cent) reported postoperative pain. The only factor significantly associated with pain was age 40 years or above ( $P=0.043$ ): 15 of the 19 women with pain (79 per cent) were aged 40 years or more versus 20 of the 39 (51 per cent) without postoperative pain.

### Nipple–areola complex necrosis

Complete NAC necrosis was reported in two patients (3 per cent). Partial or complete necrosis was reported in 5 of the 46 women (11 per cent) with a definitive breast implant and in 4 of the 13 (31 per cent) with an expander ( $P=0.097$ ). Factors related to partial or complete NAC necrosis are shown in Table 5. Six NAC complications (1 complete, 5 partial) occurred during the first 24 months of inclusion in the study and three (1 complete, 2 partial) during the following 9 months of inclusion. In all of these patients resolution was achieved without NAC resection. For five patients (1 complete, 4 partial) this took 2–3 days. Longer resolution times were also observed, ranging from 11 days (complete NAC necrosis), 30 days (2 partial necrosis) to more than 90 days (1 partial necrosis).

### Discussion

This prospective multicentre trial found a low rate (3 per cent) of complete NAC necrosis, clearly lower than the 5 per cent used to calculate the sample size. Seven of the 59 patients were observed to have partial necrosis (12 per cent). Partial or total NAC necrosis was significantly associated with lower BMI and smaller breast size. The assumption is that a low thickness of subcutaneous fat tissue in women with low BMI and traction injury during surgery owing to the smaller working space in patients with small breast could explain the higher rate of partial or total necrosis.

In the literature<sup>15–19</sup>, NAC necrosis rates between 0 and 5.6 per cent have been described. In the prospective study by Sarfati and colleagues<sup>14</sup>, of 63 robotic prophylactic NSM procedures performed in 33 patients with prepectoral implant-based IBR, there were no cases of mastectomy skin flap or NAC necrosis, but three infections occurred (9 per cent) with implant loss in one patient. This indicates some advantage of this evolving technique in preserving the NAC.

Flap necrosis rates (0 per cent to 19.5 per cent) are frequently higher than NAC necrosis rates<sup>14,16–19</sup>. Headon and co-workers<sup>20</sup> conducted a pooled analysis of 12 358 NSMs to assess complications. The overall complication rate was 22.3 per cent and the nipple necrosis rate was 5.9 per cent. In a subgroup analysis the

Table 3 Factors associated with duration of surgery

	Duration of surgery		p <sup>†</sup>
	Less than median	Median or above	
<b>Tobacco use</b>			0.818
None	13 (52)	10 (56)	
Former or current smoker	12 (48)	8 (44)	
<b>Breast cup size</b>			0.047
A–B	9 (43)	16 (73)	
C–D	12 (57)	6 (27)	
<b>Age (years)*</b>	46 (25–66)	38.5 (24–59)	0.006 <sup>‡</sup>
<40	4 (15)	16 (57)	0.001
≥40	23 (85)	12 (43)	
<b>Type of implant</b>			0.003
Definitive	16 (59)	26 (93)	
Expander	11 (41)	2 (7)	
<b>NAC incision</b>			0.033
No	15 (56)	23 (82)	
Yes	12 (44)	5 (18)	
<b>Complete muscular coverage</b>			0.003
No	11 (55)	4 (15)	
Yes	9 (45)	23 (85)	
<b>Weight (kg)*</b>	57 (48–80)	55 (47–69)	0.308 <sup>‡</sup>
<b>BMI (kg/m<sup>2</sup>)*</b>	21.1 (19.3–30.9)	20.6 (17.3–28.0)	0.226 <sup>‡</sup>
<b>Breast weight (g)*</b>	240 (174–907)	259 (127–736)	0.754 <sup>‡</sup>

Values in parentheses are percentages unless indicated otherwise;

\*values are median (range). NAC, nipple–areola complex.

<sup>†</sup> $\chi^2$  or Fisher's exact test, except,

<sup>‡</sup>Mann–Whitney *U* test.

Table 4 Factors associated with length of hospital stay

	Length of stay		p <sup>†</sup>
	Less than median	Median or above	
<b>Tobacco use</b>			0.139
None	10 (43)	15 (65)	
Former or current smoker	13 (57)	8 (35)	
<b>Breast cup size</b>			0.329
A–B	12 (52)	14 (67)	
C–D	11 (48)	7 (33)	
<b>Age (years)*</b>	46 (25–66)	40 (24–59)	0.018 <sup>‡</sup>
<40	7 (27)	16 (48)	0.092
≥40	19 (73)	17 (52)	
<b>Type of implant</b>			0.151
Definitive	18 (69)	28 (85)	
Expander	8 (31)	5 (15)	
<b>NAC incision</b>			0.725
No	17 (65)	23 (70)	
Yes	9 (35)	10 (30)	
<b>Complete muscular coverage</b>			0.001
No	12 (52)	3 (11)	
Yes	11 (48)	25 (89)	
<b>Weight (kg)*</b>	55.5 (48–80)	59 (47–75)	0.598 <sup>‡</sup>
<b>BMI (kg/m<sup>2</sup>)*</b>	20.4 (18.9–30.9)	21.3 (17.3–28.0)	0.511 <sup>‡</sup>
<b>Breast weight (g)*</b>	230 (127–481)	298 (140–907)	0.075 <sup>‡</sup>

Values in parentheses are percentages unless indicated otherwise;

\*values are median (range). NAC, nipple–areola complex.

<sup>†</sup> $\chi^2$  or Fisher's exact test, except,

<sup>‡</sup>Mann–Whitney *U* test.

authors confirmed the importance of surgeon confidence in the technique practised, highlighting the importance of a specialized surgical team for this type of operation. In a systematic review by Agha et al.<sup>21</sup>, partial or total NAC necrosis rates were, however, clearly higher at 15.0 per cent (116 of 773), with a 3.4 per cent (26 of 773) skin flap necrosis rate and an overall complication rate of 22.6 per cent (175 of 773).

Different types of incision have been described for NSMs by individual surgeons or institutions<sup>22–27</sup>, as was also observed in the present study. In the review by Endara and colleagues<sup>25</sup>, the most commonly used incision was a radial approach (46 per cent) followed by the periareolar (27 per cent) and inframammary (21 per cent) incision. The lowest rates of NAC necrosis were reported for incisions involving less of the nipple circumference (radial

Table 5 Factors associated with nipple–areola complex necrosis

	NAC necrosis		p†
	None	Partial or total	
<b>Tobacco use</b>			1.000
None	20 (54)	5 (56)	
Former or current smoker	17 (46)	4 (44)	
<b>Breast cup size</b>			0.682
A–B	21 (57)	5 (71)	
C–D	16 (43)	2 (29)	
<b>Age (years)*</b>	40 (24–59)	46 (37–66)	0.112‡
<40	20 (40)	3 (33)	1.000
≥40	30 (60)	6 (67)	
<b>Type of implant</b>			0.097
Definitive	41 (82)	5 (56)	
Expander	9 (18)	4 (44)	
<b>NAC incision</b>			0.131
No	36 (72)	4 (44)	
Yes	14 (28)	5 (56)	
<b>Complete muscular coverage</b>			0.102
No	10 (24)	5 (56)	
Yes	32 (76)	4 (44)	
<b>Weight (kg)*</b>	58.5 (47–80)	53 (48–63)	0.012‡
<b>BMI (kg/m<sup>2</sup>)*</b>	21.3 (17.3–30.9)	20.0 (19.1–21.8)	0.034‡
<b>Breast weight (g)*</b>	248 (130–907)	225 (127–393)	0.330‡

Values in parentheses are percentages unless indicated otherwise;

\*values are median (range). NAC, nipple–areola complex.

† $\chi^2$  or Fisher's exact test, except,

‡Mann–Whitney *U* test.

In this prospective multicentre trial evaluating the nipple–areola complex (NAC) necrosis rate in 59 women undergoing prophylactic nipple-sparing mastectomy with immediate breast reconstruction, complete NAC necrosis was reported in two patients (3 per cent). The only factor significantly associated with a wound-healing complication was cup size C–D versus A–B.

incision, 8.8 per cent; inframammary, 9.1 per cent; periareolar/circumareolar, 17.8 per cent; transareolar, 81.8 per cent)<sup>25</sup>. An increased risk of NAC necrosis associated with periareolar incisions (4 of 42, 10 per cent) was also reported by Salgarello *et al.*<sup>12</sup>. In the NSM consensus guideline<sup>28</sup>, the panel considered the location of the incision to be a risk factor for severe mastectomy flap necrosis. This was supported by a review of 500 NSMs,<sup>19</sup> which showed a strong correlation between mastectomy flap necrosis and the use of periareolar incisions. In contrast, the inframammary approach was associated with a lower risk of mastectomy flap necrosis<sup>19</sup>. In study of Roh and co-workers<sup>29</sup>, the inframammary approach (58 NSMs) had a significant impact on postoperative complications compared with non-inframammary incisions (83 NSMs), with a lower skin necrosis rate for the inframammary approach ( $P=0.024$ ). This approach also had superior aesthetic results and better patient satisfaction. In another review<sup>30</sup>, incision placement away from the nipple resulted in the lowest rates of ischaemic nipple complications and the best cosmetic outcomes. Placing the incision away from the nipple, with preservation of a 2–3-mm rim of tissue around the nipple bundle, combined with careful patient selection were the most significant variables in helping to lower complication rates.

Three patients (5 per cent) in the present study were found to have occult cancer despite preoperative physical examination and extensive imaging. This is similar to findings in other series in literature, with rates of occult cancer of 0.5–11 per cent observed after prophylactic mastectomy<sup>31</sup>. In the American Society of Breast Surgeons NSM registry<sup>32</sup>, NSM procedures were performed for indications of breast cancer ( $n=833$ ) and prophylaxis ( $n=1102$ ) using multiple incisions, dissection techniques and reconstruction, with an overall patient satisfaction rate of 95 per cent, 4.4 per cent flap infection rate, and 4.5 per cent NAC complication rate. In this registry, no clinically significant variation in breast characteristics (size, ptosis, incision, reconstruction type)

was noted between NSM for breast cancer or that with a prophylactic aim.

Finally, in the NSM consensus<sup>28</sup>, the panel recommended unanimously NSM in the risk-reducing setting. This latter indication is now well established in clinical practice<sup>21,28,33–35</sup>. Results of the present prospective study confirm that prophylactic NSM with IBR is associated with a low risk of complications and NAC necrosis. Results of the principal part of MAPAM trial report on the oncological safety of therapeutic NSM.

## Collaborators

Other members of the MAPAMc trial group: C. Bouteille (Clinique Mutualiste Chirurgicale, Saint Etienne, France), W. Gertych (Surgery Department, Centre Hospitalier Lyon Sud, Pierre Benite, France), M. Baron (Clinique Mathilde, Rouen, France), N. Leymarie (Department of Surgical Oncology, Institut Gustave Roussy, Villejuif, France), P. Bertrand (Surgery Department, Clinique Clementville, Montpellier, France).

**Disclosure.** The authors declare no conflict of interest.

## References

- Hartmann LC, Schaid DJ, Woods JE, Crotty TP, Myers JL, Arnold PG *et al.* Efficacy of bilateral prophylactic mastectomy in women with a family history of breast cancer. *N Engl J Med* 1999;**340**: 77–84
- Meijers-Heijboer H, van Geel B, van Putten WLJ, Henzen-Logmans SC, Seynaeve C, Menke-Pluymers MBE *et al.* Breast cancer after prophylactic bilateral mastectomy in women with a BRCA1 or BRCA2 mutation. *N Engl J Med* 2001;**345**:159–164
- Hartmann LC, Sellers TA, Schaid DJ, Frank TS, Soderberg CL, Sitta DL *et al.* Efficacy of bilateral prophylactic mastectomy in

- BRCA1 and BRCA2 gene mutation carriers. *J Natl Cancer Inst* 2001; **93**:1633–1637
4. Contant CME, Menke-Pluijmers MBE, Seynaeve C, Meijers-Heijboer EJ, Klijn JGM, Verhoog LC et al. Clinical experience of prophylactic mastectomy followed by immediate breast reconstruction in women at hereditary risk of breast cancer (HB(O)C) or a proven BRCA1 and BRCA2 germ-line mutation. *Eur J Surg Oncol* 2002; **28**:627–632
  5. Wei CH, Scott AM, Price AN, Miller HC, Klassen AF, Jhanwar SM et al. Psychosocial and sexual well-being following nipple-sparing mastectomy and reconstruction. *Breast J* 2016; **22**:10–17
  6. Moyer HR, Ghazi B, Daniel JR, Gasgarth R, Carlson GW. Nipple-sparing mastectomy: technical aspects and aesthetic outcomes. *Ann Plast Surg* 2012; **68**:446–450
  7. Gerber B, Krause A, Dieterich M, Kundt G, Reimer T. The oncological safety of skin sparing mastectomy with conservation of the nipple-areola complex and autologous reconstruction: an extended follow-up study. *Ann Surg* 2009; **249**:461–468
  8. Smith BL, Tang R, Rai U, Plichta JK, Colwell AS, Gadd MA et al. Oncologic safety of nipple-sparing mastectomy in women with breast cancer. *J Am Coll Surg* 2017; **225**:361–365
  9. Li M, Chen K, Liu F, Su F, Li S, Zhu L. Nipple sparing mastectomy in breast cancer patients and long-term survival outcomes: an analysis of the SEER database. *PLoS One* 2017; **12**:e0183448
  10. Muller T, Baratte A, Bruant-Rodier C, Bodin F, Mathelin C. Oncological safety of nipple-sparing prophylactic mastectomy: a review of the literature on 3716 cases. *Ann Chir Plast Esthet* 2018; **63**:e6–e13
  11. Munhoz AM. Outcome evaluation after 2023 nipple-sparing mastectomies: our experience. *Plast Reconstr Surg* 2017; **140**:348e–349e
  12. Salgarello M, Visconti G, Barone-Adesi L. Nipple-sparing mastectomy with immediate implant reconstruction: cosmetic outcomes and technical refinements. *Plast Reconstr Surg* 2010; **126**:1460–1471
  13. Qureshi AA, Odom EB, Parikh RP, Myckatyn TM, Tenenbaum MM. Patient-reported outcomes of aesthetics and satisfaction in immediate breast reconstruction after nipple-sparing mastectomy with implants and fat grafting. *Aesthet Surg J* 2017; **37**:999–1008
  14. Sarfati B, Struk S, Leymarie N, Honart JF, Alkhashnam H, Tran de Fremicourt K et al. Robotic prophylactic nipple-sparing mastectomy with immediate prosthetic breast reconstruction: a prospective study. *Ann Surg Oncol* 2018; **25**:2579–2586
  15. Petit JY, Veronesi U, Orecchia R, Rey P, Martella S, Didier F et al. Nipple sparing mastectomy with nipple areola intraoperative radiotherapy: one thousand and one cases of a five years experience at the European institute of oncology of Milan (EIO). *Breast Cancer Res Treat* 2009; **117**:333–338
  16. de Alcantara Filho P, Capko D, Barry JM, Morrow M, Pusic A, Sacchini VS et al. Nipplesparing mastectomy for breast cancer and risk-reducing surgery: the Memorial Sloan-Kettering Cancer Center experience. *Ann Surg Oncol* 2011; **18**:3117–3122
  17. Peled AW, Foster RD, Stover AC, Itakura K, Ewing CA, Alvarado M et al. Outcomes after total skin-sparing mastectomy and immediate reconstruction in 657 breasts. *Ann Surg Oncol* 2012; **19**:3402–3409
  18. Wagner JL, Fearmonti R, Hunt KK, Hwang RF, Meric-Bernstam F, Kuerer HM et al. Prospective evaluation of the nipple-areola complex sparing mastectomy for risk reduction and for early-stage breast cancer. *Ann Surg Oncol* 2012; **19**:1137–1144
  19. Colwell AS, Tessler O, Lin AM, Liao E, Winograd J, Cetrulo CL et al. Breast reconstruction following nipple-sparing mastectomy: predictors of complications, reconstruction outcomes, and 5-year trends. *Plast Reconstr Surg* 2014; **133**:496–506
  20. Headon HL, Kasem A, Mokbel K. The oncological safety of nipple-sparing mastectomy: a systematic review of the literature with a pooled analysis of 12 358 procedures. *Arch Plast Surg* 2016; **43**:328–338
  21. Agha RA, Al Omran Y, Wellstead G, Sagoo H, Barai I, Rajmohan S et al. Systematic review of therapeutic nipple-sparing versus skin-sparing mastectomy. *BJS Open* 2018; **3**:135–145
  22. Colwell AS, Gadd M, Smith BL, Austen WG. An inferolateral approach to nipple-sparing mastectomy: optimizing mastectomy and reconstruction. *Ann Plast Surg* 2010; **65**:140–143
  23. Stolier AJ, Levine EA. Reducing the risk of nipple necrosis: technical observations in 340 nipple-sparing mastectomies. *Breast J* 2013; **19**:173–179
  24. Salibian AH, Harness JK, Mowlds DS. Inframammary approach to nipple-areola-sparing mastectomy. *Plast Reconstr Surg* 2013; **132**:700e–708e
  25. Endara M, Chen D, Verma K, Nahabedian MY, Spear SL. Breast reconstruction following nipple-sparing mastectomy: a systematic review of the literature with pooled analysis. *Plast Reconstr Surg* 2013; **132**:1043–1054
  26. Crowe JP, Patrick RJ, Yetman RJ, Djohan R. Nipple-sparing mastectomy update: one hundred forty-nine procedures and clinical outcomes. *Arch Surg* 2008; **143**:1106–1110
  27. Donovan CA, Harit AP, Chung A, Bao J, Giuliano AE, Amersi F. Oncological and surgical outcomes after nipplesparing mastectomy: do incisions matter? *Ann Surg Oncol* 2016; **23**:3226–3231
  28. Weber WP, Haug M, Kurzeder C, Bjelic-Radisic V, Koller R, Reitsamer R et al. Oncoplastic Breast Consortium consensus conference on nipple sparing mastectomy. *Breast Cancer Res Treat* 2018; **172**:523–537
  29. Roh TS, Kim JY, Jung BK, Jeong J, Ahn SG, Kim YS. Comparison of outcomes between direct-to-implant breast reconstruction following nipple-sparing mastectomy through inframammary fold incision versus noninframammary fold incision. *J Breast Cancer* 2018; **21**:213–221
  30. Ashikari AY, Kelemen PR, Tastan B, Salzberg CA, Ashikari RH. Nipple sparing mastectomy techniques: a literature review and an inframammary technique. *Gland Surg* 2018; **7**:273–287
  31. Yamauchi H, Okawa M, Yokoyama S, Nakagawa C, Yoshida R, Suzuki K et al. High rate of occult cancer found in prophylactic mastectomy specimens despite thorough presurgical assessment with MRI and ultrasound: findings from the Hereditary Breast and Ovarian Cancer Registration 2016 in Japan. *Breast Cancer Res Treat* 2018; **172**:679–687
  32. Mitchell SD, Willey SC, Beitsch P, Feldman S. Evidence based outcomes of the American Society of Breast Surgeons Nipple Sparing Mastectomy Registry. *Gland Surg* 2018; **7**:247–257
  33. Jakub JW, Peled AW, Gray RJ, Greenup RA, Kiluk JV, Sacchini V et al. Oncologic safety of prophylactic nipple-sparing mastectomy in a population with BRCA mutations: a multi-institutional study. *JAMA Surg* 2018; **153**:123–129
  34. Yao K, Liederbach E, Tang R, Lei L, Czechura T, Sisco M et al. Nipple-sparing mastectomy in BRCA1/2 mutation carriers: an interim analysis and review of the literature. *Ann Surg Oncol* 2015; **22**:370–376
  35. Manning AT, Wood C, Eaton A, Stempel M, Capko D, Pusic A et al. Nipple-sparing mastectomy in patients with BRCA1/2 mutations and variants of uncertain significance. *Br J Surg* 2015; **102**:1354–1359