

Surgical treatment of intracerebral haemorrhage

M Shahid Siddique and A David Mendelow

Department of Surgery (Neurosurgery), University of Newcastle upon Tyne, Newcastle upon Tyne, UK

There is at present no clear indication for surgical removal of intracerebral haemorrhage (ICH) in the majority of patients. With deterioration from an initially good level of consciousness, many surgeons would agree that removal is life saving. The question is whether or not surgical removal of clot improves the ultimate outcome in patients who are stable or even improving. Improvement in function is based on the concept of a penumbra around an ICH. There is now mounting evidence that there is a penumbra of functionally impaired, but potentially reversible, neuronal injury surrounding a haematoma. A pro-active approach must, therefore, be maintained in the management of these patients to salvage as much of this brain as possible. Alert patients with small (<2 cm) haematomas and moribund patients with extensive haemorrhage may not require surgical evacuation. Indications for clot removal in patients between these extremes are controversial. Current practice favours surgical intervention in the following situations: (i) superficial haemorrhage, (ii) clot volume between 20–80 ml; (iii) worsening neurological status; (iv) relatively young patients; (v) haemorrhage causing midline shift/raised ICP; and (vi) cerebellar haematomas >3 cm or causing hydrocephalus. A large multicentre prospective randomised controlled trial (International Surgical Trial in Intracerebral Haemorrhage) is currently underway to determine if early clot evacuation will lead to a better neurological outcome in patients with spontaneous supratentorial, non-aneurysmal ICH.

Spontaneous intracerebral haemorrhage (ICH) is common and has devastating consequences^{1,2}, affects a younger age group compared to other forms of stroke and has the highest mortality of all stroke subtypes. More than 50% of patients die and half of the survivors are left severely disabled^{1,3}, with significant personal, social and health service costs.

The treatment of intracerebral haemorrhage remains anecdotal and inconsistent^{4,5}. There is no convincing evidence of benefit from any medical treatment, and the role of surgery remains controversial. There are two reasons for this: (i) the mechanism of neurological damage is poorly understood; and (ii) the prospective randomized controlled clinical trials comparing surgical and medical treatment of ICH have been small and inconclusive⁶.

*Correspondence to:
Prof A D Mendelow,
Department of
Neurosurgery,
Newcastle General
Hospital, Westgate Road,
Newcastle-upon-Tyne
NE4 6BE, UK*

Epidemiology

Accurate epidemiological data on ICH is not available, but various reports put the incidence between 10–44% of all strokes^{1,2}. The incidence is highest in Asians, intermediate in blacks and lowest in whites⁷ (120 per 100 000 in Japan, 17.5 per 100 000 for blacks, and 13.5 per 100 000 for whites). Risk factors include age, hypertension, history of coronary artery disease, previous stroke or TIA, cigarette smoking, alcohol consumption, low serum cholesterol, low dose aspirin and oral contraception⁷. Because ICH generally occurs without warning and as there is little potential to ameliorate the damage after a haemorrhage has occurred, prevention is of great importance. The decrease in incidence of ICH in the 1970s has been attributed, at least in part, to increased detection and treatment of hypertension⁸.

Aetiology and pathophysiology

Intracerebral haemorrhage due to chronic hypertension accounts for about one-half of the cases. The underlying pathology is haemodynamic injury to perforating arteries, 100–400 µm in diameter, which arise directly from much larger trunks to enter the brain at right angles and are end arteries. Whereas the cortical vessels are protected by a thicker smooth muscle layer in the media, a series of bifurcations and collateral vessels, the perforating arteries are subjected directly to changes in blood pressure. The arteries in question include the lenticulostriate arteries, the thalamoperforating arteries, the paramedian branches of the basilar artery and the superior and anterior inferior cerebellar arteries. The pathological lesions may take the form of hyalinosis, lipohyalinosis or focal necrosis and Charcot-Bouchard/miliary aneurysm formation. In a series reported by Wiener⁹, the locations of hypertensive ICH were as follows: 65% were in the basal ganglia, 15% were in the subcortical white matter, 10% were cerebellar and 10% were pontine. A number of other conditions are known to cause ICH. Coagulopathies are responsible for a significant proportion of cases. These may be congenital or acquired disorders of platelets, congenital clotting factor deficiencies or administration of anticoagulants and thrombolytic agents. Amongst the vasculopathies, cerebral amyloid angiopathy (CAA) is becoming an increasingly frequent cause due to the increase in the ageing population. Abuse of illicit drugs, which cause acute hypertension, is another cause of brain haemorrhage. Amphetamine, cocaine, phencyclidine and phenylpropanolamine are the drugs commonly responsible¹⁰. Rarely, ICH can occur following carotid

Table 1 Aetiology of spontaneous ICH

Hypertension	Chronic hypertension is responsible for over 50% of spontaneous cases. Incidence decreasing with better detection and effective treatment of hypertension. Acute hypertension – as may occur in eclampsia (ICH is the most frequent direct cause of death ⁴¹).
Coagulopathies	Reported incidence 10–26% ⁴² . Includes congenital and acquired platelet disorders, congenital clotting factor deficiencies and administration of anticoagulants and thrombolytic agents.
Arteriovenous malformation	Can occur anywhere in the brain.
Aneurysms	Haemorrhage usually located in the Sylvian or the interhemispheric fissures.
Vasculopathies	Cerebral amyloid angiopathy is the most common. The incidence is reported to be 10% in people in their 70s and over 60% in those in their 90s.
Recreational drugs	Including cocaine and amphetamines. They can cause an abrupt and often severe increase in systemic blood pressure.
Post-operative	Rarely, carotid endarterectomy and cardiac surgery can be complicated by ICH. Following craniotomy for excision of AVM, there may be ICH due to 'normal perfusion pressure breakthrough'. Cerebellar haemorrhages have been reported following pterional craniotomy and temporal lobectomy ^{43,44} .
Tumours	More commonly metastatic and pituitary tumours.
CNS infection	Fungal, bacterial and viral infections may be complicated by ICH.
Venous or dural sinus thrombosis	Can lead to ICH because of venous hypertension.
Miscellaneous	ICH has been reported following a migraine attack, strenuous physical exertion and exposure to cold possibly due to a sudden increase in cerebral blood flow.

endarterectomy or cardiac surgery (Table 1). Any ICH may be due to a ruptured arteriovenous malformation. Aneurysms produce ICH in the Sylvian or interhemispheric fissures (Fig. 1). In addition, metastatic and pituitary tumours may present with ICH.

Although it was originally believed that intracerebral haemorrhage is largely a monophasic event¹¹, a number of investigators over the recent years have shown that early haemorrhage growth in patients with intracerebral haemorrhage is common^{12–14}. Serial CT scans obtained at different intervals post ictus have shown an increase in haematoma volume in a varying proportion of patients (3–40%). Factors that have been seen to be associated with haemorrhage growth in the initial post ictus period include a previous history of brain infarction, liver disease, uncontrolled diabetes, elevated systolic blood pressure on admission (195 mmHg), a history of alcohol abuse, coagulation abnormalities (low level of fibrinogen), a large haematoma on initial CT scan, irregular shape of the haematoma, a high peripheral white cell count and elevated

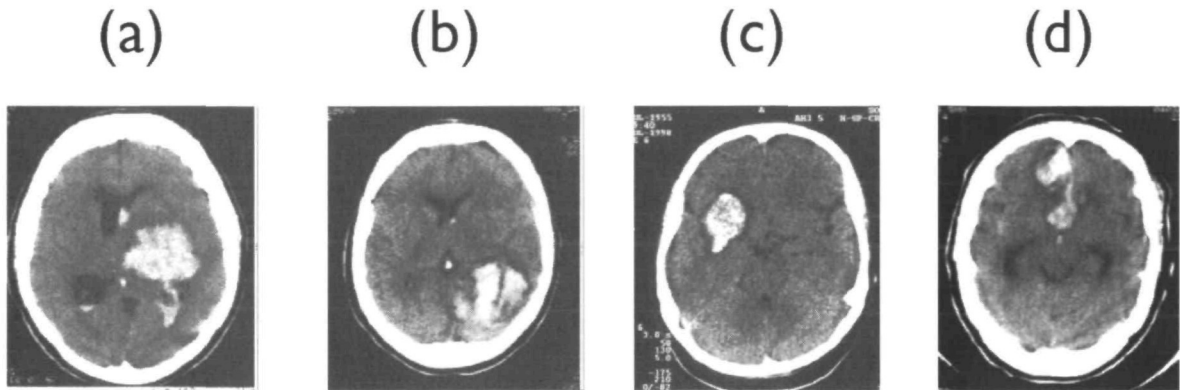


Fig. 1 Typical locations of (a) hypertensive basal ganglia bleed, (b) haemorrhage due to cerebral amyloid angiopathy and (c, d) aneurysmal bleed in the Sylvian and interhemispheric fissures, respectively

body temperature on admission^{13–16}. Murai *et al*¹⁷ have shown that persistent haemorrhage may be detected in patients with acute ICH if CT angiography, performed within 12 h of ictus, shows extravasation of contrast.

Zone of reversible injury surrounding an ICH

Adjacent brain tissue is displaced and compressed by the extravasated blood. Animal models have shown that blood is irritating to the parenchyma, and that there is an area of oedema, ischaemia and haemorrhagic necrosis at the margin of the clot (ischaemic penumbra)¹⁸. The volume of this ischaemic brain may exceed the volume of the haemorrhage several times. Cerebral blood flow studies with single photon emission computed tomography (SPECT) in patients with ICH have been analyzed by the difference based region growing method¹⁹ and have confirmed the presence of a zone of reversible ischaemia around the haematoma in man (Fig. 2). Kano and Nonomura were able to reverse some of the neurological disability in patients with ICH by giving hyperbaric oxygen²⁰. This is strong evidence for the presence of a zone of reversible neuronal injury. Experimental studies in animals have suggested that early removal of the mass lesion can reduce the ischaemic damage²¹. SPECT studies in a series of 14 patients in our department showed greater recovery in the 'ischaemic penumbra' in patients undergoing surgery for evacuation of the haematoma compared with those managed conservatively²². In experimental animals, pre-treatment with the calcium channel blocker nimodipine resulted in a significant

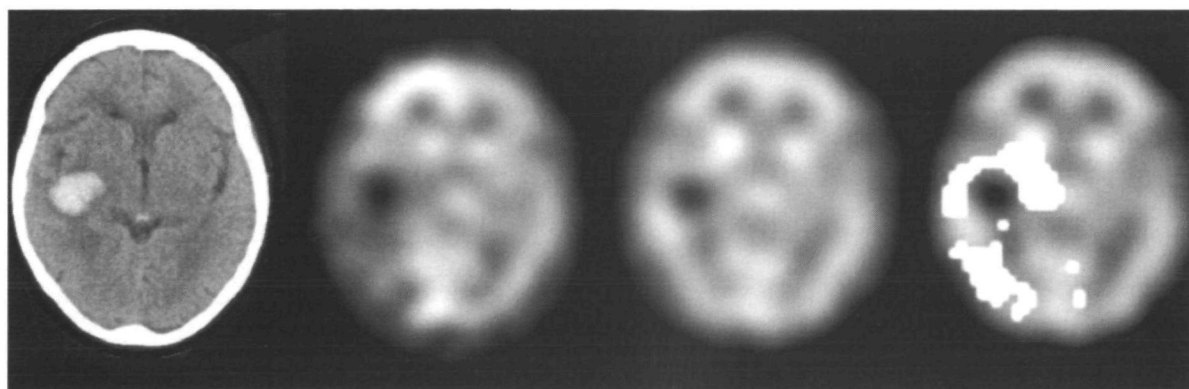


Fig. 2 Zone of reversible ischaemia around an intracerebral haematoma. Spontaneous ICH in a 69-year-old lady. (a) CT scan on day 1 following ictus. (b) SPECT study on day 1. (c) SPECT study on day 28. (d) Analysis of the day 28 SPECT study by the difference based region growing method defines 64.6 cm³ of peri-lesional brain that is absorbing at least more than 15% isotope compared to the same region on the day 1 study.

reduction in the histologically determined volume of ischaemia²³. Similarly, pre-treatment with the N-methyl-D-aspartate (NMDA) receptor antagonist D-(E)-4-(3-phosphonoprop-2-enyl) piperazine-2-carboxylic acid (D-CPP-ene) reduced the amount of oedema at 24 h post ictus²³. In addition, the magnitude of oedema was significantly less in leucopaenic animals exposed to irradiation prior to the experimental ictus²³. This evidence suggests that there are significant therapeutic possibilities in the form of early evacuation of the haematoma and pharmacological neuroprotection that need further investigation.

It is possible that part of the neuronal loss in the penumbra surrounding an ICH is effected by apoptosis. Apoptosis has been shown to be active in neurones in the human brain following cerebral contusion²⁴. This finding has also been reported from Pittsburgh²⁵. It is now widely believed that it is responsible for some cell death in stroke²⁶. In a study that is currently underway, we have seen markers of apoptosis in peri-lesional brain from patients with ICH. Substantial work has already taken place on the development of anti-apoptotic substances²⁶ and these may have a role to play in the treatment of ICH in the future.

The size of the haemorrhage determines the magnitude of rise in the intracranial pressure and the spectrum of clinical consequences ranges from headache through coma and herniation syndromes to death. The site of the bleed determines the type of neurological deficit produced. The deficit can progress over the course of a few hours following the ictus. Epilepsy is a known complication of ICH. Posterior fossa and third ventricular haematomas may obstruct the CSF pathways and produce hydrocephalus.

Management

It is important to determine the underlying aetiology rapidly. A history of hypertension, drug abuse and anticoagulant treatment is important. If a history of hypertension is not available, it may be difficult in the acute state in a patient with high blood pressure to decide whether it is due to previously undetected hypertension or secondary to raised intracranial pressure (ICP) with a Cushing response. Signs of end organ damage (brain, retina, heart and kidneys) can help differentiate the two. CT scanning is rapid and easily demonstrates blood as high density immediately after haemorrhage. Clot volume can be approximated by a modified ellipsoid volume $(a \times b \times c)/2$, where a, b and c are the diameters of the clot in the three dimensions²⁷. MRI scanning takes longer, patient monitoring and ventilation are difficult during the study and appearance of ICH is complicated and highly dependent on the age of the clot²⁸. It is, therefore, not the procedure of choice for the initial study. MRI scanning, however, is invaluable for identifying an underlying neoplastic lesion or an AVM if there are grounds for suspecting such a pathology following the initial CT scan. Routine laboratory evaluation should include coagulation studies. Screening for haematological abnormalities, infectious processes and vasculitides may be necessary in some cases. Angiography should be performed if there is any suspicion of an underlying vascular lesion, particularly if the appearances suggest an aneurysmal bleed, for example in the Sylvian or interhemispheric fissures (Fig. 1c,d).

Medical treatment

As there is reversibly injured brain around the haematoma at the time of the ictus, a pro-active and aggressive approach must be maintained in the management of these patients in the hope of salvaging as much of this brain as possible. Severely affected patients will need comprehensive management in an intensive care or high dependency unit. Intracranial pressure (ICP) may be raised as a result of the presence of a mass lesion, surrounding oedema, the strategic location of the haematoma causing hydrocephalus or due to hypertension. Hypoxia and hypercapnia, very common accompaniments of an impaired conscious level, may exacerbate brain swelling. Hydrocephalus will require treatment with ventriculostomy. Mannitol is helpful in reducing brain oedema in some patients. Very high blood pressure may contribute to haemorrhage growth in the initial phase and needs to be treated but over-treatment can compromise the cerebral perfusion pressure ($CPP = BP - ICP$). It has

Table 2 A spectrum of ICH patients

1	Alert patients with subtle neurological signs and small (< 2 cm) haematomas. Surgery not indicated
2	Indications for surgery between 1 and 3 are controversial. The following patients are more likely to be operated upon: (i) clot volumes between 20–80 ml, (ii) superficial/lobar haemorrhages, and (iii) worsening conscious level/neurological deficit
3	Large haemorrhage with significant neuronal destruction and poor neurological status (GCS < 5). Surgery not indicated

been suggested that the mean arterial pressure should be reduced to pre-morbid level if known or by approximately 20% if unknown²⁹. The value of intracranial pressure monitoring has not yet been established³⁰. In the few reported studies, an elevated ICP was statistically linked with a poor outcome but some patients with ICP in the normal range had a poor outcome. For clinical decision making, ICP monitoring should be considered in patients who are likely to run into problems from suspected elevation of ICP. Some authors recommend the use of prophylactic anticonvulsants for lobar haemorrhages. No benefit has been demonstrated from the use of steroids in ICH³¹. Nevertheless, some surgeons use them if there is significant peri-haemorrhage oedema.

Surgical treatment

There is a wide spectrum of clinical presentation with intracerebral haemorrhage and this determines surgical decision making (Table 2). On the one hand there are patients who present with large haematomas, coma with poor motor responses and unreactive pupils. At the other extreme are those who are orientated with minimal focal deficit and who have small haematomas. It is generally agreed that surgical evacuation is not needed for either of these two extremes. There is little agreement amongst surgeons on the merit of surgical evacuation in patients between these two extremes. Practice is haphazard and inconsistent. The cause for this inconsistency is a lack of objective evidence.

Attempts to evaluate the role of surgery in ICH began with McKissock's trial³², published in 1961, which showed no benefit from operative treatment, but the study was undertaken prior to the advent of CT and randomization was not concealed. More recent observational studies have had variable results^{33,34}. In the largest observational study, Kanaya and Kuroda³⁵ claimed that surgical treatment was beneficial for haematomas between 25–80 ml in volume, when the patients were stuporose. Six other randomized trials have been reported between

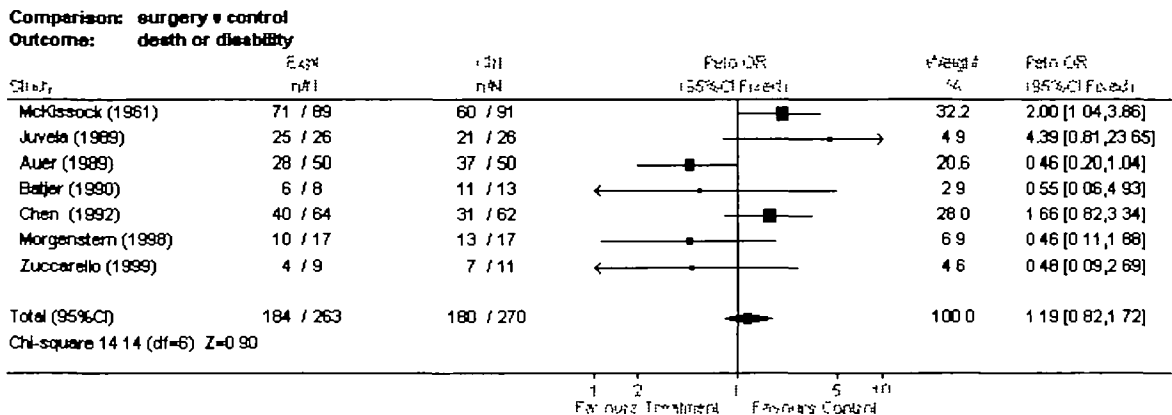


Fig. 3 Meta-analysis of trials comparing surgery with conservative management (from Fernandes *et al*⁶ with permission). Odds ratio of being dead or dependent 6 months after surgical treatment for supratentorial primary intracerebral haemorrhage compared with conservative management (control). The odds ratio of being disabled or dead after 6 months of ictus is 1.19, favouring conservative treatment. The difference is non-significant. This meta-analysis is based on all the reported prospective randomised controlled trials comparing surgery with conservative management for spontaneous supratentorial intracerebral haemorrhage. The seven trials included are McKissock *et al*³², Juvela *et al*³⁵, Auer *et al*³⁶, Batjer *et al*³⁷, Chen *et al*³⁸, Morgenstern *et al*³⁹ and Zuccarello *et al*⁴⁰.

1989–1999. None of these trials was large enough individually to have the statistical power to quantify the risks and benefits of surgery. Meta-analysis of the seven prospective randomized controlled trials shows no significant advantage for either surgical or conservative management (Fig. 3)⁶.

Under these circumstances, most therapeutic decisions have to be individualized, taking into consideration variables such as age, site, side and size of the haematoma, the mechanism of ICH and the presence of accompanying systemic complications. Currently, most neurosurgeons in the UK would operate on patients with a deteriorating conscious level and a worsening neurological deficit. In addition, haematomas between 20–80 ml in volume are more likely to be operated upon as are lobar/superficial haematomas⁴. With cerebellar haemorrhage, although there are again no randomized controlled trials comparing surgical and conservative treatment, there seems to be greater agreement that haematomas greater than 3–4 cm should be operated upon, especially when there is concomitant clinical deterioration or hydrocephalus^{36,37}.

Surgical options consist of: (i) conventional craniotomy and evacuation of the clot under direct vision, with or without the microscope; (ii) stereotactic aspiration through a burr hole – aspiration of a dense clot can be facilitated either by instillation of fibrinolytic agents or by fragmenting it by means of an ultrasonic device³⁸; and (iii) endoscopic surgery³⁹. There is as yet no evidence to suggest the superiority of one

method over another in terms of patient outcome. The haematoma and its wall should be biopsied to rule out tumour, AVM, amyloid angiopathy or other pathology⁴⁰.

International Surgical Trial in Intracerebral Haemorrhage (ISTICH)

The uncertainty in clinical practice and the magnitude of this controversy are the ideal platforms from which to launch a randomized trial to identify the risks and benefits of surgery. There is global consensus amongst neurologists/neurosurgeons about the need for such a trial.

Following a successful pilot phase, a prospective randomized controlled trial is currently underway. The study aims to determine whether a policy of early surgical evacuation of the haematoma in patients with spontaneous supratentorial ICH, will improve outcome compared to a policy of initial conservative treatment. Patients are randomized to 'early surgical evacuation' or 'initial conservative treatment' within 72 h of ictus. Patient selection is based on the 'clinical uncertainty principle' (*i.e.* those in whom the surgeon is uncertain about the possible benefits and risks of operation). This includes those in whom the haemorrhage volume is 20–80 ml with a Glasgow Coma Score of 5–15. Survival and functional outcome will be assessed at 6 months by postal questionnaire. The power calculations based on a 10% improvement in favourable outcomes (from 35%) indicate that 1000 patients will be required to complete the study. Because a number of patients cross over (mainly from initial conservative treatment to surgery), this figure allows for subgroup analysis of the non-crossover patients. It is anticipated that recruitment will continue into the year 2000. At the time of publication 400 patients have been randomized.

Key points for clinical practice

There is mounting evidence that there is a zone of reversible neuronal injury surrounding a haematoma at the time of ictus. A pro-active approach must be maintained in the management of these patients in the hope of salvaging as much of this brain as possible.

Evaluation

- Urgent CT scan. (Ensure stability of vital functions prior to scanning)
- Clot volume $(a \times b \times c)/2$, where a, b and c are the three diameters of the clot

Table 3 Surgical treatment versus medical therapy

Factors that favour surgical removal of the haematoma	Factors that favour medical therapy
Superficial haemorrhage	Large haemorrhage with moribund patient (GCS < 5)
Clot volume between 20–80 ml	Orientated patient with small haematoma (< 2 cm)
Worsening neurological status	
Relatively young patients	
Haemorrhage causing midline shift/raised ICP	
Cerebellar haematomas > 3 cm or causing hydrocephalus	

- Consider contrast infusion in the following situations:
 - * Young patient (< 40 years)
 - * Worsening neurological signs
 - * Non-hypertensive bleed
 - * Atypical appearance/location of the clot
 - * Accompanying subarachnoid haemorrhage

Initial management

- Support vital functions in severely ill patients
- Monitor and treat severe elevations of arterial blood pressure
- Administer anti-epileptic medication if indicated
- Check coagulation status. Correct/reverse abnormalities as indicated
- If mass effect is suspected from CT administer mannitol if not contra-indicated and consider ICP monitoring
- Consider angiography/MRI scanning if there is suspicion of underlying vascular abnormality or tumour

Surgical treatment

In the absence of objective evidence, Table 3 offers a guide. Decisions need to be individualized, based on the patient's neurological status, the size and location of the bleed, the age and state of health of the patient and the wishes of the patient/family. Consider the ISTICH trial if uncertain. At surgery, haematoma/wall biopsies should be taken.

Follow-up

Consider late (3–4 months) MRI/angiogram if there was suspicion of underlying vascular/neoplastic abnormality and initial investigations were negative

Acknowledgements

Any centres interested in the ISTICH trial can obtain further information from the following address: ISTICH Office, Ward 31, North Wing, Newcastle General Hospital, Westgate Road, Newcastle-upon-Tyne, NE4 6BE, UK. Tel: +44 (0) 191 219 5000; Fax: +44 (0) 191 256 3268; E-mail: stich@ncl.ac.uk.

Shahid Siddique is supported by grants from the Stroke Association and the UK Medical Research Council.

References

- 1 Bamford J, Sandercock P, Dennis M, Burn J, Warlow C. A prospective study of acute cerebrovascular disease in the community: the Oxfordshire Community Stroke Project – 1981–86. 2. Incidence, case fatality rates and overall outcome at one year of cerebral infarction, primary intracerebral and subarachnoid haemorrhage. *J Neurol Neurosurg Psychiatry* 1990; 53: 16–22
- 2 Li SC, Schoenberg BS, Wang CC, Cheng XM, Bolis CL, Wang KJ. Cerebrovascular disease in the People's Republic of China. epidemiologic and clinical features. *Neurology* 1985; 35: 1708–13
- 3 Fogelholm R, Nuutila M, Vuorela AL. Primary intracerebral haemorrhage in the Jyväskylä region, central Finland, 1985–89: incidence, case fatality rate, and functional outcome. *J Neurol Neurosurg Psychiatry* 1992; 55: 546–52
- 4 Fernandes HM, Mendelow AD. Spontaneous intracerebral haemorrhage: a surgical dilemma. *Br J Neurosurg* 1999; 13: 389–94
- 5 Masdeu JC, Rubino FA. Management of lobar intracerebral haemorrhage: Medical or surgical. *Neurology* 1984; 34: 381–3
- 6 Fernandes HF, Gregson BG, Siddique MS, Mendelow AD. Surgery in intracerebral haemorrhage: the uncertainty continues. Personal communication
- 7 Wolf PA. Epidemiology of intracerebral haemorrhage. In: Kase CS, Caplan LR (eds) *Intracerebral Haemorrhage*. Boston: Butterworth-Heinemann, 1994; 21
- 8 Kaufman HH. *Spontaneous Intraparenchymal Brain Hemorrhage. Neurosurgery*, vol I: 2nd edn. New York: McGraw-Hill, 1996; 2567
- 9 Wiener H, Cooper P. The management of spontaneous intracerebral haemorrhage. *Contemp Neurosurg* 1992; 14: 1–8
- 10 Caplan LR. Intracerebral hematomas. In: H Kaufmann, ed. New York: Raven Press, 1992; 34
- 11 Herstein DJ, Schaumburg HH. Hypertensive intracerebral haematoma; an investigation of the initial haemorrhage and rebleeding using chromium Cr 51 labeled erythrocytes. *Arch Neurol* 1974; 30: 412–4
- 12 Brot T, Broderick J, Kothari R *et al*. Early haemorrhage growth in patients with intracerebral hemorrhage. *Stroke* 1997; 28: 1–5
- 13 Fujii Y, Takeuchi S, Sasaki O, Minakawa T, Tanaka R. Multivariate analysis of predictors of hematoma enlargement in spontaneous intracerebral hemorrhage. *Stroke* 1998; 29: 1160–6
- 14 Fujii Y, Tanaka R, Takeuchi S, Koike T, Minakawa T, Sasaki O. Hematoma enlargement in spontaneous intracerebral hemorrhage [see comments]. *J Neurosurg* 1994; 80: 51–7
- 15 Kazui S, Minematsu K, Yamamoto H, Sawada T, Yamaguchi T. Predisposing factors to enlargement of spontaneous intracerebral hematoma. *Stroke* 1997; 28: 2370–5
- 16 Suzuki S, Kelley RE, Dandapani BK, Reyes-Iglesias Y, Dietrich WD, Duncan RC. Acute leukocyte and temperature response in hypertensive intracerebral hemorrhage. *Stroke* 1995; 26: 1020–3
- 17 Murai Y, Takagi R, Ikeda Y, Yamamoto Y, Teramoto A. Three-dimensional computerised tomography angiography in patients with hyperacute intracerebral haemorrhage. *J Neurosurg* 1999; 91: 424–31

- 18 Bullock R, Mendelow AD, Teasdale GM, Graham DI. Intracranial haemorrhage induced at arterial pressure in the rat Part 1: Description of technique, ICP changes and neuropathological findings. *Neurol Res* 1984; 6: 184-8
- 19 Zifko UA, Slomka PJ, Young GB, Reid RH, Bolton CF. Brain mapping of median nerve somatosensory evoked potentials with combined 99mTc-ECD single-photon emission tomography and magnetic resonance imaging. *Eur J Nuclear Med* 1996; 23: 579-82
- 20 Kanno T, Nonomura K. Hyperbaric oxygen therapy to determine the surgical indication of moderate hypertensive intracerebral hemorrhage. *Minim Invasive Neurosurg* 1996; 39: 56-9
- 21 Nehls DG, Mendelow AD, Graham DI, Teasdale GM. Experimental intracerebral hemorrhage: early removal of a spontaneous mass lesion improves late outcome. *Neurosurgery* 1990, 27: 674-82
- 22 Siddique MS, Fernandes HF, Arene N U, Wooldridge TD, Fenwick JD, Mendelow AD. Changes in cerebral blood flow as measured by HMPAO SPECT in patients following spontaneous intracerebral haemorrhage. *Acta Neurochirurg* 2000; In press
- 23 Mendelow AD. Mechanisms of ischaemic brain damage with Intracerebral haemorrhage. *Stroke* 1993; 24 (suppl): 115-7
- 24 Siddique MS, Oakley A, Kalaria RN, Mendelow AD. Activation of caspase-3 in human brain after cerebral contusion. *Br J Neurosurg* 2000; 14: 164-74
- 25 Clark RS, Kochanek PM, Chen M *et al.* Increases in Bcl-2 and cleavage of caspase-1 and caspase-3 in human brain after head injury. *FASEB J* 1999; 13: 813-21
- 26 Barinaga M. Stroke-damaged neurons may commit cellular suicide. *Science* 1998; 281: 1302-3
- 27 Broderick JP, Brott TG, Grotta JC. Intracerebral hemorrhage volume measurement [letter]. *Stroke* 1994, 25: 1081
- 28 Bradley Jr WG. MR appearance of haemorrhage in the brain. *Radiology* 1993; 189: 15-26
- 29 Kaneko T, Sawada T, Niimi T. Lower limit of blood pressure in treatment of acute hypertensive intracranial haemorrhage. *J Cereb Blood Flow Metab* 1983; 351: S51-2
- 30 Janny P, Papo I, Chazal J, Colnet G, Barretto LC. Intracranial hypertension and prognosis of spontaneous intracerebral haematomas. A correlative study of 60 patients. *Acta Neurochirurg* 1982, 61: 181-6
- 31 Pongvarin N, Bhoopat W, Viriyavejakul A *et al.* Effects of dexamethasone in primary supratentorial intracerebral hemorrhage. *N Engl J Med* 1987; 316: 1229-33
- 32 McKissock W, Richardson A, Taylor J. Primary intracerebral haemorrhage; a controlled trial of surgical and conservative treatment in 180 unselected cases. *Lancet* 1961; ii: 221-6
- 33 Kanno T, Sano H, Shinomiya Y *et al.* Role of surgery in hypertensive intracerebral hematoma. A comparative study of 305 nonsurgical and 154 surgical cases. *J Neurosurg* 1984; 61: 1091-9
- 34 Volpin L, Cervellini P, Colombo F, Zanusso M, Benedetti A. Spontaneous intracerebral hematomas: a new proposal about the usefulness and limits of surgical treatment. *Neurosurgery* 1984; 15: 663-6
- 35 Kanaya H, Kuroda K. Development in neurosurgical approaches to hypertensive intracerebral haemorrhage in Japan. In: Kaufman HH. (ed) *Intracerebral Hematomas*. New York: Raven, 1992, 197-209
- 36 Kobayashi S, Sato A, Kageyama Y, Nakamura H, Watanabe Y, Yamaura A. Treatment of hypertensive cerebellar hemorrhage - surgical or conservative management? [see comment in: *Neurosurgery* 1995; 37: 552-3]. *Neurosurgery* 1994, 34: 246-51
- 37 Mathew P, Teasdale G, Bannan A, Oluoch-Olunya D. Neurosurgical management of cerebellar haematoma and infarct. *J Neurol Neurosurg Psychiatry* 1995; 59: 287-92
- 38 Hondo H, Uno M, Sasaki K *et al.* Computed tomography controlled aspiration surgery for hypertensive intracerebral hemorrhage. Experience of more than 400 cases. *Stereotact Funct Neurosurg* 1990, 54: 432-7
- 39 Auer LM. Endoscopic evacuation of intracerebral haemorrhage. High-tec-surgical treatment - a new approach to the problem? *Acta Neurochirurg* 1985; 74: 124-8
- 40 Hinton DR, Dolan E, Sima AF. The value of histopathological examination of surgically removed blood clot in determining the etiology of spontaneous intracerebral haemorrhage. *Stroke* 1984, 15: 517-20
- 41 Salerni A, Wald S, Flanagan M. Relationships among cortical ischemia, infarction, and hemorrhage in eclampsia. *Neurosurgery* 1988; 22: 408-10

- 42 Tao HJ. *Manual of Neurosurgery Non Aneurysmal Intracerebral Haematoma*. Edinburgh: Churchill Livingstone, 1996, 486
- 43 Toczek MT, Morrell MJ, Silverberg GA, Lowe GM. Cerebellar hemorrhage complicating temporal lobectomy. Report of four cases [see comment in *J Neurosurg* 1997, 86: 916–7]. *J Neurosurg* 1996; 85: 718–22
- 44 Papanastassiou V, Kerr R, Adams C. Contralateral cerebellar hemorrhagic infarction after pterional craniotomy: report of five cases and review of the literature. *Neurosurgery* 1996; 39: 841–52
- 45 Juvela S, Heiskanen O, Poranen A *et al.* The treatment of spontaneous intracerebral hemorrhage. A prospective randomized trial of surgical and conservative treatment [see comment in *J Neurosurg* 1990; 72: 152–5]. *J Neurosurg* 1989; 70: 755–8
- 46 Auer LM, Deinsberger W, Niederkorn K *et al.* Endoscopic surgery versus medical treatment for spontaneous intracerebral hematoma: a randomized study. *J Neurosurg* 1989; 70: 530–5
- 47 Baner HH, Reisch JS, Allen BC, Plaizier LJ, Su CJ. Failure of surgery to improve outcome in hypertensive putaminal hemorrhage. A prospective randomized trial *Arch Neurol* 1990; 47: 1103–6
- 48 Chen X, Yang H, Cheng Z. Comparative study of the internal medical and surgical treatment of hypertensive intracranial haemorrhage. *Acta Acad Med Shanghai* 1992; 19: 237–40
- 49 Morgenstern L B, Frankowski R F, Shedden P, Pasteur W, Grotta J C. Surgical treatment for intracerebral hemorrhage (STICH). A single-center, randomized clinical trial. *Neurology* 1998; 51: 1359–63
- 50 Zuccarello M, Brott T, Derex L *et al.* Early surgical treatment for supratentorial intracerebral haemorrhage a randomized feasibility study *Stroke* 1999, 30: 1833–9