

# Idiopathic intracranial hypertension and visual function

James F. Acheson\*

*Department of Neuro-Ophthalmology, National Hospital for Neurology and Neurosurgery, London, and Neuro-Ophthalmology and Strabismus Service, Moorfields Eye Hospital, London, UK*

**Background:** Idiopathic intracranial hypertension is a relatively common condition (incidence up to 19/100 000/year in the high-risk group of obese women in reproductive age range) causing headaches with papilloedema. Detailed investigations are required to exclude other causes of raised intracranial pressure. The condition may be self-limiting or enter a chronic phase with significant morbidity because of headache and visual loss.

**Methods and results:** This includes an overview of literature and internal audit data.

**Discussion and conclusions:** Management of hypertension is initially medical, utilizing a combination of managed weight reduction and diuretic therapy. Cerebrospinal fluid (CSF) diversion surgery may be required to stabilize vision. Options include neurosurgical shunting by lumbar-peritoneal or ventriculo-peritoneal routes or by optic nerve sheath fenestration or both. High category evidence from randomized trials to guide management decisions is lacking. This article sets out to guide current best practice.

**Keywords:** idiopathic intracranial hypertension/papilloedema/visual loss

## Introduction and terminology

Idiopathic intracranial hypertension (IIH) is defined as a syndrome of signs and symptoms of increased intracranial pressure without causative lesions on magnetic resonance imaging (MRI) or computed tomography. The terms pseudotumour cerebri and pseudotumour syndrome are also used, but the term benign intracranial hypertension is now obsolete, reflecting current awareness of the major risks to vision from papilloedema.<sup>1,2</sup> Severe visual loss may complicate IIH, and in one hospital-based survey of 57 patients followed for 5–41 years after initial diagnosis, blinding or severe visual impairment was noted for one or both eyes of 14 patients (24%). Population-based

Accepted: December 13,  
2006

\*Correspondence to:  
James F. Acheson,  
Department of Neuro-  
Ophthalmology, National  
Hospital for Neurology  
and Neurosurgery, Queen  
Square, London WC1N  
3BG, UK. E-mail: james.  
acheson@uclh.nhs.uk

surveys indicate a lower overall rate of visual impairment between 10 and 20%.<sup>3,4</sup>

## Incidence and prevalence

IIH occurs most commonly in reproductive age women who are obese. The incidence is approximately 1/100 000/year rising to 13/100 000/year in women between 20 and 44 years who are 10% above ideal body weight and 19/100 000/year in those 20% above ideal body weight. IIH is also seen in males and children, but less frequently. Prevalence rates are higher, reflecting the chronic nature of the condition in many cases.<sup>4-7</sup>

## Diagnostic criteria

Modified Dandy criteria for diagnosis of IIH include the following:<sup>1</sup>

- (i) high-pressure headache and papilloedema;
- (ii) CSF opening pressure of >25 cm water;
- (iii) awake and alert patient;
- (iv) no localizing signs other than lateral rectus paresis;
- (v) normal CSF constituents;
- (vi) normal brain imaging with no evidence of venous obstruction;
- (vii) benign clinical course apart from visual deterioration;
- (viii) no other cause of raised intracranial pressure.

## Pathogenesis

The pathogenesis of IIH remains to be clarified. Cerebral venous hypertension caused by venous sinus thrombosis, neoplastic obstruction or a dural arteriovenous malformation causes a very similar clinical picture. A rise in venous pressure will cause a reduction in CSF absorption, and it is possible that even with careful non-invasive imaging with brain MRI and magnetic resonance venography, some cases of venous sinus thrombosis are missed, leading to the incorrect diagnosis of IIH. Abnormal pressure gradients within the dural venous sinuses can be shown on manometry even in the presence of apparently normal venous phase catheter angiograms, leading to the suggestion that venous hypertension may play a role in IIH, even when there is no obstruction. However, at this stage, it is not entirely clear whether such pressure gradients are the cause or the effect of the raised intracranial

pressure. In practice, the diagnosis of IIH is made when venous obstruction and other causes of raised intracranial pressure have been ruled out on conventional imaging.<sup>8</sup>

An association between IIH and obesity has long been recognized, especially in individuals with a history of recent weight gain, including children.<sup>9–11</sup> There is evidence that weight reduction may lead to resolution of IIH. A direct cause and effect mechanism has been proposed, with increased intra-abdominal and intrathoracic pressures causing raised central venous pressures, but this does not explain the fact that although obesity is common, IIH is rare. However, it is known that high-pressure headache may arise without papilloedema, and it is possible that obesity is the cause of the headache in these patients by this mechanism.<sup>12–16</sup>

'Secondary' IIH may arise in association with a number of medical conditions including obstructive sleep apnoea, systemic lupus erythematosus, Behcet's disease and renal impairment and also against a background of a variety of prescription medications. These include tetracyclines, vitamin A analogues and oral contraceptives. In these patients, the association with obesity, female sex and reproductive age is not found, but the symptoms and signs of intracranial hypertension (and the visual consequences) are the same. The mechanism of these associations in the absence of venous sinus thrombosis is not clear.<sup>17,18</sup>

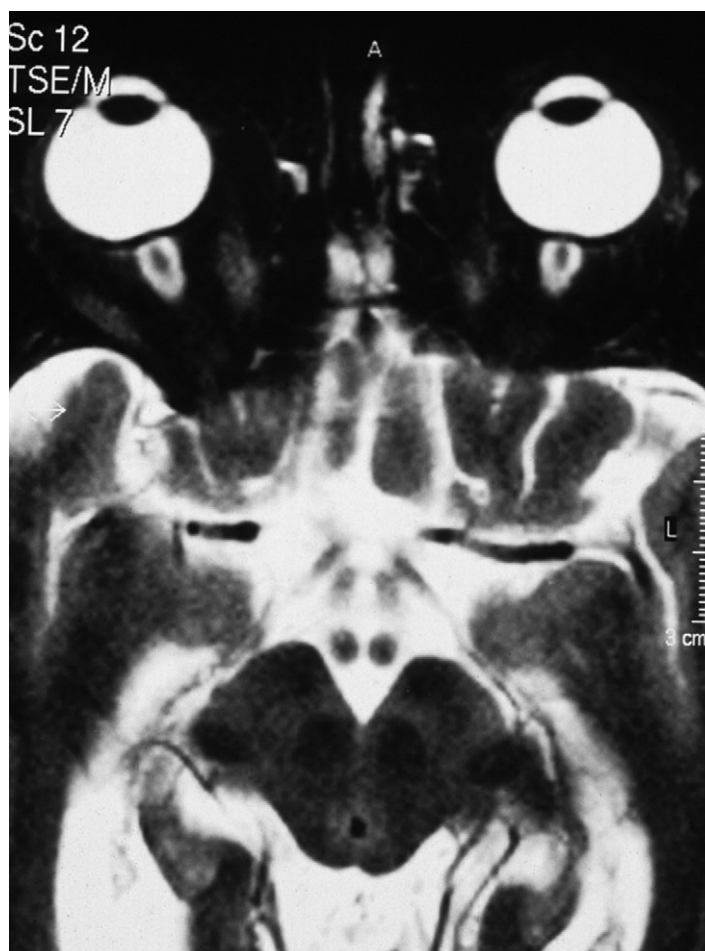### *The optic nerve in raised intracranial pressure*

The ophthalmic hallmark of raised intracranial pressure is papilloedema. Conventionally, the term papilloedema is reserved for the cases of optic disc oedema when the swelling is due to raised intracranial pressure and does not arise from local optic nerve processes such as inflammation, extrinsic compression or ischaemia. Raised CSF pressure is transmitted through the optic canal into the intra-orbital optic nerve sheath to exert effects on the axons of the optic nerve at the point of exit from the eye through the lamina cribrosa. Fast and slow axoplasmic transport is interrupted by the raised pressure, resulting in nerve fibre swelling at the nerve head. At the optic nerve head and peripapillary region, some features of central retinal vein obstruction are typically seen. These include dilatation of the pre-papillary retinal capillaries and nerve head hyperaemia, dilation of retinal veins, peripapillary haemorrhages and cotton wool spots. These are the consequences of compression of the central retinal vein, firstly by dilated axons within the pre-laminar optic nerve head and secondly by pressure from the CSF on the central retinal vein as it crosses the subarachnoid space to exit the optic nerve 1 cm behind the globe.<sup>19,20</sup> The changes

of papilloedema may sometimes be highly asymmetrical or even monocular, and chronic raised intracranial pressure needs to be included in the differential diagnosis of unilateral cases.<sup>21–23</sup>

### *Further ophthalmic features of raised intracranial pressure*

In addition to papilloedema, a number of retinal changes may contribute to the visual deficit, including choroidal compression folds across the macula, choroidal neovascularization and serous retinal elevation around the nerve head in acute severe cases. Flattening of the globe by a dilated intra-orbital optic nerve sheath may lead to refractive changes (Fig. 1). Diplopia may be a feature, usually as a result of sixth cranial nerve paresis.



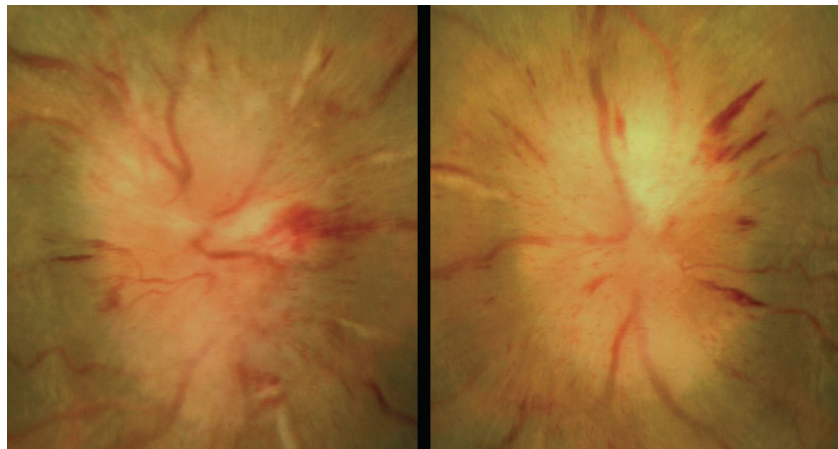
**Fig. 1** Axial MRI scan of orbits in a typical IIH case with papilloedema. Note dilatation of the optic nerve sheaths and flattening of the posterior aspect of the globes.

### *The evolution of optic nerve changes in raised intracranial pressure*

The ophthalmoscopic appearances of papilloedema reflect the severity of raised intracranial pressure and associated central retinal vein obstruction. However, typically, central vision is preserved and perimetry simply shows blind spot enlargement, reflecting lateral displacement of retinal elements by the axonal swelling (Fig. 2). In acute severe papilloedema, peripheral field and central acuity may be compromised by loss of function of the swollen axons. However, more typically, peripheral field and central acuity are only lost in longer standing cases as a result of axonal death (secondary optic atrophy). Ophthalmoscopic markers of chronicity and axonal loss include the appearance of axonal degradation products on the nerve head (corpora amylacea), choroido-retinal collateral blood vessels and disc pallor in the presence of continuing swelling<sup>24,25</sup> (Fig. 3). Although many patients may present with acute papilloedema, others are first seen with chronic and atrophic pictures at the time of diagnosis. In these instances, the abnormalities may be quite subtle, but will provide an important diagnostic clue in the assessment of a chronic headache (Fig. 2).

### *Clinical evaluation of vision in papilloedema*

Major blinding peripheral field loss may complicate papilloedema in the presence of preserved central visual acuity, and typically, acuity is only lost after the event of major field loss. Monitoring visual function is mandatory, and it is important to appreciate that uncontrolled raised intracranial pressure and persistent papilloedema can result in blindness.



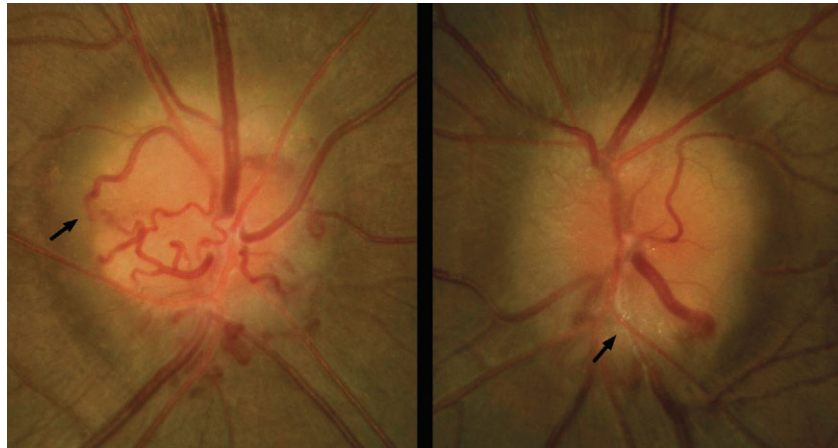
**Fig. 2** Acute papilloedema: usually visual acuity and visual field are preserved. Nerve fibre layer haemorrhages around the disc margin are obvious.

The tempo of this development is highly variable with major deficits arising within weeks in severe cases (malignant pseudotumour cerebri), but more typically over several months.

Measuring degrees of disc swelling by ophthalmoscopy or by disc imaging techniques and blind spot size measurement are unreliable markers of visual field loss, and quantitative serial perimetry is mandatory for monitoring clinical progress. Both kinetic and static perimetry equipment are suitable and each has advantages and disadvantages. Kinetic machines (for example, the Goldmann) are quick to use and study the full field, but are highly operator-dependent and at best only provide a semi-quantitative record. Computer-assisted full-threshold static perimetry is only reliable in the central 24° or 30° of field and is less operator-dependent, providing a more objective record suitable for long-term follow-up. Early signs of optic nerve compromise include nasal step defects, disc-related arcuate scotomata that reflect focal loss of retinal nerve fibres and global field depression.<sup>26,27</sup> Serial disc photography is also valuable for long-term monitoring, and peripapillary retinal nerve fibre layer imaging with ocular computed tomography is increasingly used.<sup>28</sup>

## Medical management of IIH

In many cases, IIH is a benign self-limiting condition, which remits after a single diagnostic and therapeutic lumbar puncture, together with modest weight reduction and without any visual consequences. Associated medical conditions if treated can lead to remission, especially obstructive sleep apnoea and drug-induced IIH. Other patients enter a chronic phase with long-term headache and on-going risk of insidious and devastating visual loss (Fig. 3). Occasionally, visual failure is a feature of the acute presentation ('bursting papilloedema' and 'malignant cerebral pseudotumour'), and irreversible blindness develops over a matter of weeks, not months or years. Medical measures available include serial lumbar punctures, diuretics and managed weight reduction. Carbonic anhydrase inhibitors (e.g. acetazolamide and dorzolamide) are especially suitable diuretics because of dual actions on renal function and CSF production in the cerebral choroid plexus. Acetazolamide has teratogenic effects in animals and should be avoided when possible in pregnancy, especially during the first trimester. Adjuvant analgesics, tricyclic antidepressants and the anticonvulsant agent topiramate may all be used to control headache.<sup>29–33</sup>



**Fig. 3** Chronic papilloedema: note that haemorrhages, exudates and cotton wool spots have disappeared. Florid retino-choroidal collateral vessels (arrow) in the right eye and optic disc surface white spots (corpora amylacea) on the left eye (arrow). Significant visual field loss likely to be present.

## Surgical treatment options in IIH

Acute severe visual failure, intractable headache and chronic progressive visual loss may not be controlled by medical measures alone and some form of CSF diversion surgery is required. Available options include lumbar-peritoneal shunting, ventriculo-peritoneal shunting and optic nerve sheath fenestration (decompression). The selection of procedure is controversial because of significant failure and complication rates from all methods and lack of adequate comparative data.

### *Optic nerve sheath decompression*

The first surgical technique devised for the relief of papilloedema was transconjunctival optic nerve sheath incision, allowing flow of CSF from the subarachnoid space into the orbit, reported by de Wecker<sup>34</sup> in 1871. This was performed without direct visualization and without clear understanding of the difference between disc swelling due to raised intracranial pressure and optic disc swelling due to local causes such as optic neuritis, and the procedure dropped out of use. Shunting techniques developed in the 1950s and 1960s were then applied to IIH patients with some success. However, eventually retrospective case series appeared citing failure rates of 48–52% and complications rates, particularly low-pressure headache, of 21–52%.<sup>35,36</sup> Interest turned back to optic nerve sheath decompression (ONSD) with case series published in 1988 indicating high efficacy rates in terms of visual

function in the short term.<sup>37,38</sup> Longer term follow-up at 12 months later revealed a more significant failure rate, lack of headache control and uncommon but major visual loss from intra-operative neuro-vascular injury at the optic nerve head.<sup>39,40</sup>

How an incision in the retrobulbar optic nerve sheath produces lasting effects on papilloedema remains unclear. The incision site is subject to normal wound healing, but the effects may last longer than the duration of a patent fistula into the orbit. There are reports of reparative fibrosis at the incision site which leads to obliteration of the distal subarachnoid space and protection of the optic nerve axons from high-pressure CSF at their most vulnerable point at the lamina cribrosa. In other cases, a cystic filtration bleb may develop with continuing egress of CSF in a fashion similar to the filtration bleb created in surgical trabeculectomy for glaucoma.

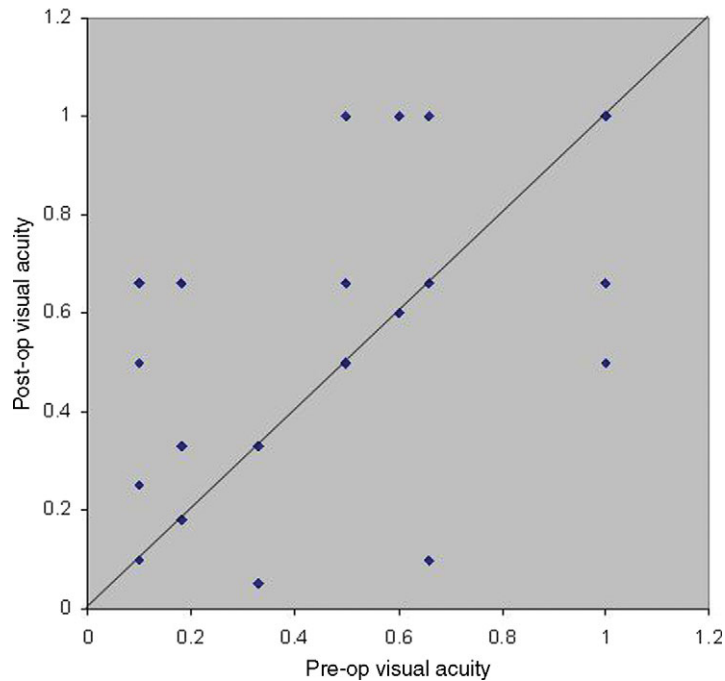
### *Lumbar-peritoneal and ventriculo-peritoneal shunting*

A successful shunt will treat both papilloedema and headache and is the definitive treatment for IIH cases when medical management fails. Lumbar-peritoneal systems (LPs) remain the most widely utilized. However, problems remain, with distal catheter migration and obstruction requiring repeat revisions and cerebellar tonsillar descent causing an iatrogenic Chiari malformation, infections and subdural haematoma. The development of shunt valve mechanisms to reduce the problems of overdrainage is a significant advance.<sup>41</sup> In some units, ventricular-peritoneal systems (VPs) utilizing frameless stereotactic image guidance techniques have been re-introduced in the face of these difficulties. There is some evidence that long-term patency rates may be superior following a VP shunt when compared with an LP shunt, presumably because of the superior stability of the proximal end of the shunt system. Problems from cerebellar tonsillar descent are avoided. An additional advantage of VP shunting is that the reservoir facilitates late reviews of shunt function and intracranial pressure in instances of persistent headache (Fig. 4). The technique is more invasive than ONSD or lumbar-peritoneal shunting and is usually reserved for cases of failure of previous CSF diversion surgery from other approaches.<sup>42</sup>

### *Principle complications of CSF diversion surgery*

ONSD (fenestration) include the following:

- (i) persistent pupil dilatation from ciliary ganglion injury;
- (ii) ophthalmoplegia and diplopia;



**Fig. 4** Scatter plot illustrating visual acuity outcomes following ONSD in internal departmental audit. Consecutive series of 29 eyes in 29 patients including one revision with adjuvant antimetabolite. Acuity expressed as best Snellen acuity fraction. All cases underwent ONSD as initial surgical intervention. Follow-up for between 12–24 months with later data if available not included. First operated eye data only included in bilateral cases. Ten of 29 (34%) required subsequent shunting, five for progressive visual failure and five for uncontrolled headache. Mean Snellen fraction acuity first operated eye improved from 0.48 to 0.65 and mean VF score first operated eye improved from 3.2 to 2.5 (scoring system after Wall and George<sup>25</sup>).

- (iii) short posterior ciliary vessel occlusion;
- (iv) retinal artery occlusion;
- (v) traumatic optic neuropathy;
- (vi) intrasheath and intra-orbital haemorrhage.

Lumbar-peritoneal shunting include the following:

- (i) obstruction;
- (ii) infection;
- (iii) low-pressure headaches;
- (iv) radiculopathy;
- (v) tonsillar herniation (acquired Chiari 1 malformation);
- (vi) shunt migration;
- (vii) subdural haematoma.

## Current practice for the management of IIH

Patients with headache, papilloedema and visual symptoms and a visual deficit require thorough evaluation to confirm the diagnosis, including brain and in selected cases, spinal MRI, and CSF manometry and analysis. Following diagnosis, initial management is medical using a combination of carbonic anhydrase inhibitors, other medications for headache and managed weight reduction. Self-help and patient support groups are helpful, and careful ophthalmic follow-up with serial perimetry is mandatory. In the cases of failed medical management with uncontrolled headache and/or progressive visual loss, CSF diversion surgery is considered. Treatment selection decisions unfortunately cannot be guided by high-grade clinical trials' evidence which are lacking. Because a successful shunt will simultaneously address headache and visual loss, in our centre, the majority of patients who require CSF diversion surgery are offered a shunt in the first instance.

However, ONSD remains a useful option, especially in the following situations:

- (i) no significant headache—mild-to-moderate visual loss;
- (ii) no significant headache—mild visual loss with prominent transient visual obscurations;
- (iii) progressive visual loss with previous shunt failure;
- (iv) shunt contraindicated by low cerebellar tonsils (LPS) or other intracranial pathology (VPS).

Optimal management of IIH requires input from ophthalmology, neurology and neurosurgery and good communications between specialties are essential to protect the patient from unnecessary lumbar punctures and CSF diversion surgery on the one hand and avoidable visual loss on the other. The multidisciplinary resources of a tertiary referral clinical neurosciences centre are usually required for initial diagnostic evaluation, with follow-up normally led by ophthalmology in conjunction with other teams as required.

## Acknowledgements

The author is grateful to the consultant neurologists and neurosurgeons at the National Hospital for Neurology and Neurosurgery for permitting to discuss with patients under their care.

## References

- 1 Digre KB, Corbett JJ (2001) Idiopathic intracranial hypertension (pseudotumor cerebri): a reappraisal. *Neurologist*, **7**, 2–67.
- 2 Friedman DI (2001) Papilledema and pseudotumor cerebri. *Ophthalmol Clin North Am*, **14**, 129–147.
- 3 Corbett JJ, Savino PJ, Thompson HS (1982) Visual loss in pseudotumor cerebri. Follow-up of 57 patients from five to 41 years and a profile of 14 patients with permanent severe visual loss. *Arch Neurol*, **39**, 461–474.
- 4 Radhakrishnan K, Ahlskog JE, Cross SA, Kurland LT, O'Fallon WM (1993) Idiopathic intracranial hypertension (pseudotumor cerebri). Descriptive epidemiology in Rochester, Minn, 1976 to 1990. *Arch Neurol*, **50**, 78–80.
- 5 Radhakrishnan K, Thacker AK, Bohlaga NH, Maloo JC, Gerryo SE (1993) Epidemiology of idiopathic intracranial hypertension: a prospective and case-control study. *J Neurol Sci*, **116**, 18–28.
- 6 Durcan FJ, Corbett JJ, Wall M (1988) The incidence of pseudotumor cerebri: population studies in Iowa and Louisiana. *Arch Neurol*, **45**, 875–877.
- 7 Gordon K (1997) Pediatric pseudotumor cerebri: descriptive epidemiology. *Can J Neurol Sci*, **24**, 219–221.
- 8 Bioussé V, Bousser MG (2001) Benign intracranial hypertension. *Rev Neurol*, **157**, 21–34.
- 9 Walker RW (2001) Idiopathic intracranial hypertension: any light on the mechanism of the raised pressure? *J Neurol Neurosurg Psychiatry*, **71**, 1–7.
- 10 Sussman JD, Sarkies N, Pickard JD (1998) Benign intracranial hypertension. Pseudotumour cerebri: idiopathic intracranial hypertension. *Adv Tech Stand Neurosurg*, **24**, 261–305.
- 11 Soler D, Cox T, Bullock P, Calver DM, Robinson RO (1998) Diagnosis and management of benign intracranial hypertension. *Arch Dis Child*, **78**, 89–94.
- 12 Johnson LN, Krohel GB, Madsen RW, March GA (1998) The role of weight loss and acetazolamide in the treatment of idiopathic intracranial hypertension (pseudotumor cerebri). *Ophthalmology*, **105**, 2313–2317.
- 13 Scott IU, Siatkowski RM, Eneyni M, Brodsky MC, Lam BL (1997) Idiopathic intracranial hypertension in children and adolescents. *Am J Ophthalmol*, **124**, 253–255.
- 14 Warman R (2000) Management of pseudotumor cerebri in children. *Int Pediatr*, **1**, 147–150.
- 15 Giuseffi V, Wall M, Siegel PZ, Rojas PB (1991) Symptoms and disease associations in idiopathic intracranial hypertension (pseudotumor cerebri): a case-control study. *Neurology*, **41**, 239–244.
- 16 Ireland B, Corbett JJ, Wallace RB (1990) The search for causes of idiopathic intracranial hypertension: a preliminary case-control study. *Arch Neurol*, **47**, 315–320.
- 17 Lochead J, Elston JS (2003) Doxycycline induced intracranial hypertension. *BMJ*, **326**, 641–642.
- 18 Lee AG, Golnik K, Kardon R, Wall M, Eggenberger E, Yedavally S (2002) Sleep apnea and intracranial hypertension in men. *Ophthalmology*, **109**, 482–485.
- 19 Hayreh SS (1964) Pathogenesis of oedema of the optic disc (papilloedema); a preliminary report. *Br J Ophthalmol*, **48**, 522–543.
- 20 Wall M (2000) Idiopathic intracranial hypertension: mechanisms of visual loss and disease management. *Semin Neurol*, **20**(1), 89–95.
- 21 Wang SJ, Silberstein SD, Patterson S, Young WB (1998) Idiopathic intracranial hypertension without papilledema: a case-control study in a headache center. *Neurology*, **51**, 245–249.
- 22 Wall M, White WM (1998) Asymmetric papilledema in idiopathic intracranial hypertension: prospective interocular comparison of sensory visual function. *Invest Ophthalmol Vis Sci*, **39**, 134–142.
- 23 Mathew NT, Ravishankar K, Sanin LC (1996) Coexistence of migraine and idiopathic intracranial hypertension without papilledema. *Neurology*, **46**, 1226–1230.
- 24 Sanders MD (1997) Papilloedema: the pendulum of progress. *Eye*, **11**, 267–294.
- 25 Miller NR (1998) Papilledema. In Miller NR, Newman NJ (eds) *Walsh & Hoyt's Clinical Neuro-Ophthalmology*, 5th ed. Baltimore: Williams & Wilkins, 487–548.

- 26 Wall M, George D (1991) Idiopathic intracranial hypertension. A prospective study of 50 patients. *Brain*, **114**, 155–180.
- 27 Rowe FJ, Sarkies NJ (1998) Assessment of visual function in idiopathic intracranial hypertension. A prospective study. *Eye*, **12**, 111–118.
- 28 Mehta JS, Plant GT, Acheson JF (2005) Twin and triple peaks papilledema. *Ophthalmology*, **112**, 1299–1301.
- 29 Go KG (2000) Pseudotumour cerebri: incidence, management and prevention. *CNS Drugs*, **14**, 33–49.
- 30 Lueck C, McIlwaine G (2003) Interventions for idiopathic intracranial hypertension (Cochrane review). *The Cochrane Library*, issue 3, Oxford: Update Software.
- 31 Liu GT, Volpe NJ, Galetta SL (1998) Pseudotumor cerebri and its medical treatment. *Drugs Today*, **34**, 563–574.
- 32 Radhakrishnan K, Ahlskog JE, Garrity JA, Kurland LT (1994) Idiopathic intracranial hypertension. *Mayo Clin Proc*, **69**, 169–180.
- 33 Palacio E, Rodero L, Pascual J (2004) Topiramate-responsive headache due to idiopathic intracranial hypertension in Behcet syndrome. *Headache*, **44**, 436–437.
- 34 De Wecker L (1872) On incision of the optic nerve in cases of neuroretinitis. *Int Ophthalmol Cong Repts*, **4**, 11–14.
- 35 Johnston I, Paterson A, Besser M (1981) The treatment of benign intracranial hypertension: a review of 134 cases. *Surg Neurol*, **16**, 218–224.
- 36 Rosenberg M, Corbett JJ, Smith C *et al.* (1993) Cerebrospinal fluid diversion procedures in pseudotumor cerebri. *Neurology*, **43**, 1071–1072.
- 37 Sergott RC, Savino PJ, Bosley TM (1988) Modified optic nerve sheath decompression provides long-term visual improvement for pseudotumor cerebri. *Arch Ophthalmol*, **106**, 1384–1390.
- 38 Acheson JF, Green WT, Sanders MD (1994) Optic nerve sheath decompression for the treatment of visual failure in chronic raised intracranial pressure. *J Neurol Neurosurg Psychiatry*, **57**, 1426–1429.
- 39 Spoor TC, McHenry J (1993) Long-term effectiveness of optic nerve sheath decompression for pseudotumor cerebri. *Arch Ophthalmol*, **111**, 632–635.
- 40 Herzau V, Baykal HE (1998) Long-term results of optic nerve sheath fenestration in pseudotumor cerebri. *Klin Monatsbl Augenheilkd*, **213**, 154–160.
- 41 Binder DK, Horton JC, Lawton MT, McDermott MW (2004) *Neurosurgery*, **54**, 538–551.
- 42 Maher CO, Garrity JA, Meyer FB (2001) Refractory idiopathic intracranial hypertension treated with stereotactically planned ventriculoperitoneal shunt placement. *Neurosurg Focus*, **10**, 1–4