
REVIEW ARTICLE

Complex visual hallucinations

Clinical and neurobiological insights

M. Manford¹ and F. Andermann²

¹Department of Clinical Neurology, Addenbrooke's Hospital, Cambridge, UK and ²Montreal Neurological Institute, Montreal, Canada

Correspondence to: Dr M. Manford, Department of Clinical Neurology, Addenbrooke's Hospital, Hills Road, Cambridge CB2 2QQ, UK.
E-mail: Markmanford@gransden.prestel.co.uk

Summary

Complex visual hallucinations may affect some normal individuals on going to sleep and are also seen in pathological states, often in association with a sleep disturbance. The content of these hallucinations is striking and relatively stereotyped, often involving animals and human figures in bright colours and dramatic settings. Conditions causing these hallucinations include narcolepsy–cataplexy syndrome, peduncular hallucinosis, treated idiopathic Parkinson's disease, Lewy body dementia without treatment, migraine coma, Charles Bonnet syndrome (visual hallucinations of the blind), schizophrenia, hallucinogen-induced states and epilepsy. We describe cases of hallucinosis due to several of these causes and expand on previous hypotheses to suggest three mechanisms underlying complex visual hallucinations. (i) Epileptic

hallucinations are probably due to a direct irritative process acting on cortical centres integrating complex visual information. (ii) Visual pathway lesions cause defective visual input and may result in hallucinations from defective visual processing or an abnormal cortical release phenomenon. (iii) Brainstem lesions appear to affect ascending cholinergic and serotonergic pathways, and may also be implicated in Parkinson's disease. These brainstem abnormalities are often associated with disturbances of sleep. We discuss how these lesions, outside the primary visual system, may cause defective modulation of thalamocortical relationships leading to a release phenomenon. We suggest that perturbation of a distributed matrix may explain the production of similar, complex mental phenomena by relatively blunt insults at disparate sites.

Keywords: visual hallucinations; thalamocortical; arousal; serotonin

Abbreviations: 5HT = 5-hydroxytryptamine; LSD = lysergic acid diethylamine tartrate; PGO = ponto-geniculo-occipital (waves); REM = rapid eye movement

Introduction

Maury (1848) coined the term hypnagogic hallucinations to describe his own vivid hallucinations in the state of drowsiness, just before sleep. There have been several further detailed descriptions of the phenomenon, especially that by Leaning (Baillarger, 1846; Leroy, 1922; Leaning, 1926; Tournay, 1941; Foulkes and Vogel, 1965). Up to one-third of normal individuals may experience these hallucinations, when going off to sleep, anywhere from once in a lifetime to most nights, but they are particularly common in the narcolepsy–cataplexy syndrome. The hallucinations may last from a few seconds to ≥ 15 min, probably depending on the duration of this stage of drowsiness. Fever may trigger the hallucinations in those predisposed and even in these early series, it was recognized that sufferers often had poor vision

(Leaning, 1926). The content of the hallucinations is dramatic; they are usually in vivid colours and may evolve from simple spots of light through geometric patterns to complex images, or they may be complex from the outset. Sufferers often see human figures or faces (sometimes torsos without heads or vice versa); animals (real or bizarre), sometimes in miniature (Lilliputian hallucinations) or scenery of outstanding beauty. The images may be static or moving and their detail and vividness seem to exceed anything experienced in real life. In contrast to the dreams of deep sleep, the dreamer is on the outside observing the action which may evolve slightly but there is rarely a 'plot' in which the dreamer is actively involved. Modalities other than vision may be involved, especially faces may talk, but this is relatively uncommon.

The emotional reaction to the images may be neutral, pleasant fascination or extreme fear.

Several pathological conditions may be associated with very similar, striking hallucinations (often with preserved insight) and altered awareness (Table 1). They include peduncular hallucinosis, delirium tremens, drug-induced hallucinations, migraine coma, treated Parkinson's disease, Lewy body dementia and Charles Bonnet syndrome (hallucinations of the blind). The patient's belief in the reality of the images varies between conditions, and is especially affected by cognitive factors and their level of awareness. The patients least likely to be distressed by the hallucinations are those with Charles Bonnet syndrome, perhaps reflecting preservation of CNS function and adaptability. In general, once familiar with the hallucinations, the patients find them non-threatening and have insight into their nature, in distinction to hallucinations associated with psychiatric illness.

It has been difficult to find a common thread to explain the occurrence of hallucinations in these diverse conditions, but their striking similarity suggests that they may act through related mechanisms, despite apparently disparate lesion sites and disease processes. The pathology is sometimes extracortical, for example in peduncular hallucinosis and Charles Bonnet syndrome. In other conditions, for instance delirium tremens and drug-induced hallucinations, there is no fixed pathological substrate. Although the extracortical visual system may support some visual function, this is vague and semiconscious (Covey and Stoerig, 1991; Matthews and Kennard, 1993). It seems likely, therefore, that the visual detail of these sorts of hallucinations is due to a cortical phenomenon, although some of the causes may be acting on the cortex indirectly or from a remote site. Previous authors have suggested three basic underlying mechanisms: (i) irritative processes in the association cortex generating discharges falsely interpreted as due to sensory inputs; (ii) release phenomena due to defective visual input causing faulty cortical stimulation; and (iii) faulty visual processing in which inputs are normal but lesions result in an inappropriate pattern of cortical excitation (Cogan, 1973; Asaad and Shapiro, 1986). These general statements have never been taken further to try and provide a more detailed neurobiological explanation for hallucinations.

We describe the similarities and differences in clinical features of the various causes of complex hallucinations in relation to their pathophysiology to try and elucidate possible common elements. We shall explore how these conditions could influence activity in striate, extrastriate and association cortices and in subcortical visual centres.

Clinical features of complex hallucinations in diverse conditions

Peduncular hallucinosis

Case 1

Whilst watching television, this 58-year-old man developed a vertical split of the visual image. One-half appeared higher

than the other and the symptom resolved after 1 min. Ten days later he developed a ball of light, with a red and blue surround in his left visual hemifield, associated with headache and mild drowsiness. This lasted 2–3 min but recurred many times over several hours. The images then changed to a man in a suit and a black butterfly, occurring especially with his eyes shut. The symptoms improved over several days but hallucinations and distressing dreams recurred several weeks later. Hallucinations always occurred when he was relaxed but awake, with his eyes shut and waiting to go to sleep. He lay and watched them for prolonged periods until he fell asleep. They were not restricted to one part of the visual field and disappeared on opening his eyes. They never occurred at times of poor illumination if his eyes were open. He often saw a dwarf whose face was hidden by a lamp. The dwarf was accompanied by a clown in a striped grey suit. On one occasion there were three dwarves with egg-shaped heads who were at the bottom of his bed. They were wearing cloaks and playing with his feet, although he did not feel anything abnormal in his feet. One dwarf had a 'comforting golden face with blue eyes' and told him: 'It's all over'. He has also seen figures dressed in 17th century Cavalier's clothes or women in Victorian clothes pushing wicker perambulators with babies. When asleep he had vivid dreams including bright, striped fish swimming across his view. In retrospect, he understood these hallucinations were not real but, at the time, he was frightened by them.

Non-insulin-dependent diabetes mellitus and mild hypertension were diagnosed at his first presentation, but there was no other significant medical history. MRI scan showed small specks of increased T₂ signal, consistent with ischaemia in the right basal ganglia and right thalamus, including the pulvinar. [¹⁸F]Fluorodeoxyglucose-PET showed a larger area of ischaemia in the right thalamus and ipsilateral occipital cortex (Fig. 1).

Visual fields and visual evoked potentials were normal. Neuropsychometric assessment was entirely normal with no visuospatial deficit. Brainstem evoked potentials showed loss of waves II–IV but a normal I–V interval. No episodes of hallucinosis occurred during 48 h of ambulatory EEG. The EEG was normal and sleep architecture appeared normal.

Comment. In his case, the investigations and clinical picture point to an abnormality at thalamic or cortical level although there is no current clinical or investigation evidence of visual pathway malfunction or cortical disease. The reduced blood flow in occipital cortex may represent primary cortical involvement or reduced activity, secondary to under-activity of the afferent thalamic nuclei.

Case 2

A 50-year-old woman had a history of rheumatic heart disease, requiring valve surgery at the age of 25 years. At the age of 46 years, she developed a sudden onset of mild right hemiparesis with dysphasia, which recovered

Table 1 Characteristics of different conditions with complex visual hallucinations

Disease	Special features of hallucinations	Duration	Consciousness	Insight	Sleep	Lesion
Hypnagogic hallucinations	On falling asleep	Seconds to minutes	Drowsy	Usually preserved	Associated with narcolepsy	Brainstem in secondary cases
Peduncular hallucinosis	More often in evening. Any part of visual field. Rarely polymodal	Often prolonged	Normal	Usually preserved	Disturbed (see text)	Brainstem or thalamus
Delirium tremens	Very variable hallucinations may be polymodal. Autonomic instability	Often prolonged	Agitated and confused in later stages	Often reduced in later stages	REM overflow, with little sleep (see text)	None
Parkinson's disease and Lewy body dementia	Often in the evening. Any part of visual field. Rarely polymodal	Minutes	Not unconscious, normal, or drowsy/inaccessible	Usually preserved	Reduced REM sleep	Widespread, cortex and brainstem (see text)
Migraine coma	Noted during recovery from coma	Up to 2 days	Usually normal at time of hallucination but may be depressed	Preserved	Unknown	Ataxia in some cases
Visual field disturbance and Charles Bonnet syndrome	Localized to disturbed visual field and often in early morning or evening	Prolonged	Normal	Preserved	Normal	Visual pathway from retina to striate cortex
Focal epilepsy	Brief, stereotyped. May be localized to part of visual field. May have other epileptic features. Normal between episodes	Usually seconds	Often impaired	Usually preserved	Normal	Posterior temporoparietal

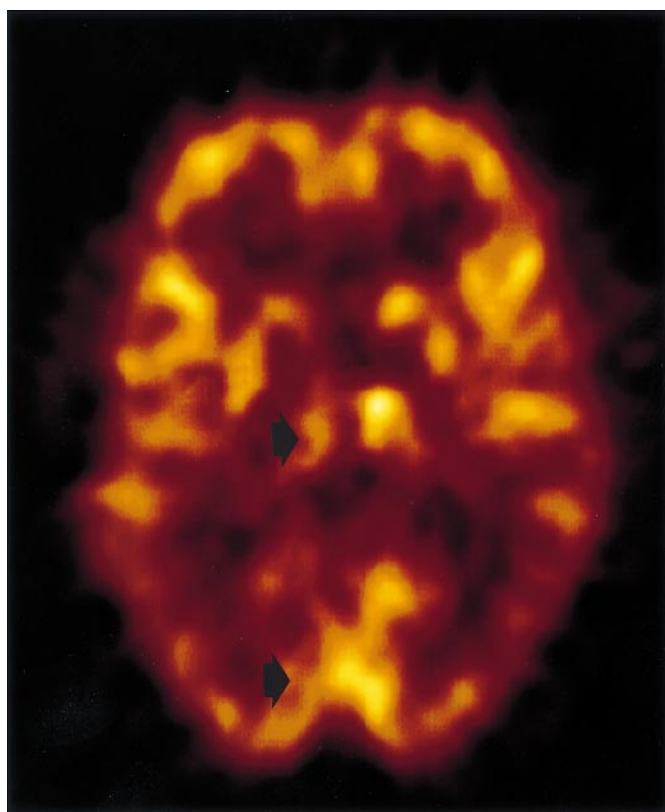


Fig. 1 Fluorodeoxyglucose-PET scan (Case 1) shows right thalamic and ipsilateral occipital ischaemia. The occipital changes may be primary or secondary to reduced activity of its afferent pathway from the thalamus. There was no visual field defect and the MRI scan had shown only a tiny speck of thalamic gliosis.

spontaneously. A few months later she had her first episode of hallucinosis, which then recurred roughly monthly. A typical episode started with an aura of nausea, vomiting and occasionally vertigo. This would last up to 5 min and she tried to lie down. On three occasions, when she had not been able to make herself safe, she sustained falls with fractures. She described four tall men—so tall she could not see their heads—in pinstripe suits. Two were on either side of her. Their hands were pink, though they appeared to be made only of bones. In front of her was a large pit filled with coloured, shiny snakes, including dancing cobras. The men tried to throw her into the pit and the snakes tried to coil around her legs. On one occasion the men managed to get her into the pit and it immediately turned into a tunnel with a golden gate at the end. During the hallucination, which lasted 30–150 min, she was unable to see anything around her.

Two episodes were observed in hospital. They started with a complaint of headache. Then she would stare, retch and vomit. There were tremors of both arms and she started to talk about monsters. She was in a dream-like state, with diminished responsiveness, but she was not unconscious. Her husband described her trying to grab his neck, especially if he tried to put her to bed and she would shout: 'I don't want to go!'. After the episode she felt sick with a severe left-

sided headache; the nausea was severe, and she tried to go to sleep. On one occasion, when she awoke, she told her husband: 'There they are again!'

She had a persistent, milder headache between episodes. There was also a history of sudden-onset bilateral, transient blindness. Treatment with anti-epileptic drugs was of no benefit. Examination showed a mild right hemiparesis but visual fields were full. CT scan showed a markedly dilated left lateral ventricle with the septum pellucidum deviating to the right but no other abnormality. A metrizamide ventriculogram showed a diverticulum, which protruded through the incisura into the posterior fossa, compressing the brainstem from above. Visual evoked responses were normal. An EEG conducted during one of the episodes, showed mainly artefact. Monitoring of the pressure of the left lateral ventricle yielded low values, mostly 0–1 cm of water with a single rise to 8 cm. Ventriculoscopy showed no evidence of a lesion, and a diagnosis of loculated ventricle was made. A small hole was made in the septum pellucidum. This was followed by resolution of her preoperative hallucinations, but she developed a severe amnesic state with confabulation, indistinguishable from Korsakoff's syndrome. These changes were long-lasting but there was eventually some improvement in her memory. CT scan did not show reduction in the shift identified preoperatively. Stereotyped hallucinations involving her mother also developed postoperatively, but were less well described.

Comment. The aetiology of this woman's complex visual hallucinations probably related to midbrain distortion due to ventricular loculation. They were episodic and associated with headache, and migraine may also have been involved. Her postoperative Korsakoff's syndrome was probably due to disconnection and interference with the function of the mamillary region.

Peduncular hallucinosis was originally described by Lhermitte in association with a rostral brainstem lesion (Lhermitte, 1922). It is characterized by striking visual images very similar to hypnagogic hallucinations (for cases and references, see the Appendix). Hallucinations generally start a few days after infarction and subside a few weeks later, but they may persist for years. The hallucinations usually last minutes to several hours, but in some cases, they may persist throughout waking. The most common diurnal pattern is for hallucinations to disappear through the day then recur each evening. They are occasionally accompanied by tactile and auditory hallucinations. There is often an associated disturbance of consciousness, and abnormally vivid dreams may occur, with peculiar states of inaccessibility. Patients usually have insight into the hallucinations, and once they understand the phenomenon, they cope with it well, without features of paranoia or psychiatric disturbance (Baska, 1992).

Lesions causing peduncular hallucinosis

The aetiology is most commonly vascular and the site of the lesion is generally in the rostral brainstem. These cases seem

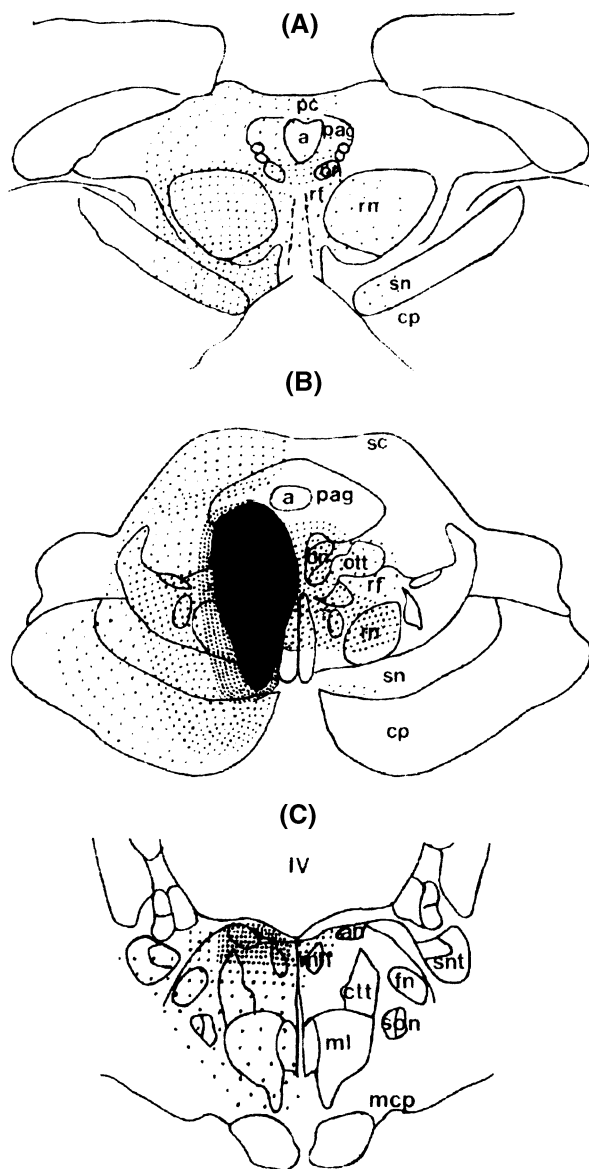


Fig. 2 Representative horizontal sections through the brainstem at the level of (A) the posterior commissure, (B) the oculomotor nucleus and (C) the abducens nucleus, showing sites of lesions causing peduncular hallucinosis documented by neuroimaging or pathology. The greater the density of dots, the more reports of lesions affecting that area. a = aqueduct; an = abducens nucleus; cp = cerebral peduncle; ctt = central tegmental tract; fn = facial nucleus; IV = fourth ventricle; ml = medial lemniscus; mlf = medial longitudinal fasciculus; mcp = middle cerebellar peduncle; on = oculomotor nucleus; pag = periaqueductal grey matter (includes raphe nuclei); pc = posterior commissure; rf = reticular formation; rn = red nucleus; sc = superior colliculus; son = superior olivary nucleus; sn = substantia nigra; snt = spinal nucleus and tract of trigeminal nerve. Lesions appear to be concentrated in the paramedian reticular formation from pontine to midbrain levels, with the maximum density of lesions in the midbrain, close to the level of the oculomotor and raphe nuclei.

to have in common an effect on the brainstem reticular formation or its targets in the thalamus (Appendix and Fig. 2). These locations are all the more surprising in that the

lesions do not directly involve the retinogeniculocortical system, which is generally considered to be required for the appreciation of complex form and colour.

Lesions restricted to the thalamus have been described. They have included the pulvinar and medial thalamus, but medial thalamic lesions usually also include rostral brainstem structures (Castaigne *et al.*, 1981; Bassetti *et al.*, 1996). Additional cases have lesions which appear to be restricted to the region of the cerebral peduncle, but in this situation they are also likely to affect the nucleus reticularis thalami and the substantia nigra. One case, examined pathologically, revealed lesions restricted to the substantia nigra pars reticulata. The nigra pars reticulata receives inputs from both serotonergic raphe neurons and cholinergic cells of the pedunculopontine tegmental nucleus (Jackson and Crossman, 1983; Beninato and Spencer, 1987) and sends reciprocal efferents to the pedunculo-pontine tegmental nucleus and reticular formation as well as to the parafascicular nucleus of the thalamus. The nigra pars reticulata is thus closely connected to nuclei more commonly implicated in peduncular hallucinosis (Beckstead *et al.*, 1979; Beckstead, 1983).

Hallucinations in Parkinson's disease

Case 3

A 68-year-old man had an 11-year history of Parkinson's disease. This initially manifested as tremor and stiffness of his right arm. He was treated with levodopa, with a good response for 7 years. Subsequently it became more difficult to control his symptoms, which had become bilateral. Adjusting his medication, with increased dose of levodopa or dopaminergic agonists, resulted in disabling dyskinesias. At the age of 67 years, he underwent a left pallidotomy. On the days following surgery he experienced hallucinations of a school of fish swimming around him. These eventually disappeared. The dose of levodopa was then increased gradually. Four months later he was admitted with disabling dyskinesias and the dose of levodopa was reduced. Three weeks later, whilst watching television, he became unresponsive. His wife noted his eyes were closed and he appeared not to be able to open them. When he opened his eyes, the furniture appeared to be skewed and for 30 min there seemed to be numerous cats in the room with them. They were black or brown and moved silently around the room. One jumped onto his knee and he was able to stroke it; he later recalled the sensation of its fur. The same hallucination recurred almost daily, at any time of day, but it was most common in the early morning or evening. During subsequent similar episodes, his wife noted that he appeared to be petting something at his feet. This hallucination was associated with reduced awareness and responsiveness, but not unconsciousness, and usually lasted 1–3 h. On another occasion the Pope appeared with him whilst travelling in the car and talked to him for up to 2 h.

At the time of interview, between hallucinations, he

understood they were not real, but when they were present, his behaviour suggested he did not have full insight. He noted that his sleep was disturbed by vivid dreams and often, on waking, he would appear to be unresponsive with his eyes closed for 30 min. He would have no recall of this time and would not be able to repeat what had been said to him. It did not appear to be a motor 'off' phenomenon, since he was not always rigid and it did not respond to levodopa. The hallucinations often occurred during these episodes, but could also occur at other times too. Between episodes, he showed evidence of mild to moderate cognitive impairment. Investigation with EEG showed no significant abnormality, but we were unable to record during hallucinations or his unresponsive state with ambulatory EEG. His MRI scan showed only the pallidotomy lesion. Cautious reduction of levodopa produced an amelioration of the hallucinations and a slight reduction in the associated unresponsiveness.

Comment. Ball (1882) was the first to suggest that psychiatric disturbance could be part of the clinical picture of Parkinson's disease. Hallucinations were not reported until specific treatments were tried, first anticholinergic agents (Porteous and Ross, 1956), then levodopa and dopaminergic agonists (Celesia and Barr, 1970; Damasio *et al.*, 1971; Sacks *et al.*, 1972; Sweet *et al.*, 1976; Rondot *et al.*, 1984; Horowski, 1986).

Our case illustrates the severe problems experienced by some patients with Parkinson's disease who receive levodopa. The hallucinations typically start after ~10 years of medication, are influenced directly by the dose of therapy and are remarkably similar to those of peduncular hallucinosis. They typically occur at the end of the day and insight is usually preserved. They are associated with sleep disturbances, vivid dreams and episodes of altered arousal (Sanchez-Ramos *et al.*, 1996). Dopaminergic agonists are much less likely to cause hallucinations when used for other indications, such as hyperprolactinaemia (Turner *et al.*, 1984). This may, in part, be because Parkinson's disease patients tend to be older, but also because the pattern of pathophysiology in Parkinson's disease predisposes to the hallucinatory effects of these drugs.

This begs the questions: (i) in what way do the pathological changes of Parkinson's disease resemble those of peduncular hallucinosis; and (ii) does levodopa alter the neurochemical changes of Parkinson's disease to mimic those in peduncular hallucinosis (see next section)? The pathology of Parkinson's disease is now recognized to extend beyond the nigrostriatal system (Jellinger, 1990), with widespread brainstem changes, affecting various neurotransmitter systems and overlapping with peduncular hallucinosis. There is substantial loss of the noradrenergic neurons of the locus coeruleus and serotonergic neurons of the raphe nuclei, especially in the dorsal raphe and the cholinergic parabrachial and pedunculopontine nuclei of the brainstem tegmentum (Halliday *et al.*, 1990; Jellinger, 1990; Duyckaerts *et al.*, 1993). In Parkinson's disease, subtle deficits of visual pathways have also been described, and are

attributed to dopamine deficiency in the retina and perhaps also in central pathways. Addition of levodopa corrects these abnormalities, probably improving the function of the visual system (Bodis-Wollner, 1990); a direct toxic effect of levodopa on vision, therefore, seems most unlikely as a cause of hallucinations.

In more recent years, a group of patients with Lewy body dementia has been identified. These patients appear to have the pathological hallmark of Parkinson's disease with greater cortical involvement. A distinctive clinical characteristic of this disease is the high incidence of complex visual hallucinations, even without levodopa treatment (Gibb, 1989; Kosaka, 1993). Even patients with Alzheimer's disease who hallucinate, are more likely to have cortical Lewy bodies than those who do not suffer hallucinations (McShane *et al.*, 1995). As well as extensive cortical abnormalities, patients with Lewy body dementia have more severe pathological changes in the brainstem than those with uncomplicated Parkinson's disease.

Hallucinations associated with migraine and migraine coma

Case 4 (reported previously in Andermann, 1987)

This 22-year-old girl had a history of severe occipital, migrainous headaches since childhood, with an aura of flashing white spots. At the age of 15 years, she developed seizures associated with vivid visual hallucinations of a stranger. This person wore white flowing robes and told her she was bad. The attacks responded to carbamazepine. At the age of 21 years she developed prolonged visual and auditory hallucinations, usually when she was reading or sitting quietly. She saw a crowd of >100 people, some dressed in white. They talked rapidly and she could not understand what they were saying, but they were not threatening. The hallucinations lasted many minutes and were not associated with any headache or motor seizure activity. They disappeared when she put on some music or changed her activity. Her EEGs showed bilateral-occipital and multiple spike and slow-wave bursts increasing on hyperventilation and sensitive to photic stimulation. The discharges tended to block with eye opening.

Comment. This case illustrates prolonged visual hallucinations, resembling peduncular hallucinosis, arising in a patient manifesting the common association between occipital epilepsy and migraine. Although there was no electrographic recording during the ictus in this case, even EEG may be misleading in these cases, with epileptiform abnormalities occurring during migraine aura (Beaumanoir and Jekiel, 1987). These prolonged hallucinations were unlike the fragmentary visual hallucinations associated with epilepsy (see below and Gloor, 1990). The overall clinical impression was that they were more likely to be related to her migraine than her epilepsy.

Case 5, migraine coma

A woman (seen at the age of 53 years) had suffered hemiplegic migraine since her teens, in association with mild cerebellar dysfunction, a syndrome described previously (Codina *et al.*, 1971; Zifkin *et al.*, 1980). For the previous 5 years they had been well controlled with pizotifen. For 3 weeks prior to admission she complained of intermittent right-sided headaches, lasting up to 2 days. These were associated with numbness, usually on the left side of her face. During admission she became somnolent and confused with high fever and hemiparesis, for 48 h. On recovery, she described small, silent, white dogs running around her room. They resolved over 2 days. Once she realized they were hallucinations, she was perplexed by them, but not unduly distressed. A CT scan was normal. Her EEG, during admission, showed a severe generalized slow-wave abnormality. PET of the brain showed diffuse reduction of glucose utilization in both hemispheres. As she was recovering after another episode, she described a tree, a horse and people. These were brightly coloured and silent. As in the previous episode, these disappeared over 1 day. Her son suffered hemiplegic migraine with classical visual aura, also in association with mild, persistent cerebellar abnormalities. He too developed complex visual hallucinations during recovery from hemiplegic episodes.

Comment. Migraine is well recognized as a cause of simple visual hallucinations, but complex visual hallucinations are much rarer. They are seen more frequently in migraine coma and in familial hemiplegic migraine. This syndrome is distinctive in its pattern of inheritance, clinical pattern, severity of symptoms and associated cerebellar signs. The complex visual phenomena were at a late stage of the attack, during recovery, rather than as an aura, at the onset of the headache. This may reflect different pathophysiology from commoner migraine syndromes; familial hemiplegic migraine is due to defects of the calcium channel (Ophoff *et al.*, 1996). There is no clearly defined pathological change in most cases of migraine, but spreading depression of cortical activity, with parallel changes in blood flow, may be important in the generation of the aura (Leao and Morrison, 1945; Lauritzen, 1987; Lance, 1993; Leao and Welch *et al.*, 1993; Cutrer *et al.*, 1998).

Visual hallucinations in schizophrenia

Visual hallucinations are probably more common in schizophrenia than traditionally thought (Goodwin *et al.*, 1971; Bracha *et al.*, 1989; Mueser *et al.*, 1990; American Psychiatric Association, 1994). Animals and figures may be prominent, but a delusional or hyper-religious character is often present, that is not usually seen in organic causes (Small *et al.*, 1966). Schizophrenic hallucinations are also usually in colour (Goodwin *et al.*, 1971) and may be Lilliputian (Lewis, 1961), and in these cases the hallucinated figures may be felt to be inside the subject's internal organs.

As the illness progresses, the clarity of the hallucination may deteriorate (Lewis, 1961).

It is difficult to find criteria that clearly differentiate the clinical characteristics of schizophrenic hallucinations from organic causes and hallucinations of manic depression may be even more akin to those of organic disease (Lowe, 1973). In organic disease, visual hallucinations often occur without auditory hallucinations. Schizophrenics rarely suffer visual hallucinations alone, though they may accompany commoner auditory hallucinations, especially in acute disease and in certain cultures (Frieske and Wilson, 1966; Goodwin *et al.*, 1971; McCabe *et al.*, 1972; Zarroug, 1975; Ndetei and Singh, 1983). Other associated clinical characteristics may be the most useful in differentiating schizophrenic from organic visual hallucinations. In organic disease they are more often nocturnal and are associated with drowsiness, whereas in schizophrenia they are often present throughout waking hours and are associated with hyper-arousal. In organic cases there is usually more insight, with less paranoia and thought disorder, and the hallucinations carry less 'personal significance' than in schizophrenia (Frieske and Wilson, 1966).

Hallucinations associated with visual loss

Charles Bonnet syndrome is characterized by complex visual hallucinations occurring in the context of ocular pathology causing visual deterioration, most commonly macular degeneration. In the largest study of the condition to date (Teunisse *et al.*, 1996), hallucinations occurred in 10% of patients with severe visual loss, generally in the elderly. These hallucinations are rarely stereotyped and they have many of the features of hypnagogic hallucinations, i.e. vivid images of animals and figures and can last for hours (Lalla and Primeau, 1993). They generally occur with the eyes open and usually in the evening or at night but do not appear to be just illusions triggered by low lighting levels. Most patients have full insight and are not generally distressed by them. Many can stop their hallucination by such manoeuvres as closing or opening their eyes, fixing vision on or away from the hallucination, suggesting it does not have a simple relationship to visual input (Teunisse *et al.*, 1996). Others have found that hallucinations fall into two categories; brief ones that occur when the patient is alert and longer ones, more like peduncular hallucinosis that occur when the patient is drowsy (Schultz *et al.*, 1996).

The disturbed visual input may cause hallucinations by an abnormal release of central processing (Taylor *et al.*, 1932; Cogan, 1973). The level at which the release occurs is not clear. It may not simply be due to withdrawal of physiological input, since secondary chemical and structural changes have been observed in the lateral geniculate nucleus of patients with optic nerve lesions or chronic glaucoma (Chaturvedi *et al.*, 1993; Rango *et al.*, 1995). Although visual loss is more common in the elderly, the significant predominance of elderly patients (Schultz and Melzack, 1991) raises the

possibility that the hallucinations are more likely to occur in individuals with macular disease, if they are superimposed on age-related degenerative CNS changes.

Hallucinations have also been described from lesions of the optic chiasm, radiation and, more commonly, the occipital cortex (Cogan, 1973; Lance, 1976; Serra Catafau *et al.*, 1992; Kolmel, 1993; Vaphiades *et al.*, 1996)

Hallucinations from posterior cerebral artery infarction

Case 6

A 55-year-old female psychiatric nurse presented with left-sided weakness of acute onset, associated with a feeling of running water down her left side. This had been preceded by 3 days of headache. She was noted to have a left hemianopia and a mild left hemiparesis. The day after admission she developed twitching of her left side associated with drowsiness. The movements settled with phenytoin and benzodiazepines, but the patient remained a little drowsy. During this phase, she described hallucinations affecting her left visual field. She described enormous snakes in vivid colours; she thought they were anacondas, thrashing about in a pool of water. These were seen intermittently over 1–2 days, lasting for hours at a time. At first she was distressed by them, but she soon realized they were not real and remained less affected. An MRI scan showed infarction throughout the territory of the left posterior cerebral artery territory, including occipital cortex and posterior thalamus. Over subsequent weeks the visual field defect contracted.

Case 7

A 54-year-old company director presented with excruciating headache waking him at night. There was a past history of migraine with visual aura, but the current headache was more severe and was not associated with nausea. Seven years earlier he had suffered a road traffic accident with multiple fractures to his left arm and leg, and loss of function in his left arm. On the current admission, he was drowsy with a left homonymous hemianopia and mild left sensory inattention. He was hypertensive (230/110) and funduscopy revealed arteriovenous nipping. A CT scan showed left posterior cerebral artery territory infarction. Over the next few days he experienced visual hallucinations in his left hemifield, lasting hours at a time, consisting of hedgehogs and small brown rodents crawling over the ceiling above him. These recurred particularly when he was drowsy and, although they distressed his wife, he found them curious and amusing. They continued intermittently for 2 weeks, up to the time of writing.

Comment. In these two patients, both occipital cortex and visual thalamus suffered infarction. In other cases the hallucinations may be due to pure occipital infarction.

Typically, the hallucinations are restricted to the abnormal visual field. Ischaemia usually underlies the cortical lesions and there is usually a delay of days to weeks between the ischaemic event and the onset of hallucinations. The hallucinations are usually transient, lasting days or weeks, but they may be more persistent and are restricted to the visual modality unless non-visual cortex is also involved (Vaphiades *et al.*, 1996). The lesions causing this phenomenon are significantly smaller than those that cause a hemianopia, without any hallucinations (Vaphiades *et al.*, 1996). This suggests that some intact cortex with visual processing capacity is required to express hallucinations, supporting the concept of a release phenomenon. In most cases there is no disorder of arousal or dreams. In more anterior lesions, affecting the occipito-temporo-parietal cortex, dreams and daytime imagery may be lost (Solms, 1997b), suggesting a possible double dissociation.

Complex visual hallucinations in focal epilepsy

Epileptic visual hallucinations are generally very different from those of the prolonged hallucinatory states described above. They are usually brief, stereotyped and fragmentary and may be associated with other seizure manifestations, such as experiential phenomena, altered awareness, motor activity and automatisms. Figures are unlikely to be identified, and may appear in colour or black and white. Complex visual hallucinations, more similar to hypnagogic hallucinations, have also been described, but they are rare. They may be prolonged as a form of non-convulsive status epilepticus, and if occurring during sleep may be interpreted as dreams (Sowa and Pituck, 1989; Walker *et al.*, 1995; Solms, 1997a). If the images are restricted to one visual field, they have lateralizing value for the underlying visual disturbance. They appear to have similar localization and pathophysiological significance to other epileptic visual hallucinations.

Strong evidence, including intracranial EEG recordings and direct cortical stimulation experiments shows that pathological excitation of visual cortical areas is responsible for epileptic, complex visual hallucinations, especially that involving posterior parietal or temporal association cortex (Taylor *et al.*, 1931; Penfield and Jasper, 1954; Ritchie Russell and Whitty, 1955; Penfield and Perot, 1963; Salanova *et al.*, 1992; Williamson *et al.*, 1992). A key feature of epileptic hallucinations is, therefore, that the visual association cortex is both necessary and sufficient for this phenomenon. This is supported by focal cortical resections resulting in complete remission (Penfield and Jasper, 1954; Penfield and Perot, 1963; Williamson *et al.*, 1992).

Neuropharmacology of complex visual hallucinations

Drug-induced hallucinations

Alcohol, barbiturate and benzodiazepine withdrawal

Acute alcohol withdrawal is a well-recognized cause of visual hallucinations, which are more common in chronic alcoholics

but may occur in occasional 'spree' drinkers (Victor and Adams, 1952). Delirium tremens has been induced experimentally in individuals unaccustomed to habitual alcohol consumption (Isbell *et al.*, 1955). This suggests that delirium tremens occurs without fixed pathology and is entirely due to metabolic derangement. It usually starts during the period of declining blood ethanol levels, or shortly thereafter. The first symptom is typically tremor, followed by intermittent, brief visual hallucinations, initially without alteration of consciousness. These may lead to profuse, almost continuous visual hallucination, occasionally associated with hallucinations in other modalities. The hallucinations are typically of animals of normal size (celebrated pink elephants), although Lilliputian hallucinations may also occur. Patients often accept them as real at this stage, but find them non-threatening (Fasullo and Lupo, 1973; Lipowski, 1980). In the earlier stages there are arousal, insomnia and nightmares, which may evolve into continuous, sleepless agitation, the patient talking to imagined people and plucking at imagined objects. Autonomic disturbance is common, especially tachycardia and pyrexia. Generalized convulsions occur in a small proportion of cases, and the hallucinated and agitated state may last several days.

Barbiturates and benzodiazepines cause a chronic dependence state, and sudden cessation is associated with many features in common with alcohol withdrawal: tremor, insomnia, anxiety, autonomic hyperactivity, visual hallucinations and seizures (Isbell *et al.*, 1950; MacKinnon and Parker, 1982). Both groups of drugs prevent the development of alcoholic delirium tremens and are recommended treatments (Hemmingsen *et al.*, 1979). Both also act at the GABA receptor site, although by different mechanisms. This close relationship suggests that alcohol withdrawal is related to deficient CNS inhibition, although alterations in monoamines may be important in the agitation, sleeplessness and autonomic changes (Kraus *et al.*, 1985; Baumgartner and Rowen, 1987; Nevo and Hamon, 1995).

Hallucinogenic drugs

There is a linear correlation between serotonergic activity of hallucinogens and their hallucinogenic potential (Glennon *et al.*, 1984). The prototypic hallucinogens mescaline and lysergic acid diethylamine tartrate (LSD) cause hypnagogic-type hallucinations and are agonists at 5-hydroxytryptamine (5HT₂) receptors, despite differing chemical structures. Hallucinations may start with coloured patterns, visual distortions and geometric shapes with features suggesting visual illusions, and progress to include figures of animals and people, sometimes with size distortions and a feeling of fantasy with heightened sensory arousal (Bliss and Clark, 1963; Young, 1974). Mitchell (1896) described his own mescaline induced hallucinations as more vivid than real life and occurring mainly when relaxed and supine with eyes closed. He was observer rather than participant in the visions and they did not cause particular emotional reactions. Insight

is usually preserved and thought disorder or psychosis are not major features (Malitz *et al.*, 1963; Rosenthal, 1964; Aggermaes, 1972). The hallucinations also lack the symbolism of those in schizophrenia, not being incorporated into a framework of delusional thinking (Hollister, 1962). LSD-induced visual hallucinations most commonly occur without auditory hallucinations (Bliss and Clark, 1963), again contrasting sharply with psychoses and resembling peduncular hallucinosis. LSD is particularly active on the serotonergic neurons of the median raphe, which are usually involved in the pathology of peduncular hallucinosis, and on postsynaptic 5HT₂ receptors distributed in the middle layers of the cerebral cortex. Antagonists with action on serotonergic systems may block these effects.

The hallucinations due to amphetamine and cocaine more commonly include auditory hallucinations and more closely resemble schizophrenia with paranoia (Johnson and Milner, 1966; Angrist *et al.*, 1974). There are differences, however, with less thought disorder and more frequent agitation than in schizophrenia, although blunted emotion is also well recognized (Griffith, 1977). Cocaine acts at 5HT₃ receptors, which tend to be concentrated in the limbic system, and also at dopamine and catecholamine receptors (Lewander, 1977). There is no cross-tolerance of its effects with LSD, supporting a different mechanism of action (Jacobs and Azmitia, 1992).

Pharmacology of hallucinations in Parkinson's disease and Lewy body dementia

Early studies suggested that a confusional state frequently accompanied levodopa-induced hallucinations in Parkinson's disease, but doses of medication used in these studies were high, sometimes 4–5 g/day (Sacks *et al.*, 1972; Sweet *et al.*, 1976; Rondot *et al.*, 1984). With lower doses, the patient was more likely to hallucinate in clear consciousness, and a reduction in the dose of levodopa could often eliminate confusion and hallucinations. One study found that methysergide (a 5HT₁ and 5HT₂ antagonist) was helpful in preventing hallucinations (Nausieda *et al.*, 1983). More recently it has been found that the hallucinations can be treated effectively with the atypical neuroleptic, clozapine (dopamine D₄ and 5HT₂ antagonist), risperidone (5HT₂ and D₂ antagonist) and ondansetron (selective 5HT₃ antagonist) (Kahn *et al.*, 1991; Kuiper *et al.*, 1994; Meco *et al.*, 1994).

There is also evidence of significant cholinergic dysfunction in patients with Parkinson's disease who hallucinate. They are more likely to be older and to have cognitive impairment, than those who do not hallucinate (Sacks *et al.*, 1972; Meco *et al.*, 1990). They are especially sensitive to anticholinergic agents; they may suffer adverse cognitive effects at doses that do not affect age-matched control subjects (de Smet *et al.*, 1982; Dubois *et al.*, 1987, 1990). In those with cognitive decline there is loss of cholinergic neurons from the basal nucleus of Meynert (which provides diffuse cortical cholinergic input), similar in scale,

but different in nature, to that seen in Alzheimer's disease. Whether this can entirely explain their dementia remains unclear; some authors also emphasize the importance of brainstem changes (Gibb, 1989; Jellinger, 1990; Xuereb *et al.*, 1990; Hughes *et al.*, 1993; Kosaka, 1993). This is pertinent in relation to peduncular hallucinosis in which very similar hallucinations are due to a primary pathology in the brainstem. The basal forebrain nuclei also send excitatory cholinergic projections to the brainstem cholinergic system and thalamic reticular nucleus (Parent *et al.*, 1988); there may be an indirect modulation of the function of the reticular formation, which is also disturbed by pathology in the basal forebrain.

Others have also demonstrated a particularly marked reduction in choline acetyl transferase in the cerebral cortices of patients with Lewy body dementia and visual hallucinations. This may be seen as a significantly higher ratio of serotonin to acetylcholine than in control subjects (Perry *et al.*, 1990; Cheng *et al.*, 1991). The greatest changes were seen in temporal and parietal cortex, likely sites for expression of complex visual hallucinations. This is an attractive hypothesis, since (i) anticholinergic agents would reduce cholinergic effects still further, so explaining their hallucinogenicity, and (ii) serotonergic antagonists would help correct the imbalance, so explaining their therapeutic effect. A selective serotonin re-uptake inhibitor has also been reported to cause hallucinosis in Parkinson's disease (Lauterbach, 1993), conforming to this model. But levodopa increases rather than decreases cortical acetylcholine levels and reduces cortical serotonin levels (Mantovani and Pepeu, 1978; Schmidt *et al.*, 1991). It seems unlikely that levodopa causes hallucinations by a simple perturbation of the serotonin : acetylcholine ratios as in this model, although it increases in the 5-hydroxyindoleacetic acid to 5HT ratio, suggesting there may be some increase in turnover of 5HT (Nausieda *et al.*, 1983; Perry *et al.*, 1993).

The relationship between cholinergic and serotonergic systems was reviewed recently (Steckler and Sahgal, 1995). The actions of 5HT on the cerebral cortex are most commonly inhibitory, whereas acetylcholine is generally excitatory (Foote and Morrison, 1987). The interactions are made more complex by the multiplicity of serotonin receptors. They may be both presynaptic and postsynaptic and there are reciprocal connections between serotonergic and cholinergic systems, especially between the raphe nuclei and the pedunculopontine tegmental nucleus, which are often affected in peduncular hallucinosis (Jellinger, 1990) (Fig. 2). There are extensive short loop pathways in the brainstem whereby serotonergic neurons modulate the activity of other serotonergic cells (Bliss and Clark, 1963). A key feature is that the effect of experimental manipulations on the action of serotonergic systems in the brain depends on whether the serotonergic pathways are intact or damaged. In intact animals, exogenous serotonin decreases activity at postsynaptic 5HT₃ receptors by acting primarily on presynaptic 5HT_{1A} receptors. But if serotonergic neurons are lost, as in peduncular hallucinosis or advanced Parkinson's disease, the predominant effect on

presynaptic inhibitory autoreceptors means the action of serotonin at postsynaptic 5HT₃ receptors may be paradoxically increased, despite a reduction in total serotonin content. This could be exacerbated by increased turnover due to levodopa, explaining the apparent discrepancy of reduced serotonin levels in levodopa-treated Parkinson's disease and efficacy of serotonin antagonists in treatment. In addition, *in vivo*, increase in action of acetylcholine is mediated by presynaptic serotonergic autoreceptors, and if serotonergic neurons are lost, the predominant effect is a reduction of acetylcholine levels, which may predispose to hallucinosis.

Hallucinations are relatively less common in Alzheimer's disease than Lewy body dementia. Although the cholinergic system is particularly affected in Alzheimer's disease, the cholinergic neurons of the pedunculopontine tegmental nucleus are spared and serotonergic neurons are also less affected than in Lewy body disease (Jellinger, 1990).

Drug treatment of other causes of visual hallucinations

Hypnagogic hallucinations of narcolepsy are best treated by monoamine oxidase inhibitors that have a powerful serotonergic effect and block rapid eye movement (REM) sleep, or by clomipramine or protriptyline, which delay onset of the first REM period and also influence 5HT₂ receptors (Wyatt *et al.*, 1971; Schmidt *et al.*, 1977; Hishikawa and Shimizu, 1995).

Much of the neurobiology of schizophrenia remains elusive (Chan, 1985; Carpenter and Buchanan, 1994; Chua and McKenna, 1995; Gold and Weinberger, 1995). The potency of drugs in the treatment of schizophrenia correlates very closely to dopamine D₂ antagonist activity, but abnormalities of the dopamine system are difficult to identify in the disease (Mackay and Iversen, 1992). Clozapine is an antipsychotic agent said to be especially effective against hallucinations and in schizophrenia refractory to dopaminergic agents. It has strong antiserotonergic activity, especially at 5HT₂ receptor subtypes, as well as dopamine D₄ antagonist activity. Clozapine resistance is associated with changes in the 5HT₂ receptor, suggesting this is a critical site of action (Williams *et al.*, 1997), and serotonin-dopamine interactions may be crucial in schizophrenia (for review, see Roth and Meltzer, 1995).

Migraine aura is blocked by pizotifen and methysergide (5HT₂ antagonists), but not by sumatriptan (5HT₁ agonist) which treats the headache. Brainstem aminergic structures, including the noradrenergic locus coeruleus and serotonergic dorsal raphe nucleus, may also affect cerebral blood flow (Lance, 1993), influencing spreading depression in migraine aura.

These many lines of evidence converge to support the importance of serotonergic mechanisms in visual hallucinations, most likely at 5HT₂ receptors, but these are influenced by the pattern of pathology, the activity of other

neurotransmitter systems and the interactions of serotonergic presynaptic and postsynaptic receptors.

Sleep mechanisms and disturbances in visual hallucinosis

Sleep disturbances are common in patients with vivid formed hallucinations (Table 1). Many reports of peduncular hallucinosis describe altered sleep and states of inaccessibility, but it is generally unclear to what extent they coincide with hallucinations (Lhermitte, 1922; Lhermitte and Levy, 1931; van Bogaert, 1924; Dunn *et al.*, 1983; Geller and Bellur, 1987; Feinberg and Rapcsak, 1989; Kolmel, 1991; Tsukamoto *et al.*, 1993; Nadvi and van Dellen, 1994). One recent report (Bassetti *et al.*, 1996) described two patients with symptoms suggestive of peduncular hallucinosis in the context of paramedian thalamic infarction. Both patients suffered hypersomnia with a marked increase in Stage 1 non-rapid eye movement (non-REM) sleep, a slight reduction in Stage 2 and marked reductions in Stage 3–4 sleep. There was relatively little change in REM sleep.

Sleep disturbances have been best characterized in narcolepsy–cataplexy syndrome. The cardinal symptoms of this condition (excess daytime sleepiness, sleep paralysis, cataplexy and hypnagogic hallucinations) seem to represent a breakdown in the co-ordination of the fundamental components of REM sleep: dreaming, atonia and sleep itself, with their intrusion into the waking state. Whereas normal individuals usually do not experience their first REM sleep period within the 90 min after sleep onset, patients with narcolepsy frequently enter REM sleep within 20 min of sleep onset. Hallucinations are related to this first REM, especially if its onset is rapid (Hishikawa *et al.*, 1978), and not to later REM episodes or total REM time, which is normal in narcolepsy (Hishikawa and Shimizu, 1995). In normal individuals, the first REM epoch arises out of deep non-REM sleep. Hallucinations may be a manifestation of going into REM from a relatively higher level of arousal (Hishikawa *et al.*, 1968). This would explain why these hallucinations only occur in the first REM epoch.

Most cases of the narcolepsy syndrome are constitutional but some are secondary to lesions of the pons and midbrain (Stahl *et al.*, 1980; Rivera *et al.*, 1986; Aldrich and Naylor, 1989; Autret *et al.*, 1994; D’Cruz *et al.*, 1994; Plazzi *et al.*, 1996), overlapping considerably with those causing peduncular hallucinosis. It seems likely that in these two situations, hallucinations share a similar pathophysiological basis. In idiopathic narcolepsy there is evidence of altered brainstem function. Increased brainstem blood flow has been shown during sleep, the reverse of that in normal individuals (Sakai *et al.*, 1979). During hypnagogic hallucinations, an increase has also been shown, especially in right parietal, occipital and posterior temporal cortex (Meyer *et al.*, 1980).

In most forms of hallucinosis, including Charles Bonnet syndrome, in which there is no direct CNS pathology,

hallucinations are most prominent at the end of the day. The patient in our Case 1 experienced hallucinations when drowsy but not at other times, even in darkness. There are patients with no perception of light, whose hallucinations also generally occurred in the evening (R. J. Teunisse, personal communication). This supports the importance of arousal and brainstem activity, rather than low levels of ambient lighting, in triggering hallucinations, even in patients whose primary pathology resides outside the brainstem. In the absence of visual input, brainstem structures are the major controlling influence on the firing of lateral geniculate neurons in the cat (McCarley *et al.*, 1983) and these are directly affected by alcohol and drugs. Enucleation increases the turnover of serotonin, a key neurotransmitter in hallucinosis, in the dorsal lateral geniculate nucleus (Vizuetto *et al.*, 1992).

It may not merely be a coincidence of anatomy that these two systems controlling arousal and causing hallucinosis are affected together in these disorders. An important component of sleep is the switching of thalamic relay nuclei out of waking relay mode, in which they faithfully transmit sensory inputs to the cortex, into sleeping burst mode, in which they do not. Brainstem connections to the midline thalamic nuclei and to the thalamic reticular nucleus are especially important for this function. Lesion studies have shown that structures within the pontine reticular formation are crucial for the generation of REM sleep, especially the nucleus reticularis pontis oralis (Jones, 1994). An abnormality could cause a sleep disturbance and abnormal cortical processing of sensory afferents. One mechanism by which this may occur is alteration of ponto-geniculo-occipital (PGO) waves, a specific pattern of electrical activity generated in animals in association with REM sleep (Hartmann, 1994). PGO waves appear 30–90 s before REM sleep but their precise role is unclear (Steriade *et al.*, 1989). PGO-related bursts are probably generated by the cholinergic pedunculopontine nucleus, and they are inhibited by serotonergic raphe nuclei (Ruch-Monachon *et al.*, 1976; Gaillard *et al.*, 1994). In the dorsal lateral geniculate nucleus, nicotinic and muscarinic cholinergic inputs are important in generating PGO spikes (Steriade *et al.*, 1989; Luebke *et al.*, 1992; Siegel, 1994), where they may be involved in modulating the phasic discharge of thalamic units (Laurent *et al.*, 1977). LSD induces hallucinatory behaviour in cats associated with an increase in eye movement potentials, which resemble ‘waking PGO waves’ (Jacobs *et al.* 1972). Barbiturates also suppress these waves and barbiturate withdrawal may lead to increased expression.

Poor sleep, frequent arousals and nightmares are common complaints of patients with Parkinson’s disease who are treated with levodopa. Various objective sleep disturbances have been reported in the untreated state, including reduced, unchanged or increased REM sleep and loss of REM atonia (for references, see Mouret, 1975; Myslobodsky *et al.*, 1982; Askenasy and Yahr, 1985). Since both the REM-generating cholinergic and the REM inhibiting serotonergic brainstem structures are affected by Parkinson’s disease, it is possible

that the balance of pathology in these structures varies from case to case, producing different effects on sleep. Levodopa and dopaminergic agonists, such as apomorphine appear to increase sleep fragmentation, reduce total sleep time and, especially, reduce REM sleep (Gillin *et al.*, 1973; Aldrich, 1994). In Parkinson's disease patients with hallucinations, a number of abnormalities have been seen when compared with control Parkinson's disease patients without hallucinations, matched for age, disease duration, motor function and treatment. These include reduced total sleep time and efficiency. There was a marked reduction in REM sleep (5 versus 20%) and an increase in motor activity during REM sleep, consistent with REM behaviour disorder (Comella *et al.*, 1993). These effects presumably reflect the increased pathology in brainstem structures controlling sleep, especially those generating REM sleep, and associated atonia, resulting in increased sensitivity to the effects of levodopa.

Hyper-arousal with reduced sleep is usually seen with drug-induced hallucinations, alcohol withdrawal and schizophrenia. The EEG in delirium tremens may show a curious pattern with rapid eye movements during Stage 1 sleep (Kaneko and Hishikawa, 1981). This may reflect a breakdown of the co-ordination of the components of REM sleep, analogous to that in the narcolepsy-cataplexy syndrome.

Corticothalamic mechanisms in the generation of complex visual hallucinations

Two neurotransmitters that appear to be particularly important in visual hallucinations, serotonin and acetylcholine, are concentrated in the visual thalamic nuclei and visual cortex rather than in regions involved in other sensory modalities (Morrison and Foote, 1986; Fitzpatrick *et al.*, 1989; Parent, 1996). Thus the predominance of visual hallucinations over other sensory modalities can be reconciled with potentially important cholinergic-serotonergic interactions in either visual thalamus or visual cortex but does not differentiate between these two sites.

Cortical involvement

Several lines of evidence point to a release of inhibition of association cortex being central to many forms of complex visual hallucinosis.

(i) There is strong evidence that the complex visual hallucinations of epilepsy are due to pathology affecting visual association cortex. In contrast, nearly all the reported cases of complex visual hallucinations following stroke are due to occipital infarction, rather than commoner middle cerebral artery infarctions, and there appears to be a double dissociation of lesions underlying hallucinations and those causing loss of visual imagery in which association cortex is affected. These differences are consistent with the hypothesis that epilepsy stimulates the visual association

cortex directly, whereas hemianopic strokes release it from a distance. One possible pathway of this release is by loss of direct corticocortical inputs (Jones and Powell, 1970). An alternative is by loss of the substantial striate cortex control of thalamic inputs to the visual association cortices.

(ii) A key feature of Lewy body dementia that differentiates it from Parkinson's disease (unaccompanied by hallucinations in the absence of treatment) is the extent of cortical involvement with cholinergic and serotonergic changes, especially in the association cortex (Perry *et al.*, 1991; Kosaka, 1993).

(iii) 5HT₂ receptors (the main target of LSD and mescaline) are especially concentrated in the cerebral cortex (Steckler and Sahgal, 1995). Serotonergic neurons vary their activity in relation to the state of arousal. They have intrinsic rhythmicity and generally discharge slowly. Many neurons do not make specific postsynaptic contacts. These characteristics suggest that serotonergic neurons are unlikely to be important in the transfer of specific sensory information in visual hallucinations. They are much more likely to have a modulatory effect on the activity of sensory pathways and cortical responses (Jacobs and Azmitia, 1992), perhaps explaining the interaction of visual pathway and brainstem disturbances in the generation of visual hallucinations.

Thalamic involvement

Both the dorsal lateral geniculate nucleus and lateral pulvinar are under brainstem control and act as a junction for the brainstem modulation of inputs to visual cortex. In support of this is the close relationship between hallucinations and alterations in sleep and arousal, which is another 'gating' function in which the same nuclei and transmitter systems are critical.

The dorsal lateral geniculate nucleus is the best understood thalamic visual area. A major electrophysiological effect of reticular formation stimulation on dorsal lateral geniculate nucleus cells is release from inhibition and release from the control of retinal afferents (reviewed in Singer, 1977). The extensive cholinergic and serotonergic inputs from the brainstem to the dorsal lateral geniculate nucleus are both direct and indirect (via the reticular nucleus of the thalamus) (Fig. 3). The cholinergic input, from the parabrachial nucleus and the parabrachial nucleus, is excitatory both directly to dorsal lateral geniculate nucleus and also by inhibiting the GABAergic inhibitory input from the reticular nucleus of the thalamus (Pasik *et al.*, 1990; Wilson, 1993). The serotonergic input, from the dorsal raphe, inhibits cholinergic excitation, probably via 5HT₁ and 5HT₃ receptors and also suppresses responses to retinal inputs (Rogawski and Aghajanian, 1980; Kemp *et al.*, 1982). Therefore, the raphe lesion of peduncular hallucinosis may cause excitation of the dorsal lateral geniculate nucleus, at the same time reducing the fidelity of retinogeniculate transmission. This is an ideal combination for the generation of hallucinations. The same pathways are involved in the control of sleep and the fidelity of

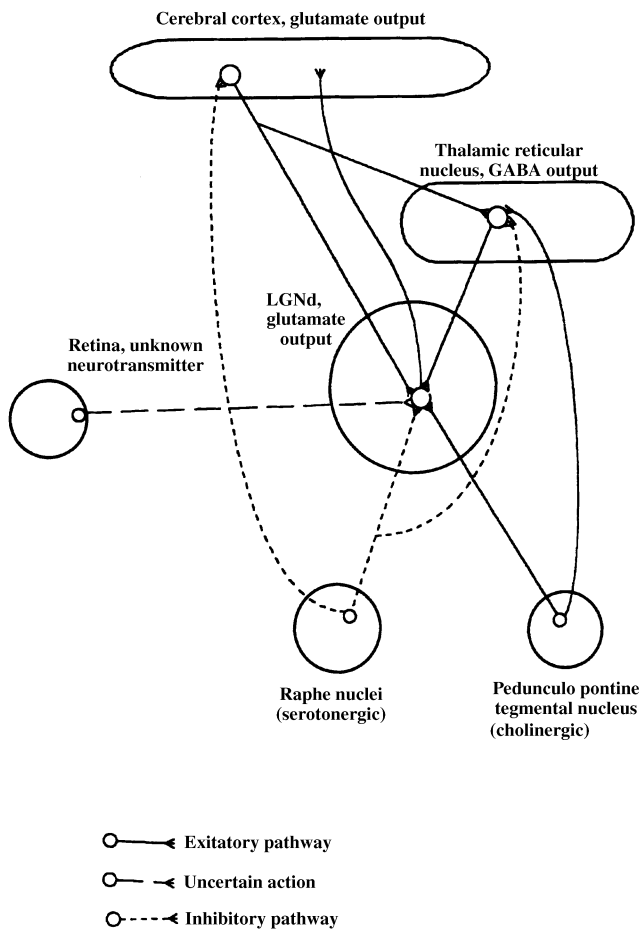


Fig. 3 Schematic diagram of dorsal lateral geniculate nucleus (LGNd); projections to the cerebral cortex are modulated by raphe serotonergic input and cholinergic input. Lesions of the raphe nuclei may produce disinhibition of the dorsal lateral geniculate nucleus and impair the fidelity of retino-geniculo-cortical transmission. The same pathways appear to be important in switching between sleep stages. Brainstem lesions may also modulate association cortex activity directly via serotonergic connections to the middle layers of the visual association cortex. (See text for full explanation.)

geniculostriate transmission also depends on sleep-stage. The level of arousal may, therefore, be particularly important in determining the occurrence of these hallucinations, and a sleep disturbance would be a common accompaniment.

A recent study suggested that a variety of (non-visual) positive symptoms may be related to pathological burst patterns of neurons in the thalamus, produced by calcium spikes when thalamic cells are in the hyperpolarized state (Jeanmonod *et al.*, 1996). Many of the lesions causing hallucinations could act on this mechanism by increasing inhibition in the thalamus. Corticothalamic, retinothalamic and cholinergic brainstem inputs are all excitatory to the thalamus, and lesions of any of these may predispose to the production of calcium spikes. As discussed above, serotonin reduces cholinergic excitation in the thalamus, and hallucinogens may also increase thalamic inhibition. Similarly, in Parkinson's disease, as well as effects on

brainstem nuclei, there is an increase in tonic inhibition of the thalamus from the pallidum, but whether this extends to visual thalamus is not clear. Slow-wave sleep is also thought to be manifest by low threshold calcium spikes, providing a mechanism for predisposing to these pathological effects at times of drowsiness (Tsoukatos *et al.*, 1997).

In an analogous situation, phantom limb hallucinations may occur in those with congenitally absent limbs, suggesting that the phenomenon may occur with release from the primary sensory pathway (Melzack *et al.*, 1997). Recent stimulation studies show that the thalamic representation of the limb remains functional after amputation (Davis *et al.*, 1998).

Although the dorsal lateral geniculate nucleus is the major projection nucleus to the striate cortex, the pulvinar lateral posterior complex is also important in visual processing, having reciprocal connections with extrastriate visual areas. Even with complete striate lesions, the response characteristics of neurons in the middle temporal gyrus to visual stimuli is relatively unchanged (Girard *et al.*, 1992). A much greater change is seen if there is a simultaneous superior colliculus lesion. The superior colliculus influences this cortical region via the pulvinar complex this centre may be important in extrastriate visual function. The microscopic anatomy and chemoarchitecture of the pulvinar appear to be similar to the better studied dorsal lateral geniculate nucleus (Mathers, 1972; Hajdu *et al.*, 1974; Ogren and Hendrickson, 1979; Cusick *et al.*, 1993). The pulvinar receives direct retinal input (Cowey and Stoerig, 1991), also particularly dense cholinergic afferents, including those from the pedunculopontine tegmental nucleus, and serotonergic inputs from the brainstem raphe (Rodrigo-Angulo and Reinoso-Suarez, 1982; Morrison and Foote, 1986; Parent *et al.*, 1988; Fitzpatrick *et al.*, 1989). A function of the pulvinar may be to filter out irrelevant information, especially in relation to eye movements (Robinson and Petersen, 1992). A corruption of this function of serotonin in the thalamus might increase 'signal-to-noise ratio' in visual transmission and contribute to visual illusions or hallucinations.

Complex visual phenomena from simple lesions

Striking features of these visual images are their complexity, sophistication and similarity across different lesion sites and pathologies. An analogy may be seen in the experiential attacks of some patients with temporal lobe epilepsy, in which there is a complex interplay of hallucinatory experience, a strong affective component (usually fear) and a component of memory recall (Taylor *et al.*, 1931; Penfield and Perot, 1963; Halgren *et al.*, 1978; Gloor *et al.*, 1982; Bancaud *et al.*, 1994). Gloor used the example of temporal lobe epilepsy to provide an hypothesis to explain how non-physiological, epileptic activation of part of a functional neuronal network can result in an almost intact mental experience (Gloor, 1990). This concept of a distributed network is supported by

experimental data, in which similar responses were elicited by stimulation of frontal and temporal lobes (Fish *et al.*, 1993). The hypothesis finds its roots in Hughlings Jackson's 'dissolution of the CNS' (Taylor *et al.*, 1932). It may explain how different pathologies may produce similar cognitive effects by interfering with a neuronal matrix at different sites and how complex mental phenomena, such as formed visual hallucinations, may arise as a result of fairly blunt pathological insults, probably via a release of association cortex (Gloor, 1990). For example, brainstem pathology, outside the primary visual system, may act on thalamocortical relationships to generate vivid and complex visual hallucinations similar to those seen with direct lesions of afferent visual pathways.

Summary

Normal individuals may experience prolonged hypnagogic hallucinations prior to falling asleep. These are characterized by brilliant scenery, figures and animals, and insight is often preserved. Strikingly similar hallucinations are seen in lesions of the visual pathways, and in brainstem and thalamic lesions affecting the ascending reticular activating system. Evidence from chemical hallucinogens points to the importance of serotonin, probably acting via 5HT₂ receptors. Brainstem lesions associated with hallucinations tend to affect the ascending reticular activating system, including serotonergic pathways, and are often associated with a sleep disturbance. They include peduncular hallucinosis and secondary narcolepsy-cataplexy syndrome. Even in conditions in which hallucinations are not associated with sleep disorders, such as Charles Bonnet syndrome and occipital lesions, hallucinations are more likely to occur when the individual is drowsy, suggesting a role for the reticular activating system.

Smaller rather than larger occipital lesions tend to be associated with hallucinations, and more anterior association cortex lesions cause a loss of visual imagery. It appears that the capacity for generating hallucinations is in association cortex and that it is released by restricted lesions but prevented by larger or more anterior lesions.

We postulate that hallucinations in these pathologies share a release of visual association cortex, acting by loss of cortico-cortical inputs, and alteration of activity via effects on the reticular activating system, especially serotonergic inputs. These mechanisms may explain how such strikingly similar hallucinations may be produced by various pathologies at different sites.

Acknowledgements

We wish to thank Professor Ronald Melzack for his helpful advice with the manuscript and Dr Gislaine Savard for her interpretation of psychiatric aspects of the cases.

References

Aggernaes A. The difference between the experienced reality of hallucinations in young drug abusers and schizophrenic patients. *Acta Psychiatr Scand* 1972; 48: 287–99.

Alajouanine Th, Gopcevitch V. Hallucinoses préhypniques, automatisme ambulateur et verbal nocturne, éclipses confusionnelles paroxystiques chez une malade atteinte d'un syndrome parkinsonien postencéphalitique, avec syndrome Parinaud respectant les mouvements automatico-réflexes, et crises toniques des membres à type de crampes vespérales. *Rev Neurol (Paris)* 1928; 2: 714–8.

Alajouanine Th, Thurel R, Durupt L. Lesion protuberantielle basse d'origine vasculaire et hallucinose. *Rev Neurol (Paris)* 1944; 76: 90–1.

Aldrich MS. Parkinsonism. In: Kryger MH, Roth T, Dement WC, editors. *Principles and practice of sleep medicine*. 2nd ed. Philadelphia: W.B. Saunders. 1994. p. 783–8.

Aldrich MS, Naylor MW. Narcolepsy associated with lesions of the diencephalon. *Neurology* 1989; 39: 1505–8.

American Psychiatric Association. *Diagnostic and statistical manual of mental disorders (DSM-IV)*. 4th ed. Washington (DC): American Psychiatric Association; 1994.

Andermann F. Clinical features of migraine-epilepsy syndromes. In: Andermann F, Lugesesi E, editors. *Migraine and epilepsy*. Boston: Butterworths; 1987. p. 3–30.

Angrist B, Sathanathan G, Wilk S, Gershon S. Amphetamine psychosis: behavioral and biochemical aspects. *J Psychiatr Res* 1974; 11: 13–23.

Asaad G, Shapiro B. Hallucinations: theoretical and clinical overview. [Review]. *Am J Psychiatry* 1986; 143: 1088–97.

Askenasy JJ, Yahr MD. Reversal of sleep disturbance in Parkinson's disease by antiparkinsonian therapy. *Neurology* 1985; 35: 527–32.

Autret A, Lucas B, Henry-Lebras F, Toffol B. Symptomatic narcolepsies. [Review]. *Sleep* 1994; 17 (8 Suppl): S21–4.

Baillarger J. De l'influence de l'état intermédiaire à la veille et au sommeil sur la production et la marche des hallucinations. *Mem Acad de Med Par* 1846; 12: 476–516.

Ball B. De l'insanité dans la paralysie agitante. *Encephale* 1882; 2: 22–52.

Bancaud J, Brunet-Bourgin F, Chauvel P, Halgren E. Anatomical origin of déjà vu and vivid 'memories' in human temporal lobe epilepsy. *Brain* 1994; 117: 71–90.

Baska RE. Hypothalamic-midbrain dysregulation syndrome [letter; comment]. *J Child Neurol* 1992; 7: 116–7. Comment on: *J Child Neurol* 1991; 6: 115–22.

Bassetti C, Mathis J, Gugger M, Lovblad KO, Hess CW. Hypersomnia following paramedian thalamic stroke: a report of 12 patients. *Ann Neurol* 1996; 39: 471–80.

Baumgartner GR, Rowen RC. Clonidine vs chlordiazepoxide in the management of acute alcohol withdrawal syndrome. *Arch Intern Med* 1987; 147: 1223–6.

Beaumanoir A, Jekiel M. Electrographic observations during attacks of classical migraine. In: Andermann F, Lugesesi E, editors. *Migraine and Epilepsy*. Boston: Butterworths; 1987. p. 163–80.

Beckstead RM. Long collateral branches of substantia nigra pars reticulata axons to thalamus, superior colliculus and reticular

- formation in monkey and cat. Multiple retrograde neuronal labeling with fluorescent dyes. *Neuroscience* 1983; 10: 767–79.
- Beckstead RM, Domesick VB, Nauta WJ. Efferent connections of the substantia nigra and ventral tegmental area in the rat. *Brain Res* 1979; 175: 191–217.
- Beninato M, Spencer RF. A cholinergic projection to the rat substantia nigra from the pedunculopontine tegmental nucleus. *Brain Res* 1987; 412: 169–74.
- Bliss EL, Clark LD. Visual hallucinations. In: West LJ, editor. *Hallucinations*. New York: Grune & Stratton. 1963. p. 92–107.
- Bodis-Wollner I. Visual deficits related to dopamine deficiency in experimental animals and Parkinson's disease patients. [Review]. *Trends Neurosci* 1990; 13: 296–302.
- Bracha HS, Wolkowitz OM, Lohr JB, Karson CN, Bigelow LB. High prevalence of visual hallucinations in research subjects with chronic schizophrenia. *Am J Psychiatry* 1989; 146: 526–8.
- Carpenter WT, Jr., Buchanan RW. Schizophrenia [see comments]. [Review]. *N Engl J Med* 1994; 330: 681–90. Comment in: *N Engl J Med* 1994; 331: 275–6.
- Castaigne P, Lhermitte F, Buge A, Escourolle R, Hauw JJ, Lyon-Caen O. Paramedian thalamic and midbrain infarct: clinical and neuropathological study. *Ann Neurol* 1981; 10: 127–48.
- Celesia GG, Barr AN. Psychosis and other psychiatric manifestations of levodopa therapy. *Arch Neurol* 1970; 23: 193–200.
- Chan AW. Alcoholism and epilepsy. [Review]. *Epilepsia* 1985; 26: 323–33.
- Chaturvedi N, Hedley-Whyte ET, Dreyer EB. Lateral geniculate nucleus in glaucoma [see comments]. *Am J Ophthalmol* 1993; 116: 182–8. Comment in: *Am J Ophthalmol* 1993; 116: 182–8.
- Cheng AV, Ferrier IN, Morris CM, Jabeen S, Sahgal A, McKeith IG, et al. Cortical serotonin-S2 receptor binding in Lewy body dementia, Alzheimer's and Parkinson's diseases. *J Neurol Sci* 1991; 106: 50–5.
- Chua SE, McKenna PJ. Schizophrenia—a brain disease? A critical review of structural and functional cerebral abnormality in the disorder. [Review]. *Br J Psychiatry* 1995; 166: 563–82.
- Codina A, Acarin PN, Miquel F, Noguera M. Familial hemiplegic migraine associated with nystagmus. [French]. *Rev Neurol (Paris)* 1971; 124: 526–30.
- Cogan DG. Visual hallucinations as release phenomena. *Albrecht von Graefes Arch Klin Exp Ophthalmol* 1973; 188: 139–50.
- Comella CL, Tanner CM, Ristanovic RK. Polysomnographic sleep measures in Parkinson's disease patients with treatment-induced hallucinations. *Ann Neurol* 1993; 34: 710–4.
- Cowey A, Stoerig P. The neurobiology of blindsight. [Review]. *Trends Neurosci* 1991; 14: 140–5.
- Cusick CG, Scriptor JL, Darenbourg JG, Weber JT. Chemoarchitectonic subdivisions of the visual pulvinar in monkeys and their connective relations with the middle temporal and rostral dorsolateral visual areas, MT and DLr. *J Comp Neurol* 1993; 336: 1–30.
- Cutrer FM, Sorensen AG, Weisskopf RM, Ostergaard L, Sanchez del Rio M, Lee EJ, et al. Perfusion-weighted imaging defects during spontaneous migrainous aura. *Ann Neurol* 1998; 43: 25–31.
- Damasio AR, Lobo-Antunes J, Macedo C. Psychiatric aspects in parkinsonism treated with L-dopa. *J Neurol Neurosurg Psychiatry* 1971; 34: 502–7.
- Davis KD, Kiss ZH, Luo L, Tasker RR, Lozano AM, Dostrovsky JO. Phantom sensations generated by thalamic microstimulation [see comments]. *Nature* 1998; 391: 385–7. Comment in: *Nature* 1998; 391: 331, 333.
- D'Cruz OF, Vaughn BV, Gold SH, Greenwood RS. Symptomatic cataplexy in pontomedullary lesions [published erratum appears in *Neurology* 1995; 45: 2123]. *Neurology* 1994; 44: 2189–91.
- de la Fuente Fernandez R, Lopez J, Rey del Corral P, de la Iglesia Martinez F. Peduncular hallucinosis and right hemiparkinsonism caused by left mesencephalic infarction [letter]. *J Neurol Neurosurg Psychiatry* 1994; 57: 870.
- de Smet Y, Ruberg M, Serdaru M, Dubois B, Lhermitte F, Agid Y. Confusion, dementia and anticholinergics in Parkinson's disease. *J Neurol Neurosurg Psychiatry* 1982; 45: 1161–4.
- Dubois B, Danze F, Pillon B, Cusimano G, Lhermitte F, Agid Y. Cholinergic-dependent cognitive deficits in Parkinson's disease. *Ann Neurol* 1987; 22: 26–30.
- Dubois B, Pillon B, Lhermitte F, Agid Y. Cholinergic deficiency and frontal dysfunction in Parkinson's disease. *Ann Neurol* 1990; 28: 117–21.
- Dunn DW, Weisberg LA, Nadell J. Peduncular hallucinations caused by brainstem compression. *Neurology* 1983; 33: 1360–1.
- Duyckaerts C, Gaspar P, Costa C, Bonnet A-M, Hauw J-J. Dementia in Parkinson's disease: morphometric data. *Adv Neurol* 1993; 60: 447–55.
- Fasullo S, Lupo I. Neurophysiopathology of the visual hallucinations in the delirium tremens type of syndrome. [Italian]. *Acta Neurol (Napoli)* 1973; 28: 471–80.
- Feinberg WM, Rapcsak SZ. 'Peduncular hallucinosis' following paramedian thalamic infarction. *Neurology* 1989; 39: 1535–6.
- Fish DR, Gloor P, Quesney LF, Olivier A. Clinical responses to electrical brain stimulation of the temporal and frontal lobes in patients with epilepsy. *Brain* 1993; 116: 397–414.
- Fitzpatrick D, Diamond IT, Raczkowski D. Cholinergic and monoaminergic innervation of the cat's thalamus: comparison of the lateral geniculate nucleus with other principal sensory nuclei. *J Comp Neurol* 1989; 288: 647–75.
- Foote SL, Morrison JH. Extrathalamic modulation of cortical function. [Review]. *Ann Rev Neurosci* 1987; 10: 67–95.
- Foulkes D, Vogel G. Ego functions and dreaming Mental activity at sleep onset. *J Abnorm Psychol* 1965; 70: 231–43.
- Frieske DA, Wilson WP. Formal qualities of hallucinations: a comparative study of the visual hallucinations in patients with schizophrenic, organic, and affective psychoses. *Proceedings of the Annual Meeting of the American Psychopathological Association* 1966; 54: 49–62.

- Gaillard J-M, Nicholson AN, Pascoe PA. Neurotransmitter systems. In: Kryger MH, Roth T, Dement WC, editors. Principles and practice of sleep medicine. 2nd ed. Philadelphia: W. B. Saunders; 1994. p. 338–48.
- Geller TJ, Bellur SN. Peduncular hallucinosis: magnetic resonance imaging confirmation of mesencephalic infarction during life. *Ann Neurol* 1987; 21: 602–4.
- Gibb WRG. The pathology of parkinsonian disorders. In: Quinn NP, Jenner PG, editors. Disorders of movement: clinical, pharmacological and physiological aspects. London: Academic Press; 1989. p. 33–57.
- Gillin JC, Post RM, Wyatt RJ, Goodwin FK, Snyder F, Bunney WE Jr. REM inhibitory effect of L-DOPA infusion during human sleep. *Electroencephalogr Clin Neurophysiol* 1973; 35: 181–6.
- Girard P, Salin PA, Bullier J. Response selectivity of neurons in area MT of the macaque monkey during reversible inactivation of area V1. *J Neurophysiol* 1992; 67: 1437–46.
- Glennon RA, Titeler M, McKenney JD. Evidence for 5HT₂ involvement in the mechanism of action of hallucinogenic agents. *Life Sci* 1984; 35: 2505–11.
- Gloor P. Experiential phenomena of temporal lobe epilepsy: facts and hypotheses. [Review]. *Brain* 1990; 113: 1673–94.
- Gloor P, Olivier A, Quesney LF, Andermann F, Horowitz S. The role of the limbic system in experiential phenomena of temporal lobe epilepsy. *Ann Neurol* 1982; 12: 129–44.
- Gold JM, Weinberger DR. Cognitive deficits and the neurobiology of schizophrenia. [Review]. *Curr Opin Neurobiol* 1995; 5: 225–30.
- Goodwin DW, Alderson P, Rosenthal R. Clinical significance of hallucinations in psychiatric disorders. A study of 116 hallucinatory patients. *Arch Gen Psychiatry* 1971; 24: 76–80.
- Griffith JD. Amphetamine dependence; clinical features. In: Martin WR, editor. Drug addiction II. Amphetamine, psychotogen, and marijuana dependence. Handbook of experimental pharmacology, Vol. 45/II. Berlin: Springer-Verlag; 1977. p. 277–304.
- Hajdu F, Somogyi G, Tombol T. Neuronal and synaptic arrangement in the lateralis posterior-pulvinar complex of the thalamus in the cat. *Brain Res* 1974; 73: 89–104.
- Halgren E, Walter RD, Cherlow DG, Crandall PH. Mental phenomena evoked by electrical stimulation of the human hippocampal formation and amygdala. *Brain* 1978; 101: 83–117.
- Halliday GM, Blumbergs PC, Cotton RG, Blessing WW, Geffen LB. Loss of brainstem serotonin- and substance P-containing neurons in Parkinson's disease. *Brain Res* 1990; 510: 104–7.
- Hartmann E. Psychobiology and dreaming. In: Kryger MH, Roth T, Dement WC, editors. Principles and practice of sleep medicine. 2nd ed. Philadelphia: W. B. Saunders; 1994. p. 373–410.
- Hemmingsen R, Kramp P, Rafaelsen OJ. Delirium tremens and related clinical states. [Review]. *Acta Psychiatr Scand* 1979; 59: 337–69.
- Hishikawa Y, Shimizu T. Physiology of REM sleep, cataplexy, and sleep paralysis. [Review]. *Adv Neurol* 1995; 67: 245–71.
- Hishikawa Y, Nan'no H, Tachibana M, Furuya E, Koida H, Kaneko Z. The nature of sleep attack and other symptoms of narcolepsy. *Electroencephalogr Clin Neurophysiol* 1968; 24: 1–10.
- Hishikawa Y, Koida H, Yoshino K, Wakamatsu H, Sugita Y, Iijima S, et al. Characteristics of REM sleep accompanied by sleep paralysis and hypnagogic hallucinations in narcoleptic patients. *Waking Sleeping* 1978; 2: 113–23.
- Hollister LE. Drug-induced psychoses and schizophrenic reactions: a critical comparison. *Ann N Y Acad Sci* 1962; 96: 80–8.
- Horowski R. Psychiatric side-effects of high-dose lisuride therapy in parkinsonism [letter]. *Lancet* 1986; 2: 510.
- Howlett DC, Downie AC, Banerjee AK, Tonge KA, Oakeley HF. MRI of an unusual case of peduncular hallucinosis (Lhermitte's syndrome). *Neuroradiology* 1994; 36: 121–2.
- Hughes AJ, Daniel SE, Blankson S, Lees AJ. A clinicopathologic study of 100 cases of Parkinson's disease. *Arch Neurol* 1993; 50: 140–8.
- Isbell H, Altschul S, Kornetsky CH, Eisenman AJ, Flanary HG, Fraser HF. Chronic barbiturate intoxication: an experimental study. *Arch Neurol Psychiatry* 1950; 64: 1–28.
- Isbell H, Fraser HF, Wikler A, Belleville RE, Eisenman AJ. An experimental study of the etiology of 'rum fits' and delirium tremens. *Quart J Stud Alcohol* 1955; 16: 1–33.
- Jackson A, Crossman AR. Nucleus tegmenti pedunculopontinus: efferent connections with special reference to the basal ganglia, studied in the rat by anterograde and retrograde transport of horseradish peroxidase. *Neuroscience* 1983; 10: 725–65.
- Jacobs BL, Azmitia EC. Structure and function of the brain serotonin system. [Review]. *Physiol Rev* 1992; 72: 165–229.
- Jacobs BL, Henriksen SJ, Dement WC. Neurochemical bases of the PGO wave. *Brain Res* 1972; 48: 406–11.
- Jeanmonod D, Magnin M, Morel A. Low-threshold calcium spike bursts in the human thalamus. Common physiopathology for sensory, motor and limbic positive symptoms. *Brain* 1996; 119: 363–75.
- Jellinger K. New developments in the pathology of Parkinson's disease. [Review]. *Adv Neurol* 1990; 53: 1–16.
- Johnson J, Milner G. Psychiatric complications of amphetamine substances. *Acta Psychiatr Scand* 1966; 42: 252–63.
- Jones BE. Basic mechanisms of sleep-wake states. In: Kryger MH, Roth T, Dement WC, editors. Principles and practice of sleep medicine. 2nd ed. Philadelphia: W. B. Saunders; 1994. p. 145–62.
- Jones EG, Powell TP. An anatomical study of converging sensory pathways within the cerebral cortex of the monkey. *Brain* 1970; 93: 793–820.
- Kahn N, Freeman A, Juncos JL, Manning D, Watts RL. Clozapine is beneficial for psychosis in Parkinson's disease. *Neurology* 1991; 41: 1699–700.
- Kaneko Z, Hishikawa Y. Paradoxical sleep in psychiatric disorders and narcolepsy. [Review]. *Int J Neurol* 1981; 15: 40–55.
- Kemp JA, Roberts HC, Sillito AM. Further studies on the action of 5-hydroxytryptamine in the dorsal lateral geniculate nucleus of the cat. *Brain Res* 1982; 246: 334–7.

- Kolmel HW. Peduncular hallucinations. *J Neurol* 1991; 238: 457–9.
- Kolmel HW. Visual illusions and hallucinations. [Review]. *Baillieres Clin Neurol* 1993; 2: 243–64.
- Kosaka K. Dementia and neuropathology in Lewy body disease. In: Narabayashi H, Nagatsu T, Yanigasawa N, Mizuno Y, editors. *Advances in Neurology*. New York: Raven Press; 1993. p. 456–63.
- Kraus ML, Gottlieb LD, Horwitz RI, Anscher M. Randomized clinical trial of atenolol in patients with alcohol withdrawal. *N Engl J Med* 1985; 313: 905–9.
- Kuiper MA, Zwaan WA, Wolters EC. Between Scylla and Charybdis: drug-induced psychosis in patients with Parkinson disease. [Dutch]. *Ned Tijdschr Geneesk* 1994; 138: 1353–7.
- Lalla D, Primeau F. Complex visual hallucinations in macular degeneration. *Can J Psychiatry* 1993; 38: 584–6.
- Lance JW. Simple formed hallucinations confined to the area of a specific visual field defect. *Brain* 1976; 99: 719–34.
- Lance JW. Current concepts of migraine pathogenesis. [Review]. *Neurology* 1993; 43 (6 Suppl 3): S11–5.
- Laurent JP, Rondouin G, Benita M, Jouvet M. Reversible blockade of PGO waves and concomitant modifications of thalamic unit activity in chronic cats. *Brain Res* 1977; 137: 305–322.
- Lauritzen M. Cerebral blood flow in migraine and spreading depression. In: Andermann F, Lugaesi E, editors. *Migraine and epilepsy*. Boston: Butterworths; 1987. p. 325–37.
- Lauterbach EC. Dopaminergic hallucinosis with fluoxetine in Parkinson's disease [letter]. *Am J Psychiatry* 1993; 150: 1750.
- Leaning FE. An introductory study to hypnagogic phenomena. *Proc Soc Psych Res* 1926; 35: 288–409.
- Leao AAP, Morrison RS. Propagation of spreading cortical depression. *J Neurophysiol* 1945; 8: 33–45.
- Leroy R. The syndrome of Lilliputian hallucinations. *J Nerv Ment Dis* 1922; 56: 325–33.
- Lewander T. General pharmacology of amphetamine-like drugs. B: Effects of amphetamines in animals. In: Martin WR, editor. *Drug addiction II. Amphetamine, psychotogen, and marihuana dependence*. Handbook of experimental pharmacology, Vol. 45/II. Berlin: Springer-Verlag; 1977. p. 33–246.
- Lewis DJ. Lilliputian hallucinations in the functional psychoses. *Canad Psychiat Ass J* 1961; 6: 177–201.
- Lhermitte J. Syndrome de la calotte du Pedoncule cérébral. Les troubles psycho-sensoriels dans les lésions du mésocéphale. *Rev Neurol (Paris)* 1922; 2: 1359–65.
- Lhermitte J, Bineau R. Les hallucinations visuelles consecutives aux lésions pédonculaires en foyer. *Rev Neurol (Paris)* 1937; 68: 827–31.
- Lhermitte J, Levy G. L'hallucineuse pédonculaire (un nouveau cas de lésion de la calotte pédonculaire provoqué par une intoxication aiguë par divers narcotiques). *Rev Neurol (Paris)* 1931; 1: 312–8.
- Lhermitte J, Levy G, Trelles J. L'hallucineuse pédonculaire (étude anatomique d'un cas). *Rev Neurol (Paris)* 1932; 1: 382–8.
- Lipowski ZJ. Delirium due to alcohol and drug withdrawal. In: Lipowski ZJ. *Delirium: acute brain failure in man*. Springfield (IL): Charles C. Thomas; 1980. p. 317–43.
- Lowe GR. The phenomenology of hallucinations as an aid to differential diagnosis. *Br J Psychiatry* 1973; 123: 621–33.
- Luebke JI, Greene RW, Semba K, Kamondi A, McCarley RW, Reiner PB. Serotonin hyperpolarizes cholinergic low-threshold burst neurons in the rat laterodorsal tegmental nucleus in vitro. *Proc Natl Acad Sci USA* 1992; 89: 743–7.
- Mackay AVP, Iversen LL. Neurotransmitters and schizophrenia. In: Weller M, Eysenck M, editors. *The scientific basis of psychiatry*. London: W. B. Saunders; 1992. p. 558–81.
- MacKinnon GL, Parker WA. 1982; Benzodiazepine withdrawal syndrome: a literature review and evaluation. [Review]. *Am J Drug Alcohol Abuse* 1992; 9: 19–33.
- Malitz S, Wilkens B, Esecover H. A comparison of drug-induced hallucinations with those seen in spontaneously occurring psychoses. In: West LJ, editor. *Hallucinations*. New York: Grune & Stratton; 1963. p. 50–63.
- Mantovani P, Pepeu G. Influence of dopamine agonists on cholinergic mechanisms in the cerebral cortex. In: Garrattini S, editor. *Interactions between putative neurotransmitters in the brain*. New York: Raven Press; 1978. p. 53–9.
- Mathers LH. Ultrastructure of the pulvinar of the squirrel monkey. *J Comp Neurol* 1972; 146: 15–42.
- Matthews TD, Kennard C. Residual vision following geniculostriate lesions. [Review]. *Baillieres Clin Neurol* 1993; 2: 227–41.
- Maury A. Des hallucinations hypnagogiques, ou des erreurs des sens dans l'état intermédiaire entre la veille et le sommeil. *Ann Medico-Psychol* 1848; VII: 26–40.
- McCabe MS, Fowler RC, Cadoret RJ, Winokur G. Symptom differences in schizophrenia with good and poor prognosis. *Am J Psychiatry* 1972; 128: 1239–43.
- McCarley RW, Benoit O, Barrionuevo G. Lateral geniculate nucleus unitary discharge in sleep and waking: state- and rate-specific aspects. *J Neurophysiol* 1983; 50: 798–818.
- McKee AC, Levine DN, Kowall NW, Richardson EP Jr. Peduncular hallucinosis associated with isolated infarction of the substantia nigra pars reticulata. *Ann Neurol* 1990; 27: 500–4.
- McShane R, Gedling K, Reading M, McDonald B, Esiri MM, Hope T. Prospective study of relations between cortical Lewy bodies, poor eyesight, and hallucinations in Alzheimer's disease. *J Neurol Neurosurg Psychiatry* 1995; 59: 185–8.
- Meco G, Bonifati V, Cusimano G, Fabrizio E, Vanacore N. Hallucinations in Parkinson disease: neuropsychological study. *Italian Journal of Neurological Sciences* 1990; 11: 373–9.
- Meco G, Alessandria A, Bonifati V, Giustini P. Risperidone for hallucinations in levodopa-treated Parkinson's disease patients [letter] [see comments]. *Lancet* 1994; 343: 1370–1. Comment in: *Lancet* 1994; 344: 681.
- Melzack R, Israel R, Lacroix R, Schultz G. Phantom limbs in people with congenital limb deficiency or amputation in early childhood. *Brain* 1997; 120: 1603–20.

- Meyer JS, Sakai F, Karacan I, Derman S, Yamamoto M. Sleep apnea, narcolepsy, and dreaming: regional cerebral hemodynamics. *Ann Neurol* 1980; 7: 479–85.
- Mitchell SW. The effects of *Anhelonium lewinii* (The mescal button). *Br Med J* 1896; 2: 1625–9.
- Morrison JH, Foote SL. Noradrenergic and serotonergic innervation of cortical, thalamic, and tectal visual structures in Old and New World monkeys. *J Comp Neurol* 1986; 243: 117–38.
- Mouret J. Differences in sleep in patients with Parkinson's disease. *Electroencephalogr Clin Neurophysiol* 1975; 38: 653–7.
- Mueser KT, Bellack AS, Brady EU. Hallucinations in schizophrenia. *Acta Psychiatr Scand* 1990; 82: 26–9.
- Myslobodsky M, Mintz M, Ben-Mayor V, Radwan H. Unilateral dopamine deficit and lateral EEG asymmetry: sleep abnormalities in hemi-Parkinson's patients. *Electroencephalogr Clin Neurophysiol* 1982; 54: 227–31.
- Nadvi SS, Van Dellen JR. Transient peduncular hallucinations secondary to brain stem compression by a medulloblastoma. *Surg Neurol* 1994; 41: 250–2.
- Nausieda PA, Tanner CM, Klawans HL. Serotonergically active agents in levodopa-induced psychiatric toxicity reactions. *Adv Neurol* 1983; 37: 23–32.
- Ndetei DM, Singh A. Hallucinations in Kenyan schizophrenic patients. *Acta Psychiatr Scand* 1983; 67: 144–7.
- Nevo I, Hamon M. Neurotransmitter and neuromodulatory mechanisms involved in alcohol abuse and alcoholism. [Review]. *Neurochem Int* 1995; 26: 305–36.
- Ogren MP, Hendrickson AE. The structural organization of the inferior and lateral subdivisions of the Macaca monkey pulvinar. *J Comp Neurol* 1979; 188: 147–78.
- Ophoff RA, Terwindt GM, Vergouwe MN, van Eijk R, Oefner PJ, Hoffman SM, et al. Familial hemiplegic migraine and episodic ataxia type-2 are caused by mutations in the calcium channel gene CACNL1A4. *Cell* 1996; 87: 543–52.
- Parent A. *Carpenter's human neuroanatomy*. Baltimore: Williams & Wilkins; 1996.
- Parent A, Pare D, Smith Y, Steriade M. Basal forebrain cholinergic and noncholinergic projections to the thalamus and brainstem in cats and monkeys. *J Comp Neurol* 1988; 277: 281–301.
- Pasik P, Molinar-Rode R, Pasik T. Chemically specified systems in the dorsolateral geniculate nucleus of mammals. In: Cohen B, Bodis-Wollner I, editors. *Vision and the brain*. New York: Raven Press; 1990. p. 43–83.
- Penfield W, Jasper HH. *Epilepsy and the functional anatomy of the human brain*. Boston: Little, Brown; 1954.
- Penfield W, Perot P. The brain's record of auditory and visual experience. *Brain* 1963; 86: 595–696.
- Perry EK, Marshall E, Kerwin J, Smith CJ, Jabeen S, Cheng AV, et al. Evidence of a monoaminergic-cholinergic imbalance related to visual hallucinations in Lewy body dementia. *J Neurochem* 1990; 55: 1454–6.
- Perry EK, McKeith I, Thompson P, Marshall E, Kerwin J, Jabeen S, et al. Topography, extent, and clinical relevance of neurochemical deficits in dementia of Lewy body type, Parkinson's disease, and Alzheimer's disease. *Ann N Y Acad Sci* 1991; 640: 197–202.
- Perry EK, Marshall E, Thompson P, McKeith IG, Collerton D, Fairbairn AF, et al. Monoaminergic activities in Lewy body dementia: relation to hallucinosis and extrapyramidal features. *J Neural Transm Park Dis Dement Sect* 1993; 6: 167–77.
- Plazzi G, Montagna P, Provini F, Bizzi A, Cohen M, Lugaresi E. Pontine lesions in idiopathic narcolepsy. *Neurology* 1996; 46: 1250–4.
- Porteous HB, Ross DN. Mental symptoms in parkinsonism following benzhexol hydrochloride therapy. *Br Med J* 1956; 2: 138–40.
- Rango M, Spagnoli D, Tomei G, Bamonti F, Scarlato G, Zetta L. Central nervous system trans-synaptic effects of acute axonal injury: a 1H magnetic resonance spectroscopy study. *Magn Reson Med* 1995; 33: 595–600.
- Ritchie Russell W, Whitty CWM. Studies in traumatic epilepsy. 3. Visual fits. *J Neurol Neurosurg Psychiatry* 1955; 18: 79–96.
- Rivera VM, Meyer JS, Hata T, Ishikawa Y, Imai A. Narcolepsy following cerebral hypoxic ischemia. *Ann Neurol* 1986; 19: 505–8.
- Robinson DL, Petersen SE. The pulvinar and visual salience. [Review]. *Trends Neurosci* 1992; 15: 127–32.
- Rodrigo-Angulo MI, Reinoso-Suarez F. Topographical organization of the brainstem afferents to the lateral posterior-pulvinar thalamic complex in the cat. *Neuroscience* 1982; 7: 1495–508.
- Rogawski MA, Aghajanian GK. Norepinephrine and serotonin: opposite effects on the activity of lateral geniculate neurons evoked by optic pathway stimulation. *Exp Neurol* 1980; 69: 678–94.
- Rondot P, de Recondo J, Coignet A, Ziegler M. Mental disorders in Parkinson's disease after treatment with L- DOPA. *Adv Neurol* 1984; 40: 259–69.
- Rosenthal SH. Persistent hallucinosis following repeated administration of hallucinogenic drugs. *Am J Psychiatry* 1964; 121: 238–44.
- Roth BL, Meltzer HY. The role of serotonin in schizophrenia. In: Bloom FE, Kupfer DJ, editors. *Psychopharmacology: the fourth generation of progress*. New York: Raven Press; 1995. p. 1215–27.
- Rozanski J. Peduncular hallucinosis following vertebral angiography. *Neurology* 1952; 2: 341–9.
- Ruch-Monachon MA, Jalfre M, Haefely W. Drugs and PGO waves in the lateral geniculate body of the curarized cat. II. PGO wave activity and brain 5-hydroxytryptamine. *Arch Int Pharmacodyn* 1976; 219: 269–86.
- Sacks OW, Kohl MS, Messeloff CR, Schwartz WF. Effects of levodopa in parkinsonian patients with dementia. *Neurology* 1972; 22: 517–9.
- Sakai F, Meyer JS, Karacan I, Yamaguchi F, Yamamoto M. Narcolepsy: regional cerebral blood flow during sleep and wakefulness. *Neurology* 1979; 29: 61–7.
- Salanova V, Andermann F, Olivier A, Rasmussen T, Quesney LF. Occipital lobe epilepsy: electroclinical manifestations, electrocorticography, cortical stimulation and outcome in 42 patients

- treated between 1930 and 1991. Surgery of occipital lobe epilepsy. *Brain* 1992; 115: 1655–80.
- Sanchez-Ramos JR, Ortoll R, Paulson GW. Visual hallucinations associated with Parkinson disease [see comments]. *Arch Neurol* 1996; 53: 1265–8. Comment in: *Arch Neurol* 1997; 54: 799.
- Schmidt HS, Clark RW, Hyman PR. Protriptyline: an effective agent in the treatment of the narcolepsy-cataplexy syndrome and hypersomnia. *Am J Psychiatry* 1977; 134: 183–5.
- Schmidt CJ, Black CK, Taylor VL. L-DOPA potentiation of the serotonergic deficits due to a single administration of 3,4-methylenedioxymethamphetamine, p-chloroamphetamine or methamphetamine to rats. *Eur J Pharmacol* 1991; 203: 41–9X.
- Schultz G, Melzack R. The Charles Bonnet syndrome: 'phantom visual images'. [Review]. *Perception* 1991; 20: 809–25.
- Schultz G, Needham W, Taylor R, Shindell S, Melzack R. Properties of complex hallucinations associated with deficits in vision. *Perception* 1996; 715–26.
- Serra Catafau J, Rubio F, Peres Serra J. Peduncular hallucinosis associated with posterior thalamic infarction. *J Neurol* 1992; 239: 89–90.
- Siegel JM. Brainstem mechanisms generating REM sleep. In: Kryger MH, Roth T, Dement WC, editors. *Principles and practice of sleep medicine*. 2nd ed. Philadelphia: W. B. Saunders; 1994. p. 125–44.
- Singer W. Control of thalamic transmission by corticofugal and ascending reticular pathways in the visual system. [Review]. *Physiol Rev* 1977; 57: 386–420.
- Small IJ, Small JG, Andersen JM. Clinical characteristics of hallucinations of schizophrenia. *Dis Nerv Syst* 1966; 27: 349–53.
- Solms M. *The neuropsychology of dreams*. Hillsdale (NJ): Lawrence Erlbaum; 1997a. p. 205.
- Solms M. The classic case reports of Charcot-Willebrand syndrome. In: Solms M. *The neuropsychology of dreams*. Hillsdale (NJ): Lawrence Erlbaum; 1997b. p. 4–19.
- Sowa MV, Pituck S. Prolonged spontaneous complex visual hallucinations and illusions as ictal phenomena. *Epilepsia* 1989; 30: 524–6.
- Stahl SM, Layzer RB, Aminoff MJ, Townsend JJ, Feldon S. Continuous cataplexy in a patient with a midbrain tumor: the limp man syndrome. *Neurology* 1980; 30: 1115–8.
- Steckler T, Sahgal A. The role of serotonergic-cholinergic interactions in the mediation of cognitive behaviour. [Review]. *Behav Brain Res* 1995; 67: 165–99.
- Steriade M, Pare D, Bouhassira D, Deschenes M, Oakson G. Phasic activation of lateral geniculate and perigeniculate thalamic neurons during sleep with ponto-geniculo-occipital waves. *J Neurosci* 1989; 9: 2215–29.
- Sweet RD, McDowell FH, Feigenson JS, Loranger AW, Goodell H. Mental symptoms in Parkinson's disease during chronic treatment with levodopa. *Neurology* 1976; 26: 305–10.
- Taylor J, Holmes G, Walshe FMR, editors. *Selected writings of John Hughlings Jackson, Vol. 1. On epilepsy and epileptiform convulsions*. London: Hodder & Stoughton; 1931.
- Taylor J, Holmes G, Walshe FMR. Evolution and dissolution of the nervous system. In: Taylor J, Holmes G, Walshe FMR, editors. *Selected writings of John Hughlings Jackson, Vol 2*. London: Hodder & Stoughton; 1932. p. 3–120.
- Teunisse RJ, Cruysberg JR, Hoefnagels WH, Verbeek AL, Zitman FG. Visual hallucinations in psychologically normal people: Charles Bonnet's syndrome. *Lancet* 1996; 347: 794–7.
- Tournaï A. Sur mes propres visions du demi-sommeil. *Rev Neurol (Paris)* 1941; 73: 209–24.
- Tsoukatos J, Kiss ZH, Davis KD, Tasker RR, Dostrovsky JO. Patterns of neuronal firing in the human lateral thalamus during sleep and wakefulness. *Exp Brain Res* 1997; 113: 273–82.
- Tsukamoto H, Matsushima T, Fujiwara S, Fukui M. Peduncular hallucinosis following microvascular decompression for trigeminal neuralgia: case report. *Surg Neurol* 1993; 40: 31–4.
- Turner TH, Cookson JC, Wass JA, Drury PL, Price PA, Besser GM. Psychotic reactions during treatment of pituitary tumours with dopamine agonists. *Br Med J* 1984; 289: 1101–3.
- Van Bogaert L. Syndrome inferieur du noyau rouge, troubles psychosensoriels d'origine mesocephalique. *Rev Neurol (Paris)* 1924; 1: 417–23.
- Van Bogaert L. L'hallucinoïse pedonculaire. *Rev Neurol (Paris)* 1927; 1: 608–17.
- Vaphiades MS, Celesia GG, Brigell MG. Positive spontaneous visual phenomena limited to the hemianopic field in lesions of central visual pathways. *Neurology* 1996; 47: 408–17.
- Victor M, Adams RD. The effect of alcohol on the nervous system. In: Merritt HH, Hare CC, editors. *Metabolic and toxic disease of the nervous system*. Baltimore: Williams and Wilkins; 1952. p. 526–73.
- Vizuete ML, Steffen V, Machado A, Cano J. Effects of neonatal enucleation on catecholamine and serotonin turnover and amino acid levels in lateral geniculate nucleus and visual cortex of the adult rat. *Brain Res* 1992; 575: 231–7.
- Walker MC, Smith SJ, Sisodiya SM, Shorvon SD. Case of simple partial status epilepticus in occipital lobe epilepsy misdiagnosed as migraine: clinical, electrophysiological, and magnetic resonance imaging characteristics. *Epilepsia* 1995; 36: 1233–6.
- Welch KM, Barkley GL, Tepley N, Ramadan NM. Central neurogenic mechanisms of migraine. [Review]. *Neurology* 1993; 43 (6 Suppl 3): S21–5.
- Williams J, McGuffin P, Nothen M, Owen MJ. Meta-analysis of association between 5-HT_{2A} receptor T102C polymorphism and schizophrenia [letter]. *Lancet* 1997; 349: 1221.
- Williamson PD, Boon PA, Thadani VM, Darcey TM, Spencer DD, Spencer SS, et al. Parietal lobe epilepsy: diagnostic considerations and results of surgery. *Ann Neurol* 1992; 31: 193–201.
- Wilson JR. Circuitry of the dorsal lateral geniculate nucleus in the cat and monkey. [Review]. *Acta Anat (Basel)* 1993; 147: 1–13.

Wyatt RJ, Fram DH, Buchbinder R, Snyder F. Treatment of intractable narcolepsy with a monoamine oxidase inhibitor. *N Engl J Med* 1971; 285: 987–91.

Xuereb JH, Tomlinson BE, Irving D, Perry RH, Blessed G, Perry EK. Cortical and subcortical pathology in Parkinson's disease: relationship to parkinsonian dementia. *Adv Neurol* 1990; 53: 35–40.

Young BG. A phenomenological comparison of LSD and schizophrenic states. *Br J Psychiatry* 1974; 124: 64–74.

Zarroug E-TA. The frequency of visual hallucinations in

schizophrenic patients in Saudi Arabia. *Br J Psychiatry* 1975; 127: 553–5.

Zifkin B, Andermann E, Andermann F, Kirkham T. An autosomal dominant syndrome of hemiplegic migraine, nystagmus, and tremor. 1980; *Ann Neurol* 8: 329–32.

Received March 11, 1998. Revised May 19, 1998.

Accepted June 8, 1998

Appendix 1 Characteristics of reported cases of peduncular hallucinosis

Reference	Clinical features	Clinical/pathological/radiological localization
Lhermitte (1922)	Vivid visual hallucinations of animals at the end of the day with insight. Nocturnal insomnia with daytime hypersomnolence. Vertigo, persistent vomiting, left central scotoma, partial left III and left, VI palsies, possible right extensor plantar response, right arm paraesthesiae. Mild dysmetria right arm, no other cerebellar signs.	Clinical: midbrain and pontine tegmentum signs, and also probably affecting secondary vestibular inputs in the medial longitudinal fasciculus and the reticular formation. The absence of major long tract or cerebellar signs suggests the lesion is restricted to medial structures. Also, a distal optic nerve or retinal lesion.
van Bogaert (1924), van Bogaert (1927)	Fell without loss of consciousness and noted bilateral ptosis with diplopia. Overnight she had hallucinations, including dogs' and horses' heads on the wall opposite. She saw and felt a snake and was convinced of the reality of the images. Right III palsy with irregular, unreactive pupils. Right pupil sluggish and nystagmus on left lateral gaze. Mild dysmetria of left limbs. Gradual resolution of signs over 14 months.	Pathological examination showed infarction extending from the level of the red nucleus inferiorly to the level of the pulvinar superiorly, including the superior cerebellar peduncle, oculomotor nucleus, periaqueductal grey and substantia nigra.
Alajouanine and Gopcevitch (1928)	Encephalitis lethargica followed by left-sided Parkinsonism, bulbar dysfunction, weight gain (hypothalamic?), diplopia, Parinaud's syndrome and hallucinations. Hallucinations every day, only in the early part of the evening. A rapid sequence of images, e.g. a human head, then an animal's head. They disappeared on eye closure, and after 6 years became less frequent. Also disturbed sleep with abnormal movements and vocalizations.	Clinical localization indicates rostral brainstem disturbance, including tectum and tegmentum, and possibly pontine disturbance with sleep disorder.
Lhermitte and Levy (1931)	Known case of tertiary syphilis, found unconscious. He was later drowsy, but could respond and was only mildly confused. Right III palsy, with left Argyll-Robertson pupil, 'choreo-ataxic' movements of arms, tremulous movements of his tongue and occasional spasms of his limbs. He improved over the next days. Soon after onset he said his room was transformed into a train each evening, with several people walking in it. An aeroplane flew down from the ceiling. At other times his room was an underground carriage. His trousers on the cupboard opposite appeared to be women talking and smiling.	Clinical localization to midbrain tegmentum. Some experiences may be illusions rather than hallucinations.
Lhermitte <i>et al.</i> (1932)	Right third nerve palsy with dysarthria. Several days later he felt the room was transformed into a railway carriage and figures before him spoke to him; he understood them. Hallucinations worst in the evening but they subsequently disappeared. He died from bronchopneumonia.	Pathological changes of pigmentary degeneration in raphe region, maximal in the median raphe and least more ventrally. Degeneration of the third nerve nucleus, especially its ventromedian part but otherwise no changes in the region of the cerebral peduncle. A small lacuna in the substantia nigra but no changes in the locus coeruleus or other brainstem structures.

Appendix 1 continued

Reference	Clinical features	Clinical/ pathological/radiological localization
Lhermitte and Bineau (1937)	Sudden loss of consciousness at onset. Several hours later noted to have bilateral ptosis and failure of eye abduction with mild left limb weakness. She was somnolent, responding appropriately when roused. Two days later hallucinations of animals which frightened her, and she tried to shake them off. Two weeks later hallucinations resolved.	Clinical signs suggest a long midline lesion from central nucleus of III to superior pons, probably including a large part of the reticular formation.
Lhermitte and Bineau (1937)	Sudden onset of vomiting and ataxia without weakness. Drowsy but could be awoken and asked bizarre questions, suggesting cognitive change. She hallucinated many animals, especially cats and dogs for several months. Severe truncal ataxia, with limb ataxia. Reduction of distal proprioception in legs.	Clinical localization suggests predominant lesion of midline cerebellum or cerebellar connection in ponto-medullary region.
Alajouanine <i>et al.</i> (1944)	A 37-year-old with septic lesion from shrapnel wound developed left hemiparesis with right VI and VII palsies, Horner's syndrome. Slept for 48 h, then had hallucinations of white or red horses coming off the ceiling, which he tried to trap on the bed. Then was in an unbreakable glass machine from which he negotiated with Germans to deliver a Russian prisoner. Then paranoid thoughts that his wife was unfaithful.	Clinical localization to pontine tegmentum including nucleus reticularis pontis oralis.
Rozanski (1952)	Patient investigated for mild left-sided weakness and numbness. Vertebral angiography caused nausea and was followed by hallucinations when she shut her eyes. At first these were shapes and lines but later flocks of birds with trees and flowers. She realized it was abnormal. She was insomniac with some disinhibition. There was poor convergence and limitation of left lateral gaze. Resolution over a few weeks.	Clinically, failure of lateral gaze and convergence suggest midbrain and pontine tegmentum involvement.
Dunn <i>et al.</i> (1983)	Six-year-old boy noted blurred vision. Two years later, he described seeing snakes, vivid black objects moving, present almost all the time he was awake. Nocturnal insomnia and diurnal hypersomnolence.	CT showed a lesion compressing the brainstem from above, which proved to be a cystic craniopharyngioma, and hallucinations resolved with surgery, despite poor residual visual acuity.
Geller and Bellur, (1987)	Sudden onset of hallucinations throughout the visual field in a diabetic with pre-existing impaired visual acuity. Initially drowsy with slurred speech. Bilateral ptosis with complete right III palsy, left upper motor neuron facial weakness and opsoclonus.	MRI showed infarction in right midbrain, tegmentum, extending to cerebral peduncle. Clear involvement of midbrain grey matter. Hallucinations did not occur from diabetic maculopathy prior to CNS infarction.
McKee <i>et al.</i> (1990)	Two seizures followed by hallucinations of animals and people who walked across his field of vision. Previous sequential right III and left III palsies with complete recovery. Hallucinations usually at night associated with feelings of persecution.	Pathological examination showed foci of necrosis restricted to the substantia nigra pars reticulata on both sides.
Tsukamoto <i>et al.</i> (1993)	Hallucinations of Mickey Mouse or of tigers 2 days after microvascular decompression of trigeminal nerve. These evolved into gangsters and snakes. She suffered insomnia and had some auditory hallucinations, as well as a feeling of levitation. Hallucinations subsided after 5 days.	CT showed midbrain swelling with a haematoma in the upper part of the cerebellopontine cistern.

Appendix 1 continued

Reference	Clinical features	Clinical/ pathological/radiological localization
Nadvi and van Dellen, (1994)	Almost continuous visual hallucinations of a man herding cattle. Worst in the evening. He was seen to warn the herdsman that his cattle were straying. Associated with neck stiffness, papilloedema, ataxia and bilateral partial third nerve palsies.	Vermian mass on CT scan causing hydrocephalus and infiltrating the roof of the fourth ventricle—medulloblastoma. Shunting relieved symptoms and signs except hallucinosis, which only responded to tumour removal, and may have been directly due to the tumour, rather than the hydrocephalus.
Howlett <i>et al.</i> (1984)	Hallucinations of three men who walked towards him and genuflected. Abrupt onset and no associated neurological symptoms.	The nucleus reticulari thalami and lateral pulvinar.
de la Fernandez <i>et al.</i> (1994)	Onset of hallucinations of people, animals and motorbikes across the whole visual field, lasting minutes to hours. Brisk reflexes on the right with no other signs.	MRI infarct in left cerebral peduncle, probably includes nucleus reticularis thalami and substantia nigra. Additional hemispheric periventricular ischaemic lesions.
Feinberg and Rapesak (1989)	Sudden onset of hallucinations in a man blind from diabetic retinopathy. Military people marching in front of him, who appeared real. At one point bent down to pet a dog by his side. Worse in the afternoon and evening and resolved after 3 days.	MRI showed acute posterior right paramedian thalamic infarction. Structures affected centromedian nucleus and posterior midline nuclei. Probably also medial pulvinar, substantia nigra and possibly other medial midbrain structures. Other small ischaemic cerebral lesions, including right parieto-occipital infarction, affecting grey and white matter.
Kolmel (1991)	Sudden attacks of somnolence for 3 days. Complete vertical gaze palsy noted, with saccadic horizontal eye movements and failure of convergence. Mild amnesia and mild bilateral limb ataxia. He complained of nocturnal insomnia and was less drowsy in the day. One evening he reported that two strangers came into his room and threatened him with clubs. He was sufficiently disturbed to throw things at them. The hallucinations recurred 3 days later.	MRI showed bilateral thalamic lesions affecting the midline nuclei, the nucleus medialis dorsalis and the left pulvinar. There were separate lesions affecting the red nucleus on both sides and the midbrain reticular formation. In addition there were small, hemispheric white matter lesions.