

The reorganization of sensorimotor function in children after hemispherectomy

A functional MRI and somatosensory evoked potential study

Victoria Holloway,¹ David G. Gadian,¹ Faraneh Vargha-Khadem,^{2,3} David A. Porter,^{1,*} Stewart G. Boyd³ and Alan Connelly¹

¹Radiology and Physics Unit, ²Cognitive Neuroscience Unit, Institute of Child Health, University College London and ³Great Ormond Street Hospital for Children NHS Trust, London, UK

Correspondence to: Victoria Holloway, Radiology and Physics Unit, Institute of Child Health, University College London, 30 Guilford Street, London WC1N 1EH, UK
E-mail: vhollow@ich.ucl.ac.uk

*Present address: Siemens AG, Med MRIA, Postfach 3260, D-91050 Erlangen, Germany

Summary

Children who have suffered extensive unilateral brain injury early in life may show a remarkable degree of residual sensorimotor function. It is generally believed that this reflects the high capacity of the immature brain for cerebral reorganization. In this study, we investigated 17 patients who had undergone hemispherectomy for relief from seizures; eight of the patients had congenital brain damage and nine had sustained their initial insult at the age of 1 year or older. Sensorimotor functions of the hand were investigated using functional MRI (fMRI) during a passive movement task, somatosensory evoked potentials (SEPs) arising from electrical and vibration stimulation, and behavioural tests including grip strength, double simultaneous stimulation and joint position sense. On fMRI, two of the eight patients studied with this technique (one with congenital damage and one with damage acquired at the age of 3 years) showed activation in the sensorimotor cortex of the remaining hemisphere with passive movement of the hemiplegic hand. The location of the ipsilateral brain activation was similar to that found on movement of the normal contralateral

hand, although the latter was greater in spatial extent. In one of these patients, a greater role was demonstrated for the ipsilateral secondary sensorimotor area (compared with the ipsilateral primary sensorimotor area) for movement of the hemiplegic hand than for movement of the normal hand. Median nerve stimulation of the hemiplegic hand showed reproducible early-latency ipsilateral SEP components in the remaining sensorimotor cortex in 10 of the 17 patients (five with congenital and five with acquired disease). Five of the patients who demonstrated ipsilateral electrical SEPs also showed ipsilateral vibration SEPs (two with congenital and three with acquired disease). The behavioural tests revealed residual sensorimotor function in 14 of the patients; however, not all of the patients who exhibited ipsilateral SEP or fMRI responses had residual sensorimotor function in the hemiplegic hand. Ipsilateral sensorimotor responses were demonstrated both in patients with congenital disease and those with acquired disease, suggesting that factors additional to aetiology and age at injury may influence the degree of residual sensorimotor function and cerebral reorganization.

Keywords: reorganization; sensorimotor; hemispherectomy; children; fMRI

Abbreviations: fMRI = functional MRI; SEP = somatosensory evoked potential; S-II = second somatosensory cortex

Introduction

Hemispherectomy is a surgical procedure that is sometimes performed for the treatment of children with severe drug-resistant epilepsy arising from conditions such as hemimegalencephaly, Sturge–Weber syndrome, infantile hemiplegia and Rasmussen's encephalitis (Tuxhorn *et al.*, 1997). Anatomical hemispherectomy involves complete excision of

the hemisphere in which the seizures originate (Dandy, 1928), whereas functional hemispherectomy involves only partial removal (but complete disconnection) of the hemisphere (Rasmussen, 1973; Tinuper *et al.*, 1988; Villemure and Rasmussen, 1993). A number of investigations of hemispherectomized patients have noted a remarkable degree of

residual sensorimotor function in the limb contralateral to the excised hemisphere (Bell and Karnosh, 1949; Krynauw, 1950; Cairns and Davidson, 1951; French and Johnson, 1955a, b; Obrador, 1964; Ueki, 1966; Wilson, 1970; Zülch, 1974; Zülch and Micheler, 1978; Glees, 1980; Verity *et al.*, 1982; Müller *et al.*, 1991), some showing unchanged or even improved motor function after surgery (Gardner *et al.*, 1955; Damásio *et al.*, 1975; Van Buren and Fedio, 1976; Ameli, 1980; Beardsworth and Adams, 1988; Becking *et al.*, 1994; Peacock *et al.*, 1996; Vargha-Khadem *et al.*, 1997). As the entire sensorimotor cortex in one hemisphere is removed or functionally disconnected in these patients, this residual function must be subserved either by cortical regions in the remaining hemisphere or by subcortical regions.

A number of attempts have been made to identify the cortical regions associated with sparing or recovery of motor function in patients who have undergone hemispherectomy. Using transcranial magnetic stimulation, ipsilateral muscle action potentials have been recorded after stimulation of the intact hemisphere both in patients with congenital disease and in patients with acquired disease (Benecke *et al.*, 1991). The cortical representation of such ipsilateral muscle action potentials was reported to be similar in location to the normal contralateral representation or in a region 2–4 cm anterior to this (Benecke *et al.*, 1991; Pascual-Leone *et al.*, 1992). The involvement of secondary association areas has also been suggested. Activation of the supplementary motor area, insula, inferior frontal cortex, premotor area, basal ganglia and cerebellum in the isolated hemisphere after movement of the hemiplegic hand has been reported in a number of PET studies (Müller *et al.*, 1997b, 1998; Toussaint *et al.*, 1997). In addition, somatosensory evoked potential (SEP) studies have demonstrated ipsilateral cortical and subcortical responses after stimulation of the median nerve contralateral to the removed hemisphere (Hazemann *et al.*, 1969; Matsumita *et al.*, 1971; Villanueva and Castilla, 1988; Mauguière and Desmedt, 1989; Dijkerman *et al.*, 1993). Such ipsilateral responses exist independently of any contralateral potentials, since in these patients one hemisphere has been functionally disconnected.

To date, there have been few functional MRI (fMRI) studies reported in hemispherectomized patients, and these mainly report case studies of one or two patients. Spencer and colleagues investigated active and passive movements of the normal and paretic hands in a single patient who underwent hemispherectomy at the age of 16 years (Spencer *et al.*, 1998). The patient had Rasmussen's encephalitis, with refractory seizures from the age of 12 years. They did not detect any activation with passive movement of the paretic hand, and cerebral activation associated with active and passive movement of the normal side was apparently more diffuse than expected, involving the premotor, supplementary motor and parietal areas. Using elbow flexion/extension (sensorimotor task) or tactile stimulation (sensory task), Graveline and colleagues investigated two patients who had undergone hemispherectomy surgery, one at 9 years and the other at 17 years of age. Both patients had had intractable

seizures from younger than 9 years of age; one had Sturge-Weber syndrome and the other had suffered a middle cerebral artery infarction. With the motor task, the patient who underwent surgery at age 9 years (Patient 1) showed contralesional activation in the supplementary motor and premotor areas on movement of both hemiparetic and non-hemiparetic limbs, while the second patient showed only premotor cortex activation. In both cases, the premotor and supplementary motor area activations on movement of the hemiparetic limb were smaller in extent than those involving the normal limb. Sensory stimulation of the non-hemiparetic hand produced contralateral activations in the primary sensory and motor cortices, in the premotor and supplementary motor areas (Patient 1 only), and in a region posterior to the somatosensory cortex. In Patient 1, sensory stimulation of the hemiparetic hand was reported to activate areas similar to those activated with the non-hemiparetic hand, while the second patient only showed activation in the posterior somatosensory area (Graveline *et al.*, 1998).

The aim of the present study was to investigate the cortical substrates associated with residual sensorimotor function in a group of 17 hemispherectomized children using fMRI and SEP techniques. In order to examine whether the age at injury has a differential effect on sensorimotor reorganization, the patients were divided into two groups, one with congenital disease and the other with acquired disease. Behavioural measures were used to determine residual sensory and motor function in the distal portion of the upper limb contralateral to the hemispherectomized side, and the findings were related to the fMRI and SEP data.

Methods

Patients

Patients were selected for the study if they had undergone either functional or anatomical hemispherectomy and were at least 1 year post-surgery. Only patients who were older than 5 years and were sufficiently cooperative to undergo SEP recordings were included in the study.

Seventeen patients were involved in this study, with ages ranging from 7 to 19 years (mean age 12 years 9 months). There were seven females and 10 males. Ten patients had undergone left hemispherectomy and seven had undergone right hemispherectomy; four patients had anatomical hemispherectomy and 13 had functional hemispherectomy.

Informed consent was obtained from all patients, and the study was approved by the Great Ormond Street Hospital for Children/Institute of Child Health Research Ethics Committee.

Behavioural measures

Measures of sensory and motor function of the hand were obtained for all patients. The motor tasks consisted of moving pegs, force production and finger-tapping. For peg-moving, a pegboard was used which consisted of two

rows of 10 holes (Annett, 1970a, b). Ten short (2 cm) wooden pegs were placed in the top row of holes, and the patient was instructed to move the pegs one at a time into the corresponding hole in the bottom row as quickly as possible. The procedure was timed with a stopwatch, and an average score was obtained from five trials performed with each hand, alternating sides. Force production by the hand was assessed using a hand dynamometer (Model 78011; Lafayette Instruments, Lafayette, Ind., USA), which measures grip strength in kilograms (Dodrill, 1978). An average score was obtained from three trials performed with each hand, alternating sides. Finger-tapping was carried out with a manual tapper mounted on a wooden board connected to an electronic counter (Peters and Durling, 1979; Peters, 1981). Patients were instructed to tap with their index finger (i.e. to depress the switch) as many times as possible in 20 s. An average score was taken from two runs with each hand, alternating the two sides. This test was also used to assess the presence of mirror movements. The hand not tapping rested on the table and was observed for movement which clearly mimicked the tapping of the index finger of the opposite hand. In all three tasks, the hand ipsilateral to the operated hemisphere was always tested first.

The sensory measures included double simultaneous stimulation and joint position sense. The procedure for double simultaneous stimulation consisted of the investigator touching a finger on the patient's hand, either in isolation or simultaneously with a finger on the other hand (Bender, 1945). After training, the patient wore a blindfold and was instructed to indicate which finger(s) had been touched. Each combination of fingers touched was tested in a randomized order to prevent bias. There were no blank trials. For joint position sense, the subject's distal phalanx was moved six times up and six times down by the investigator in a randomized order on each finger in turn, and the patient was asked to report the direction of each single movement whilst blindfolded (Corkin *et al.*, 1970).

The patients' residual sensory function in the affected hand was graded according to their performance in the test of double simultaneous stimulation (the test of joint position sense was performed in only 12 of 17 patients, and therefore could not be used in the classification of patients' sensory function). A score of $\geq 80\%$ correct responses was designated as indicating normal function, 60–79% mild deficit, 30–59% moderate deficit, 1–29% severe deficit, and 0% no detectable function.

In order to grade residual motor function in the affected hand, an average value was calculated from the patients' performance in the peg-moving, force production and finger-tapping tests. Expressed as a percentage of the score achieved with the unaffected hand, a performance of $\geq 80\%$ was designated as indicating normal function, 60–79% mild deficit, 30–59% moderate deficit, 1–29% severe deficit, and 0% no detectable function.

SEP recordings

All patients had SEP investigations, involving electrical stimulation applied above the motor threshold (i.e. such that a visible twitch in the thumb was observed). Electrical stimuli were of 0.2 ms duration and delivered to the median nerve at the wrist at a rate of 2 Hz using surface electrodes and an isolated constant current stimulator (Model DS2; Digitimer, Welwyn Garden City, UK). In an attempt to corroborate the findings from electrical stimulation, 10 of the more cooperative patients also underwent SEP recordings in response to vibration stimuli, using a method similar to that described by Hämäläinen and colleagues (Hämäläinen *et al.*, 1990). Vibration stimuli were delivered to the index and middle fingertips (median nerve stimulation) via a T-bar attached to an oscillating coil driven by a computer-generated sine wave, with a rise time of 0.3 ms. Fingertip stimulation was chosen because it was not possible to stimulate the median nerve in isolation at the wrist using a T-bar, and also because vibration of the T-bar at the fingertips was more comfortable for the children. The displacement of the T-bar was set to 2 mm; stimuli lasted for 150 ms and were applied at the rate of 1 per second at the frequency of 60 Hz.

Recordings were taken from a total of 50 electrodes, 44 of which were located over the intact hemisphere. Because the location of any ipsilateral response could not be assumed in advance, a large number of electrodes were used to ensure that any response could be detected, particularly if it proved to have a field of small spatial extent. Continuous data were collected using a SYNAMPs digital amplifier system (Neuroscan Inc., Herndon, Va., USA) and Neuroscan version 4 software, with a bandwidth of 0.05–200 Hz and sampling rate 5 kHz, and were amplified at $\times 12\,500$. Responses to 200 electrical stimuli and 400 vibration stimuli were acquired. Epochs of –50 to 200 ms were subsequently selected and averaged. All averages were referenced to two frontal electrodes over the side of the excision. Vibration and electrical SEPs were digitally filtered off-line at 0.3–55 and 0.3–100 Hz respectively. The vibration SEPs were filtered at a lower frequency than electrical SEPs to filter out the 60 Hz artefact from the stimulus itself. At least two runs of each paradigm were collected and compared to ensure reproducibility. Topographical 2D surface voltage maps were constructed subsequently, using the Neuroscan software. Recordings were made after separate stimulation of both the normal and the hemiplegic hand. In every case, ipsilateral potentials could be compared directly with normal contralateral responses, as data were acquired in the same session. The largest early-latency (10–200 ms) ipsilateral positive or negative component was used for analysis and display. Amplitude measurements from the waveforms were taken from the first peak-to-peak distance of different polarities, and the latency was measured from the earliest positive or negative component. Paired *t*-tests were performed between contralateral and ipsilateral measurements.

Table 1 Patient details

Patient	Age at first seizure (years.months)	Aetiology/pathology	Age at surgery (years/months)	Age at time of testing (years/months)	Residual sensory function	Residual motor function	Ipsilateral fMRI activation	Ipsilateral electrical SEPs	Ipsilateral vibration SEPs
Congenital disease									
1	0.0	SWS	8.7	17.0	*	*	N	Y	Y
2	0.0	MCA infarct	9.8	15.0	†	0	N	N	–
3	0.0	Hemimegalencephaly	0.4	6.8	*	0	–	N	–
4	0.1	CD	15.4	19.0	†	0	Y	Y	–
5	0.7	Intractable seizures/gliosis	12.4	14.2	†	0	–	Y	–
6	1.6	Extradural cyst	13.9	18.2	*	† (m)	N	N	–
7	4.5	Porencephaly	11.10	13.1	*	* (m)	–	Y	Y
8	7.0	CD	10.5	19.5	‡	† (m)	–	Y	N
Acquired disease									
9	1.7	RE	5.2	9.0	0	0	–	Y	–
10	2.4	RE	11.8	12.6	*	0	–	N	N
11	2.5	MCA infarct	9.6	13.7	‡	0	–	Y	N
12	3.7	RE	4.1	9.0	0	0	N	N	N
13	4.4	RE	7.0	14.0	*	0	–	Y	Y
14	4.8	RE	6.10	8.7	0	0	–	N	N
15	6.0	RE	11.9	16.0	*	0	N	Y	Y
16	7.0	MCA infarct	14.9	18.0	†	0	Y	Y	Y
17	8.0	RE	15.10	17.0	†	0	N	N	–

RE = Rasmussen's encephalitis; MCA infarct = middle cerebral artery infarct; SWS = Sturge–Weber syndrome; CD = cortical dysplasia; Y (yes) = detectable response; N (no) = no detectable response; – = a particular investigation was not performed; 0 = no function; (m) = mirror movements. *Severe deficit, †moderate deficit and ‡mild deficit in the hand contralateral to the removed hemisphere (see Methods).

Functional MRI

MRI investigations were performed on a 1.5 T Siemens Vision system. Axial T₁-weighted FLASH (fast low angle shot) images [TR (repetition time) = 31 ms, TE (echo time) = 11 ms, flip angle 40°, matrix size 256 × 256 × 64, voxel size 0.75 × 0.75 × 3 mm] were collected for the anatomical localization of activated voxels. Functional MRI was performed using a whole-brain 3D EPI (echo planar imaging) sequence [TR = 87 ms, TE = 40 ms, flip angle = 30°, matrix 64 × 64 × 64, 3 mm isotropic voxels (Porter *et al.*, 1997)]. The anatomical and functional data sets were acquired from identical positions. Eight of the patients underwent passive movement of both the normal and hemiplegic hand, performed by the examiner moving the patient's fingers in and out of the palm with a flexion/extension movement of the metacarpophalangeal joints, at a rate of ~2 Hz. A total of 120 3D data sets were collected, divided into 12 task–rest cycles with five data sets in each state. The total acquisition time for one experiment was just under 12 min. The collected images were realigned and analysed using statistical parametric mapping (Friston *et al.*, 1995) (SPM96b, Wellcome Department of Cognitive Neurology, London, UK). Activation maps were spatially smoothed to three times the original voxel size. *P*-values are reported as uncorrected or corrected for multiple comparisons.

Patients were excluded from fMRI investigations if they had potentially magnetic vascular clips within the brain, or were too young or intellectually impaired to achieve the required level of cooperation.

Ten adult normal volunteers (four males and six females, age range 22–29 years, mean age 25 years 5 months, four

left-handed and six right-handed) and six child controls (five males and one female, age range 9–15 years, mean age 11 years 7 months, three right-handed, three left-handed) were included in the study. Passive movement was performed with the participant's arm, hand and fingers fixed to a support with Velcro straps and the fingers were flexed by means of a rod attached to the distal end of the support.

Results

Patients

Details of the 17 patients involved in the study are shown in Table 1. There were eight patients with congenital disease and nine with acquired disease. There was a large difference between the mean age at first seizure between these two groups (1 year 7 months in patients with congenital disease compared with 4 years 4 months in patients with acquired disease). However, the mean age at surgery (10 years 3 months and 9 years 6 months for patients with congenital and acquired disease, respectively) and the mean age at the time of investigation (15 years 4 months and 13 years 1 month for patients with congenital and acquired disease, respectively) were similar for the two groups.

Summary of findings

Table 1 summarizes the data obtained with behavioural measures, SEP recordings and fMRI, each of which are discussed in turn below.

Behavioural measures

All eight patients with congenital disease had some residual sensory function in the hand contralateral to the hemispherectomized side on double simultaneous stimulation. Four of the patients with congenital disease showed residual motor function on the measure of force production. (Three of these patients also demonstrated residual motor function on the finger-tapping and peg-moving tests.) Of these four patients, three had mirror movements (Patients 6, 7 and 8) and one patient had independent hand movements (Patient 1).

Of the nine patients with acquired disease, six showed residual sensory function, including patients with early onset and with late onset of epilepsy. However, none of these patients demonstrated any residual motor function in the limb contralateral to the surgically removed hemisphere.

SEPs

Electrical SEPs

All 17 patients showed a normal contralateral SEP response on electrical stimulation of the unaffected hand (Fig. 1). Five of the eight patients with congenital disease and five of the nine patients with acquired disease demonstrated ipsilateral SEPs on electrical stimulation of the hemiplegic side. Figure 1 (B and C) shows the results from two of the patients who demonstrated an ipsilateral electrical SEP response on stimulation of the hemiplegic hand. None of the remaining patients showed any detectable response to stimulation of the affected hand.

Of the 10 patients who demonstrated ipsilateral SEPs, the latency of the earliest positive or negative component was significantly longer ($P < 0.005$; paired t -test) for responses from the hemiplegic side than for responses from stimulation of the normal side (mean \pm standard deviation, 30.4 ± 8.8 and 45.6 ± 15.2 ms for stimulation of the normal and hemiplegic sides, respectively). In addition, the amplitude of the earliest peak-to-peak component was significantly smaller ($P < 0.0005$; paired t -test) for responses to stimulation of the hemiplegic side than for stimulation of the normal side (2.36 ± 1.6 and 6.46 ± 2.7 V, respectively).

Vibration SEPs

SEP recordings in response to vibration stimuli were undertaken in three of the eight patients with congenital disease and in seven of the nine patients with acquired disease. Normal contralateral vibration SEPs were recorded after stimulation of the unaffected hand. Individual vibration SEP components were longer in latency and smaller in amplitude than their electrical stimulus counterparts.

On stimulation of the hemiplegic side, ipsilateral vibration SEPs were detected in two of the three patients tested who had congenital disease and in three of the seven patients tested who had acquired disease. Figure 1A shows the results from one of the patients who demonstrated an ipsilateral

vibration SEP response on stimulation of the hemiplegic hand. Among the patients who demonstrated ipsilateral SEPs, the latency of the early component was significantly longer ($P < 0.05$; paired t -test) for responses from the hemiplegic side than for those from the normal side (mean \pm standard deviation, 66.2 ± 16.9 and 96.2 ± 17.8 ms for stimulation of the normal and hemiplegic side, respectively). In addition, the amplitude of the early component was significantly smaller ($P < 0.01$; paired t -test) for responses to stimulation of the hemiplegic side than of the normal side (1.35 ± 0.5 versus 3.72 ± 0.8 V).

Ipsilateral vibration SEPs on stimulation of the hemiplegic side were seen only in patients who also demonstrated ipsilateral electrical SEPs, and were similar in location to the equivalent ipsilateral electrical SEP in all five cases. Two patients showed ipsilateral electrical SEPs but no vibration SEPs.

Functional MRI

All 16 volunteers demonstrated contralateral primary sensorimotor cortex activation on passive movement of the left and right hands. None showed ipsilateral primary sensorimotor cortex activation on passive movement of either hand.

Eight of the 17 patients underwent fMRI. Of these eight patients, four had congenital disease (Patients 1, 2, 4 and 6) and four had acquired disease (Patients 12, 15, 16 and 17). There was a large difference in mean age at first seizure between these two groups (4 months in patients with congenital disease versus 6 years 2 months in patients with acquired disease). However, the mean age at surgery (12 years for patients with congenital disease, 11 years 5 months for patients with and acquired disease) and the mean age at the time of investigation (17 years 3 months for patients with congenital disease, 15 years for patients with acquired disease) were similar for the two groups.

All patients showed normal contralateral sensorimotor cortex activation on passive movement of the non-paretic hand. Examples are shown in Figs 2A and 3A.

Patients with congenital disease

One of the four patients with congenital disease (Patient 4) demonstrated ipsilateral primary sensorimotor cortex activation on passive movement of the hemiplegic hand (Fig. 2B). The site of cortical activation was similar in location to that seen with passive movement of the normal hand (Fig. 2A). The other three patients showed no detectable fMRI activation after passive movement of the hemiplegic side.

Patients with acquired disease

One of the four patients (Patient 16) with acquired disease demonstrated activation of the ipsilateral sensorimotor cortex on passive movement of the hemiplegic hand (Fig. 3B); the

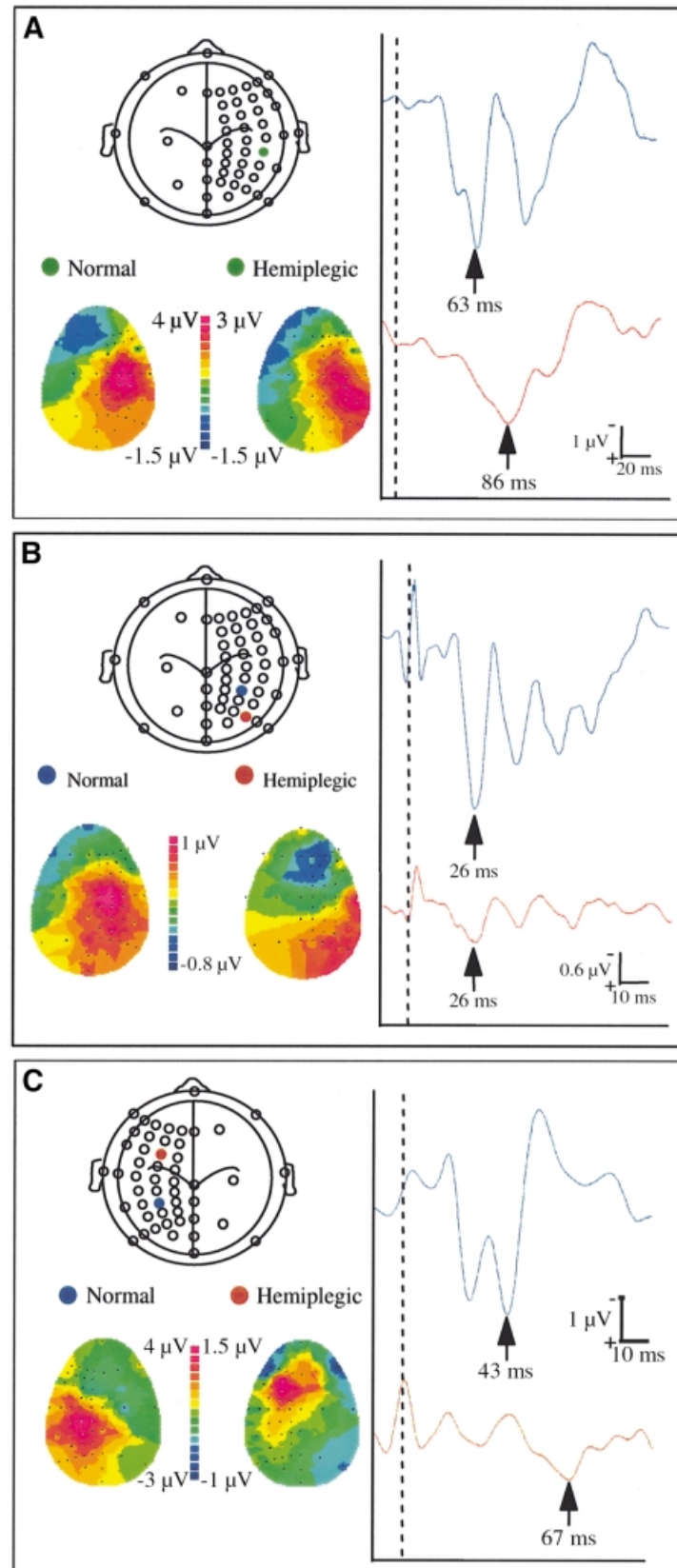


Fig. 1 SEP findings in (A) Patient 1 (vibration stimulation), (B) Patient 4 (electrical stimulation) and (C) Patient 16 (electrical stimulation). *Top left*: schematic representation of the montage used. Blue electrode corresponds to peak contralateral SEP, red electrode to peak ipsilateral SEP, and green corresponds to peak contralateral and ipsilateral SEP. *Right*: selected waveforms of the peak activity for stimulation of the normal side (contralateral SEP, upper waveform) and hemiplegic side (ipsilateral SEP, lower waveform). *Bottom left*: 2D topographical voltage maps for indicated time-points for stimulation of normal and hemiplegic sides.

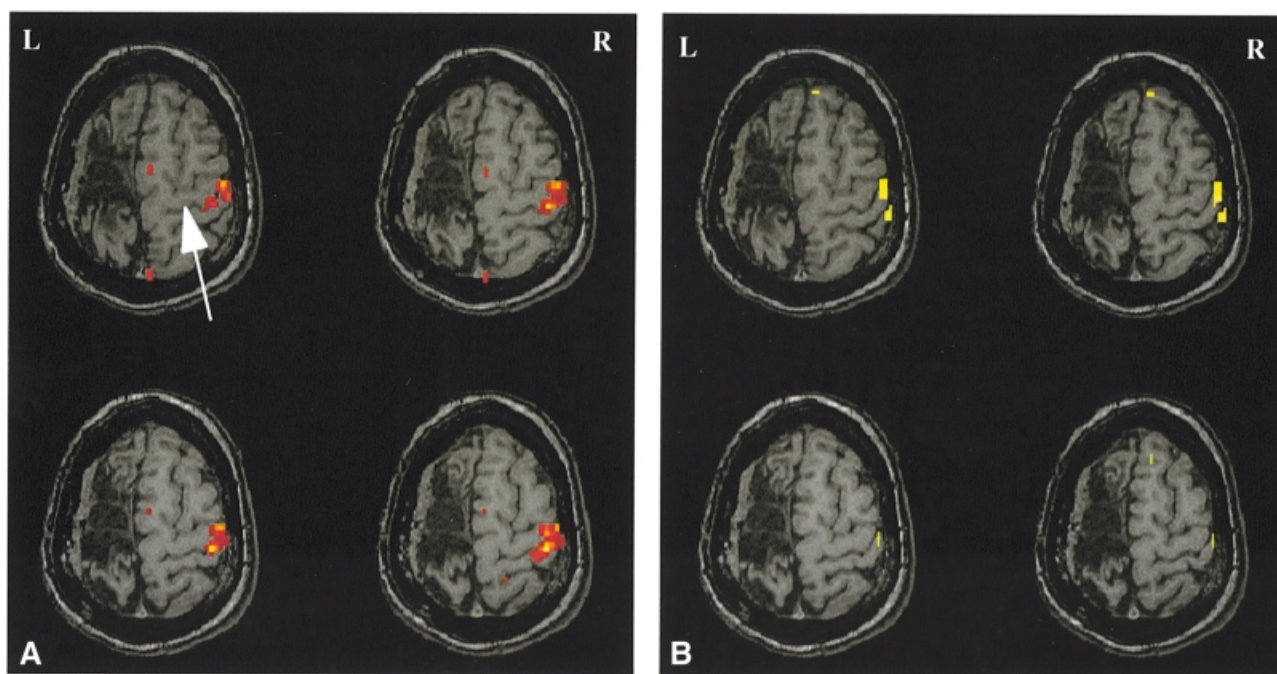


Fig. 2 Four adjacent axial slices through the sensorimotor cortex in Patient 4. Sensorimotor cortex activation (the central sulcus is indicated by the arrow) is shown for passive movement of the normal (right) hand (A) and for passive movement of the hemiplegic (left) hand (B). Yellow voxels are more significant than red voxels.

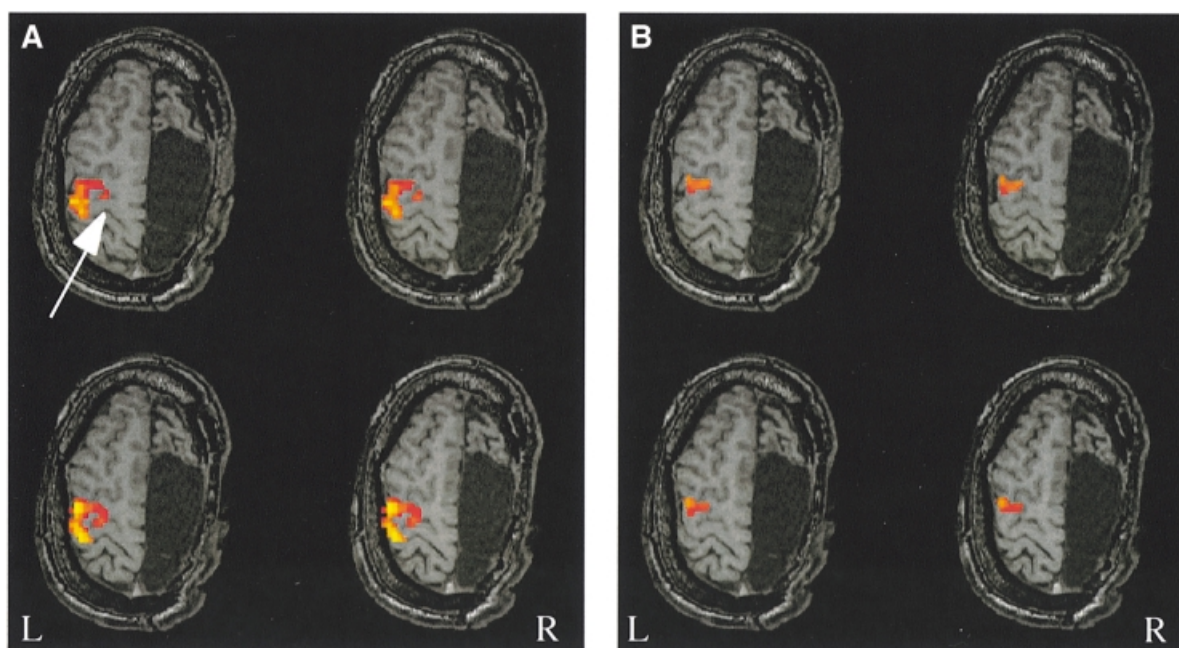


Fig. 3 Four adjacent axial slices through the sensorimotor cortex in Patient 16. Sensorimotor cortex activation (the central sulcus is indicated by the arrow) is shown for passive movement of the normal (right) hand (A) and passive movement of the hemiplegic (left) hand (B). Yellow voxels are more significant than red voxels.

other three patients showed no detectable fMRI activation. The location of activation was along the precentral sulcus, anterior to the primary motor cortex, consistent with activation of the premotor cortex. The activation on passive movement of the normal hand was more extensive in distribution (Fig. 3A), with maximal significance over the central sulcus,

posterior to the location of the ipsilateral activation. All of the functional images are displayed at an uncorrected P -value threshold of 0.01.

Figure 4 shows the distribution of activation throughout the brain on passive movement of the normal (panel A) and hemiplegic (panel B) hand in Patient 16. Direct visual

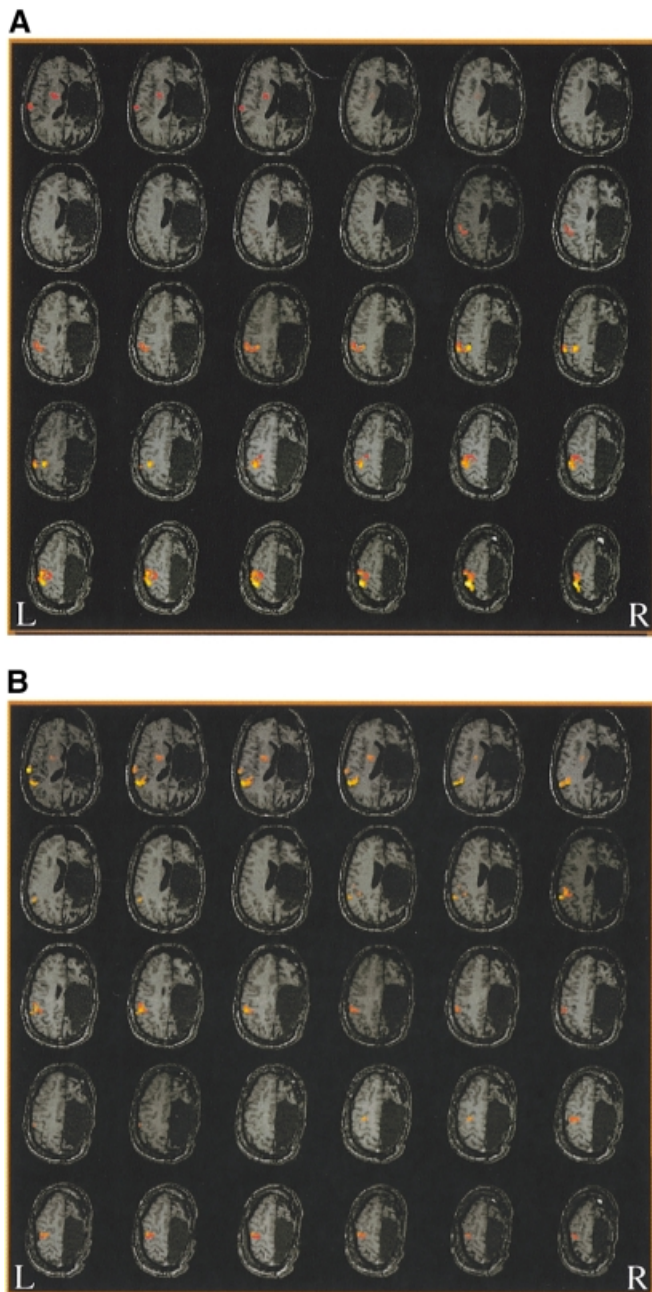


Fig. 4 Thirty axial images (covering most of the brain) showing the distribution of fMRI activation in Patient 16 after passive movement of the normal hand (**A**) and the hemiplegic hand (**B**). Yellow voxels are more significant than red voxels.

comparison revealed that, with the exception of the primary sensorimotor cortex, similar regions were activated with passive movement of the hemiplegic and normal hands. The activated regions are the primary sensorimotor cortex (normal hand only) and an immediately anterior area identified as the premotor cortex (Brodmann area 6), the lentiform nucleus of the basal ganglia, and the second somatosensory cortex (S-II) in the parietal operculum. The peak significance of the activated regions, however, differed between the two hands. On passive movement of the normal hand, peak activation

was detected in superior axial slices within the region of the primary sensorimotor cortex [this region and another in the anterior part of the S-II region achieved corrected significance ($P < 0.001$)]. However, with passive movement of the hemiplegic hand, the peak activation was located in the lower axial slices, within a posterior region of the S-II cortex that did not show significant activation on passive movement of the normal hand [this region achieved corrected significance ($P = 0.001$) with the hemiplegic hand]. Figure 5 shows one selected slice within the region of S-II for direct comparison of the activated regions with passive movement of the normal and hemiplegic hands of Patient 16.

Discussion

This study has demonstrated that SEP and fMRI recordings can be used to investigate sensorimotor function in patients who have undergone hemispherectomy. All of the patients examined (17 with electrical SEP, 10 with vibration SEP and eight with fMRI) showed normal SEP and fMRI responses in the contralateral primary sensorimotor area when stimuli were applied to the unaffected hand. Whenever detected (i.e. in 10 of the 17 patients who underwent electrical SEP, in five of the 10 patients who underwent vibration SEP and in two of the eight patients who underwent fMRI), the location of responses to stimuli applied to the hemiplegic side was confined to the intact (i.e. ipsilateral) hemisphere.

There has been much debate about the origin of ipsilateral responses in normal and diseased brains. In the normal human brain, ipsilateral fMRI responses have been shown to occur with active movement tasks (Li *et al.*, 1996; Singh *et al.*, 1998). They are thought to result from ipsilateral sensory and motor pathways which persist after cortical maturation. In the case of the motor system, such ipsilateral fibres may account for ~25% of all ascending fibres in the normal human (for review, see Nyberg-Hansen and Rinvik, 1963). However, the ipsilateral SEP responses to electrical stimuli that have been demonstrated in control subjects are thought by most authors to result from either voltage spread of the electrical current on the surface of the brain or interhemispheric transmission to the opposite sensorimotor cortex through the corpus callosum (e.g. Kakigi, 1986; Schnitzler *et al.*, 1995). Investigation of sensorimotor function in hemispherectomized patients provides an excellent opportunity to study such responses in the absence of any contribution from the other hemisphere. Although ipsilateral fMRI responses have been shown to occur in control subjects after active movement tasks, they have not been demonstrated on passive movement tasks (Goran *et al.*, 1996). In the present study, ipsilateral responses were demonstrated by fMRI on passive movement of the hemiplegic hand in two patients, although they have not been seen after passive movement of the hand in any of our adult or child controls. Isolated ipsilateral SEP responses were also seen after electrical and/or vibration stimuli applied to the hemiplegic hand in 10 patients. These responses were longer in latency and smaller in amplitude than the responses

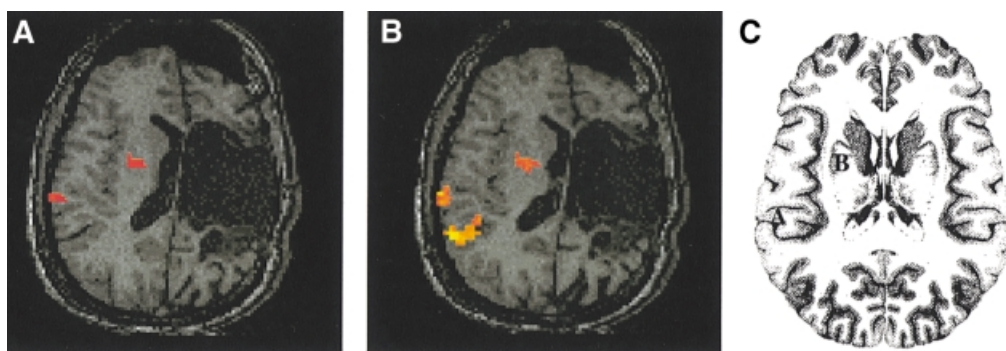


Fig. 5 Activation in the region of S-II from passive movement of the normal hand (A) and the hemiplegic hand (B) in Patient 16. (C) Schematic representation of the anatomical location of S-II (labelled A) and the lentiform nucleus (labelled B).

to stimuli applied to the contralateral side, in agreement with several previous studies (e.g. Hazemann *et al.*, 1969).

However, it should be noted that in some cases, because of differences in the waveforms of the responses to stimulation of the two sides, it is not possible to be certain that the selected components are functionally equivalent. The ipsilateral responses in these hemispherectomized patients must occur as a consequence of direct ipsilateral pathways; they cannot be due to voltage spread or transcallosal pathways from the opposite hemisphere. This conclusion is consistent with that suggested in previous studies of hemispherectomized patients (Villanueva and Castilla, 1988).

There are several possible reasons why direct ipsilateral pathways may become more active in the diseased brain. There may be a strengthening of the ipsilateral connections that have been present from childhood, this strengthening being promoted by functional demand (Benecke *et al.*, 1991). Alternatively, there may be reorganization of the ipsilateral pathway with axonal sprouting to allow a novel functional pathway (Hicks and D'Amato, 1970; Barth and Stanfield, 1990; Farmer *et al.*, 1990; Cohen *et al.*, 1991; Carr *et al.*, 1993). It has also been suggested that during cortical maturation through childhood, ipsilateral pathways become functionally suppressed by an inhibitory influence from the opposite hemisphere through the corpus callosum (Netz *et al.*, 1997). This is supported by the fact that children may show associated movements until the age of ~10 years, when callosal maturation is thought to be complete (Yakolev and Lecours, 1967; Lazarus and Todor, 1987). In addition, one study has demonstrated the presence of ipsilateral motor evoked potentials, which are no longer detected after the age of ~10 years (Müller *et al.*, 1997a). After hemispherectomy, particularly if the hemispherectomy (or brain damage) takes place early in life, such inhibition would not occur and so the ipsilateral pathways would remain functioning as the child went through cortical maturation. This might be expected to result in the patient displaying mirror movements; it may be significant that, of the patients in this study who had significant residual motor function, three out of four showed mirror movements. However, the two patients who

demonstrated ipsilateral fMRI activation on passive movement of the hemiplegic hand did not display mirror movements.

There is debate in the literature about the location of ipsilateral responses and how ipsilateral fibres may be organized in the primary sensorimotor cortex relative to contralateral fibres. A number of studies using different techniques have demonstrated ipsilateral activation in a similar location to, or overlapping with, the contralateral activation (e.g. Benecke *et al.*, 1991; Roth *et al.*, 1996). This suggests that the projections of ipsilateral and contralateral sensorimotor fibres are intermingled with each other at the level of the cortex (which is also suggested in a transcranial magnetic stimulation study by Wassermann *et al.*, 1994). Other studies have reported ipsilateral responses located several centimetres anterior to the peak location of the contralateral response. Pascual-Leone and colleagues, using transcranial magnetic stimulation in five hemispherectomized patients, found two peak locations for ipsilateral motor responses: one identical to and one 2–4 cm anterior to the contralateral response (Pascual-Leone *et al.*, 1992). The responses that occur in these two regions may result from two distinct pathways that may serve ipsilateral function: the uncrossed corticospinal (primary motor cortex) and corticoreticulospinal (premotor cortex) pathways. Benecke and colleagues also suggested that there may be two pathways involved in ipsilateral sensorimotor reorganization: in patients with acquired disease, ipsilateral projections may be associated with the corticoreticulospinal pathway, whereas patients with congenital disease may show ipsilateral projections from corticoreticulospinal or uncrossed corticospinal pathways (Benecke *et al.*, 1991). The reticulospinal and uncrossed corticospinal pathways both contain fast-conducting fibres and both originate from the primary motor cortex (although the reticulospinal pathway has a larger projection from the premotor cortex) (Lawrence and Kuypers, 1968; Freund, 1987). In the present study, the fMRI results indicate that one patient with congenital disease showed maximal ipsilateral activation on passive movement of the hemiplegic hand that was in a similar location to the region

activated in the primary sensorimotor cortex on passive movement of the normal side. A second patient with acquired disease demonstrated ipsilateral activation consistent with activation of the premotor cortex (Fig. 3B). Passive movement of the normal hand also showed activation in this region, in addition to the peak activation seen more posteriorly in the primary sensorimotor cortex. The work of Benecke and colleagues provides evidence for the recruitment of the reticulospinal pathway and the uncrossed corticospinal pathway in sensorimotor reorganization, as described above (Benecke *et al.*, 1991). It is possible, therefore, that the anteriorly located ipsilateral activation demonstrated in the patient with acquired disease may have been due to the activation of the corticoreticulospinal pathway, while the ipsilateral corticospinal tract may have been responsible for the ipsilateral activation in the patient with congenital disease.

Many studies have found an association between the activation found in the ipsilateral (as well as the contralateral) primary motor cortex and the presence of mirror movements (e.g. Cohen *et al.*, 1991; Weiller *et al.*, 1992). In addition, several studies have reported mirror movements in patients who have undergone hemispherectomy (Ueki, 1966; Müller *et al.*, 1991). Weder and Seitz suggested that the effort of the patient to move the fingers of the affected hand resulted in associated movements and bilateral activation of the motor cortex (Weder and Seitz, 1994). This raises the possibility that ipsilateral activations might be due to additional contralateral movements and represent an epiphenomenon. In this study, passive movement was carried out during fMRI investigations which did not involve active participation by the patients. All patients were assessed before the fMRI examination to ensure that they could allow one hand to be moved without moving the contralateral hand. In addition, during the session the contralateral hand was positioned so that it could be seen by the examiner to ensure that it was not moving. One patient did have demonstrable mirror movements, but it was still possible to move the hemiplegic hand passively with no visible movement in the normal hand. In fact, in fMRI this patient did not demonstrate ipsilateral activation on passive movement of the hemiplegic hand, thereby supporting the view that increased activation in the unaffected sensorimotor cortex after movement of the hemiplegic side is not a result of simultaneous contralateral movement of the unaffected hand. For all SEP recordings performed in this study, interaction between the hands was prevented by ensuring that the patients' hands were kept apart throughout the session, so that the stimulus could not be felt in the other hand.

A further potential source of ipsilateral activation on fMRI is movement of the ipsilateral shoulder during the hand movement task, since the proximal muscles of the limbs have bilateral cortical representation (Colebatch *et al.*, 1991). However, as emphasized above, the motor task performed in the present study consisted of passive movement of the patient's hand, which minimizes the potential for involvement of remote muscle activity; it should be noted in this context that none of our control studies, performed using the same

passive task, showed any evidence of ipsilateral activation on fMRI.

As expected from the literature (e.g. Gardner *et al.*, 1955), patients with congenital disease showed generally better residual sensory and motor function in the hemiplegic limb than patients with acquired disease. Such function, however, does not appear to correlate with the demonstration of ipsilateral responses with fMRI or SEP. For example, patients with the greatest amount of residual sensory or motor function did not necessarily demonstrate ipsilateral responses. (It should be noted, however, that the absence of detectable ipsilateral activation in patients with brain lesions does not necessarily mean that there is no neuronal activity in the appropriate region, as it may be below the level of sensitivity of the techniques used for investigation.) In addition, functional activations were seen equally in patients with congenital and acquired disease, and there also appeared to be no difference between patients with early and late acquired disease in ipsilateral responses or residual function. Patients who demonstrated residual sensory but no motor function also showed ipsilateral SEP and fMRI responses. In one case, ipsilateral SEP responses to electrical stimuli were seen even though the patient displayed no residual sensory or motor function in the hemiplegic hand. Residual sensory or motor function therefore appears not to be a prerequisite for ipsilateral cortical sensorimotor activation using fMRI and SEPs.

Previous investigators have generally shown a correlation between residual sensorimotor function and the time of onset of the disease (e.g. Benecke *et al.*, 1991). The present study does not show such a correlation, but this may be explained by a number of factors. First, several studies have suggested that the age at surgery influences the reorganization of sensory and motor function (e.g. Beckung *et al.*, 1994); as may be seen from Table 1, the mean age at which the patients had their surgery was similar for the groups with congenital and acquired disease, which may explain our findings. In addition, all of the children studied had their first seizure at the age of 8 years or younger. This is particularly significant, given the findings of Müller and colleagues suggesting that cortical maturation occurs around the age of 10 years (Müller *et al.*, 1997a). Cortical damage sustained before this time could effectively result in the reorganization of the sensory and motor pathways before 'hard wiring' is complete. Thus, in order to make significant interpretations of the effects of age of onset of disease and age at surgery, a greater number of patients with congenital and acquired disease and with more variation in the age of onset of the disease and age at surgery is required.

One patient in this study demonstrated particularly increased ipsilateral fMRI activation in the second somatosensory area (S-II) after passive movement of the hemiplegic hand. This finding suggests that reorganization may have occurred both interhemispherically (to the ipsilateral hemisphere) and intrahemispherically (within the ipsilateral hemisphere). First, there may be interhemispheric re-

organization through ipsilateral pathways subserving the sensation in the hand (as mentioned previously); secondly, intrahemispheric reorganization may occur within the remaining hemisphere, whereby secondary sensorimotor areas have a more important role with respect to the primary sensorimotor cortex in subserving sensorimotor function. Due to the intricate network of interconnecting fibres throughout the cortex, there are pre-existing fibres between the primary somatosensory cortex and S-II and between S-II and the descending sensory pathway (e.g. Fox *et al.*, 1987; Mauguière *et al.*, 1997). In fact, S-II is thought to represent the body bilaterally in the normal human (e.g. Richer *et al.*, 1993; Forss *et al.*, 1994). It appears unlikely, therefore, that axonal sprouting is entirely responsible for such reorganization of the input–output connections to S-II, but rather a strengthening of the fibres already present. There has been a small number of brain mapping studies demonstrating ipsilateral pathways in association sensorimotor cortices in hemispherectomized patients. Recently, Graveline and colleagues showed ipsilateral fMRI activation in the premotor and supplementary motor areas in patients after hemispherectomy (Graveline *et al.*, 1998). Several PET studies have also shown similar areas to be activated (e.g. Müller *et al.*, 1997b, 1998). However, none of these studies have reported an increased role for the ipsilateral S-II area in the reorganization of sensorimotor function in hemispherectomized patients.

Conclusions

In this study, activation of the ipsilateral sensorimotor cortex has been demonstrated using fMRI and SEP recordings in a number of children after hemispherectomy. In the two children who showed fMRI activation on passive movement of the hemiplegic hand, the location of the ipsilateral sensorimotor cortex activation was similar to that found on movement of the normal contralateral side. In addition, the results for one of the patients suggest a greater role for the secondary somatosensory area for movement of the hemiplegic hand than for movement of the normal hand. Ipsilateral sensorimotor responses were demonstrated in patients with both congenital and acquired disease, suggesting that factors additional to the age at injury may influence cerebral reorganization. Future studies, involving larger numbers of hemispherectomized patients, will be necessary to obtain a greater understanding of how cerebral reorganization can contribute to residual sensorimotor function.

Acknowledgements

We wish to thank our colleagues in the epilepsy surgery team. This work was undertaken by Great Ormond Street Hospital for Children NHS Trust, which received a proportion of its funding from the NHS Executive; the views expressed in this publication are those of the authors and not necessarily those of the NHS Executive. The work was also supported by the Wellcome Trust.

References

- Ameli NO. Hemispherectomy for the treatment of epilepsy and behavior disturbance. *Can J Neurol Sci* 1980; 7: 33–8.
- Annett M. The growth of manual preference and speed. *Br J Psychol* 1970a; 61: 545–58.
- Annett M. A classification of hand preference by association analysis. *Br J Psychol* 1970b; 61: 303–21.
- Barth TM, Stanfield BB. The recovery of forelimb-placing behavior in rats with neonatal unilateral cortical damage involves the remaining hemisphere. *J Neurosci* 1990; 10: 3449–59.
- Beardsworth ED, Adams CB. Modified hemispherectomy for epilepsy: early results in 10 cases. *Br J Neurosurg* 1988; 2: 73–84.
- Beckung E, Uvebrant P, Hedström A, Rydenhag B. The effects of epilepsy surgery on the sensorimotor function of children. *Dev Med Child Neurol* 1994; 36: 893–901.
- Bell ET, Karnosh LJ. Cerebral hemispherectomy. Report of a case ten years after operation. *J Neurosurg* 1949; 6: 285–93.
- Bender MB. Extinction and precipitation of cutaneous sensations. *Arch Neurol Psychiatry* 1945; 54: 1–9.
- Benecke R, Meyer BU, Freund HJ. Reorganisation of descending motor pathways in patients after hemispherectomy and severe hemispheric lesions demonstrated by magnetic brain stimulation. *Exp Brain Res* 1991; 83: 419–26.
- Cairns H, Davidson MA. Hemispherectomy in the treatment of infantile hemiplegia. *Lancet* 1951; 261: 411–5.
- Carr LJ, Harrison LM, Evans AL, Stephens JA. Patterns of central motor reorganization in hemiplegic cerebral palsy. *Brain* 1993; 116: 1223–47.
- Cohen LG, Zeffiro T, Bookheimer S, Wassermann EM, Fuhr P, Matsumoto J, et al. Reorganization in motor pathways following a large congenital hemispheric lesion in man: different ipsilateral motor representation areas for ipsi- and contralateral muscles [abstract]. *J Physiol (Lond)* 1991; 438: 33P.
- Colebatch JG, Deiber MP, Passingham RE, Friston KJ, Frackowiak RS. Regional cerebral blood flow during voluntary arm and hand movements in human subjects. *J Neurophysiol* 1991; 65: 1392–401.
- Corkin S, Milner B, Rasmussen T. Somatosensory thresholds. Contrasting effects of postcentral-gyrus and posterior parietal-lobe excisions. *Arch Neurol* 1970; 23: 41–58.
- Damásio AR, Lima A, Damásio H. Nervous function after right hemispherectomy. *Neurology* 1975; 25: 89–93.
- Dandy WE. Removal of right cerebral hemisphere for certain tumors with hemiplegia. *J Am Med Assoc* 1928; 90: 823–5.
- Dijkerman HC, Jones S, Polkey C, Vargha-Khadem F, Weiskrantz L. Sensorimotor functioning after a hemispherectomy, a case study [abstract]. *Soc Neurosci Abstr* 1993; 19: 616.
- Dodrill CB. The hand dynamometer as a neuropsychological measure. *J Consult Clin Psychol* 1978; 46: 1432–5.
- Farmer SF, Ingram DA, Stephens JA. Mirror movements studied in a patient with Klippel–Feil syndrome. *J Physiol (Lond)* 1990; 428: 467–84.

- Forss N, Salmelin R, Hari R. Comparison of somatosensory evoked fields to airpuff and electric stimuli. *Electroencephalogr Clin Neurophysiol* 1994; 92: 510–7.
- Fox PT, Burton H, Raichle ME. Mapping human somatosensory cortex with positron emission tomography. *J Neurosurg* 1987; 67: 34–43.
- French LA, Johnson DR. Examination of the sensory system in patients after hemispherectomy. *Neurology* 1955a; 5: 390–3.
- French LA, Johnson DR. Observations on the motor system following cerebral hemispherectomy. *Neurology* 1955b; 5: 11–4.
- Freund HJ. Abnormalities of motor behavior after cortical lesions in humans. In: Mountcastle CB, Plum F, editors. *Handbook of Physiology*, Sect 1, Vol V, Pt 2. Bethesda (MD): American Physiological Society; 1987. p. 763–810.
- Friston KJ, Holmes AP, Worsley KJ, Poline J-B, Frith CD, Frackowiak RSJ. Statistical parametric maps in functional imaging: a general linear approach. *Hum Brain Mapp* 1995; 2: 189–210.
- Gardner WJ, Karnosh LJ, McClure CC, Gardner AK. Residual functioning following hemispherectomy for tumour and for infantile hemiplegia. *Brain* 1955; 78: 487–502.
- Glees P. Functional cerebral reorganization following hemispherectomy in man and after small experimental lesions in primates. In: Bach-y-Rita P, editor. *Recovery of function*. Baltimore: Baltimore University Press; 1980. p. 106–26.
- Goran DA, Bernard RA, Nordell BA, Cooper TG, Conlon T, Neros C, et al. Cortical processing involved in the performance of a simple task: a functional MRI study [abstract]. *Neuroimage* 1996; 3 (3 Pt 2): S381.
- Graveline CJ, Mikulis DJ, Crawley AP, Hwang PA. Regionalized sensorimotor plasticity after hemispherectomy fMRI evaluation. *Pediatr Neurol* 1998; 19: 337–42.
- Hämäläinen H, Kekoni J, Sams M, Reinikainen K, Näätänen R. Human somatosensory evoked potentials to mechanical pulses and vibration: contributions of SI and SII somatosensory cortices to P50 and P100 components. *Electroencephalogr Clin Neurophysiol* 1990; 75: 13–21.
- Hazemann O, Olivier L, Dupont E. Potentiels évoqués somesthésiques recueillis sur le scalp chez 6 hémisphérectomisés. *Rev Neurol (Paris)* 1969; 121: 246–57.
- Hicks SP, D'Amato CJ. Motor–sensory and visual behavior after hemispherectomy in newborn and mature rats. *Exp Neurol* 1970; 29: 416–38.
- Kakigi R. Ipsilateral and contralateral SEP components following median nerve stimulation: effects of interfering stimuli applied to the contralateral hand. *Electroencephalogr Clin Neurophysiol* 1986; 64: 246–59.
- Krynauw RA. Infantile hemiplegia treated by removing one cerebral hemisphere. *J Neurol Neurosurg Psychiatry* 1950; 13: 243–67.
- Lawrence DG, Kuypers HG. The functional organization of the motor system in the monkey. I. The effects of bilateral pyramidal lesions. *Brain* 1968; 91: 1–14.
- Lazarus JA, Todor JI. Age differences in the magnitude of associated movement. *Dev Med Child Neurol* 1987; 29: 726–33.
- Li A, Yetkin FZ, Cox R, Haughton VM. Ipsilateral hemisphere activation during motor and sensory tasks. *AJNR Am J Neuroradiol* 1996; 17: 651–5.
- Matsumita Y, Gennarelli TA, Lombroso CT. Somatosensory evoked response in the hemispherectomized man [abstract]. *Electroencephalogr Clin Neurophysiol* 1971; 31: 289.
- Mauguière F, Desmedt JE. Bilateral somatosensory evoked potentials in four patients with long-standing surgical hemispherectomy. *Ann Neurol* 1989; 26: 724–31.
- Mauguière F, Merlet I, Forss N, Vanni S, Jousmäki V, Adeleine P, et al. Activation of a distributed somatosensory cortical network in the human brain: a dipole modelling study of magnetic fields evoked by median nerve stimulation. Part II: effects of stimulus rate, attention and stimulus detection. *Electroencephalogr Clin Neurophysiol* 1997; 104: 290–5.
- Müller F, Kunesch E, Binkofski F, Freund HJ. Residual sensorimotor functions in a patient after right-sided hemispherectomy. *Neuropsychologia* 1991; 29: 125–45.
- Müller K, Kass-Iliyya F, Reitz M. Ontogeny of ipsilateral corticospinal projections: a developmental study with transcranial magnetic stimulation. *Ann Neurol* 1997a; 42: 705–11.
- Müller R-A, Rothmel RD, Behen ME, Muzik O, Chakraborty PK, Chugani HT. Plasticity of motor organization in children and adults. *Neuroreport* 1997b; 8: 3103–8.
- Müller R-A, Chugani HT, Muzik O, Mangner TJ. Brain organization of motor and language functions following hemispherectomy: a [(15)O]-water positron emission tomography study. *J Child Neurol* 1998; 13: 16–22.
- Netz J, Lammers T, Homberg V. Reorganization of motor output in the non-affected hemisphere after stroke. *Brain* 1997; 120: 1579–86.
- Nyberg-Hansen R, Rinvik E. Some comments on the pyramidal tract, with special reference to its individual variations in man. *Acta Neurol Scand* 1963; 39: 1–30.
- Obrador S. Nervous integration after hemispherectomy in man. In: Schaltenbrand G, Woolsey CN, editors. *Cerebral localization and organization*. Madison (WI): University of Wisconsin Press, 1964. p. 133–54.
- Pascual-Leone A, Chugani HT, Cohen LG, Brasil-Neto JP, Wassermann EM, Valls-Sole J, et al. Reorganization of human motor pathways following hemispherectomy [abstract]. *Ann Neurol* 1992; 32. p. 120.
- Peacock WJ, Wehby-Grant MC, Shields WD, Shewmon DA, Chugani HT, Sankar R, et al. Hemispherectomy for intractable seizures in children: a report of 58 cases. [Review]. *Childs Nerv Syst* 1996; 12: 376–84.
- Peters M. Handedness: effect of prolonged practice on between hand performance differences. *Neuropsychologia* 1981; 19: 587–90.
- Peters M, Durling B. Left-handers and right-handers compared on a motor task. *J Mot Behav* 1979; 11: 103–11.
- Porter D, Howseman AM, Josephs O, Turner R. A comparison of 2D and 3D echo-planar imaging for whole brain fMRI [abstract]. *Proceedings of the ISMRM 5th Annual Meeting*; 1997. p. 1621.

- Rasmussen T. Postoperative superficial hemisiderosis of the brain, its diagnosis, treatment and prevention. *Trans Am Neurol Assoc* 1973; 98: 133–7.
- Richer F, Martinez M, Robert M, Bouvier G, Saint-Hilaire JM. Stimulation of human somatosensory cortex: tactile and body displacement perceptions in medial regions. *Exp Brain Res* 1993; 93: 173–6.
- Roth M, Decety J, Raybaudi M, Massarelli R, Delon-Martin C, Segebarth C, et al. Possible involvement of primary motor cortex in mentally simulated movement: a functional magnetic resonance imaging study. *Neuroreport* 1996; 19: 1280–4.
- Schnitzler A, Salmelin R, Salenius S, Jousmaki V, Hari R. Tactile information from the human hand reaches the ipsilateral primary somatosensory cortex. *Neurosci Lett* 1995; 200: 25–8.
- Singh LN, Higano S, Takahashi S, Abe Y, Sakamoto M, Kurihara N, et al. Functional MR imaging of cortical activation of the cerebral hemispheres during motor tasks. *AJNR Am J Neuroradiol* 1998; 19: 275–80.
- Spencer DC, Poldrack R, Vaidya CJ, Temple E, Glover GH, Zeifert P, et al. Functional brain reorganization after hemispherectomy with functional MRI [abstract]. *Epilepsia* 1998; 39 Suppl 6: 254.
- Tinuper P, Andermann F, Villemure JG, Rasmussen TB, Quesney LF. Functional hemispherectomy for treatment of epilepsy associated with hemiplegia: rationale, indications, results, and comparison with callosotomy. *Ann Neurol* 1988; 24: 27–34.
- Toussaint P-J, Bernasconi A, Ladbon-Bernasconi N, Meyer E, Villemure JG. Sensorimotor reorganisation after functional hemispherectomy: a CBF positron emission tomography study [abstract]. *Neuroimage* 1997; 5 (4 Pt 2): S323.
- Tuxhorn I, Holthausen H, Boenigk H. Paediatric epilepsy syndromes and their surgical treatment. London: John Libbey; 1997.
- Ueki K. Hemispherectomy in the human with special reference to the preservation of function. *Prog Brain Res* 1966; 21: 285–338.
- Van Buren JM, Fedio P. Functional representation on the medial aspect of the frontal lobes in man. *J Neurosurg* 1976; 44: 275–89.
- Vargha-Khadem F, Carr LJ, Isaacs E, Brett E, Adams C, Mishkin M. Onset of speech after left hemispherectomy in a nine-year-old boy. *Brain* 1997; 120: 159–82.
- Verity CM, Strauss EH, Moyes PW, Wada JA, Dunn HG, Lapointe JS. Long-term follow-up after cerebral hemispherectomy: neurophysiologic, radiologic, and psychological findings. *Neurology* 1982; 32: 629–39.
- Villanueva J, Castilla JM. Consideraciones anatomofuncionales sobre la vía generadora de los potenciales evocados somestésicos corticales de nervio mediano. Estudio en seis enfermos hemisferectomizados. *Arch Neurobiol (Madrid)* 1988; 51: 316–23.
- Villemure JG, Rasmussen T. Functional hemispherectomy in children. *Neuropediatrics* 1993; 24: 53–5.
- Wassermann EM, Pascual-Leone A, Hallett M. Cortical motor representation of the ipsilateral hand and arm. *Exp Brain Res* 1994; 100: 121–32.
- Weder B, Seitz RJ. Deficient cerebral activation pattern in stroke recovery. *Neuroreport* 1994; 5: 457–60.
- Weiller C, Chollet F, Friston KJ, Wise RJ, Frackowiak RS. Functional reorganization of the brain in recovery from striatocapsular infarction in man. *Ann Neurol* 1992; 31: 463–72.
- Wilson PJ. Cerebral hemispherectomy for infantile hemiplegia. A report of 50 cases. *Brain* 1970; 93: 147–80.
- Yakovlev PI, Lecours AR. The myelogenetic cycles of regional maturation of the brain. In: Minkowski A, editor. *Regional development of the brain in early life*. Oxford: Blackwell; 1967. p. 3–70.
- Zülch KJ. Motor and sensory findings after hemispherectomy: ipsi- or contralateral functions? *Clin Neurol Neurosurg* 1974; 77: 3–14.
- Zülch KJ, Micheler E. Hemispherectomy 25 years later—findings and concepts. *Neurosurg Rev* 1978; 1: 69–78.

Received January 5, 2000. Revised May 22, 2000.

Accepted July 24, 2000