

Cortical motor reorganization in akinetic patients with Parkinson's disease

A functional MRI study

U. Sabatini,^{1,5} K. Boulanouar,¹ N. Fabre,^{1,2} F. Martin,¹ C. Carel,^{1,2} C. Colonnese,⁵ L. Bozzao,⁵
I. Berry,^{1,3} J. L. Montastruc,⁴ F. Chollet^{1,2} and O. Rascol^{1,4}

¹INSERM U455 and Departments of ²Neurology, ³Neuroradiology, ⁴Clinical Pharmacology and Clinical Investigation Center, University Hospital of Toulouse, France and ⁵Neuroradiology Department, Istituto Mediterraneo di Neuroscienze, Pozzilli, Italy

Correspondence to: Professor O. Rascol, Laboratoire de Pharmacologie Médicale et Clinique, Faculté de Médecine, 37 Allées Jules Guesde, 31073 Toulouse Cedex, France
E-mail: rascol@cict.fr

Summary

Using functional MRI (fMRI), we have studied the changes induced by the performance of a complex sequential motor task in the cortical areas of six akinetic patients with Parkinson's disease and six normal subjects. Compared with the normal subjects, the patients with Parkinson's disease exhibited a relatively decreased fMRI signal in the rostral part of the supplementary motor area (SMA) and in the right dorsolateral prefrontal cortex, as previously shown in PET studies. Concomitantly, the same patients exhibited a significant bilateral relative increase in fMRI signal in the primary sensorimotor cortex, lateral premotor cortex, inferior parietal cortex, caudal part of the SMA and anterior cingulate cortex.

These fMRI data confirm that the frontal hypoactivation observed in patients with Parkinson's disease is restricted to the rostral part of the SMA and to the dorsolateral prefrontal cortex. These results also show that, apart from the lateral premotor and parietal cortices, increased fMRI signals can be found in other cortical motor areas of these patients, including the posterior SMA, the anterior cingulate cortex and the primary sensorimotor cortices, which are then likely to participate in the same putative attempt by the dopamine-denervated brain to recruit parallel motor circuits in order to overcome the functional deficit of the striatocortical motor loops.

Keywords: Parkinson's disease; fMRI; supplementary motor area; cingulate cortex; akinesia; motor reorganization

Abbreviations: DLPF = dorsolateral prefrontal; fMRI = functional MRI; SMA = supplementary motor area; SPECT = single photon emission computed tomography

Introduction

A limited number of pilot studies have used emission tomography, both single photon emission computed tomography (SPECT) and PET, to study the anatomofunctional correlates of akinesia in Parkinson's disease. These studies showed that cortical motor areas, such as the supplementary motor area (SMA), are 'underactive' in akinetic parkinsonian patients (Playford *et al.*, 1992; Rascol *et al.*, 1992, 1994; Jahanshahi *et al.*, 1995), while other motor areas, such as the parietal and lateral premotor cortex and the cerebellum, are 'overactive' (Rascol *et al.*, 1997; Samuel *et al.*, 1997a).

Beside PET and SPECT, functional MRI (fMRI) is another useful technique for localization of motor-related activity in the human brain. To the best of our knowledge, no fMRI study has yet been published describing brain activation in patients with Parkinson's disease. Using fMRI thus offers

the opportunity to study, with a novel method, how motor pathways of the parkinsonian brain are disorganized in response to the degeneration of the nigrostriatal dopamine projections. Therefore, we have compared motor activation in normal subjects and in akinetic patients with Parkinson's disease using fMRI.

Material and methods

Subjects

Six right-handed patients with an akinetic-rigid Parkinson's disease were studied. Handedness was determined by simple enquiry. All patients fulfilled the UK Parkinson's Disease Brain Bank criteria for the diagnosis of idiopathic Parkinson's

Table 1 Clinical details of Parkinson's disease patients (mean \pm SD)

Age (years)	61 \pm 8
Sex	2F, 4M
Disease duration (years)	5 \pm 2
Hoehn and Yahr score	2.7 \pm 0.5
UPDRS III score (off)	16 \pm 4
L-dopa daily dose (mg/day)	410 \pm 230
Bromocriptine daily dose (mg/day)	42 \pm 16

disease (Gibbs and Lees, 1988). All patients had a clear positive response to L-dopa. All were studied in the 'off' condition, 12 h after all anti-parkinsonian drugs had been withheld. None of the patients had tremor in the 'off' condition. Disability was recorded on the Hoehn and Yahr scale (Hoehn and Yahr, 1967) and the Unified Parkinson's Disease Rating scale (UPDRS) (Fahn *et al.*, 1987), immediately before the patients were scanned. We specifically selected patients with mild to moderate symptoms of Parkinson's disease in order to ensure that they could perform the task while in their 'off' state. The clinical details of the Parkinson's disease patients are summarized in Table 1.

Six right-handed normal volunteers (two females and four males; mean age 59 \pm 19 years) were included as a control group. All had a normal neurological examination and none had a history of neurological, cardiovascular or psychiatric disturbance. Handedness was determined by simple enquiry.

Informed consent was obtained from all patients and volunteers. The study was approved by the local ethical committee (Toulouse I CCPPRB)

Motor task

The activation paradigm consisted of a sequential movement performed with the right hand. This sequential task had been chosen among several others, according to preliminary fMRI data from our laboratory, because it induces a clear activation signal in areas known to be involved in both motor programming and motor execution. To perform this task, the subjects had to (i) make finger-to-thumb opposition movements in the specified order of the index, middle, ring and little finger; (ii) open and clench the fist twice; (iii) complete finger-to-thumb oppositions in the opposite order (i.e. little, ring, middle and index finger); (iv) open and clench the fist twice again; and finally (v) repeat the same series of movements during the 30 s of data acquisition. This was intentionally a more complex and cognitively demanding task than generally used in previously published SPECT and PET studies performed in patients with Parkinson's disease.

All subjects were instructed to practise this sequential task in advance, before the scan, until they were able to perform the full series without errors at a frequency of \sim 1 Hz and with an intermediate amplitude. Subjects were instructed not to move any other part of the body except the right hand, to ignore the scanning noise and to close their eyes. The baseline condition was defined as the 'resting state', when the subjects

were asked to relax without movement in the machine, with their eyes closed. A sound signal informed the subjects when they had to switch (every 30 s) from the 'resting state' to the 'activation state', and vice versa. During each test, two of the investigators (U.S. and N.F.) stayed beside the subject, closely watching all his/her movements. One observer counted the number of finger oppositions and hand clenches to measure movement frequency, checking that the sequences of movements were appropriate and quantifying the amplitude of the movements on a 0–3 point scale (0 = no amplitude, 3 = maximal amplitude of hand opening). All these parameters were recorded onto a grid specially designed for the purpose of the study. The second observer checked that the subject did not perform any unspecific associated movement.

fMRI data acquisition

Imaging was performed on a Siemens Magnetom Vision scanner operating at 1.5 T and equipped with EPI (echoplanar imaging) hardware. The subjects lay in the scanner with their eyes closed. Nine joint axial slices of 5 mm thickness, parallel to the intercommissural plane (from $z = +20$ mm to $z = +60$ mm) were collected using an EPI gradient echo sequence (echo time, TE = 66 ms; repetition time, TR = 3 s; flip angle = 90°; field of view, FOV = 200 mm, 64 \times 64 interpolated to 128 \times 128 mm pixels). The subjects were resting for 30 s and activating for 30 s four times. Each scanning run (4 min) thus comprised 80 image volumes (10 volumes per block). The first three images of each run were discarded to allow for T₁ stabilization.

T₁-weighted images were also acquired (128 slices, TR = 15 ms, TE = 7 ms, flip angle = 12°, voxel size = 1.2 mm) to obtain structural three-dimensional volume.

Data analysis

The fMRI data were analysed using SPM96 (Wellcome Department of Cognitive Neurology, London, UK) (Friston *et al.*, 1995). The functional images of each subject were realigned to the first volume and normalized to the stereotaxic space of Talairach and Tournoux (Talairach and Tournoux, 1988) using the three-dimensional volume. The images were spatially smoothed with a Gaussian kernel of 8 mm FWHM (full-width half-volume) and temporally smoothed with a Gaussian kernel (FWHM = 8 s).

The haemodynamic response function was modelled by a half-sine function. Low frequency noise was removed by applying a high-pass filter (0.5 cycles/min) to the fMRI time series at each voxel.

The 12 subjects (six parkinsonians and six controls) were included in the same statistical analysis on a pixel by pixel basis. Statistical parametric maps (SPMs) were then generated using an ANCOVA (analysis of covariance) model implemented through the General Linear Model formulation

Table 2 Mean frequency and amplitude of movements in the motor task (mean \pm SD)

Motor task	Controls ($n = 6$)	Parkinson's disease patients ($n = 6$)	<i>t</i> -test
Frequency of finger oppositions (per min)	18 \pm 3	17 \pm 5	NS
Frequency of fist open-clenches (per min)	8 \pm 3	9 \pm 4	NS
Amplitude (0–3 scale)	2.2 \pm 0.4	2.2 \pm 0.4	NS

of SPM96 (Friston *et al.*, 1995) after normalization for global effect by proportional scaling.

The pattern of cerebral activation associated with the motor task compared with rest was determined for the controls and the Parkinson's disease groups (within-group comparisons). Significant differences were accepted at a threshold of $P < 0.001$ (corrected for multiple comparisons). The local maxima, Talairach coordinates and peak Z -scores of areas of significant increase were identified.

In order to test for relative differences in the pattern of cerebral activation between controls and patients, we performed between-group comparisons. Activation differences were considered significant at $P < 0.01$ and if their spatial extent was > 10 pixels. The locations, coordinates and peak Z -scores of areas showing increased or decreased fMRI signals were identified in the controls compared with parkinsonian patients and in patients compared with controls.

The locations of activated areas in the controls and in the Parkinson's disease group (within and between-group comparisons) were displayed by superimposing them on axial sections of a Talairach–Tournoux normalized high-resolution three-dimensional T_1 -weighted MRI brain scan, provided by the SPM96 package.

The demographic and behavioural variables of the two groups of subjects were compared using an unpaired Student's *t*-test.

Results

The normal subjects and patients with Parkinson's disease executed the motor task with a similar frequency and amplitude (Table 2). None exhibited visible movements other than those of the hand executing the motor task for the activation paradigm.

Within-group comparisons (motor task versus rest condition)

Controls

Significant foci of activation were seen in the left primary sensorimotor cortex, the left lateral premotor cortex, in both the left and right inferior and posterior parietal cortex, in both the rostral and caudal parts of the SMA and in the anterior cingulate cortex. The location, coordinates and peak Z -scores of activated areas are detailed in Table 3 and are shown on MRI T_1 -weighted axial sections in Fig. 1.

Patients with Parkinson's disease

Significant foci of activation were seen in the left and right primary sensorimotor cortex with a relatively stronger left overactivity, in the left and right premotor cortex with a relatively stronger left overactivity, in the left and right inferior parietal cortex, in the caudal but not the rostral part of the SMA and in the cingulate cortex. The location, coordinates and peak Z -scores of activity are detailed in Table 3 and shown on MRI T_1 -weighted axial sections in Fig. 2.

Between-group comparisons

Relatively increased fMRI signals in controls

When the increases in activation in the controls were compared with those of patients, a significant relative increase in fMRI signal was seen in the rostral part of the SMA, in the right dorsolateral prefrontal cortex and in small areas of the left lateral premotor cortex and the left inferior parietal cortex. The location, coordinates and peak Z -scores of activity are detailed in Table 3 and shown on MRI T_1 -weighted axial sections in Fig. 3.

Relatively increased fMRI signals in patients with Parkinson's disease

When the increases in activation in the patients were compared with those of controls, a significant relative increase in fMRI signal was seen in the right and left primary sensorimotor cortex, in the right and left premotor cortex, in the right and left inferior parietal cortex, in the caudal part of SMA and in the cingulate cortex. The location, coordinates and peak Z -scores of activity are detailed in Table 4 and shown on MRI T_1 -weighted axial sections in Fig. 4.

Discussion

Our findings show relatively decreased fMRI signals in the anterior SMA and dorsolateral prefrontal cortex (DLPC) and relatively increased fMRI signals in the lateral premotor and parietal cortices of patients with Parkinson's disease performing sequential finger movements. These data are consistent with previously reported findings in SPECT and PET studies (Playford *et al.*, 1992; Rascol *et al.*, 1992; Samuel *et al.*, 1997a). Novel findings are that the lateral premotor and parietal cortices are not the only detectable overactive areas in the parkinsonian brain, since the caudal

Table 3 Within-group analyses: sites of activation in controls and patients during the motor task

Region	Controls				Parkinson's disease patients			
	x	y	z	Z-score	x	y	z	Z-score
Left SMC	-32	-18	+40	6.96	-36	-20	+40	8.46
	32	-30	+45	6.82				
	-32	-14	+50	6.84				
SMA caudal	-4	-12	+50	7.06	-4	-12	+50	7.79
SMA rostral	+4	+10	+55	4.90				
Cingulate	-2	+10	+40	5.19	-4	-2	+45	7.84
Left IPC	-42	-32	+30	5.78	-40	-30	+30	6.80
	-30	-50	+45	6.34				
Right IPC	+30	-46	+40	4.45	+38	-34	+35	6.01
Left lateral PMC	-32	-8	+45	4.75	-42	+4	+35	6.47
Right lateral PMC					+34	-12	+45	6.09

Talairach x, y, z coordinates and peak Z-scores are shown.

SMC = sensorimotor cortex; SMA = supplementary motor area; IPC = inferior parietal cortex; PMC = lateral premotor cortex

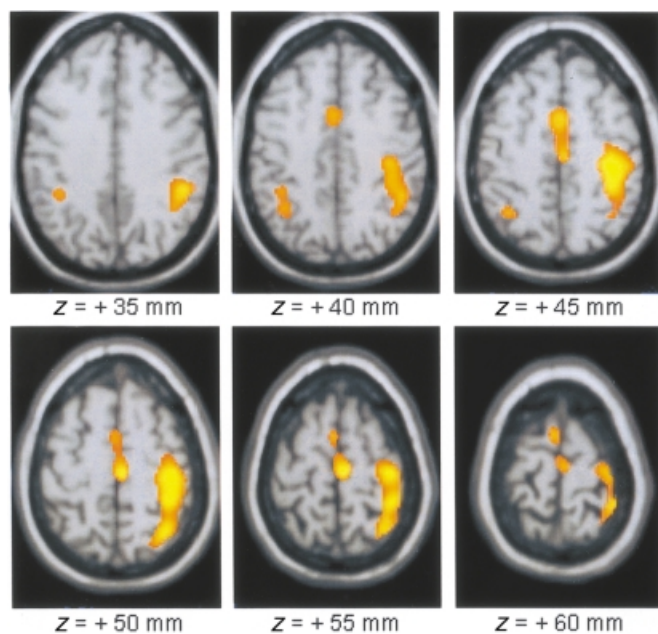


Fig. 1 Area of activation foci during a complex sequential right-hand movement in six normal subjects, superimposed onto a stereotaxically normalized MRI brain scan (z = location of area of activation above commissural plane; threshold = $P < 0.001$).

SMA, the anterior cingulate and the primary sensorimotor cortices also exhibited abnormal fMRI signals.

Relatively decreased fMRI signals in rostral SMA and dorsolateral prefrontal cortices of patients with Parkinson's disease.

It is now established according to SPECT and PET studies that the SMA is hypoactive when akinetic patients with Parkinson's disease are performing sequential movements (Playford *et al.*, 1992; Rascol *et al.*, 1992). This defective SMA activation is thought to reflect the decrease in the positive efferent feedback arising from the basal ganglia–

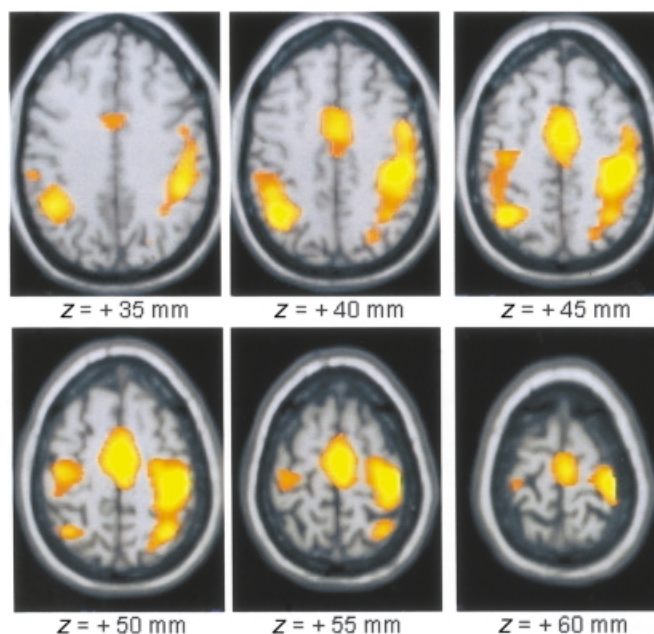


Fig. 2 Area of activation foci during a complex sequential right hand movement in six patients with Parkinson's disease off medication, superimposed onto a stereotaxically normalized MRI brain scan (z = location of area of activation above commissural plane; threshold = $P < 0.001$).

thalamocortical motor loop due to striatal dopamine depletion (DeLong, 1990).

The high resolution of fMRI has recently allowed refinement of our concepts on SMA functional organization, identifying a gradual functional heterogeneity between the rostral and caudal parts of the medial premotor cortex of normal human volunteers (Tyszaka *et al.*, 1994; Humberstone *et al.*, 1997; Van Oostende *et al.*, 1997; Boecker *et al.*, 1998). This heterogeneity is supposed to correspond in humans to the differentiation between SMA proper and pre-SMA recently described in primate studies (Matsuzaka *et al.*, 1992; Tanji, 1994; Rizzolatti *et al.*, 1998). These last studies suggest that

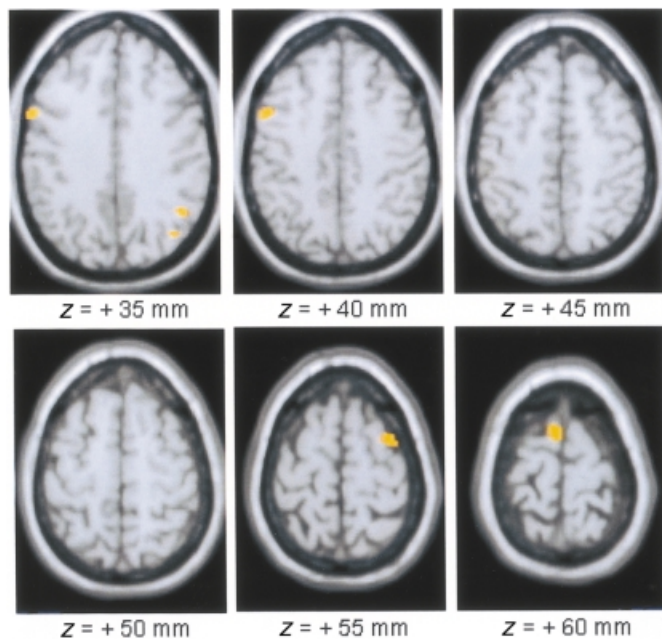


Fig. 3 Area of relative overactivity in normal controls compared with patients with Parkinson's disease during a complex sequential right hand movement (z = location of area of activation above commissural plane; threshold = $P < 0.01$).

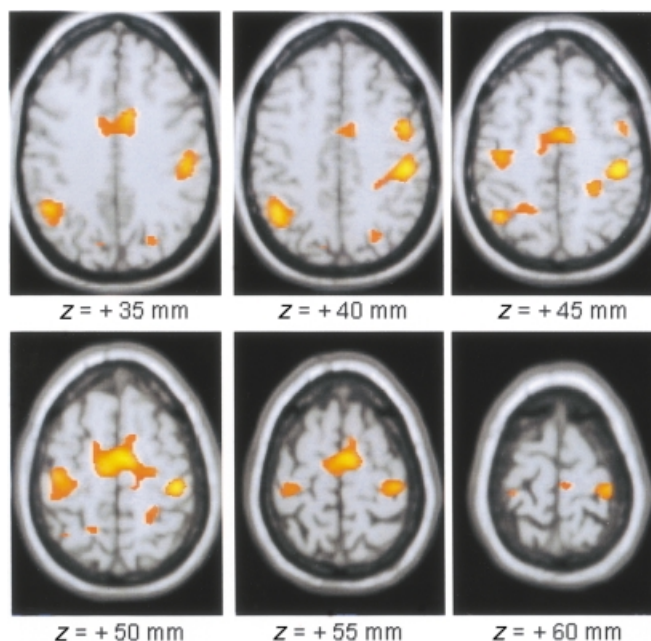


Fig. 4 Area of relative overactivity in patients with Parkinson's disease compared with normal controls during a complex sequential right hand movement, superimposed onto a stereotaxically normalized MRI brain scan (z = location of area of activation above commissural plane; threshold = $P < 0.001$).

Table 4 Between-group analyses: sites of relative overactivity in controls compared with patients and patients compared with controls during the motor task

Region	Controls				Parkinson's disease patients			
	x	y	z	Z-score	x	y	z	Z-score
Left SMC					30	-20	+40	5.31
					-30	-20	+55	3.55
Right SMC					+34	-12	+45	3.73
SMA caudal					-4	0	+50	4.29
SMA rostral	+4	+10	+55	3.54				
Anterior cingulate					+8	+12	+30	3.68
					-4	0	+45	4.79
					+6	-4	+45	4.03
Left IPC	-40	-46	+30	2.48	-27	-30	+40	3.20
Right IPC					+38	-46	+35	4.38
Left lateral PMC	-30	+8	+50	3.08	-40	+6	+35	4.01
Right lateral PMC					+36	-10	+40	3.04
Right DLPF	+44	+8	+35	2.78				

Talairach x , y , z coordinates and peak Z-scores are shown. DLPF = dorsolateral prefrontal; SMC = sensorimotor cortex; SMA = supplementary motor area; IPC = inferior parietal cortex; PMC = lateral premotor cortex.

the pre-SMA may have a greater role in premotor activities, whereas SMA proper appears to have a greater role in motor performance (Picard and Strick, 1996).

With fMRI, we observed two main peaks of activation within the SMA of the normal subjects: the first was located 10 mm in front of the vertical anterior commissure line, while the second was located 10 mm behind (Table 3). This finding is consistent with the fact that the complexity of the motor task involved both aspects of SMA motor function.

Unlike the normal volunteers, the patients with Parkinson's

disease did not exhibit a significant focus of activation in the rostral part of the SMA. Rather, they exhibited in this area a relatively decreased fMRI signal compared with the normal controls. Both normal controls and patients had been trained in advance in a similar way and executed the task with the same performance. Thus, the defective activation of the parkinsonian rostral SMA cannot be related to inadequate movement learning or execution. The PET coordinates of the SMA relative underactivity reported in patients with Parkinson's disease (Samuels *et al.*, 1997a) and those of the

SMA 'reactivation' induced by apomorphine (Jenkins *et al.*, 1992) or subthalamic nucleus stimulation (Limousin *et al.*, 1997) in such patients were also located in front of the vertical anterior commissure line. Taken together, these observations strongly suggest that it is indeed the rostral rather than the caudal part of the SMA which is not activated properly in Parkinson's disease.

We also observed in the akinetic patients with Parkinson's disease small relatively decreased fMRI signals in the right DLPF cortex and in a few other areas such as the left inferior parietal and lateral premotor cortex. Applying a more stringent threshold ($P < 0.005$) suppressed such signals, while this did not change the relatively decreased fMRI signal in the rostral SMA (data not shown). These small foci of relative underactivity could then be considered as artefacts. However, a relative DLPF hypoactivation has already been reported with PET when parkinsonian patients selected the timing (Jahanshahi *et al.*, 1995) or direction (Playford *et al.*, 1992) of movements. Pallidotomy (Samuel *et al.*, 1997b) and subthalamic stimulation (Limousin *et al.*, 1997) reversed such hypoactivation. The right rather than the left DLPF cortex is claimed to have a specialist role in motor planning, possibly because of the spatial component involved. It is known to be involved in selecting actions in normal subjects (Deiber *et al.*, 1991). The rostral, but not the caudal SMA is connected anatomically with the prefrontal cortex (Bates and Goldman-Rakic, 1993) and the DLPF cortex receives projections from the basal ganglia and related thalamic nuclei (Selemon and Goldman-Rakic, 1985). Taken together, these findings suggest that the DLPF cortex is not normally active in patients with Parkinson's disease. Such a defective signal could be due to the degeneration of mesofrontal dopaminergic afferents or to a functional deafferentation of the prefrontal cortex from its basal ganglia-thalamic inputs.

Relatively increased fMRI signals in cortical motor areas of patients with Parkinson's disease

Beside these circumscribed foci of relatively decreased cortical fMRI signals, a large number of areas with increased fMRI signals were also observed in patients with Parkinson's disease. These included the lateral premotor and parietal cortex, the primary motor cortex, the caudal SMA and the contiguous anterior cingulate cortex, covering motor areas activated by the normal subjects, but encompassing a more widespread and bilateral distribution.

Lateral premotor and parietal cortex

Bilateral increased fMRI signals in the lateral premotor and parietal cortices of patients with Parkinson's disease have already been observed using PET (Samuel *et al.*, 1997a). As already pointed out, the parietal cortex participates in the control of complex movements in extrapersonal space (Deiber *et al.*, 1991; Jenkins *et al.*, 1994) and sends dense projections

to the lateral premotor cortex (Petrides and Pandya, 1984), supporting the hypothesis that patients with Parkinson's disease might divert from using impaired striatomesial-frontal projections to intact lateral premotor-parietal cortex circuits.

A novel finding of the present study was that such relatively increased fMRI signals also involved the ipsi- and contralateral primary motor cortex, the caudal SMA and the anterior cingulate cortex.

Primary sensorimotor cortex

It is the absence of relative overactivity in the primary sensorimotor cortex of patients with Parkinson's disease that has been reported previously, using PET (Playford *et al.*, 1992). Conversely, like us, Humberstone and colleagues (Humberstone *et al.*, 1998), using fMRI, reported a bilateral increase in signal in the primary sensorimotor cortex of patients with Parkinson's disease. There are a number of anatomical (Kuypers, 1981; Armand *et al.*, 1982), electrophysiological (Glees and Cole, 1952; Tanji *et al.*, 1988) and neuroimaging (Wiesendanger, 1981; Weiller *et al.*, 1992; Kawashima *et al.*, 1993, 1994; Wassermann *et al.*, 1994; Chen *et al.*, 1997) studies which provide evidence for a role of the ipsilateral pathways in normal motor function. Several observations also support the participation of the ipsilateral cortex in post-lesional motor deficit (Colebatch and Gandevia, 1989; Jones *et al.*, 1989; Marque *et al.*, 1997) and in functional recovery after lesion (Benecke *et al.*, 1991; Chollet *et al.*, 1991; Fries *et al.*, 1991; Di Piero *et al.*, 1992; Fisher, 1992; Weiller *et al.*, 1993; Sabatini *et al.*, 1994). Shibasaki and colleagues observed with PET that normal subjects activated their primary motor cortex bilaterally when preparing for and/or executing a complex sequence of unilateral finger movements (Shibasaki *et al.*, 1993). Our motor task was more complex than those used in previous PET studies. This complexity could explain this bilateral signal. However, our normal subjects did not exhibit bilateral activation in the primary motor cortex, suggesting that the task's complexity cannot explain, alone, the bilateral signal observed in patients with Parkinson's disease. Associated movement of the opposite hand is a rather common phenomenon in patients with motor deficit (Krams *et al.*, 1994). Therefore, an ipsilateral primary motor cortex activation has sometimes been seen as merely representing an epiphenomenon due to the presence of unspecific associated movements of the opposite hand. Although we do not have EMG control to rule out definitely the occurrence of such unspecific associated movements, one of us carefully checked by direct visual control, throughout the periods of data acquisition, that no such movements were present in our patients. Interestingly, a relative increase in fMRI signal was also present in the contralateral primary sensorimotor cortex of the patients with Parkinson's disease. We carefully checked that the patients executed the motor task in a similar way to the normal controls and there is thus no reason to suspect that any associated unspecific movements occurred on this

side. Therefore, our data suggest that both the ipsi- and contralateral primary sensorimotor cortices are actually involved in a functional reorganization process comparable with that which occurred in the lateral premotor and parietal cortices.

Caudal SMA

Another novel finding of this study is that the caudal part of the SMA exhibited a relatively increased fMRI signal in the patients with Parkinson's disease. This observation reinforces the notion that there is a functional difference between the anterior and posterior parts of the SMA. This inverse activation pattern within the SMA has not been reported previously in PET or SPECT studies conducted in parkinsonian patients. This cannot be explained by the limits of the spatial resolution of the tomographs, considering the size and the amplitude of the fMRI signal that we found. Differences in motor tasks or patient selection are more likely. As pointed out, the present task was a more complex sequential movement than any other task previously used in patients with Parkinson's disease: joystick movements (Jenkins *et al.*, 1992; Playford *et al.*, 1992; Limousin *et al.*, 1997; Samuel *et al.*, 1997b), lifting the index finger (Jahanshahi *et al.*, 1995), finger-to-thumb oppositions (Rascoll *et al.*, 1992, 1994, 1997) or pressing keys sequentially (Samuel *et al.*, 1997a). The present task was probably more demanding, and patients with Parkinson's disease might have found it more difficult to perform automatically than normal healthy volunteers, with a consequent increased activation signal in some areas such as the posterior part of the SMA or the ipsilateral primary motor cortex. Another possibility is that our patients with Parkinson's disease may have suffered from a less advanced disease than those enrolled in other studies, and that mildly affected patients could still be capable of activating areas which cannot be recruited once the disease has progressed.

It is not surprising to observe that the caudal part of the SMA behaved like the lateral premotor and parietal motor areas. In the monkey, the SMA proper, unlike the pre-SMA, has reciprocal connections with the primary sensorimotor cortex and receives dense inputs from the parietal lobe (Luppino *et al.*, 1993). Single neuron recordings showed that many neurons of the caudal SMA respond to somatosensory and visual stimuli (Tanji and Shima, 1994; Rizzolatti *et al.*, 1996) and discharge in association with active movements (Tanji *et al.*, 1996), thus exhibiting behaviour similar in many aspects to that of the primary motor neurons. Therefore, unlike the rostral part of the SMA, its caudal part is considered by some authors as part of a specific parietofrontal circuit (Luppino *et al.*, 1993).

Anterior cingulate cortex

In this study, we also observed a large area of activation in the anterior cingulate cortex, corresponding to Brodmann

areas 24 and 32. The association of the anterior cingulate cortex with motor function is supported by anatomical (Dum and Strick, 1991; Luppino *et al.*, 1993; Morecraft and Van Hoesen, 1993; Tokuno and Tanji, 1993), electrophysiological (Luppino *et al.*, 1991; Shima *et al.*, 1991; Matsuzaka *et al.*, 1992; for a review, see Devinsky *et al.*, 1995) and clinical observations (Devinsky *et al.*, 1995).

In normal subjects, the main focus of cingulate activation was located 10 mm anterior to the vertical anterior commissural line (Table 3). This area is contiguous to and below the rostral part of the SMA. It corresponds to Brodmann area 24c'. The projections of this area target mainly the caudal portion of the SMA, with limited access to the primary motor cortex and the spinal cord (Luppino *et al.*, 1990; Dum and Strick, 1991). Several neuroimaging studies performed in normal volunteers have shown that the anterior cingulate cortex is implicated in response selection and willed acts, but not in practised responses, and that cingulate activation decreases with habituation (Colebatch *et al.*, 1991; Deiber *et al.*, 1992; Paus *et al.*, 1993; Tyszkka *et al.*, 1994; Van Oostende *et al.*, 1996). Conversely, the expression of specific motor sequences that require little automatic activity has been reported to be directed by anterior cingulate motor areas (see Devinsky *et al.*, 1995). The fact that this area was significantly activated when our normal subjects were performing the motor task suggests that the complexity of the movement was demanding enough to prevent it being performed automatically.

There were several foci of relatively increased fMRI signals in the anterior cingulate cortex of patients with Parkinson's disease. This result was unexpected. Dense reciprocal anatomical connections between the anterior cingulate cortex and the prefrontal cortex, especially the DLPF, have been described in the monkey (Bates and Goldman-Rakic, 1993; Morecraft and Van Hoesen, 1993). This suggests that this cortex, like the DLPF, may be instrumental in contributing to the formation of higher order voluntary motor responses. High levels of motor control are believed to be impaired in Parkinson's disease and, indeed, we observed relatively decreased fMRI signals in the DLPF cortex and rostral SMA of our patients. Therefore, we anticipated finding comparable results in the cingulate, as reported previously with PET (Jahanshahi *et al.*, 1995).

In fact, the anterior cingulate cortex, like the SMA, is functionally heterogeneous regarding cytoarchitecture (Vogt *et al.*, 1995), connections (Luppino *et al.*, 1990; Dum and Strick, 1991) and electrophysiological behaviour (Shima *et al.*, 1991). It is probable that the cingulate cortex, like the SMA, has motor and 'pre' motor divisions, probably in the rostrocaudal direction (Zilles *et al.*, 1995; Picard and Strick, 1996).

The main focus of the relatively increased fMRI signal observed in the anterior cingulate cortex of our patients was located more caudally than in the normal controls, behind and not in front of the vertical anterior commissural line (Table 4). This more caudal part of the anterior cingulate

cortex might be, like the caudal SMA, more closely related to executive aspects of the motor function than the rostral part, which may instead be involved in other aspects of higher order control, reinforcing the notion that similar gradual rostrocaudal functional differences might exist in both areas.

We observed in our parkinsonian patients another focus of increased cingulate fMRI signal, which was located more anteriorly, 10 mm in front of the vertical anterior commissural line, corresponding to the border between Brodmann areas 32 and 24 (Table 4). This signal is too anterior to fit with the simplistic hypothesis of a simple rostrocaudal premotor-motor division of the anterior cingulate cortex. It must be remembered that the anterior cingulate cortex is also involved in affective behaviours. It has been suggested that the dichotomy within the anterior cingulate cortex of affective and cognitive regions is best shown by a line drawn just caudal to the border of area 32, most evidence suggesting that besides this line, area 24' is more involved in cognitive processes that do not require affect (Devinsky *et al.*, 1995). One can thus speculate that the anterior focus of the increased cingulate fMRI signal that we observed at the border of area 32 might be explained by a greater emotional, attentional or motivational response in the patients with Parkinson's disease, due to greater difficulties in performing the motor task adequately because of their akinetic handicap.

Conclusions

The present fMRI neuroimaging study shows that the subcortical putaminal dopamine deficit which characterizes Parkinson's disease disorganizes the cortical motor pathways in a complex way. It induces a focal 'underactivation' restricted to the rostral SMA and DLPC, possibly responsible for the patients' akinesia. It also induces an abnormal pattern of 'overactivation' in most of the other known motor cortical areas, including the caudal SMA, the anterior cingulate cortex, the lateral premotor, the primary sensorimotor and the parietal cortices. This reorganization, which involves parallel-acting multiple motor areas, can be seen as an attempt at motor recovery. The general aspect of this reorganization resembles what has been described previously with PET in other motor diseases, such as paresis induced by acute stroke (Chollet *et al.*, 1991; Weiller, 1995; Chollet and Weiller, 1997). It is also interesting to compare the present results with those reported in patients with cerebellar degeneration (Wessel *et al.*, 1995). The pattern of motor activation in this last condition appeared to be the opposite to what we observed in Parkinson's disease: several areas of the lateral motor circuit, including the lateral premotor cortex and the lobus parietalis inferior, were less activated in the cerebellar patients than in the normal controls, probably as a result of defective cerebellar inputs, while, in contrast, other premotor systems, including the SMA, were used more heavily in the cerebellar patients than in the controls. It is thus tempting to speculate that these phenomena illustrate the capacity of the adult

human brain for functional plasticity in compensating for one motor circuit deficit by recruiting another parallel one. The exact mechanisms of these phenomena remain to be understood.

Acknowledgements

We wish to thank Mrs E. Guillaud for careful manuscript preparation, the Toulouse Clinical Investigation Centre for its invaluable help in conducting this protocol and the Italian Neuroradiological Association who supported this work with the Research Grant 'Maurizio Bracchi'.

References

- Armand J. The origin, course and terminations of corticospinal fibers in various mammals. *Prog Brain Res* 1982; 57: 329–60.
- Bates JF, Goldman-Rakic PS. Prefrontal connections of medial motor areas in the rhesus monkey. *J Comp Neurol* 1993; 336: 211–28.
- Benecke R, Meyer BU, Freund HJ. Reorganisation of descending motor pathways in patients after hemispherectomy and severe hemispheric lesions demonstrated by magnetic brain stimulation. *Exp Brain Res* 1991; 83: 419–26.
- Boecker H, Dagher A, Ceballos-Baumann AO, Passingham RE, Samuel M, Friston KJ, et al. Role of the human rostral supplementary motor area and the basal ganglia in motor sequence control: investigations with H2 15O PET. *J Neurophysiol* 1998; 79: 1070–80.
- Chen R, Gerloff C, Hallett M, Cohen LG. Involvement of the ipsilateral motor cortex in finger movements of different complexities. *Ann Neurol* 1997; 41: 247–54.
- Chollet F, Weiller C. Imaging recovery of function following brain injury. [Review]. *Curr Opin Neurobiol* 1994; 4: 226–30.
- Chollet F, Di Piero V, Wise RJ, Brooks DJ, Dolan RJ, Frackowiak RS. The functional anatomy of motor recovery after stroke in humans: a study with positron emission tomography. *Ann Neurol* 1991; 29: 63–71.
- Colebatch JG, Gandevia SC. The distribution of muscular weakness in upper motor neuron lesions affecting the arm. *Brain* 1989; 112: 749–63.
- Colebatch JG, Deiber M-P, Passingham RE, Friston KJ, Frackowiak RS. Regional cerebral blood flow during voluntary arm and hand movements in human subjects. *J Neurophysiol* 1991; 65: 1392–401.
- Deiber M-P, Passingham RE, Colebatch JG, Friston KJ, Nixon PD, Frackowiak RS. Cortical areas and the selection of movement: a study with positron emission tomography. *Exp Brain Res* 1991; 84: 393–402.
- De Long MR. Primate models of movement disorders of basal ganglia origin. *Trends Neurosci* 1990; 13: 281–5.
- Devinsky O, Morrell MJ, Vogt BA. Contributions of anterior cingulate cortex to behaviour. [Review]. *Brain* 1995; 118: 279–306.
- Di Piero V, Chollet F, MacCarthy P, Lenzi GL, Frackowiak RS. Motor recovery after acute ischaemic stroke: a metabolic study. *J Neurol Neurosurg Psychiatry* 1992; 55: 990–6.

- Dum RP, Strick PL. The origin of corticospinal projections from the premotor areas in the frontal lobe. *J Neurosci* 1991; 11: 667–89.
- Fahn S, Elton R and the members of the Unified Parkinson's Disease Rating Scale Development Committee. Unified Parkinson's Disease Rating Scale. In: Fahn S, Marsden CD, Calne D, editors. Recent developments in Parkinson's disease. New York: MacMillan; 1987. p. 153–63.
- Fisher CM. Concerning the mechanism of recovery in stroke hemiplegia. *Can J Neurol Sci* 1992; 19: 57–63.
- Fries W, Danek A, Witt TN. Motor responses after transcranial electrical stimulation of cerebral hemispheres with a degenerated pyramidal tract. *Ann Neurol* 1991; 29: 646–50.
- Friston KJ, Holmes AP, Worsley KJ, Poline JP, Frith CD, Frackowiak RS. Statistical parametric maps in functional imaging: a general linear approach. *Hum Brain Mapp* 1995; 2: 189–210.
- Gibbs WR, Lees AJ. The relevance of the Lewy body to the pathogenesis of idiopathic Parkinson's disease. [Review]. *J Neurol Neurosurg Psychiatry* 1988; 51: 745–52.
- Glees P, Cole J. Ipsilateral representation in the cerebral cortex: its significance in relation to motor function. *Lancet* 1952; 1: 1191–2.
- Hoehn MM, Yahr MD. Parkinsonism: onset, progression and mortality. *Neurology* 1967; 17: 427–42.
- Humberstone M, Sawle GV, Clare S, Hykin J, Coxon R, Bowtell R, et al. Functional magnetic resonance imaging of single motor events reveals human presupplementary motor area. *Ann Neurol* 1997; 42: 632–7.
- Humberstone M, Clare S, Morris PG, Sawle GV. Functional MRI demonstrates cortical mechanisms underlying rigidity and bradykinesia in Parkinson's disease [abstract]. *Mov Disord* 1998; 13 Suppl 2: 107.
- Jahanshahi M, Jenkins IH, Brown RG, Marsden CD, Passingham RE, Brooks DJ. Self-initiated versus externally triggered movements. I. An investigation using measurement of regional cerebral blood flow with PET and movement-related potentials in normal and Parkinson's disease subjects. *Brain* 1995; 118: 913–33.
- Jenkins IH, Fernandez W, Playford ED, Lees AJ, Frackowiak RS, Passingham RE, et al. Impaired activation of the supplementary motor area in Parkinson's disease is reversed when akinesia is treated with apomorphine. *Ann Neurol* 1992; 32: 749–57.
- Jenkins IH, Brooks DJ, Nixon PD, Frackowiak RS, Passingham RE. Motor sequence learning: a study with positron emission tomography. *J Neurosci* 1994; 14: 3775–90.
- Jones RD, Donaldson IM, Parkin JP. Impairment and recovery of ipsilateral sensory-motor function following unilateral cerebral infarction. *Brain* 1989; 112: 113–32.
- Kawashima R, Yamada K, Kinomura S, Yamaguchi T, Matsui H, Yoshioka S, et al. Regional cerebral blood flow changes of cortical motor areas and prefrontal areas in humans related to ipsilateral and contralateral hand movement. *Brain Res* 1993; 623: 33–40.
- Kawashima R, Roland PE, O'Sullivan BT. Activity in the human primary motor cortex related to ipsilateral hand movements. *Brain Res* 1994; 663: 251–6.
- Krams M, Moering B, Rijntjes M, Faiss J, Diener HC, Weiller C. Associated movements in stroke patients and normal controls [abstract]. *Cerebrovasc Dis* 1994; 4: 233.
- Kuypers HG. Anatomy of the descending pathways. In: Brookhart JM, Mountcastle VB, editors. *Handbook of physiology*, Sect. 1, Vol. 2, Pt. 1. Bethesda (MD): American Physiological Society 1981. p. 597–666.
- Limousin P, Greene J, Pollak P, Rothwell J, Benabid AL, Frackowiak R. Changes in cerebral activity pattern due to subthalamic nucleus or internal pallidum stimulation in Parkinson's disease. *Ann Neurol* 1997; 42: 283–91.
- Luppino G, Matelli M, Rizzolatti G. Cortico-cortical connections of two electrophysiologically identified arm representations in the mesial agranular frontal cortex. *Exp Brain Res* 1990; 82: 214–8.
- Luppino G, Matelli M, Camarda RM, Gallese V, Rizzolatti G. Multiple representations of body movements in mesial area 6 and the adjacent cingulate cortex: an intracortical microstimulation study in the macaque monkey. *J Comp Neurol* 1991; 311: 463–82.
- Luppino G, Matelli M, Camarda R, Rizzolatti G. Corticocortical connections of area F3 (SMA-proper) and area F6 (pre-SMA) in the macaque monkey. *J Comp Neurol* 1993; 338: 114–40.
- Marque P, Felez A, Puel M, Demonet JF, Guiraud-Chaumeil B, Roques CF, et al. Impairment and recovery of left motor function in patients with right hemiplegia. *J Neurol Neurosurg Psychiatry* 1997; 62: 77–81.
- Matsuzaka Y, Aizawa H, Tanji J. A motor area rostral to the supplementary motor area (presupplementary motor area) in the monkey: neuronal activity during a learned motor task. *J Neurophysiol* 1992; 68: 653–62.
- Morecraft RJ, Van Hoesen GW. Frontal granular cortex input to the cingulate (M3), supplementary (M2) and primary (M1) motor cortices in the rhesus monkey. *J Comp Neurol* 1993; 337: 669–89.
- Paus T, Petrides M, Evans AC, Meyer E. Role of the human anterior cingulate cortex in the control of oculomotor, manual, and speech responses: a positron emission tomography study. *J Neurophysiol* 1993; 70: 453–69.
- Petrides M, Pandya DN. Projections to the frontal cortex from the posterior parietal region in the rhesus monkey. *J Comp Neurol* 1984; 228: 105–16.
- Picard N, Strick PL. Motor areas of the medial wall: a review of their location and functional activation. [Review]. *Cereb Cortex* 1996; 6: 342–53.
- Playford ED, Jenkins IH, Passingham RE, Nutt J, Frackowiak RS, Brooks DJ. Impaired mesial frontal and putamen activation in Parkinson's disease: a positron emission tomography study. *Ann Neurol* 1992; 32: 151–61.
- Rascol O, Sabatini U, Chollet F, Celsis P, Montastruc JL, Marc-Vergnes JP, et al. Supplementary and primary sensory motor area activity in Parkinson's disease. Regional cerebral blood flow changes during finger movements and effects of apomorphine. *Arch Neurol* 1992; 49: 144–8.
- Rascol O, Sabatini U, Chollet F, Fabre N, Senard JM, Montastruc JL, et al. Normal activation of the supplementary motor area in patients with Parkinson's disease undergoing long-term treatment with levodopa. *J Neurol Neurosurg Psychiatry* 1994; 57: 567–71.

- Rascol O, Sabatini U, Fabre N, Brefel-Courbon C, Loubinoux I, Celsis P, et al. The ipsilateral cerebellar hemisphere is overactive during hand movements in akinetic parkinsonian patients. *Brain* 1997; 120: 103–10.
- Rizzolatti G, Luppino G, Matelli M. The classic supplementary motor area is formed by two independent areas. [Review]. *Adv Neurol* 1996; 70: 45–56.
- Rizzolatti G, Luppino G, Matelli M. The organization of the cortical motor system. [Review]. *Electroencephalogr Clin Neurophysiol* 1998; 106: 283–96.
- Sabatini U, Toni D, Pantano P, Brughitta G, Padovani A, Bozzao L, et al. Motor recovery after early brain damage. A case of brain plasticity. *Stroke* 1994; 25: 514–7.
- Samuel M, Ceballos-Baumann AO, Blin J, Uema T, Boecker H, Passingham RE, et al. Evidence for lateral premotor and parietal overactivity in Parkinson's disease during sequential and bimanual movements. A PET study. *Brain* 1997a; 120: 963–76.
- Samuel M, Ceballos-Baumann AO, Turjanski N, Boecker H, Gorospe A, Linazasoro G, et al. Pallidotomy in Parkinson's disease increases supplementary motor area and prefrontal activation during performance of volitional movements. An H2(15)O PET study. *Brain* 1997b; 120: 1301–13.
- Selemon LD, Goldman-Rakic PS. Longitudinal topography and interdigitation of corticostriatal projections in the rhesus monkey. *J Neurosci* 1985; 5: 776–94.
- Shibasaki H, Sadato N, Lyshkow H, Yonekura Y, Honda M, Nagamine T, et al. Both primary motor cortex and supplementary motor area play an important role in complex finger movement. *Brain* 1993; 116: 1387–98.
- Shima K, Aya K, Mushiaki H, Inase M, Aizawa H, Tanji J. Two movement-related foci in the primate cingulate cortex observed in signal-triggered and self-paced forelimb movements. *J Neurophysiol* 1991; 65: 188–201.
- Talairach J, Tournoux P. Co-planar stereotaxic atlas of the human brain. Stuttgart: Thieme; 1988.
- Tanji J. The supplementary motor area in the cerebral cortex. [Review]. *Neurosci Res* 1994; 19: 251–68.
- Tanji J, Shima K. Role for supplementary motor area cells in planning several movements ahead. *Nature* 1994; 371: 413–6.
- Tanji J, Okano K, Sato KC. Neuronal activity in cortical motor areas related to ipsilateral, contralateral and bilateral digit movements of the monkeys. *J Neurophysiol* 1988; 60: 325–43.
- Tanji J, Shima K, Mushiaki H. Multiple cortical motor areas and temporal sequencing of movements. [Review]. *Brain Res Cogn Brain Res* 1996; 5: 117–22.
- Tokuno H, Tanji J. Input organization of distal and proximal forelimb areas in the monkey primary motor cortex: a retrograde double labeling study. *J Comp Neurol* 1993; 333: 199–209.
- Tyszka JM, Grafton ST, Chew W, Woods RP, Colletti PM. Parceling of mesial frontal motor areas during ideation and movement using functional magnetic resonance imaging at 1.5 tesla. *Ann Neurol* 1994; 35: 746–9.
- Van Oostende S, Van Hecke P, Sunaert S, Nuttin B, Marchal G. FMRI studies of the supplementary motor area and the premotor cortex. *Neuroimage* 1997; 6: 181–90.
- Vogt BA, Nimchinsky EA, Vogt LJ, Hof PR. Human cingulate cortex: surface features, flat maps, and cytoarchitecture. *J Comp Neurol* 1995; 359: 490–506.
- Wassermann EM, Pascual-Leone A, Hallett M. Cortical motor representation of the ipsilateral hand and arm. *Exp Brain Res* 1994; 100: 121–32.
- Weiller C. Recovery from motor stroke: human positron emission tomography studies. *Cerebrovasc Dis* 1995; 5: 282–91.
- Weiller C, Chollet F, Friston KJ, Wise RJ, Frackowiak RS. Functional reorganization of the brain in recovery from striatocapsular infarction in man. *Ann Neurol* 1992; 31: 463–72.
- Weiller C, Ramsay SC, Wise RJ, Friston KJ, Frackowiak RS. Individual patterns of functional reorganization in the human cerebral cortex after capsular infarction. *Ann Neurol* 1993; 33: 181–89.
- Wessel K, Zeffiro T, Lou JS, Toro C, Hallett M. Regional cerebral blood flow during a self-paced sequential finger opposition task in patients with cerebellar degeneration. *Brain* 1995; 118: 379–93.
- Wiesendanger M. The pyramidal tract. Its structure and function. In: Tow AL, Luschei ES, editors. *Handbook of behavioural neurobiology*, Vol. 5. Motor coordination. New York: Plenum Press; 1981. p. 401–91.
- Zilles K, Schlaug G, Matelli M, Luppino G, Schleicher A, Qu M, et al. Mapping of human and macaque sensorimotor areas by integrating architectonic, transmitter receptor, MRI and PET data. *J Anat* 1995; 187: 515–37.

Received June 21, 1999. Accepted September 9, 1999