*Brain* (2000), **123,** 1850–1862

# Striatocapsular haemorrhage

Chin-Sang Chung,[1] Louis R. Caplan,[4] Yasumasa Yamamoto,[5] Hui Meng Chang,[6] Soo-Joo Lee,[1] Hee-Jung Song,[1] Hye-Seung Lee,[1] Hyun-Kil Shin[2] and Kyung-Moo Yoo[3]

*Departments of Neurology in [1]Samsung Medical Center, Sungkyunkwan University School of Medicine, Seoul, [2]Soonchunhyang University Hospital, Chunan and [3]Koshin University Hospital, Pusan, Korea, [4]Beth-Israel-Deaconess Hospital, Harvard Medical School, Boston, USA, [5]Kyoto Second Red Cross Hospital, Kyoto, Japan and [6]Singapore General Hospital, Singapore*

*Correspondence to: Chin-Sang Chung, MD, Department of Neurology, Samsung Medical Center, Sungkyunkwan University School of Medicine, 50 ILWON-dong, Kangnam-ku, Seoul, Korea 135-710*
*E-mail: cschung@smc.samsung.co.kr*

## Summary

**Haemorrhages in the striatocapsular area, or striatocapsular haemorrhages (SCHs), have been regarded as a single entity, although the area is composed of several functionally discrete structures that receive blood supply from different arteries. We analysed the morphological and clinical presentations of 215 cases of SCHs according to a new classification method we have designed on the basis of arterial territories. SCHs were divided into six types: (i) anterior type (Heubner's artery); (ii) middle type (medial lenticulostriate artery); (iii) posteromedial type (anterior choroidal artery); (iv) posterolateral type (posteromedial branches of lateral lenticulostriate artery); (v) lateral type (most lateral branches of lateral lenticulostriate artery); and (vi) massive type. The anterior type (11%) formed small caudate haematomas, always ruptured into the lateral ventricle, causing severe headache, and mild contralateral hemiparesis developed occasionally. The outcome was excellent. The middle type (7%) involved the globus pallidus and medial putamen, frequently causing contralateral hemiparesis and transient conjugate eye deviation to the lesion side. About 50% of the patients recovered to normal. The posteromedial type (4%) formed very small haematomas in the posterior limb of the internal capsule and presented with mild dysarthria, contralateral hemiparesis and sensory deficit, with excellent outcome in general. The posterolateral type (33%) affected the posterior half of the putamen and posterior limb of the internal capsule and presented with impaired consciousness and contralateral hemiparesis with either language dysfunction or contralateral neglect. The outcome was fair to poor but there were no deaths. The lateral type (21%) formed large elliptical haematomas between the putamen and insular cortex. Contralateral hemiparesis with language dysfunction or contralateral neglect developed frequently but resolved over several weeks. The clinical outcome was relatively excellent except when the haematoma size was very large. The massive type (24%) formed huge haematomas affecting the entire striatocapsular area. Marked sensorimotor deficits and impaired consciousness, ocular movement dysfunctions including the 'wrong-way' eyes were observed quite frequently. The outcome was very poor with a case fatality rate of 81%. The clinico-radiological presentations suggested its origin was the same as the posterolateral type.**

**Keywords**: striatocapsular haemorrhage; classification; vascular territories; clinical courses

**Abbreviations**: ICH = intracerebral haemorrhage; MCA = middle cerebral artery; MRS = Modified Rankin Scale; SCH = striatocapsular haemorrhage

## Introduction

The striatocapsular area is the most frequently affected site of spontaneous intracerebral haemorrhage (ICH) caused by hypertension. This area is supplied by a variety of arteries including the recurrent artery of Heubner and the medial lenticulostriate artery from the anterior cerebral artery, the anterior choroidal artery from the internal carotid artery, and the lateral lenticulostriate arteries from the middle cerebral artery (MCA) (Bogousslavsky *et al.*, 1988; Barth *et al.*, 1995). Thus, the haematomas developing in these areas should vary in size, location, direction and extent of haematoma spread, clinical presentations, and prognoses according to the arteries that have bled. However, they have long been regarded as a single entity and collectively called basal ganglionic or putaminal haemorrhage. Until recently

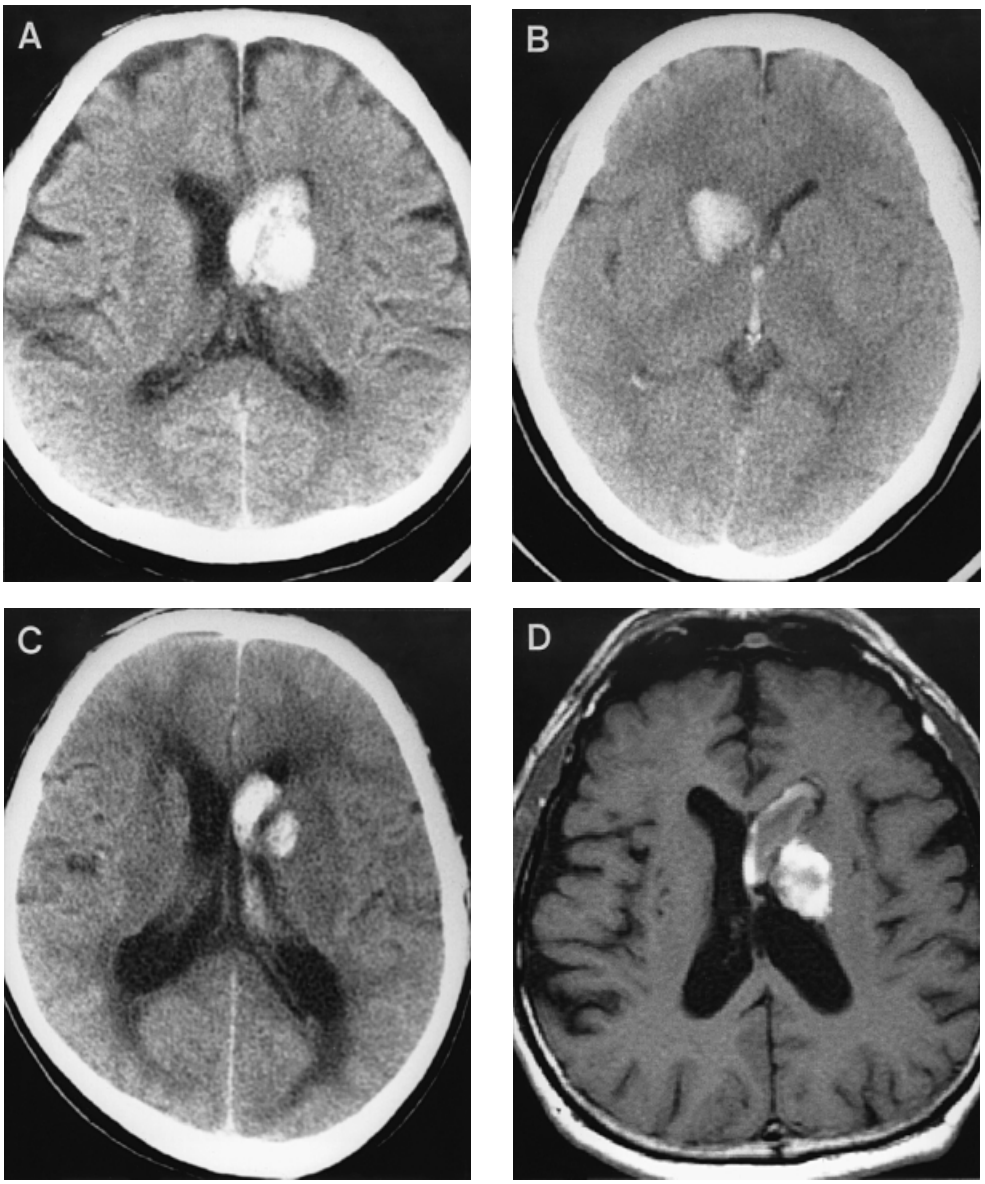


**Fig. 1** CT (**A–C**) and $T_1$-weighted MR (**D**) images showing the anterior type of SCHs. Haematomas may be located in the head (**A** and **B**) or in the body of the caudate nucleus (**C** and **D**). They usually rupture into the lateral ventricle. Each picture is from a different patient.

very few studies have divided haematomas in the striatocapsular regions, or striatocapsular haemorrhages (SCHs), and most included a small number of cases. There has been no uniform classification system to allow a simple way to predict clinical outcomes and guide therapeutic options. This idea has been tested successfully in primary pontine (Chung and Park, 1992) and thalamic (Chung *et al.*, 1996) haemorrhages.

In this study we propose a new classification method of SCHs based on anatomical location and arterial territories. For this purpose we analysed retrospectively the clinical and radiologic data from three general hospitals from Korea, the US and Japan. We investigated the impact of haematoma location and vascular territory on the clinical symptoms and signs, neuroimaging findings, and clinical outcomes of SCHs.

## Patients and methods

### *Patients, demographic characteristics and clinical analyses*

We collected the clinical and neuroimaging data of 215 consecutive patients who had had a spontaneous haemorrhage in the striatocapsular areas seen at three general hospitals in Korea (Samsung Medical Center, Seoul, 136 cases), the US (New England Medical Center, Boston, Mass., 39 cases), and

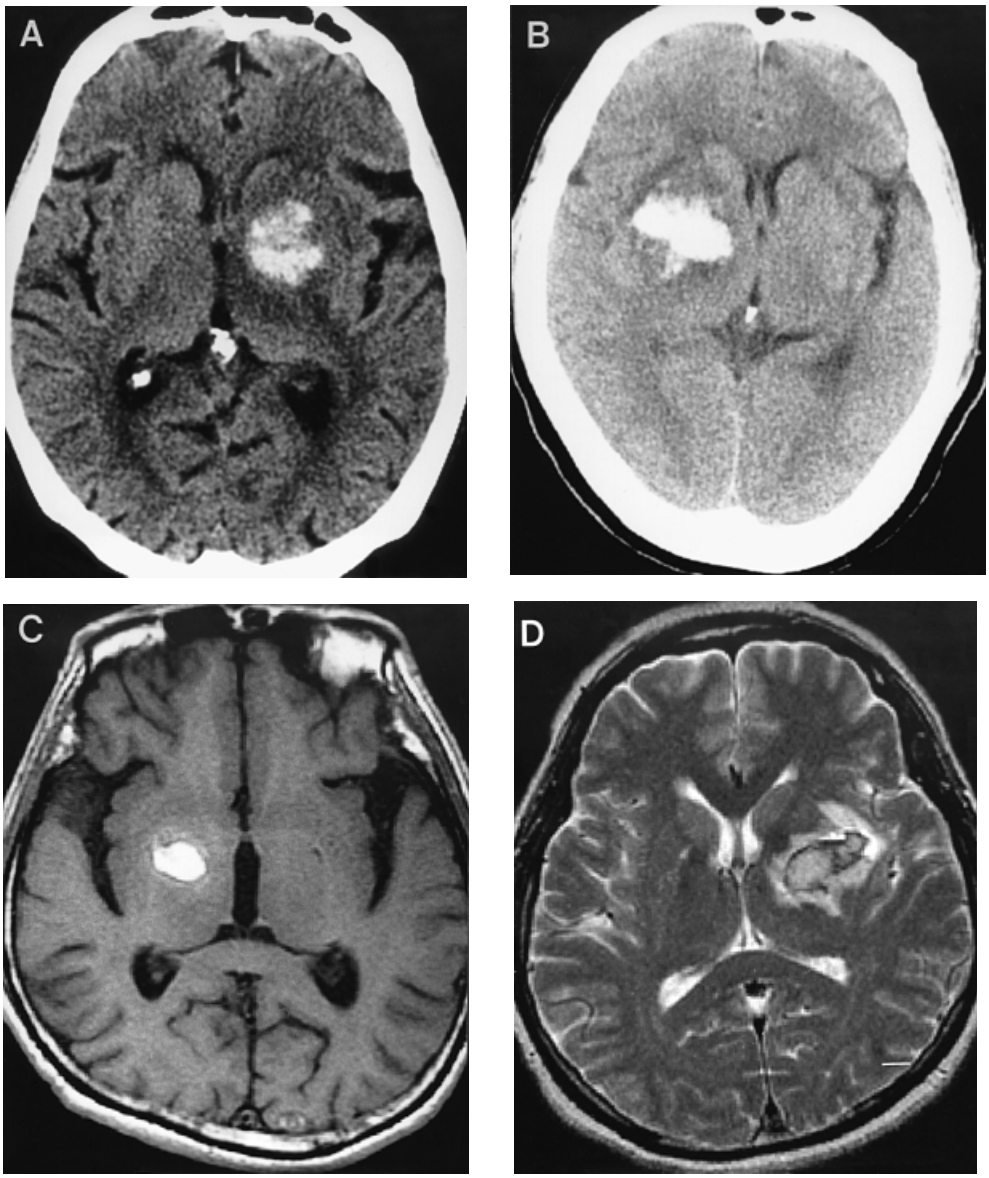


**Fig. 2** CT (**A** and **B**), $T_1$-weighted (**C**) and $T_2$-weighted MR (**D**) images showing the middle type of SCH. Haematomas develop in the middle and medial portion of the lentiform nucleus (mostly globus pallidus and medial portion of the putamen), often extending in the lateral direction. They do not rupture into the ventricles. Each picture is from a different patient.

Japan (Second Red Cross Hospital, Kyoto, 40 cases). The patients were selected from the CT logbooks of each medical centre between 1995 and 1998, and all the CT pictures were collected and reviewed at one centre: Samsung Medical Center, Seoul, Korea. The subjects included 136 Koreans, 40 Japanese, 23 Caucasians and 16 Chinese. Of these, 133 (61.9%) were men and they ranged from 27 to 90 years of age, with a mean of 57.4 ($\pm$10.45) years. Hypertension was the most significant stroke risk factor for haemorrhage (196 patients, 91.2%), followed by chronic alcoholism (9, 4.2%), moyamoya disease (2, 0.9%) and cocaine use (1, 0.5%). Seven patients (3.3%) had no identifiable risk factor.

The clinical data were obtained from medical records and included the initial level of consciousness, cognitive and behavioural abnormalities, neuro-ophthalmological signs, and sensory and motor signs. Cognitive and behavioural dysfunctions like confusion or disorientation, memory disturbances, neglect and language abnormalities were included. Neuro-ophthalmologic signs such as primary eye position (adversion and 'wrong-way' deviation), ocular movement abnormalities and Horner's syndrome were recorded. Short-term clinical outcome was assessed at the time of discharge from the neurology or neurosurgery department (mean duration of stay = 10.3 $\pm$ 4.82 days). We converted the clinical outcome to the Modified Rankin Scale (MRS), which is relatively simple to apply in retrospective outcome

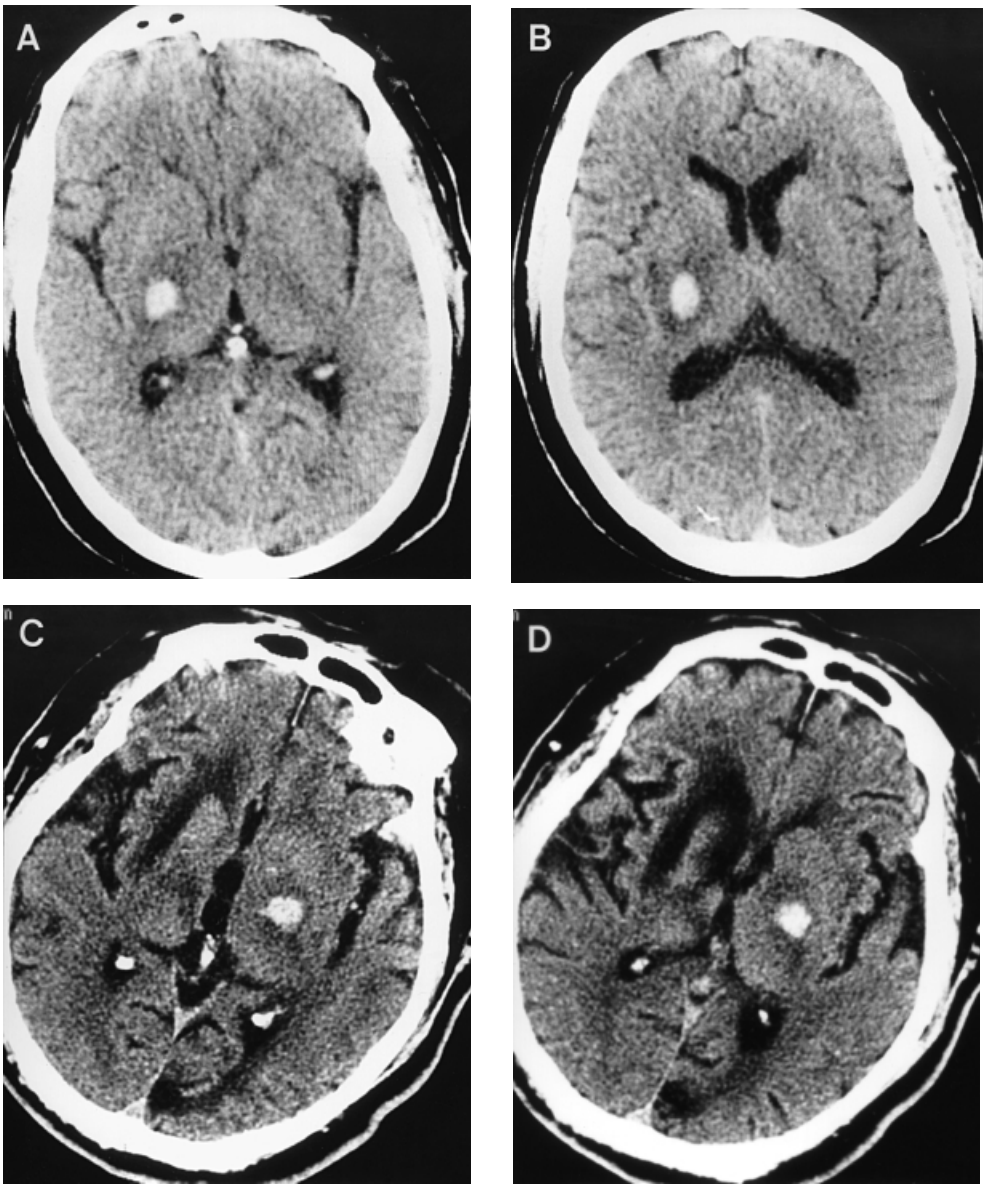


**Fig. 3** CT pictures showing the posteromedial type of SCH. This type forms very small haematomas that are limited to the posterior limb of the internal capsule ('capsular haemorrhage'). They usually extend rostrally along the capsular fibres without rupture into the ventricles. They exert pressure on the medial part of the putamen or the lateral thalamus. The panels represent two patients (**A** and **B** one, and **C** and **D** another) showing the patterns of vertical spread of haematomas.

assessment of stroke patients (van Swieten *et al*., 1988). The outcome was graded as excellent, fair or poor. The 'excellent' outcome was defined as an MRS of 0 (no symptom at all), 1 (no significant disability despite symptoms: able to carry out all usual duties and activities) or 2 (slight disability: unable to carry out all previous activities but able to look after own affairs without assistance). The 'fair' outcome was defined as an MRS of 3 (moderate disability: requiring some help, but able to walk without assistance) or 4 (moderately severe disability: unable to walk without assistance, and unable to attend to own bodily needs without assistance). The outcome was defined as 'poor' when the MRS was 5 (severe disability: bedridden, incontinent and requiring constant nursing care and attention) or 6 (death).

## *Classification of SCHs and neuroimaging analyses*

The striatocapsular area was defined as an area including the caudate nucleus, putamen, globus pallidus, anterior and posterior limbs of the internal capsule, and subinsular area, which are supplied by the anterior choroidal, Heubner's, and medial and lateral lenticulostriate arteries (Ghika *et al*., 1990).

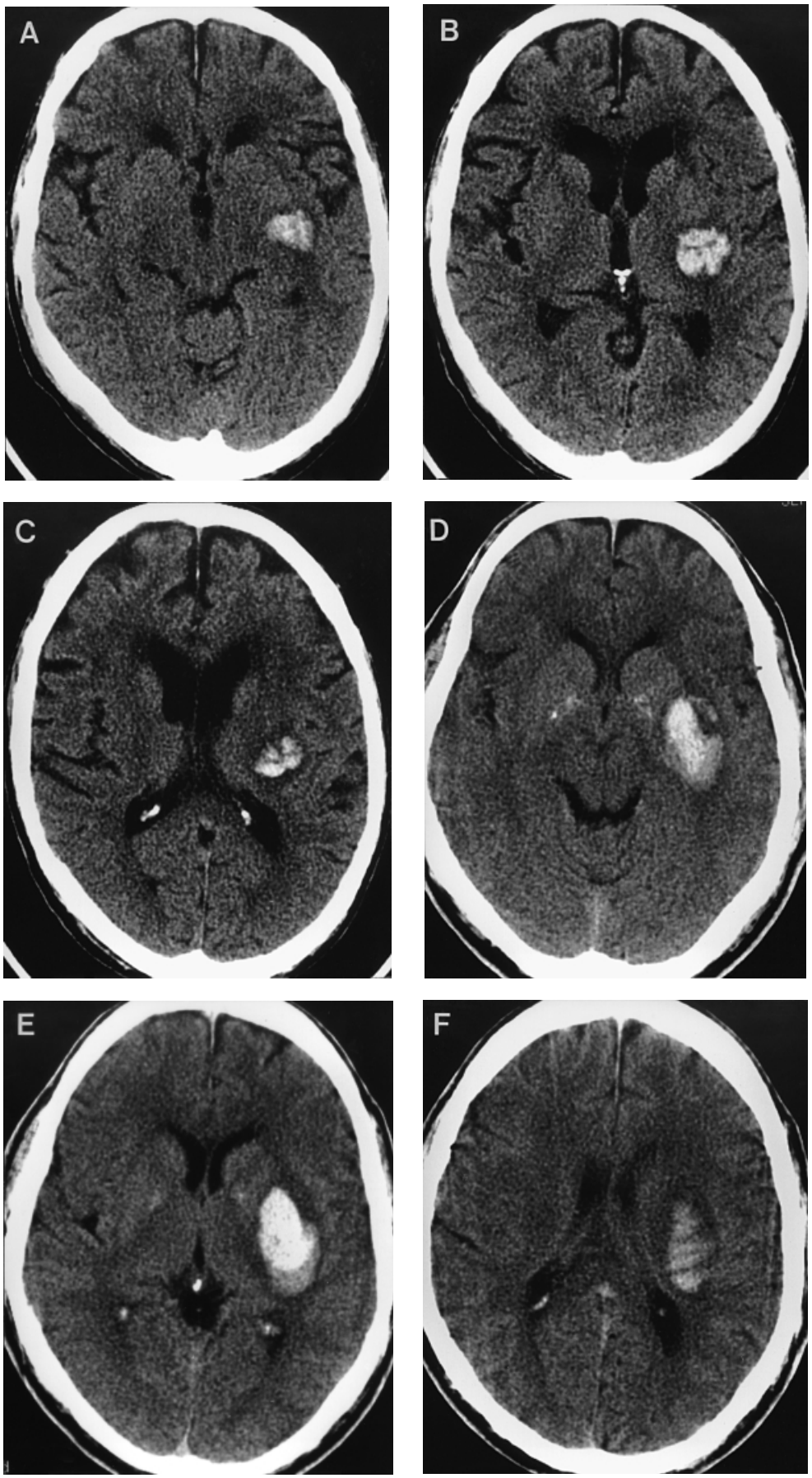
A
B
C
D
E
F

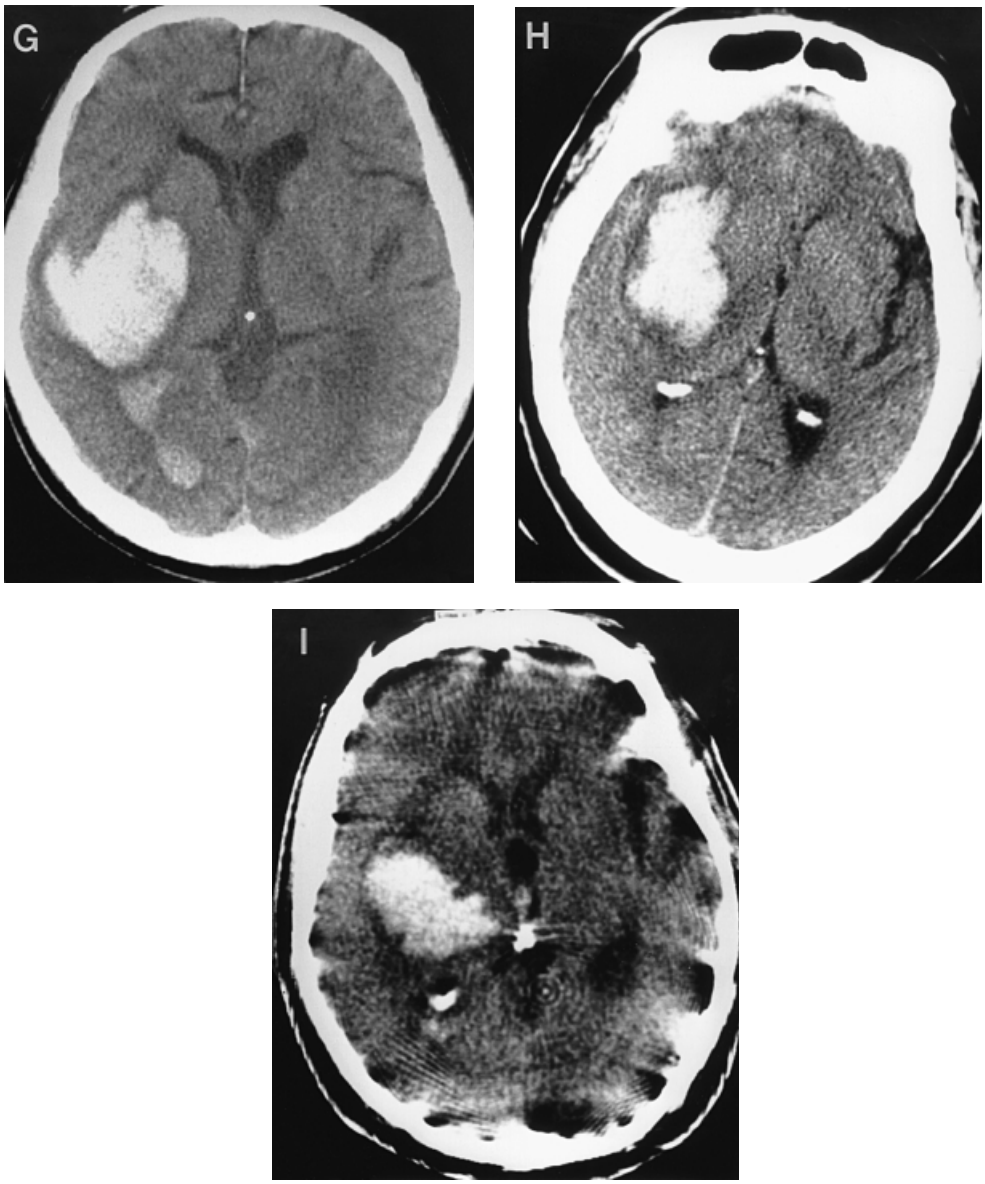


**Fig. 4** CT pictures showing the posterolateral type of SCHs. Haematomas develop in the posterior part of the putamen, often compressing or invading the posterior half of the posterior limb of the internal capsule (**A–F**). They occasionally extend laterally into the temporal lobe (**G–I**) or posteriorly rupture into the posterior horn of the lateral ventricle (**G**). Panels **A–C** are from one patient, and **D–F** from another, and panels **G–I** are from three different patients.

Thus, an SCH was defined as a haematoma primarily located in these areas. Huge ganglio-thalamic haematomas were not included due to vagueness of bleeding sources.

All SCHs were classified independently by two of the authors blinded to the clinical information (C.-S.C. and S.J.L.) according to the vascular territory of tentative primary bleeding focus of each SCH. The focus was defined as the centre of the largest circle that best fit the contour of the haematoma on the CT scans or MRIs. Thus SCHs were divided into six types (five regional and one massive) according to the major vascular territories: (i) the anterior type in the Heubner's artery territory (including the caudate nucleus) (Fig. 1); (ii) the middle type in the medial lenticulostriate artery territory (Fig. 2); (iii) the posteromedial type in the anterior choroidal artery territory (Fig. 3); (iv) the posterolateral type in the posteromedial branches of the lateral lenticulostriate artery territory (Fig. 4); and (v) the lateral type in the subinsular region supplied by the most lateral branches of the lateral lenticulostriate artery (Fig. 5); and the haematomas that occupied the entire striatocapsular area were defined as (vi), the massive type (Fig. 6).

On the basis of our provisional classification, we

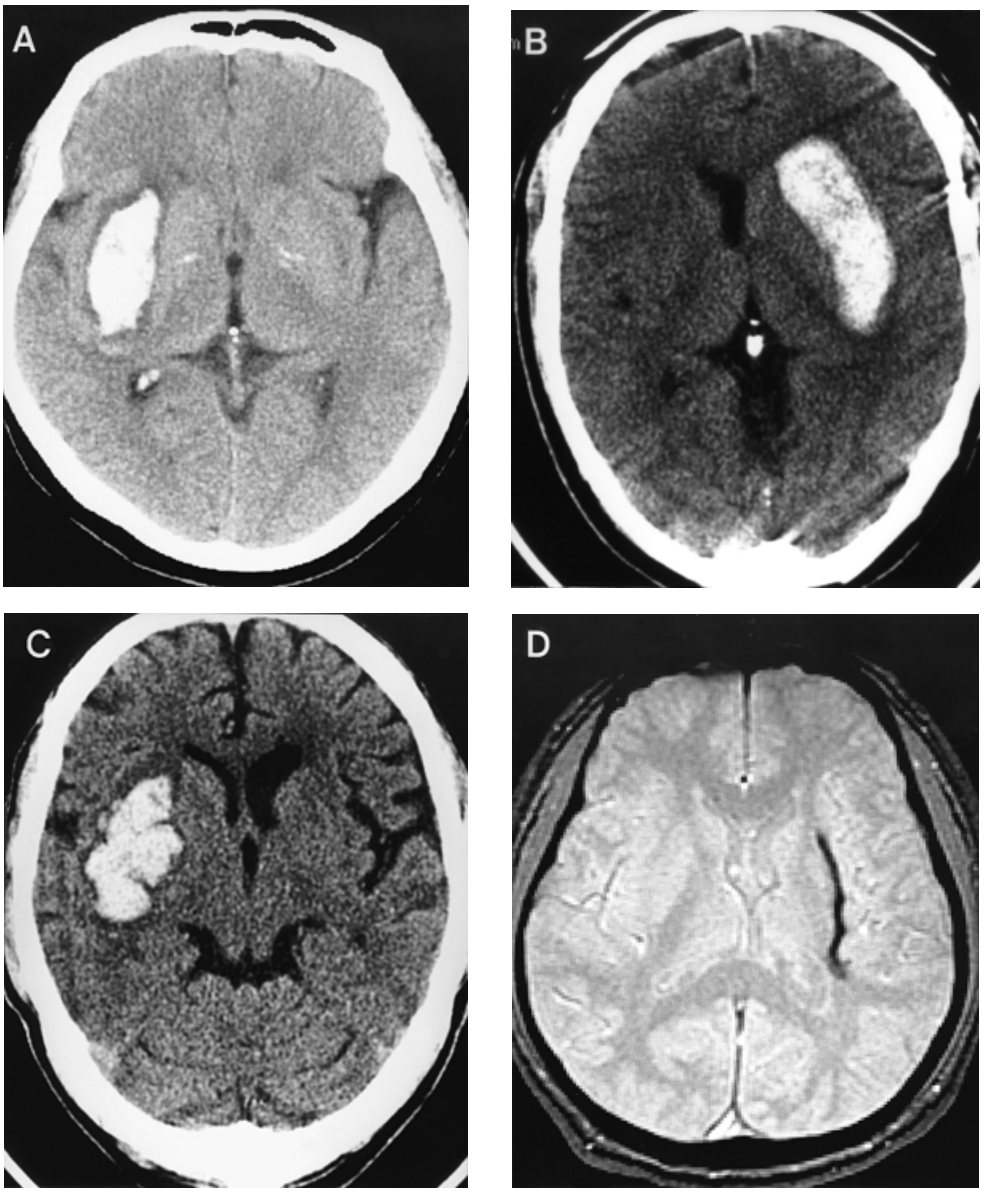


**Fig. 5** CT (**A**–**C**) and MR (**D**) images showing the lateral type of SCHs. As shown in **A**–**C**, they are usually located between the insular cortex and the putamen, forming long elliptical haematomas that exert pressure on the lateral part of the putamen. They usually leave a slit-like low signal lesion on the follow-up gradient echo MR image (**D** and 3 months after the onset in the patient in **C**).

investigated the morphological characteristics of the individual types in neuroimaging studies. We analysed the features with respect to haematoma size and directions and patterns of haematoma spread. Two patterns of haematoma spread were assessed: (i) ventricular rupture causing intraventricular haemorrhage; and (ii) parenchymal spread involving the specific adjacent structures like the thalamus or adjacent subcortical white matter. The direction of haematoma spread was determined as the vector line that was drawn from the centre of the haematoma to its farthest point. We correlated the clinical data with the neuroimaging features to characterize the individual types of SCHs.

## Results

### *Clinical and neuroimaging characteristics of individual types*

Of 215 haematomas, 112 (52.1%) occurred on the left side. The posterolateral type was most common (72, 33%) and was followed by massive (24%), lateral (21%), anterior (11%), middle (7%) and posteromedial (4%) types in decreasing order of frequency.

### *Anterior type of SCH*

Twenty-three patients (23/215, 11%; right 12, left 11) had the anterior type, which mainly involved the caudate nucleus

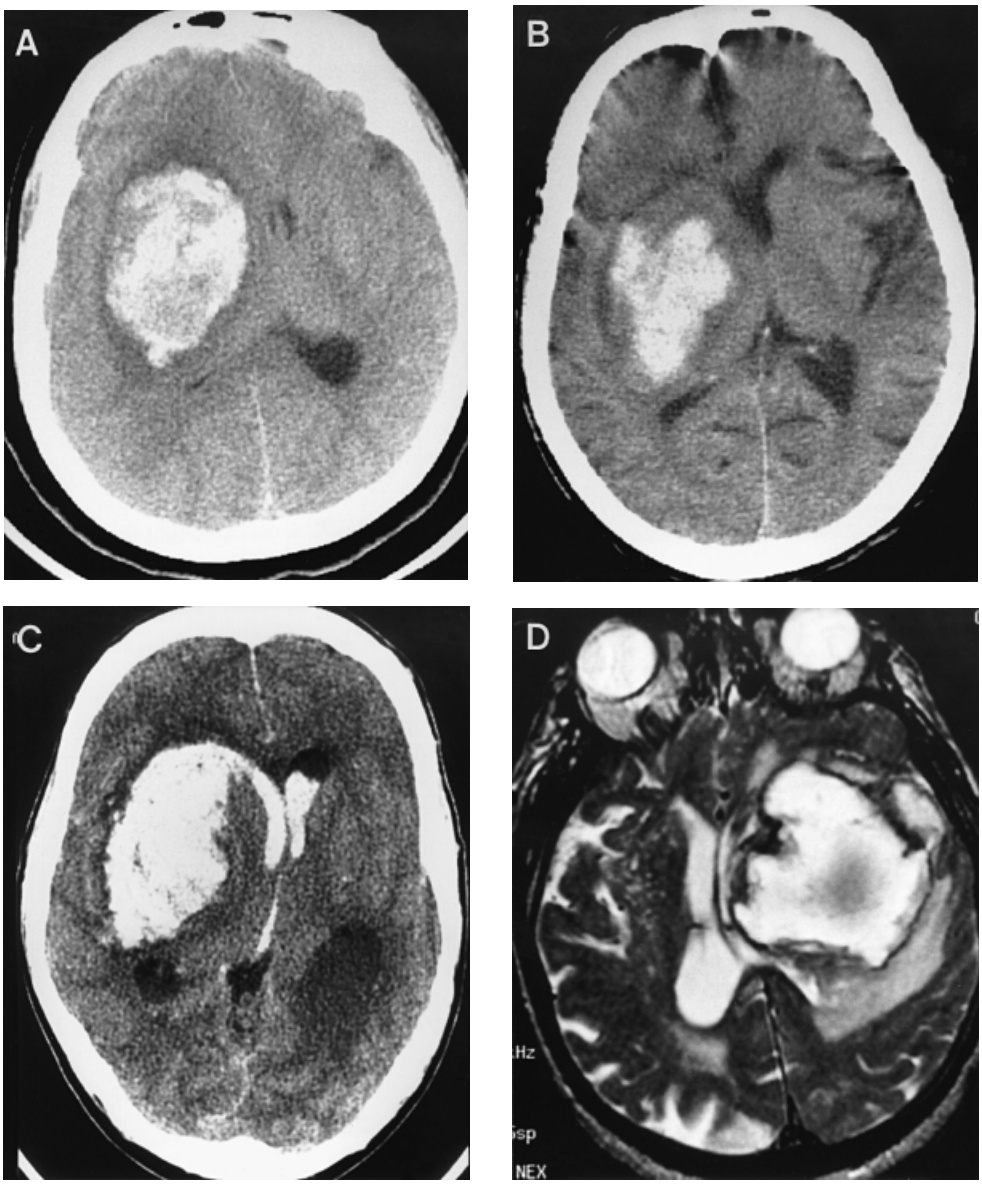


**Fig. 6** CT (**A**–**C**) and MR (**D**) images showing the massive type of SCH. Haematomas are huge and occupy the entire striatocapsular area but occasionally save the caudate nucleus and anterior limb of the internal capsule (**C**). They often rupture into the anterior horn of the lateral ventricle through its most lateral portion and often compress or extend medially into the lateral portion of the putamen (**A**–**D**). Each picture is from a different patient.

head and/or body (so-called 'caudate haemorrhage'). The haematomas were relatively small (23 ± 5.7 mm), always ruptured into the anterior horn of the lateral ventricle, and occasionally spread posterolaterally into the anterior limb of the internal capsule and anterior putamen (Fig. 1).

The most significant clinical presentations were severe headache and marked meningeal irritation signs, mimicking a subarachnoid haemorrhage. Transient mild motor weakness developed in seven patients (30%). The patients usually remained alert but often showed acute confusion and abulic features initially (10, 44%), which disappeared within 1 week. Transcortical motor dysphasia was noticed in three patients with relatively large haematomas, which also resolved completely with time. Neglect, sensory deficit, eyeball movement and pupillary abnormalities were not observed in any case. The outcome was so excellent that 20 patients (87%) returned to normal (MRS = 0) and only three patients remained mildly hemiparetic (MRS = 1). There were no deaths.

## *Middle type of SCH*

The middle type was uncommon (15/215, 7%; right 9, left 6) and involved the globus pallidus and the middle portion of the medial putamen. The haematomas were moderate in size (27.8 ± 7.3 mm) and ventricular rupture did not happen in any case. They often spread anterolaterally (Fig. 2).

Consciousness was impaired in five patients (33%) initially, but they recovered within a few days. Language impairment was observed in three patients who had a relatively large SCH (anomic dysphasia in two and global aphasia in one). Transient conjugate gaze paresis was observed in four patients (27%). Contralateral hemiparesis of mild to moderate degree developed in all cases. Contralateral hemisensory deficits were also observed in 10 patients (67%). Eight patients (53%) returned to normal activities (MRS = 0 or 1) and other patients remained mildly to moderately disabled (MRS = 2 or 3). There were no deaths.

### *Posteromedial type of SCH*

The posteromedial type was the least frequent (8/215, 4%; right 4, left 4) and was usually localized in the anterior half of the posterior limb of the internal capsule (so-called 'capsular haemorrhage'). Haematomas were smallest (15 ± 2.3 mm) with no associated ventricular haemorrhage. They frequently spread to the rostral direction along the capsular fibres and often exerted pressure on the medial part of the putamen or the lateral thalamus (Fig. 3).

Clinically, this type presented with lacunar syndromes. All patients were alert and oriented throughout the whole clinical courses. Language impairment was absent, except that mild dysarthria was noticed in three patients. Neglect was not observed. Transient conjugate gaze paresis was observed in one. Motor weakness of mild to moderate degree of the contralateral face and limbs was observed in all patients. Sensory deficit was observed in four. The outcome was excellent (MRS = 0 to 2) in seven patients (87.5%) while only one patient remained moderately disabled (MRS = 3). There were no deaths.

### *Posterolateral type of SCH*

The posterolateral type of SCH was most common (72/215, 33%; right 39, left 33) and primarily affected the posterior part of the putamen. Haematomas were moderate to large in size (35 ± 9.1 mm). They often involved the anterior putamen and/or retrolenticular portion of the internal capsule. They occasionally ruptured into the anterior horn of the lateral ventricle (Fig. 4).

Initially, about a half of the patients were alert and the other half were drowsy. None was comatose. Language impairments were quite commonly observed with a left-sided SCH (25/33, 76%), while contralateral neglect was observed in 15 patients with a right-sided SCH (15/39, 38%). About 24 patients showed conjugate eyeball deviation to the haematoma side (33%) and wrong-way eye was observed in two patients (3%). Contralateral hemiparesis of moderate to severe degree developed in all. Sensory deficit was present in 32 patients (44%). The clinical outcome was excellent in 18 patients (25%) with a relatively small localized haematoma, fair in 44 (69%), and poor in 10 (6%). Twelve patients (16.7%) were treated with stereotactic surgical drainage and there was an excellent outcome in nine (75%). There were no deaths.

### *Lateral type of SCH*

The lateral type was common (46/215, 21%; right 16, left 30) and primarily located between the external capsule and insular cortex. They were elliptical or lens-shaped and usually large, with the mean long diameter of 53 (±8.2) mm and the mean short diameter of 23 (±5.5) mm. In 10 patients (22%) the haematoma ruptured into the lateral ventricle through the most lateral branches of the anterior horn of the lateral ventricle. This type of SCHs often exerted marked pressure medially on the middle portion of the putamen and usually saved the putamen as shown in the follow-up MRIs in some patients (Fig. 5D). They only occasionally they spread partly into the putamen (Fig. 5C). They were not putaminal in origin, although they have long been regarded as putaminal haemorrhages.

Initially, 30 patients (65%) were alert, 12 drowsy and four stuporous. Language impairment was a common presentation in left-sided lesions (16/30, 53%), but usually resolved over several weeks. Contralateral neglect was observed in five of 16 patients with a right-sided haematoma (31%). Conjugate gaze paresis was noticed in nine patients (20%) and there were no wrong-way eyes. Contralateral hemiparesis of mild to moderate degrees developed in all patients, while sensory deficit was uncommon (8, 17%). In 10 patients (22%) the haematomas were surgically evacuated and the clinical outcome was excellent in eight and fair in two. The overall clinical outcome was excellent in 26 (57%), fair in 10 (22%) and poor in 10 (22%). Three patients died (fatality rate 7%).

### *Massive type of SCH*

The massive type was the second most common type (51/215, 24%; right 23, left 28) and involved the entire striatocapsular region but occasionally the caudate nucleus and anterior limb of the internal capsule were spared. The haematomas were too large (mean diameter: 65 ± 10.2 mm) to define the bleeding focus. They frequently ruptured into the anterior horn of the lateral ventricle.

Consciousness was impaired in all patients. Language impairment or neglect was present in all patients. Ocular movement was impaired in 28 patients (55%) and wrong-way eyes were observed in five (10%). Contralateral hemiparesis of a marked to severe degree developed in all. Sensory deficit was noticed in 18 patients (35%). Patients with a massive type of SCH often presented with herniation syndromes with decreasing level of consciousness, tetraparesis, and oculomotor signs of upper brain stem dysfunction within minutes or hours, even before admission to the hospital.

There were no cases of excellent recovery. The outcome was fair in 17 patients (33%) and poor in nine (18%), and

25 patients died (fatality rate = 49%). The haematomas were surgically evacuated in 20 patients, but 11 of them died.

The radiological and clinical characteristics of the individual types of SCHs are summarized in Table 1.

### *Management*

Most patients were managed medically. None of the patients of the anterior, middle and posteromedial types was managed surgically. Surgical interventions were performed in a total of 42 patients (19.5%). Of these, there were 12 cases of posterolateral type, 10 of lateral type and 20 of massive type. Stereotactic aspiration was performed for 19 patients (12 posterolateral and seven lateral types) and open haematoma evacuation was performed for 23 patients, including all patients with massive type and three with lateral type.

Surgical outcome was excellent in 17 patients, fair in seven and poor in 18 (MRS = 5 in seven and MRS = 6 or dead in 11).

## Discussion

### *Brain haemorrhages and vascular territory*

Our assumptions in this study have been that all spontaneous haemorrhages develop from ruptures of specific arteries, that the resulting haematomas differ in size, shape, location (even in the given anatomical site) and spread patterns, and that they present with corresponding different clinical presentations and outcomes.

SCHs, so-called basal ganglionic haematomas, involve the striatum and internal capsule near the capsular genu and extending into the posterior limb of the internal capsule and often into the adjacent lateral ventricle. Before the advent of CT, scanning clinicians depended on Miller Fisher's descriptions based on the clinical–pathological findings in patients with very large putaminal haemorrhages, which were most likely to cause death (Fisher, 1961). These findings included contralateral hemiplegia, hemisensory loss and hemianopia, ipsilateral conjugate gaze deviation, and language abnormalities in dominant hemispheric lesions and contralateral neglect in nondominant hemispheric lesions. These had long been considered as the classical signs of putaminal or basal ganglionic haemorrhages before the era of CT scans. When CT scanning became available, it was recognized that both large and small haematomas occurred in the basal ganglia and internal capsule, and that the clinical signs varied considerably depending on the size and location of the haematomas as defined by CT scan (Scott *et al*., 1974; Hier *et al*., 1977; Mizukami *et al*., 1981). The classical signs described by Fisher occurred only in the very large haematomas that usually involved the putamen and the genu portion of the internal capsule, but less severe deficits frequently occurred in smaller haemorrhages. Small haemorrhages could produce minor neurological signs even mimicking the pure motor hemiplegia syndrome found in patients with lacunar capsular infarcts (Tapia *et al*., 1983; Weisberg and Wall, 1984). With the advent of MRI, which had the additional capability of producing images in multiple planes, the location, haematoma size and haematoma spread pattern could be more accurately determined. Thus more precise clinico-anatomical correlation of ICHs became possible.

Different from ischaemic strokes, spontaneous ICHs have long been classified according to the neuroanatomical locations, but bleeding arteries themselves have been neglected and given little attention by clinicians. Only a few studies have tried this concept in the classification of ICHs. Thalamic haemorrhages (Chung *et al*., 1996) and pontine haemorrhages (Chung and Park, 1992) were re-classified according to the vascular territories of the thalamus and pons, and it was found that each type of new classification system presented with unique haematoma locations, parenchymal spread patterns, ventricular rupture patterns, neurological features and clinical outcomes. The classification system of pontine haemorrhages has been found to be useful in clinical practice (Wijdicks and St Louis, 1997). In this study we have provided a more consistent clinico-topographical classification method of SCHs on the basis of vascular territories.

### *Anatomical substrates for clinical presentations of each type of SCH*

The basal ganglia are organized into several structurally and functionally distinct 'circuits' that link the cerebral cortex, basal ganglia and thalamus, with each circuit focused on a different portion of the frontal lobe (Alexander *et al*., 1986). Two distinct loops seem to exist through the basal ganglia: (i) a 'motor' loop passing largely through the putamen, which receives inputs from sensorimotor cortex and whose influences are ultimately transmitted to certain premotor areas; and (ii) an 'association' (or 'complex') loop passing through the caudate nucleus, which receives input from the association areas and whose influences are ultimately returned to portions of the prefrontal cortex (DeLong *et al*., 1983).

The anterior type of SCH results from rupture of the Heubner's arteries or branches of the medial lenticulostriate arteries and mainly affects the caudate nucleus head or body; this type has been relatively well described under the classification, caudate haemorrhage (Stein *et al*., 1984; Weisberg, 1984; Kumral *et al*., 1999). Because the caudate nucleus forms the wall of the lateral ventricle, haematomas developing in this region always cause ventricular haemorrhage and the symptoms and clinical signs of meningeal irritation, and thus often mimic subarachnoid haemorrhage. When a haematoma affects the anterior limb of the internal capsule and anterior putamen, mild contralateral hemiparesis and transient behavioural abnormalities might develop, but they usually show excellent recovery as shown in this series (Stein *et al*., 1984).

**Table 1** *Summary of clinical and imaging characteristics of the individual types of SCHs*

| | Anterior | Middle | Posteromedial | Posterolateral | Lateral | Massive |
|---|---|---|---|---|---|---|
| Frequency | Uncommon (23/215 = 11%, Rt 12, Lt 11) | Uncommon (15/215 = 7%, Rt 9, Lt 6) | Least common (8/215 = 4%, Rt 4, Lt 4) | Most common (72/215 = 33%, Rt 39, Lt 33) | Common (46/215 = 21%, Rt 16, Lt 30); not a true basal ganglionic haemorrhage | Second most common (51/215 = 24%, Rt 23, Lt 28) |
| Main location | The caudate nucleus head and/or body—'caudate haemorrhage' | The middle portion of the lentiform nucleus (globus pallidus and/or medial putamen) | Usually localized in the posterior limb of the internal capsule—'capsular haemorrhage' | Primarily the posterior part of the putamen | Primarily located in the white matter between the external capsule and insular cortex | Involve the entire striatocapsular areas but may save the caudate nucleus and anterior limb of the internal capsule |
| Haematoma size (mean diameter ± SD | Small to moderate (23 ± 5.7 mm) | Moderate (27.8 ± 7.3 mm) | Smallest (15 ± 2.3 mm) | Moderate to large (35 ± 9.1 mm) | Elliptical or convex lens shape: large haematoma: 53 (± 8.2) mm by 23 (± 5.5) mm | Huge (65 ± 10.2 mm) |
| Parenchymal spread | Posterolaterally into the anterior limb of the internal capsule and anterior putamen if any | Frequently anterolaterally into the external capsular area | Frequently rostal spread along the capsular fibres; occasionally exerts pressure on the medial part of the putamen or the lateral thalamus | Anterolaterally spread into the anterior putamen; medially compress the posterior limb of the internal capsule and often lateral thalamus together | Occasionally compress or spread medially into the middle portion of the putamen | Posterolateral or lateral type seems to be the source of bleeding in most cases |
| Ventricular rupture | Always | None | None | Rupture into the anterior horn of the lateral ventricle in most cases | Occasionally rupture into the anterior horn of the lateral ventricle via its most lateral part | Frequently rupture into the anterior horn of the lateral ventricle |
| Consciousness | Only rarely impaired | Impaired in about $\frac{1}{3}$ of the patients | Alert | Alert in $\frac{1}{2}$, drowsy in $\frac{1}{2}$, never comatose | Alert in $\frac{1}{2}$, drowsy in $\frac{1}{2}$, rarely comatose (<5%) | Impaired in almost all cases |
| Language impairment | Only rarely in large haematoma | Only rarely in large haematoma | None | Quite common with left-sided lesions (in 75%) | Common in left-sided lesions (in 50%) | All |
| Neglect | None | None | None | In $\frac{1}{2}$ with right-sided lesions | Occasionally (15%) | All |
| Abnormal ocular movement | None | About 40% | In $\frac{1}{3}$ (deviated to the lesion side) | In about $\frac{1}{3}$ (ispi-deviated); rarely wrong-way eye | $<\frac{1}{5}$, no wrong-way eyes | Impaired in $>\frac{1}{2}$ of the patients, rarely wrong-way eyes |
| Motor weakness | Often absent but very mild in $\frac{1}{3}$ | Mild to moderate | Mild to moderate | Moderate to severe | Mild to moderate | Marked to severe |
| Sensory deficit | None | Occasional | Relatively frequent | In about $\frac{1}{3}$ | Rare | In about $\frac{1}{3}$ |
| Outcome | Very excellent, >80% of patients return to normal activities (MRS 0 or 1), no death | >50% of patients return to normal activities (MRS 0 or 1), fair in others, no death | Very excellent in 75% (MRS 0 or 1), only occasionally moderate disability, no death | Excellent in 25% (MRS 0–2), fair in 70% (MRS 3–4), poor in 5% (MRS 5), no death | Excellent in 60% (MRS 0–2), fair in 20% (MRS 3–4), poor in 20% (MRS 5 or 6), case fatality rate of 7% | Poor in $\frac{2}{3}$ (MRS 5 or 6); no excellent recovery, case fatality rate of 49% |

MRS = Modified Rankin Scale; Rt = right; Lt = left.

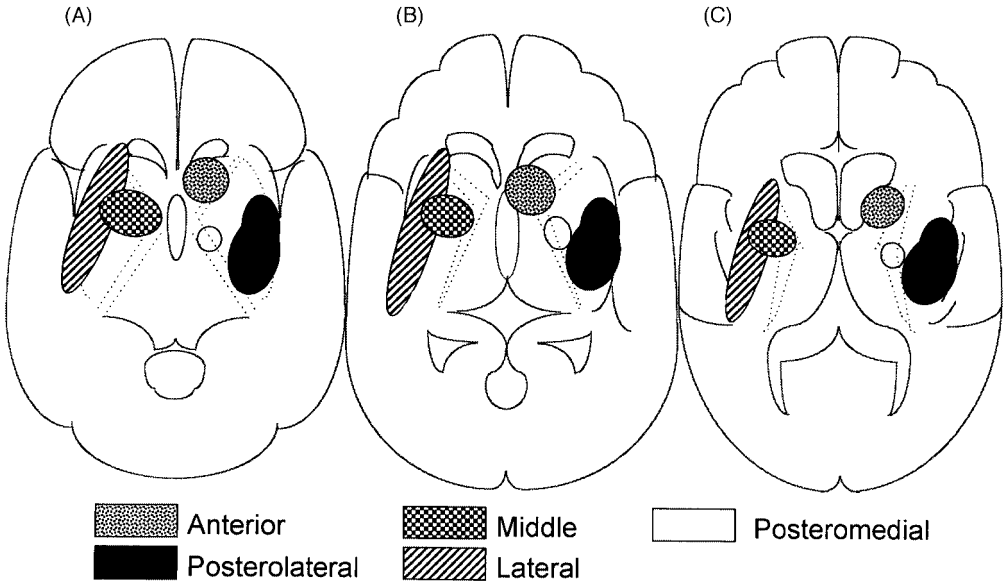


**Fig. 7** A diagrammatic classification of SCHs.

The uncommon middle type of SCH has been less well described separately prior to this study, and affects the globus pallidus, the middle portion of the medial putamen, and occasionally the genu portion of the internal capsule. Thus, this type of SCH causes a variety of clinical syndromes and presents with consciousness impairment, dysphasia, contralateral hemiparesis and hemisensory deficits in variable combinations. The outcome is also benign and is frequently excellent.

The posteromedial type of SCH causes injury to the anterior portion of the posterior limb of the internal capsule and thus can be called 'capsular haemorrhage'. It often spreads rostrally along the internal capsular fibres. Thus its clinical presentations are invariably motor-related lacunar syndromes like pure motor hemiparesis or sensorimotor stroke, with or without dysarthria. The outcome is excellent.

The posterolateral type of SCH involves the retrolenticular portion of the internal capsule and often dissects into the temporal isthmus white matter. It causes one of the most characteristic and well-recognized syndromes of ICH. Initially about a half of the patients are alert and the other half are drowsy, but none is comatose. Weakness of the contralateral side is invariably present. Sensory impairment may be associated. Cortical deficits are usually prominent and include aphasia, or neglect and inattention to contralateral-side stimuli. Aphasia is quite commonly observed with a left-sided SCH and is often global, but at times may be predominantly motor or sensory. In the acute phase, a precise correlation with lesion site on CT scan and aphasia type is usually difficult because of expansive effects of the haematoma but it becomes clearer after the acute phase. The clinical outcome is excellent in only a quarter of patients who have a small, localized haematoma. Others present relatively poor outcome but they do not result in death.

The relatively common lateral type of SCH is primarily located in the subinsular white matter between the external capsule and insular cortex. This type does not directly affect the putamen but often compresses the middle portion of the putamen, forming an elliptical haematoma. Long-term follow-up by neuroimaging usually demonstrates slit-like remnant lesions between the putamen and insular cortex as shown in Fig. 5D. Nevertheless, this type has long been regarded as a putaminal or basal ganglionic haemorrhage. Occasionally the haematomas rupture into the lateral ventricle through the anterior horn of the lateral ventricle.

Despite the relatively larger size of haematoma, this type presents with a benign clinical course. Only a few patients become stuporous and most patients remain alert. Contralateral hemiparesis of a mild to moderate degree develops in all patients, whereas sensory deficit is uncommon. Transient language impairments are quite common and seem to be caused by destruction of the arcuate fasciculus or by compression of the overlying operculum.

The clinical course presents two extreme outcomes: in about 80% of patients the outcome is relatively excellent, whereas it is very poor in others who have both large parenchymal haematoma and ventricular haemorrhages.

The massive type of SCH affects the entire striatocapsular region, often sparing the caudate nucleus and anterior limb of the internal capsule. It frequently ruptures into the anterior horn of the lateral ventricle. Consciousness impairment and marked contralateral hemiparesis develop in all patients. It often presents with a midline shift, obstruction of the foramen of Monro with dilatation of the contralateral lateral ventricle, and typical 'central' or 'uncal' herniation syndromes with decreasing level of consciousness, tetraparesis and oculomotor signs of upper brainstem dysfunction. There is no case of excellent recovery and more than 80% of patients die.

### *Overall prognosis and management options for SCHs*

The prognosis is clearly related to the anatomical type of SCHs (Table 1). Within a given type the haematoma size and presence of spread to the adjacent regions were the most significant prognostic factor. Medical management alone resulted in satisfactory outcome in most patients, particularly in the anterior, middle and posteromedial types. In most patients with the non-extensive posterolateral type of SCH, saving the internal capsule could be managed medically with a favourable outcome. Despite the relatively large haematoma size the patients of the lateral type presented with benign clinical courses and thus were managed medically.

Surgical interventions were considered in patients who presented with progressing neurological deficits and deepening of altered consciousness. About 20% of the patients underwent surgical interventions. In the posterolateral type of SCH stereotactic aspiration was done for the patients showing extensive haematomas which presented with spread into the anterior part of the putamen, compression of the posterior limb of the internal capsule, or both. In these cases surgical aspiration decompressed the involving structures successfully and resulted in rapid clinical improvement in most cases. However, clinical improvement was delayed or was not observed by the time of discharge when the haematoma damaged the lateral thalamus also or when the surgical intervention was performed >24 h after onset.

In case of the lateral type of SCHs, 10 patients underwent surgical intervention due to extensive haematomas large enough to cause intraventricular haemorrhage and progression of neurological deficits. Clinical outcome was also excellent in general.

Open surgical evacuation of haematoma was performed in 20 patients with the massive type of SCH. More than half of the patients died and the other patients remained markedly disabled. Only two patients improved up to MRS of 4 after surgery. Thus surgical intervention seemed to be a life-saving tool in the massive type of SCHs.

In conclusion, the haemorrhages developing in the striatocapsular regions can be classified according to the supplying arteries as in pontine and thalamic haemorrhages. This classification system is relatively simple and easy to employ, as shown diagrammatically in Fig. 7. Each type presents with its own unique location, morphological characteristics, and clinical presentations and outcomes. Thus this new classification system seems to provide a more accurate assessment of possible clinical outcomes and to indicate good therapeutic guidelines during the early phase of SCHs.

## Acknowledgements

The authors are grateful to Ms Sooyeon Lee for her technical and secretarial assistance. The authors wish to acknowledge the financial support of the Korea Research Foundation (Grant #198-001-F00421) made in the program year of 1998 to C.-S.C.

**References**

Alexander GE, DeLong MR, Strick PL. Parallel organization of functionally segregated circuits linking basal ganglia and cortex. [Review]. Annu Rev Neurosci 1986; 9: 357–81.

Barth A, Bogousslavsky J, Caplan L. Thalamic infarcts and hemorrhages. In: Bogousslavsky J, Caplan L, editors. Stroke syndromes. Cambridge: Cambridge University Press; 1995. p. 276–83.

Bogousslavsky J, Regli F, Uske A. Thalamic infarcts: clinical syndromes, etiology and prognosis. Neurology 1988; 38: 837–48.

Chung C-S, Caplan LR, Han W, Pessin MS, Lee K-H, Kim JM. Thalamic haemorrhage. Brain 1996; 119: 1873–86.

Chung C-S, Park C-H. Primary pontine hemorrhage: a new CT classification. Neurology 1992; 42: 830–4.

DeLong MR, Crutcher MD, Georgopoulos AP. Relations between movement and single cell discharge in the substantia nigra of the behaving monkey. J Neurosci 1983; 3: 1599–606.

Fisher CM. Clinical syndromes in cerebral hemorrhage In: Fields WS (editor). Pathogenesis and treatment of cerebrovascular disease. Springfield (IL): Charles C. Thomas; 1961. p. 318–42.

Ghika JA, Bogousslavsky J, Regli F. Deep perforators from the carotid system: template of the vascular territories. [Review]. Arch Neurol 1990; 47: 1097–100.

Hier DB, Davis KR, Richardson EP Jr, Mohr JP. Hypertensive putaminal hemorrhage. Ann Neurol 1977; 1: 152–9.

Kumral E, Evyapan D, Balkir K. Acute caudate vascular lesions. Stroke 1999; 30: 100–8.

Mizukami M, Nishijima M, Kin H. Computed tomographic findings of good prognosis for hemiplegia in hypertensive putaminal hemorrhage. Stroke 1981; 12: 648–52.

Scott WR, New PF, Davis KR, Schnur JA. Computerized axial tomography of intracerebral and intraventricular hemorrhage. Radiology 1974; 112: 73–80.

Stein RW, Kase CS, Hier DB, Caplan LR, Mohr JP, Hemmati M, et al. Caudate hemorrhage. Neurology 1984; 34: 1549–54.

Tapia JF, Kase CS, Sawyer RH, Mohr JP. Hypertensive putaminal hemorrhage presenting as pure motor hemiparesis. Stroke 1983; 14: 505–6.

van Swieten JC, Koudstaal PJ, Visser MC, Schouten HJA, van Gijn J. Interobserver agreement for the assessment of handicap in stroke patients. Stroke 1988; 19: 604–7.

Weisberg LA. Caudate hemorrhage. Arch Neurol 1984; 41: 971–4.

Weisberg LA, Wall M. Small capsular hemorrhages. Clinical-computed tomographic correlations. Arch Neurol 1984; 41: 1255–7.

Wijdicks EF, St Louis E. Clinical profiles predictive of outcome in pontine hemorrhage. Neurology 1997; 49: 1342–6.

*Received October 25, 1999. Revised May 10, 2000. Accepted May 25, 2000*