Brain (2002), **125,** 1719–1732

Focal cortical dysplasia: neuropathological subtypes, EEG, neuroimaging and surgical outcome

L. Tassi,[1] N. Colombo,[2] R. Garbelli,[4] S. Francione,[1] G. Lo Russo,[1] R. Mai,[1] F. Cardinale,[1] M. Cossu,[1] A. Ferrario,[4] C. Galli,[3] M. Bramerio,[3] A. Citterio[2] and R. Spreafico[4]

[1]*Epilepsy Surgery Centre 'C. Munari',* [2]*Department of Neuroradiology and* [3]*Department of Pathology, Niguarda Hospital,* [4]*Department of Experimental Neurophysiology and Epileptology, Istituto Nazionale Neurologico 'C. Besta', Milan, Italy*

Correspondence to: Roberto Spreafico, MD, PhD, Department of Experimental Neurophysiology and Epileptology, Istituto Nazionale Neurologico 'C. Besta', Via Celoria 11, 20133 Milano, Italy
E-mail: spreafico@istituto-besta.it

Summary

Since the original description by Taylor, the term focal cortical dysplasia has been used to refer to a wide range of alterations of the cortical mantle. More recently, these conditions have been described from neuroimaging, neuropathological and genetic standpoints, generating several classifications. It is widely recognized that these classifications are unsatisfactory. We propose a simplified classification of focal cortical dysplasias based on easily recognized neuropathological characteristics. We retrospectively re-examined histological sections of cortex from 52 of 224 (23%) patients operated on for drug-resistant partial epilepsy in which cortical dysplasia was present but not associated with other brain pathologies except hippocampal sclerosis. Three subgroups were identified: (i) architectural dysplasia (31 patients) characterized by abnormal cortical lamination and ectopic neurones in white matter; (ii) cytoarchitectural dysplasia (six patients) characterized by giant neurofilament-enriched neurones in addition to altered cortical lamination; and (iii) Taylor-type cortical dysplasia (15 patients) with giant dysmorphic neurones and balloon cells (all but two patients) associated with cortical laminar disruption. The patients with architectural dysplasia had lower seizure frequency than those with cytoarchitectural and Taylor-type dysplasia, and the epileptogenic zone was mainly in the temporal lobe. In patients with Taylor-type dysplasia, the epileptogenic zone was mainly extratemporal, and interictal stereo-EEG was distinctive. MRI was unrevealing in 34% of patients, but distinctive signal alterations characterized most patients with Taylor-type dysplasia, while focal hypoplasia with MRI abnormalities was found in architectural dysplasia. Patients with Taylor-type dysplasia had the best outcome, with 75% seizure-free (Engel class Ia) after at least a year of follow-up compared with 50% of cytoarchitectural dysplasia and 43% of architectural dysplasia patients seizure-free. This three-category classification is based on easily recognized histopathological characteristics and avoids complicated terminology, while the distinctive ensemble of other characteristics defines clinically homogeneous groups.

Keywords: neuropathology; stereo-EEG; epilepsy; MRI; dysplasia

Abbreviations: AD = architectural dysplasia; CD = cytoarchitectural dysplasia; FCD = focal cortical dysplasia; FLAIR = fluid-attenuated inversion recovery; GFAP = glial fibrillary acidic protein; HE = haematoxylin and eosin; IR = inversion recovery; MCD = malformations of cortical development; SEEG = stereo-EEG; TFCD = Taylor-type cortical dysplasia; TSE = turbo spin-echo; VEEG = video-EEG

Introduction

The final organization of the cortical mantle is the result a series of partially overlapping prenatal developmental processes. Three major stages generally are recognized: (i) proliferation of undifferentiated cells in the neuroepithelium; (ii) migration of neuroblasts; and (iii) cell differentiation. Perturbation of any of these processes, as a result of a genetic defect or noxious environmental influence, usually results in malformations of cortical development (MCD). Such malformations are associated with neurological defects, cognitive deficits and particularly epilepsy. In fact, 8–12% of cases of

© *Guarantors of Brain 2002*

intractable epilepsy are associated with MCD (Li *et al*., 1995; Semah *et al*., 1998), while 14–26% of surgically treated cases of paediatric epilepsy have MCD (Polkey, 1996; Wyllie *et al*., 1998).

MCD are a heterogeneous group of focal and diffuse anatomical derangements whose pathological features depend largely on the timing of the defect in the developmental process and to a lesser extent on its cause (Barkovich *et al*., 1996). Modern neuroimaging techniques increasingly are able to pick out MCD *in vivo*, revealing that they are more common than previously suspected and that they present a wide spectrum of forms (Raymond *et al*., 1995; Shorvon, 1997; Yagishita *et al*., 1997; Barkovich *et al*., 2001). However, even high resolution MRI fails to detect many malformations, and ~20–50% are recognized only by careful neuropathological study following surgery, usually for intractable epilepsy (Kuzniecky *et al*., 1993; Li *et al*., 1995; Kuzniecky and Barkovich, 1996; Spreafico *et al*., 1998; Ying *et al*., 1998).

Taylor *et al*. (1971) were the first to describe distinctive focal anomalies of cortical structure, to which they gave the term focal cortical dysplasia (FCD). Subsequently, this term has been used extensively in the literature to refer to a wide range of derangements of cortical anatomy, while alterations originally observed in surgical specimens and subsequently detected by MRI may be referred to by such terms as mild cortical dysplasia and microdysgenesis as well as FCD. Numerous classifications of these complex structural abnormalities have been proposed (see for example Kuzniecky *et al*., 1991; Palmini *et al*., 1994; Barkovich *et al*., 1996). However, it is widely recognized that none are satisfactory. Furthermore, the aetiologies of these abnormalities are often uncertain and the mechanisms by which they generate epilepsy are also unclear (Janota and Polkey, 1992; Wolf *et al*., 1993; Raymond *et al*., 1995; Bronen *et al*., 1997; Cotter *et al*., 1999; Gomez-Anson *et al*., 2000).

With the aim of developing a more satisfactory classification of FCDs, we re-examined histological specimens from a series of patients operated on for intractable epilepsy. We selected cases in which other brain conditions were absent as determined from case history, laboratory data and MRI findings, as well as the neuropathological observations. From these data, we were able to exclude metabolic disorders, inherited disorders, other types of malformations, tumours, vascular lesions and post-traumatic lesions. However, we did include FCD cases with hippocampal sclerosis because the two conditions frequently are found together (Arai and Oda, 1997), suggesting a relationship between them at least in a proportion of cases. Based on neurohistological properties, we subdivided the FCD cases into three groups. We then examined the electroclinical findings, including pre-surgery stereo-EEG (SEEG) when performed, MRI data and post-surgical outcome in each subgroup in order to assess whether the neuropathologically defined subgroups corresponded to clinically homogeneous groups.

Material and methods

From May 1996 to November 2000, 224 patients were operated on for drug-resistant partial epilepsy at the 'Claudio Munari' Surgery Centre for Epilepsy, Milan. Surgery was performed only after the patient or parent had given informed consent, and after comprehensive pre-surgical evaluation that included: (i) history to establish type, age of onset and frequency of seizures; (ii) neurological examination; and (iii) comprehensive EEG or video-EEG (VEEG) examination with at least one ictal recording to relate ictal EEG events to the clinical aspects of the seizure. When the electroclinical data and MRI findings did not identify the epileptogenic zone with sufficient precision, invasive pre-surgical SEEG was used in order to achieve the required precision.

We reviewed the neurohistological data on all these cases and retrospectively selected 52 out of 224 (23%) for further examination. The selected cases were characterized by the presence of FCD with or without cytological alterations. Hippocampal sclerosis may also have been present. However, cases with other types of malformation, tumours, vascular lesions or post-traumatic lesions were excluded, even in the presence of focal cortical alterations. The permanent slides were reviewed independently by three neuropathologists, one of whom had not been involved in the initial diagnosis and was blind to the electroclinical data, MRI findings and surgical outcome. In the case of disagreement, the sections were discussed and an agreed diagnosis arrived at.

Histopathological review and classification

The surgical specimens were fixed in 10% neutral buffered formalin, embedded in paraffin and sectioned (4–10 μm). The sections were mounted on gelatin-coated slides and stained with haematoxylin and eosin (HE), thionin, luxol fast blue or Bielschowsky. Immunocytochemical investigations were also performed routinely using anti-glial fibrillary acid protein (GFAP; Boehringer Mannheim, Germany) and anti-neurofilament (SMI 311, Sternberger Monoclonal; 2F11 monoclonal, DAKO, Glostrup, Denmark). The review systematically evaluated the following in all specimens.

Laminar cortical disruption

This was disorganization of the normal layering of the cortex observed on at least two different non-consecutive HE- and thionin-stained sections at different depths of the surgical specimen(s).

Undifferentiated cells

These were characterized as cells of round or oval outline with a large nucleus and thin rim of cytoplasm. They were observed as scattered or clustered elements within the cortical mantle. These cells, not present in the normal adult cortex, were identified as immature neurones (Fig. 1A).

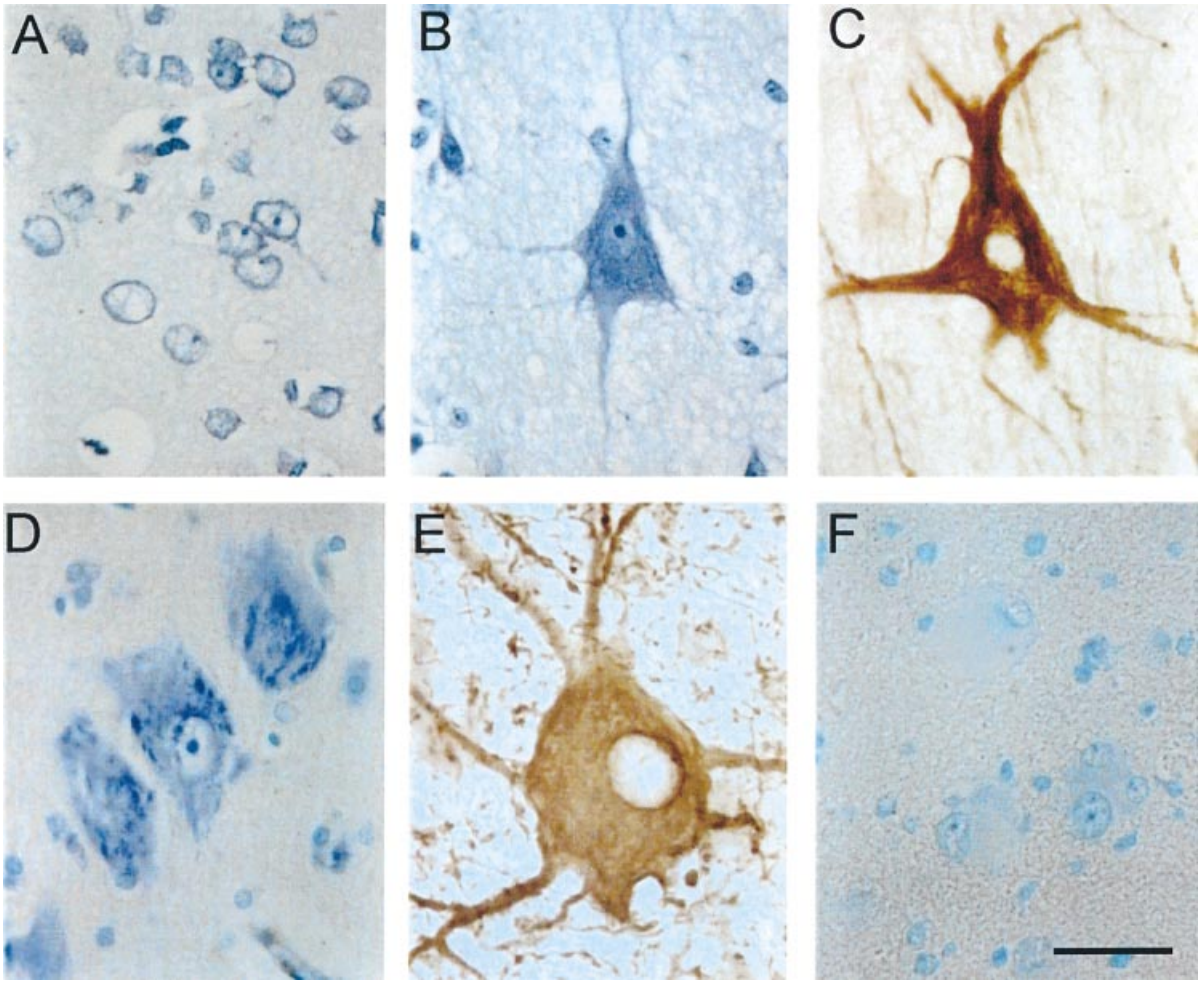

Fig. 1 High power photomicrographs showing cytological features of different types of focal cortical dysplasia. (**A**) Thionin-stained clusters of rounded cells with large nuclei and a thin rim of cytoplasm interpreted as immature neurones. Observed in AD. (**B**) Thionin-stained large pyramidal neurone in CD. (**C**) Large pyramidal neurone showing intense immunostaining for neurofilaments, observed in CD. These neurones (**B** and **C**) were mainly in the superficial half of the grey matter of CD specimens. (**D** and **E**) Large dysmorphic neurones as observed by thionin staining (**D**) and neurofilament immunostaining (**E**) in TFCD. (**F**) Thionin-stained balloon cells frequently observed at the border between grey and white matter in TFCD. All micrographs are at the same magnification (bar = 25 μm).

Giant neurones

These were abnormally large cells (the same size or larger than the large neurones normally present in layer V) present in layers others than layer V (Fig. 1B) and with greater than normal neurofilament content as shown by Bielschowsky or anti-neurofilament immunostaining (Fig. 1C); otherwise their morphology was normal. Such cells were never present outside layer V in normal cortex.

Dysmorphic neurones

These were neurones with abnormal morphology, abnormal size or (when identifiable as pyramidal neurones) abnormal orientation and high neurofilament content (Fig. 1D and E). These morphological characteristics have been described previously at the light microscope and ultrastructural levels (Spreafico *et al*., 1998; Garbelli *et al*., 1999).

Balloon cells

These were abnormal cells frequently of huge size, specifically characterized by an ill-defined cell membrane, pale eosinophilic cytoplasm and one or more eccentric nuclei (Fig. 1F). When present, these cells generally were numerous and clustered particularly at the grey–white matter junction.

Hippocampal sclerosis was diagnosed when the pyramidal cell layers in the hippocampus or dentate gyrus were disrupted, with marked reduction in number of neurones and presence of extensive gliosis (as revealed by GFAP immunocytochemistry).

MRI review

The following sequences were acquired: transverse double-echo spin-echo of the entire brain; T_2-weighted coronal turbo spin-echo (TSE); T_2-weighted coronal TSE fluid-attenuated

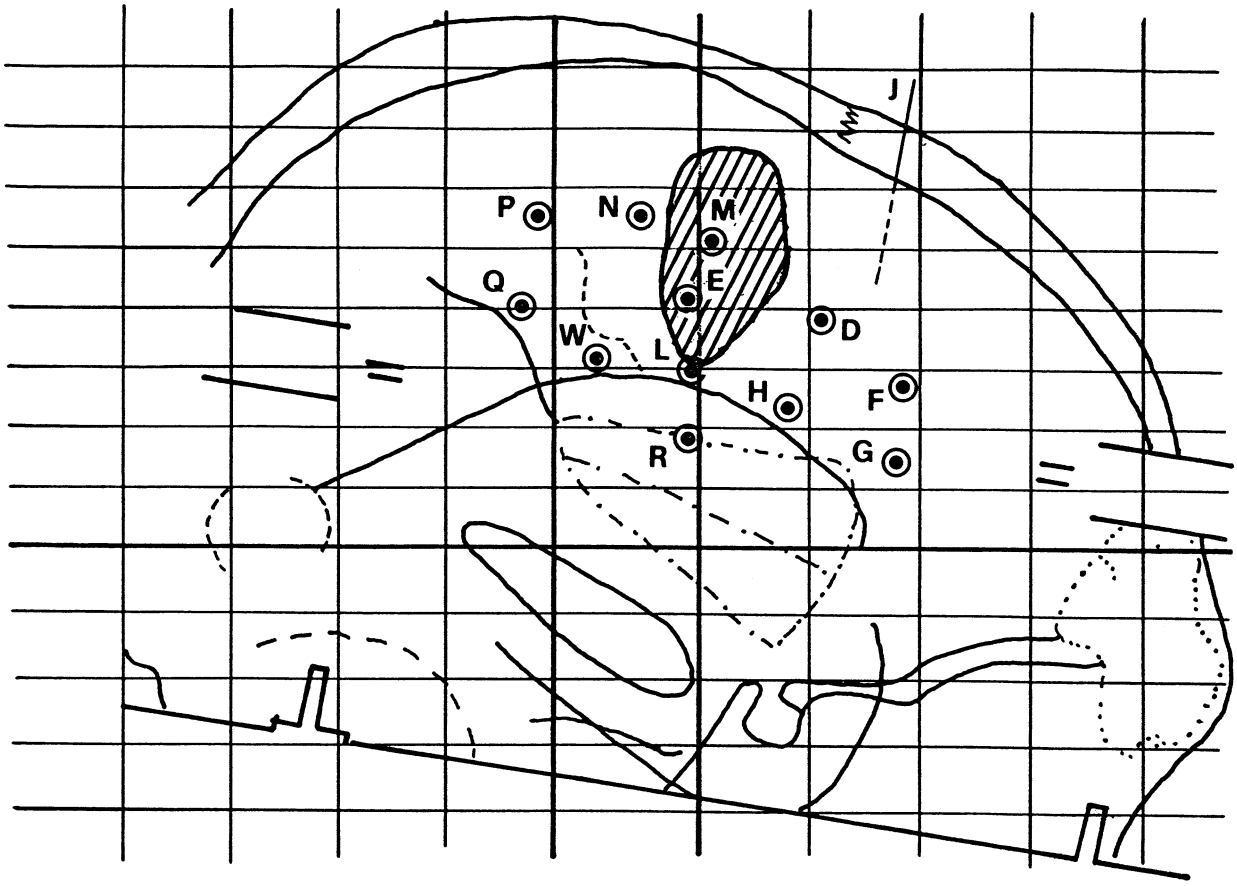

Fig. 2 Schematic lateral view illustrating positions of stereotactically implanted SEEG electrodes (lettered) to explore the right fronto-centro-parietal areas of patient with right frontal TFCD located in the sulcus between F1 and F2 (see Fig. 7 showing an MRI of the same patient). Two intracerebral electrodes (E and M) allowed recordings directly from the anatomical lesion (represented as the hatched area).

inversion recovery (FLAIR); and T_1-weighted coronal inversion recovery (IR). The coronal sequences were acquired at the epileptogenic zone as surmised from the electroclinical data. In most patients, three-dimensional volume fast field echo T_1-weighted images were also acquired. Additional FLAIR or TSE T_2-weighted images in the sagittal plane were obtained when necessary. In patients suspected of having temporal lobe epilepsy, transverse images were acquired parallel, and coronal images acquired perpendicular to the major hippocampal axis. For extratemporal lobe epilepsies, sections were acquired parallel and perpendicular to the bicommissural line. Intravenous contrast was used in some patients, but generally was not useful for diagnosis.

The MRIs were evaluated retrospectively by two neuroradiologists blinded to the histopathological classification. The following features were assessed: gyration anomalies; focal thickenings of the cortex; blurring of the grey–white matter junction; abnormal signal intensity in the cortex and subcortical white matter and focal hypoplasia. Hippocampal sclerosis was diagnosed radiologically in the presence of one or more of the following: hippocampal atrophy; increased signal on T_2-weighted images; decreased signal on T_1-weighted images; and loss of definition of internal structures.

SEEG

In 17 patients (33%), preoperative SEEG was not considered necessary. SEEG, performed in the remaining 35 (67%), was considered mandatory when ictal events recorded by VEEG and imaging data did not identify the epileptogenic zone with sufficient precision to plan the resection. In these patients, the SEEG was tailored to individual anatomic and electroclinical characteristics.

Multilead (5–18) electrodes (Dixi; Besançon, France) were placed intracerebrally under general anaesthesia some weeks after stereo-arteriography to localize blood vessels and guide electrode trajectory (Fig. 2). The procedure used was that described by Talairach and Bancaud (1966) and later refined by Munari and Bancaud (1985) and Munari *et al*. (1994). A few days after electrode implantation three-dimensional MRI was performed to verify electrode trajectory and location in relation to the lesion (when present) or suspected epileptogenic zone. Recordings were obtained over 5–20 days. After at least one ictal recording had been obtained, the electrodes were removed and the final surgical approach defined. The SEEG data were examined preoperatively by at least two neurologists, and three intracerebral volumes were identified: (i) the lesional zone characterized by depression of back-

ground activity or consistent presence of slow waves; (ii) an irritative zone defined by the presence of spikes and waves; and (iii) the epileptogenic zone identified as the cortical area(s) that were the primary origin of the ictal discharges (Talairach and Bancaud, 1966; Munari *et al*., 1994; Chassoux *et al*., 2000). The zones thus identified were related to lesion locations when revealed by MRI.

Surgery

In addition to corticectomy, the anatomic lesion (when identified) was removed. In two patients, however, partial lesionectomy was performed in order not to damage nearby critical structures. In each case, the extent of resection was planned carefully preoperatively taking account of the severity of the epilepsy and other neurological symptoms and the risk of additional post-surgical neurological deficits. In patients who underwent SEEG, the electrode tracts were identified on the brain surface. Tracts present on removed material were marked in order to facilitate correlation of neuropathology with the epileptogenic zone identified by SEEG and the anatomical lesion identified by MRI.

Control tissue

Four specimens (three from the frontal cortex and one from the temporal lobe) from non-epileptic patients operated on for deep low-grade, non-infiltrating tumours served as controls. The samples were processed similarly to those removed from the FCD patients. Alterations of cortical lamination or abnormal cortical neurones or other cells were never observed in these control specimens (Fig. 3A and A′).

Results

The main characteristics of the 52 patients are shown in Table 1. MRI findings are presented in Table 2. Outcomes (at least 1 year after surgery) are available in 37 patients and are shown in Table 3. Based on the neurohistological review, the cases were grouped into the following three categories:

(i) Architectural dysplasia (AD). This was abnormal cortical lamination; ectopic neurones frequently were present in the white matter in quantities greatly exceeding those found scattered in normal tissue (Hardiman *et al*., 1988; Meyer *et al*., 1992); sometimes there were single isolated immature neurones or clusters of these cells within the cortical mantle.

(ii) Cytoarchitectural dysplasia (CD). This was abnormal cortical lamination always associated with the presence of (a) numerous ectopic neurones in the white matter; and (b) giant neurones in cortical layers other than V.

(iii) Taylor-type cortical dysplasia (TFCD). This was abnormal cortical lamination always associated with (a) giant neurones; (b) dysmorphic neurones and (c) large ectopic neurones in the white matter; balloon cells may or not have been present.

Thirty-one patients had AD, six patients had CD and 15 patients had TFCD. We now present the electroclinical, imaging and surgical findings for each of these groups.

Architectural dysplasia (AD)

Histopathological characteristics

In the AD group (60% of the series), the most prominent histopathological feature was disorganization of the cortical layering (Fig. 3B). In general, layers I and II were clearly visible in thionin- and HE-stained sections, although sometimes layer II was thinner and discontinuous as a result of evident reduction in the number of neurones compared with control tissue. The cell concentration in layer I was greater than in controls in specimens from 14 out of 31 (45%) patients and, although most of these cells were glia (GFAP-positive), in most cases increased numbers of neurones, particularly represented by Cajal–Retzius cells, were also present (Garbelli *et al*., 2001). The border between layers III and IV frequently was unrecognizable and, in most cases, layer IV granular cells were either scattered or grouped into clusters. Layer IV was completely absent from the specimens of 18 out of 31 (58%) patients. In no case was a border between layer V and layer VI discerned; this zone always presented as a continuous band of medium and large size neurones, including pyramidal cells. No malformed or giant neurones were present. In eight cases (25%), cells (isolated or clustered) characterized by uniform size, large nuclei and a thin ring of cytoplasm were present throughout the cortex. These poorly differentiated cells also contained sparse neurofilaments and were identified as immature neurones (Fig. 1A). Moderate or intense gliosis (positive GFAP) of the grey matter, white matter or both was observed frequently; however, the extent and distribution of gliosis did not seem related to the extent of cortical disruption. The intensity of immunostaining for neurofilaments was reduced compared with normal tissue and patchily distributed (Fig. 3B′). In 12 cases (39%) who received temporal lobe surgery, ectopic neurones exceeding the quantities present in normal tissue (Hardiman *et al*., 1988; Meyer *et al*., 1992) were present in the underlying white matter. Excessive neurones in layer I, associated with the absence of layer IV and the presence of ectopic neurones in the white matter, were present in six (19%) patients.

Electroclinical findings

The 31 patients with AD consisted of 12 males (39%) and 19 females (61%). Their mean age at surgery was 27 years (range 2–41 years, SD 9) and the mean duration of epilepsy 20 years (range 2–34 years, SD 8). Mean age of epilepsy onset was 7 years (range 0–24 years, SD 8) and the mean seizure frequency (Fig. 4A) was 39 per month (range 1–600, SD 107). Five (16%) patients had an abnormal neurological examination and three (9%) presented mental retardation.

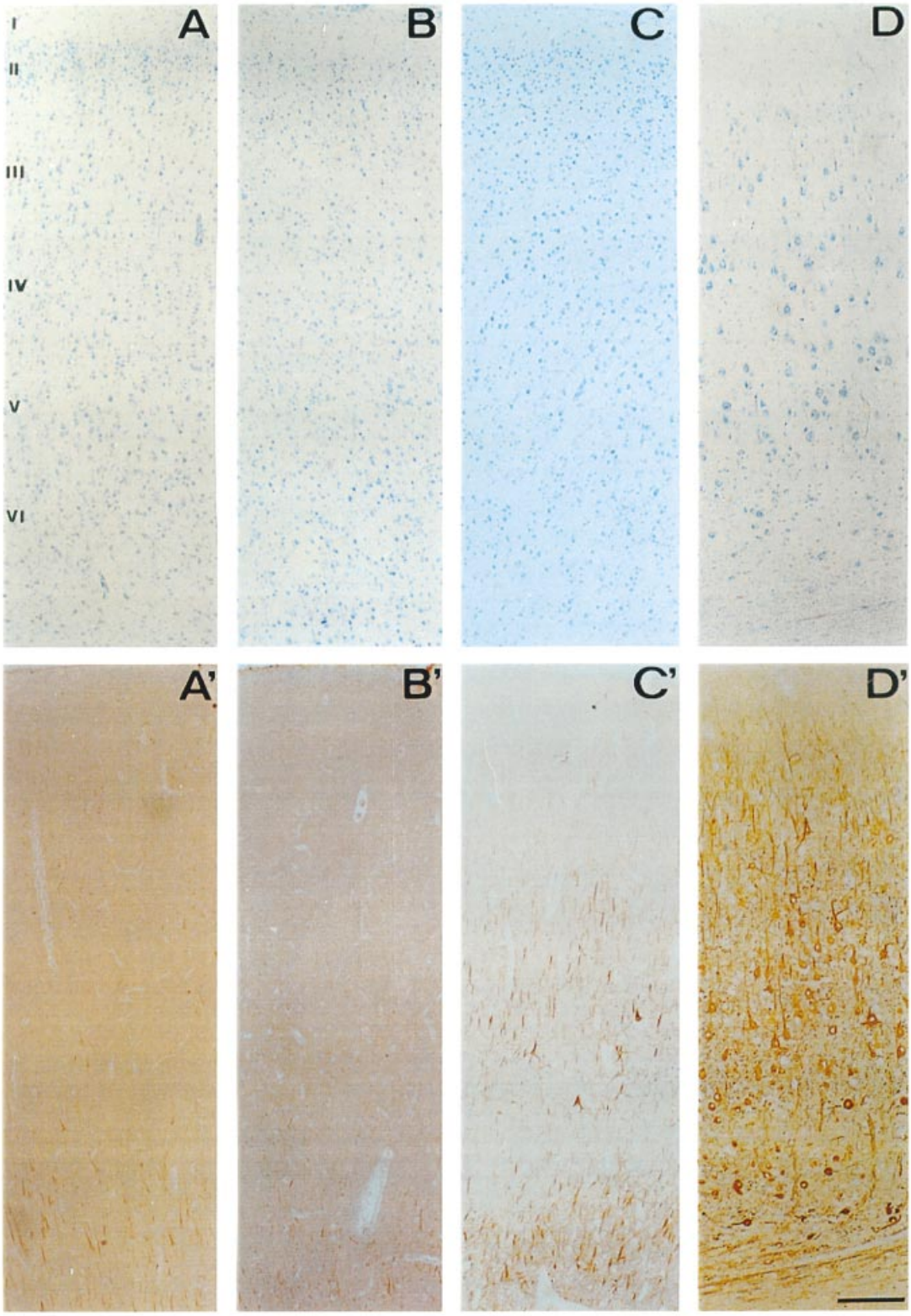

Fig. 3 Low power photomicrographs of thionin-stained sections (upper row) and neurofilament immunostained (SMI 311) sections (lower row), from normal tissue (**A**, **A′**), AD (**B**, **B′**), CD (**C**, **C′**) and TFCD (**D**, **D′**). The thionin-stained sections reveal disorganization of the cortical layer in all three subtypes of dysplasia. Reduced neurofilament immunostaining is visible in AD (**B′**) while large, intensely stained pyramidal cells are visible in CD (**C′**). The disruption of the cortical layers is particularly evident in TFCD (**D**) with intensely stained dysmorphic neurones visible in **D′**. All micrographs are at the same magnification (bar = 300 μm).

Table 1 *Main characteristics of the 52 patients operated on for intractable epilepsy with only FCD on surgical specimens*

Age at seizure onset	Duration of epilepsy	Febrile convulsions	Abnormal neurological examination	Seizure frequency (per month)	Age at surgery
7 years (SD 7) (range 0–26)	17 years (SD 10) (range 1–42)	13 patients (25%)	16 patients (31%)	67 (SD 112) (range 1–600)	24 years (SD 11) (range 2–42)

Febrile convulsions were present in 11 (35%), in nine (29%) of whom hippocampal sclerosis homolateral to the site of dysplasia was demonstrated histologically.

SEEG was performed in 19 (61%) patients while VEEG only (in addition to standard EEG) was performed in 12 (39%). Twenty (65%) patients (subgroup 1) received simple temporal corticectomy, and 11 (35%) (subgroup 2) received extratemporal or multilobar surgery. Subjective ictal manifestations were reported by all patients of subgroup 1, but by only eight (73%) of subgroup 2. Secondary generalized attacks were present in nine (45%) of subgroup 1 and four (36%) of subgroup 2. Status epilepticus occurred in one (5%) of subgroup 1, and one (9%) of subgroup 2, with recurrent seizures in two (10%) of subgroup 1 and seven (64%) of subgroup 2.

MRI findings

In 14 patients (43%), a cortical lesion and hippocampal sclerosis were identified on MRI and confirmed histologically. Signal alteration only was found in the cortex of five patients (16%), in two of whom hippocampal sclerosis was found histologically. In another two patients (9%), signal alterations suggested the presence of hippocampal sclerosis, but in only one of these was this observed histologically. In all cases, hippocampal sclerosis revealed by MRI was unilateral, and ipsilateral to the site of the dysplasia. MRI was unrevealing for hippocampal sclerosis, dysplasia and other brain abnormalities in 10 patients (32%), in two of whom hippocampal sclerosis was associated with architectural dysplasia on histopathology (Table 4).

In two cases, there was extensive grey–white matter blurring, and increased subcortical white matter signal intensity in T_2-weighted images, which diminished in T_1-weighted images (Fig. 5). In 17 (55%) patients, the MRI abnormalities allowed the general diagnosis of cortical dysplasia; of these, 13 patients presented focal hypoplasia (Fig. 5B) associated in nine with a mildly increased signal in T_2-weighted FLAIR sequences in the subcortical white matter. Grey–white matter blurring associated with signal hyperintensity in T_2-weighted images was found in four patients. Slight cortical thickening was observed in three patients.

Surgery and outcome

The temporal lobe was the intervention site in 20 (66%) patients and, in all these, mesial structures were resected.

Table 2 *MRI findings in 52 patients with FCD operated on for intractable epilepsy*

MRI findings	No. of patients	%
Normal	18	34
Focal cortical dysplasia (FCD)	17	33
Hippocampal sclerosis (HS)	3	6
FCD + HS	14	27

Table 3 *Surgical outcome (Engel, 1987) in the 37 intractable epilepsy patients with at least 1 year of follow-up*

Outcome	No. of patients	%
Ia	20	54
Ib	4	11
II	2	5
III	7	19
IV	4	11

Frontal areas were resected in six patients. In four patients, two adjacent lobes were involved, including a temporal lobe, although in only one of these cases were mesial structures resected. In the remaining patient, the occipital lobe was operated on (Fig. 4B).

A follow-up of at least 1 year post-surgery is available for 21 patients. Following the Engel (1987) scale for surgical outcome, 13 of these (62%) are in class I, of whom nine (43%) are in class Ia (Fig. 4C). No outcome differences were observed between patients who received mesial structure resections and those who did not.

Within the AD group, there was no association between histological abnormalities (excessive cells in layer I, absence of layer IV, presence of immature neurones and excessive neurones in the white matter) and the presence of febrile convulsions, age of seizure onset, seizure frequency, presence of MRI abnormalities or surgical outcome (χ^2 analysis, $P > 0.1$ in all cases).

Cytoarchitectural dysplasia (CD)

Neuropathological characteristics

In the six (11% of total) patients with CD, in addition to laminar disruption of the normal cortical layering (Fig. 3C and C′), giant neurones were found throughout the cortex, mainly in the upper half of the cortical grey matter, but not

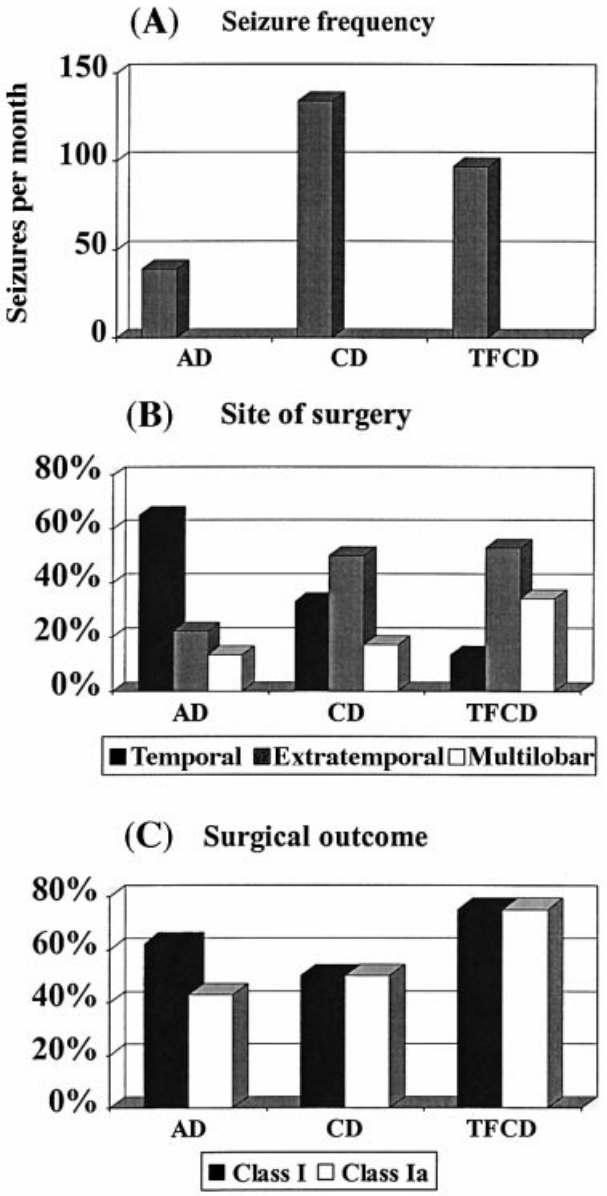

Fig. 4 (**A**) Histogram showing the mean seizure frequency per month in the three subtypes of focal cortical dysplasia. (**B**) Histogram showing the distribution of the site of surgery in the three subgroups. While most AD patients underwent temporal lobe surgery, extratemporal surgery was more common in CD and in TFCD. (**C**) Although 62% of AD patients had class I outcomes, only 43% are seizure-free. TFCD patients had the best outcome (75% seizure-free, class Ia).

clustered in any particular layer. These cells generally had a pyramidal shape (Fig. 1B), but were larger than layer V pyramidal neurones. Immunostaining showed that these giant neurones (well revealed with Bielschowsky silver impregnation) had abundant neurofilaments in their cytoplasm and proximal dendritic arborization (Fig. 1C). However, the cells maintained their morphology and hence were not dysmorphic. Although cortical layering seemed more disrupted than in cases classified as AD, the extent and distribution of gliosis were similar.

Table 4 *Comparison between MRI and histological findings in the 31 patients diagnosed with AD*

MRI diagnosis	*n*	Histopathology	
		FCD	FCD + HS
FCD + HS	14	–	14
FCD	5	3	2
HS	2	1	1
Normal	10	8	2
Total	31	12	19

Electroclinical data

The three males and three females in this group underwent surgery at a mean age of 20 years (range 4–42 years, SD 16); mean age of epilepsy onset was 6 years (range 0–26 years, SD 10) and mean duration of epilepsy was 14 years (range 1–42 years, SD 16). Seizure frequency (Fig. 4A) was very high at 134 per month (range 1–300, SD 33). In four patients, the neurological examination was abnormal and included mental retardation. Two patients received VEEG only; in the remaining four, SEEG investigation was used to define the surgical targets better. Four patients had no subjective ictal manifestations and one experienced secondary generalized seizures. Status epilepticus was not reported, but repetitive seizures were present in 50% of the patients.

MRI findings

Anatomical lesions were identified in three patients (50%) with unremarkable MRI in the other three. Among the former, two had abnormalities similar to those observed in the TFCD patients; in the remaining case, focal hypoplasia of the fronto-temporal poles was identified, without significant signal alterations.

Surgery and outcome

The operation was on a temporal lobe in two patients, a frontal lobe in three (50%) and was bilobar, including a temporal lobe, in one (Fig. 4B). At least 1 year of follow-up is available in four patients: two are in class Ia, one in class III and one in class IV (Fig. 4C).

Taylor-type cortical dysplasia (TFCD)

Neuropathological characteristics

In addition to cortical laminar disorganization, giant neurones, dysmorphic neurones and ectopic neurones were observed in all 15 TFCD cases; balloon cells were observed in all but two cases. The latter were classified as TFCD based on the presence of the other anomalous cells, in accord with the original criteria of Taylor *et al*. (1971).

The neuropathological appearance of cortical tissue from these patients clearly differed from that of the other two

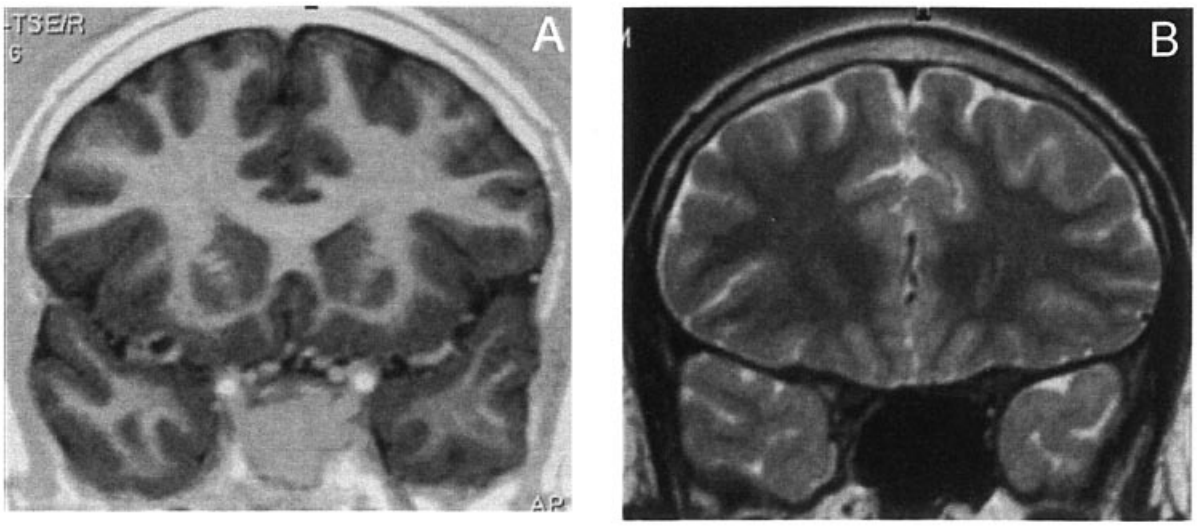

Fig. 5 Coronal T_1-weighted IR (**A**) and coronal T_2-weighted TSE (**B**) images from a patient with AD, showing a decreased signal in the white matter of the left temporal lobe (**A**), and a hypoplastic temporal pole with local reduction of white matter (**B**).

groups. Laminar disorganization was more prominent (Fig. 3D) and the morphology of layer I differed from that observed in the other groups. In particular, the molecular layer was particularly thick but had reduced or normal cellularity. In most cases, cortical layering was absent or barely discernible, and the border between grey and white matter was indistinct due to the presence of numerous cells interspersed between the fibres of the white matter. Giant neurones and dysmorphic neurones were present throughout the cortex, with pyramidal-shaped giant cells more common in the upper half of the grey matter particularly just below layer I. In contrast, dysmorphic and giant oval-shaped neurones were more prominent in the lower part of the grey matter and at the border between grey and white matter. Giant neurones and dysmorphic neurones always immunostained intensely for neurofilaments and all took up Bielschowsky's silver stain (Fig. 1D and E). Balloon cells, evident mainly at the grey–white matter junction (Fig. 1F), were also dispersed within the white matter, and in some patients were also present in the grey matter. The extent of gliosis appeared unrelated to the extent of cortical disruption, or to the numbers of giant neurones, dysmorphic neurones or balloon cells present.

Electroclinical data

For the eight males and seven females of this group, mean age at surgery was 19 years (range 2–35 years, SD 11), mean age of epilepsy onset was 6 years (range 0–22 years, SD 7) and mean disease duration was 13 years (range 2–27 years, SD 8). Febrile convulsions were reported in two patients; however, hippocampal sclerosis was not found on histological examination. Seizure frequency (Fig. 4A) was 97 per month (range 1–400, SD 100). Intellectual impairment was present in five patients (in one associated with mild contralateral hemiparesis) and there was language deficit in another.

Twelve patients (80%) underwent both VEEG and SEEG, while three received VEEG only. The interictal intralesional electrical activity recorded by the intracerebral electrodes was in most cases characterized by total absence of background activity and a distinctive pattern of repetitive, high amplitude, fast spikes (Fig. 6), followed by high amplitude slow waves, interspersed by relatively flat periods. During drowsiness and slow sleep, fast spikes became more prominent, increased in frequency and tended to spread into contiguous non-lesional areas. During REM (rapid eye movement) sleep, there was a marked decrease in electrical abnormalities.

The ictal pattern, sometimes preceded by 2–3 s of fragmentation of the typical rhythmic interictal activity, was characterized by the usual low voltage fast activity. Such features were never observed in patients with AD or CD.

Subjective experience of seizures was reported in 10 patients (66%). Secondary generalization was reported in two (13%) patients only. Status epilepticus had occurred in two (13%) patients. Repeated and prolonged seizures were present in six (40%).

MRI findings

Nine (60%) of our TFCD patients had focal thickening of the cortex with blurring of the grey–white matter junction in association with increased signal intensity in the subcortical white matter on T_2-weighted images (Fig. 7), sometimes (three cases) extending to the ventricle, and a decreased signal in the white matter on T_1-weighted images. These findings are those reported as suggestive for TFCD by Bronen *et al*. (1997). The MRI lesions in these nine patients were always included within the epileptogenic zone indicated by

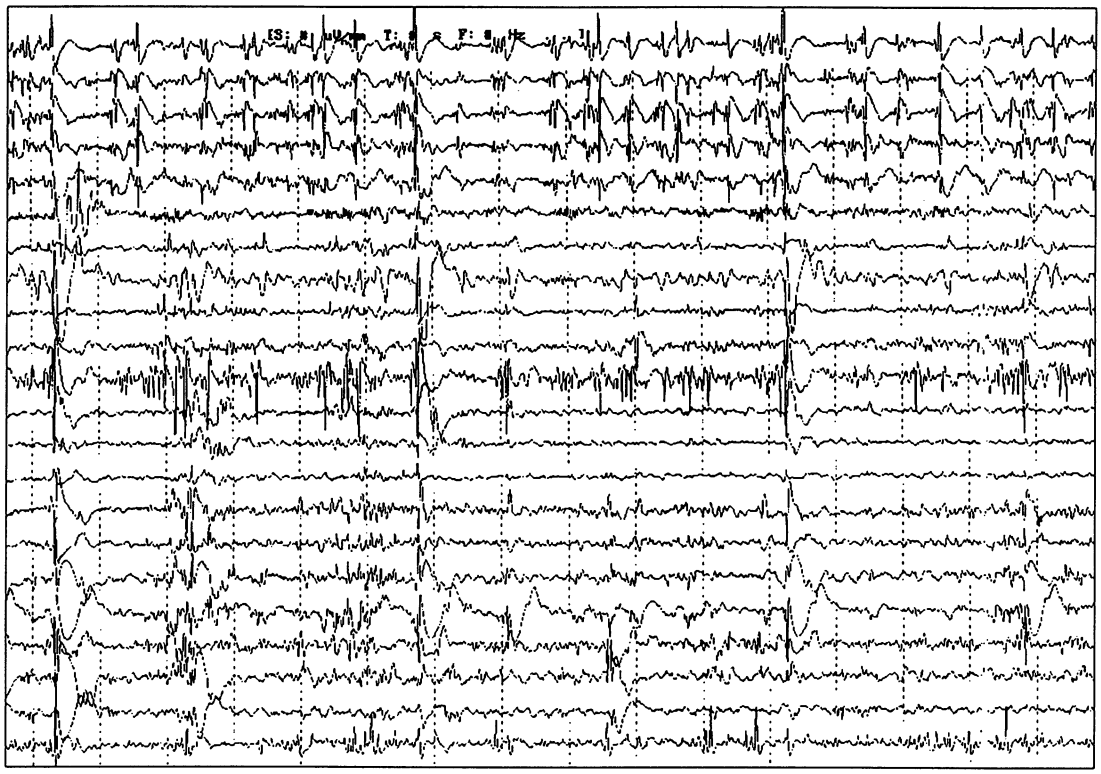

Fig. 6 Intralesional contacts (upper five traces) from a single electrode in a patient with TFCD. Awake interictal activity is characterized by complete disruption of background activity, high frequency fast spikes and polyspikes, occasionally of high amplitude, interspersed by flattenings and fast lower amplitude activity.

the electroclinical data. In another TFCD case, there was focal hypoplasia with hippocampal sclerosis, associated with mildly increased signal in T_2-weighted FLAIR sequences, similar to the situation in AD patients. In the remaining five cases (33%), the MRI findings were unremarkable.

Surgery and outcome

Frontal corticectomy was performed in six patients (40%), temporal corticectomy in two (13%), and central and occipital corticectomies in one patient each. A bilobar intervention not including the temporal lobe was performed in one patient, while multilobar surgery was given to four patients (27%) and included a temporal lobe intervention in three (Fig. 4B). Twelve patients have a follow-up of >1 year: nine (75%) are class Ia (Fig. 4C), two class III and one class IV. In the three patients who are not seizure-free, the epileptogenic zone was not completely excised as it involved motor areas, language areas or both.

Discussion

Some forms of MCD have been clearly defined. This is not the case for FCDs, which are variously grouped, using disparate terminology based on a hotchpotch of genetic, clinical, imaging, histological and embryological criteria (Kuzniecky *et al*., 1991; Palmini *et al*., 1994; Mischel *et al*., 1995; Barkovich *et al*., 1996; Gambardella *et al*., 1996; Cotter *et al*., 1999).

Mischel *et al*. (1995) proposed a grading system for cortical dysplasia that attempted to correlate the time of the disruption with the severity of the disease. These authors identified nine microscopic abnormalities which they considered specific and easily recognizable, including polymicrogyria which is now recognized as a distinct form no longer classified among the FCDs. Another of their grading criteria was increased neuronal cellularity in the cortical molecular layer; however, in routine neuropathological examinations, this is usually indistinguishable from other criteria of Mischel grading, specifically remnants of the subpial granular layer and marginal glio-neural heterotopia.

In our series, increased layer I cellularity was found in 45% of patients in the AD group and never in TFCD. Furthermore, all patients with layer I alterations also presented other histopathological characteristics of AD and never presented aspects characteristic of CD, much less TFCD; thus, layer I alterations are not pathognomic for FCD. In fact, histological alterations of layer I were first described by Meencke (1985) in patients with generalized epilepsy, and given the name microdysgenesis. Subsequently, other forms of cortical dysplasia (affecting layers other than layer I) were also termed microdysgenesis. Later still, the term assumed an even wider significance, being used to refer to cortical dysplasia in general. The term microdysgenesis has therefore

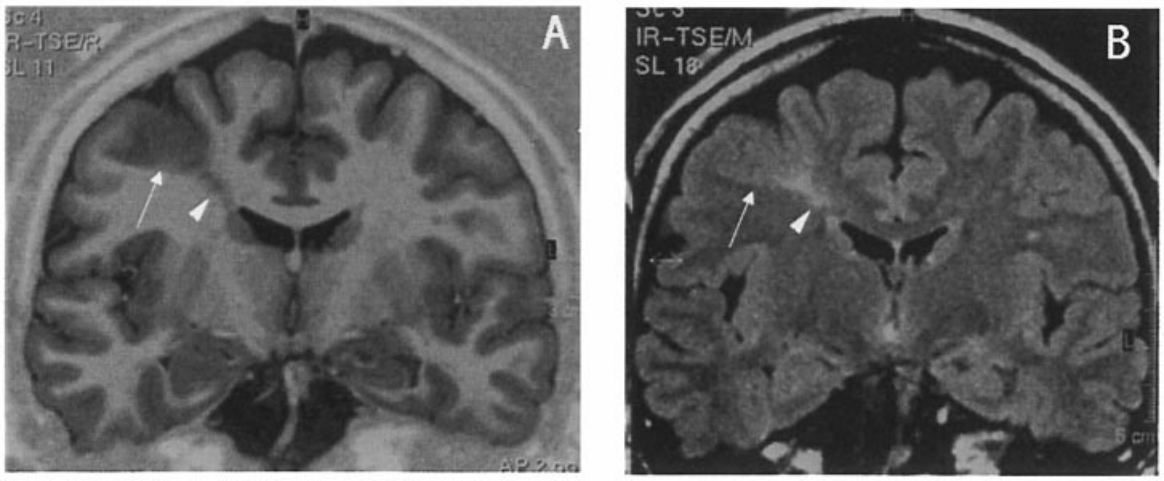

Fig. 7 Coronal T_1-weighted IR TSE (**A**) and T_2-weighted FLAIR (**B**) images in a patient with TCFD, revealing abnormal thickening of the right frontal cortex, blurring of the grey–white matter junction (arrow) and hyperintensity (**B**) of subcortical white matter, tapering to the ventricle (arrowhead).

become seriously misleading and is avoided in this classification.

As in the original paper by Taylor *et al*. (1971), most of the cortex samples from the patients we classified as TFCD were characterized by cortical laminar disorganization, cytoskeletal abnormalities and balloon cells. Only in two patients were balloon cells not found; however, the presence of the other histological characteristics permitted classification as TFCD. Patients in this category also differed from the others in terms of clinical characteristics, SEEG, MRI findings and post-surgical outcome. Thus, seizure frequency in TFCD was significantly greater ($P = 0.042$) than in AD (Fig. 4A), and the SEEG had a distinctive interictal pattern characterized by complete disruption of background activity, high frequency fast spikes and polyspikes, occasionally of high amplitude, interspersed by flattenings and fast lower amplitude activity (Fig. 6) (see also Tassi *et al*., 2000). In most TFCD patients, MRI revealed abnormal thickening of cortex, blurring of the grey–white matter junction and hyperintensity of subcortical white matter that were rarely observed in AD patients.

TFCD seems to be due to derangement of migratory events coupled with differentiation abnormalities in both neuronal and glial lineages (Prayson and Estes, 1995; Crino *et al*., 1997; Garbelli *et al*., 1999; Vinters, 2000; Taylor *et al*., 2001). The good postoperative outcome in this group (75% in class Ia) suggests that, although severely deranged, the involved cortical areas were circumscribed. Thus, although the epileptogenic zone frequently extended beyond the lesion identified on MRI, SEEG allowed precise definition of its boundaries and served as a reliable guide to excision (Tassi *et al*., 2001).

We defined our AD category by the presence of cortical laminar disorganization without cytoskeletal abnormalities or balloon cells. Ectopic neurones in white matter, increased layer I cellularity, absence of layer IV and undifferentiated neurones scattered in the grey matter were also found in some AD patients. However, no significant correlations were found between the presence or absence of these abnormalities and the electroclinical data, MRI findings or surgical outcome in this group, and no coherent subgroups were identified within the AD group.

Importantly, the electroclinical findings, imaging data and surgical outcome in AD differed from those in CD and TFCD. Seizure frequency was significantly lower ($P = 0.04$) in AD than TFCD, while the SEEG of AD and CD patients did not show the distinctive features observed in TFCD. The most distinctive MRI findings in AD were focal hypoplasia with reduced white matter core, in contrast to the signal alterations found in TFCD. Furthermore, AD usually was found in the temporal lobe, whereas in TFCD the lesions were mainly extratemporal. Nevertheless, the differences in age of onset, duration of seizure and MRI features between AD and TFCD were not statistically significant.

In the present study, the co-presence of dysplasia with hippocampal sclerosis (dual pathology) was lower than reported by Ho *et al*. (1998) and Kuzniecky *et al*. (1999). In their series, dual pathology was reported in 87–90%, with high proportions (57% in both series) presenting bilateral hippocampal or amygdala abnormalities. This difference is probably due to the fact that both of the above cited studies used a quantitative MRI-based method for the volumetric analysis of mesial temporal lobe structures; this technique can detect morphological alterations not revealed by the routine MRI used in the present study.

The frequent co-presence of ipsilateral hippocampal sclerosis and FCD, also reported by other authors (Raymond *et al*., 1994; Mitchell *et al*., 1999; Takahashi *et al*., 2000), lends credence to the suggestion of Falconer *et al*. (1964) that hippocampal sclerosis often is part of a more diffuse abnormality of the temporal lobe and is not due simply to febrile convulsions. Recent evidence from animal studies suggests that hippocampal sclerosis may be an

epiphenomenon arising from increased susceptibility to hyperthermia-induced seizures as a result of the presence of neuronal migration disorders in the temporal lobe (Germano *et al*., 1996; Fisher *et al*., 1998)

With regard to surgical outcome, a review of the literature published since 1971 (Sisodiya, 2000) indicated that only 38–40% of patients operated on for FCD achieve Engel class I one or more years after the operation. Outcomes in our AD patients (62% class I after at least a year of follow-up) were better than the average suggested by this review, while outcomes in the TFCD group were better still (75%). Although this difference was not significant (probably because few patients in either group had at least a year of follow-up), it does suggest that in AD patients the morphological abnormalities, epileptogenic zone or both were more extensive than indicated by the preoperative investigations.

In the absence of general agreement on FCD classification, findings from different groups are difficult to compare. However, recent data indicate that the best results are obtained if SEEG investigations guide the surgery (Chassoux *et al*., 2000; Tassi *et al*., 2001) rather than other methods such as subdural grids, electrocorticography or depth electrodes (Palmini *et al*., 1995, 1996; Olivier *et al*., 1996; Polkey, 1996; Yagishita *et al*., 1997). Note also that our study and that of Chassoux *et al*. (2000) gave surgical outcome as the proportion of seizure-free patients (54 and 43%, respectively, in Engel class Ia). Other series, however, gave the outcome in terms of the proportion in Engel class I, thus including patients still presenting some seizures.

Among the invasive presurgical procedures available, only SEEG allows mesial structures and intra-sulcal areas to be investigated. However, the utility of SEEG is limited because only a small volume is explored by the intracerebral electrodes, and the procedure is time consuming and expensive (Chassoux *et al*., 2000; Tassi *et al*., 2001).

Recent studies on the intrinsic organization of the dysplastic tissue in entities corresponding to AD and TFCD have shown that the GABAergic circuitry differs (Marco *et al*., 1996; Spreafico *et al*., 2000; Crino *et al*., 2001), indicating that the epileptogenic mechanisms in these two forms of dysplasia may differ fundamentally. This conclusion is reinforced further by the finding of the present study that the overall neuropathological, electroclinical and neuroimaging features of AD and TFCD are distinct, with a trend to a better prognosis in TFCD.

Our patients with CD had conspicuous cortical laminar disorganization associated with giant neurones. Dysmorphic neurones and balloon cells were absent. Thus the histopathological characteristics of this group were intermediate between those of AD and TFCD. However, there were too few patients in this group to provide a definitive or representative picture. Clinical features (age of seizure onset and seizure frequency) were similar to those of the TFCD group, while MRI signal alterations were not sufficiently different from those of the other groups to permit clear discrimination. However, EEG (or SEEG) characteristics did differ markedly from those of the TFCD group (but not the AD group), while surgical outcome was better than in the AD group. We expect that as more patients are examined, a more precise neuropathological definition of the CD group will emerge.

It is difficult to assess the utility of modern MRI in identifying FCD in patients for epilepsy surgery, mainly because reported series refer to patients selected for the presence of an MRI-visible lesion (Palmini *et al*., 1995, 1996; Olivier *et al*., 1996; Polkey, 1996). Even with high resolution MRI, cortical dysplasia often can be detected only by post-surgical histological examination (Yagishita *et al*., 1997; Ying *et al*., 1998; Spreafico *et al*., 1998; Tassi *et al*., 2001), and it has been estimated that ~25% of cases with refractory epilepsies have normal MRI (Li *et al*., 1995; Sisodiya, 2000).

Only seven of the 28 FCD patients in the series of Chassoux *et al*. (2000) received MRI. In one of these, nothing remarkable was found, while in three the histopathological abnormalities were more extensive than the MRI signal alterations. In the 13 cases presented by Tassi *et al*. (2001), 23% had normal MRI even though all had TFCD with balloon cells.

In our series, 34% had unremarkable high resolution MRI, a higher proportion than generally reported, and in most cases it was the VEEG or SEEG findings that provided information for defining the epileptogenic zone.

Even when MRI did reveal a lesion, the boundaries were not always well defined and were thus an imperfect guide to surgical resection. Furthermore, although in all patients in whom MRI revealed a lesion, this was involved in seizure onset as revealed by SEEG, in most cases the epileptogenic zone extended beyond the MRI lesion. This justifies our use of invasive SEEG and also our surgical approach which was to combine lesionectomy with corticetomy. The results in our TFCD and AD patients compared with those in other reported series seem to vindicate this approach (for references see Sisodiya, 2000).

While the presence of unresectable areas within the lesion or the epileptogenic zone limited the utility of surgical resection, the poor outcomes in some of our patients, particularly in the AD group, require comment. One possible explanation is that the anatomical or functional alteration extended beyond the lesion revealed by MRI or SEEG and was not removed. Another possibility is that, following surgical ablation of the leading or at least electroclinically evident epileptogenic zone, another zone that previously was silent or covered by the leading one could become evident or 'switched on.'

Acknowledgements

We wish to thank Ms Marina Denegri for help in preparing this manuscript, and Don Ward for help with the English. The research reported here was supported by the Italian Ministry of Health and by the Mariani Foundation. We dedicate this work to Claudio Munari.

References

Arai N, Oda M. Surgical neuropathology of intractable epilepsy. Epilepsia 1997; 38 Suppl 6: 11–6.

Barkovich AJ, Kuzniecky RI, Dobyns WB, Jackson GD, Becker LE, Evrard P. A classification scheme for malformations of cortical development. [Review]. Neuropediatrics 1996; 27: 59–63.

Barkovich AJ, Kuzniecky RI, Dobyns WB. Radiologic classification of malformations of cortical development. [Review]. Curr Opin Neurol 2001; 14: 145–9.

Bronen RA, Vives KP, Kim JH, Fulbright RK, Spencer SS, Spencer DD. Focal cortical dysplasia of Taylor, balloon cell subtype: MR differentiation from low-grade tumors. AJNR Am J Neuroradiol 1997; 18: 1141–51.

Chassoux F, Devaux B, Landré E, Turak B, Nataf F, Varlet P, et al. Stereoelectroencephalography in focal cortical dysplasia. A 3D approach to delineating the dysplastic cortex. Brain 2000; 123: 1733–51.

Cotter DR, Honavar M, Everall I. Focal cortical dysplasia: a neuropathological and developmental perspective. [Review]. Epilepsy Res 1999; 36: 155–64.

Crino PB, Trojanowski JQ, Eberwine J. Internexin, MAP1B and nestin in cortical dysplasia as markers of developmental maturity. Acta Neuropathol (Berl) 1997; 93: 619–27.

Crino PB, Duhaime AC, Baltuch G, White R. Differential expression of glutamate and GABA-A receptor subunit mRNA in cortical dysplasia. Neurology 2001; 56: 906–13.

Engel J Jr. Outcome with respect to epileptic seizures. In: Engel J Jr, editor. Surgical treatment of the epilepsies. New York: Raven Press; 1987. p. 553–71.

Falconer MA, Serafetinides EA, Corsellis JA. Etiology and pathogenesis of temporal lobe epilepsy. Arch Neurol 1964; 10: 233–48.

Fisher PD, Sperber EF, Moshé SL. Hippocampal sclerosis revisited. [Review]. Brain Dev 1998; 20: 563–73.

Gambardella A, Palmini A, Andermann F, Dubeau F, Da Costa JC, Quesney LF, et al. Usefulness of focal rhythmic discharges on scalp EEG of patients with focal cortical dysplasia and intractable epilepsy. Electroencephalogr Clin Neurophysiol 1996; 98: 243–9.

Garbelli R, Munari C, De Biasi S, Vitellaro-Zuccarello L, Galli C, Bramerio M, et al. Taylor's cortical dysplasia: a confocal and ultrastructural immunohistochemical study. Brain Pathol 1999; 9: 445–61.

Garbelli R, Frassoni C, Ferrario A, Tassi L, Bramerio M, Spreafico R. Cajal–Retzius cell density as marker of type of focal cortical dysplasia. Neuroreport 2001; 12: 2767–71.

Germano IM, Zhang YF, Sperber EF, Moshé SL. Neuronal migration disorders increase susceptibility to hyperthermia-induced seizures in developing rats. Epilepsia 1996; 37: 902–10.

Gomez-Anson B, Thom M, Moran N, Stevens J, Scaravilli F. Imaging and radiological–pathological correlation in histologically proven cases of focal cortical dysplasia and other glial and neuronoglial malformative lesions in adults. Neuroradiology 2000; 42: 157–67.

Hardiman O, Burke T, Phillips J, Murphy S, O'Moore B, Staunton H, et al. Microdysgenesis in resected temporal neocortex: incidence and clinical significance in focal epilepsy. Neurology 1988; 38: 1041–7.

Ho SS, Kuzniecky RI, Gilliam F, Faught E, Morawetz R. Temporal lobe developmental malformations and epilepsy. Dual pathology and bilateral hippocampal abnormalities. Neurology 1998; 50: 748–54.

Janota I, Polkey CE. Cortical dysplasia in epilepsy. In: Pedley TA, Meldrum BS, editors. Recent advances in epilepsy, No. 5. Edinburgh: Churchill Livingstone; 1992. p. 37–49.

Kuzniecky RI, Barkovich AJ. Pathogenesis and pathology of focal malformations of cortical development and epilepsy. [Review]. J Clin Neurophysiol 1996; 13: 468–80.

Kuzniecky R, Garcia JH, Faught E, Morawetz RB. Cortical dysplasia in temporal lobe epilepsy: magnetic resonance imaging correlations. Ann Neurol 1991; 29: 293–8.

Kuzniecky R, Murro A, King D, Morawetz R, Smith J, Powers R, et al. Magnetic resonance imaging in childhood intractable partial epilepsies: pathologic correlations. Neurology 1993; 43: 681–7.

Kuzniecky R, Ho SS, Martin R, Faught E, Morawetz R, Palmer C, et al. Temporal lobe developmental malformations and hippocampal sclerosis. Epilepsy surgical outcome. Neurology 1999; 52: 479–84.

Li LM, Fish DR, Sisodiya SM, Shorvon SD, Alsanjari N, Stevens JM. High resolution magnetic resonance imaging in adults with partial or secondary generalised epilepsy attending a tertiary referral unit. J Neurol Neurosurg Psychiatry 1995; 59: 384–7.

Marco P, Sola RG, Pulido P, Alijarde MT, Sanchez A, Ramon y Cajal S, et al. Inhibitory neurons in the human epileptogenic temporal neocortex. Brain 1996; 119: 1327–47.

Meencke HJ. Neuron density in the molecular layer of the frontal cortex in primary generalized epilepsy. Epilepsia 1985; 26: 450–4.

Meyer G, Wahle P, Castaneyra-Perdomo A, Ferres-Torres R. Morphology of neurons in the white matter of the adult human neocortex. Exp Brain Res 1992; 88: 204–12.

Mischel PS, Nguyen LP, Vinters HV. Cerebral cortical dysplasia associated with pediatric epilepsy. Review of neuropathologic features and proposal for a grading system. [Review]. J Neuropathol Exp Neurol 1995; 54: 137–53.

Mitchell LA, Jackson GD, Kalnins RM, Saling MM, Fitt GJ, Ashpole RD, et al. Anterior temporal abnormality in temporal lobe epilepsy. A quantitative MRI and histopathologic study. Neurology 1999; 52: 327–36.

Munari C, Bancaud J. The role of stereo-EEG in the evaluation of partial epileptic seizures. In: Morselli PL, Porter RJ, editors. The epilepsies. London: Butterworths; 1985. p. 267–306.

Munari C, Hoffmann D, Francione S, Kahane P, Tassi L, Lo Russo G, et al. Stereo-electroencephalography methodology: advantages and limits. Acta Neurol Scand 1994; Suppl 152: 56–67.

Olivier A, Andermann F, Palmini A, Robitaille Y. Surgical treatment of the cortical dysplasias. In: Guerrini R, Andermann F, Canapicchi R, Roger J, Zifkin BG, Pfanner P, editors. Dysplasias of

cerebral cortex and epilepsy. Philadelphia: Lippincott-Raven; 1996. p. 351–66.

Palmini A, Gambardella A, Andermann F, Dubeau F, da Costa JC, Olivier A, et al. Operative strategies for patients with cortical dysplastic lesions and intractable epilepsy. [Review]. Epilepsia 1994; 35 Suppl 6: S57–71.

Palmini A, Gambardella A, Andermann F, Dubeau F, da Costa JC, Olivier A, et al. Intrinsic epileptogenicity of human dysplastic cortex as suggested by corticography and surgical results. Ann Neurol 1995; 37: 476–87.

Palmini A, Gambardella A, Andermann F, Olivier A, da Costa JC, Tampieri D, et al. Outcome of surgical treatment in patients with localized cortical dysplasia and intractable epilepsy. In: Guerrini R, Andermann F, Canapicchi R, Roger J, Zifkin BG, Pfanner P, editors. Dysplasias of cerebral cortex and epilepsy. Philadelphia: Lippincott-Raven; 1996. p. 367–74.

Polkey CE. Cortical dysplasia: resective surgery in children. In: Guerrini R, Andermann F, Canapicchi R, Roger J, Zifkin BG, Pfanner P, editors. Dysplasias of cerebral cortex and epilepsy. Philadelphia: Lippincott-Raven; 1996. p. 435–9.

Prayson RA, Estes ML. Cortical dysplasia: a histopathologic study of 52 cases of partial lobectomy in patients with epilepsy. Hum Pathol 1995; 26: 493–500.

Raymond AA, Fish DR, Stevens JM, Cook MJ, Sisodiya SM, Shorvon SD. Association of hippocampal sclerosis with cortical dysgenesis in patients with epilepsy. Neurology 1994; 44: 1841–5.

Raymond AA, Fish DR, Sisodiya SM, Alsanjari N, Stevens JM, Shorvon SD. Abnormalities of gyration, heterotopias, tuberous sclerosis, focal cortical dysplasia, microdysgenesis, dysembrioplastic neuroepithelial tumour and dysgenesis of the archicortex in epilepsy. Clinical, EEG and neuroimaging features in 100 adult patients. [Review]. Brain 1995; 118: 629–60.

Semah F, Picot MC, Adam C, Broglin D, Arzimanoglou A, Bazin B, et al. Is the underlying cause of epilepsy a major prognostic factor for recurrence? Neurology 1998; 51: 1256–62.

Shorvon S. MRI of cortical dysgenesis. Epilepsia 1997; 38 Suppl 10: 13–8.

Sisodiya SM. Surgery for malformations of cortical development causing epilepsy. [Review]. Brain 2000; 123: 1075–91.

Spreafico R, Battaglia G, Arcelli P, Andermann F, Dubeau F, Palmini A, et al. Cortical dysplasia: an immunocytochemical study of three patients. Neurology 1998; 50: 27–36.

Spreafico R, Tassi L, Colombo N, Bramerio M, Galli C, Garbelli R, et al. Inhibitory circuits in human dysplastic tissue. Epilepsia 2000; 41 Suppl 6: S168–73.

Takahashi C, Berg MJ, Takase Y, Powers JM, Pilcher WH, Numaguchi Y. MR findings of heterotopic neurons in the medial temporal lobe white matter in epileptic patients [abstract]. Radiology 2000; 217 (P): 182–3.

Talairach J, Bancaud J. Lesions, 'irritative' zone and epileptogenic focus. Confin Neurol 1966; 27: 91–4.

Tassi L, Spreafico R, Bramerio M, Citterio A, Mai R, Cossu M, Castana L, Lo Russo G, Munari C. Stereo-EEG analysis in Taylor's focal cortical dysplasia (TFCD) [abstract]. Epilepsia 2000; 41 Suppl Florence: 52–3.

Tassi L, Pasquier B, Minotti L, Garbelli R, Kahane P, Benabid AL, et al. Cortical dysplasia: electroclinical, imaging, and neuropathologic study of 13 patients. Epilepsia 2001; 42: 1112–23.

Taylor DC, Falconer MA, Bruton CJ, Corsellis JA. Focal dysplasia of the cerebral cortex in epilepsy. J Neurol Neurosurg Psychiatry 1971; 34: 369–87.

Taylor JP, Sater R, French J, Baltuch G, Crino PB. Transcription of intermediate filament genes is enhanced in focal cortical dysplasia. Acta Neuropathol (Berl) 2001; 102: 141–8.

Vinters HV. Surgical pathologic findings in extratemporal-based intractable epilepsy. A study of 133 consecutive cases [letter]. Arch Pathol Lab Med 2000; 124: 1111–2.

Wolf HK, Campos MG, Zentner J, Hufnagel A, Schramm J, Elger CE, et al. Surgical pathology of temporal lobe epilepsy. Experience with 216 cases. J Neuropathol Exp Neurol 1993; 52: 499–506.

Wyllie E, Comair YG, Kotagal P, Bulacio J, Bingaman W, Ruggieri P. Seizure outcome after epilepsy surgery in children and adolescents. Ann Neurol 1998; 44: 740–8.

Yagishita A, Arai N, Maehara T, Shimizu H, Tokumaru AM, Oda M. Focal cortical dysplasia: appearance on MR images. Radiology 1997; 203: 553–9.

Ying Z, Babb TL, Comair YG, Bingaman W, Bushey M, Touhalisky K. Induced expression of NMDAR2 proteins and differential expression of NMDAR1 splice variants in dysplastic neurons of human epileptic neocortex. J Neuropathol Exp Neurol 1998; 57: 47–62.

Received July 19, 2001. Revised January 9, 2002.
Accepted February 25, 2002