

Gradual loss of myelin and formation of an astrocytic scar during Wallerian degeneration in the human spinal cord

A. Buss,¹ G. A. Brook,¹ B. Kakulas,² D. Martin,^{3,4,5} R. Franzen,⁵ J. Schoenen,^{4,5} J. Noth¹ and A. B. Schmitt¹

¹Department of Neurology, Aachen University Medical School, Pauwelsstrasse 30, Germany, ²Centre for Neuromuscular and Neurological Disorders, University of Western Australia, Australia, and ³Department of Neurosurgery, Sart Tilman Hospital, ⁴Department of Neurology and Neuropathology and ⁵Center for Cellular and Molecular Neuroscience, University of Liège, Liège, Belgium

Correspondence to: Armin Buss, Department of Neurology, Aachen University Hospital, Pauwelsstrasse 30, 52074 Aachen, Germany
E-mail: arminbuss@hotmail.com

Summary

Axons undergo Wallerian degeneration distal to a point of injury. Experimental investigations have documented many of the cellular and molecular events that underlie this behaviour. Since relatively little is known about such events in human CNS pathologies and current experimental intervention strategies indicate the possibility of significant axon regeneration along the original degenerated fibre tract, we performed an immunohistochemical investigation of the dynamics of Wallerian degeneration in *post mortem* spinal cords of patients who died 2 days to 30 years after either cerebral infarction or traumatic spinal cord injury. Neurofilament (NF) staining demonstrated a spatio-temporal pattern of axonal loss within degenerating descending nerve fibre tracts that could be detected close to the lesion as early as 12 days after injury and progressed to an almost complete loss of NF immunoreactivity at survival times of 1 year and longer. Immunohistochemistry for glial fibrillary acidic protein revealed a late astrocytic reac-

tion starting at 4 months after injury in the degenerating tracts, leading to the long-term deposition of a dense astrocytic scar. These events were accompanied by the gradual reduction of myelin basic protein in affected nerve fibre tracts, leading to almost complete loss by 3 years after injury. Since the extracellular matrix molecule chondroitin sulphate proteoglycan (CSPG) is known to be strongly inhibitory for axonal regeneration and to be a major component of gliotic scar tissues, we investigated the possible deposition of CSPG within the degenerating nerve fibre tracts. Apart from a local up-regulation close to the lesion site, our results show no enhanced CSPG expression within degenerated tracts at any survival time. This suggests that despite the apparent lack of CSPG in Wallerian degeneration, the slow reduction of CNS myelin and the long-term deposition of a dense astrocytic scar may present an environment that is non-supportive for axon regrowth.

Keywords: astrocyte; CSPG; GFAP; myelin; Wallerian degeneration

Abbreviations: CSPG = chondroitin sulphate proteoglycan; CST = corticospinal tract; GFAP = glial fibrillary acidic protein; MBP = myelin basic protein; NF = neurofilament

Introduction

Degeneration of the axon distal to a point of injury is a common feature. This process was first described in 1850 by Waller in degenerating frog peripheral nerves, and was subsequently termed Wallerian degeneration (Waller, 1850). The pattern of cellular and molecular events in Wallerian degeneration in both the PNS and the CNS is highly

stereotyped and has been investigated in great detail in experimental animals. It comprises the breakdown and degradation of the lesioned axons and their myelin sheaths (Lubinska, 1977; Franson and Ronnevi, 1984; George and Griffin, 1994), accompanied by the apoptotic death of glial cells, mainly oligodendrocytes in the degenerating CNS

(Crowe *et al.*, 1997; Shuman *et al.*, 1997). In the PNS, macrophages from the peripheral blood and local Schwann cells are responsible for the phagocytosis of PNS axons and myelin sheaths (Bruck, 1997), whereas in the CNS, resident microglia are the main phagocytosing cell population (Giulian *et al.*, 1994; Kreutzberg, 1996; Schmitt *et al.*, 1998).

In the lesioned PNS, Wallerian degeneration may be followed by successful axonal regeneration and functional recovery. However, in the lesioned adult mammalian CNS, the phase of transient axonal sprouting is not followed by any functional regeneration (Schwab and Bartholdi, 1996). This lack of significant axonal regeneration in the lesioned CNS, in particular the lesioned spinal cord, is due to a number of factors, including the presence of a glial environment that is hostile to axonal regrowth. Myelin-associated proteins, extracellular matrix proteoglycans and barrier formation by reactive astrocytes are believed to play significant roles in preventing axon regeneration in the CNS (Schafer *et al.*, 1996; Schwab and Bartholdi, 1996; Bradbury *et al.*, 2002). Despite the abundance of experimental data concerning the cellular and molecular events that take place in the lesioned CNS, there is a relative paucity of correlative investigations in human tissues; therefore, the relevance of much of the experimental data to what actually takes place in the clinical situation remains uncertain.

A number of CNS myelin-associated proteins have been identified that contribute to the inhibition of axon regrowth after injury, these include Nogo-A, myelin-associated glycoprotein and oligodendrocyte myelin glycoprotein (Liu *et al.*, 2002; Wang *et al.*, 2002; Simonen *et al.*, 2003). These molecules have been reported to mediate their effects by binding to the Nogo 66 receptor; however, the identity of a specific receptor for the 200 amino acid inhibitory domain of Nogo-A remains unknown.

Astroglia are also known to play a key role in the tissue response to CNS injury (Hatten *et al.*, 1991; Fawcett and Asher, 1999). These cells are involved in the uptake of potentially harmful substances, such as excitatory amino acids and potassium, and also in the release of certain cytokines (Norenberg, 1994, 1996). Experimental investigations have demonstrated a heterogeneous reaction pattern of astrocytes depending on the proximity to and the type of injury. Lesions involving direct tissue damage and destruction of the blood–brain barrier lead to an anisomorphic astrogliosis. At the site of injury, the cells proliferate and hypertrophy, and their processes tend to assume an irregular orientation to fill the cavities left by the trauma, finally leading to a dense scar. In conditions such as neurodegenerative diseases or in areas of the CNS remote from the primary lesion site, such as in Wallerian degeneration, astrocytes display an isomorphic reaction. The cells hypertrophy without proliferation and the processes tend to leave the extracellular framework intact. Accordingly, there is no formation of a dense, permanent scar (Reier *et al.*, 1983; Feraud-Espinosa *et al.*, 1993; Ridet *et al.*, 1997). In contrast to the experimental data, some unexpected findings have been

described in *post mortem* human tissues. A detailed investigation of penetrating spinal cord injuries has revealed a surprisingly slow astrogliosis taking place around the lesion site. After long survival times (up to 23 years post-injury) the network of astrocytic processes in the degenerated white matter tracts were reported to show a decrease in glial fibrillary acidic protein (GFAP) staining (Bunge *et al.*, 1997; Puckett *et al.*, 1997).

The importance of tissue scarring to the hostile CNS environment has recently been emphasized by a number of investigations demonstrating the increased expression and inhibition of axonal regrowth by a family of highly sulphated proteoglycans, e.g. chondroitin sulphate proteoglycans (CSPGs) (Jones and Tuszynski, 2002; Jones *et al.*, 2002; Morgenstern *et al.*, 2002). The rapid deposition of such extracellular matrix molecules has been shown to inhibit the regeneration of grafted populations of neurons as well as of intrinsic CNS neurons (Davies *et al.*, 1997, 1999; Bradbury *et al.*, 2002). Recent studies have demonstrated that in traumatic human spinal cord injury lacking Schwannosis, CSPG immunoreactivity was largely confined to blood vessels, macrophages and some astrocytes at the lesion site. In other cases, however, the migration of Schwann cells from spinal nerve roots into the injured CNS led to a local increase of CSPG expression (Bruce *et al.*, 2000). It remains uncertain whether the reactive astrocytes located in degenerating human nerve fibre tracts also express CSPG.

In the present immunohistochemical investigation, we studied the pattern of axonal degeneration, loss of myelin, astrocytic activation and CSPG expression during Wallerian degeneration of nerve fibre tracts in *post mortem* spinal cord tissue of patients who died at a range of times following stroke or traumatic spinal cord injury. We report a centrifugal pattern of axonal degeneration away from the site of injury and the gradual loss of the major component of compact myelin, myelin basic protein (MBP). Confirming earlier studies, we also detected a delayed astroglial reaction in the degenerating white matter tracts. However, in contrast to other reports we show the deposition of a dense anisomorphic GFAP-positive astroglial matrix 1 year and longer after injury with clearly increased immunoreactivity. This scar formation is not associated with a concomitant increase of the axon growth inhibitory molecule CSPG.

Material and methods

Pathology

Post mortem, the spinal cords were removed from four control patients who had not suffered from any neurological disease and from 22 patients who died at a range of time points after either cerebral infarction or traumatic spinal cord injury. The study was approved by the Aachen University Ethics Committee and subjects' families gave consent. Patients with cerebral infarction had a massive infarction in the territory of the middle cerebral artery with severe hemiparesis on the contralateral side (Table 1). Patients with traumatic injury had been diagnosed as having 'complete' injuries

Table 1 Patients who died after cerebral infarction by the occlusion of the middle cerebral artery

Case number	Age (years)	Side of infarction	Injury–death interval
1	36	Left	3 days
2	63	Right	4 days
3	62	Left	4 days
4	78	Left	7 days
5	76	Left	8 days
6	74	Left	14 days
7	45	Right	5 weeks
8	84	Left	4 months
9	79	Left	3 years

Table 2 Patients who died after traumatic injury to the spinal cord

Case number	Age (years)	Injury level	Injury–death interval
1	21	T12	2 days
2	51	C1	4 days
3	84	C3–4	5 days
4	65	C5	8 days
5	63	C6	11 days
6	18	T6	12 days
7	72	T11–12	24 days
8	85	C3	4 months
9	80	C5–6	1 year
10	44	L1	8 years
11	71	C3–4	20 years
12	47	T5	26 years
13	57	T3–4	30 years

and presented with paraplegia or tetraplegia (Table 2). The spinal columns were removed at autopsy, ~15–48 h after death. Following incision of the dura mater, the spinal cord was fixed in 4% buffered formaldehyde for at least 2 weeks. Thereafter, blocks of the lesion site and tissue from regions rostral and caudal to the lesion (~1 cm thickness) were embedded in paraffin wax.

Immunohistochemistry

For neurofilament (NF) and GFAP immunohistochemistry, transverse or longitudinal sections (5 µm thick) were collected onto poly-L-lysine-coated slides and allowed to dry. Sections were de-waxed in xylene, rehydrated and endogenous peroxidase activity was blocked by incubation in 0.1 M phosphate-buffered saline containing 3% H₂O₂ for 30 min. Microwave treatment in 0.2% citrate buffer for 3 × 5 min was followed by blockade of non-specific binding by incubation in 10% defatted milk powder for 20 min and subsequent incubation with the primary antibody, overnight at room temperature. The following monoclonal antibodies were used: anti-GFAP (diluted 1 : 1000; clone G-A-5; Sigma) and anti-NF 200 kDa (diluted 1 : 1000; clone NE14; Sigma). Following extensive rinsing steps in 0.1 M phosphate-buffered saline, sections were incubated in biotinylated horse anti-mouse antibody (diluted 1 : 500; Vector Laboratories) for 1 h at room temperature. For visualization, sections

were treated with the Vector ABC system for 1 h at room temperature, followed by incubation in diaminobenzidine as described previously (Schmitt *et al.*, 1998). Finally, sections were counterstained with thionin, dehydrated and coverslipped. For CSPG immunohistochemistry, sections were incubated with chondroitinase ABC (Sigma) at 1 U/ml for 2 h at room temperature after blockade of endogenous peroxidase. The primary antibody (mouse immunoglobulin M, anti-proteoglycan ΔDi-6S; Seikagaku Corporation) was used at a concentration of 1 : 1000. The secondary antibody used was a biotinylated horse anti-mouse immunoglobulin M (Vector Laboratories) diluted 1 : 500. For MBP immunohistochemistry, section de-waxing was followed by a 20 min incubation in ethanol/acetic acid (95%/5%) at 4°C. The primary antibody rabbit anti-MBP Ab980; Chemicon) was used at a concentration of 1 : 1000. For visualization, sections were incubated for 3 h with a Texas Red-conjugated goat anti-rabbit secondary antibody (diluted 1 : 500; Jackson Laboratories) at room temperature. For negative controls the primary antibody was omitted.

Results

Pathology

The spinal cords of 26 individuals were examined using NF, GFAP, CSPG and MBP immunohistochemistry. The brains of all cases were examined carefully. Those obtained from control cases were declared to be without pathological findings. Patients who suffered cerebral infarction had a massive vascular insult in the region of the middle cerebral artery and cases of spinal trauma had a complete lesion without remaining nerve fibres traversing the lesion centre (not shown). The cases have been subdivided into three groups according to the post-injury survival times (early, intermediate and late survival times), because distinct morphological stages in the course of Wallerian degeneration and the astrocytic reaction were found.

Early survival times (2–14 days post-injury)

Following traumatic spinal cord injury, segments close to the lesion site demonstrated early signs of degeneration with a loss of the regular pattern of NF staining due to swelling, fragmentation and increased space between the axons. This pathological pattern extended approximately one to two segments rostral and caudal to the lesion, was spread over the entire white matter and was not restricted to changes in particular descending or ascending nerve fibre pathways (not shown). At survival times from 2 to 11 days, no signs of Wallerian degeneration were observed in the area of the affected corticospinal tract (CST) further than one to two segments away from the lesion, nor in cervical, thoracic and lumbar segments of stroke cases. NF immunohistochemistry in transverse sections demonstrated a regular staining pattern with evenly distributed axons throughout the white matter (Fig. 1A). Longitudinal sections showed the parallel orientation of these nerve fibres (Fig. 1E). However, early signs of degeneration could be seen in the lateral CSTs of lumbar tissue blocks obtained from a case in which T6 level injury

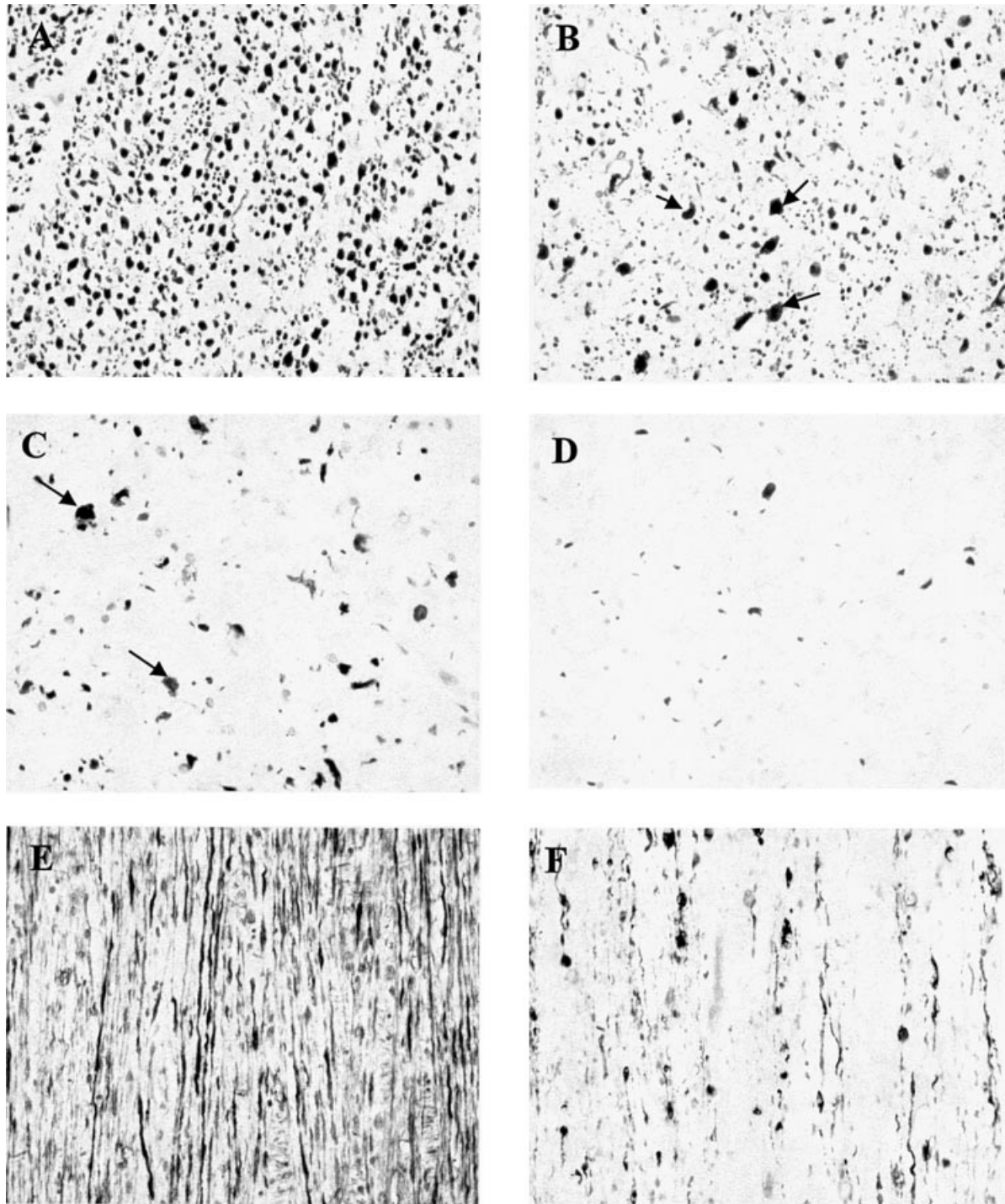


Fig. 1 NF immunohistochemistry of nerve fibre tracts during Wallerian degeneration. **A** and **B** are cervical sections from a patient who died 14 days after cerebral infarction. **(A)** The unaffected CST shows the regular appearance with evenly distributed nerve fibres. **(B)** The degenerating CST displays many swollen and fragmented axonal profiles (arrows). **(C)** Degenerating cervical CST 5 weeks after cerebral infarction; swollen and fragmented axonal profiles (arrows) can still be seen beside a further reduction in the amount of nerve fibres compared with the earlier survival time. **(D)** Degenerated cervical CST 3 years after cerebral infarction—here, the tract is nearly devoid of axonal profiles; **(E)** unaffected CST; **(F)** longitudinal section from the CST shown in **D**. **A–E**, magnification $\times 200$.

occurred 12 days before death. Similarly, 14 days after cerebral infarction of the left hemisphere, clear pathological alterations could be seen in the right lateral (crossed) CST and also in the left anterior (uncrossed) CSTs (Fig. 1B) of cervical

segments. In this case, no changes could be seen in sections taken from either thoracic or lumbar blocks.

Four days after traumatic spinal cord injury, GFAP immunohistochemistry in sections taken from tissue blocks

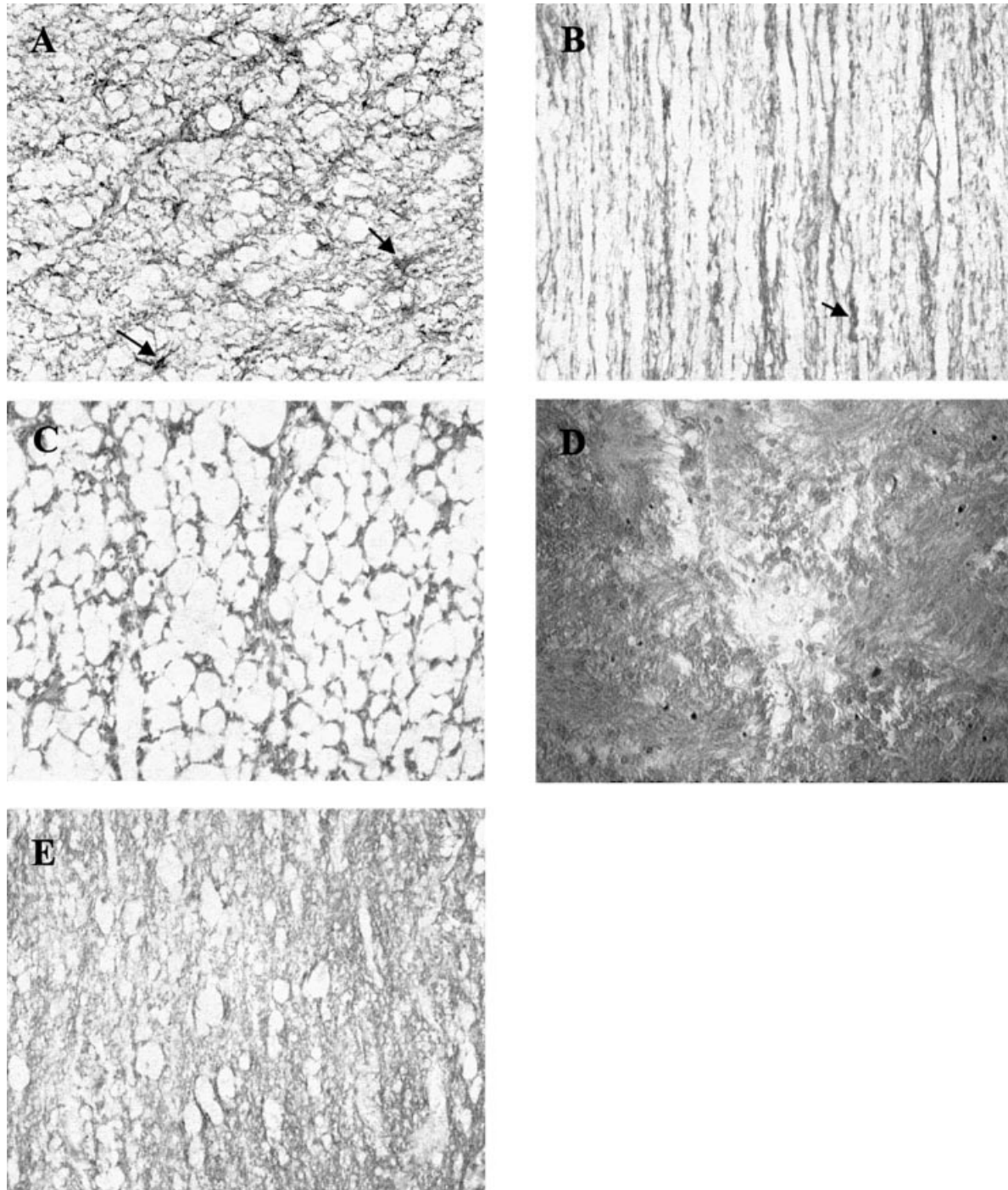


Fig. 2 GFAP immunohistochemistry of nerve fibre tracts during Wallerian degeneration. **A** and **B** show sections from the spinal cord of a control case. **(A)** A transverse section from the CST demonstrates the normal network of astrocytic processes with some cell bodies (arrows). **(B)** The longitudinal orientation of this astroglial network with interjacent cell bodies (arrow). **(C)** Degenerating thoracic CST 4 months after traumatic injury at C4, showing a 'honeycomb'-like appearance due to intensely labelled processes around fluid or macrophage filled spaces. **(D)** Transverse section from the degenerating CST 8 years after traumatic injury at L1. The dense GFAP-positive matrix can be seen after these long survival times. This irregular scar shows increased staining intensity compared with the normal situation (compare with **A**). **(E)** A longitudinal section from the same CST demonstrates the loss of orientation of the astroglial matrix. Again, the staining intensity is increased compared with the control case (compare with **B**). **A–E**, magnification $\times 200$.

one to two segments away from the lesion site demonstrated clusters of activated astrocytes with increased immunoreactivity and hypertrophic cell bodies. These clusters were not

confined to either affected descending or ascending nerve fibre tracts, but were also found in grey matter and could be seen close to the lesion site in all cases up to the 12 day

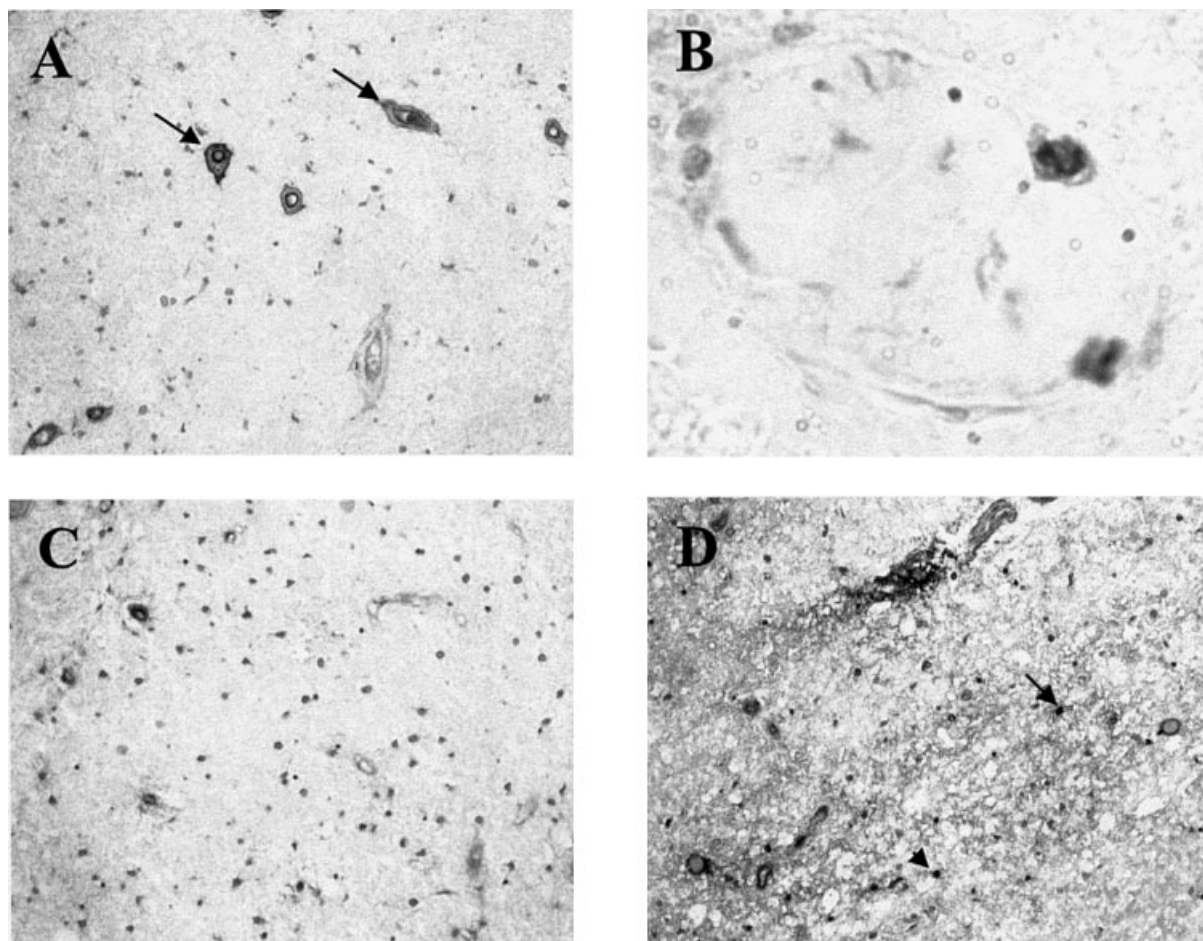


Fig. 3 CSPG immunohistochemistry of nerve fibre tracts during Wallerian degeneration. (A) The CST of a control case reveals CSPG staining in the wall of blood vessels (arrows). (B) Immunoreactive macrophages in parenchymal white matter blood. (C) Degenerated CST 1 year after traumatic spinal cord injury shows no change in the staining pattern compared with A. Occasional blood vessels are positive, but no deposition of CSPG can be seen. (D) section taken close to the primary lesion at 8 days after C5 traumatic injury shows areas of strong CSPG immunoreactivity. Immunoreactive macrophages can be detected (arrows) and CSPG appears to be deposited in the extracellular matrix. A, C and D, magnification $\times 200$; B, $\times 400$.

survival time (data not shown). Further away from the lesion site, the GFAP staining pattern was identical in distribution and intensity to control cases. Correspondingly, sections from stroke cases showed, at all segmental levels, no pathological changes in the astrocytic pattern. In the white matter, cell bodies were visible with their stellate-shape situated within a network of fine processes (Fig. 2A). Longitudinal sections show the parallel orientation of this astroglial framework (Fig. 2B). In the grey matter, staining intensity was generally weaker, with only sporadic cell bodies and a lower number of processes being detectable.

CSPG immunohistochemistry on sections close to the lesion site of traumatic injuries revealed a diffuse extracellular deposit of CSPG (Fig. 3D). Apart from these changes, the staining pattern was consistent in all sections tested. Similar to control tissues, there were relatively few structures within these sections that demonstrated immunoreactivity. Staining could be identified on some blood vessel walls and in occasional macrophages (Fig. 3A and B).

Immunohistochemistry for MBP displayed no morphological changes of myelin sheaths in the degenerating fibre tracts. Transverse sections showed evenly distributed ring-like structures throughout the white matter without signs of degeneration up to 14 days after injury (Fig. 4A and B).

Intermediate survival time (24 days to 4 months post-injury)

As early as 24 days after level T11–12 traumatic spinal cord injury, the medial portion of the dorsal columns at level T6 (six segmental levels rostral to the lesion) was nearly devoid of any NF staining. The few remaining axonal profiles displayed an irregular, mostly swollen appearance. By 5 weeks after a cerebral infarction, degenerative changes in axons of the affected the lateral CST (left side); axonal swelling, fragmentation and increased spacing between axons could now be identified in sections as far caudal as the lumbar

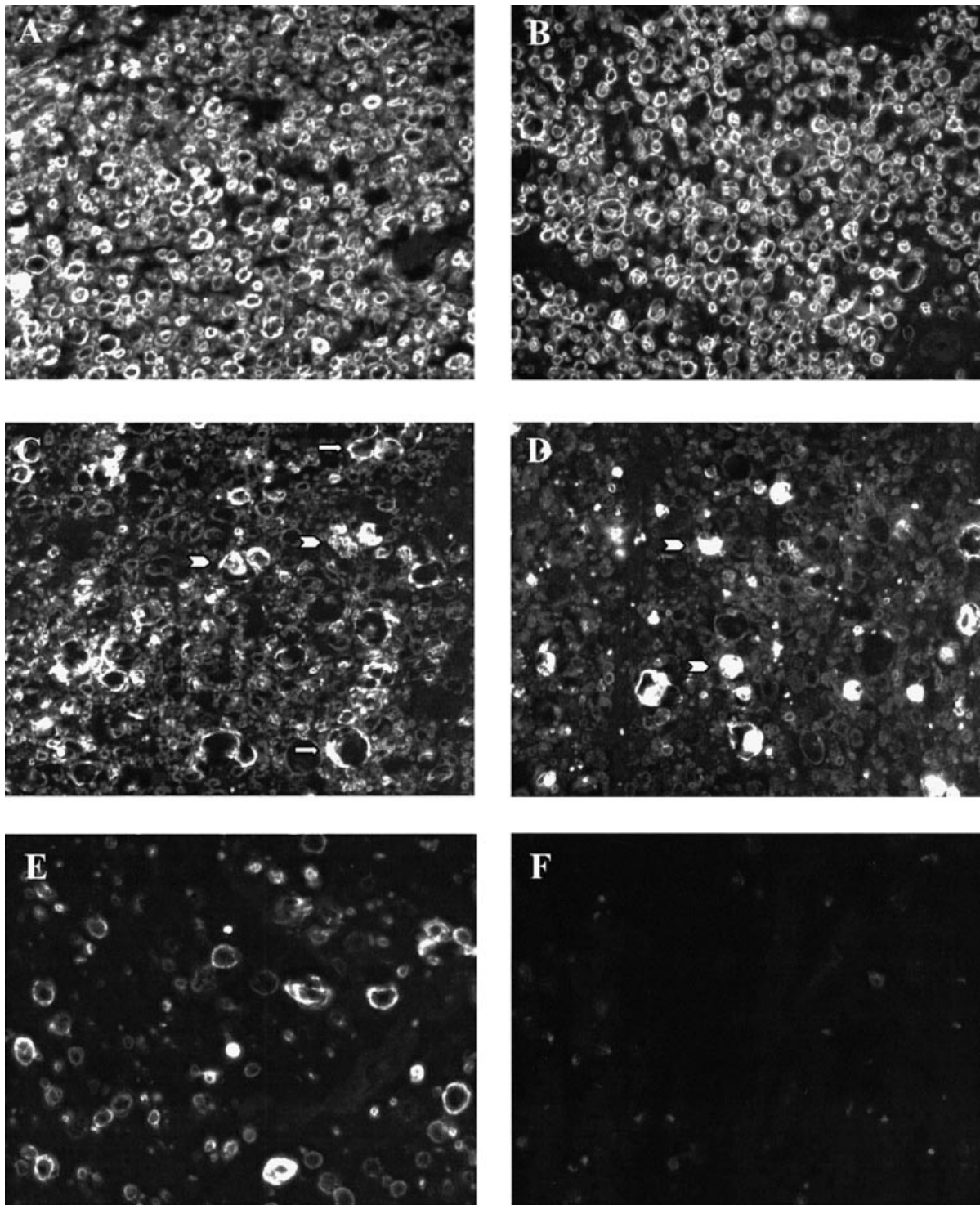


Fig. 4 MBP immunohistochemistry of nerve fibre tracts during Wallerian degeneration. (A) the CST of a control case shows an even distribution of myelin rings. (B) Fourteen days after cerebral infarction the homogeneous distribution of MBP-positive rings is unchanged compared with the control case. (C) Degenerated CST 5 weeks after cerebral infarction demonstrates a clear reduction in the amount of myelin rings, many with a swollen and irregular appearance (arrows). In between, highly immunoreactive irregular profiles can be seen most likely representing degenerated myelin debris (arrowheads). (D) Four months after trauma, the density of myelin rings is further reduced; more amorphous debris is visible (arrowheads). (E) Degenerated CST 3 years after cerebral infarction still displays sporadic myelin rings. (F) Eight years after trauma, the white matter that had undergone Wallerian degeneration has become devoid of MBP immunoreactivity. A–F, magnification $\times 400$.

region (Fig. 1C). Pathology in the region of the anterior CST could only be demonstrated at cervical levels.

GFAP immunohistochemistry close to the point of traumatic spinal cord injury still demonstrated numerous activated astrocytes that were evenly distributed over the whole section. Two segments further away from the lesion site, no significant astrocytic reaction could be detected. There was no indication of increased GFAP immunoreactivity, and the astrocytic processes and cell bodies appeared normal in both grey matter and white matter tracts. By 4 months post-traumatic spinal cord injury, axonal degeneration led to the formation of large fluid- and macrophage-filled spaces within the affected nerve fibre tracts. This resulted in a 'honeycomb'-like appearance of the white matter tracts. The dense packing of intensely GFAP-positive astroglial processes between the spaces made it extremely difficult to comment on changes in astrocytic cell body density (Fig. 2C).

Compared with the control cases, there were no apparent changes in the density or distribution of the few CSPG-positive profiles detected in the sections from these survival times. MBP staining demonstrated a reduced density of myelin rings in the degenerating white matter. The overall picture was heterogeneous, with swollen and irregularly shaped ring-like structures and amorphous structures, which most likely represented degenerated myelin debris. Nevertheless, there were still a number of seemingly intact MBP-positive myelin rings visible 4 months after cerebral infarction and traumatic spinal injury (Fig. 4C and D).

Long survival time (1 year to 30 years post-injury)

Affected nerve fibre pathways from these cases revealed a similar staining pattern for NF immunohistochemistry. Hardly any NF-positive elements could be detected in the affected ascending or descending nerve fibre pathways. The few remaining axonal profiles often appeared pathological (Fig. 1D and F). The white matter tracts that had undergone long-term Wallerian degeneration appeared to be consistently filled with a densely packed GFAP-positive matrix. The tight packing of the GFAP-positive astrocytic cell bodies and processes made it extremely difficult to identify whether there had been any preservation of the longitudinal orientation of these elements (Fig. 2D and E). At these survival times, the intensity of GFAP immunoreactivity appeared to be greater than that detected in control or unaffected white matter regions of the cord (as seen in Fig. 2A and B).

As described for the intermediate survival times, no changes could be detected in CSPG staining in the affected white matter tracts (Fig. 3C). Staining for the surrounding myelin sheaths showed, up to 3 years after trauma, some ring-like structures with weak immunoreactivity and mostly irregular shape (Fig. 4E). The staining density was clearly reduced compared with earlier survival times. By 8 years

after injury, the degenerated tracts had become devoid of MBP-positive structures (Fig. 4F).

Discussion

A number of experimental intervention strategies have proven to be useful in promoting significant axonal regeneration following traumatic injury to the CNS. It is possible that the route taken by the regrowing axons may influence the rate of regeneration as well as their ability to find and re-innervate their appropriate target regions. Some intervention strategies appear to promote axon regeneration through remaining grey matter (Ramon-Cueto *et al.*, 2000; Tuszynski *et al.*, 2003). Other experimental strategies have been reported to promote regeneration along the original degenerated fibre tract (Li *et al.*, 1997; Liu *et al.*, 1999; Stichel *et al.*, 1999; Moon *et al.*, 2001). Since the properties of degenerated fibre tracts may critically influence the routing of nerve fibre regeneration, we decided to perform an immunohistochemical investigation of the dynamics of Wallerian degeneration in *post mortem* spinal cords of patients who died 2 days to 30 years after either cerebral infarction or traumatic spinal cord injury.

Axonal breakdown in Wallerian degeneration is an active process triggered by a rise in intracellular calcium levels followed by the activation of calcium-sensitive proteases such as calpains (Coleman and Perry, 2002). The spatio-temporal pattern of axonal degeneration remains controversial. Numerous studies have addressed this question and have resulted in different patterns of degeneration, probably due to differences in methodology but also to the different experimental models that were used.

The present NF staining demonstrated the first signs of pathology in the tracts undergoing Wallerian degeneration at 12 days after injury. Lumbar sections from this individual, who died after traumatic injury at T6, demonstrated swollen and fragmented axonal profiles in both CSTs. Fourteen days after cerebral infarction leading to massive loss of sensorimotor pyramidal neurons in the cortex, NF staining demonstrated swollen and fragmented axonal profiles in the corresponding lateral and anterior CST in the cervical spinal cord. In contrast, thoracic and lumbar sections revealed no pathological alterations. In an earlier study, the pattern of microglial activation observed in this same case revealed that microglia were activated in the CST at cervical levels only (Schmitt *et al.*, 1998). At thoracic and lumbar levels, microglial activation was only evident in the grey matter, in the terminal target territory of the CST, probably reflecting early removal of pre-synaptic terminals. The later survival times, which in the present investigation demonstrated axonal pathology and loss in the CSTs at thoracic and lumbar levels, also revealed microglial activation in these fibre tracts (Schmitt *et al.*, 1998, 2000). Comparing the spatio-temporal pattern of axonal degeneration observed in the present investigation with the previously described pattern of microglial activation suggests strongly that early degeneration of pre-synaptic terminals (and the immediate pre-

terminal axon) together with centrifugal degeneration of the remaining axon takes place during Wallerian degeneration in the human CNS. This pattern of axonal and terminal changes has previously been reported to take place in the lesioned PNS (Miledi and Slater, 1970; Levenson and Rosenbluth, 1990).

Immunohistochemistry for MBP, a major component of compact myelin, demonstrated the gradual reduction of MBP immunoreactivity in the affected nerve fibre tracts over a number of years. Several months after injury, myelin debris and even ring-like structures could still be detected in areas of severe axonal depletion. At survival times of up to 3 years after injury, the affected CST was still not devoid of myelin proteins. Only after 8 years or more was myelin completely removed from the degenerated white matter. This supports previous observations of the relatively slow removal of myelin during Wallerian degeneration in the CNS (Miklossy and Van der Loos, 1991; Becerra *et al.*, 1995). It was recently reported that individual components of CNS myelin are degraded at different rates during Wallerian degeneration following experimental spinal cord injury. Myelin-associated glycoprotein located in the peri-axonal myelin membrane was degraded more rapidly than either MBP or Nogo-A (Buss and Schwab, 2003). The present demonstration of continued presence of MBP in *post mortem* human material following either stroke or traumatic spinal cord injury suggests that the potent axon growth inhibitory molecule Nogo-A may also remain in the degenerating nerve fibre tracts for several years.

It is widely acknowledged that astrocytes play a major role in the response of CNS tissue to injury. Reactive astrocytes, located at the lesion site and also within degenerating CNS white matter tracts, are known to undergo a range of changes including increased protein expression (e.g. growth factors, cytokines, cytoskeletal and recognition molecules), hypertrophy and hyperplasia (Ridet *et al.*, 1997). This reactive astrogliosis has been regarded as being hostile to axon regeneration (Reier *et al.*, 1983; Hatten *et al.*, 1991; Fawcett and Asher, 1999). Experimental investigations have been able to identify numerous aspects of this response. Astrocytes close to the lesion demonstrate an anisomorphic response, whereas astrocytes located further away from the primary lesion, particularly in the degenerating nerve fibre tracts, demonstrate an isomorphic response without the formation of a permanent glial scar or distortion of the local cytoarchitecture (Mansour *et al.*, 1990; Fernaud-Espinosa *et al.*, 1993; Ridet *et al.*, 1997). The present investigation into *post mortem* human tissues revealed astrocytic hypertrophy and increased GFAP staining in tissues close to the primary lesion site as early as 4 days after injury. However, reactive astrocytic changes in the white matter tracts undergoing Wallerian degeneration were remarkably slow, being first detected at 4 months after injury. By this stage, GFAP immunoreactivity demonstrated a honeycomb-like appearance in the white matter tracts. This staining pattern possibly reflects a network of intensely stained astrocytic processes around fluid- or macrophage-filled spaces that have been reported to appear

during the removal of degenerated nerve fibres (Schmitt *et al.*, 1998). This was followed by the long-term (1–30 years post-injury) development of a densely packed astroglial matrix without a visible orientation within the degenerated tracts. An increased density of GFAP-positive processes in degenerating dorsal columns and CSTs has previously been reported to take place 4–6 months after human spinal cord injury. However, in contrast to the present investigation, this was followed by a long-term reduction of staining intensity, and in only one case was the degenerated fibre tract almost entirely composed of densely packed astrocytes (Puckett *et al.*, 1997). Thus, in contrast to the investigations in experimental animals and to most of the human cases described by Puckett and colleagues, our study provides evidence for an anisomorphic pattern of astrogliosis and scar formation. This resulted in the loss of the orientated astroglial framework that is present in normal fibre tracts. The reason for the differences in the pattern of astrocytic activation in *post mortem* human spinal cord after injury remain unclear. It is possible that the type and severity of the lesion may influence this behaviour. All cases of spinal cord injury chosen for the present investigation were from cases defined as ‘complete’ injuries. All stroke cases of the present study suffered from severe cerebral infarction caused by the occlusion of the middle cerebral artery, provoking massive loss of corticospinal neurons. Most of the pathological samples studied by Puckett *et al.* (1997) were obtained from cases defined as ‘incomplete’ injuries. A marked variability of the astrocytic response to cystic cavitation of the spinal cord has been described by others. The gliotic response to non-expanding cavitation that evolves after uncomplicated spinal cord contusion is substantially less than that which develops after post-traumatic syringomyelia (Bunge *et al.*, 1997). A number of experimental investigations have suggested that the astroglial response of degenerated CNS white matter tracts presents a hostile environment to axon regeneration (Mansour *et al.*, 1990; Bovolenta *et al.*, 1993). However, this notion has recently been challenged. Microtransplantation of adult dorsal root ganglion neurons into ‘chronically’ lesioned adult rat white matter tracts has revealed a remarkable degree of long-distance regeneration through the isomorphic reactive astroglial environment (Davies *et al.*, 1999). The only region of the white matter found to be refractory to axonal regeneration was the lesion site, which was surrounded by intensely CSPG immunoreactive anisomorphic astrocytes. The substantial role of local CSPG expression in the inhibition of axon regeneration at the lesion site has recently been demonstrated in experimental brain and spinal cord injury (Moon *et al.*, 2001; Bradbury *et al.*, 2002). Relatively little spread of CSPG immunoreactivity has been reported to take place following spinal cord injury, most up-regulation taking place in the immediate vicinity of the lesion site (Davies *et al.*, 1999; Jones and Tuszynski, 2002; Morgenstern *et al.*, 2002). In contrast, a substantial spread of elevated CSPG expression along the dorsal columns 6 weeks after injury was reported by Bradbury and colleagues (Bradbury *et al.*, 2002). Although

elevated levels of CSPG immunoreactivity have been reported to take place at the primary lesion site following traumatic human spinal cord injury (Bruce *et al.*, 2000), there had been no reports concerning the expression of this important axon-growth repulsive molecule along the degenerating central white matter tracts. In the present investigation, despite the eventual development of a dense GFAP-positive astrocytic matrix, it was not possible to detect any increase of CSPG expression in either ascending or descending nerve fibre tracts at early (2–14 days), intermediate (24 days to 4 months) or late (1–30 years) post-injury survival times.

The present observations highlight the importance of comparing data obtained from the numerous experimental investigations with the events that take place in human pathology. Axonal degeneration during Wallerian degeneration in *post mortem* human spinal cord is followed by the gradual loss of myelin over a number of years. These events are accompanied by a slowly developing anisomorphic astrogliosis, which leads to the deposition of a dense astroglial scar. This does not appear to be associated with an up-regulation of the extracellular matrix molecule CSPG in the degenerated fibre tract. Nevertheless, the deposition of a dense scar and the loss of an orientated astroglial framework still point to a non-supportive environment for outgrowing nerve fibres.

It is possible that the astrocytic response in the nerve fibre tracts undergoing Wallerian degeneration may have been influenced by the influx of macrophages or the activation of microglia. A direct role of microglia in the inhibition of axons was suggested by Nieto-Sampedro and colleagues (Bovolenta *et al.*, 1993). The increased production of extracellular matrix, including that of CSPGs, has been correlated to breakdown of the blood–brain barrier and the influx of inflammatory cells such as activated macrophages into areas of experimental CNS pathology (Fitch and Silver, 1997). Investigations into the behaviour of inflammatory cells in the spinal cord in the same material as used for the present investigation has revealed the appearance of major histocompatibility complex II-positive/CD68-positive macrophages in the degenerating fibre tracts from 1–4 months after insult (Schmitt *et al.*, 2000).

To conclude, the present data reveal a number of interesting points. The clearance of myelin debris in the degenerating nerve fibre tracts is a rather slow process, and associated axon growth inhibitory molecules might remain in these regions for many years after the insult. Although there appears to be no indication of an up-regulation of CSPG in the affected CNS fibre tracts, the progressive formation of a densely packed astrocytic scar may represent a major obstacle to nerve fibre regeneration.

In the context of the future application of clinical intervention strategies aimed at promoting axonal regeneration following severe spinal cord injury, the present data suggest the presence of a ‘window of opportunity’ during which axon regrowth along the degenerated fibre tract might

take place. For example, the use of blockers of myelin-related axonal inhibition might be beneficial during the first year or so after injury; however, the eventual formation of the dense astrocytic scar during Wallerian degeneration could provoke the need for regenerating axons to follow alternative routes through the spinal cord tissue.

Acknowledgements

We would like to thank B. Müller and K. Pech for excellent technical assistance. This study was supported by grants from the Bundesministerium für Bildung und Forschung and the Deutsche Forschungsgemeinschaft.

References

- Becerra JL, Puckett WR, Hiester ED, Quencer RM, Marcillo AE, Post MJ, et al. MR-pathologic comparisons of wallerian degeneration in spinal cord injury. *AJNR Am J Neuroradiol* 1995; 16: 125–33.
- Bovolenta P, Wandosell F, Nieto-Sampedro M. Neurite outgrowth inhibitors associated with glial cells and glial cell lines. *Neuroreport* 1993; 5: 345–8.
- Bradbury EJ, Moon LD, Popat RJ, King VR, Bennett GS, Patel PN, et al. Chondroitinase ABC promotes functional recovery after spinal cord injury. *Nature* 2002; 416: 636–40.
- Bruce JH, Norenberg MD, Kraydieh S, Puckett W, Marcillo A, Dietrich D. Schwannosis: role of gliosis and proteoglycan in human spinal cord injury. *J Neurotrauma* 2000; 17: 781–8.
- Bruck W. The role of macrophages in Wallerian degeneration. *Brain Pathol* 1997; 7: 741–52.
- Bunge RP, Puckett WR, Hiester ED. Observations on the pathology of several types of human spinal cord injury, with emphasis on the astrocyte response to penetrating injuries. *Adv Neurol* 1997; 72: 305–15.
- Buss A, Schwab ME. Sequential loss of myelin proteins during Wallerian degeneration in the rat spinal cord. *Glia* 2003; 42: 424–32.
- Coleman M, Perry V. Axon pathology in neurological disease: a neglected therapeutic target. *Trends Neurosci* 2002; 25: 532–7.
- Crowe MJ, Bresnahan JC, Shuman SL, Masters JN, Beattie MS. Apoptosis and delayed degeneration after spinal cord injury in rats and monkeys. *Nat Med* 1997; 3: 73–6.
- Davies SJ, Fitch MT, Memberg SP, Hall AK, Raisman G, Silver J. Regeneration of adult axons in white matter tracts of the central nervous system. *Nature* 1997; 390: 680–3.
- Davies SJ, Goucher DR, Doller C, Silver J. Robust regeneration of adult sensory axons in degenerating white matter of the adult rat spinal cord. *J Neurosci* 1999; 19: 5810–22.
- Fawcett JW, Asher RA. The glial scar and central nervous system repair. *Brain Res Bull* 1999; 49: 377–91.
- Fernaund-Espinosa I, Nieto-Sampedro M, Bovolenta P. Differential activation of microglia and astrocytes in aniso- and isomorphic gliotic tissue. *Glia* 1993; 8: 277–91.
- Fitch MT, Silver J. Activated macrophages and the blood–brain barrier: inflammation after CNS injury leads to increases in putative inhibitory molecules. *Exp Neurol* 1997; 148: 587–603.
- Franson P, Ronnevi LO. Myelin breakdown and elimination in the posterior funiculus of the adult cat after dorsal rhizotomy: a light and electron microscopic qualitative and quantitative study. *J Comp Neurol* 1984; 223: 138–51.
- George R, Griffin JW. The proximo-distal spread of axonal degeneration in the dorsal columns of the rat. *J Neurocytol* 1994; 23: 657–67.
- Giulian D, Li J, Li X, George J, Rutecki PA. The impact of microglia-derived cytokines upon gliosis in the CNS. *Dev Neurosci* 1994; 16: 128–36.
- Hatten ME, Liem RK, Shelanski ML, Mason CA. Astroglia in CNS injury. *Glia* 1991; 4: 233–43.

- Jones LL, Tuszynski MH. Spinal cord injury elicits expression of keratan sulfate proteoglycans by macrophages, reactive microglia, and oligodendrocyte progenitors. *J Neurosci* 2002; 22: 4611–24.
- Jones LL, Yamaguchi Y, Stallcup WB, Tuszynski MH. NG2 is a major chondroitin sulfate proteoglycan produced after spinal cord injury and is expressed by macrophages and oligodendrocyte progenitors. *J Neurosci* 2002; 22: 2792–803.
- Kreutzberg GW. Microglia: a sensor for pathological events in the CNS. *Trends Neurosci* 1996; 19: 312–8.
- Levenson D, Rosenbluth J. Electrophysiologic changes accompanying Wallerian degeneration in frog sciatic nerve. *Brain Res* 1990; 523: 230–6.
- Li Y, Field PM, Raisman G. Repair of adult rat corticospinal tract by transplants of olfactory ensheathing cells. *Science* 1997; 277: 2000–2.
- Liu BP, Fournier A, GrandPre T, Strittmatter SM. Myelin-associated glycoprotein as a functional ligand for the Nogo-66 receptor. *Science* 2002; 297: 1190–3.
- Liu Y, Kim D, Himes BT, Chow SY, Schallert T, Murray M, et al. Transplants of fibroblasts genetically modified to express BDNF promote regeneration of adult rat rubrospinal axons and recovery of forelimb function. *J Neurosci* 1999; 19: 4370–87.
- Lubinska L. Early course of Wallerian degeneration in myelinated fibres of the rat phrenic nerve. *Brain Res* 1977; 130: 47–63.
- Mansour H, Asher R, Dahl D, Labkovsky B, Perides G, Bignami A. Permissive and non-permissive reactive astrocytes: immunofluorescence study with antibodies to the glial hyaluronate-binding protein. *J Neurosci Res* 1990; 25: 300–11.
- Miklossy J, Van der Loos H. The long-distance effects of brain lesions: visualization of myelinated pathways in the human brain using polarizing and fluorescence microscopy. *J Neuropathol Exp Neurol* 1991; 50: 1–15.
- Miledi R, Slater CR. On the degeneration of rat neuromuscular junctions after nerve section. *J Physiol* 1970; 207: 507–28.
- Moon LD, Asher RA, Rhodes KE, Fawcett JW. Regeneration of CNS axons back to their target following treatment of adult rat brain with chondroitinase ABC. *Nat Neurosci* 2001; 4: 465–6.
- Morgenstern DA, Asher RA, Fawcett JW. Chondroitin sulphate proteoglycans in the CNS injury response. *Prog Brain Res* 2002; 137: 313–32.
- Norenberg MD. Astrocyte responses to CNS injury. *J Neuropathol Exp Neurol* 1994; 53: 213–20.
- Norenberg MD. Reactive astrocytosis. In: Aschner M, Kimelberg HK, editors. *The role of glia in neurotoxicity*. Boca Raton (FL): CRC Press; 1996. p. 93–107.
- Puckett WR, Hiester ED, Norenberg MD, Marcillo AE, Bunge RP. The astroglial response to Wallerian degeneration after spinal cord injury in humans. *Exp Neurol* 1997; 148: 424–32.
- Ramon-Cueto A, Cordero MI, Santos-Benito FF, Avila J. Functional recovery of paraplegic rats and motor axon regeneration in their spinal cords by olfactory ensheathing glia. *Neuron* 2000; 25: 425–35.
- Reier PJ, Stensaas LJ, Guth L. The astrocytic scar as an impediment to regeneration in the central nervous system. In: Kao CC, Bunge RP, Reier PJ, editors. *Spinal cord reconstruction*. New York (NY): Raven Press; 1983. p. 162–95.
- Ridet JL, Malhotra SK, Privat A, Gage FH. Reactive astrocytes: cellular and molecular cues to biological function. *Trends Neurosci* 1997; 20: 570–7.
- Schafer M, Fruttiger M, Montag D, Schachner M, Martini R. Disruption of the gene for the myelin-associated glycoprotein improves axonal regrowth along myelin in C57BL/Wlds mice. *Neuron* 1996; 16: 1107–13.
- Schmitt AB, Brook GA, Buss A, Nacimiento W, Noth J, Kreutzberg GW. Dynamics of microglial activation in the spinal cord after cerebral infarction are revealed by expression of MHC class II antigen. *Neuropathol Appl Neurobiol* 1998; 24: 167–76.
- Schmitt AB, Buss A, Breuer S, Brook GA, Pech K, Martin D, et al. Major histocompatibility complex class II expression by activated microglia caudal to lesions of descending tracts in the human spinal cord is not associated with a T cell response. *Acta Neuropathol (Berl)* 2000; 100: 528–36.
- Schwab ME, Bartholdi D. Degeneration and regeneration of axons in the lesioned spinal cord. *Physiol Rev* 1996; 76: 319–70.
- Shuman SL, Bresnahan JC, Beattie MS. Apoptosis of microglia and oligodendrocytes after spinal cord contusion in rats. *J Neurosci Res* 1997; 50: 798–808.
- Simonen M, Pedersen V, Weinmann O, Schnell L, Buss A, Ledermann B, et al. Systemic deletion of the myelin-associated outgrowth inhibitor Nogo-A improves regenerative and plastic responses after spinal cord injury. *Neuron* 2003; 38: 201–11.
- Stichel CC, Hermanns S, Luhmann HJ, Lausberg F, Niermann H, D'Urso D, et al. Inhibition of collagen IV deposition promotes regeneration of injured CNS axons. *Eur J Neurosci* 1999; 11: 632–46.
- Tuszynski MH, Grill R, Jones LL, Brant A, Blesch A, Low K, et al. NT-3 gene delivery elicits growth of chronically injured corticospinal axons and modestly improves functional deficits after chronic scar resection. *Exp Neurol* 2003; 181: 47–56.
- Waller A. Experiments on the section of glossopharyngeal and hypoglossal nerves of the frog and observations of the alternatives produced thereby in the structure of their primitive fibres. *Phil Trans R Soc Lond* 1850; 140: 423.
- Wang KC, Koprivica V, Kim JA, Sivasankaran R, Guo Y, Neve RL, et al. Oligodendrocyte-myelin glycoprotein is a Nogo receptor ligand that inhibits neurite outgrowth. *Nature* 2002; 417: 941–4.

Received March 18, 2003. Revised July 8, 2003

Accepted July 17, 2003