

Morphometry of the amusic brain: a two-site study

Krista L. Hyde,^{1,2} Robert J. Zatorre,² Timothy D. Griffiths,⁴ Jason P. Lerch³ and Isabelle Peretz¹

¹Department of Psychology, University of Montreal, ²Cognitive Neuroscience Unit, Montreal Neurological Institute, McGill University, Montreal, Quebec, ³Toronto Hospital for Sick Children, Toronto, Ontario, Canada and ⁴Newcastle University Medical School, Newcastle Upon Tyne, UK

Correspondence to: Krista L. Hyde, Cognitive Neuroscience Unit, Montreal Neurological Institute, McGill University, 3801 University Street, Montreal, Quebec, Canada H3A 2B4

E-mail: krista.hyde@mcgill.ca

Congenital amusia (or tone deafness) is a lifelong disability that prevents otherwise normal-functioning individuals from developing basic musical skills. Behavioural evidence indicates that congenital amusia is due to a severe deficit in pitch processing, but very little is known about the neural correlates of this condition. The objective of the present study was to investigate the structural neural correlates of congenital amusia. To this aim, voxel-based morphometry was used to detect brain anatomical differences in amusic individuals relative to musically intact controls, by analysing T₁-weighted magnetic resonance images from two independent samples of subjects. The results were consistent across samples in highlighting a reduction in white matter concentration in the right inferior frontal gyrus of amusic individuals. This anatomical anomaly was correlated with performance on pitch-based musical tasks. The results are consistent with neuroimaging findings implicating right inferior frontal regions in musical pitch encoding and melodic pitch memory. We conceive the present results as a consequence of an impoverished communication in a right-hemisphere-based network involving the inferior frontal cortex and the right auditory cortex. Moreover, the data point to the integrity of white matter tracts in right frontal brain areas as being key in acquiring normal musical competence.

Keywords: brain; congenital amusia; pitch; tone deafness; voxel-based morphometry

Abbreviations: BA = Brodmann area; IFG = inferior frontal gyrus; MBEA = Montreal Battery of Evaluation of Amusia; VBM = voxel-based morphometry; VOI = volume of interest

Received March 23, 2006. Revised June 21, 2006. Accepted July 5, 2006. Advance Access publication August 24, 2006.

Introduction

Human societies have always produced and enjoyed music, but ~4% of the general population is not able to do so (Kalmus and Fry, 1980). The existence of a developmental disorder of musical abilities, colloquially known as ‘tone-deafness’, has been entertained for over one century (Grant, 1878; Geschwind, 1984). Individuals afflicted with this musical disorder currently termed ‘congenital amusia’ (Peretz *et al.*, 2001) exhibit lifelong impairments that are specific to the perception and production of music, despite normal neurological history, audition, education, intelligence and memory. Several studies have been conducted on the behavioural manifestations of congenital amusia (Ayotte *et al.*, 2002; Peretz *et al.*, 2002; Foxton *et al.*, 2004; Hyde and Peretz, 2004; Hyde and Peretz, 2005; Patel *et al.*, 2005), but very little is known about the neural correlates of the condition. The objective of the present study was to investigate the structural neural correlates of congenital amusia.

Individuals tested in our laboratory are considered amusic on the basis of two main criteria: they experience difficulties

to recognize familiar tunes without the assistance of the lyrics, and they are unable to detect if and when they sing ‘out-of-tune’. These criteria are formally operationalized via the Montreal Battery of Evaluation of Amusia (MBEA), a standardized battery of music perception and memory tests (Peretz *et al.*, 2003). To be considered amusic, individuals must perform <2 SD from the mean performance of musically intact controls on the MBEA. All amusic participants tested with the MBEA to date have been impaired relative to musically intact controls on the tests requiring discrimination of melodic changes, while about half of them have shown normal performance on the test of rhythmic discrimination. Thus, congenital amusia appears to be principally due to a deficit in the processing of sequential pitch information, while temporal processing appears to be affected only in some individuals.

A deficit in musical pitch processing appears to be a core deficit underlying congenital amusia since amusic individuals have consistently demonstrated a selective impairment in the

processing of musical pitch in several studies. Every amusic individual tested to date in our laboratory has shown a severe problem in the detection of out-of-key notes inserted in melodies (Ayotte *et al.*, 2002; Hyde and Peretz, 2005), but had no problem in detecting a temporal irregularity in the same melodies (Hyde and Peretz, 2005). The tones that do not belong to the key in which the melody has been written sound anomalous for listeners of Western music as early as 5 years of age (Trainor and Trehub, 1994). This ability to map pitch onto musical scales is an essential component of music processing. Tonal pitch encoding helps to create expectancies and feelings of surprise or satisfaction (*see* Krumhansl, 2003, for a recent review). Tonal pitch information is also essential in melody recognition (Hébert and Peretz, 1997). Thus, a defect in tonal pitch encoding may account for the highly selective nature of the musical difficulties experienced by individuals with congenital amusia (Peretz and Hyde, 2003).

The amusic's tonal pitch deficit might arise from a more elemental problem in terms of an acoustic impairment in fine-grained pitch discrimination (Hyde and Peretz, 2004) and pitch direction (Foxton *et al.*, 2004). In two independent psychophysical studies, amusics were shown to be impaired relative to musically intact controls in detecting pitch deviations as small as one semitone (corresponding to adjacent notes on a keyboard) in tone sequences (Hyde and Peretz, 2004), and in the context of tone pairs (Peretz *et al.*, 2002; Foxton *et al.*, 2004). Amusic subjects were also impaired in judging the direction of the same pitch changes in the context of tone pairs (Foxton *et al.*, 2004). Such a pitch deficit may account for problems in melodic processing since most Western melodies (Vos and Troost, 1989) and those from other cultures (Dowling and Harwood, 1986) are constructed with pitch intervals on the order of one semitone.

The fine-grained pitch discrimination deficit experienced by amusic individuals can also be traced down to their brain responses. Peretz *et al.* (2005) conducted an event-related potential (ERP) study and showed that the amusic brain does not respond to pitch deviance smaller than one semitone, whereas a normal brain does so reliably. In contrast, the amusic brain shows enhanced responses to large pitch changes by eliciting an N2-P3 complex that is almost twice as large as that observed in normals. However, this altered pattern of electrical activity does not appear to arise from an anomalous functioning of the auditory cortex. The N1 component of the electrical waveform was normal and was consistent with a localization of the generators in the secondary auditory cortex (Näätänen *et al.*, 1987).

The results from the ERP study were surprising because a neural anomaly in the right auditory cortex of congenital amusic individuals was expected. The right auditory cortex plays a critical role in various aspects of pitch processing. For example, studies of brain-lesioned patients have shown that the right auditory cortex is critical for melody discrimination (Milner, 1962), for the perception of melody in terms of its global contour (Peretz, 1990; Liégeois-Chauvel *et al.*, 1998), the perception of pitch direction (Johnsrude *et al.*, 2000) and

the use of melodic contextual cues in pitch judgements (Warrier and Zatorre, 2004). Neuroimaging studies of normal listeners also show an asymmetry favouring right auditory regions in the processing of pitch sequences (Zatorre *et al.*, 1994; Patterson *et al.*, 2002; Jamison *et al.*, 2005), in the maintenance of pitch while singing (Perry *et al.*, 1999) and in the imagery of tunes (Halpern and Zatorre, 1999). Thus, a congenital neural anomaly in the auditory cortex was predicted in individuals with a severe musical disorder. The fact that such an anomaly was not detected in the above ERP study (Peretz *et al.*, 2005) may, however, be due to the lack of spatial resolution of the ERP technique.

In order to explore the whole amusic brain, and not only the auditory cortex, voxel-based morphometry (VBM) was used in the present study. VBM is a computerized, automated procedure that allows one to search throughout the whole brain for structural differences in terms of local concentration of brain tissue between groups (Ashburner and Friston, 2000). VBM is a method of choice to investigate the structural neural correlates of congenital amusia since this technique has been effective in revealing brain abnormalities in a number of other developmental disorders. For example, it has revealed grey matter abnormalities in individuals with severe speech and language disorders relative to normal controls in the caudate nucleus, an area implicated in speech and motor processes (Watkins *et al.*, 2002). VBM has also revealed grey matter differences in the superior temporal sulcus, a brain region implicated in social perceptual skills, in individuals with autism relative to normal controls (Boddaert *et al.*, 2004).

Similarly, it was expected that the VBM analyses would reveal differences in white matter and/or grey matter concentrations between congenital amusic subjects and musically intact controls. In particular, we predicted that the VBM analyses would reveal structural differences in the right auditory cortex, given its role in various aspects of pitch processing. We also expected that white and/or grey matter concentrations in the vicinity of the right auditory cortex would correlate with poor performance on the tests of melodic pitch perception more so than the test of rhythmic perception of the MBEA (Peretz *et al.*, 2003).

Material and methods

The MRI data used in the present VBM study were acquired at two different centres according to exactly the same imaging parameters, in Montreal (Canada) and Newcastle (UK). We initially acquired MRI data from a group of amusic adults and musically intact controls from Montreal. Although VBM analyses yielded some intriguing and unexpected results, they did not meet a stringent statistical cut-off for a whole-brain analysis. In order to ensure that the results from the original Montreal sample were not false-positives, we deemed it essential to confirm these results in a second sample. Thus, the Newcastle group independently acquired a sample of MRIs from a group of amusics and controls. We used a hypothesis-generating/testing approach across the Montreal and Newcastle samples because it was not possible to merge the data

Table 1 Subject characteristics

	Characteristics	Amusics	Controls
Montreal	Age in years (SD)	56.0 (10.9)	54.9 (6.0)
	Gender	(9F 4M)	(13F 9M)
	Education in years (SD)	16.3 (1.7)	16.9 (1.8)
	Global musical score/30 (SD)	19.5 (2.2)	27.0 (1.4)
Newcastle	Age in years (SD)	54.4 (12.6)	54.6 (4.6)
	Gender	(4F 4M)	(4F 3M)
	Education in years (SD)	16.8 (2.5)	17.2 (2.6)
	Global musical score/30 (SD)	20.3 (1.3)	26.7 (1.3)

SD = standard deviation; F = female; M = male; global musical score corresponds to the average score (/30) over all six tests on the MBEA.

owing to inherent cross-scanner incompatibilities (Ashburner and Friston, 2000).

Subjects

The primary sample from Montreal consisted of 13 amusic adults and 22 controls. The second sample from Newcastle consisted of 8 amusics and 7 controls. The controls were musically intact but had no formal musical training. Amusic subjects were matched to controls in terms of age, gender, education and handedness (see Table 1). All amusic subjects had been thoroughly evaluated on previous behavioural testing sessions (Ayotte *et al.*, 2002; Foxton *et al.*, 2004), and identical criteria were used for subject selection in both the Montreal and Newcastle samples. All amusics had normal intellectual, memory and language skills, and scored <2 SD below mean control performance on the MBEA. The MBEA involves six tests. One test evaluates the sense of metre, and the final test is one of recognition memory. The other four tests assess discrimination. Three of these assess the ability to discriminate melodic changes (that violate key, pitch direction or pitch distance) and one tests rhythmic discrimination (by changing temporal grouping). Both the melodic and rhythmic tests use a 'same-different' discrimination task, with the same set of novel but conventional sounding music. Consistent with the evidence that amusia is largely a pitch-based condition, all amusic participants were severely impaired relative to controls on the melodic tests while about half of them showed normal performance on the rhythmic test (Fig. 1).

This research was approved by the ethics committees of the Montreal Neurological Institute, of the Institut Universitaire de Gériatrie de Montréal and of the University of Newcastle-upon-Tyne. Subjects' written informed consent was obtained according to the Declaration of Helsinki.

Scanning protocol

T₁-weighted MR sequences were obtained for all subjects on a Siemens Sonata 1.5 T scanner at both the Montreal and the Newcastle sites according to the same MR acquisition parameters: 3D fast field echo scan with 160 slices, 1 mm thick, repetition time (TR) = 22 ms, echo time (TE) = 9.2 ms, flip angle = 30. The data from both samples were then processed in exactly the same way. Each T₁-weighted image volume was corrected for signal intensity

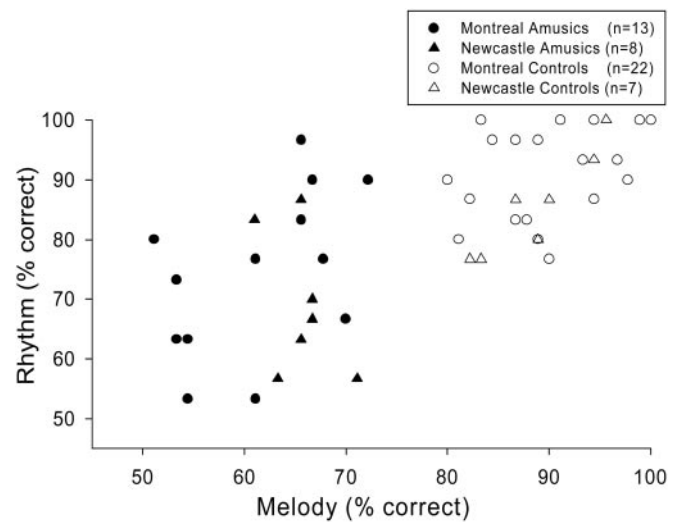


Fig. 1 Behavioural results on the MBEA. Percentage of correct responses obtained by the congenital amusic participants relative to musically intact controls in the melodic pitch tests (averaged over the key, pitch direction and pitch distance tests; abscissa) and the rhythm test (ordinate axis) of the MBEA.

non-uniformity (Sled *et al.*, 1998) and linearly transformed into standardized stereotaxic space (Collins *et al.*, 1994). The transformed images were then classified into white matter, grey matter and cerebrospinal fluid, using INSECT (Zijdenbos *et al.*, 2002), an automatic tissue classification paradigm. The tissue-classified white matter and grey matter maps were smoothed using a Gaussian smoothing kernel of 10-mm full width at half-maximum, resulting in three-dimensional maps of white matter and grey matter concentration.

Data analyses

Three different types of analyses were performed on the Montreal and Newcastle data. First, a group comparison at each voxel in the brain was performed to identify brain regions that differed in terms of white matter or grey matter concentration between amusics and controls within each sample. Next, voxel-based correlational analyses were performed by way of linear regression at each voxel in the brain to detect brain regions where white and grey concentration correlate with performance on the musical tests of the MBEA. Given that each test of the battery assesses a different aspect of music processing, and that there exists some variability in performance, we considered each test separately. Lastly, in order to specify the common areas of white and grey matter concentration differences across the samples and analyses, we performed conjunction analyses by spatially overlapping the thresholded results from the two samples for the group and correlational analyses. This analysis is independent of the order in which the samples are considered since it is a logical 'AND' operation.

Thresholds for *t*-statistic values were calculated according to random field theory (Worsley *et al.*, 2002). The analysis of the Montreal sample was exploratory in nature since this constituted the first neuroanatomical investigation in congenital amusia. Thus, we employed a lenient statistical threshold of $P < 0.05$ (uncorrected for multiple comparisons) in order to maximize the possibility of capturing subtle tissue concentration differences. The significant

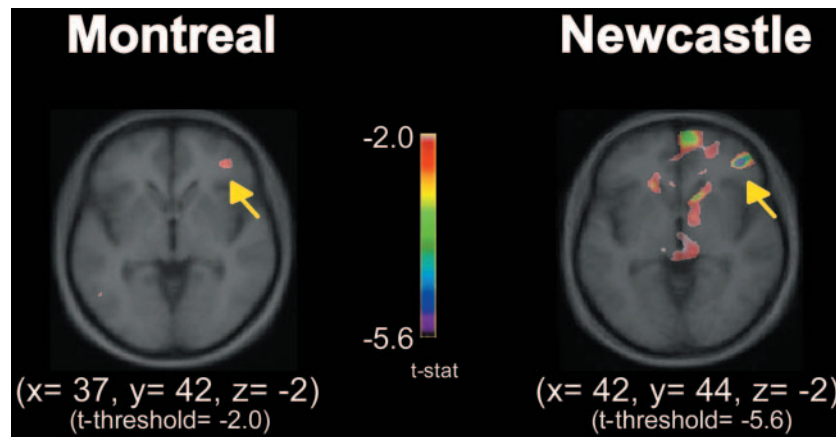


Fig. 2 VBM group comparison of white matter concentration differences. VBM results of group differences in white matter concentration shown for each sample (Montreal and Newcastle). Each brain image corresponds to a thresholded map of t -statistic values superimposed on the average anatomical MRI of the corresponding sample. Images are shown as horizontal sections, and coordinates are in standardized stereotaxic space (Collins *et al.*, 1994). In all images, the yellow arrows correspond to the pars orbitalis of the right IFG (BA 47).

voxels from the Montreal sample defined a volume of interest (VOI) that was then tested in the Newcastle sample. The Newcastle peaks that exceeded a t -threshold associated with this VOI were deemed significant at $P < 0.05$ (corrected for multiple comparisons).

Results

Group comparison

The group comparison in the Montreal sample considering white matter yielded four candidate brain regions where amusics showed less white matter concentration than controls. Three of these regions were found in the right inferior frontal gyrus (IFG), and one in the left IFG. However, only one of the four candidate regions, corresponding to the pars orbitalis of the right IFG in the vicinity of Brodmann area (BA) 47 ($t = -2.7$, $P < 0.01$, uncorrected for multiple comparisons), was also significant in the Newcastle sample ($t = -5.7$, $P < 0.05$, corrected at VOI 20 261 mm³; Fig. 2). There were no other significant peaks of decreased white matter in the Newcastle sample. There were also candidate peaks of increased concentration of white matter in the Montreal sample. However, none of these were confirmed in the Newcastle sample. Thus, these peaks most likely correspond to false-positives and are not reported here. There were no significant peaks of increased white matter in the Newcastle sample alone. Contrary to expectation, there were no significant white matter differences found in the right or the left auditory cortex in either sample.

The group comparison considering grey matter in the Montreal sample yielded candidate brain regions of grey matter concentration differences in amusics versus controls in the same brain regions as for the white matter differences reported above, but in the opposite direction. The finding of an inverse relationship between white matter and grey matter concentration in approximately the same brain regions is primarily due to the partial-volume effect where

a given voxel may contain both white matter and grey matter (Ashburner and Friston, 2000). Partial volumes are typically found in brain regions in which white matter and grey matter tissues are in close proximity, as in the cortex. Only one of the candidate peaks from the Montreal sample corresponding to the right IFG (BA 47) ($x = 37$, $y = 42$, $z = -2$; $t = 2.8$, $P < 0.01$, uncorrected for multiple comparisons) was significant in the Newcastle sample ($x = 40$, $y = 43$, $z = -3$; $t = 6.4$, $P < 0.05$, corrected at VOI 26 451 mm³). Amusic subjects in both samples showed more grey matter concentration relative to controls at this peak, which was the same region of the right IFG as found in the group comparison considering white matter concentration. No other candidate peaks of grey matter differences from the Montreal sample were confirmed in the Newcastle sample. Moreover, there were no significant peaks of decreased or increased grey matter in the Newcastle sample alone. As in the group comparison considering white matter, there were no significant grey matter differences found in the right or the left auditory cortex in either sample.

Voxel-based correlations with performance on musical tests

The voxel-based correlational analyses considering white matter concentration as a function of performance on each of the six musical tests of the MBEA yielded several candidate regions in the Montreal sample, but none in the right or left auditory cortex. As found in the group comparison, only one particular peak in the right IFG (BA 47) was confirmed in the Newcastle sample in two of the musical tests. White matter concentration in this right IFG region was positively correlated with both the melodic key-violation test ($t = 2.4$, $P < 0.05$, uncorrected; Fig. 3A, left panel), and with the memory test ($t = 2.8$, $P < 0.01$, uncorrected; Fig. 4A, left panel), but not with the other four musical

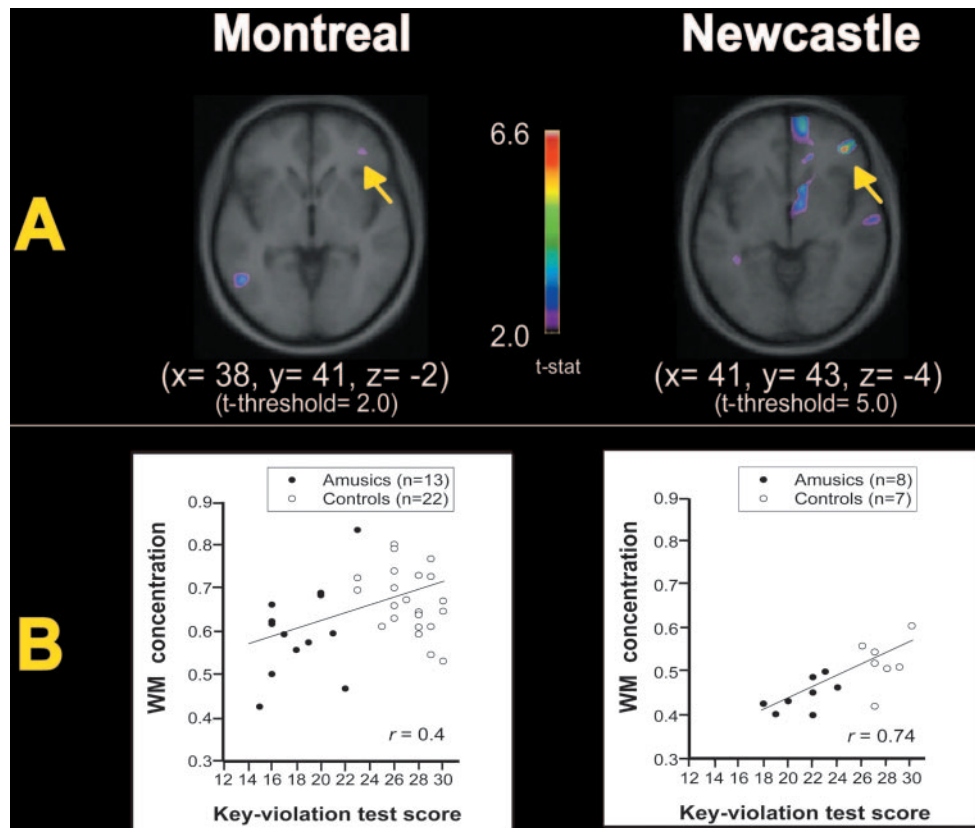


Fig. 3 Voxel-based correlational analyses of white matter concentration and the melodic key-violation test of the MBEA. Shown for each sample (Montreal and Newcastle) in **A** are the voxel-based correlations for white matter (WM) concentration and the melodic key-violation test of the MBEA, and in **B** are the significant positive correlations of WM concentration as a function of increasing score (out of 30) on the melodic key-violation test at the right IFG peak. WM concentration is expressed as the proportion of WM contained within the rIFG peak voxel, where the minimum value is 0 (no WM), and the maximum value is 1 (all WM). Each brain image corresponds to a thresholded map of t -statistic values superimposed on the average anatomical MRI of the corresponding sample. Images are shown as horizontal sections, and coordinates are in standardized stereotaxic space (Collins et al., 1994). In all images, the yellow arrows correspond to the pars orbitalis of the right IFG (BA 47).

tests. The same analyses in the Newcastle sample confirmed the positive correlation of white matter concentration in the right IFG with both the key-violation test ($t = 6.6$, $P < 0.01$, corrected at VOI 8807 mm³; Fig. 3A, right panel) and the memory test ($t = 4.1$, $P < 0.05$, corrected at VOI 1215 mm³; Fig. 4A, right panel). There were no other significant peaks in the Newcastle sample in any of the musical test correlations. To illustrate this relationship between brain morphometry and behaviour, we plotted the white matter concentration obtained at the right IFG peak for each subject as a function of their behavioural scores on the key-violation and memory tests. As shown in Fig. 3B, white matter concentration increased with increasing performance score on the key-violation test, in both the Montreal ($r = 0.4$, $P < 0.02$) and Newcastle samples ($r = 0.74$, $P < 0.001$). This was also true in the memory test for the Montreal ($r = 0.4$, $P < 0.02$) and Newcastle ($r = 0.75$, $P < 0.001$) samples (Fig. 4B). The voxel-based correlational analyses considering grey matter concentration as a function of performance on each of the six tests of the MBEA yielded several

candidate regions in the Montreal sample. However, none of these candidate peaks were confirmed in the Newcastle sample.

Conjunction analyses

The conjunction analyses of the white matter concentration results revealed that the same right IFG region (BA 47) as reported above was common to both samples in each of the group and voxel-based correlational analyses, as well as across these two analyses, within three millimetres along the x , y , and z planes, respectively (Fig. 5). The joint probability that the same right inferior frontal peak voxel would be significant in both the Montreal and Newcastle samples is $P < 10^{-5}$ (uncorrected) in the group and correlational analyses. Therefore, it is extremely unlikely that the right inferior peak found in both samples is a false-positive. In order to further specify where the conjunction occurs relative to the regions delineated in each sample, we quantified what proportion the conjunction represents relative to the total volume in

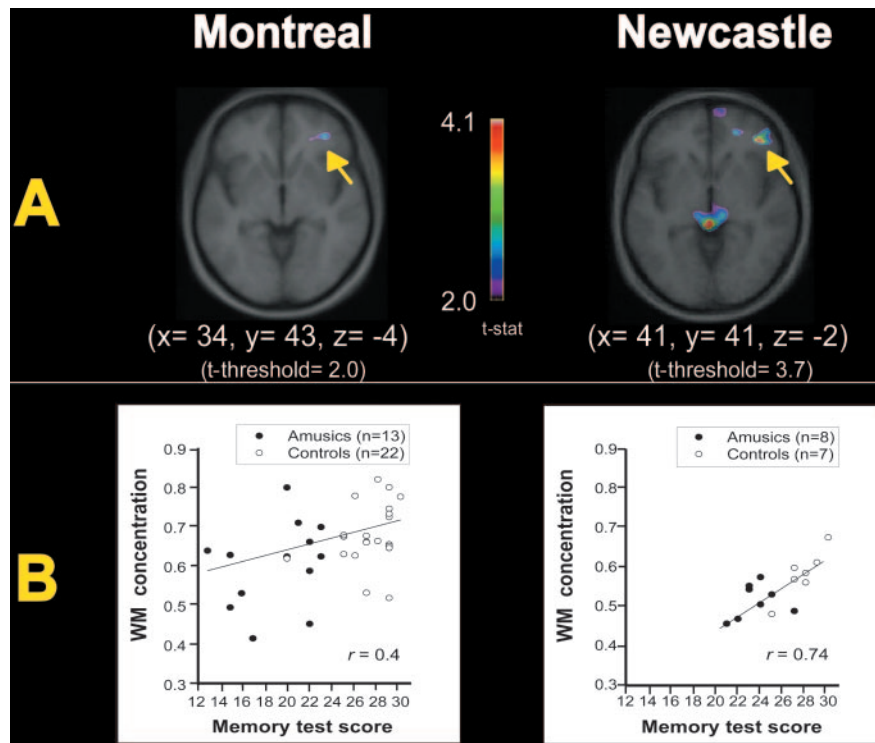


Fig. 4 Voxel-based correlational analyses of white matter concentration and the memory test of the MBEA. Shown for each sample (Montreal and Newcastle) in **A** are the voxel-based correlations for white matter (WM) concentration and the memory test of the MBEA, and in **B** are the significant positive correlations of WM concentration as a function of increasing score (out of 30) on the memory at the right IFG peak. WM concentration is expressed as the proportion of WM contained within the rIFG peak voxel, where the minimum value is 0 (no WM), and the maximum value is 1 (all WM). Each brain image corresponds to a thresholded map of *t*-statistic values superimposed on the average anatomical MRI of the corresponding sample. Images are shown as horizontal sections, and coordinates are in standardized stereotaxic space (Collins *et al.*, 1994). The yellow arrows correspond to the pars orbitalis of the right IFG (BA 47).

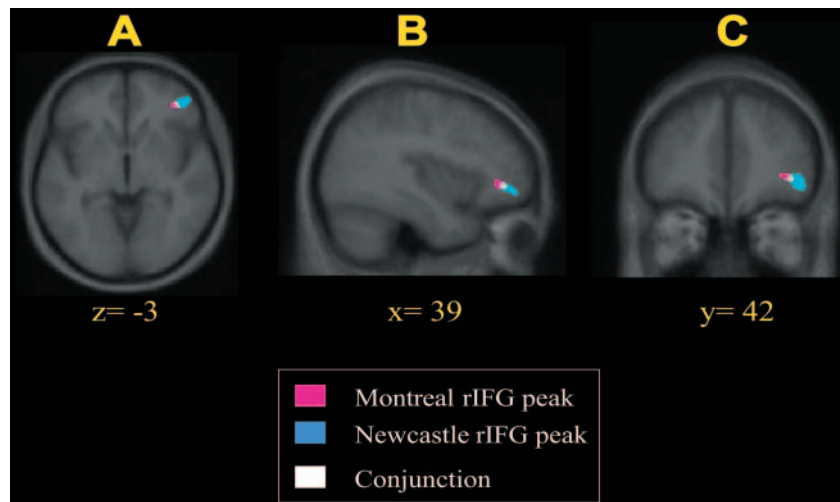


Fig. 5 Conjunction results in three planes of section. Right IFG peak of decreased white matter in the group comparison (amusics versus controls) in the Montreal and Newcastle samples, and their conjunction in three planes of section: **(A)** horizontal, **(B)** sagittal and **(C)** coronal slices. Each individual map was thresholded at $P < 0.05$ (uncorrected), and the conjunction results shown here were superimposed on the average anatomical MRI of all subjects in both samples.

each sample. The conjunction area represents 34% of the Montreal sample, and 19% of the Newcastle sample. Thus, the conjunction is not merely an edge artefact of the regions defined independently in each sample.

Discussion

In the present study, VBM was used to examine differences in white and grey matter concentrations across the whole brain between congenital amusic subjects and musically

intact controls from two independent samples. The results were consistent in pointing to a significant decrease in white matter in the vicinity of the pars orbitalis of the right IFG (BA 47) of the amusic brain relative to controls. Moreover, the white matter concentration in this same right IFG area was positively correlated with the melodic key-violation test and the memory tests of the MBEA, but not with any of the other musical tests. As we will argue, this convergent and salient neuroanatomical difference in the amusic brain is consistent with a number of relevant findings.

VBM analyses also indicated that amusics had more grey matter relative to controls in this same right IFG region. The inverse relationship between white and grey matter concentrations observed here is probably due to the partial-volume effect that occurs in brain regions where voxels contain both white and grey matter (Ashburner and Friston, 2000). Thus, in principle, VBM results can reflect a number of anatomical features, including grey matter changes, shifts in gyral or sulcal anatomy, or white matter changes. A grey matter increase in the right IFG of the amusic brain may occur consequent to a malformation in cortical development, such as abnormal neuronal migration, as has been found in other neurological conditions [e.g. dyslexia (Silani *et al.*, 2005) and epilepsy (Merschhemke *et al.*, 2003)]. However, before accepting this interpretation, a more direct morphometric investigation of grey matter will be required. To this aim, future studies with cortical thickness measures (e.g. Kim *et al.*, 2005) will be ideal since, unlike VBM, this technique allows one to investigate cortical morphology directly and quantifiably (e.g. Chung *et al.*, 2005; Lerch *et al.*, 2005; Shaw *et al.*, 2006). Conversely, the right IFG abnormality observed in the amusic brain may correspond to a white matter decrease. As reviewed in the introduction, regional decreases in white and/or grey matter concentrations are typically reported in studies of adult brains that have experienced long-lasting deficiencies (Watkins *et al.*, 2002; Boddaert *et al.*, 2004). It is therefore reasonable to assume that the perceptual disorder of amusia is related to a decrement in white matter.

Further support for this claim comes from the functional literature on musical pitch perception. Finding a decrease in white matter concentration in the right IFG of amusic individuals that is related to performance in both melodic key discrimination and memory tests is highly consistent with current knowledge of the brain organization for musical pitch encoding and memory. Several studies have demonstrated that right inferior frontal areas are implicated in pitch memory. In a PET study, Zatorre *et al.* (1994) found activation in the right IFG when normal subjects performed a pitch memory task by comparing the pitch of the first and last notes in unfamiliar tonal melodies. Two subsequent PET studies confirmed this finding in tasks that required the holding of pitch information in short-term memory for short melodies (Griffiths *et al.* 1999) and for isolated tones (Holcomb *et al.*, 1998). The right IFG area activation obtained in these studies

corresponds well to the right IFG area (BA 47) found to be correlated with the musical memory task in the present study. Furthermore, it is well established that recognition of melodies critically depends on pitch structure, not rhythm (White, 1960; Hébert and Peretz, 1997). Collectively, the evidence is consistent with the present relation between white matter concentration in the right IFG and performance on the musical memory task.

Further support for the presence of a network in right inferior frontal regions that plays a central role in various aspects of musical pitch processing can be found in two recent functional MRI (fMRI) studies (Koelsch *et al.*, 2002; Tillmann *et al.*, 2003). In both studies, the detection of unexpected chords in the harmonic context recruited the right IFG (BA 44). It is worth specifying here that chord and tone expectancies are judged along similar tonal principles that derive from exposure to the pitch regularities of Western music (Tillmann *et al.*, 2000). Thus, these neuroimaging findings are convergent with the present observation of a correlation between white matter concentration in the right IFG and performance on the melodic key-violation test. Although the area BA 44 is posterior (by ~20 mm) to the right BA 47 found here, both regions are probably part of the same network of right inferior frontal regions implicated in musical pitch processing. Moreover, these frontal regions are connected to the auditory cortex by the same frontotemporal fibre tracts (Hackett *et al.*, 1999; Kaas and Hackett, 1999; Romanski *et al.*, 1999; Parker *et al.*, 2005) that seem to be less developed in the amusic brain. We propose, therefore, that the white matter changes observed here reflect anomalous connectivity between auditory and frontal cortical areas critical to the development of tonal perceptual competence.

Such an account of congenital amusia in terms of reduced connectivity to the right IFG can be more directly assessed in future by way of diffusion tensor imaging, as well as by MRI methods that subdivide white matter by parcellating it both regionally by lobes and radially for fibre system sub-compartments (e.g. Herbert *et al.*, 2004). Another aspect of the morphometry of the amusic brain that would require closer examination is the auditory cortex. Contrary to expectations, we did not find white and/or grey matter differences in the vicinity of the right auditory cortex in the amusic brain. This may be due to the fact that the neural anomaly lies outside the auditory cortex or that it is too subtle to be captured via VBM, which is designed to detect macroscopic brain abnormalities. We cannot rule out, therefore, the possibility that structural abnormalities of auditory regions exist. Further examination of the auditory cortex with other techniques, such as post-mortem microstructural histology (*see* Hutsler and Galuske, 2003 for a recent review), and receptor methods (e.g. Morosan *et al.*, 2005), should be the goal of future studies.

In sum, we conceive the decrease in white matter found here in the right IFG of amusic individuals as a sign of an anomalous wiring of the connections to the right auditory cortex. Its cause may be endogenous or it may interact with

experience. For example, lack of extensive exposure to music could be a contributing factor. Amusic individuals may be less inclined to listen to music during their lifetime than most other people. Long-term consequences of this musical attitude might be a reduced myelination of the connections to the frontal regions. This is plausible given that long-term musical training induces increases in white matter structure (Bengtsson *et al.*, 2005). In favour of an environmental explanation of the current findings, the long maturation time of frontal brain structures and pathways that develop well into adolescence (e.g. Toga *et al.*, 2006) may mean that these brain structures and pathways are particularly sensitive to experience. Conversely, it may be argued that the right IFG abnormality found in the amusic brain has a genetic basis, which interacts with the course of the maturation of frontal brain structures and pathways.

Indeed, use-dependent plasticity does not rule out the intervention of genetic factors. The impulse to listen to music appears to be innate (Trehub and Hannon, 2006). Encoding pitch in terms of musical scales is also a processing component that may have some genetic basis (*see* Peretz, 2006, for a recent review), although we are not suggesting that there is necessarily a causal or direct genetic linkage. A recent twin study provides supportive evidence for the notion that musical pitch encoding may have a heritable component (Drayna *et al.*, 2001). Thus, the present finding of a positive correlation between white matter concentration in the right IFG and performance on a test that requires pitch encoding in terms of musical scales might also reflect the operation of a heritable trait. This would be consistent with our recent family study indicating that about half of the first-degree relatives of the amusic cases are also musically deficient (I.P. Peretz, manuscript in preparation). According to the present findings, the affected members of the family should exhibit abnormalities along the right frontotemporal pathway while the intact members should not. Thus, normal acquisition of basic musical abilities should depend upon structural integrity of the right frontotemporal pathway identified in the present study.

Conclusions

In conclusion, one salient difference in the congenital amusic brain is the presence of an impoverished communication in a right-hemisphere-based network involving the inferior frontal cortex and subserving the processing of pitch in musical contexts. The present study constitutes the first investigation into the structural neural correlates of congenital amusia. The results have implications for the understanding of normal acquisition of musical abilities and for the diagnosis and remediation of this music-specific disorder. This work serves to motivate and guide future studies on the neural correlates of congenital amusia and other disorders.

Acknowledgements

We thank Elizabeth Coulthard in particular and Philip English for collecting the Newcastle MRI data, and

Jessica Foxton for collecting the Newcastle behavioural data. We thank Marc Bouffard and the MRI technicians of the McConnell Brain Imaging Centre of the Montreal Neurological Institute for technical assistance in the acquisition of the Montreal MRI data. We thank our subjects for their continued cooperation. This work was supported by funds from the Fonds de recherche en santé du Québec and Centre for Interdisciplinary Research in Music Media and Technology to K.L.H., by funds from Canadian Institutes of Health Research to I.P. and R.J.Z., and by funds from the Wellcome Trust (UK) to T.D.G.

References

- Ashburner J, Friston KJ. Voxel-based morphometry—the methods. *Neuroimage* 2000; 11: 805–21.
- Ayotte J, Peretz I, Hyde K. Congenital amusia: a group study of adults afflicted with a music-specific disorder. *Brain* 2002; 125: 238–51.
- Bengtsson SL, Nagy Z, Skare S, Forsman L, Forssberg H, Ullen F. Extensive piano practicing has regionally specific effects on white matter development. *Nat Neurosci* 2005; 8: 1148–50.
- Boddaert N, Chabane N, Belin P, Bourgeois M, Royer V, Barthelemy C, et al. Perception of complex sounds in autism: abnormal auditory cortical processing in children. *Am J Psychiatry* 2004; 161: 2117–20.
- Chung MK, Robbins SM, Dalton KM, Davidson RJ, Alexander AL, Evans AC. Cortical thickness analysis in autism with heat kernel smoothing. *Neuroimage* 2005; 25: 1256–65.
- Collins DL, Neelin P, Peters TM, Evans AC. Automatic 3D intersubject registration of MR volumetric data in standardized Talairach space. *J Comput Assist Tomogr* 1994; 18: 192–205.
- Dowling W, Harwood D. *Music cognition*. New York: Academic Press; 1986.
- Drayna D, Manichaikul A, de Lange M, Snieder H, Spector T. Genetic correlates of musical pitch recognition in humans. *Science* 2001; 291: 1969–72.
- Foxton JM, Dean JL, Gee R, Peretz I, Griffiths TD. Characterization of deficits in pitch perception underlying ‘tone deafness’. *Brain* 2004; 127: 801–10.
- Geschwind N. The brain of a learning-disabled individual. *Ann Dyslexia* 1984; 34: 319–27.
- Grant A. Note-deafness. *Mind* 1878; 10: 157–67.
- Griffiths TD, Johnsrude I, Dean JL, Green GG. A common neural substrate for the analysis of pitch and duration pattern in segmented sound? *Neuroreport* 1999; 10: 3825–30.
- Hackett TA, Stepniewska I, Kaas JH. Prefrontal connections of the parabelt auditory cortex in macaque monkeys. *Brain Res* 1999; 817: 45–58.
- Halpern AR, Zatorre RJ. When that tune runs through your head: a PET investigation of auditory imagery for familiar melodies. *Cereb Cortex* 1999; 9: 697–704.
- Hébert S, Peretz I. Recognition of music in long-term memory: are melodic and temporal patterns equal partners? *Mem Cognit* 1997; 25: 518–33.
- Herbert MR, Ziegler DA, Makris N, Filipek PA, Kemper TL, Normandin JJ. Localization of white matter volume increase in autism and developmental language disorder. *Ann Neurol* 2004; 55: 530–40.
- Holcomb HH, Medoff DR, Caudill PJ, Zhao Z, Lahti AC, Dannals RF, et al. Cerebral blood flow relationships associated with a difficult tone recognition task in trained normal volunteers. *Cereb Cortex* 1998; 8: 534–42.
- Hutsler J, Galuske RA. Hemispheric asymmetries in cerebral cortical networks. *Trends Neurosci* 2003; 26: 429–35.
- Hyde KL, Peretz I. Brains that are out of tune but in time. *Psychol Sci* 2004; 15: 356–60.
- Hyde KL, Peretz I. Congenital amusia: impaired musical pitch but intact musical time. In: Syka J, Merzenich M, editors. *Plasticity and signal representation in the auditory system*. New York: Springer Publishing Co.; 2005. p. 291–6.

- Jamison HL, Watkins KE, Bishop DV, Matthews PM. Hemispheric specialization for processing auditory nonspeech stimuli. *Cereb Cortex* 2005, Advance Access published on November 9, 2005; doi:10.1093/cercor/bhj068.
- Johnsrude IS, Penhune VB, Zatorre RJ. Functional specificity in the right human auditory cortex for perceiving pitch direction. *Brain* 2000; 123: 155–63.
- Kaas JH, Hackett TA, Tramo MJ. Auditory processing in primate cerebral cortex. *Curr Opin Neurobiol* 1999; 9: 164–70.
- Kalmus H, Fry DB. On tune deafness (dysmelodia): frequency, development, genetics and musical background. *Ann Hum Genet* 1980; 43: 369–82.
- Kim JS, Singh V, Lee JK, Lerch J, Ad-Dab'bagh Y, MacDonald D, et al. Automated 3-D extraction and evaluation of the inner and outer cortical surfaces using a Laplacian map and partial volume effect classification. *Neuroimage* 2005; 27: 210–21.
- Koelsch S, Gunter TC, Cramon DY, Zysset S, Lohmann G, Friederici AD. Bach speaks: a cortical 'language-network' serves the processing of music. *Neuroimage* 2002; 17: 956–66.
- Krumhansl CL. Experimental strategies for understanding the role of experience in music cognition. *Ann NY Acad Sci* 2003; 999: 414–28.
- Lerch JP, Pruessner JC, Zijdenbos A, Hampel H, Teipel SJ, Evans AC. Focal decline of cortical thickness in Alzheimer's disease identified by computational neuroanatomy. *Cereb Cortex* 2005; 15: 995–1001.
- Liegeois-Chauvel C, Peretz I, Babai M, Laguitton V, Chauvel P. Contribution of different cortical areas in the temporal lobes to music processing. *Brain* 1998; 121: 1853–67.
- Merschhemke M, Mitchell TN, Free SL, Hammers A, Kinton L, Siddiqui A, et al. Quantitative MRI detects abnormalities in relatives of patients with epilepsy and malformations of cortical development. *Neuroimage* 2003; 18: 642–9.
- Milner BA. Laterality effects in audition. In: Mountcastle V, editor. *Interhemispheric relations and cerebral dominance*. Baltimore: Johns Hopkins University Press; 1962. p. 177–95.
- Morosan P, Schleicher A, Amunts K, Zilles K. Multimodal architectonic mapping of human superior temporal gyrus. *Anat Embryol (Berl)* 2005; 210: 401–6.
- Näätänen R, Picton T. The N1 wave of the human electric and magnetic response to sound: a review and an analysis of the component structure. *Psychophysiology* 1987; 24: 375–425.
- Parker GJ, Luzzi S, Alexander DC, Wheeler-Kingshott CA, Ciccarelli O, Lambon Ralph MA. Lateralization of ventral and dorsal auditory-language pathways in the human brain. *Neuroimage* 2005; 24: 656–66.
- Patel AD, Foxton JM, Griffiths TD. Musically tone-deaf individuals have difficulty discriminating intonation contours extracted from speech. *Brain Cogn* 2005; 59: 310–3.
- Patterson RD, Uppenkamp S, Johnsrude IS, Griffiths TD. The processing of temporal pitch and melody information in auditory cortex. *Neuron* 2002; 36: 767–76.
- Peretz I. Processing of local and global musical information by unilateral brain-damaged patients. *Brain* 1990; 113: 1185–205.
- Peretz I. Brain specialization for music. New evidence from congenital amusia. *Ann NY Acad Sci* 2001; 930: 153–65.
- Peretz I. The nature of music from a biological perspective. *Cognition* 2006; 100: 1–32.
- Peretz I, Champod AS, Hyde K. Varieties of musical disorders. The Montreal Battery of Evaluation of Amusia. *Ann NY Acad Sci* 2003; 999: 58–75.
- Peretz I, Brattico E, Tervaniemi M. Abnormal electrical brain responses to pitch in congenital amusia. *Ann Neurol* 2005; 58: 478–82.
- Peretz I, Hyde KL. What is specific to music processing? Insights from congenital amusia. *Trends Cogn Sci* 2003; 7: 362–367.
- Perry DW, Zatorre RJ, Petrides M, Alivisatos B, Meyer E, Evans AC. Localization of cerebral activity during simple singing. *Neuroreport* 1999; 10: 3979–84.
- Peretz I, Ayotte J, Zatorre RJ, Mehler J, Ahad P, Penhune VB, et al. Congenital amusia: a disorder of fine-grained pitch discrimination. *Neuron* 2002; 33: 185–91.
- Romanski LM, Bates JF, Goldman-Rakic PS. Auditory belt and parabelt projections to the prefrontal cortex in the rhesus monkey. *J Comp Neurol* 1999; 403: 141–57.
- Shaw P, Greenstein D, Lerch J, Clasen L, Lenroot R, Gogtay N, et al. Intellectual ability and cortical development in children and adolescents. *Nature* 2006; 440: 676–9.
- Silani G, Frith U, Demonet JF, Fazio F, Perani D, Price C, et al. Brain abnormalities underlying altered activation in dyslexia: a voxel based morphometry study. *Brain* 2005; 128: 2453–61.
- Sled JG, Zijdenbos AP, Evans AC. A nonparametric method for automatic correction of intensity nonuniformity in MRI data. *IEEE Trans Med Imaging* 1998; 17: 87–97.
- Tillmann B, Bharucha JJ, Bigand E. Implicit learning of tonality: a self-organizing approach. *Psychol Rev* 2000; 107: 885–913.
- Tillmann B, Janata P, Bharucha JJ. Activation of the inferior frontal cortex in musical priming. *Brain Res Cogn Brain Res* 2003; 16: 145–61.
- Toga AW, Thompson PM, Sowell ER. Mapping brain maturation. *Trends Neurosci* 2006; 29: 148–59.
- Trainor LJ, Trehub SE. Key membership and implied harmony in Western tonal music: developmental perspectives. *Percept Psychophys* 1994; 56: 125–32.
- Trehub SE, Hannon EE. Infant music perception: domain-general or domain-specific mechanisms? *Cognition* 2006; 100: 73–99.
- Warrier CM, Zatorre RJ. Right temporal cortex is critical for utilization of melodic contextual cues in a pitch constancy task. *Brain* 2004; 127: 1616–25.
- Watkins KE, Vargha-Khadem F, Ashburner J, Passingham RE, Connelly A, Friston KJ, et al. MRI analysis of an inherited speech and language disorder: structural brain abnormalities. *Brain* 2002; 125: 465–78.
- Vos PG, Troost JM. Ascending and descending melodic intervals: statistical findings and their perceptual relevance. *Music Percept* 1989; 6: 383–96.
- White BW. Recognition of distorted melodies. *Am J Psychol* 1960; 73: 100–7.
- Worsley KJ, Liao CH, Aston J, Petre V, Duncan GH, Morales F, et al. A general statistical analysis for fMRI data. *Neuroimage* 2002; 15: 1–15.
- Zatorre RJ, Evans AC, Meyer E. Neural mechanisms underlying melodic perception and memory for pitch. *J Neurosci* 1994; 14: 1908–19.
- Zijdenbos AP, Forghani R, Evans AC. Automatic 'pipeline' analysis of 3-D MRI data for clinical trials: application to multiple sclerosis. *IEEE Trans Med Imag* 2002; 21:1280–91.