

# Short-lasting unilateral neuralgiform headache attacks with conjunctival injection and tearing (SUNCT) or cranial autonomic features (SUNA)—a prospective clinical study of SUNCT and SUNA

Anna S. Cohen, Manjit S. Matharu and Peter J. Goadsby

Headache Group, Institute of Neurology and The National Hospital for Neurology and Neurosurgery, London, UK

Correspondence to: Prof P. J. Goadsby, Institute of Neurology, Queen Square, London WC1N 3BG, UK  
E-mail: peterg@ion.ucl.ac.uk

**Short-lasting unilateral neuralgiform headache attacks with conjunctival injection and tearing (SUNCT) and short-lasting unilateral neuralgiform headache attacks with cranial autonomic features (SUNA) are described, although SUNA is rarely reported. The phenotype of SUNCT and SUNA was characterized from a large series of patients (43 SUNCT, 9 SUNA). Three attack types were identified: stabs, groups of stabs and saw-tooth attacks. The mean duration of stabs was 58 s (1–600 s); stab groups, 396 s (10–1200 s); and saw-tooth, 1160 s (5–12 000s). The attack frequency was a mean of 59 attacks/day (2–600), and this depended largely on the type of attack. The pain was orbital, supraorbital or temporal in 38 (88%) SUNCT and 7 (78%) SUNA, and also occurred in the retro-orbital region, side, top, back of head, second and third trigeminal divisions, teeth, neck and ear. All SUNCT patients had conjunctival injection and tearing. Two SUNA patients had conjunctival injection, four had tearing, but none had both. Other cranial autonomic symptoms included nasal blockage, rhinorrhoea, eyelid oedema, facial sweating/flushing and ear flushing. Cutaneous stimuli triggered attacks in 74% of SUNCT but only in 22% of SUNA patients. The majority (95% SUNCT and 89% SUNA) had no refractory period between attacks. For SUNCT 58% and for SUNA 56% of patients were agitated with the attacks. We propose a new set of diagnostic criteria for these syndromes to better encompass the clinical presentations and which include a wider range of attack length, wider trigeminal pain distribution, cutaneous triggering and lack of refractory period.**

**Keywords:** attack load; cutaneous triggering; phenotype; refractory period; SUNA; SUNCT; trigeminal autonomic cephalgia (TAC)

**Abbreviations:** CH = cluster headache; SUNA = short-lasting unilateral neuralgiform headache attacks with cranial autonomic features; SUNCT = short-lasting unilateral neuralgiform headache attacks with conjunctival injection and Tearing; TACs = trigeminal autonomic cephalgias; TN = trigeminal neuralgia

Received February 14, 2006. Revised June 14, 2006. Accepted July 5, 2006. Advance Access publication August 11, 2006.

## Introduction

Short-lasting unilateral neuralgiform headache attacks with conjunctival injection and tearing (SUNCT) is a rare primary headache syndrome first described in 1978 (Sjaastad *et al.*, 1978). The syndrome has been described more fully over subsequent years (Sjaastad *et al.*, 1989; Pareja and Sjaastad, 1997), although only in small series. It has been suggested that

it be grouped together with cluster headache (CH) and paroxysmal hemicrania as trigeminal autonomic cephalgias (TACs) (Goadsby and Lipton, 1997) based on the classical clinical combination of head pain and activation of cranial autonomic efferents (May and Goadsby, 1999). SUNCT was included in the second edition of the International Headache

Classification (Headache Classification Committee of The International Headache Society, 2004), as was a syndrome of short-lasting unilateral neuralgiform headache attacks with cranial autonomic features (SUNA). Here, the first substantial series of patients with SUNCT or SUNA are described in an attempt to define these conditions better.

SUNCT is defined by the International Headache Society as being characterized by unilateral orbital or temporal pain that is stabbing or throbbing in quality and of moderate severity. There should be at least 20 attacks, lasting for 5–240 s, and ipsilateral conjunctival injection and lacrimation should be present (Headache Classification Committee of The International Headache Society, 2004). In recognition of the possibility that all patients with generically the same condition might not have both conjunctival injection and tearing, the classification committee considered that SUNCT syndrome may be a subset of SUNA. In SUNA, there may be cranial autonomic symptoms other than conjunctival injection and lacrimation, or, indeed, only one of those symptoms may be present. A comprehensive review of 50 cases from the worldwide literature was published in 2003 (Matharu *et al.*, 2003a), and there have been further case reports since then (Malik *et al.*, 2002; Matharu *et al.*, 2003b, 2004a; Rossi *et al.*, 2003; Calvo *et al.*, 2004; Cohen *et al.*, 2004b; Prakash and Lo, 2004; Ramirez-Moreno *et al.*, 2004). A difficulty in defining the clinical characteristics of a rare syndrome is to obtain sufficient experience in one place and case histories to make comparisons and see common themes. This has not been hitherto possible with SUNCT/SUNA. We report a case series of 52 patients with SUNCT or SUNA, which is a substantial enough cohort to compare and contrast the clinical presentation. We prospectively studied the clinical and epidemiological characteristics of a large clinic-based population of persons with SUNCT and SUNA. This study addresses the clinical characteristics of the syndrome and the management strategies used. We also report the phenotype of the attacks in more detail than has been previously described. The work was initially reported at the 12th Congress of the International Headache Society (Kyoto, 9–12 October 2005, Cohen *et al.*, 2005a).

## Material and methods

The study group was taken from patients with a mean age of 57 (32–87 years), who were identified from 1995 to 2005 at the National Hospital for Neurology and Neurosurgery, and attended outpatient clinics between 2002 and 2005. The patients were seen by at least two doctors in the outpatient clinic. Some were seen further when admitted for inpatient investigations. To establish a consistent basis for the clinical comparisons, we ensured that one researcher (A.S.C.) spoke to every patient. Most patients (49 out of 52) were contacted by telephone after giving their written consent, or consent during the clinic appointment. Of the remaining three patients, one contacted us by phone directly, and the other two were lost to follow-up, and we could only use their medical notes for information. The study was approved by the National Hospital for

Neurology and Neurosurgery and Institute of Neurology Joint Research Ethics Committee.

A standardized approach was used for history taking such that each patient was asked the same questions about the side, site and character of their pain; duration, frequency and periodicity of their attacks; triggering and relieving factors; their response to medications and the Modified Indotest (100 mg intramuscularly with a blinded placebo control, Matharu *et al.*, 2004b); their responses to non-pharmacological treatments; personal and family history of headache; and any other medical problems.

The patients' notes were also used for information about response to medications and imaging reports.

Where possible, relatives and particular partners were questioned regarding the presence or absence of clinical features during the acute attacks.

The results were all collated on a Microsoft Excel® spreadsheet.

## Results

### Primary importance: defining criteria

Of the 52 patients, 43 had SUNCT as defined by the International Headache Society (Headache Classification Committee of The International Headache Society, 2004), and 9 had syndromes whose cranial autonomic symptoms did not include both conjunctival injection and lacrimation, and were better described as SUNA (Headache Classification Committee of The International Headache Society, 2004). It is not clear whether SUNCT is a subgroup of all SUNA, as suggested by the Classification Committee, or whether the two are separate. Here, we describe them separately to act as a basis for further research. Therefore, SUNCT patients make up an 83% subset of all SUNCT/SUNA.

### Laterality of attacks

Taking SUNCT and SUNA patients together, 20 (38%) patients had attacks that were exclusively left-sided, and 22 (42%) had exclusively right-sided attacks. Eight patients had unilateral, side-variable attacks that affected one side more than the other. One SUNCT patient had unilateral attacks on either side in equal proportions, and one SUNCT patient had bilateral attacks.

### Site of attacks

Eighty-eight per cent of SUNCT and 78% of SUNA patients had pain in the distribution recognized by the IHS criteria (Headache Classification Committee of The International Headache Society, 2004): the eye, retro-orbital region and temple. The majority of SUNCT patients (29, 67%) experienced pain in the eye, with 24 (56%) having retro-orbital pain, 16 (37%) with forehead pain, 16 (37%) with pain in the nose and 14 (33%) each in the temple and maxillary (second) division of the trigeminal nerve. In contrast, only two SUNA patients (22%) had pain in the eye. The pain was in the retro-orbital region in five patients (56%) and temple in five patients (56%). The distribution of pain is shown in Table 1.

**Table 1** Site of attacks

	SUNCT	SUNA
Eye	29 (67%)	2 (22%)
Retro-orbital region	24 (56%)	5 (56%)
Eyebrow	3 (7%)	0 (0%)
Forehead	16 (37%)	1 (11%)
Temple	14 (33%)	5 (56%)
Side of head	4 (9%)	4 (44%)
Top of head	9 (21%)	0 (0%)
Back of head	12 (28%)	2 (22%)
Nose	16 (37%)	1 (11%)
V <sub>2</sub>	14 (33%)	3 (33%)
V <sub>3</sub>	0 (0%)	3 (33%)
Teeth	9 (21%)	2 (22%)
Neck	1 (2%)	1 (11%)
Ear	2 (5%)	1 (11%)

### Autonomic symptoms

By definition, all of the SUNCT patients had both ipsilateral conjunctival injection and lacrimation associated with their attacks (Headache Classification Committee of The International Headache Society, 2004). Twenty-two patients (51%) had ipsilateral ptosis, 17 (40%) had nasal blockage and 23 (53%) had ipsilateral rhinorrhoea associated with their attacks. Twenty-one patients (49%) noticed ipsilateral eyelid oedema, four (9%) had facial flushing, two of which were unilateral and two bilateral. Three (7%) had facial sweating, two of which were unilateral and two bilateral. A further four (9%) had other cranial autonomic symptoms, such as blotchy skin in the face and neck, ipsilateral gritty eye (after Newman *et al.*, 1994), ipsilateral cheek oedema and a sense of ipsilateral aural fullness (after Boes *et al.*, 1998). One patient experienced her autonomic symptoms even without the attacks (#57).

Of the nine SUNA patients, two (22%) had ipsilateral conjunctival injection and four (44%) had lacrimation. Of those with lacrimation, three were ipsilateral and one was contralateral. None had both conjunctival injection and lacrimation. Two patients (22%) had both nasal blockage and rhinorrhoea. Three patients (33%) had ipsilateral ptosis, one (11%) had ipsilateral eyelid oedema and one (11%) had bilateral facial sweating. Three patients (33%) had other symptoms including visual blurring in the ipsilateral eye, ipsilateral mydriasis and a feeling of flushing red hot ipsilateral ear in one patient each (Table 2). 'Red ear syndrome' was considered in the latter patient and felt to be clinically unlikely (Lance, 1996).

### Association between site of pain and autonomic symptoms

Thirty patients with SUNCT had attacks affecting the second division of the trigeminal nerve (V<sub>2</sub>; cheek and nose). Of these 30 patients, 22 (73%) had associated nasal autonomic symptoms. Of the four SUNA patients who had V<sub>2</sub> and V<sub>3</sub> pain, two had nasal autonomic symptoms. One patient

**Table 2** Associated cranial autonomic symptoms\*

	SUNCT	SUNA	CH** (%)
Conjunctival injection	43 (100%)	2 (22%)	77
Lacrimation	43 (100%)	3 ipsilateral, 1 contralateral (44%)	91
Nasal blockage	17 (40%)	2 (22%)	75
Rhinorrhoea	23 (53%)	2 (22%)	72
Eyelid oedema	21 (49%)	1 (11%)	74
Ptosis	22 (51%)	3 (33%)	74
Facial flushing	2 unilateral, 2 bilateral (9%)	1 (11%)	
Sweating	2 unilateral, 1 bilateral (7%)	1 bilateral (11%)	
Other	4 (9%)	3 (33%)	

\*By definition, 100% of SUNCT patients had both conjunctival injection and lacrimation and no patients with SUNA had both;

\*\*CH, cluster headache (after Bahra *et al.*, 2002).

(#59) specifically reported lacrimation when his pain was predominantly in V<sub>2</sub> and nasal congestion when his pain was predominantly in V<sub>3</sub> (mandibular division of the trigeminal nerve).

### Severity of pain

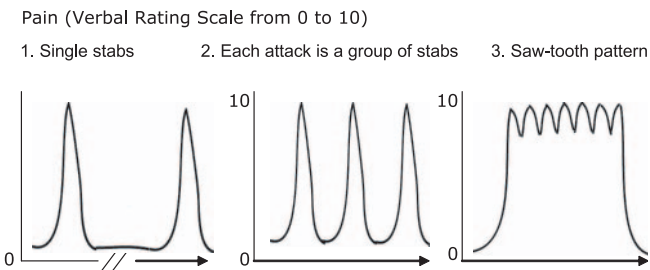
The patients were asked to rate the severity of their attacks on a verbal rating scale (VRS) of 0 to 10, 0 being no pain at all and 10 being the most severe pain imaginable. The majority of SUNCT patients (84%) rated their most painful attacks at 10/10 on the VRS. In contrast, out of the nine patients with SUNA, only three patients (33%) recorded their maximum severity as 10/10. A further three patients recorded their maximum severity as 9/10. Out of the SUNCT patients, most said that this was the most painful condition they had ever experienced; none could name anything more painful. Specifically, patients said that their attacks were worse than childbirth in six patients; tooth abscesses and associated pains in two patients; and gallstones, fractured ribs, renal stones and other headaches in one patient each. For SUNA patients, eight had not experienced pain greater than their SUNA attacks. Only one patient cited the pain of bilateral trabeculectomies as greater than the pain of her SUNA attacks.

### Character, duration and frequency of attacks

Attacks took one or more of three forms: single stabs, a group of stabs or a long attack with a 'saw-tooth' pattern of stabs between which the pain would not return to the baseline (Fig. 1). Patients could have one or more different types of attacks. Fifteen SUNCT and three SUNA patients had single attacks only, two SUNCT and two SUNA had groups of stabs only (of whom one had groups of groups—#21) and eight SUNCT and one SUNA had saw-tooth attacks only.

### Attack timing

*Length of attacks.* The International Headache Society criterion for the length of attacks is 5–240 s (Headache



**Fig. 1** The three types of clinical picture of attacks of SUNCT/SUNA.

**Table 3** Length of attacks and number of attacks per day, and attack load in minutes per day

Attack length	Single stab (s)	Stab groups (s)	Saw tooth (s)	Number of attacks/day	Attack load per day (min)
Mean	58	396	1160	59	139
Median	10	300	285	20	47
Range	1–600	10–1200	5–12 000	2–600	2–1350

Classification Committee of The International Headache Society, 2004). However, patients may have groups of attacks for which each individual stab is of the order of 5–240 s, but the attacks themselves are perceived as much longer in the order of minutes or even hours. This may have caused some diagnostic confusion in the past, as patients with attacks lasting >240 s may have had the diagnosis of SUNCT or SUNA falsely ruled out, whereas in fact their individual attacks were much shorter. We present the findings from our group of patients as length of original stab attacks separate from length of groups of stabs or saw-tooth attacks.

For all patients, the mean length of stab attacks was 58 s (range = 1–600 s). This included the stabs that came as part of a group of stabs, or as part of the saw-tooth attacks. The groups of stabs lasted for a mean of 396 s (10–1200 s), and the saw-tooth attacks ranged from 5 to 12 000 s (200 min), with a mean of 1160 s. One patient (#21) had second-long stabs, occurring in 10 s groups, which in turn would occur in groups of groups, lasting 60 min. One patient (#51) had attacks that lasted as long as the trigger lasted; for instance, pulling his hair for 1 s or 1 h would result in an attack lasting 1 s or 1 h, respectively. This patient's data were not included in the analysis of length of attacks. The remaining results are in Table 3.

**Number of attacks per day.** The International Headache Society criterion for the number of attacks a day is 20–300 (Headache Classification Committee of The International Headache Society, 2004). However, 10 patients, 8 SUNCT and 2 SUNA, had so many attacks a day that they could not accurately quantify them. The number of attacks ranged from two to 'many hundreds'. In total, 42 patients were able to quantify their attacks. The number of attacks

per day ranged from 2 to 600, with a mean of 59 attacks per day.

Some patients had longer attacks than others, and some had groups of attacks. For instance, one patient had stabs lasting 120 s that would occur 12 times per hour, for 3 hours at a time, and she would get three of these attacks a day. This could either be reported as 3 attacks, or as 108 attacks a day, which we have reported here. It would therefore make sense to report both the number of attacks per day and the attack load per day, which would be the number of minutes of pain per day (Table 3). This may be a better marker for monitoring the therapeutic response to treatments.

### Triggering of attacks

In the SUNCT patients, one patient (#51) only had triggered attacks with no spontaneous ones, and six (14%) had entirely spontaneous attacks with no triggers. The rest had attacks that could be spontaneous or triggered. In contrast, in the SUNA patients, two (22%) had mostly triggered attacks, and six (67%) had entirely spontaneous attacks with no triggers.

In 34 SUNCT patients (79%) and 3 SUNA patients (33%), the attacks could be triggered by various cutaneous stimuli. Touching the face was a trigger in 27 SUNCT patients. This was the ipsilateral first division of the trigeminal nerve ( $V_1$ ) in 6 patients, ipsilateral  $V_2$  in 7 patients, ipsilateral side of the face in both divisions or unspecified area in 13 patients and bilateral  $V_1$  in 1 patient (#47) with strictly unilateral attacks. Other trigger factors are listed in Table 4, as are factors that would worsen attacks.

### Refractory period absent

Only two SUNCT patients (5%) and one SUNA patient (11%) had a refractory period; that is, 95% of SUNCT patients and 89% of SUNA patients could have one attack triggered or occurring spontaneously immediately after cessation of another one.

### Secondary importance: non-defining criteria

#### Age and gender of patients and duration of symptoms

Thirty-one patients were male and 21 were female (M : F ratio of 1.5 : 1). There were 28 male and 15 female SUNCT patients (M : F ratio 2 : 1), and three male and six female SUNA patients (M : F ratio 0.5 : 1). The mean age at onset of symptoms was 48 for SUNCT (range = 19–75) and 44 for SUNA (range = 15–57). The mean duration of symptoms for SUNCT was 10 years (range = 2–28 years) and 8 years for SUNA (range = 1–46 years). It took a mean of 6.7 years (range = 0.25–24) for SUNCT and a mean of 7.1 years (range = 1–46) for SUNA to be diagnosed. Previous diagnoses are shown in Table 5. Three SUNA patients had original diagnoses of SUNCT before they were classified as SUNA.



**Table 4** Triggered attacks and refractory period

	SUNCT	SUNA	Total
<b>Triggers to attacks</b>			
Touch	27 (63%)	0 (0%)	27 (52%)
Chew/eat	26 (60%)	2 (22%)	28 (54%)
Wind	17 (40%)	1 (11%)	18 (35%)
Wash face	17 (40%)	0 (0%)	17 (33%)
Brushing teeth	16 (37%)	0 (0%)	16 (31%)
Move	14 (33%)	2 (22%)	16 (31%)
Talk	9 (21%)	1 (11%)	10 (19%)
Wash or brush hair	5 (12%)	0 (0%)	5 (10%)
Exercise	5 (12%)	1 (11%)	6 (12%)
Light	4 (9%)	0 (0%)	4 (8%)
Shower	4 (9%)	0 (0%)	4 (8%)
Shaving	4 (9%)	0 (0%)	4 (8%)
Blow nose	3 (7%)	0 (0%)	3 (6%)
Alcohol	0 (0%)	1 (11%)	1 (2%)
Smoke	1 (2%)	0 (0%)	1 (2%)
Smells	1 (2%)	0 (0%)	1 (2%)
Warm	1 (2%)	0 (0%)	1 (2%)
Others	5 (12%)	0 (0%)	5 (10%)
<b>Factors making attacks worse</b>			
Stress	3 (7%)	1 (11%)	4 (8%)
Tired	1 (2%)	1 (11%)	2 (4%)
Travel	3 (7%)	0 (0%)	3 (6%)
Weather	1 (2%)	0 (0%)	1 (2%)
All triggered	1 (2%)	0 (0%)	1 (2%)
Mostly triggered	12 (28%)	2 (22%)	14 (27%)
Equal triggered and spontaneous	7 (16%)	0 (0%)	7 (13%)
Mostly spontaneous	12 (28%)	0 (0%)	12 (23%)
All spontaneous	6 (14%)	6 (67%)	12 (23%)
Unknown	5 (12%)	1 (11%)	6 (12%)

**Table 5** Diagnoses made before SUNCT/SUNA, and years to diagnosis

	SUNCT n (%)	SUNA n (%)
TN	18 (42)	1 (11)
CH	11 (26)	1 (11)
PH	4 (9)	4 (44)
TAC not otherwise specified	6 (14)	1 (11)
HC	1 (2)	1 (11)
Migraine	5 (12)	2 (22)
Other: stress, psychiatric conditions, shingles, seizures, Bell's palsy	13 (30)	1 (11)
SUNCT	n/a	3 (33)
Years to diagnosis	6.7	7.1
Median	5	2
Range of years to diagnosis	0.25–24	1–46

### Precipitating events

Seven patients with SUNCT and two with SUNA had precipitating events in the three weeks before their attacks commenced. These involved head or facial trauma in four cases; back trauma in one case; and viral infection, episode of extreme stress, analgesic withdrawal and cabin pressure changes on an airline flight in each of the others. One patient (#2) had an episode of severe dizziness, ataxia and headache

**Table 6** Characteristics of pain

Type of attack	SUNCT	SUNA	All
Stab	29 (67%)	3 (33%)	32 (62%)
Electric shock	9 (21%)	1 (11%)	10 (19%)
Sharp	7 (16%)	2 (22%)	9 (17%)
Shooting	7 (16%)	1 (11%)	8 (15%)
Burn	5 (12%)	0 (0%)	5 (10%)
Throb	3 (7%)	2 (22%)	5 (10%)
Pressure	3 (7%)	1 (11%)	4 (8%)
Needle	3 (7%)	0 (0%)	3 (6%)
Boring	2 (5%)	1 (11%)	3 (6%)
Jab	2 (5%)	0 (0%)	2 (4%)
Hot	1 (2%)	1 (11%)	2 (4%)
Burning	1 (2%)	0 (0%)	1 (2%)
Burst	1 (2%)	0 (0%)	1 (2%)
Scraping	1 (2%)	0 (0%)	1 (2%)
Squeeze	1 (2%)	0 (0%)	1 (2%)
Sting	1 (2%)	0 (0%)	1 (2%)
Tight	1 (2%)	0 (0%)	1 (2%)
Twang	0 (0%)	1 (11%)	1 (2%)
Twitching	0 (0%)	1 (11%)	1 (2%)
Metallic	0 (0%)	1 (11%)	1 (2%)

of sudden onset, which preceded his SUNCT attacks by a few weeks.

### Type of pain

Thirty-two of the 52 patients (62%) described their attacks as stabbing. Other descriptions of the pain are listed in Table 6.

### Other symptoms

**Agitation.** There were data on 40 SUNCT patients as to whether they felt agitated during the attack. Twenty-five SUNCT (62%) and five SUNA patients were agitated during an attack. Agitation has been reported in 88% of patients with CH (Torelli and Manzoni, 2003) and in 50% of patients with paroxysmal hemicrania (Antonaci and Sjaastad, 1989), but is less of a feature in migraine, where movement classically makes the pain worse (Headache Classification Committee of The International Headache Society, 2004). Of the 30 agitated patients, 11 of them (37%) had migraine. Of the nine patients in whom movement made the pain worse, six of them (67%) had migraine, and of the remaining three patients, one had a family history of migraine.

**Migrainous symptoms.** Photophobia and phonophobia are also generally associated with migraine, although usually this is bilateral. Unilateral photophobia and phonophobia can occur in migraine (Drummond, 1986; Vingen *et al.*, 1998), CH (Vingen *et al.*, 1998) and in other TACs, such as paroxysmal hemicrania and SUNCT (Irimia *et al.*, 2005). In our group, 21 SUNCT patients (49%) and 6 SUNA patients (67%) had a personal or family history of migraine: migrainous biology. Of the four SUNCT patients with a

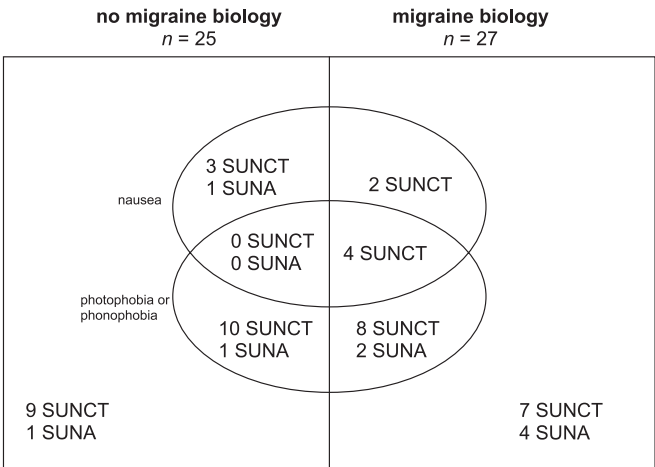


Fig. 2 Photophobia and phonophobia in SUNCT/SUNA.

Table 7 Laterality of photophobia and phonophobia

	SUNCT	SUNA	SUNCT and SUNA
Photophobia	16 (37%)	2 (22%)	18 (35%)
Unilateral photophobia	11 (26%)	2 (22%)	13 (25%)
Phonophobia	13 (30%)	2 (22%)	15 (29%)
Unilateral phonophobia	4 (9%)	2 (22%)	6 (12%)

combination of nausea, photophobia and phonophobia, all had migrainous biology (Fig. 2 and Table 7). The vast majority of our patients had no symptoms of aura such as visual, speech, sensory disturbances or motor disturbances associated with their attacks. One patient had some dizziness with his attacks.

**Diurnal variation of attacks.** Thirty-seven SUNCT and eight SUNA patients could specify whether their attacks occurred more during waking or sleeping hours. Three (7%) SUNCT patients and no SUNA patients reported that their attacks occurred primarily during sleep. Of SUNCT patients, 17 (40%) experienced attacks mainly during waking hours and 17 (40%) experienced attacks equally during sleep and wakefulness. Attacks were specifically worse in the early morning in four patients. Four patients with SUNA had attacks mainly during waking hours, with one especially in the early mornings, and four experienced attacks both during sleep and wakefulness.

**Background pain, migraine and analgesic overuse** Classically, SUNCT and SUNA are not associated with background pain. We found 20 SUNCT and two SUNA with interictal background pain. Initially, some of these patients were misdiagnosed as having hemicrania continua, but negative placebo-controlled indomethacin tests (Matharu *et al.*, 2004b) ruled out this diagnosis, while the syndrome in these SUNCT patients manifested in all other respects in the same way as those without inter-paroxysmal pain.

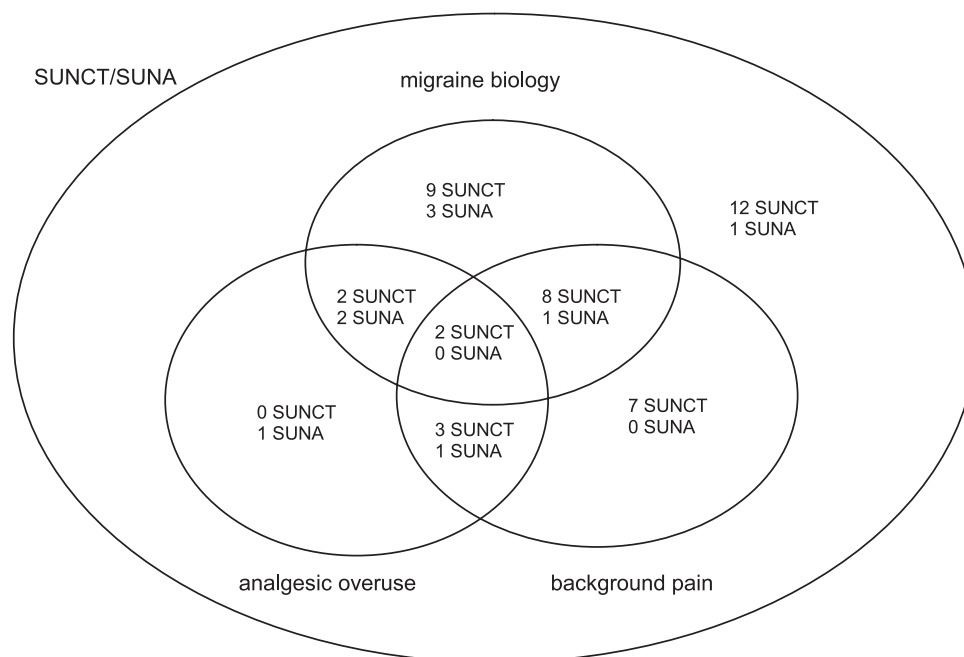
We assessed the relationship between migrainous biology and SUNCT/SUNA and found that in total 40% of patients had a personal history of migraine and 52% had migrainous biology, that is, a personal history of migraine or a family history of migraine in a first-degree relative. Fifteen SUNCT patients (35%) had a personal history of migraine, and in total 21 (49%) had migrainous biology. Six SUNA patients had migraine (67%), and all had migrainous biology. Analgesic overuse, defined as the use of analgesics on 15 or more days per month, was present at some point in seven SUNCT patients and four SUNA patients. The analgesics used were codeine, paracetamol (acetaminophen), dihydro-codeine, codeine and paracetamol combinations in most patients, and codeine and morphine in one patient (#52). Of these 11 patients, 6 had migrainous biology. Analgesic overuse has been reported to be associated with chronic daily headache, in migraine (Bigal *et al.*, 2004) and CH (Paemeleire *et al.*, 2004), and we found that two SUNCT patients with migrainous biology and analgesic overuse developed a chronic daily headache. However, even without analgesic overuse, there was background pain present in 15 SUNCT patients and 1 SUNA patient, of whom 9 had migrainous biology. These interactions are illustrated in Fig. 3.

Periodicity and chronicity of SUNCT and SUNA

All the SUNA patients had primary chronic SUNA, that is, attacks occurring for a year or more without more than a month's break. Thirteen SUNCT patients (30%) had primary episodic SUNCT. Their bouts lasted for a mean of 7.5 weeks (range = 1–30 weeks). The average remission time was 52 weeks, with a range of 3–364 weeks (7 years). Seventeen SUNCT patients had primary chronic SUNCT (40%). Ten patients (23%) had secondary chronic SUNCT, with average time from the start of the disease to chronic SUNCT being 8.4 years (range = 1–16 years). One SUNCT and one SUNA patient had primary chronic forms of the syndromes for more than a year, and then have been in remission for 2 and 3 years, respectively. One SUNCT patient had primary chronic SUNCT for 2 years, then went into remission for 14 years and then had secondary episodic SUNCT with a bout lasting 8 months and remission to date. One patient had primary chronic SUNCT, which went into remission for a year, and then the patient was lost to follow-up.

SUNCT and SUNA with abnormal examination and MRI findings—symptomatic SUNCT and SUNA

Thirteen SUNCT patients (30%) and one SUNA patient (11%) had abnormal findings on neurological examination. These were mainly ipsilateral sensory changes, either reduced sensation to pinprick in V<sub>1</sub> or V<sub>2</sub>: five SUNCT (12%) and one SUNA patient (11%), or hyperaesthesia to pinprick in V<sub>1</sub>: one SUNCT (2%). One SUNCT patient had ipsilateral reduced sensation in V<sub>2</sub> secondary to an infraorbital nerve block. Six SUNCT patients (14%) had other abnormal signs;



**Fig. 3** SUNCT/SUNA migraine biology, analgesic overuse and background headache.

one had a mildly abnormal response to pinprick on the ipsilateral side of the body (#27) and one had a Horner's syndrome, which was investigated and no cause was found (#23). The remaining three patients had signs relating to other pathology, which were reduced field of vision in one eye in a patient with microprolactinoma (#25), ipsilateral VI and contralateral XII nerve palsy after a head injury (#51) and contralateral pyramidal weakness following surgery to remove astrocytoma (#57).

Thirty-six SUNCT and eight SUNA patients had cranial imaging, which in the majority of cases was MRI. Nineteen SUNCT (44%) and seven SUNA patients (78%) had normal intracranial appearances. Of the remainder, five SUNCT patients had incidental findings, such as scattered cerebral white matter lesions, which were not considered clinically relevant when the scans were reviewed by a radiologist.

Eleven SUNCT and one SUNA patient had abnormal intracranial findings. These were as follows:

- (i) Vascular loops compressing on the trigeminal nerve in three patients. One was ipsilateral to the pain (#13), one had bilateral loops but only unilateral pain (#46) and one had a loop on one side but had bilateral attacks (#55).
- (ii) Pathological white matter changes in two SUNCT patients and one SUNA patient. One SUNCT patient had scattered cerebral white matter lesions (#7) reported in Matharu *et al.* (2004a) and one had a lesion on the ipsilateral cerebral peduncle (#52). The SUNA patient had primary progressive multiple sclerosis with extensive white matter changes and lesions in the midbrain, pons and middle cerebral peduncle (#SUNA4).
- (iii) Pituitary lesions in three SUNCT patients, of whom two had macroadenomas [#37 reported in Matharu *et al.* (2003b) and #20], which resolved on treatment of the macroadenoma; and one had a microprolactinoma (#25), the excision of which rendered her pain-free for 8 months.
- (iv) Space-occupying lesions in two patients, which included a parietal astrocytoma in one patient, which on excision did not cause a resolution of her SUNCT. The other patient had an ipsilateral parieto-occipital lesion of unknown cause, which had been excised 2 years before the onset of his SUNCT. This patient had also suffered a head injury and had residual ipsilateral VI nerve and contralateral XII nerve palsy (Table 8).

## Discussion

We report the first substantial case series clinically characterizing SUNCT/SUNA. The syndrome fundamentally is of unilateral, episodic severe pain that occurs in stabs or jabs and is associated with ipsilateral cranial autonomic outflow. The attacks are more severe than has hitherto been reported; they can be prolonged and are triggerable without an apparent refractory period in the vast majority. The series clearly establishes the existence of what has been called SUNA, and provides a basis for considering the two syndromes as closely related, with the majority having SUNCT. The data suggest the need for changes in the International Headache Society classification and provide a firm basis for neurologists to recognize this relatively newly identified, highly disabling form of primary headache.

**Table 8** Secondary SUNCT/SUNA and abnormal intracranial imaging

	SUNCT	SUNA	All
Abnormal examination			
Ipsilateral reduced sensation to pinprick	5 (12%)	1 (11%)	6 (12%)
Ipsilateral hyperaesthesia	1 (2%)	0 (0%)	1 (2%)
Ipsilateral changes post-procedures	1 (2%)	0 (0%)	1 (2%)
Other neurological abnormalities	6 (14%)	0 (0%)	6 (12%)
Intracranial imaging			
Total number imaged	37	8	45
Normal intracranial appearances	20 (54%)	7 (88%)	27 (60%)
Incidental findings	6 (16%)	0 (0%)	6 (13%)
Abnormal intracranial appearances			
Vascular loops	3 (8%)	0 (0%)	3 (7%)
Pathological white matter changes	2 (5%)	1 (12%)	3 (7%)
Pituitary lesions	3 (8%)	0 (0%)	3 (7%)
Space-occupying lesions	2 (5%)	0 (0%)	2 (4%)
Unusual configuration in brainstem and lacune in thalamus	1 (3%)	0 (0%)	1 (2%)
Total abnormal intracranial appearances	11 (29%)	1 (12%)	12 (27%)

### Epidemiology

The prevalence of SUNCT is unknown, although the low number of hitherto reported cases suggests that it is very rare. The fact that at the National Hospital for Neurology and Neurosurgery we only have 52 SUNCT and SUNA cases referred in the United Kingdom with a population of 59.6 million ([www.statistics.gov.uk](http://www.statistics.gov.uk)) may highlight the rarity of the syndrome. Moreover, since we have seen in excess of 600 patients with TACs over the same period, the SUNCT/SUNA group is small. However, the fact that the majority of the patients had previous diagnoses (Table 5) suggests that there may be more cases of SUNCT and SUNA that have been misdiagnosed.

### Male : female ratio

SUNCT has been thought to have a male preponderance, with a recent review giving a male : female ratio of 1.3 : 1 (28 males and 22 females) (Matharu *et al.*, 2003a). We find a slightly higher ratio of 1.5 : 1 for total SUNCT and SUNA combined. However, when separated into SUNCT and SUNA, we found a higher male : female ratio in SUNCT (2 : 1), and almost the opposite ratio in SUNA (0.5 : 1). Thus, it could be that the full syndrome of SUNCT with both conjunctival injection and tearing is commoner in men than in women, with SUNA being commoner in women than men. Alternatively, the sample number for SUNA (nine patients) may be too small to make a significant comment.

### Site of pain

The International Headache Society describes the site of pain in SUNCT as unilateral orbital, supraorbital or temporal pain (Headache Classification Committee of The International Headache Society, 2004). In our series, the majority

of SUNCT patients conformed to these criteria (78%), with orbital (67%), supraorbital/forehead (37%) or temporal (33%) pain, the latter of which was present in 56% of SUNA patients. However, 56% of both SUNCT and SUNA patients reported retro-orbital pain, and the pain was reported in wider areas of the head and face, including the top, side and back of head, nose, V<sub>2</sub> and V<sub>3</sub>, teeth, neck and ear. It is interesting to note that only a small proportion of SUNA patients had pain in the eye, supraorbital region or forehead, but pain was more likely to be reported in the temple. Three patients with SUNA (33%) had pain in V<sub>3</sub>, whereas no SUNCT patients had pain in V<sub>3</sub>. This may illustrate a difference between the two syndromes, such that SUNCT is more likely to affect the orbital and supraorbital regions, and SUNA is more likely to affect the temple and V<sub>2</sub> and V<sub>3</sub>. This in turn may represent a functional anatomical relationship between ophthalmic division pain and lacrimation and conjunctival injection (May *et al.*, 2001).

### Laterality of attacks

Attacks of SUNCT and SUNA have been typically described as strictly unilateral and side-locked (88%), with a slight preponderance of SUNCT attacks on the right (Matharu *et al.*, 2003a). We report side-alternating attacks in 20% of SUNCT patients, which have been observed in a few cases previously (D'Andrea and Granella, 2001; D'Andrea *et al.*, 2001; Matharu *et al.*, 2004a). One patient reported attacks that affected both sides simultaneously (#55). Although considered atypical of SUNCT, this has been reported before (Pareja and Sjaastad, 1997; Sabatowski *et al.*, 2001). In that patient's case a vascular loop was noticed on MRI on the right side only, even though his pain was bilateral. Conversely, another patient (#46) had bilateral vascular loops impinging on the brainstem, but only suffered attacks on the right side. It seems that a pathogenetic role of vascular loops compressing the brainstem or trigeminal nerve may not be as important in SUNCT as in trigeminal neuralgia (TN) (Goadsby *et al.*, 2001).

### Severity of pain

The pain of SUNCT and SUNA is usually excruciating, on a VRS of 10/10 in severity. This serves to highlight the devastating morbidity of these syndromes, especially with a mean time to diagnosis of 6.7 years in SUNCT and 7.1 years in SUNA (Table 5), and subsequent failure of response to many conventional medications (Pareja *et al.*, 1995).

### Duration, frequency and temporal profile of individual attacks

The International Headache Classification specifies attack length of 5–240 s, with 3–200 attacks per day. We have found that attacks may take on different characters: single stabs, groups of stabs or a longer attack composed of many stabs between which the pain does not resolve to normal, thus giving a 'saw-tooth' phenomenon (Fig. 3). Although this



variability in the character of attacks is well recognized in the literature (Antonaci and Sjaastad, 1989), the variability may have led to confusion in the description of length of attacks. The length of single stabs, whether alone, as part of a group or as part of a saw-tooth attack, ranged from 1 to 600 s, with a mean of 56 s. This correlates reasonably well with the IHS classification of length of attacks. The shorter stabs (1–5 s in length) may make up part of a group of stabs or a saw-tooth attack, which will last longer in total. Groups of stabs, or saw-tooth attacks, may be made up of many individual stab attacks; thus a ‘single attack’ would be perceived as longer than 240 s leading to wrong diagnoses of paroxysmal hemicrania or CH.

Another consideration in assessing the temporal profile of attacks is the wide inter-patient variation in the number of attacks per day and the length of these attacks. For example, a patient with 200 attacks a day, each lasting 2 s, will have a rather different experience from the patient with three saw-tooth attacks a day, lasting up to 30 min at a time. The first patient will have 400 s of pain a day, which is just <7 min. The second patient will have 180 min of pain a day. From a therapeutic point of view it would be desirable to reduce not only the number of attacks per day but also the attack load, that is, the number of minutes of pain per day. We therefore propose a system of quantifying SUNCT and SUNA attacks, in the following terms for the purpose of therapeutic studies:

- (i) Type of attack (stab, group or saw-tooth)
- (ii) Number of attacks per day
- (iii) Attack load in minutes per day.

### Frequency and periodicity of attacks

Most cases of SUNCT in the literature have occurred in an episodic manner, with the symptomatic bouts alternating with remissions in an erratic manner. In a series of 21 patients, the symptomatic bouts last from a few days to several months and occurred once to twice annually, although a maximum of 22 episodes per year have been reported, and the symptomatic periods appeared to increase in frequency and duration over time (Pareja and Sjaastad, 1997). Remissions typically lasted for a few months, but have been reported to last from 1 week to 8.5 years (Jimenez-Huete *et al.*, 2002). Both the episodic and chronic forms of SUNCT have been included in the International Headache Society Classification of Headache (Headache Classification Committee of The International Headache Society, 2004). We found that only 13% of SUNCT patients and no SUNA patients had the primary episodic form of the disease. Most, 63% of SUNCT patients, had either primary chronic or secondary chronic SUNCT, and 89% of SUNA were of the primary chronic form. The average time from the start of the syndrome to chronicity was 8.4 years. We also report one SUNCT and one SUNA patient who had primary chronic disease, which then went into spontaneous remission for 2 and 3 years, respectively. We also note a patient with 2 years

of SUNCT, then a spontaneous remission for 14 years and then a bout lasting 8 months with remission afterwards (to date).

These data differ from CH databases, where most patients have the primary episodic form of CH (79%), and a small percentage (8%) go on to develop secondary chronic CH (Bahra *et al.*, 2002). Chronic CH can revert or evolve to secondary episodic CH in as many as 50% of affected individuals (Manzoni *et al.*, 1991).

We also report differences in the diurnal variation of SUNCT attacks. Only 7% of SUNCT patients reported predominantly nocturnal attacks as opposed to up to 73% of CH patients (Russell, 1981; Bahra *et al.*, 2002). However, a further 40% of SUNCT patients experienced attacks that could occur equally during sleep and wakefulness. This may be due to the fact that SUNCT attacks are triggered by cutaneous stimuli that would occur more often during wakefulness; however, the diurnal variation in the attacks was equally diverse between those patients who had predominantly triggered and those with mainly spontaneous attacks.

### Interictal pain

We found 20 patients with SUNCT and 2 patients with SUNA who had interictal background pain (Fig. 3). SUNCT is not usually thought of as having a component of background pain, although a persistent dull interictal ache has been described in association with SUNCT in two cases (Pareja *et al.*, 1996; Matharu *et al.*, 2004a). The differential diagnosis for what may appear to be prolonged attacks includes paroxysmal hemicrania and CH. For constant interictal pain the differential diagnosis would include hemicrania continua. However, there are important clinical characteristics that lead to the suspicion of a diagnosis of SUNCT, such as the cutaneous (or other) triggerability of attacks and the lack of a response to indomethacin. We find it helpful to perform a controlled indomethacin test to rule out paroxysmal hemicrania and hemicrania continua (Matharu *et al.*, 2004b), and also to assess the response to high-flow inhaled oxygen and sumatriptan subcutaneously, which would be more characteristic of CH (Lance and Goadsby, 2005). In our cohort, oxygen was unhelpful in 100% of patients, and the indomethacin test showed no distinction between indomethacin and saline placebo in all patients (Cohen *et al.*, 2005b).

### Concomitant headache, migraine and background pain

As seen in Fig. 3, 34% of our patients had a personal history of migraine and 50% had migrainous biology. This is in contrast to the 11–15% migraine prevalence in the general population (Steiner *et al.*, 2003). Migraine is considered to be more common in patients with CH (Bahra *et al.*, 2002), and may co-exist with paroxysmal hemicrania (Cohen *et al.*, 2004a). The increased prevalence of migraine in our population of SUNCT and SUNA patients may reflect a

predisposition for primary headache syndromes, or simply that the patients more readily are coming to medical attention because of the SUNCT/SUNA. Patients with primary headache syndromes, notably migraine (Bahra *et al.*, 2003) or CH (Paemeleire *et al.*, 2004), may develop chronic daily headache with analgesic overuse. SUNCT and SUNA patients with migraine biology, especially those who overuse analgesics, may also be at increased risk of developing an interictal chronic background pain.

### Family history

There is only one reported case in the literature of a family history of SUNCT (Gantenbein and Goadsby, 2005). This case is in our database (#12). It is well known that migraine has a significant genetic component (Ferrari, 1998), and this is strengthened by the description of clear genetic mutations in familial hemiplegic migraine (Ophoff *et al.*, 1996; De Fusco *et al.*, 2003; Dichgans *et al.*, 2005). As for the TACs, there have been reports of familial CH (Leone *et al.*, 2001; El Amrani *et al.*, 2002), and, recently, familial paroxysmal hemicrania (Cohen *et al.*, 2004a). These syndromes are so rare that an accurate evaluation of their genetic status is difficult, although a primarily inherited basis seems a reasonable way to think about the underlying determinant for these syndromes.

### Triggers

It is known that the following can trigger SUNCT attacks: touching the face or scalp, washing, shaving, chewing, eating, brushing teeth, talking and coughing (Pareja and Sjaastad, 1997). We add to this list the following as potential triggers: washing or brushing the hair, light (including sunlight and fluorescent lights), blowing the nose, exercise and showering. Movement of the neck has previously been shown either to precipitate or abort an attack (Sjaastad *et al.*, 1989; Pareja and Sjaastad, 1997; Calvo *et al.*, 2004). Triggers that are characteristically associated with CH, such as alcohol, smoke, strong smells and a warm environment (Matharu and Goadsby, 2002b), can trigger SUNCT or SUNA in a small proportion of patients. It is known that patients can have a mixture of spontaneous and triggered attacks, but purely triggered attacks (2% in our series) are hitherto unreported. This may be due to the fact that purely triggered attacks have been previously diagnosed as TN. It is therefore useful to recognize that some patients with SUNCT syndrome may experience only triggered, and not spontaneous, attacks.

### Refractory period

Unlike TN, SUNCT patients have generally been thought not to have a refractory period (Pareja and Sjaastad, 1997; Matharu *et al.*, 2003a). Our case series bears out the general lack of a refractory period between attacks, so that 92% of all patients can experience one attack spontaneously occurring immediately after the previous one, or that they can trigger an attack immediately on top of the previous one.

This serves as a good clinical feature to distinguish TN and SUNCT, and should be asked of all patients who are suspected to have SUNCT or TN.

### Neurological examination

Generally, the neurological examination is normal in SUNCT. There are some reports of allodynia or hyperaesthesia in the face (Pareja and Sjaastad, 1997; Raimondi and Gardella, 1998; Graff-Radford, 2000; Sabatowski *et al.*, 2001), and a case of post-traumatic SUNCT with a sensory deficit in V<sub>1</sub> (Putzki *et al.*, 2005), and one with a persistent ipsilateral Horner's syndrome (Prakash and Lo, 2004). We report six patients with SUNCT (12%) with abnormal sensation to pinprick in V<sub>1</sub> and V<sub>2</sub>, and one with SUNA (11%). Interestingly, only one patient had hyperaesthesia (#46). He also had vascular loops compressing on his trigeminal nerve root bilaterally. The hyperaesthesia was only on the side ipsilateral to the pain. Five of six SUNCT patients had reduced sensation to pinprick, and in none of them was the SUNCT attributable to a structural cause. Therefore, reduced facial sensation may occur in SUNCT and SUNA as a normal part of the syndromes. Trigeminal sensory pathways can be impaired in CH as reflected by measurements of trigeminal somatosensory evoked potentials (van Vliet *et al.*, 2003b), and this was thought to be due to higher cortical functions or central neuroplasticity (van Vliet *et al.*, 2003a). This may also be due to hypothalamic activity in SUNCT or SUNA. The hypothalamus is known to have a role in general nociceptive control (Millan *et al.*, 1983); there are direct hypothalamic-trigeminal connections (Malick and Burstein, 1998; Malick *et al.*, 2000) and the hypothalamus is known to have a modulatory role on the nociceptive and autonomic pathways, specifically trigeminovascular nociceptive pathways (Bartsch *et al.*, 2004).

One patient with SUNCT had abnormal facial sensation after an infraorbital nerve block, which did nothing to stop the attacks. This is consistent with the notion that SUNCT is a centrally driven pain syndrome, as even with iatrogenic reduction of sensation the attacks still occurred. This is also seen in CH, where attacks have continued despite surgical ablation of the trigeminal nerve (Matharu and Goadsby, 2002a).

### Symptomatic SUNCT

Most cases of SUNCT are idiopathic, but there are a few cases in the literature that are secondary to intracranial lesions. These are either due to pituitary lesions or posterior fossa lesions. We report here three cases of pituitary lesions causing SUNCT. Two macroadenomas, one of whose symptoms resolved completely and one almost completely on treatment of the pituitary lesion, and one microprolactinoma whose symptoms resolved initially for 8 months and then recurred with return of the tumour. One of the patients with macroadenoma has been reported previously (Matharu *et al.*, 2003b). A patient with a pituitary macroadenoma had reported symptoms of SUNCT, which were labelled as TN

(Ferrari *et al.*, 1988). SUNCT has been described in patients with microprolactinomas (Levy *et al.*, 2003) and macroprolactinomas (Massiou *et al.*, 2002; Matharu *et al.*, 2003b), with attacks occurring on the side ipsilateral to the side of the tumour, suggesting a role for a direct or mechanical mode of action in macroadenomas, but this would not account satisfactorily for microadenomas. It has therefore been suggested that the attacks were predominantly neurohormonally mediated rather than by the size or invasiveness of the tumour (Matharu *et al.*, 2003b). It is also interesting to note that headache symptoms can precede pituitary symptoms by 3–10 years (Ferrari *et al.*, 1988; Massiou *et al.*, 2002). It is now seen that headache symptoms can continue beyond the treatment of the tumours as a general principle (Levy *et al.*, 2005) as in one of our patients (#20).

Cases of symptomatic SUNCT secondary to a posterior fossa abnormality include the following: ipsilateral cerebellopontine arteriovenous malformations in two patients (Bussone *et al.*, 1991; Morales *et al.*, 1994), a brainstem cavernous haemangioma (De Benedittis, 1996), a posterior fossa lesion associated with HIV/AIDS (Goadsby and Lipton, 1997), severe basilar impression causing pontomedullary compression in a patient with osteogenesis imperfecta (ter Berg and Goadsby, 2001), craniostosis resulting in a foreshortened posterior fossa (Moris *et al.*, 2001) and ischaemic brainstem infarction (Penart *et al.*, 2001). We report one new case of SUNCT secondary to an acute event of dizziness and ataxia, with an unusual configuration in the brainstem and lacune in the thalamus (#2). We have one case of SUNCT with pathological white matter changes and a lesion in the ipsilateral cerebral peduncle (#52). We also have a case of SUNA apparently related to multiple sclerosis with lesions in the midbrain and pons that might account for the pain (#SUNA4).

Rare cases of SUNCT have been reported in association with vascular compression of the trigeminal nerve (Gardella *et al.*, 2001; Koseoglu *et al.*, 2005), in contrast to TN, for which the incidence of trigeminal nerve compression is 47–90% (Kuroiwa *et al.*, 1996; Majoie *et al.*, 1997; Love and Coakham, 2001). In our series, only three SUNCT patients (7%) have vascular compression: one with the compression ipsilateral to the pain (#13), one with bilateral vascular compressions but only unilateral pain (#56) and one with unilateral compression but bilateral pain (#55). The question therefore arises as to the role of trigeminal nerve root compression by vascular loops, as it is possible to have vascular compression without attacks, and also attacks on the side contralateral to the compression. It may be that the vascular loops are incidental findings.

One SUNCT patient had generalized cerebral white matter lesions (#7), and two patients had parietal or parieto-occipital lesions that anatomically may not account for the pain: #57 and 51, who also had an ipsilateral VI nerve and contralateral XII nerve palsy due to a head injury. It is unclear as to whether these lesions were a direct cause of the SUNCT attacks, or whether they are incidental findings unassociated

with the headache symptoms. Indeed, in both patients with space-occupying lesions the symptoms persisted even after their excision.

## SUNA

SUNA may include SUNCT and simplifies the classification of patients without the C or the T component. However, for the moment, given how distinctive SUNCT is clinically, keeping the separation may be useful. SUNA patients have attacks similar to SUNCT in location, duration, frequency and severity, but there is a lack of conjunctival injection, and instead there are other cranial autonomic symptoms (Headache Classification Committee of The International Headache Society, 2004). Pure SUNA is rather rare, having only one other case reported in the literature (Volcy *et al.*, 2005). The clinical phenotype and response to medications are in most other respects very similar to SUNCT. The reason for labelling these patients with the diagnosis of SUNA is partly because SUNCT by definition requires conjunctival injection and tearing, and partly because there may be many more patients in general neurological and clinical practice who have SUNA but have been misdiagnosed because of the lack of autonomic symptoms in the eye. We report the only series of patients in the literature with SUNA. Most patients had primary chronic SUNA, with one patient experiencing spontaneous remission, as opposed to the 65% of SUNCT patients who had episodic SUNCT at some point during their disease.

The site of attacks was more varied for SUNA than SUNCT; particularly, the temple, side of the head and V<sub>3</sub> were affected more in SUNA than in SUNCT. There were no SUNA patients whose attacks could be triggered by touch, as opposed to 63% of SUNCT patients in whom touching the face could trigger attacks. Cranial autonomic symptoms were more varied in SUNA, without the duo of conjunctival injection and lacrimation, and with more diverse autonomic symptoms, such as mydriasis and ear flushing, which were not present in SUNCT. Indeed, one would predict from the experimental and human physiology that a different involvement of the trigeminal sub-divisions would produce differences in the activation of the cranial autonomic pathways (Goadsby *et al.*, 1997; May *et al.*, 2001). All of these differences, which would be contrary to the usual picture of SUNCT, could account for the underdiagnosis of SUNA in the general and neurological clinics. However, the basic phenotype of the disease remains the same in SUNCT and SUNA, that is, the length, frequency and severity of attacks; the type and temporal character of the pain; the presence of cranial autonomic symptoms; the ability to trigger attacks, the lack of refractory period between attacks, and the nocturnal occurrence, but not preponderance, of attacks. We propose changes to the current classification based on our cases (Table 9).

## Pathophysiology of SUNCT

Features characteristic of all TACs are pain in the trigeminal distribution (usually, but not always in the first trigeminal

**Table 9** Diagnostic criteria

## Current diagnostic criteria

*Short-lasting unilateral neuralgiform headache attacks with conjunctival injection and tearing (SUNCT)*

## 3.3 Diagnostic criteria

- A. At least 20 attacks fulfilling criteria B–E
- B. Attacks of unilateral, orbital, supraorbital or temporal stabbing or pulsating pain last 5–240 s
- C. Pain is accompanied by ipsilateral conjunctival injection and lacrimation
- D. Attacks occur with a frequency from 3 to 200 per day
- E. Not attributed to another disorder

*Short-lasting unilateral neuralgiform headache attacks with cranial autonomic symptoms (SUNA)*

## A 3.3 Diagnostic criteria

- A. At least 20 attacks fulfilling criteria B–E
- B. Attacks of unilateral orbital, supraorbital or temporal stabbing pain lasting from 2 s to 10 min
- C. Pain is accompanied by one of
  - 1. conjunctival injection and/or tearing
  - 2. nasal congestion and/or rhinorrhoea
  - 3. eyelid oedema
- D. Attacks occur with a frequency of  $\geq 1$  per day for more than half the time
- E. Not attributed to another disorder

## A 3.3.1 Episodic SUNA

Description: SUNA attacks occurring for 7 days to 1 year with pain-free intervals longer than 1 month

## A 3.3.2 Chronic SUNA

Description: At least 2 attack periods last 7 days to 1 year separated by remission periods of &lt;1 month (untreated)

## Proposed diagnostic criteria

*Short-lasting unilateral neuralgiform headache attacks with conjunctival injection and tearing (SUNCT) or cranial autonomic features (SUNA)*

## 3.3R Diagnostic criteria

- A. At least 20 attacks fulfilling criteria B–E
- B. Attacks of short-lasting (1–600 s) unilateral head pain
  - a. Orbital, supraorbital, temporal or other trigeminal distribution of moderate or severe pain
  - b. Occurring as
    - i. single stabs
    - ii. groups of stabs
    - iii. in a saw-tooth pattern
  - c. Triggerable without a refractory period
- C. Pain is accompanied ipsilaterally by either
  - a. conjunctival injection and tearing (SUNCT), or
  - b. one or more of the following cranial autonomic symptoms (SUNA)
    - i. Conjunctival injection, or tearing, but not both
    - ii. Nasal congestion and/or rhinorrhoea
    - iii. Eyelid oedema
    - iv. Ipsilateral sense of aural fullness or peri-aural swelling
    - v. Ipsilateral forehead and facial sweating
    - vi. Ipsilateral miosis and/or ptosis
- D. Attacks occur with a frequency of  $\geq 1$  per day for more than half the time when the disorder is active
- E. Not attributed to another disorder

## A 3.3.1 Episodic SUNCT/SUNA

Description: SUNA attacks occurring for 7 days to 1 year with pain-free intervals longer than 1 month

## A 3.3.2 Chronic SUNCT/SUNA

Description: At least 2 attack periods last 7 days to 1 year separated by remission periods of &lt;1 month (untreated)

distribution) and ipsilateral cranial autonomic features (Goadsby, 2005). The pain-producing innervation of the head projects via branches of the trigeminal and upper cervical nerves to the trigeminocervical complex, from where nociceptive pathways project to higher centres. It has been suggested that the pathophysiology of these syndromes revolves around the trigeminal-autonomic reflex (Goadsby

and Lipton, 1997). There is considerable experimental animal literature to document that stimulation of trigeminal efferents can result in cranial autonomic outflow, the trigeminal-autonomic reflex (May and Goadsby, 1999). In fact, some degree of cranial autonomic symptomatology is a normal physiological response to cranial nociceptive input (May *et al.*, 2001), and patients with other headache syndromes



may report these symptoms (Benoliel and Sharav, 1998a, b; Barbanti *et al.*, 2002). The distinction between these and other headache syndromes is the degree of cranial autonomic activation. It has been proposed that the cranial autonomic symptoms may be prominent in these syndromes owing to a central disinhibition of the trigeminal-autonomic reflex by the hypothalamus (Goadsby and Lipton, 1997). Indeed, there are direct hypothalamic-trigeminal connections (Malick and Burstein, 1998) and the hypothalamus is known to have a modulatory role on the nociceptive and autonomic pathways, specifically trigeminovascular nociceptive pathways (Bartsch *et al.*, 2004).

The understanding of the pathophysiology of primary headache syndromes had been greatly improved in recent years, with the introduction of functional imaging (Cohen and Goadsby, 2004).  $^{15}\text{H}_2\text{O}$ -PET studies have shown activation in the brainstem in migraine (Weiller *et al.*, 1995), and in the posterior hypothalamus in CH during triggered and spontaneous attacks (May *et al.*, 1998; Sprenger *et al.*, 2004), and paroxysmal hemicrania (Matharu *et al.*, 2006), but not in migraine (Bahra *et al.*, 2001; Afridi *et al.*, 2005a, b). Voxel-based morphometry has shown a significant difference in hypothalamic grey matter density between CH patients and healthy controls (May *et al.*, 1999a). Functional MRI (fMRI) has been employed to show hypothalamic activation during attacks of SUNCT (May *et al.*, 1999b; Cohen *et al.*, 2004c; Sprenger *et al.*, 2005) and in a TAC not otherwise specified (Sprenger *et al.*, 2004), which is probably a longer-lasting attack of SUNCT. Hemicrania continua, which is not a TAC but shares some similar phenotypic qualities with the TACs, shows both hypothalamic and brainstem activity (Matharu *et al.*, 2004b). In terms of clinical relevance, deep brain electrical stimulation of the posterior hypothalamus has had beneficial effects in both intractable CH and SUNCT (Leone *et al.*, 2004, 2005). Hence, SUNCT, as the other TACs, probably results from an abnormality in the region of the hypothalamus with subsequent trigeminovascular and cranial autonomic activation.

## Summary

We have undertaken a prospective clinical study in 52 patients with SUNCT and SUNA. Our study reports 43 patients with SUNCT and 9 with SUNA. The clinical phenotype of both conditions has been characterized. We suggest changes to the International Headache Society classification on the basis of these cases. In view of the widely varying range of attack character, frequency and duration, it appears that many patients were misdiagnosed with conditions such as TN and other TACs, such as CH and paroxysmal hemicrania. We propose a system of assessing the temporal pattern, duration and frequency of attacks in terms of stabs, groups of stabs and saw-tooth attacks, and the concept of attack load in terms of minutes of pain per day. We note the concept of a constant background pain in these syndromes, and the implication this has on patients with a history of

migraine, migraine biology and analgesic overuse. We also note the ability to trigger attacks, specifically the concept of attacks that are 100% triggered, and the overwhelming lack of a refractory period between attacks that seems characteristic of SUNCT/SUNA. In terms of symptomatic SUNCT/SUNA, we note the importance of posterior fossa abnormalities. The concept of post-traumatic SUNCT and SUNA has been discussed, as has the issue of vascular loops compressing on the trigeminal nerve root, for which the evidence as a causative factor to the pain is much less robust than in TN. The role of the hypothalamus as a generator for these attacks has been discussed in the wider context of the other TACs, and also with specific functional imaging evidence of hypothalamic activation in SUNCT. Further studies will emerge, including an fMRI series in SUNCT/SUNA and a detailed clinical study of pharmacological manipulations in this syndrome.

## References

- Afridi S, Giffin NJ, Kaube H, Friston KJ, Ward NS, Frackowiak RSJ, *et al.* A PET study in spontaneous migraine. *Arch Neurol* 2005a; 62: 1270–5.
- Afridi S, Matharu MS, Lee L, Kaube H, Friston KJ, Frackowiak RSJ, *et al.* A PET study exploring the laterality of brainstem activation in migraine using glyceryl trinitrate. *Brain* 2005b; 128: 932–9.
- Antonaci F, Sjaastad O. Chronic paroxysmal hemicrania (CPH): a review of the clinical manifestations. *Headache* 1989; 29: 648–56.
- Bahra A, Matharu MS, Buchel C, Frackowiak RSJ, Goadsby PJ. Brainstem activation specific to migraine headache. *Lancet* 2001; 357: 1016–7.
- Bahra A, May A, Goadsby PJ. Cluster headache: a prospective clinical study in 230 patients with diagnostic implications. *Neurology* 2002; 58: 354–61.
- Bahra A, Walsh M, Menon S, Goadsby PJ. Does chronic daily headache arise de novo in association with regular analgesic use? *Headache* 2003; 43: 179–90.
- Barbanti P, Fabbri G, Pesare M, Vanacore N, Cerbo R. Unilateral cranial autonomic symptoms in migraine. *Cephalalgia* 2002; 22: 256–9.
- Bartsch T, Levy MJ, Knight YE, Goadsby PJ. Differential modulation of nociceptive dural input to [hypocretin] orexin A and B receptor activation in the posterior hypothalamic area. *Pain* 2004; 109: 367–78.
- Benoliel R, Sharav Y. SUNCT syndrome: case report and literature review. *Oral Surg Oral Med Oral Pathol Oral Radiol Endod* 1998a; 85: 158–61.
- Benoliel R, Sharav Y. Trigeminal neuralgia with lacrimation or SUNCT syndrome? *Cephalalgia* 1998b; 18: 85–90.
- Bigal ME, Rapoport AM, Sheftell FD, Tepper SJ, Lipton RB. Transformed migraine and medication overuse in a tertiary headache centre—clinical characteristics and treatment outcomes. *Cephalalgia* 2004; 24: 483–90.
- Boes CJ, Swanson JW, Dodick DW. Chronic paroxysmal hemicrania presenting as otalgia with a sensation of external acoustic meatus obstruction: two cases and a pathophysiologic hypothesis. *Headache* 1998; 38: 787–91.
- Bussone G, Leone M, Volta GD, Strada L, Gasparotti R. Short-lasting unilateral neuralgiform headache attacks with tearing and conjunctival injection: the first symptomatic case. *Cephalalgia* 1991; 11: 123–7.
- Calvo JF, Bruera OC, de Lourdes Figuerola M, Gestro D, Tinetti N, Leston JA. SUNCT syndrome: clinical and 12-year follow-up case report. *Cephalalgia* 2004; 24: 900–2.
- Cohen AS, Goadsby PJ. Functional neuroimaging of primary headache disorders. *Curr Neurol Neurosci Rep* 2004; 4: 105–10.
- Cohen AS, Matharu MS, Goadsby PJ. Familial paroxysmal hemicrania. *Cephalalgia* 2004a; 24: 1099.
- Cohen AS, Matharu MS, Goadsby PJ. SUNCT syndrome in the elderly. *Cephalalgia* 2004b; 24: 508–9.

- Cohen AS, Matharu MS, Kalisch R, Friston K, Goadsby PJ. Functional MRI in SUNCT shows differential hypothalamic activation with increasing pain. *Cephalalgia* 2004c; 24: 1098–9.
- Cohen AS, Matharu MS, Goadsby PJ. Revisiting the International Headache Society Criteria for SUNCT and SUNA: a case series of 52 patients. *Cephalalgia* 2005a; 25: 1194.
- Cohen AS, Matharu MS, Goadsby PJ. Suggested guidelines for treating SUNCT and SUNA. *Cephalalgia* 2005b; 25: 1200.
- D'Andrea G, Granella F. SUNCT syndrome: the first case in childhood. *Cephalalgia* 2001; 21: 701–2.
- D'Andrea G, Granella F, Ghiotto N, Nappi G. Lamotrigine in the treatment of SUNCT syndrome. *Neurology* 2001; 57: 1723–5.
- De Benedittis G. SUNCT syndrome associated with cavernous angioma of the brain stem. *Cephalalgia* 1996; 16: 503–6.
- De Fusco M, Marconi R, Silvestri L, Atorino L, Rampoldi L, Morgante L, et al. Haploinsufficiency of ATP1A2 encoding the Na<sup>+</sup>/K<sup>+</sup> pump  $\alpha 2$  subunit associated with familial hemiplegic migraine type 2. *Nat Genet* 2003; 33: 192–6.
- Dichgans M, Freilinger T, Eckstein G, Babini E, Lorenz-Depiereux B, Biskup S, et al. Mutation in the neuronal voltage-gated sodium channel *SCN1A* causes familial hemiplegic migraine. *Lancet* 2005; 366: 371–7.
- Drummond PD. A quantitative assessment of photophobia in migraine and tension headache. *Headache* 1986; 26: 465–9.
- El Amrani M, Ducros A, Boulan P, Aidi S, Crassard I, Visy JM, et al. Familial cluster headache: a series of 186 index patients. *Headache* 2002; 42: 974–7.
- Ferrari MD. Migraine. *Lancet* 1998; 351: 1043–51.
- Ferrari MD, Haan J, van Setters AP. Bromocriptine-induced trigeminal neuralgia attacks in a patient with pituitary tumor. *Neurology* 1988; 38: 1482–4.
- Gantenbein A, Goadsby PJ. Familial SUNCT. *Cephalalgia* 2005; 25: 457–9.
- Gardella L, Viruega A, Rojas H, Nagel J. A case of a patient with SUNCT syndrome treated with Jannetta procedure. *Cephalalgia* 2001; 21: 996–9.
- Goadsby PJ. Trigeminal autonomic cephalalgias (TACs): another fancy term or a constructive change to the International Headache Classification? *J Neurol Neurosurg Psychiatr* 2005; 76: 301–5.
- Goadsby PJ, Lipton RB. A review of paroxysmal hemicranias, SUNCT syndrome and other short-lasting headaches with autonomic features, including new cases. *Brain* 1997; 120: 193–209.
- Goadsby PJ, Knight YE, Hoskin KL, Butler P. Stimulation of an intracranial trigeminally-innervated structure selectively increases cerebral blood flow. *Brain Research* 1997; 751: 247–52.
- Goadsby PJ, Matharu MS, Boes CJ. SUNCT syndrome or trigeminal neuralgia with lacrimation. *Cephalalgia* 2001; 21: 82–3.
- Graff-Radford SB. SUNCT syndrome responsive to gabapentin. *Cephalalgia* 2000; 20: 515–7.
- Headache Classification Committee of The International Headache Society. (2004) The International Classification of Headache Disorders: 2nd edition. *Cephalalgia* 2004; 24 (Suppl. 1): 1–160.
- Irimia P, Cittadini E, Paemeleire K, Cohen A, Kaube H, Goadsby PJ. Unilateral phonophobia and photophobia: a helpful symptom for the diagnosis of trigeminal autonomic cephalalgias (TACs) and hemicrania continua (HC). *Cephalalgia* 2005: 856.
- Jimenez-Huete A, Franch O, Pareja JA. SUNCT syndrome: priming of symptomatic periods and worsening of symptoms by treatment with calcium channel blockers. *Cephalalgia* 2002; 22: 812–4.
- Koseoglu E, Karaman Y, Kucuk S, Arman F. SUNCT syndrome associated with compression of trigeminal nerve. *Cephalalgia* 2005; 25: 473–5.
- Kuroiwa T, Matsumoto S, Kato A, Harano K, Totoki T, Tabuchi K. MR imaging of idiopathic trigeminal neuralgia: correlation with non-surgical therapy. *Radiat Med* 1996; 14: 235–9.
- Lance JW. The red ear syndrome. *Neurology* 1996; 47: 617–20.
- Lance JW, Goadsby PJ. Mechanism and management of headache. New York: Elsevier; 2005.
- Leone M, Russell MB, Rigamonti A, Attanasio A, Grazzi L, D'Amico D, et al. Increased familial risk of cluster headache. *Neurology* 2001; 56: 1233–6.
- Leone M, Franzini A, Broggi G, May A, Bussone G. Long-term follow-up of bilateral hypothalamic stimulation for intractable cluster headache. *Brain* 2004; 127: 2259–64.
- Leone M, Franzini A, D'Andrea G, Broggi G, Casucci G, Bussone G. Deep brain stimulation to relieve drug-resistant SUNCT. *Ann Neurol* 2005; 57: 924–7.
- Levy MJ, Matharu MS, Goadsby PJ. Prolactinomas, dopamine agonist and headache: two case reports. *Eur J Neurol* 2003; 10: 169–174.
- Levy MJ, Matharu MS, Meeran K, Powell M, Goadsby PJ. The clinical characteristics of headache in patients with pituitary tumours. *Brain* 2005; 128: 1921–30.
- Love S, Coakham HB. Trigeminal neuralgia: pathology and pathogenesis. *Brain* 2001; 124: 2347–60.
- Majoie CB, Hulsmans FJ, Verbeeten B Jr, Castelijns JA, van Beek EJ, Valk J. Trigeminal neuralgia: comparison of two MR imaging techniques in the demonstration of neurovascular contact. *Radiology* 1997; 204: 455–60.
- Malick A, Burstein R. Cells of origin of the trigeminohypothalamic tract in the rat. *J Comp Neurol* 1998; 400: 125–44.
- Malick A, Strassman AM, Burstein R. Trigemino-hypothalamic and reticulohypothalamic tract neurons in the upper cervical spinal cord and caudal medulla of the rat. *J Neurophysiol* 2000; 84: 2078–112.
- Malik K, Rizvi S, Vaillancourt PD. The SUNCT syndrome: successfully treated with lamotrigine. *Pain Med* 2002; 3: 167–8.
- Manzoni GC, Miceli G, Granella F, Tassorelli C, Zanferrari C, Cavallini A. Cluster headache—course over ten years in 189 patients. *Cephalalgia* 1991; 11: 169–74.
- Massiou H, Launay JM, Levy C, El Amran M, Emperauger B, Bousser M-G. SUNCT syndrome in two patients with prolactinomas and bromocriptine-induced attacks. *Neurology* 2002; 58: 1698–9.
- Matharu MS, Goadsby PJ. Persistence of attacks of cluster headache after trigeminal nerve root section. *Brain* 2002a; 125: 976–84.
- Matharu MS, Goadsby PJ. Trigeminal autonomic cephalgias. *J Neurol Neurosurg Psychiatr* 2002b; 72: ii19–26.
- Matharu MS, Cohen AS, Boes CJ, Goadsby PJ. SUNCT syndrome: a review. *Curr Pain Headache Rep* 2003a; 7: 308–18.
- Matharu MS, Levy MJ, Merry RT, Goadsby PJ. SUNCT syndrome secondary to prolactinoma. *J Neurol Neurosurg Psychiatr* 2003b; 74: 1590–2.
- Matharu MS, Cohen AS, Goadsby PJ. SUNCT syndrome responsive to intravenous lidocaine. *Cephalalgia* 2004a; 24: 985–92.
- Matharu MS, Cohen AS, McGonigle DJ, Ward N, Frackowiak RSJ, Goadsby PJ. Posterior hypothalamic and brainstem activation in hemicrania continua. *Headache* 2004b; 44: 747–61.
- Matharu MS, Cohen AS, Frackowiak RSJ, Goadsby PJ. Posterior hypothalamic activation in paroxysmal hemicrania. *Ann Neurol* 2006; 59: 535–45.
- May A, Goadsby PJ. The trigeminovascular system in humans: pathophysiological implications for primary headache syndromes of the neural influences on the cerebral circulation. *J Cereb Blood Flow Metab* 1999; 19: 115–27.
- May A, Bhatta A, Buchel C, Frackowiak RSJ, Goadsby PJ. Hypothalamic activation in cluster headache attacks. *Lancet* 1998; 352: 275–8.
- May A, Ashburner J, Buchel C, McGonigle DJ, Friston KJ, Frackowiak RSJ, et al. Correlation between structural and functional changes in brain in an idiopathic headache syndrome. *Nat Med* 1999a; 5: 836–8.
- May A, Bhatta A, Buchel C, Turner R, Goadsby PJ. Functional MRI in spontaneous attacks of SUNCT: short-lasting neuralgiform headache with conjunctival injection and tearing. *Ann Neurol* 1999b; 46: 791–3.
- May A, Buchel C, Turner R, Goadsby PJ. MR-angiography in facial and other pain: neurovascular mechanisms of trigeminal sensation. *J Cereb Blood Flow Metab* 2001; 21: 1171–6.
- Millan MJ, Przewlocki R, Millan MH, Herz A. Evidence for a role of the ventro-medial posterior hypothalamus in nociceptive processes in the rat. *Pharmacol Biochem Behav* 1983; 18: 901–7.
- Morales F, Mostacero E, Marta J, Sanchez S. Vascular malformation of the cerebellopontine angle associated with SUNCT syndrome. *Cephalalgia* 1994; 14: 301–2.

- Moris G, Ribacoba R, Solar DN, Vidal JA. SUNCT syndrome and seborrheic dermatitis associated with craniostenosis. *Cephalalgia* 2001; 21: 157–9.
- Newman LC, Lipton RB, Solomon S. Hemicrania continua: ten new cases and a review of the literature. *Neurology* 1994; 44: 2111–4.
- Ophoff RA, Terwindt GM, Vergouwe MN, van Eijk R, Oefner PJ, Hoffman SMG, et al. Familial hemiplegic migraine and episodic ataxia type-2 are caused by mutations in the  $\text{Ca}^{2+}$  channel gene CACNL1A4. *Cell* 1996; 87: 543–52.
- Paemeleire K, Bahra A, Evers S, Matharu MS, Goadsby PJ. Medication-overuse headache in cluster headache patients. *Cephalalgia* 2004; 24: 1101.
- Pareja JA, Sjaastad O. SUNCT syndrome. A clinical review. *Headache* 1997; 37: 195–202.
- Pareja JA, Kruszewski P, Sjaastad O. SUNCT syndrome: trials of drugs and anesthetic blockades. *Headache* 1995; 35: 138–42.
- Pareja JA, Joubert J, Sjaastad O. SUNCT syndrome. Atypical temporal patterns. *Headache* 1996; 36: 108–10.
- Penart A, Firth M, Bowen JRC. Short-lasting unilateral neuralgiform headache with conjunctival injection and tearing (SUNCT) following presumed dorsolateral brainstem infarction. *Cephalalgia* 2001; 21: 236–9.
- Prakash KM, Lo YL. SUNCT syndrome in association with persistent Horner syndrome in a Chinese patient. *Headache* 2004; 24: 256–58.
- Putzki N, Nirkko A, Diener H-C. Trigeminal autonomic cephalalgias: a case of post-traumatic SUNCT syndrome? *Cephalalgia* 2005; 25: 395–7.
- Raimondi E, Gardella L. SUNCT syndrome. Two cases in Argentina. *Headache* 1998; 38: 369–71.
- Ramirez-Moreno JM, Fernandez-Portales I, Garcia-Castanon I, Gomez-Gutierrez M, Ojalvo MJ, Casado-Naranjo I. [SUNCT syndrome and neoplasms in the central nervous system. A new association]. *Neurologia* 2004; 19: 326–30.
- Rossi P, Cesarino F, Faroni J, Malpezzi MG, Sandrini G, Nappi G. SUNCT syndrome successfully treated with topiramate: case reports. *Cephalalgia* 2003; 23: 998–1000.
- Russell D. Cluster headache: severity and temporal profile of attacks and patient activity prior to and during attacks. *Cephalalgia* 1981; 1: 209–16.
- Sabatowski R, Huber M, Meuser T, Radbruch L. SUNCT syndrome: a treatment option with local opioid blockade of the superior cervical ganglion? A case report. *Cephalalgia* 2001; 21: 154–6.
- Sjaastad O, Russell D, Horven I, Bunnaes U. Multiple neuralgiform unilateral headache attacks associated with conjunctival injection and appearing in clusters. A nosological problem. *Proc Scand Migr Soc Arhus* 1978: 31.
- Sjaastad O, Saunte C, Salvesen R, Fredriksen TA, Seim A, Roe OD, et al. Short-lasting unilateral neuralgiform headache attacks with conjunctival injection, tearing, sweating, and rhinorrhea. *Cephalalgia* 1989; 9: 147–56.
- Sprenger T, Boecker H, Tolle TR, Bussone G, May A, Leone M. Specific hypothalamic activation during a spontaneous cluster headache attack. *Neurology* 2004; 62: 516–7.
- Sprenger T, Valet M, Platzer S, Pfaffenrath V, Steude U, Tolle TR. SUNCT: bilateral hypothalamic activation during headache attacks and resolving of symptoms after trigeminal decompression. *Pain* 2005; 113: 422–6.
- Steiner TJ, Scher AI, Stewart WF, Kolodner K, Liberman J, Lipton RB. The prevalence and disability burden of adult migraine in England and their relationships to age, gender and ethnicity. *Cephalalgia* 2003; 23: 519–27.
- ter Berg HWM, Goadsby PJ. Significance of atypical presentation of symptomatic SUNCT: a case report. *J Neurol, Neurosurg Psychiatry* 2001; 70: 244–6.
- Torelli P, Manzoni GC. Pain and behaviour in cluster headache. A prospective study and review of the literature. *Funct Neurol* 2003; 18: 205–10.
- van Vliet JA, Eekers PJ, Haan J, Ferrari MD. Dutch RUSSH Study Group. Features involved in the diagnostic delay of cluster headache. *J Neurol Neurosurg Psychiatry* 2003a; 74: 1123–5.
- van Vliet JA, Ferrari MD, Haan J. SUNCT syndrome resolving after contralateral hemispheric ischaemic stroke. *Cephalalgia* 2003b; 23: 235–7.
- Vingen JV, Pareja JA, Stovner LJ. Quantitative evaluation of photophobia and phonophobia in cluster headache. *Cephalalgia* 1998; 18: 250–6.
- Volcy M, Tepper S, Rapoport A, Sheftell F, Bigal M. Short-lasting unilateral neuralgiform headache attacks with cranial autonomic symptoms (SUNA)—a case report. *Cephalalgia* 2005; 25: 470–2.
- Weiller C, May A, Limmroth V, Juptner M, Kaube H, Schayck RV, et al. Brain stem activation in spontaneous human migraine attacks. *Nat Med* 1995; 1: 658–60.