

REVIEW ARTICLE

Spatial neglect—a vestibular disorder?

Hans-Otto Karnath¹ and Marianne Dieterich²

¹Section Neuropsychology, Department of Cognitive Neurology, Hertie-Institute for Clinical Brain Research, University of Tübingen, Tübingen and ²Department of Neurology, Johannes Gutenberg-University of Mainz, Mainz, Germany

Correspondence to: Prof. Hans-Otto Karnath, MD, PhD, Center of Neurology, University of Tübingen, Hoppe-Seyler-Strasse 3, D-72076 Tübingen, Germany
E-mail: Karnath@uni-tuebingen.de

The phenomenon of spatial neglect after right brain damage greatly helps our understanding of the normal mechanisms of directing and maintaining spatial attention, of spatial orientation, and the characteristics of neural representation of space. The intriguing symptom is a spontaneous orientation bias towards the right leading to neglect of objects or persons on the left. Interestingly, we observe similar symptoms namely a spontaneous bias of eyes and head along the horizontal dimension of space in patients with unilateral vestibular dysfunction. Further similarities concern anatomical findings. Both spatial neglect and vestibular processing at cortical level show dominance in the right hemisphere and involve common brain areas. Lesion studies in human and monkey, electrical and transcranial magnetic stimulation, as well as functional imaging results have revealed the superior temporal cortex, insula and the temporo-parietal junction to be substantial parts of the multisensory (vestibular) system as well as to be affected in spatial neglect. We argue that these structures are not strictly ‘vestibular’ but rather have a multimodal character representing a significant site for the neural transformation of converging vestibular, auditory, neck proprioceptive and visual input into higher order spatial representations. Neurons of these regions provide us with redundant information about the position and motion of our body in space. They seem to play an essential role in adjusting body position relative to external space. This view may initiate further development of those strategies to treat spatial neglect that use routes to rehabilitation based on specific manipulations of sensory input feeding into this system.

Keywords: vestibular system; vestibular dysfunction; spatial neglect; exploration; visual search; attention; temporal cortex; insula

Abbreviations: IPL = inferior parietal lobule; PIVC = parieto-insular vestibular cortex; STG = superior temporal gyrus; TPJ = temporo-parietal junction

Received August 16, 2005. Revised October 19, 2005. Accepted October 21, 2005. Advance Access publication December 21, 2005

Introduction

In recent years, the phenomenon of spatial neglect has received the attention of an increasing number of researchers. This is because it may greatly help our understanding of the normal mechanisms of directing and maintaining spatial attention, of spatial orientation, and of the characteristics of neural representation of space. In this article we concentrate on the orientation bias affecting the horizontal dimension of space. It is a unique symptom characterizing patients with neglect in contrast to other stroke patients. Our main thrust will be to investigate whether or not this orienting bias towards the right might be attributed to a dysfunction of the vestibular system. We ask whether or not spatial neglect should be regarded as a ‘vestibular disorder’ at cortical level.

Biased spatial orientation in patients with neglect

Spatial neglect is a very intriguing neurological disorder. It appears unbelievable that patients after (predominantly) right brain damage, although not blind to the side opposite to the damaged hemisphere, do not react or respond to persons or objects located in the contralesional side of space. They orient towards the right side when addressed from somewhere in the room and show a marked bias of active motor behaviour towards the right. When searching for targets, copying or reading, such patients direct their eyes and hand predominantly towards the ipsilesional right, leading to neglect of the contralesional side (Chedru *et al.*, 1973; Johnston and Diller, 1986; Hornak, 1992; Karnath, 1994a; Behrmann *et al.*, 1997;

Karnath and Perenin, 1998; Karnath *et al.*, 1998). This exploratory bias is specific for patients with spatial neglect and is not observed in other stroke patients. Thus, tasks requiring active exploratory skills such as cancellation, copying or clock drawing are used traditionally to examine spatial neglect (Weintraub and Mesulam, 1985; Gauthier *et al.*, 1989; Halligan *et al.*, 1989).

Beyond this rightward orientation bias, additional components contribute to the pathological behaviour (Husain and Rorden, 2003; Malhotra *et al.*, 2005). After initial orienting towards the right, items on this side often are recursively inspected (Husain *et al.*, 2001; Mannan *et al.*, 2005). Thus, it has been suggested that neglect patients may not retain the fact that they have already explored there. Such a non-lateralized spatial working memory deficit is not neglect-specific, as it can occur in brain-damaged patients who do not have neglect (Kessels *et al.*, 2000; Shapiro *et al.*, 2002). But when combined with the rightward bias of neglect patients, it may exacerbate neglect of contralesional locations by inducing recursive search through those rightward locations already favoured by the attentional bias (Driver and Husain, 2002).

In the following, we focus on the attentional bias of spatial neglect, not its additional components. We discuss whether this characteristic disturbance of spatial orienting represents a disorder of the vestibular system.

Consequences of unilateral dysfunction of the vestibular system

Vestibular pathways run from the VIIIth nerve and the vestibular nuclei through ascending fibres such as the medial longitudinal fasciculus to the ocular motor nuclei and the supranuclear integration centres in the pontomesencephalic and rostral mesencephalic brainstem. This part represents the three-neuron arc of the vestibulo-ocular reflex, which is embedded in a more complex sensorimotor system responsible for the orientation of eyes, head and body in space with descending input to vestibulospinal projections for head (vestibulocollic reflex) and postural control (vestibulospinal reflexes) (Abzug *et al.*, 1974; Iwamoto *et al.*, 1996; Nathan *et al.*, 1996; Nishiike *et al.*, 2000) and ascending input to thalamocortical connections for perception (Akbarian *et al.*, 1994). Coordination of eye, head and body movements during locomotion is further mediated by corticofugal connections between cortical areas and the vestibular nuclei (Nishiike *et al.*, 2000). From the midbrain, ascending fibres reach several multisensory cortical areas through thalamic projections. The two major cortical functions of the vestibular system are the perception of verticality and of self-motion. Perception of verticality relies mainly on otolith input; perception of self-motion involves otolith and semicircular canal input. The multiplicity of representations of vestibular cortex areas as identified in electrophysiological and tracer studies in animals (Fredrickson *et al.*, 1966; Schwarz *et al.*, 1971; Ödkvist *et al.*, 1974; Büttner and Büttner, 1978;

Faugier-Grimaud and Ventre, 1989; Grüsser 1990*a, b*; Guldin and Grüsser 1996; Bremmer *et al.*, 2002; Klam and Graf, 2003*a, b*; Ebata *et al.*, 2004; Schlack *et al.*, 2005) and the multisensory neuronal function of these areas argue for a network of multisensory (vestibular) areas at cortical level.

Unilateral vestibular lesion

One way to study the function of the vestibular system is to learn from its disturbance. An acute unilateral vestibular lesion, e.g. a typical vestibular neuritis, induces a tonic imbalance of the bilateral peripheral vestibular input which normally stabilizes eyes, head and body in an upright position. An acute imbalance of ocular motor, perceptual and postural functions results in rotatory vertigo, spontaneous nystagmus (with the slow nystagmus phase towards the lesioned ear), ipsilateral torsion of both eyes, ipsilateral tilts of perceived vertical, and an instability of stance and gait with ipsilateral falls (Curthoys *et al.*, 1991; Curthoys and Halmagyi, 1994). This imbalance improves gradually by central compensation within the next 4–6 weeks (Strupp *et al.*, 1998) so that many signs and symptoms fade away even when the loss of peripheral vestibular function is complete. However, some functions remain asymmetrical after unilateral loss of vestibular function, especially during movements in the higher frequency range (Aw *et al.*, 2001; Borel *et al.*, 2002; Lopez *et al.*, 2005). Similar signs and symptoms also can be elicited by acute unilateral lesions along the ascending vestibular pathways of the brainstem such as the vestibular nucleus, the medial longitudinal fasciculus and the interstitial nucleus of Cajal (integration centre for torsional and vertical eye position) (Dieterich and Brandt, 1993*a*). Among other brainstem signs patients with an acute unilateral infarction of the medullary brainstem affecting the vestibular nucleus (i.e. Wallenberg's syndrome) typically present with a tonic lateropulsion of eyes, head and body towards the lesioned side. Unilateral lesions of the posterolateral thalamus and—at the cortical level (Fig. 1)—the superior temporal cortex and the insular cortex [including the parieto-insular vestibular cortex (PIVC)] cause vestibular tonic imbalances without ocular motor deficits but with perceptual and postural deficits, namely deviations of the perceived visual vertical and lateral imbalance of stance and gait (Dieterich and Brandt, 1993*b*; Brandt *et al.*, 1994; Dieterich *et al.*, 2005).

Unilateral vestibular stimulation

Unilateral vestibular stimulation of the horizontal semicircular canal by caloric irrigation of one ear or of the whole vestibular nerve by galvanic stimulation over the mastoid also induces a tonic imbalance in the bilateral vestibular system provoking identical vestibular symptoms as observed with a unilateral lesion. The direction depends on e.g. the water temperature used for caloric irrigation of the horizontal canal (ipsilateral effects with 30°C cold water; contralateral effects with 40°C warm water). Beyond a nystagmus, unilateral vestibular stimulation in healthy subjects also

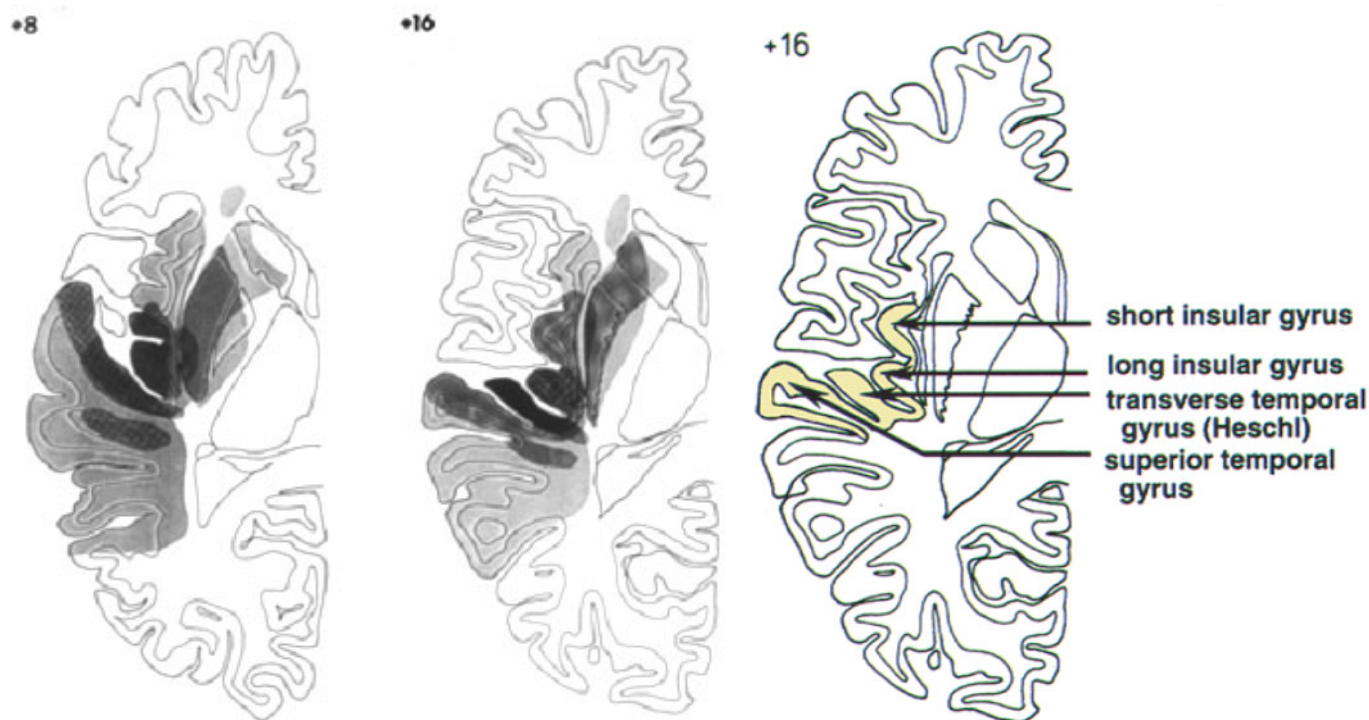


Fig. 1 Overlap of infarcted areas taken from MRI scans of seven patients with infarctions in the middle cerebral artery territory that caused significant signs of vestibular deficits (e.g. contraversive tilts of perceived vertical). The overlap centred at the STG, the posterior part of the insula, the long insular with the adjacent short insular gyrus and the transverse temporal gyrus (modified from Brandt *et al.*, 1994). Note that this study still did not use a control group for lesion analysis which causes some caveat with respect to the exact location of critical areas involved [for discussion (Rorden and Karnath, 2004)].

induces a tonic shift of the average horizontal eye position with the nystagmus (Abderhalden, 1926; Jung, 1953). This lateral bias of eye position is towards the left with left-sided cold caloric stimulation and towards the right with right-sided caloric stimulation. Figure 2 (right panel) shows an example for this effect in a healthy subject. The task of the subject was to search for a (non-existent) target in complete darkness. Beyond a nystagmus, unilateral caloric stimulation provokes a shift of the exploratory eye movements towards the side of stimulation, leading to asymmetric target search. With cold water irrigation the healthy individual illustrated in Figure 2 (right panel) even directs hardly any spontaneous eye movements towards the side opposite of stimulation. A further consequence of unilateral vestibular stimulation in healthy subjects is a tonic bias of spontaneous head orientation around the yaw axis (Karnath *et al.*, 2003a). For example, cold caloric stimulation of the right ear provokes a deviation of spontaneous head orientation of $\sim 20\text{--}30^\circ$ towards the right (Fig. 3).

Unilateral vestibular lesion and asymmetric vestibular stimulation not only seem to have similar behavioural consequences but also seem to lead to similar neuronal activity. A recent fluorodeoxyglucose (FDG)-PET study (Bense *et al.*, 2004) in patients with acute right-sided vestibular neuritis, i.e. with a lesion of the right vestibular nerve, showed an activation–deactivation pattern in the acute stage of the disorder (compared with a second examination 3 months later when the vestibular deficit was centrally compensated)

that was similar to what was found in healthy volunteers during vestibular stimulation. The pattern was found although the patients were lying with their eyes closed and had no external stimulation. This means that a patient with a unilateral vestibular neuritis under rest conditions shows cortical neuronal processing similar to that of a healthy person during artificial stimulation of his vestibular system, e.g. on a roundabout.

Similar bias of eye and head with vestibular dysfunction and with spatial neglect

Beyond nystagmus, unilateral vestibular loss in neurological patients or asymmetrical stimulation of one vestibular organ in healthy subjects provokes a tonic shift of the average horizontal position of the eyes and of the head towards the affected side (Figs 2 and 3; Abderhalden, 1926; Jung, 1953; Karnath *et al.*, 1996, 2003a). Interestingly, such a bias of eyes and head towards the right likewise is observed in patients with spatial neglect. This bias is apparent not only with active motor behaviour (exploring, copying, reading, etc.) but also even at rest when ‘doing nothing’, i.e. just sitting and waiting. Fruhmann-Berger and Karnath (2005) recorded the spontaneous eye-in-head and head-on-trunk orientation in patients with spatial neglect under rest conditions. In contrast to controls, right brain-damaged neglect patients showed a marked deviation of spontaneous eye and head orientation of about 30° towards the right (Fig. 4). A more recent study (M. Fruhmann Berger, R.D. Pross, U.J. Ilg, H.-O. Karnath,

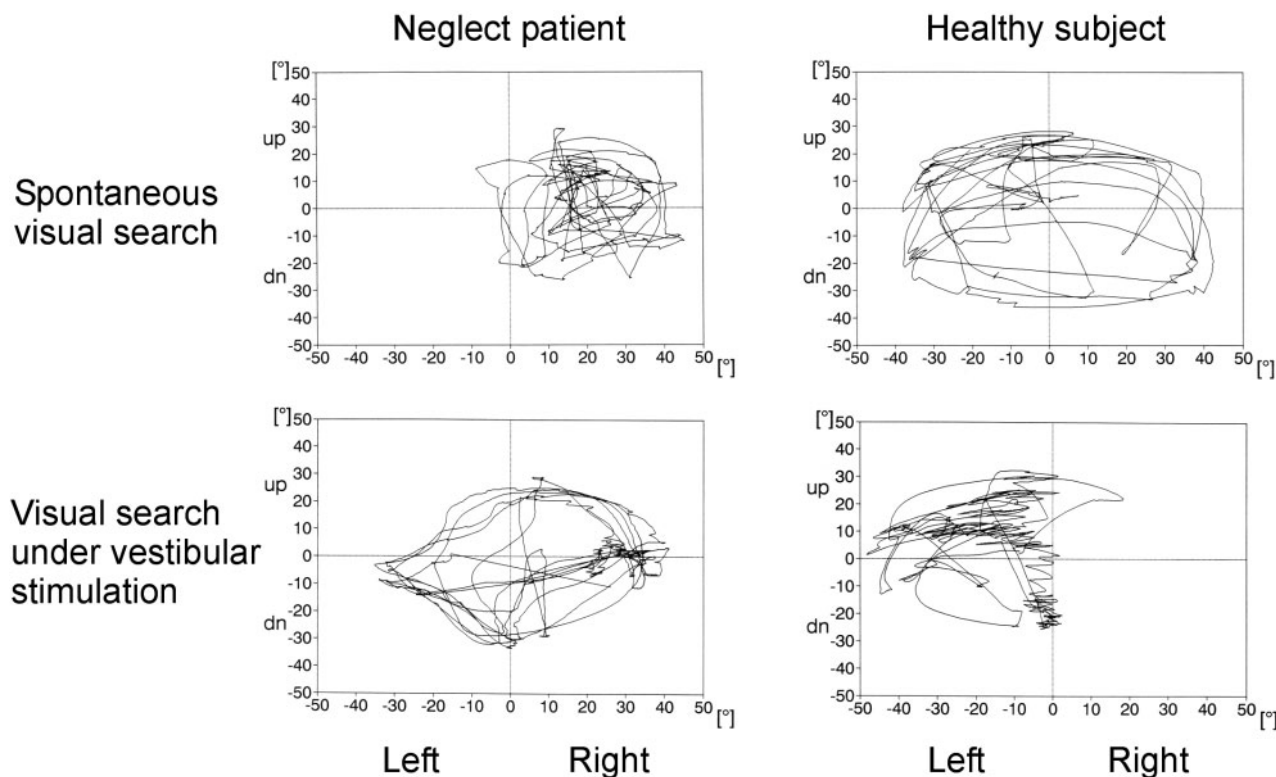


Fig. 2 Exploratory scan paths of an exemplary patient with spatial neglect (left) and a healthy subject (right) while searching for a (non-existent) target in darkness with the head fixed. The upper panel shows the patients' exploratory eye movements with no further stimulation; the lower panel with left-sided vestibular stimulation (cold water irrigation). In the condition without stimulation, the neglect patient showed a bias of ocular exploration towards the right and neglect of the left, while symmetrical eye movements were observed under unilateral vestibular stimulation. The healthy subject showed exactly the opposite behaviour, i.e. symmetrical search without stimulation and asymmetrical search under vestibular stimulation. (From Karnath *et al.*, 1996.)

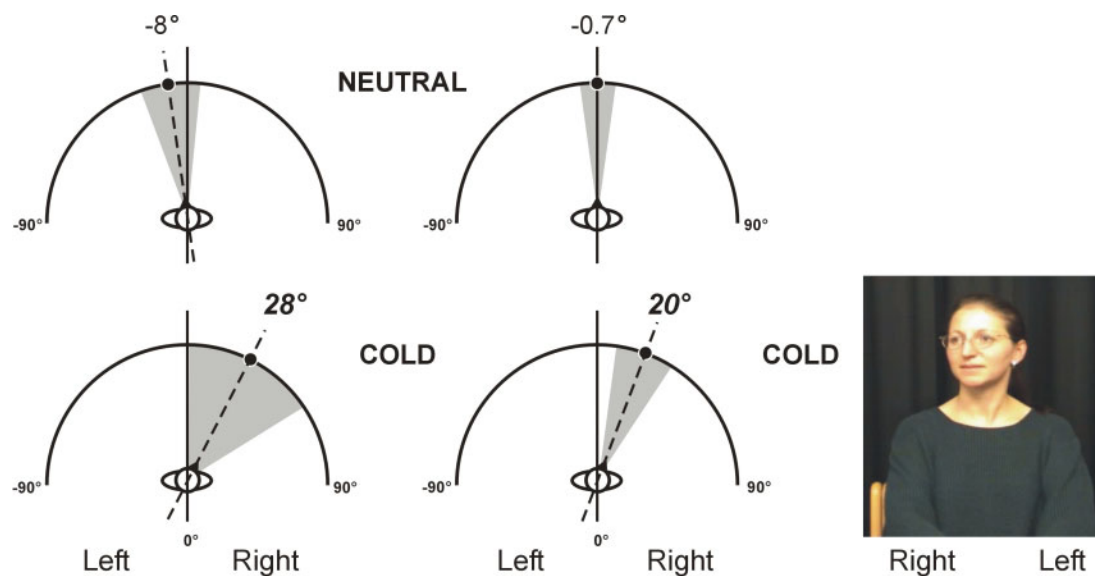


Fig. 3 Left: Spontaneous head orientation of healthy subjects with unilateral vestibular stimulation. Illustrated is the averaged spontaneous head orientation of nine healthy subjects during tactile exploration (left panel) and of eight healthy subjects during goal-directed pointing (right panel). The scene is illustrated as seen from above. The head is represented by a circle and the body by an ellipse. The dashed line illustrates the averaged median deviation of the head from straight ahead (solid vertical line at '0'); the grey area represents the standard deviation. While performing the two tasks, subjects received an injection in the right auditory canal for one minute either with water at body temperature (NEUTRAL) or with cold water (COLD) at a temperature of about 4°C. Caloric stimulation induced a marked deviation of spontaneous head orientation towards the right. (Modified from Karnath *et al.*, 2003a.) Right: Example of the spontaneous head orientation of a healthy subject under cold caloric stimulation.

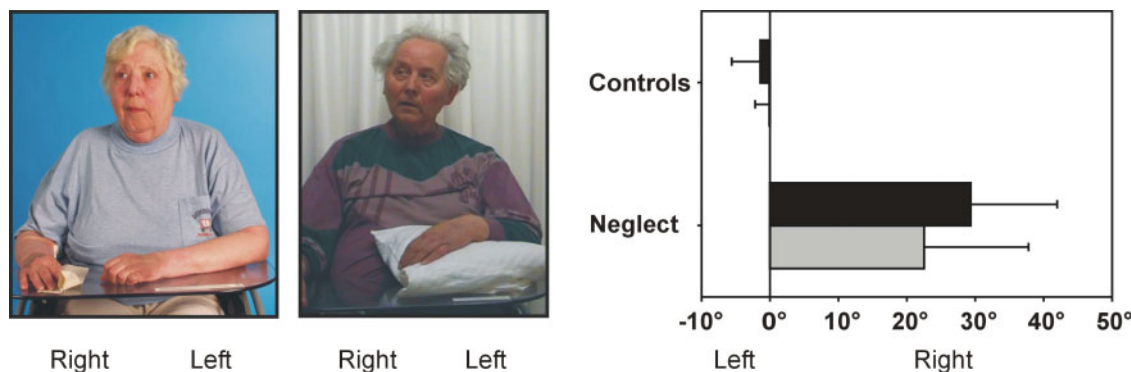


Fig. 4 Left: Examples of the spontaneous eye and head orientation of patients with spatial neglect following a right hemispheric stroke while 'doing nothing', i.e. just sitting and waiting. The patients typically orient eyes and head towards the ipsilesional, right side. One could have the impression that they were fixating a certain target situated on the right side. However, the room was empty with only the photographer standing right in front of them. Right: Mean horizontal position (and standard deviation) in degrees of visual angle for gaze (=combined eye-in-head and head-on-trunk position) in a group of 12 neglect patients and in 12 controls while 'doing nothing', just sitting and waiting (black bars) or when subsequently instructed to 'look straight ahead' (grey bars). Note that data are illustrated here from the patients' perspective, i.e. the rightward gaze deviation is plotted on the right side. (Modified from Fruhmann-Berger and Karnath, 2005.)

manuscript submitted) aimed to re-investigate this observation as early as possible after the stroke onset. The authors measured the relationship between spontaneous horizontal eye-in-head and head-on-trunk deviation and spatial neglect in 33 consecutively admitted patients with unilateral left or right hemisphere stroke 1.4 days on average post-stroke. In each single patient with spatial neglect and right hemisphere lesion the authors found an enormous deviation of the eyes and the head to the right. The average spontaneous gaze position (=combined eye-in-head and head-on-trunk position) in this group was 46° towards the right, while it was close to the sagittal body midline (0°) in all, left or right hemisphere stroke groups without spatial neglect as well as in healthy controls.

The data demonstrate that in neglect patients a bias towards the right is present even without any explicit requirements of activity, namely in the patients' spontaneous eye and head position. Moreover, they show that this bias is not a general phenomenon observed with any acute brain lesion. As from the very early stage after stroke onset, the bias of eyes and head seems to be specific for only those patients suffering from spatial neglect.

Such findings strengthen the view that an important component of the behaviour in patients with spatial neglect, namely the bias towards the right, is due to a very elementary disturbance of spatial information processing. This disorder may be understood as a pathological adjustment of the subject's normal resting position to a more rightward position (Fruhmann-Berger and Karnath, 2005). While the resting position of eyes and head in subjects without spatial neglect is in line with trunk orientation, this 'default position' of eye-in-head and head-on-trunk is shifted to a new origin in stroke patients suffering from spatial neglect.

Obviously, asymmetric function of the vestibular system and the horizontal bias of eye and head position in patients with spatial neglect seem to be closely related. This is strongly demonstrated by the observation that stimulation of one

vestibular organ has compensatory effects on the clinical signs of patients with spatial neglect (Rubens, 1985; Vallar *et al.*, 1993, 1995; Karnath *et al.*, 1996; Rode *et al.*, 1998; for review see Rossetti and Rode, 2002). For example, the ipsilesionally biased field of spontaneous exploration in neglect patients has been demonstrated to be transiently shifted back towards the contralesional side by cold caloric stimulation of the left vestibular organ (see left panel of Fig. 2). By analogy with such improvement in neglect patients, the opposite behaviour is induced in healthy subjects. Left-sided cold caloric stimulation induces a leftward shift of visual exploration, resulting in a bias of the scan path that resembles the spontaneous, asymmetrical behaviour of patients with spatial neglect (compare left and right panel in Fig. 2).

Further similarities: human vestibular cortex and the anatomy of spatial neglect

The multisensory (vestibular) cortical system

Animal studies have identified several distinct and separate areas of the temporal and parietal cortices that receive vestibular afferents, such as the area 2v at the tip of the intraparietal sulcus (Fredrickson *et al.*, 1966; Schwarz *et al.*, 1971; Büttner and Büttner, 1978), area 3aV in the central sulcus (Ödkvist *et al.*, 1974), the PIVC at the posterior end of the insula and retroinsular regions (Grüsser *et al.*, 1990a, b; Guldin and Grüsser, 1996), the periarculate cortical area 6 pa (Ebata *et al.*, 2004), area 7 in the inferior parietal lobule (IPL) (Faugier-Grimaud and Ventre, 1989) and the ventral intraparietal area (VIP) in the fundus of the intraparietal sulcus (Bremmer *et al.*, 2002; Klam and Graf, 2003a, b; Schlack *et al.*, 2005). These cortical areas receive different amounts of bilateral vestibular input from the vestibular nuclei, often project directly to the vestibular nuclei, and respond to vestibular as well as to somatosensory and/or visual stimulation (Guldin *et al.*, 1992; Akbarian *et al.*, 1994; Guldin and

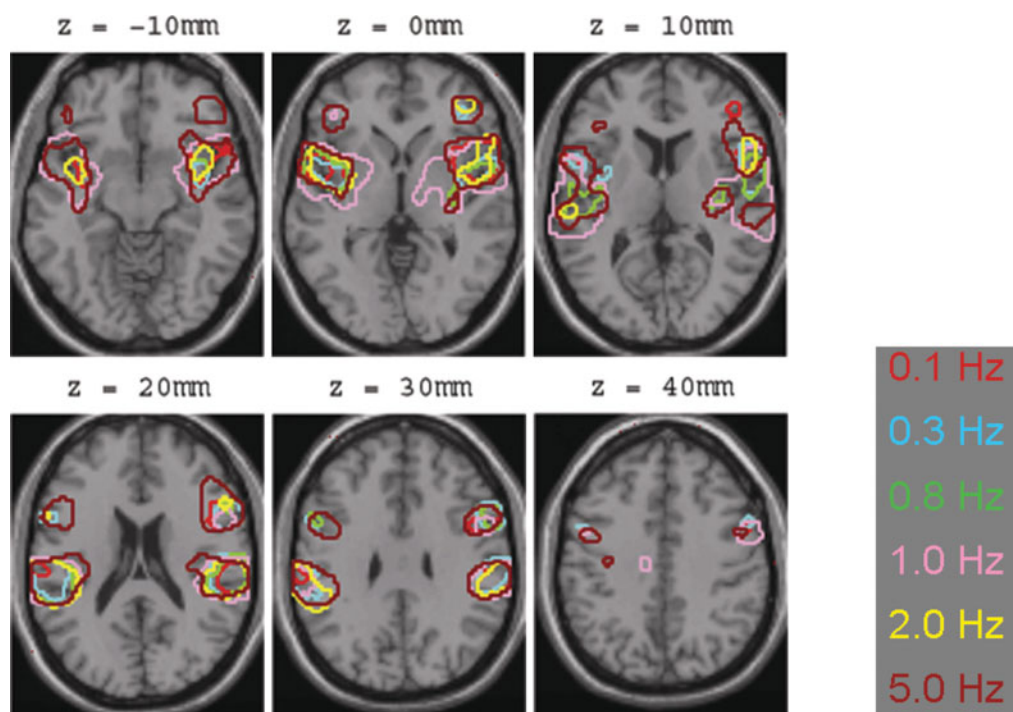


Fig. 5 Borders of BOLD activation clusters obtained with six different frequencies of galvanic vestibular stimulation over the mastoids using fMRI. Group analysis results of 28 healthy volunteers were superimposed onto transverse sections of a standard brain template ($P < 0.05$, corrected for multiple comparisons). All stimulation frequencies led to activations of comparable cortical areas including the supramarginal gyrus, lateral sulcus, STG, anterior and posterior insula, inferior and middle frontal gyri, anterior cingulum, and pre-central sulcus. (Modified from Stephan *et al.*, 2005.)

Grüsser, 1996). Due to its tight connections to the vestibular nuclei and to the other temporo-parietal areas, the area PIVC was proposed as a ‘core region’ within this network of multisensory (vestibular) areas in monkeys (Guldin and Grüsser, 1996).

During the last 10 years evidence from functional imaging studies with vestibular, somatosensory and visual optokinetic stimulation suggested that these multisensory (vestibular) cortical areas are similarly located and connected in humans. A complex network of areas predominantly in the temporo-insular and temporo-parietal cortex could be delineated in both human hemispheres (Bottini *et al.*, 1994, 2001; Bucher *et al.*, 1998; Lobel *et al.*, 1998; Bense *et al.*, 2001; Bremmer *et al.*, 2001; Suzuki *et al.*, 2001; Fasold *et al.*, 2002; Dieterich *et al.*, 2003a; Emri *et al.*, 2003; Stephan *et al.*, 2005). The areas in humans activated during caloric or galvanic vestibular stimulation were located in the posterior insula (first and second long insular gyri) and retroinsular regions [representing PIVC and the posterior adjacent visual temporal sylvian area (Guldin and Grüsser, 1996) in the monkey], the STG, the parts of the IPL representing area 7 in monkey, the depth of the intraparietal sulcus representing monkey area VIP, the post-central and pre-central gyrus, the anterior insula and adjacent inferior frontal gyrus, the anterior cingulate gyrus, the precuneus and hippocampus most often bilaterally (Fig. 5).

Simultaneous to these activations, deactivations of areas within the visual and somatosensory systems of both

hemispheres were observed (Wenzel *et al.*, 1996; Bense *et al.*, 2001). Since opposite activation–deactivation patterns occurred during visually induced self-motion perception with activations of parietal areas and concurrent deactivations of the multisensory (vestibular) cortex (Brandt *et al.*, 1998; Dieterich *et al.*, 1998), a reciprocal inhibitory cortical interaction between the sensory systems was assumed (Brandt *et al.*, 1998). The fMRI finding that coherent motion stimulation of the right or left visual hemifield exhibited negative signal changes (deactivations) in the primary visual cortex and the lateral geniculate nucleus contralateral to the stimulated hemisphere (Brandt *et al.*, 2000) was psychophysically evaluated to determine the functional significance of this contralateral inhibition of the visual system. In fact, mean detection times for horizontal and vertical object motion were significantly prolonged during concurrent motion pattern stimulation in the contralateral hemifield (Brandt *et al.*, 2003). These data supported the interpretation that the deactivation of neuronal activity in the visual system found by fMRI is associated with a functional decrement in the sensitivity needed to perceive motion and may reflect transcallosal attentional shifts between the hemispheres.

Right hemisphere dominance of the multisensory (vestibular) cortical system

Activation of the cortical network during vestibular stimulation is not symmetric in both hemispheres. Rather, it depends

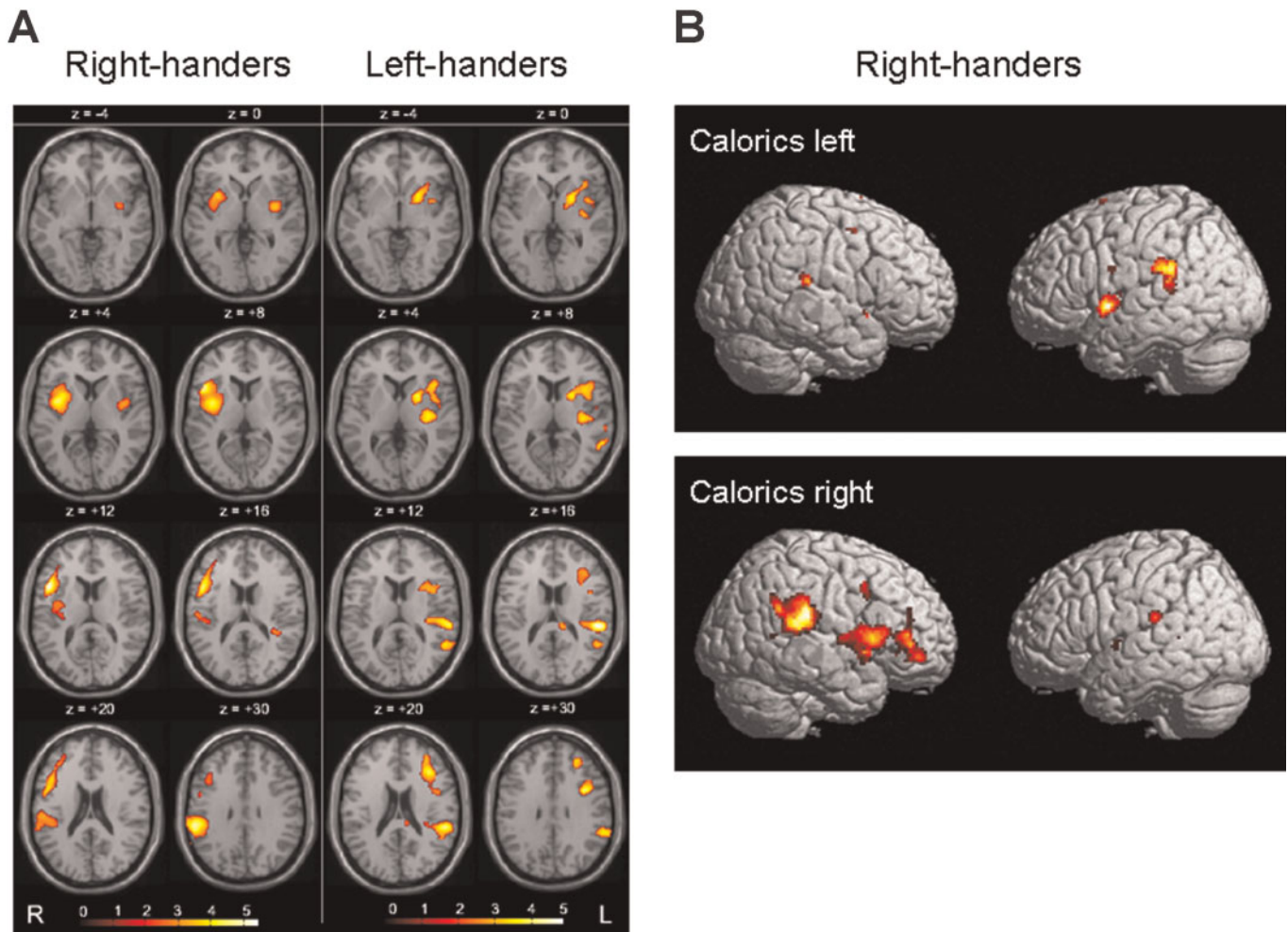


Fig. 6 (A) Areas activated during caloric stimulation (warm water at 44°C) of the right ear in right-handed and of the left ear in left-handed healthy volunteers (group analysis; $n = 12$; $P < 0.001$; ^{15}O -labelled H_2O bolus, positron emission tomography). Activations were located in the anterior and posterior insula, the STG, the inferior frontal gyrus, the post-central gyrus, the IPL and the anterior cingulum. Note that the activations were more pronounced in right-handers during irrigation of the right ear in the right hemisphere and in left-handers during irrigation of the left ear in the left hemisphere. This indicates dominance of the non-dominant hemisphere in the processing of vestibular information. (B) Lateral views of the surfaces of both hemispheres showing activated areas during caloric stimulation of the right or left ear in right-handers in the superior temporal cortex, TPJ, insular cortex and inferior frontal cortex. Compared with the activation pattern during caloric irrigation of the right ear, caloric irrigation of the left ear led to activations which were smaller in both hemispheres and more frequently located within the ipsilateral left hemisphere. These results represent dominance of the ipsilateral vestibular pathways. (Modified from Dieterich *et al.*, 2003a.)

on three determinants which were defined recently in a study investigating healthy right- and left-handers (Dieterich *et al.*, 2003a). The determinants were first the subjects' handedness, second the side of the stimulated ear and third the direction of the induced vestibular symptoms. Activation was stronger in the non-dominant hemisphere, in the hemisphere ipsilateral to the stimulated ear, and in the hemisphere ipsilateral to the fast phase of vestibular caloric nystagmus (Bense *et al.*, 2003; Dieterich *et al.*, 2003a, 2005) (Fig. 6).

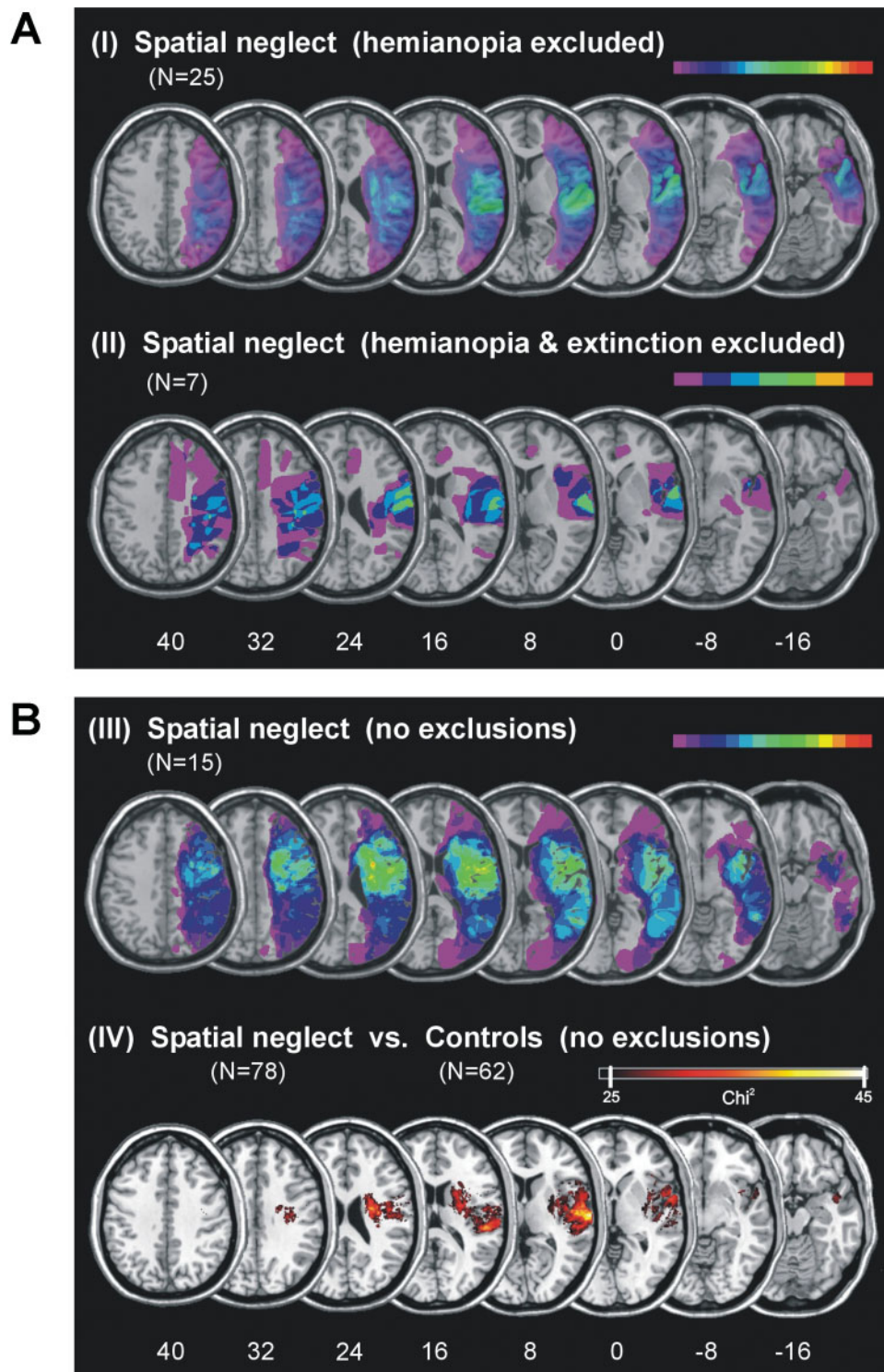
A dominance of the right hemisphere for multisensory (vestibular) cortical areas had been assumed earlier in healthy right-handers during optokinetic stimulation (Dieterich *et al.*, 1998) and vestibular stimulation (Dieterich *et al.*, 1996; Bense *et al.*, 2001; Suzuki *et al.*, 2001; Fasold *et al.*, 2002). Furthermore, in right-handed healthy volunteers, who performed

allocentric visuospatial judgements (line bisection) with and without galvanic stimulation of the right or left vestibular nerve, the most relevant cortical area for the processing of vestibular information was located in the posterior insula bilaterally, right significantly more than left, i.e. including the PIVC (Fink *et al.*, 2003). A significant specific interaction of galvanic vestibular stimulation with the neural mechanisms underlying allocentric visuospatial judgements was observed in right posterior parietal and ventral premotor cortex only.

Evidence for an involvement of the temporo-parietal cortex in processing vestibular information also derives from electrical stimulation studies carried out directly on the human cortex. Searching for the human representation of 'vestibular cortex', Kahane *et al.* (2003) retrospectively investigated patients with epilepsy who had undergone stereotactic

intracerebral electroencephalogram recordings before surgery and looked for those in whom an illusion of rotation was induced. The authors stimulated at 44 different loci in the temporal and parietal cortex and found that electrical stimulation of an area in the temporo-peri-sylvian cortex particularly elicited rotatory sensations. This area included Brodmann areas 40, 21 and 22. Of these, the STG and middle

temporal gyrus (MTG) preferentially caused illusions of rotation around the subjects' yaw axis, whereas the parietal operculum elicited pitch plane illusions. In other words, stimulation at the STG and MTG typically induced the illusion that the head or body rotated around the patient's longitudinal body axis to one side. The feeling of being rotated to one side with STG/MTG stimulation is an extremely



interesting functional-anatomical finding with respect to lesion localization data in this area obtained in patients with spatial neglect (*see below*). Kahane *et al.* (2003) thus confirmed earlier findings of Penfield and co-workers who had observed sensations of dizziness and rotary bodily movements especially following electrical stimulation of the STG in epileptic patients (Penfield and Jasper, 1954; Penfield, 1957; Penfield and Rasmussen, 1957).

Anatomical findings in spatial neglect

The anatomical findings reviewed above and the observation of a right hemisphere dominance for processing vestibular input have obvious parallels with anatomical findings in patients suffering from spatial neglect. Spatial neglect occurs predominantly with right hemisphere lesions. The function underlying spatial neglect is as asymmetrically lateralized in the right hemisphere as are language functions in the left hemisphere. Damage to the right IPL and TPJ (Heilman *et al.*, 1983; Vallar and Perani, 1986; Perenin, 1997; Leibovitch *et al.*, 1998, 1999; Mort *et al.*, 2003) has been observed to correlate with spatial neglect. In addition, recent studies found the right superior temporal cortex, the STG and the right insula as being critically related to the disorder (Fig. 7; Karnath *et al.*, 2001, 2003b, 2004a, b). Moreover, it was observed that subcortical strokes centring on the right basal ganglia which provoke spatial neglect induce abnormal perfusion in exactly these cortical areas, namely in the STG, the IPL and TPJ, as well as the inferior frontal gyrus (Karnath *et al.*, 2005).

In correspondence with these findings, many ablation and inactivation experiments in the monkey showed that lesions in the inferior parietal and frontal cortices can induce symptoms that share similarities with deficits observed in stroke patients exhibiting extinction or neglect (for review Wardak *et al.*, 2002a, b). However, such symptoms typically recover rapidly and (in clear contrast to humans) were elicited symmetrically after left- and right-hemisphere lesions which may point to a true difference in the cerebral organization between human and monkey. Beyond parietal and frontal structures,

involvement of the monkey right superior temporal cortex also has been shown. Luh and co-workers (1986) found reduced orientation to contralaterally presented visual stimuli in monkeys after unilateral left- or right-sided lesion of the dorsal bank and depth of the superior temporal sulcus (STS). A more recent study (Watson *et al.*, 1994) tested for various behavioural abnormalities in monkeys seen with spatial neglect in humans. The authors observed spatial neglect with lesions of the monkeys' superior temporal cortex, including both banks of the STS and STG.

Supporting anatomical evidence also has been reported from transcranial magnetic stimulation (rTMS) as well as from functional imaging studies in healthy subjects. While stimulation, i.e. 'virtually lesioning', of the right STG using rTMS, Ellison *et al.* (2004) observed a specific impairment of mean reaction times (RTs) for feature based serial exploratory search. In contrast, rTMS over the right posterior parietal cortex (PPC) resulted in increased RTs during conjunction search but had no effect on the difficult visual search for feature items (termed 'hard feature search task') as seen for the STG. Moreover, rTMS over the right PPC, but not over the right STG, induced underestimation of the contralateral segment of bisected lines when subjects performed a perceptual version of the traditional line bisection task (Ellison *et al.*, 2004). In a cued spatial-attention task, Hopfinger *et al.* (2000) aimed to dissociate in a fMRI study brain activity related to attentional control from that related to selective processing of target stimuli. Subjects were presented with an arrow cue at fixation that instructed them to attend to right or left peripheral locations and then to make a discrimination of a target at that location. Beyond superior frontal and inferior parietal areas, the authors found activations in the superior temporal cortex bilaterally that were specifically correlated with covert attentional shifts in the horizontal dimension of space, indicating that these structures are part of a network for voluntary attentional control. Evidence for the involvement of superior temporal cortex in tasks related to attentional orienting and spatial exploration also has been reported from a recent fMRI experiment (M. Himmelbach, M. Erb, H.-O. Karnath, manuscript submitted). It investigated the subjects' cortical pattern

Fig. 7 Investigating the anatomical correlate of spatial neglect. **(A)** Two recent studies have intentionally excluded patients who had additional neurological symptoms (hemianopia, extinction) beyond neglect. **(I)** Overlay lesion plots of 25 patients with spatial neglect who had no hemianopia studied by Karnath *et al.* (2001). **(II)** Overlay lesion plots of 7 patients with spatial neglect without hemianopia and without extinction from the study of Karnath *et al.* (2003b). The number of overlapping lesions is illustrated by different colours coding increasing frequencies from violet ($n = 1$) to red ($n = \text{max. number}$). Talairach z-coordinates are given. **(B)** Two further studies have investigated unselected samples of consecutively admitted patients instead. These studies included patients independently of whether or not they showed other neurological symptoms (i.e. patients were not excluded based on e.g. hemianopia or extinction). **(III)** Overlay lesion plots of 15 patients with spatial neglect from the study of Karnath *et al.* (2004a). The study employed a technique where the location of the lesion was drawn directly on the patient's own MRI scan using statistical parametric mapping normalization and cost-function masking for subsequent transformation into stereotaxic space. The number of overlapping lesions is illustrated by different colours coding increasing frequencies from violet ($n = 1$) to red ($n = \text{max. number}$). **(IV)** Voxelwise statistical analysis from the study of Karnath *et al.* (2004b) comparing 78 neglect patients with 62 patients without spatial neglect. The idea of voxelwise testing is to compute an independent statistical test between two groups of subjects for each and every voxel of the brain. Presented are all voxels that were damaged significantly more often in neglect patients than in control patients following a Bonferroni corrected alpha level of $P < 0.05$. The orange-yellow colour gradient corresponds with the χ^2 value. Talairach z-coordinates are given. The four studies (I to IV) consistently found that the right superior temporal cortex and insula are anatomical structures typically lesioned in patients with spatial neglect.

of activation in a visual exploratory task that closely resembled clinical procedures (visual search in a letter array) known to be sensitive to the neglect patients' behavioural bias. Beyond the TPJ and the inferior frontal gyrus, significant differences in activation between visual exploration and the control tasks were located at the middle part of superior temporal cortex.

Recently, Catani *et al.* (2005) investigated the anatomy of the arcuate fasciculus in the left hemisphere by means of diffusion tensor MRI (DTI) in healthy subjects. They found a three-way connection between the inferior frontal, superior temporal and the inferior parietal cortex. If this pattern of connectivity between these areas should exist also in the right hemisphere (can be expected but needs to be shown), the arcuate fasciculus would connect exactly those three areas which have been described as neural correlates of spatial neglect in brain-damaged patients and as locations of increased fMRI activation in healthy subjects under conditions of visual exploration and attentional orienting. This would argue for a tightly connected neural system involved in these processes straddling the sylvian fissure in the right hemisphere.

In conclusion, recent functional imaging studies aiming to identify the multisensory (vestibular) cortical areas in human have suggested that a few areas of the human non-dominant right hemisphere (in right-handers) are important for the processing of head and body orientation in space, namely the posterior insula and retroinsular regions (corresponding to the PIVC in monkey), the STG, and the TPJ (including area 7 in monkey). Interestingly, these areas seem to correspond to anatomical locations that can provoke spatial neglect in case of their lesion, i.e. lead to a spontaneous bias of eyes and head towards the right and neglect of information located on the left.

Spatial neglect—a vestibular disorder?

We reviewed arguments favouring a close relationship between vestibular function on the one hand and spatial neglect on the other. They basically concentrate on two aspects: (i) identical or closely related anatomical findings with respect to right superior temporal cortex, insula and TPJ, and (ii) similarities in the behaviour of patients with unilateral vestibular dysfunction and of patients with spatial neglect, namely a constant deviation of eyes and head in the horizontal plane. However, does this mean that spatial neglect should be regarded a 'vestibular disorder' at cortical level, as has been asked by Brandt (1999)?

Probably not in a strict sense. The typical lesion sites observed in large groups of neglect patients (Karnath *et al.*, 2004b; Buxbaum *et al.*, 2004) cannot be regarded as 'primary vestibular cortex' in the same sense in which we term e.g. the occipital lobe as 'primary visual cortex'. Neither the neurophysiological findings in monkeys (Grüsser *et al.*, 1990a, b; Fu *et al.*, 2003) nor the functional imaging and lesion analyses in humans (Brandt *et al.*, 1998; Brandt and Dieterich, 1999; Bense *et al.*, 2001; Dieterich *et al.*, 2003a; Stephan *et al.*, 2005) argued for the existence of a 'primary

vestibular cortex' but rather of a 'multisensory cortex', with processing of vestibular input as only one component. Beyond vestibular responses, the so-called 'vestibular neurons' respond to somatosensory, optokinetic and/or visual input as well. In other words, neurons responding to only vestibular input have not been identified so far, neither in humans nor in monkeys. Also, functional imaging studies with nociceptive, somatosensory, optokinetic, acoustic, vestibular and even olfactory stimulation confirm the convergence of different sensory modalities and the multisensory character of these cortical areas (Bense *et al.*, 2001; Dieterich *et al.*, 2003b; Fu *et al.*, 2003; Porter *et al.*, 2005).

Neurophysiological findings in monkeys as well as functional imaging results in humans have revealed evidence that our brain uses internal maps of the visual environment, in which the topographical positions of objects reflect their head- and trunk-centred as well as world-centred position in space instead of the retinotopic position of their images (Andersen *et al.*, 1993, 1997; Galletti *et al.*, 1993; Brodchie *et al.*, 1995; Snyder *et al.*, 1998; Boussaoud and Bremmer, 1999; Bottini *et al.*, 2001; Jellema and Perrett, 2003; Deutschländer *et al.*, 2005). In line with earlier work (Karnath, 2001), we suggest that right superior temporal cortex, insula and TPJ are significant sites for the neural integration of multimodal sensory input—vestibular, auditory, neck proprioceptive, visual, olfactory—into such higher order spatial co-ordinate systems. The multimodal neurons of this region seem to play an essential role in the spatial encoding of the surrounding space with reference to our body position. They provide us with redundant information about the position and motion of our body relative to external space. It has been argued that an important aspect leading to neglect of the contralesional side may be a disturbance of the process that converts multimodal sensory input (vestibular, neck proprioceptive, visual, etc.) into longer-lasting spatial representations (Karnath, 1994b, 1997). It was further proposed that in neglect patients this co-ordinate transformation is working with a systematic error resulting in a deviation of these reference frames to the ipsilesional side. The pathological 'default position' observed in neglect patients (Fruhmann-Berger and Karnath, 2005) might be a consequence of this deviation and be the reason for the constant bias of eyes and head orientation towards that side.

In conclusion, the orientation bias of neglect patients in the horizontal dimension of space does not seem to be a strictly 'vestibular disorder' but is linked with structures identified as 'multisensory cortex' in which vestibular, auditory, neck proprioceptive and visual input converge for encoding higher order spatial representations and for adjusting our body position relative to external space. This view may initiate further development of those strategies to treat spatial neglect that use routes to rehabilitation based on specific manipulations of sensory input feeding into this system, such as vestibular stimulation or neck proprioceptive stimulation by muscle vibration (Rubens, 1985; Karnath *et al.*, 1993; Vallar *et al.*, 1993, 1995; Rode *et al.*, 1998; Schindler *et al.*, 2002; Johannsen

et al., 2003; for reviews: Rossetti and Rode, 2002; Kerkhoff, 2003).

Acknowledgements

This work was supported by grants from the Deutsche Forschungsgemeinschaft (SFB 550-A4, DI 379/4-3). The authors are most grateful to Prof. Thomas Brandt for his helpful and stimulating discussion of the manuscript.

References

- Abderhalden E. Lehrbuch der Physiologie in Vorlesungen. Bd. 3. Berlin: Urban & Schwarzenberg; 1926.
- Abzug C, Maeda M, Peterson BW, Wilson VJ. Cervical branching of lumbar vestibulo-spinal axons. *J Physiol* 1974; 243: 499–522.
- Akbadian S, Grüsser O-J, Guldin WO. Corticofugal connections between the cerebral cortex and brainstem vestibular nuclei in the macaque monkey. *J Comp Neurol* 1994; 339: 421–37.
- Andersen RA, Snyder LH, Li C-S, Stricanne B. Coordinate transformations in the representation of spatial information. *Curr Opin Neurobiol* 1993; 3: 171–6.
- Andersen RA, Lawrence H, Snyder LH, Bradshaw JA. Multimodal representation of space in the posterior parietal cortex and its use in planning movements. *Annu Rev Neurosci* 1997; 20: 303–30.
- Aw ST, Fetter M, Cremer PD, Karlberg M, Halmagyi GM. Individual semicircular canal function in superior and inferior vestibular neuritis. *Neurology* 2001; 57: 768–74.
- Behrmann M, Watt S, Black SE, Barton JJ. Impaired visual search in patients with unilateral neglect: an oculographic analysis. *Neuropsychologia* 1997; 35: 1445–58.
- Bense S, Stephan T, Yousry TA, Brandt T, Dieterich M. Multisensory cortical signal increases and decreases during vestibular galvanic stimulation (fMRI). *J Neurophysiol* 2001; 85: 886–99.
- Bense S, Bartenstein P, Lutz S, Stephan T, Schwaiger M, Brandt Th, et al. Three determinants of vestibular hemispheric dominance during caloric stimulation. *Ann N Y Acad Sci* 2003; 1004: 440–5.
- Bense S, Bartenstein P, Lochmann M, Schlindwein P, Brandt T, Dieterich M. Metabolic changes in vestibular and visual cortices in acute vestibular neuritis. *Ann Neurol* 2004; 56: 624–30.
- Borel L, Harlay F, Magnan J, Chays A, Lacour M. Deficits and recovery of head and trunk orientation and stabilization after unilateral vestibular loss. *Brain* 2002; 125: 880–94.
- Bottini G, Sterzi R, Paulesu E, Vallar G, Cappa SF, Erminio F, et al. Identification of the central vestibular projections in man: a positron emission tomography activation study. *Exp Brain Res* 1994; 99: 164–9.
- Bottini G, Karnath HO, Vallar G, Sterzi R, Frith CD, Frackowiak RS, et al. Cerebral representations for egocentric space: functional-anatomical evidence from caloric vestibular stimulation and neck vibration. *Brain* 2001; 124: 1182–96.
- Boussaoud D, Bremmer F. Gaze effects in the cerebral cortex: reference frames for space coding and action. *Exp Brain Res* 1999; 128: 170–80.
- Brandt T. Vertigo. Its multisensory syndromes. 2nd edn. London: Springer; 1999.
- Brandt T, Dieterich M. The vestibular cortex. Its locations, functions, and disorders. *Ann N Y Acad Sci* 1999; 871: 293–12.
- Brandt T, Dieterich M, Danek A. Vestibular cortex lesions affect the perception of verticality. *Ann Neurol* 1994; 35: 403–12.
- Brandt T, Bartenstein P, Janek A, Dieterich M. Reciprocal inhibitory visual-vestibular interaction: visual motion stimulation deactivates the parieto-insular vestibular cortex. *Brain* 1998; 121: 1749–58.
- Brandt T, Stephan T, Bense S, Yousry TA, Dieterich M. Hemifield visual motion stimulation: an example of interhemispheric crosstalk. *Neuroreport* 2000; 11: 2803–9.
- Brandt T, Marx E, Stephan T, Bense S, Dieterich M. Inhibitory interhemispheric visuovisual interaction in motion perception. *Ann N Y Acad Sci* 2003; 1004: 283–8.
- Bremmer F, Schlack A, Duhamel J-R, Graf W, Fink GR. Space coding in primate posterior parietal cortex. *Neuroimage* 2001; 14: 46–51.
- Bremmer F, Klam F, Duhamel J-R, Hamed SB, Graf W. Visual-vestibular interactive responses in the macaque ventral intraparietal area (VIP). *J Neurosci* 2002; 16: 1569–86.
- Brotchie PR, Andersen RA, Snyder LH, Goodman SJ. Head position signals used by parietal neurons to encode locations of visual stimuli. *Nature* 1995; 375: 232–5.
- Bucher SF, Dieterich M, Wiesmann M, Weiss A, Zink R, Yousry T, et al. Cerebral functional MRI of vestibular, auditory, and nociceptive areas during galvanic stimulation. *Ann Neurol* 1998; 44: 120–5.
- Büttner U, Büttner UW. Parietal cortex (2v) neuronal activity in the alert monkey during natural vestibular and optokinetic stimulation. *Brain Res* 1978; 153: 392–7.
- Buxbaum LJ, Ferraro MK, Veramonti T, Farne A, Whyte J, Ladavas E, et al. Hemispatial neglect: subtypes neuroanatomy, and disability. *Neurology* 2004; 62: 749–56.
- Catani M, Jones DK, ffytche DH. Perisylvian language networks of the human brain. *Ann Neurol* 2005; 57: 8–16.
- Chedru F, Leblanc M, Lhermitte F. Visual searching in normal and brain-damaged subjects (contribution to the study of unilateral inattention). *Cortex* 1973; 9: 94–111.
- Curthoys IS, Halmagyi GM. Vestibular compensation: a review of the oculomotor, neural, and clinical consequences of unilateral vestibular loss. *J Vestib Res* 1995; 5: 67–107.
- Curthoys IS, Dai MJ, Halmagyi GM. Human ocular torsional position before and after unilateral vestibular neurectomy. *Exp Brain Res* 1991; 85: 218–25.
- Deutschländer A, Marx E, Stephan T, Riedel E, Wiesmann M, Dieterich M, et al. Asymmetric modulation of human visual cortex activity during 10° lateral gaze (fMRI study). *Neuroimage* 2005; 28: 4–13.
- Dieterich M, Brandt T. Ocular torsion and tilt of subjective visual vertical are sensitive brainstem signs. *Ann Neurol* 1993a; 33: 292–9.
- Dieterich M, Brandt T. Thalamic infarctions: differential effects on vestibular function in the roll plane (35 patients). *Neurology* 1993b; 43: 1732–40.
- Dieterich M, Brandt T, Bartenstein P, Wenzel R, Danek A, Lutz S, et al. Different vestibular cortex areas activated during caloric irrigation: a PET study. *J Neurol* 1996; 243 Suppl 2: 40.
- Dieterich M, Bucher SF, Seelos KC, Brandt T. Horizontal or vertical optokinetic stimulation activates visual motion-sensitive, ocular motor, and vestibular cortex areas with right hemispheric dominance: an fMRI study. *Brain* 1998; 121: 1479–95.
- Dieterich M, Bense S, Lutz S, Drzezga A, Stephan T, Brandt T, et al. Dominance for vestibular cortical function in the non-dominant hemisphere. *Cerebral Cortex* 2003a; 13: 994–1007.
- Dieterich M, Bense S, Stephan T, Yousry TA, Brandt T. fMRI signal increases and decreases in cortical areas during small-field optokinetic stimulation and central fixation. *Exp Brain Res* 2003b; 148: 117–27.
- Dieterich M, Bartenstein P, Spiegel S, Bense S, Schwaiger M, Brandt T. Thalamic infarctions cause side-specific suppression of vestibular cortex activations. *Brain* 2005; 128: 2052–67.
- Driver J, Husain M. The role of spatial working memory deficits in pathological search by neglect patients. In: Karnath H-O, Milner AD, Vallar G, editors. *The cognitive and neural bases of spatial neglect*. Oxford: Oxford University Press; 2002. p. 101–18.
- Ebata S, Sugiuchi Y, Izawa Y, Shinomiya K, Shinoda Y. Vestibular projection to the periaruate cortex in the monkey. *Neurosci Res* 2004; 49: 55–68.
- Ellison A, Schindler I, Pattison LL, Milner AD. An exploration of the role of the superior temporal gyrus in visual search and spatial perception using TMS. *Brain* 2004; 127: 2307–15.
- Emri M, Kisely M, Lengyel Z, Balkay L, Marian T, Miko L, et al. Cortical projection of peripheral vestibular signaling. *J Neurophysiol* 2003; 89: 2639–46.

- Fasold O, von Brevern M, Kuhberg M, Ploner CJ, Villringer A, Lempert T, et al. Human vestibular cortex as identified with caloric stimulation in functional magnetic resonance imaging. *Neuroimage* 2002; 17: 1384–93.
- Faugier-Grimaud S, Ventre J. Anatomic connections of inferior parietal cortex (Area 7) with subcortical structures related to vestibulo-ocular function in a monkey (*Macaca fascicularis*). *J Comp Neurol* 1989; 280: 1–14.
- Fink GR, Marshall JC, Weiss PH, Stephan T, Grefkes C, Shah NJ, et al. Performing allocentric visuospatial judgements with induced distortion of the egocentric reference frame: an fMRI study with clinical implications. *Neuroimage* 2003; 20: 1505–17.
- Fredrickson JM, Figge U, Scheid P, Kornhuber HH. Vestibular nerve projection to the cerebral cortex of the rhesus monkey. *Exp Brain Res* 1966; 2: 318–27.
- Fruhmann-Berger M, Karnath H-O. Spontaneous eye and head position in patients with spatial neglect. *J Neurol* 2005; 252: 1194–200.
- Fu K-MG, Johnston TA, Shah AS, Arnold L, Smiley J, Hackett TA, et al. Auditory cortical neurons respond to somatosensory stimulation. *J Neurosci* 2003; 23: 7510–5.
- Galletti C, Battaglini PP, Fattori P. Parietal neurons encoding spatial locations in craniotopic coordinates. *Exp Brain Res* 1993; 96: 221–9.
- Gauthier L, Dehaut F, Joanette Y. The bells test: a quantitative and qualitative test for visual neglect. *Int Clin Neuropsychol* 1989; 11: 49–54.
- Grüsser OJ, Pause M, Schreier U. Localization and responses of neurons in the parieto-insular cortex of awake monkeys (*Macaca fascicularis*). *J Physiol (Lond)* 1990a; 430: 537–57.
- Grüsser OJ, Pause M, Schreier U. Vestibular neurones in the parieto-insular cortex of monkeys (*Macaca fascicularis*): visual and neck receptor responses. *J Physiol (Lond)* 1990b; 430: 559–83.
- Guldin WO, Grüsser OJ. The anatomy of the vestibular cortices of primates. In: Collard M, Jeannerod M, Christen Y, editors. *Le cortex vestibulaire*. Editions IRVING. Paris: Ipsen; 1996. p. 17–26.
- Guldin WO, Akbarian S, Grüsser O-J. Cortico-cortical connections and cytoarchitectonics of the primate vestibular cortex: a study in squirrel monkeys (*Saimiri sciureus*). *J Comp Neurol* 1992; 324: 1–27.
- Halligan PW, Marshall JC, Wade DT. Visuospatial neglect: underlying factors and test sensitivity. *Lancet* 1989; 2: 908–11.
- Heilman KM, Watson RT, Valenstein E, Damasio AR. Localization of lesions in neglect. In: Kertesz A, editor. *Localization in neuropsychology*. New York: Academic Press; 1983. p. 471–92.
- Hopfinger JB, Buonocore MH, Mangun GR. The neural mechanisms of top-down attentional control. *Nat Neurosci* 2000; 3: 284–91.
- Hornak J. Ocular exploration in the dark by patients with visual neglect. *Neuropsychologia* 1992; 30: 547–52.
- Husain M, Rorden C. Non-spatially lateralized mechanisms in hemispatial neglect. *Nat Rev Neurosci* 2003; 4: 26–36.
- Husain M, Mannan S, Hodgson T, Wojciulik E, Driver J, Kennard C. Impaired spatial working memory across saccades contributes to abnormal search in parietal neglect. *Brain* 2001; 124: 941–52.
- Iwamoto Y, Perlmutter SI, Baker JF, Peterson BW. Spatial coordination by descending vestibular signals. 2. Response properties of medial and lateral vestibulospinal tract neurons in alert and decerebrate cats. *Exp Brain Res* 1996; 108: 85–100.
- Jellema T, Perrett D. Cells in monkey STS responsive to articulated body motions and consequent static posture: a case of implied motion? *Neuropsychologia* 2003; 41: 1728–37.
- Johannsen L, Ackermann H, Karnath H-O. Lasting amelioration of spatial neglect by treatment with neck muscle vibration even without concurrent training. *J Rehabil Med* 2003; 35: 249–53.
- Johnston CW, Diller L. Exploratory eye movements and visual hemi-neglect. *J Clin Exp Neuropsychol* 1986; 8: 93–101.
- Jung R. Neurophysiologische Untersuchungsmethoden. In: Bergmann Gv, Frey W, Schwiegl H, editors. *Handbuch der Inneren Medizin*, Bd. V. Berlin: Springer; 1953. p. 1206–420.
- Kahane P, Hoffmann D, Minotti L, Berthoz A. Reappraisal of the human vestibular cortex by cortical electrical stimulation study. *Ann Neurol* 2003; 54: 615–24.
- Karnath H-O. Spatial limitation of eye movements during ocular exploration of simple line drawings in neglect syndrome. *Cortex* 1994a; 30: 319–30.
- Karnath H-O. Disturbed coordinate transformation in the neural representation of space as the crucial mechanism leading to neglect. *Neuropsychol Rehabil* 1994b; 4: 147–50.
- Karnath H-O. Spatial orientation and the representation of space with parietal lobe lesions. *Philos Trans R Soc Lond B Biol Sci* 1997; 352: 1411–9.
- Karnath H-O. New insights into the functions of the superior temporal cortex. *Nat Rev Neurosci* 2001; 2: 568–76.
- Karnath H-O, Perenin M-T. Tactile exploration of peripersonal space in patients with neglect. *Neuroreport* 1998; 9: 2273–7.
- Karnath H-O, Christ K, Hartje W. Decrease of contralateral neglect by neck muscle vibration and spatial orientation of trunk midline. *Brain* 1993; 116: 383–96.
- Karnath H-O, Fetter M, Dichgans J. Ocular exploration of space as a function of neck proprioceptive and vestibular input-observations in normal subjects and patients with spatial neglect after parietal lesions. *Exp Brain Res* 1996; 109: 333–42.
- Karnath H-O, Niemeier M, Dichgans J. Space exploration in neglect. *Brain* 1998; 121: 2357–67.
- Karnath H-O, Ferber S, Himmelbach M. Spatial awareness is a function of the temporal not the posterior parietal lobe. *Nature* 2001; 411: 950–3.
- Karnath H-O, Himmelbach M, Perenin M-T. Neglect-like behaviour in healthy subjects: dissociation of space exploration and goal-directed pointing following vestibular stimulation. *Exp Brain Res* 2003a; 153: 231–8.
- Karnath H-O, Himmelbach M, Küker W. The cortical substrate of visual extinction. *Neuroreport* 2003b; 14: 437–42.
- Karnath H-O, Fruhmann Berger M, Zopf R, Küker W. Using SPM normalization for lesion analysis in spatial neglect. *Brain* 2004a; 127: E10.
- Karnath H-O, Fruhmann Berger M, Küker W, Rorden C. The anatomy of cortical neglect based on voxelwise statistical analysis: a study of 140 patients. *Cereb Cortex* 2004b; 14: 1164–72.
- Karnath H-O, Zopf R, Johannsen L, Berger MF, Nägele T, Klose U. Normalised perfusion MRI to identify common areas of dysfunction: patients with basal ganglia neglect. *Brain* 2005; 128: 2462–9.
- Kerkhoff G. Modulation and rehabilitation of spatial neglect by sensory stimulation. In: Prablanc C, Pélisson D, Rossetti Y, editors. *Progress in Brain Research*. Vol. 142. Amsterdam: Elsevier Science; 2003: 257–71.
- Kessels RP, Postma A, Wijndal EM, De Haan EH. Frontal-lobe involvement in spatial memory: evidence from PET, fMRI, and lesion studies. *Neuropsychol Rev* 2000; 10: 101–13.
- Klam F, Graf W. Vestibular signals of posterior parietal cortex neurons during active and passive head movements in macaque monkeys. *Ann N Y Acad Sci* 2003a; 1004: 271–82.
- Klam F, Graf W. Vestibular response kinematics in posterior parietal cortex neurons of macaque monkeys. *Eur J Neurosci* 2003b; 18: 995–1010.
- Leibovitch FS, Black SE, Caldwell CB, Ebert PL, Ehrlich LE, Szalai JP. Brain-behavior correlations in hemispatial neglect using CT and SPECT. The Sunnybrook Stroke Study. *Neurology* 1998; 50: 901–8.
- Leibovitch FS, Black SE, Caldwell CB, McIntosh AR, Ehrlich LE, Szalai JP. Brain SPECT imaging and left hemispatial neglect covaried using partial least squares: the Sunnybrook Stroke study. *Hum Brain Mapp* 1999; 7: 244–53.
- Lobel E, Kleine JF, Le Bihan D, Leroy-Willig A, Berthoz A. Functional MRI of galvanic vestibular stimulation. *J Neurophysiol* 1998; 80: 2699–709.
- Lopez C, Borel L, Magnan J, Lacour M. Torsional optokinetic nystagmus after unilateral vestibular loss: asymmetry and compensation. *Brain* 2005; 128: 1511–24.
- Luh KE, Butter CM, Buchtel HA. Impairments in orienting to visual stimuli in monkeys following unilateral lesions of the superior sulcal polysensory cortex. *Neuropsychologia* 1986; 24: 461–70.
- Malhotra P, Jager HR, Parton A, Greenwood R, Playford ED, Brown MM, et al. Spatial working memory capacity in unilateral neglect. *Brain* 2005; 128: 424–35.
- Mannan SK, Mort DJ, Hodgson TL, Driver J, Kennard C, Husain M. Revisiting previously searched locations in visual neglect: role of right parietal

- and frontal lesions in misjudging old locations as new. *J Cogn Neurosci* 2005; 17: 340–54.
- Mort DJ, Malhotra P, Mannan SK, Rorden C, Pambakian A, Kennard C, et al. The anatomy of visual neglect. *Brain* 2003; 126: 1986–97.
- Nathan PW, Smith M, Deacon P. Vestibulospinal, reticulospinal and descending propriospinal nerve fibres in man. *Brain* 1996; 119: 1809–33.
- Nishiike S, Guldin WO, Baurle J. Corticofugal connections between the cerebral cortex and vestibular nuclei in rat. *J Comp Neurol* 2000; 420: 363–72.
- Ödkvist LM, Schwarz DWF, Fredrickson JM, Hassler R. Projection of the vestibular nerve to the area 3a arm field in the squirrel monkey (*Saimiri sciureus*). *Exp Brain Res* 1974; 21: 97–105.
- Penfield W. Vestibular sensation and the cerebral cortex. *Ann Otol Rhinol Laryngol* 1957; 66: 691–8.
- Penfield W, Jasper H, editors. *Epilepsy and functional anatomy of the human brain*. Boston: Little Brown; 1954.
- Penfield W, Rasmussen T. *The cerebral cortex of man*. New York: Mac Millan Company; 1957.
- Perenin MT. Optic ataxia and unilateral neglect: clinical evidence for dissociable spatial functions in posterior parietal cortex. In: Thier P, Karnath H-O, editors. *Parietal lobe contributions to orientation in 3D space*. Heidelberg: Springer; 1997. p. 289–308.
- Porter J, Anand T, Johnson B, Khan RM, Sobel N. Brain mechanisms for extracting spatial information from smell. *Neuron* 2005; 47: 581–92.
- Rode G, Perenin M-T, Honoré J, Boisson D. Improvement of the motor deficit of neglect patients through vestibular stimulation: evidence for a motor neglect component. *Cortex* 1998; 34: 253–61.
- Rorden C, Karnath H-O. Using human brain lesions to infer function: a relic from a past era in the fMRI age? *Nat Rev Neurosci* 2004; 5: 813–9.
- Rossetti Y, Rode G. Reducing spatial neglect by visual and other sensory manipulations: noncognitive (physiological) routes to the rehabilitation of a cognitive disorder. In: Karnath H-O, Milner AD, Vallar G, editors. *The cognitive and neural bases of spatial neglect*. Oxford: Oxford University Press; 2002. p. 375–96.
- Rubens AB. Caloric stimulation and unilateral visual neglect. *Neurology* 1985; 35: 1019–24.
- Schindler I, Kerkhoff G, Karnath H-O, Keller I, Goldenberg G. Neck muscle vibration induces lasting recovery in spatial neglect. *J Neurol Neurosurg Psychiatry* 2002; 73: 412–9.
- Schlack A, Sterbing-D'Angelo SJ, Hartung K, Hoffmann KP, Bremmer F. Multisensory space representations in the macaque ventral intraparietal area. *J Neurosci* 2005; 25: 4616–25.
- Schwarz DWF, Fredrickson JM. Rhesus monkey vestibular cortex: a bimodal primary projection field. *Science* 1971; 172: 280–1.
- Shapiro K, Hillstrom A, Husain M. Control of visuotemporal attention by inferior parietal and superior temporal cortex. *Curr Biol* 2002; 12: 1320–5.
- Snyder LH, Grieve KL, Brotchie P, Andersen RA. Separate body- and world-referenced representations of visual space in parietal cortex. *Nature* 1998; 394: 887–91.
- Stephan T, Deutschländer A, Nolte A, Schneider E, Wiesmann M, Brandt T, et al. Functional MRI of galvanic vestibular stimulation with alternating currents at different frequencies. *Neuroimage* 2005; 26: 721–32.
- Strupp M, Arbusow V, Maag KP, Gall C, Brandt T. Vestibular exercises improve central vestibulospinal compensation after vestibular neuritis. *Neurology* 1998; 51: 838–44.
- Suzuki M, Kitano H, Ito R, Kitanishi T, Yazawa Y, Ogawa T, et al. Cortical and subcortical vestibular response to caloric stimulation detected by functional magnetic resonance imaging. *Brain Res Cogn Brain Res* 2001; 12: 441–9.
- Vallar G, Perani D. The anatomy of unilateral neglect after right-hemisphere stroke lesions. A clinical/CT-scan correlation study in man. *Neuropsychologia* 1986; 24: 609–22.
- Vallar G, Bottini G, Rusconi ML, Sterzi R. Exploring somatosensory hemineglect by vestibular stimulation. *Brain* 1993; 116: 71–86. Erratum: 116: 756.
- Vallar G, Papagno C, Rusconi ML, Bisiach E. Vestibular stimulation, spatial hemineglect and dysphasia, selective effects. *Cortex* 1995; 31: 589–93.
- Wardak C, Olivier E, Duhamel J-R. Neglect in monkeys: effect of permanent and reversible lesions. In: Karnath H-O, Milner AD, Vallar G, editors. *The cognitive and neural bases of spatial neglect*. Oxford: Oxford University Press; 2002a: 47–58.
- Wardak C, Olivier E, Duhamel J-R. Saccadic target selection deficits after lateral intraparietal area inactivation in monkeys. *J Neurosci* 2002b; 22: 9877–84.
- Watson RT, Valenstein E, Day A, Heilman KM. Posterior neocortical systems subserving awareness and neglect. *Arch Neurol* 1994; 51: 1014–21.
- Weintraub S, Mesulam MM. Mental state assessment of young and elderly adults in behavioral neurology. In: Mesulam MM, editor. *Principles of behavioural neurology*. Philadelphia: F.A. Davis Company; 1985; p. 71–123.
- Wenzel R, Bartenstein P, Dieterich M, Danek A, Weindl A, Minoshima S, et al. Deactivation of human visual cortex during involuntary ocular oscillations. A PET activation study. *Brain* 1996; 119: 101–10.