

Clinical features and natural history of neuroferritinopathy caused by the *FTL* 460InsA mutation

Patrick F. Chinnery,^{1,2} Douglas E. Crompton,^{1,2} Daniel Birchall,³ Margaret J. Jackson,² Alan Coulthard,^{3,8} Anne Lombès,⁹ Niall Quinn,⁴ Adrian Wills,⁵ Nicholas Fletcher,⁶ John P. Mottershead,⁷ Paul Cooper,⁷ Mark Kellett,⁷ David Bates² and John Burn¹

¹Institute of Human Genetics, ²Department of Neurology, University of Newcastle upon Tyne, ³Department of Neuroradiology, Regional Neurosciences Centre, Newcastle Upon Tyne Hospitals NHS Trust, Newcastle upon Tyne, ⁴Institute of Neurology, Queen Square, London, ⁵Queens Medical Centre, Nottingham, ⁶The Walton Centre for Neurology and Neurosurgery, Liverpool, ⁷Greater Manchester Centre for Clinical Neurosciences, Hope Hospital, Salford, UK, ⁸Department of Medical Imaging, University of Queensland, Royal Brisbane and Women's Hospital, Brisbane, Australia and ⁹Institut National de la Santé et de la Recherche Médicale, U582, Paris, France

Correspondence to: Professor Patrick F. Chinnery, The Medical School, Framlington Place, Newcastle upon Tyne, NE2 4HH, UK

Email: p.f.chinnery@ncl.ac.uk

Neuroferritinopathy is a progressive potentially treatable adult-onset movement disorder caused by mutations in the ferritin light chain gene (*FTL*). Features overlap with common extrapyramidal disorders: idiopathic torsion dystonia, idiopathic Parkinson's disease and Huntington's disease, but the phenotype and natural history have not been defined. We studied a genetically homogeneous group of 41 subjects with the 460InsA mutation in *FTL*, documenting the presentation, clinical course, biochemistry and neuroimaging. The mean age of onset was 39.4 years (SD = 13.3, range 13–63), beginning with chorea in 50%, focal lower limb dystonia in 42.5% and parkinsonism in 7.5%. The majority reported a family history of a movement disorder often misdiagnosed as Huntington's disease. The disease progressed relentlessly, becoming generalized over a 5–10 year period, eventually leading to aphonia, dysphagia and severe motor disability with subcortical/frontal cognitive dysfunction as a late feature. A characteristic action-specific facial dystonia was common (65%), and in 63% there was asymmetry throughout the disease course. Serum ferritin levels were low in the majority of males and post-menopausal females, but within normal limits for pre-menopausal females. MR brain imaging was abnormal on all affected individuals and one presymptomatic carrier. In conclusion, isolated parkinsonism is unusual in neuroferritinopathy, and unlike Huntington's disease, cognitive changes are absent or subtle in the early stages. Depressed serum ferritin is common and provides a useful screening test in routine practice, and gradient echo brain MRI will identify all symptomatic cases.

Keywords: chorea; dystonia; ferritin; iron; movement disorder; neurodegeneration; neuroferritinopathy

Abbreviations: *FTL* = ferritin light chain gene; ITD = idiopathic torsion dystonia; PANK2 = pantothenate kinase 2

Received August 23, 2006. Revised and Accepted October 16, 2006. Advance Access publication December 2, 2006.

Introduction

Neuroferritinopathy (MIM 606159, also labelled hereditary ferritinopathy and neurodegeneration with brain iron accumulation type 2, NBIA2) is an adult-onset progressive movement disorder due to mutations in the ferritin light

chain gene (*FTL*) (Curtis *et al.*, 2001). Four pathogenic mutations in *FTL* have been described to date (Curtis *et al.*, 2001; Vidal *et al.*, 2004; Maciel *et al.*, 2005; Mancuso *et al.*, 2005). 460InsA was the original mutation and has been

found in the largest number of cases. The resulting altered reading frame extends the peptide, disrupting the ferritin dodecahedron structure and causing accumulation of ferritin and iron, primarily in central neurons (Curtis *et al.*, 2001; Vidal *et al.*, 2004; Maciel *et al.*, 2005; Mancuso *et al.*, 2005). The disorder therefore provides a direct link between disordered iron storage and a neurodegenerative disease, opening new avenues for treatment by altering brain iron stores (Crompton *et al.*, 2005).

Based on limited published clinical descriptions, extrapyramidal neurological features dominate the clinical presentation of neuroferritinopathy, with focal onset dystonia, chorea and parkinsonism in different family members (Curtis *et al.*, 2001; Wills *et al.*, 2002; Chinnery *et al.*, 2003; Vidal *et al.*, 2004; Crompton *et al.*, 2005; Maciel *et al.*, 2005; Mancuso *et al.*, 2005; Mir *et al.*, 2005). Neuroferritinopathy thus enters the differential diagnosis of common neurological disorders, including idiopathic Parkinson's disease, idiopathic torsion dystonia (ITD) and Huntington's disease. Given the clinical genetic implications of the diagnosis, the early diagnosis of neuroferritinopathy is essential with molecular genetic confirmation. On the other hand, given the prevalence of Parkinson's disease and dystonia, molecular diagnostic services could be overwhelmed with referrals for *FTL1* analysis. There is therefore a clear need to define the neurological features of neuroferritinopathy in detail to clarify which patients should have molecular genetic testing. To address this issue we studied the vast majority of known cases with the 460InsA *FTL1* mutation.

Material and methods

Through clinical or molecular referral to us (J.B./P.F.C.) and by family tracing 41 subjects were identified.

A total of 105 DNA samples referred to the Northern Genetics Service with a diagnosis of possible Huntington's disease, but which lacked an expansion in the *HD* gene, were analysed for the 460InsA in *FTL1*, leading to the identification of seven further cases. Five of these were haplotyped and shown to be identical to the Cumbrian pedigree and therefore presumed to be distant relatives (Chinnery *et al.*, 2003). The entire *FTL1* gene was sequenced in 97 of the HD-negative patients but no mutations were identified. The samples of 44 patients referred for dentatorubropallidolysian atrophy testing but without an expansion in the *DRPLA* gene were also analysed specifically for 460InsA. Two had the common mutation, one of them was already known to be a member of the large pedigree. Media coverage heard by a colleague in Nottingham identified a further case with a similar phenotype in the Midlands (Wills *et al.*, 2002), but no further cases were found in 18 other early referrals. Contact with colleagues in London, Strasbourg and Leiden identified 144 Huntington-like cases, which had been found not to have a *HD* expansion. One of the 119, which could be amplified, a previously identified known case was positive for the common mutation. The French cases were identified through personal contact with one of the persons affiliated with a clinical description of cases in the literature (Caparros-Lefebvre *et al.*, 1997). The 460InsA insertion was not present in the 100 anonymized samples from the Cumbrian population collected as part of a resource for genetic epidemiology.

Of the 41 patients reported here 9 have been described elsewhere (Caparros-Lefebvre *et al.*, 1997; Wills *et al.*, 2002; Crompton *et al.*, 2005; Mir *et al.*, 2005). All 41 were studied to define the disease spectrum, and were assessed clinically by one of us, with 85% assessed by both P.F.C. and J.B. Examinations included detailed cognitive assessments ($n = 26$), serum ferritin ($n = 20$, multiple measurements were made in 7), electromyography and nerve conduction studies ($n = 8$), brain imaging (29 with MRI, serial in 8, range 5–49 months, and 1 with CT only). Two had dopamine transporter imaging (DaTSCAN). Nine had a muscle biopsy analysed histochemically. Six had respiratory chain activities measured in skeletal muscle (Caparros-Lefebvre *et al.*, 1997; Taylor and Turnbull, 1997).

Results

Presenting clinical features

Detailed clinical data were available for 21 females and 20 males (Table 1). Case 1 was identified by predictive genetic testing. There was no significant difference in the mean age of onset between males and females (two-sample *t*-test, $P = 0.31$, Fig. 1A). Overall, the mean age of onset was 39.4 years ($SD = 13.3$, range 13–63 years). Of the 40 affected subjects, the majority presented with focal onset chorea (50%, 20 out of 40) or focal dystonia (43%, 17 out of 40), which was either in the leg (76%) or arm (24%). The movements were ballistic in two individuals, beginning suddenly and leading to a diagnosis of stroke. One subject described an 'alien limb'; uncontrolled semi-purposeful movements in one limb with inter-manual conflict but no cortical sensory signs. Parkinsonism was the presenting feature in three individuals (7.5%, 3 out of 40). Blepharospasm and writer's cramp were early features in four, two individuals described marked diurnal variation of their lower limb dystonia with sleep benefit early in the disease course, and two had palatal tremor (previously known as palatal myoclonus). There was no significant gender difference in the mode of presentation, nor was there a relationship between the age of onset and the presenting clinical features.

Clinical course

Follow-up data were available on 38 subjects (range 1–36 years, Table 1, column 3), with patients being assessed on at least two occasions, the minimum being at presentation and subsequently on follow-up. The presenting movement disorder remained the major phenotype, with clear asymmetry remaining throughout the clinical course in 63%. The vast majority developed dystonia (83%), predominantly in the legs. Likewise, the majority also developed chorea (70%). Oromandibular dyskinesia was observed in 26 subjects (65%), causing tongue injury in 3; and 25 (63%) developed a characteristic speech with a dysarthrophonia, and an action-specific dystonia. This involved symmetric frontalis and platysma contraction giving a startled appearance. While 35% developed facial hypomimia and bradykinesia not directly related to their dystonia; only one

Table 1 Clinical features of neuroferritinopathy

Case number/ ethnic origin	Age (years) /gender	Age of onset/duration of follow -up (years)	Presenting phenotype		Speech and swallowing				Eyes		Motor				Cognitive**						
			Limb	Phenotype	Asymmetry	Dysarthria	Dysphonia	Orolingual dyskinesia		Dysphagia	EOM	Fundi	Bradykinesia	Tremor	Dystonia	Chorea	Spasticity	Power*	Reflexes/Babinski	Ataxia	
1 E	46 F	N/A	NA	C	0	0	0	0	0	0	0	0	0	0	0	0	0	0	0	0	0
2 E	40 F	40/<1	Leg	D	0	0	0	0	0	0	0	0	0	0	0	0	0	0	0	0	0
3 E	53 M	53/<1	Arm	C	0	0	0	0	0	0	0	0	0	0	0	0	0	0	0	0	0
4 E	34 F	33/<1	Arm	C	0	0	0	0	0	0	0	0	0	0	0	0	0	0	0	0	0
5 E	39 F	38/>1	Arm	D	0	0	0	0	0	0	0	0	0	0	0	0	0	0	0	0	0
6 E	39 F	37/2	Arm	C	0	0	0	0	0	0	0	0	0	0	0	0	0	0	0	0	0
7 E	53 M	51/2	Arm	C	0	0	0	0	0	0	0	0	0	0	0	0	0	0	0	0	0
8 E	63 F	61/2	Arm	C	0	0	0	0	0	0	0	0	0	0	0	0	0	0	0	0	0
9 E	34 M	32/2	Leg	D	0	0	0	0	0	0	0	0	0	0	0	0	0	0	0	0	0
10 E	59 M	57/2	Arm	C	0	0	0	0	0	0	0	0	0	0	0	0	0	0	0	0	0
11 E	54 M	52/2	Arm	C	0	0	0	0	0	0	0	0	0	0	0	0	0	0	0	0	0
12 E	40 F	38/2	Leg	D	0	0	0	0	0	0	0	0	0	0	0	0	0	0	0	0	0
13 Fr	48 M	44/4	Arm	C	0	0	0	0	0	0	0	0	0	0	0	0	0	0	0	0	0
14 E	58 F	53/5	Arm	C	0	0	0	0	0	0	0	0	0	0	0	0	0	0	0	0	0
15 E	35 F	30/5	Leg	D	0	0	0	0	0	0	0	0	0	0	0	0	0	0	0	0	0
16 E	58 M	53/5	Leg	C	0	0	0	0	0	0	0	0	0	0	0	0	0	0	0	0	0
17 E	57 M	51/6	Arm	C	0	0	0	0	0	0	0	0	0	0	0	0	0	0	0	0	0
18 E	30 F	24/6	Arm	D	0	0	0	0	0	0	0	0	0	0	0	0	0	0	0	0	0
19 E	60 M	54/6	Leg	C	0	0	0	0	0	0	0	0	0	0	0	0	0	0	0	0	0
20 E	69 F	63/6	Gait	P	0	0	0	0	0	0	0	0	0	0	0	0	0	0	0	0	0
21 E	53 M	46/7	Leg	C	0	0	0	0	0	0	0	0	0	0	0	0	0	0	0	0	0
22 E	50 F	41/9	Arm	C	0	0	0	0	0	0	0	0	0	0	0	0	0	0	0	0	0
23 E	44 M	35/9	Arm	D	0	0	0	0	0	0	0	0	0	0	0	0	0	0	0	0	0
24 E	65 F	55/10	Arm	P	0	0	0	0	0	0	0	0	0	0	0	0	0	0	0	0	0
25 E	53 F	42/11	Leg	D	0	0	0	0	0	0	0	0	0	0	0	0	0	0	0	0	0
26 E	49 M	37/12	Sp ^h	C	0	0	0	0	0	0	0	0	0	0	0	0	0	0	0	0	0
27 E	38 F	23/15	Leg	D	0	0	0	0	0	0	0	0	0	0	0	0	0	0	0	0	0
28 E	62 F	47/15	Leg	D	0	0	0	0	0	0	0	0	0	0	0	0	0	0	0	0	0

Table 1 Continued

Case number/ ethnic origin	Age (years)/gender	Age of onset/duration of follow-up (years)	Presenting phenotype				Speech and swallowing				Eyes		Motor				Cognitive**			
			Phenotype	Limb	Asymmetry	Dysarthria	Dysphonia	Orolingual dyskinesia	Dysphagia	EOM	Fundi	Bradykinesia	Tremor	Dystonia	Chorea	Spasticity	Power*	Reflexes/Babinski	Ataxia	
29 E	76 F	59/17	D	Arm	++	0	0	0	0	Z	Z	++	+	++	0	0	Z	N/↓	0	Normal psychometry
30 E	52 M	35/17	D	Leg	++	++	++	++	++	Z	Z	++	0	++	++	0	Z	N/↓	0	
31 E	59 F	42/17	P	Sp ^{pch}	0	++	0	++	0	BP	Z	0	0	++	+	0	Z	N/↓	0	Normal psychometry
32 E	62 F	45/17	C	Arm	0	++	++	++	0	↑UG	Z	0	0	++	0	0	Z	N/↓	0	
33 E	40 M	22/18	D	Leg	++	++	++	++	++	Z	Z	0	0	++	+	0	Z	N/↓	0	Normal psychometry
34 E	54 F	33/21	D	Leg	++	++	++	++	++	Z	Z	0	0	++	0	0	Z	N/↓	0	
35 E	50 M	25/25	C	Arm	++	++	++	++	++	Z	Z	+	0	++	++	0	Z	+++/↑	0	↓ Verbal fluency M28/30 ↓ verbal fluency A80/70 ↓ verbal fluency
36 Fr	53 M	24/29	D	Leg	++	++	++	++	++	Z	Z	0	0	++	0	0	Z	N/↓	0	
37 E	44 F	13/31	C	Arm	0	+	0	+	0	Z	Z	0	0	+	++	0	Z	N/↓	0	Limited by aphonia
38 E	49 M	17/32	C	Arm	++	0	0	0	0	Z	Z	0	0	0	++	0	Z	N/↓	0	
39 Fr	60 M	27/33	D	Leg	0	++	++	0	++	Z	Z	++	0	++	0	0	Z	N/↓	0	Normal psychometry
40 E	51 M	17/34	C	Arm	++	0	0	0	0	Z	Z	0	0	0	++	0	Z	N/↓	0	
41 E	61 M	25/36	D	Leg	++	+	+	++	+	Z	Z	0	0	++	+	0	Z	N/↓	0	Normal psychometry

Cases ordered based on duration since the onset of symptoms, with asymptomatic and recent onset cases at the top. Ethnic origin: E = English, Fr = French. Phenotype: U = unaffected; C = chorea; D = dystonia; P = parkinsonism. *Power in non-dystonic limbs. **M = MMSE, A = Addenbrookes cognitive score, EOM = external ocular movements. N/A not applicable, Sp^{pch} = speech, ↑UG = limited up-gaze. BP = broken ocular pursuit movements. Global cognitive decline = cognitive deficits in all modalities present.

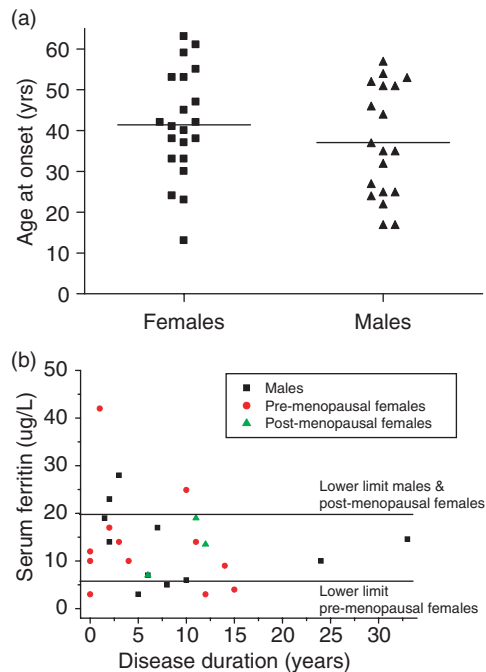


Fig. 1 (A) Age of onset for 40 affected individuals with neuroferritinopathy. Mean age of onset for females = 41.4 years (SD = 13.1). Mean age of onset for males was 37.1 years (SD = 13.6). There was no significant difference between males and females (two-sample *t*-test, *P* = 0.31). (B) Serum ferritin levels for 20 subjects with neuroferritinopathy. Black squares = males, red circles = pre-menopausal females, green triangles = post-menopausal females. Seven subjects had serial measurements over time (difference between the two measurements, mean = 13 months, range 4–25 months). Note that two pre-menopausal women had a ferritin measurement of 12 µg/L when presenting with symptoms for the first time, leading to two superimposed data points. Haemoglobin levels were normal at the time of all ferritin measurements. Horizontal lines show the lower limit of normal for males, post-menopausal females, and pre-menopausal females.

individual developed a pure rest tremor, and another had tremor present at rest and on intention. The majority of subjects remained ambulant two decades after onset. The most severe physical disability was seen in subjects presenting with a predominantly dystonic phenotype. Although dysphagia was common (40%), this could be effectively managed with dietary advice in most cases. Severe dystonic hypophonia and aphonia required speech amplification in four individuals.

Consistent negative/normal findings included: fundoscopy (*n* = 38), slit-lamp examination (*n* = 8); well preserved eye movements, with broken ocular pursuit in two (5%) and non-correcting limitation of up-gaze in one (3%). Brisk tendon reflexes were uncommon (13% in upper limbs, 18% in lower limbs), and none developed overt spasticity. Extensor plantar responses were noted in one individual (3%) which were probably striatal toes given the leg dystonia and normal tendon reflexes. None had documented seizures.

Cognitive features were subtle early in the disease course. The majority (56%, 5 out of 9) of subjects whose symptoms began <10 years previously had normal psychometric profiles, with the remaining 44% (4 out of 9) showing mild defects of verbal fluency. The remaining 44% (4 out of 9) had normal psychometry >10 years after symptom onset, among whom 33% (3 out of 9) had mild abnormalities of verbal fluency at >10 years of onset, and two had features consistent with a frontal/subcortical dementia (present 12 and 29 years after onset). One subject (Case 41) had a normal psychometric profile 36 years after onset. Disinhibition and emotional lability were frequently noted even in the early stages. One individual presented with a paranoid psychosis. Mini-Mental State Examination was not sensitive for the frontal/subcortical cognitive deficits.

Clinical investigations

Full blood count and film, urea and electrolytes, liver and bone biochemistry, plasma glucose, HbA1c, and serum creatine kinase were normal (*n* = 11). CSF analysis was normal (*n* = 6) with the exception of an elevated CSF protein (0.8 g/l) in one subject (Case 10). Fasting plasma and CSF lactate were normal (Cases 14, 23, 28 and 30). Serum ferritin levels were below the normal range for iron deficiency, despite normal haemoglobin and serum iron levels (Fig. 1B) in 82% of males (9 out of 11) and all post-menopausal females (3 out of 3) but only 23% of pre-menopausal females (3 out of 13). In seven subjects there were serial ferritin measurements, with values remaining below the reference range. There was no relationship between age or disease duration and the serum ferritin.

Electroretinography (*n* = 3), electromyography (*n* = 8) and peripheral nerve conduction studies (*n* = 8) were normal. Electroencephalography (*n* = 11) was normal apart from minor non-specific slowing of the alpha rhythm in two.

None of the subjects reported or were shown to have symptomatic disease in other organs. One subject required an implanted cardiac pacemaker.

Muscle biopsy

Nine subjects had a muscle biopsy prior to diagnosis. Histochemistry was normal in seven. Two had a greater percentage of cytochrome *c* oxidase negative fibres than expected for age (2% in a 48-year-old, Case 25; and 1% in a 45-year-old, Case 37). Respiratory chain complex assays were performed in six subjects [three of these results were published before reaching the molecular diagnosis (Caparros-Lefebvre *et al.*, 1997)]. Two had a combined defect involving multiple respiratory chain complexes (I and III, Case 13; I, III and IV, Case 36), and three had an isolated defect involving complex I (Cases 21, 37 and 39). In one subject (Case 25), respiratory chain complex activities were normal in muscle and cultured skin fibroblasts.

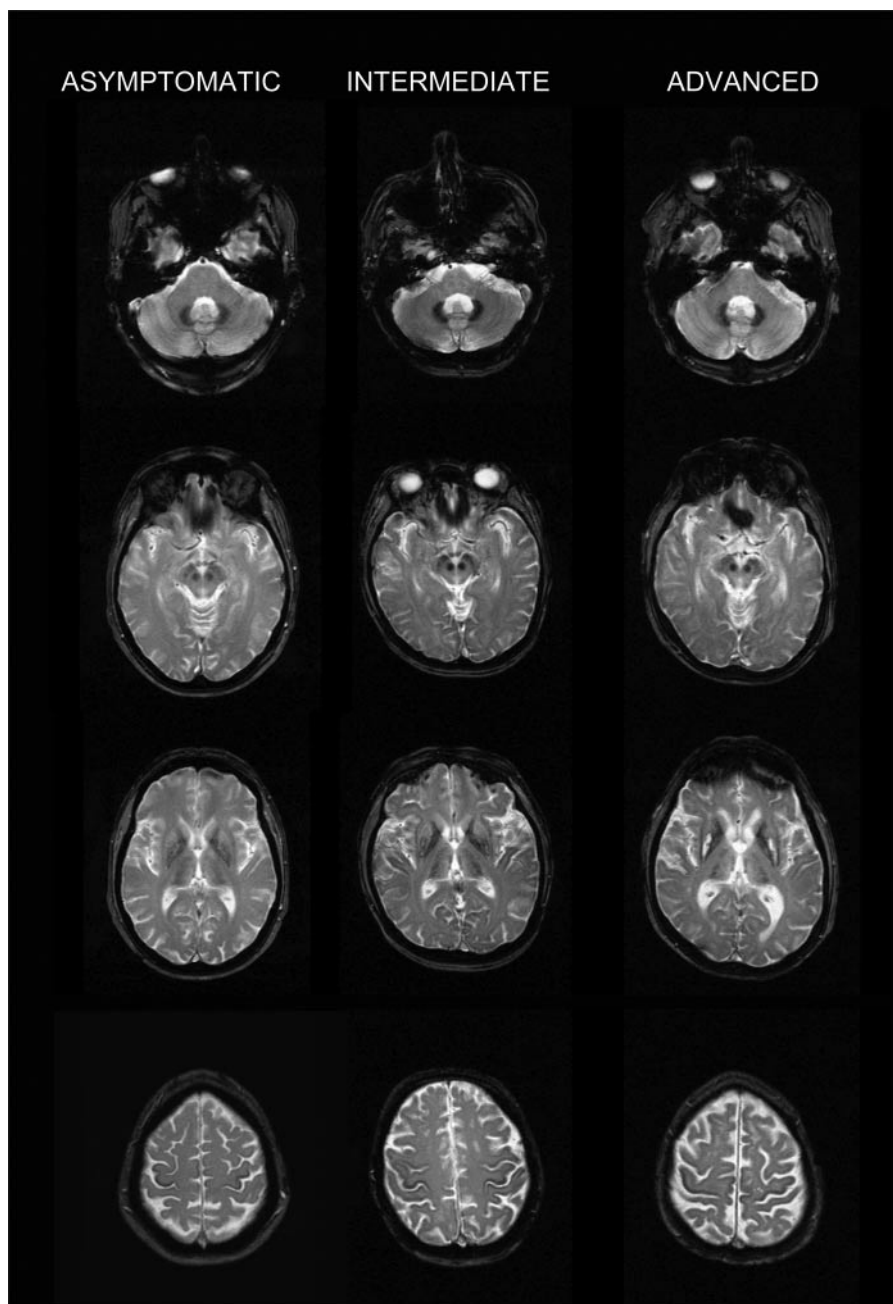


Fig. 2 Brain magnetic resonance imaging in neuroferritinopathy. *Left hand images:* asymptomatic subject (Case 1, who had predictive testing and harboured the 460InsA *FTL1* mutation). Profound signal loss is noted on T_2^* imaging in red nuclei, substantia nigra and globus pallidus, with less marked loss in dentate nuclei, thalami, putamen, caudate nucleus head, and precentral gyrus. Abnormalities are inconspicuous on T_2 , except for minor low signal in red nuclei and substantia nigra. *Middle images:* intermediate case (Case 12). T_2^* signal loss is present in the same locations, but also within the internal capsules, and more prominently within the dentate nuclei and thalami. T_2 now shows signal abnormality in the lentiform and caudate nuclei, particularly focally in the globus pallidus and posterior putamen, mirroring areas of high signal on T_1 (indicative of mineral deposition). *Right hand images:* advanced case (Case 35). The pallidal lesions have now undergone internal cystic degeneration. There is involuntional change, and there are several small vessel ischaemic lesions present.

Brain MR imaging

A characteristic pattern of signal change was observed in all subjects, consistent with iron deposition predominantly in the basal ganglia (Fig. 2). Serial scans of the same subject performed up to 49 months apart did not demonstrate significant qualitative change.

Even in an asymptomatic carrier, a characteristic pattern of iron deposition was seen on gradient echo sequences, consisting of loss of T_2^* signal within the dentate nuclei, red nuclei, substantia nigra, putamina, globi pallidi, thalami, caudate nuclei and the Rolandic prefrontal cortex. In early cases, the only discernible abnormality on

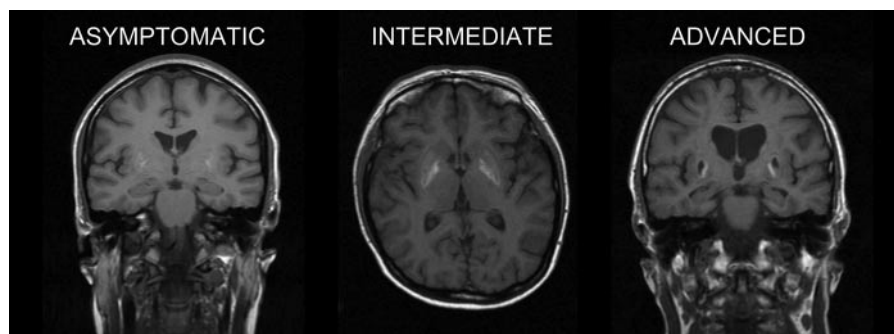


Fig. 3 Brain magnetic resonance imaging in neuroferritinopathy. T₁ weighted images acquired on the same subjects as shown in Fig. 2. *Left hand panel:* faint increase in T₁ signal in the putamen bilaterally in the asymptomatic case (Case 1). *Middle panel:* more prominent signal increase in the periphery of the putamen and globus pallidus in the intermediate case (Case 12). *Right hand panel:* prominent peripheral signal increase surrounding the cystic degeneration of the putamen and globus pallidus in the advanced case (Case 35).

conventional spin echo MR sequences in this group was a mild reduction in T₂ signal within the red nuclei and substantia nigra.

In increasingly severe disease, T₂* signal loss became more pronounced within the dentate nuclei, thalami and globi pallidi, with abnormal T₂ signal in the lentiform and caudate nuclei, mirroring areas of high signal on T₁ in these locations, and indicating mineral deposition. As the disease advanced there was more pronounced focal signal abnormality within the globus pallidus, with central high T₂ and FLAIR signal and peripheral high T₁, consistent with focal pre-cystic degeneration. In advanced cases, these foci showed internal cystic degeneration associated with generalized involutinal changes and an excess of small vessel ischaemic lesions.

T₁ weighted images from the same subjects are shown in Fig. 3, demonstrating the sensitivity of T₂* imaging, particularly in early disease. The MR findings were the same in the two patients with palatal tremor.

DaTScan imaging

There was no evidence of a presynaptic nigrostriatal dopaminergic deficit in two symptomatic subjects (Cases 5 and 9, Fig. 4).

Discussion

We have defined the phenotype of neuroferritinopathy. Our early suspicion of earlier male clinical onset is not confirmed; there is no gender difference in the age of onset, features or progression. With one exception, all of the individuals tested for the disorder had clinical features of the disease. We have not formally studied penetrance by systematically carrying out genetic testing in unaffected individuals, but re-analysis of the linkage data in our original paper (Curtis *et al.*, 2001) indicates a very high life-time penetrance for the 460InsA *FTL1* mutation, in the order of 100%.

To date, four different pathogenic mutations of *FTL1* have been identified, all affecting exon 4 (Curtis *et al.*, 2001;

Maciel *et al.*, 2005; Mancuso *et al.*, 2005; Vidal *et al.*, 2004). A male with a 2 bp insertion in exon 4 of *FTL1* (498InsTC) presented aged 20 with tremor followed by cerebellar signs aged 47 (dysarthria and ataxia, but no nystagmus), frontal/sub-cortical cognitive impairment, dyskinesia (described as involuntary movement of the face, resembling tardive dyskinesia, evolving into dystonic posturing and buccolingual dyskinesia), brisk tendon reflexes and Babinski signs (Vidal *et al.*, 2004). The 646InsC mutation was identified in a 63-year-old man presenting with chorea, limb ataxia, areflexia and bilateral extensor plantar responses (Mancuso *et al.*, 2005). The 474G→A (A96T) mutation was found in a man with mild non-progressive mental retardation, who developed a gait disturbance at 13 years of age, followed by episodes of psychosis treated with neuroleptics. He subsequently developed an akinetic-rigid syndrome, ataxia and pyramidal signs. His 40-year-old mother also harboured the same mis-sense mutation and was asymptomatic (Maciel *et al.*, 2005). With the exception of the reported cerebellar signs, the clinical presentation of the patients with the 498InsTC and 646InsC mutations fall within the spectrum we have seen in patients with 460InsA. The facial and orolingual dyskinesia appears to be a consistent finding, and is characteristic of neuroferritinopathy. It is intriguing that all three mutations alter the reading frame, leading to a lengthening of the C-terminus of FTL. By contrast, the clinical picture was strikingly different in the patient with a mis-sense mutation. It is tempting to suggest that mis-sense mutations cause a different phenotype, although neuroleptic medication may have complicated the picture. Prominent psychiatric features were noted in one case with 460InsA (Wills *et al.*, 2002). Despite the clinical differences, the neuroimaging was similar in cases with all four *FTL1* mutations.

The overwhelming majority of individuals have a relevant family history but this was often overlooked due to variable diagnostic labels. Historically, many affected relatives were admitted to psychiatric institutions for many decades before death. These relatives were not included in this study, but case review revealed the reason for admission was not

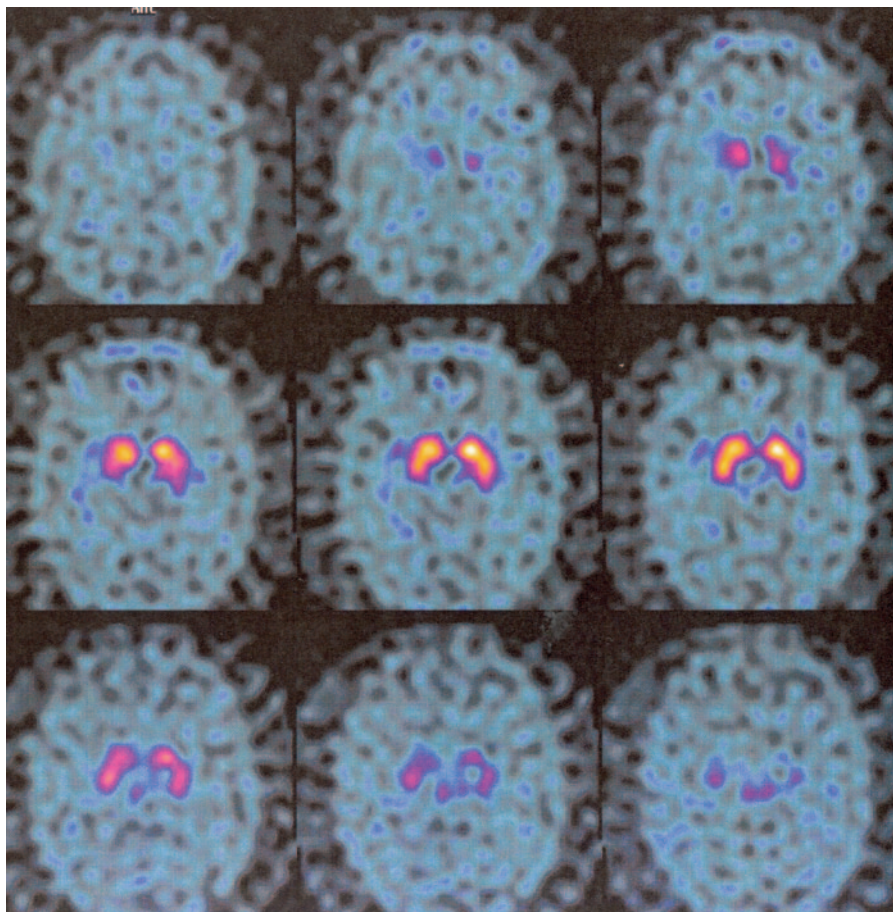


Fig. 4 ^{18}F -dopa PET scan in an early case of neuroferritinopathy (images from Case 9, corresponding to the early case in Fig. 2). No evidence of a nigrostriatal dopaminergic deficiency.

psychiatric disturbance *per se*, but abnormal involuntary movements considered psychogenic.

The original family carried a clinical diagnosis of Huntington's disease, but the lack of cognitive impairment over many years of follow-up first alerted us to this new disease. Only ~50% of individuals had demonstrable cognitive deficits ten years after disease onset. This contrasts with Huntington's disease, where memory, attention and concentration are affected early in the disease (Massman *et al.*, 1990; Pillon *et al.*, 1991). Even in advanced neuroferritinopathy, the deficit was subtle, usually involving verbal fluency. Only two individuals developed a clear frontal/subcortical dementia, and intriguingly, there was not an obvious relationship between the severity of the cognitive phenotype and disease duration. It is therefore likely that other factors modulate phenotype.

Neuroferritinopathy shares features with other inherited movement disorders. A dominant family history of a movement disorder raises the possibility of Huntington's disease and Huntington-like disease (Margolis *et al.*, 2001), idiopathic torsion dystonia (Bressman *et al.*, 2000) or spinocerebellar ataxia [particularly SCA17 (Nakamura *et al.*, 2001)]. The well-preserved cognition makes Huntington's

disease unlikely, and the absence of ataxia, as in the majority of patients with neuroferritinopathy, would be unusual for SCA17 (Rolfs *et al.*, 2003; Craig *et al.*, 2005). Two individuals presenting with focal lower-limb dystonia with secondary generalization were thought to have *DYT1* idiopathic torsion dystonia until exclusion of the *Torsin A* CAG deletion (Bressman *et al.*, 2000). Neuroferritinopathy is distinguished from autosomal dominant dopa-responsive dystonia due to mutations in *GCH1* (Tassin *et al.*, 2000) and *Parkin* mutation positive Parkinson's disease (Lucking *et al.*, 2000) by unresponsiveness to L-dopa.

A number of non-dominant neurogenetic disorders also enter the differential diagnosis of neuroferritinopathy, including Nieman–Pick disease type C (NPC) (Fink *et al.*, 1989), X-linked (McLeod's) neuroacanthocytosis (mutations in *XK*) (Ho *et al.*, 1994), and recessive choreoacanthocytosis (mutations in *VPS13A*) (Rampoldi *et al.*, 2001), pantothenate kinase (PANK) deficiency (previously known as Hallervorden–Spatz disease, mutations in *PANK2*; Hayflick *et al.*, 2003), and mitochondrial disease (Hanna and Bhatia, 1997). Normal eye movements make NPC unlikely and a normal creatine kinase, the absence of a compensated haemolysis, normal nerve conduction studies and the

absence of seizures reduce the likelihood of McLeod's disease and recessive choreoacanthocytosis.

There are neuroradiological similarities between neuroferritinopathy and PANK2 deficiency (Hayflick *et al.*, 2003), recessive aceruloplasminaemia (mutations CP) (Grisoli *et al.*, 2005), and mitochondrial disorders (Barragan-Campos *et al.*, 2005). Aceruloplasminaemia can present with psychiatric features in late middle age, but is usually preceded by anaemia with diabetes mellitus and retinal degeneration in association with a low serum caeruloplasmin and a high ferritin (Morita *et al.*, 1995). The slowly progressive form of PANK2 deficiency presents in the second or third decade with a speech disturbance, psychiatric features and an extrapyramidal disturbance (Hayflick *et al.*, 2003). Spasticity is a major feature, although this can be difficult to distinguish from dystonia, and the retinopathy and optic atrophy seen in the early-onset forms are uncommon when the disorder presents later in life. In males and non-menstruating females, the serum ferritin will help to distinguish PANK2 deficiency from neuroferritinopathy—but mutation analysis may be required to make a definitive diagnosis, particularly in pre-menopausal women.

The clinical and radiological overlap with mitochondrial disorders is intriguing, particularly given the respiratory chain defects noted in skeletal muscle in five of the six 460InsA cases studied here, and possibly in the cerebellum of one other case [646InsC (Mancuso *et al.*, 2005)]. Additional brain immunocytochemical abnormalities point to a secondary defect of the respiratory chain in neuroferritinopathy (Mancuso *et al.*, 2005), which, given the clinical similarity to primary mitochondrial disorders (McFarland *et al.*, 2002), could be a key mechanism initiating neurodegeneration in the basal ganglia. Abnormal iron storage and respiratory chain defects have been implicated in a number of more common neurodegenerative movement disorders, including Parkinson's disease (Jellinger, 1999), adding weight to the view that understanding rare metabolic disorders has broader relevance.

The most difficulty arises from the common movement disorders seen in some neuroferritinopathy patients early in the disease course, such as writer's cramp ($n = 1$), blepharospasm ($n = 2$), restless legs ($n = 2$) and parkinsonism. Although a family history is helpful, the presentation of neuroferritinopathy in middle age means that this is not always reliable, with parents occasionally dying from another illness before developing features of the disorder. Although a serum ferritin level may help, this can be normal, and brain MR imaging or molecular genetic analysis are the only ways of providing a definitive answer. Such detailed investigation is unnecessary in the vast majority of patients with non-familial focal movement disorders. However, if there is clinical progression, a strong family history, or an inappropriately low serum ferritin, we recommend MR T₂* imaging in the first instance, and molecular genetic testing if there is clear evidence of abnormal iron storage in the basal ganglia.

The heterogeneous clinical presentation and lack of natural history data make it difficult to assess the outcome of treatments, and our observations can only be considered largely anecdotal, albeit from a large group of patients by a limited number of clinicians. We have seen both subjective and objective improvements in the hyperkinetic movements with sulpiride ($n = 3$, max. dose 400 mg daily) and tetrabenazine ($n = 11$, max. dose 125 mg), although three had to stop the latter drug because they developed depression. Three subjects reported an improvement with trihexyphenidyl (benzhexol, max. dose 16 mg), L-dopa had no effect in five (max dose 375 mg daily), and deanol (20 mg t.i.d) was ineffective in two. Baclofen ($n = 2$, max dose 60 mg daily) and dantrolene ($n = 2$, max. dose 400 mg daily) were also tried without convincing benefit. Diazepam (20 mg daily), clonazepam (1 mg daily) and lorazepam (max. dose 15 mg daily) subjectively improved the dystonia, each in two patients. Other agents that did not have an effect on the movement disorder were: apomorphine ($n = 1$), amantadine ($n = 1$), lorazepam ($n = 2$), olanzapine ($n = 1$), risperidone ($n = 1$), amitriptyline ($n = 2$), paroxetine ($n = 1$), mirtazapine ($n = 1$), gabapentin ($n = 1$), sodium valproate ($n = 1$), and carbamazepine ($n = 1$), all in standard doses. Botulinum toxin has helped the focal dystonia ($n = 4$) and hyperkinetic tongue in two subjects.

We have tried to reduce brain iron stores in three subjects, documenting the clinical course with a videoed standardized examination. Three had monthly venesection for 6 months, and two had intravenous desferrioxamine (4000 mg weekly subcutaneously for up to 14 months), and one had oral deferriprone (2 g t.i.d for 2 month). All three measures caused profound and refractory iron depletion. One individual with generalized dystonia deteriorated significantly during the treatment period, and the other subjects did not notice any benefit. We conclude that a short period of iron depletion does not have a dramatic affect in the short term, but longer term benefits remain a possibility.

Acknowledgements

P.F.C. is a Wellcome Trust Senior Fellow in Clinical Science, and receives additional grant support from The Wellcome Trust, Ataxia UK, The Alzheimer's Research Trust, the Association Francaise Contre les Myopathies, the United Mitochondrial Diseases Foundation, and the EU FP6 programme EUMitocombat and MITOCIRCLE. This work was partially funded by the Newcastle Hospitals Special Trustees. We are indebted to the clinicians who referred the patients, and particularly the families and patients who have helped with this study. Funding to pay the Open Access publication charges for this article was provided by The Wellcome Trust.

References

- Barragan-Campos HM, Vallee JN, Lo D, Barrera-Ramirez CF, Argote-Greene M, Sanchez-Guerrero J, *et al.* Brain magnetic resonance imaging findings in patients with mitochondrial cytopathies. *Arch Neurol* 2005; 62: 737–42.

- Bressman SB, Sabatti C, Raymond D, de Leon D, Klein C, Kramer PL, et al. The *DYT1* phenotype and guidelines for diagnostic testing. *Neurology* 2000; 54: 1746–1752.
- Caparros-Lefebvre D, Destee A, Petit H. Late onset familial dystonia: could mitochondrial deficits induce a diffuse lesioning process of the whole basal ganglia system? *J Neurol Neurosurg Psychiatry* 1997; 63: 196–203.
- Chinnery PF, Curtis AR, Fey C, Coulthard A, Crompton D, Curtis A, et al. Neuroferritinopathy in a French family with late onset dominant dystonia. *J Med Genet* 2003; 40: e69.
- Craig K, Keers SM, Walls TJ, Curtis A, Chinnery PF. Minimum prevalence of spinocerebellar ataxia 17 in the north east of England. *J Neurol Sci* 2005; 239: 105–9.
- Crompton DE, Chinnery PF, Bates D, Walls TJ, Jackson MJ, Curtis AJ, et al. Spectrum of movement disorders in neuroferritinopathy. *Mov Disord* 2005; 20: 95–9.
- Curtis AR, Fey C, Morris CM, Bindoff LA, Ince PG, Chinnery PF, et al. Mutation in the gene encoding ferritin light polypeptide causes dominant adult-onset basal ganglia disease. *Nat Genet* 2001; 28: 350–4.
- Fink JK, Filling-Katz MR, Sokol J, Cogan DG, Pikus A, Sonies B, et al. Clinical spectrum of Niemann-Pick disease type C. *Neurology* 1989; 39: 1040–9.
- Grisoli M, Piperno A, Chiapparini L, Mariani R, Savoirdo M. MR imaging of cerebral cortical involvement in aceruloplasminemia. *AJNR Am J Neuroradiol* 2005; 26: 657–61.
- Hanna MG, Bhatia KP. Movement disorders and mitochondrial dysfunction. *Curr Opin Neurol* 1997; 10: 351–6.
- Hayflick SJ, Westaway SK, Levinson B, Zhou B, Johnson MA, Ching KH, et al. Genetic, clinical, and radiographic delineation of Hallervorden-Spatz syndrome. *N Engl J Med* 2003; 348: 33–40.
- Ho M, Chelly J, Carter N, Danek A, Crocker P, Monaco AP. Isolation of the gene for McLeod syndrome that encodes a novel membrane transport protein. *Cell* 1994; 77: 869–80.
- Jellinger KA. The role of iron in neurodegeneration: prospects for pharmacotherapy of Parkinson's disease. *Drugs Aging* 1999; 14: 115–40.
- Lucking CB, Durr A, Bonifati V, Vaughan J, De Michele G, Gasser T, et al. Association between early-onset Parkinson's disease and mutations in the parkin gene. French Parkinson's Disease Genetics Study Group. *N Engl J Med* 2000; 342: 1560–7.
- Maciel P, Cruz VT, Constante M, Iniesta I, Costa MC, Gallati S, et al. Neuroferritinopathy: missense mutation in FTL causing early-onset bilateral pallidal involvement. *Neurology* 2005; 65: 603–5.
- Mancuso M, Davidzon G, Kurlan RM, Tawil R, Bonilla E, Di Mauro S, et al. Hereditary ferritinopathy: a novel mutation, its cellular pathology, and pathogenetic insights. *J Neuropathol Exp Neurol* 2005; 64: 280–94.
- Margolis RL, O'Hearn E, Rosenblatt A, Willour V, Holmes SE, Franz ML, et al. A disorder similar to Huntington's disease is associated with a novel CAG repeat expansion. *Ann Neurol* 2001; 50: 373–80.
- Massman PJ, Delis DC, Butters N, Levin BE, Salmon DP. Are all subcortical dementias alike? Verbal learning and memory in Parkinson's and Huntington's disease patients. *J Clin Exp Neuropsychol* 1990; 12: 729–44.
- McFarland R, Taylor RW, Turnbull DM. The neurology of mitochondrial DNA disease. *Lancet Neurol* 2002; 1: 343–51.
- Mir P, Edwards MJ, Curtis AR, Bhatia KP, Quinn NP. Adult-onset generalized dystonia due to a mutation in the neuroferritinopathy gene. *Mov Disord* 2005; 20: 243–5.
- Morita H, Ikeda S, Yamamoto K, Morita S, Yoshida K, Nomoto S, et al. Hereditary ceruloplasmin deficiency with hemosiderosis: a clinicopathological study of a Japanese family. *Ann Neurol* 1995; 37: 646–56.
- Nakamura K, Jeong SY, Uchihara T, Anno M, Nagashima K, Nagashima T, et al. SCA17, a novel autosomal dominant cerebellar ataxia caused by an expanded polyglutamine in TATA-binding protein. *Hum Mol Genet* 2001; 10: 1441–8.
- Pillon B, Dubois B, Agid Y. Severity and specificity of cognitive impairment in Alzheimer's, Huntington's, and Parkinson's diseases and progressive supranuclear palsy. *Ann NY Acad Sci* 1991; 640: 224–7.
- Rampoldi L, Dobson-Stone C, Rubio JP, Danek A, Chalmers RM, Wood NW, et al. A conserved sorting-associated protein is mutant in chorea-acanthocytosis. *Nat Genet* 2001; 28: 119–20.
- Rolfs A, Koeppen AH, Bauer I, Bauer P, Buhlmann S, Topka H, et al. Clinical features and neuropathology of autosomal dominant spinocerebellar ataxia (SCA17). *Ann Neurol* 2003; 54: 367–75.
- Tassin J, Durr A, Bonnet AM, Gil R, Vidailhet M, Lucking CB, et al. Levodopa-responsive dystonia. GTP cyclohydrolase I or parkin mutations? *Brain* 2000; 123: 1112–21.
- Taylor RW, Turnbull DM. Laboratory diagnosis of mitochondrial disease. In: Applegarth DA, Dimmick J, Hall JG, editors. *Organelle diseases*. London: Chapman & Hall; 1997. p. 341–50.
- Vidal R, Ghetti B, Takao M, Brefel-Courbon C, Uro-Coste E, Glazier BS, et al. Intracellular ferritin accumulation in neural and extraneural tissue characterizes a neurodegenerative disease associated with a mutation in the ferritin light polypeptide gene. *J Neuropathol Exp Neurol* 2004; 63: 363–80.
- Wills AJ, Sawle GV, Guilbert PR, Curtis AR. Palatal tremor and cognitive decline in neuroferritinopathy. *J Neurol Neurosurg Psychiatry* 2002; 73: 91–2.