

Does corticobasal degeneration exist? A clinicopathological re-evaluation

Helen Ling,^{1,2} Sean S. O'Sullivan,^{1,2} Janice L. Holton,² Tamas Revesz,² Luke A. Massey,^{2,3}
David R. Williams,^{1,4} Dominic C. Paviour² and Andrew J. Lees^{1,2,3}

1 Reta Lila Weston Institute of Neurological Studies, Institute of Neurology, University College London, London WC1N 1PJ, UK

2 Queen Square Brain Bank for Neurological Disorders and Institute of Neurology, University College London, London WC1N 1PJ, UK

3 Sara Koe PSP Research Centre, Institute of Neurology, University College London, London WC1N 1PJ, UK

4 Van Cleef Roet Centre for Nervous Diseases, Monash University, Melbourne, 3004, Australia

Correspondence to: Professor Andrew J. Lees,
Reta Lila Weston Institute of Neurological Studies,
Institute of Neurology,
University College London,
1 Wakefield Street,
London WC1N 1PJ, UK
E-mail: alees@ion.ucl.ac.uk

The pathological findings of corticobasal degeneration are associated with several distinct clinical syndromes, and the corticobasal syndrome has been linked with a number of diverse pathologies. We have reviewed all the archival cases in the Queen Square Brain Bank for Neurological Disorders over a 20-year period with either a clinical diagnosis of corticobasal syndrome or pathological diagnosis of corticobasal degeneration in an attempt to identify the main diagnostic pitfalls. Of 19 pathologically confirmed corticobasal degeneration cases, only five had been diagnosed correctly in life (sensitivity = 26.3%) and four of these had received an alternative earlier diagnosis. All five of these had a unilateral presentation, clumsy useless limb, limb apraxia and myoclonus, four had cortical sensory impairment and focal limb dystonia and three had an alien limb. Eight cases of corticobasal degeneration had been clinically diagnosed as progressive supranuclear palsy, all of whom had vertical supranuclear palsy and seven had falls within the first 2 years. On the other hand, of 21 cases with a clinical diagnosis of corticobasal syndrome, only five had corticobasal degeneration pathology, giving a positive predictive value of 23.8%; six others had progressive supranuclear palsy pathology, five had Alzheimer's disease and the remaining five had other non-tau pathologies. Corticobasal degeneration can present very commonly with a clinical picture closely resembling classical progressive supranuclear palsy or Richardson's syndrome, and we propose the term corticobasal degeneration-Richardson's syndrome for this subgroup. Cases of corticobasal degeneration-Richardson's syndrome have delayed onset of vertical supranuclear gaze palsy (>3 years after onset of first symptom) and the infrequent occurrence of predominant downgaze abnormalities, both of which can be helpful pointers to their underlying corticobasal degeneration pathology. Forty-two per cent of corticobasal degeneration cases presented clinically with a progressive supranuclear palsy phenotype and 29% of cases with corticobasal syndrome had underlying progressive supranuclear palsy pathology. In contrast, in the Queen Square Brain Bank archival collection, corticobasal syndrome is a rare clinical presentation of progressive supranuclear palsy occurring in only 6 of the 179 pathologically diagnosed progressive supranuclear palsy cases (3%). Despite these diagnostic difficulties we conclude that corticobasal degeneration is a discrete clinicopathological entity but with a broader clinical spectrum than was originally proposed.

Keywords: corticobasal degeneration; corticobasal syndrome; diagnostic accuracy; progressive supranuclear palsy; tau

Abbreviations: CBD = corticobasal degeneration; CBS = corticobasal syndrome; PSP = progressive supranuclear palsy; TDP-43 = trans-activation response DNA binding protein

Introduction

The earliest description of corticobasal syndrome (CBS) dates back to 1925 when Jean L'Hermitte and colleagues reported the case of a 72-year-old carpenter presenting with a clumsy useless arm with rigidity, ideomotor apraxia, abnormal flexed posture, 'jerky' contractions, alien limb phenomenon and cortical parietal sensory dysfunction (Lhermitte *et al.*, 1925; Ballan *et al.*, 1997). There is also speculation that the French composer Maurice Ravel (1875–1937) who developed aphasia, apraxia and loss of musical creativity had CBS (Alajouanine, 1948).

In 1967, the first comprehensive clinicopathological description of corticobasal degeneration (CBD) was published by Rebeiz and colleagues, who described three patients with progressive clumsy, slow and awkward movements of one limb for which no cause could be found (Rebeiz *et al.*, 1967, 1968). Other features, such as alien hand, jerky tremor, dystonia, parkinsonism, pyramidal features and gait difficulty were also noted. Cortico-dentato-nigral degeneration with neuronal achromasia and swollen cortical cells identical to those found in Pick's disease led to the proposal that this was a hitherto unreported distinctive nosological clinicopathological entity (Rebeiz *et al.*, 1967, 1968). In the 1980s, several further small series of similar cases were described but the disorder received little interest and was considered to be a rare neurological curiosity (Watts *et al.*, 1985). In 1989, Gibb and colleagues coined the abbreviated term corticobasal degeneration (CBD). They highlighted the pathological similarities to Pick's disease but concluded that the clinical picture and distribution of neuronal loss and neurofibrillary degeneration supported the view that this was a distinct disease (Gibb *et al.*, 1989). Molecular pathological studies have further supported this distinction by demonstrating that CBD, in common with progressive supranuclear palsy (PSP), is a predominantly four-repeat isoform tauopathy; whereas three-repeat tau accumulation predominates in Pick's disease (Arai *et al.*, 2001).

The classic description of CBD includes clumsiness and loss of function of one hand due to a combination of frontoparietal and basal ganglia sensorimotor dysfunction. Ideomotor and limb-kinetic apraxia, cortical sensory loss leading to an alien limb, limb dystonia, focal action or stimulus-sensitive myoclonus and L-dopa unresponsive rigidity and bradykinesia may all be found on examination and contribute to the asymmetric limb dysfunction. A similar constellation of signs has been linked with cerebrovascular disease (Kreisler *et al.*, 2007), Alzheimer's disease (Imamura *et al.*, 2009), PSP (Tsuboi *et al.*, 2005), Pick's disease (Boeve *et al.*, 1999), dementia with Lewy bodies (Horoupian *et al.*, 1999), Creutzfeldt–Jakob disease (Vandenberghe *et al.*, 2007), frontotemporal dementia and parkinsonism linked to chromosome 17 (FTDP-17) (Casseron *et al.*, 2005), neurofilament inclusion body disease (Josephs *et al.*, 2003) and argyrophilic grain disease (Rippon *et al.*, 2005). Trans-activation response DNA binding

protein (TDP-43) proteinopathies and progranulin mutations are other rare causes (Masellis *et al.*, 2006; Tartaglia *et al.*, 2009) and the term CBS has been used to embrace this distinctive collection of symptoms and signs.

Conversely, pathologically diagnosed CBD can masquerade as PSP (Boeve, 2005), frontotemporal dementia (Josephs *et al.*, 2006), progressive non-fluent aphasia and apraxia of speech (Josephs *et al.*, 2006; McMonagle *et al.*, 2006) and progressive posterior cortical atrophy syndrome (Renner *et al.*, 2004; Tang-Wai *et al.*, 2004). Marked early cognitive dysfunction, which was once considered an exclusion criteria for the diagnosis of CBD, is now accepted as a clinical variant (Grimes *et al.*, 1999). Kertesz and colleagues have suggested that the phenotypes of CBS, PSP, primary progressive aphasia and the behavioural variant of frontotemporal dementia are closely related and frequently overlap, leading them to propose that all of these different diagnoses should be lumped together and referred to as the frontotemporal dementia/Pick complex (Kertesz *et al.*, 2005).

Previous studies have indicated that between 25 and 56% of CBD cases are diagnosed correctly in life (Grimes *et al.*, 1999; Hughes *et al.*, 2002; Boeve, 2005; Murray *et al.*, 2007). Pathological prediction of a primary tauopathy is, however, much more accurate (Josephs *et al.*, 2006). For example, Josephs *et al.* (2006) indicated that the clinical presentation of CBS- or a PSP-like syndrome was 100% specific for a primary tauopathy. Of the 83 cases presenting with CBS studied in four large clinicopathological series, 69 (83%) had a tauopathy with pathological inclusions made up predominantly of four-repeat tau in CBD and PSP, and three-repeat tau in Pick's disease (Wadia *et al.*, 2007).

In the latest neuropathological consensus diagnostic criteria frontotemporal lobar degeneration is classified into tau-positive and -negative groups (Cairns *et al.*, 2007). Both CBD and frontotemporal lobar degeneration with Pick bodies (previously termed Pick's disease) are examples of tau-positive frontotemporal lobar degeneration (Cairns *et al.*, 2007) and these criteria also have a high sensitivity in distinguishing CBD from other tauopathies. A few cases of frontotemporal lobar degeneration with *microtubule-associated protein tau* mutation (previously termed FTDP-17) have a similar pathological signature as CBD and it may be reasonable to look on these cases as examples of monogenetic CBD (Dickson *et al.*, 2002).

We have retrospectively reviewed cases with either clinical diagnosis of CBS or pathological diagnosis of CBD examined at the Queen Square Brain Bank for Neurological Disorders over a 20-year period, between 1989 and 2009, and compared the diagnostic accuracy of CBD with the other atypical parkinsonian syndromes.

Material and methods

Patients

Patients with either a final clinical diagnosis of CBS or pathological diagnosis of CBD were identified from the archive of 1440 cases referred to the Queen Square Brain Bank for Neurological Disorders over a 20-year period (1989–2009). Some cases have been included in previous reports from the Queen Square Brain Bank for Neurological Disorders, previously known as the United Kingdom Parkinson's Disease Society Brain Research Centre (Jendroska *et al.*, 1995; Litvan *et al.*, 1996; Houlden *et al.*, 2001; Pittman *et al.*, 2005; Williams *et al.*, 2005; O'Sullivan *et al.*, 2008). Most of the cases were registered as donors while under the care of physicians at the National Hospital for Neurology and Neurosurgery, Queen Square, London. Prospective brain donors were required to fill in annual assessment forms that provided clinical information related to their neurological condition. Consent for brain donation was obtained from the patients prior to death and consent for post-mortem examination was obtained from the next of kin after death. The protocols for the retention and access to human tissue and clinical records at the Queen Square Brain Bank for Neurological Disorders have been approved by the London Multi-Centre Research Ethics Committee. The Queen Square Brain Bank for Neurological Disorders restricted itself to the collection of abnormal movement disorders until 5 years ago when it also started to collect brains of patients dying with presumed frontotemporal dementia, who had presented to the Dementia Research Centre at the Institute of Neurology, University College London.

Medical record review

We performed a systematic review of all medical records available including the primary care medical notes, the correspondence between the medical specialists and general practitioners, National Hospital for Neurology and Neurosurgery medical files and the Queen Square Brain Bank annual assessment data. All patients, except one who had incidental CBD pathology, had been assessed by hospital specialists (general neurologists, movement or cognitive disorders specialists) throughout the course of their illness. The information from the case notes was independently assessed by two neurologists (H.L. and S.S.O'S) who were blinded to the pathological diagnosis.

Symptoms were recorded as being absent if they were not reported in the case notes. Clinical signs were recorded as unknown if they were not specifically mentioned. The time of onset of selected clinical features was noted. When the onset was not recorded, we noted the onset as the time when the particular clinical feature was first mentioned in the chart. In cases with conflicting clinical features, the findings of the hospital specialist were used.

The clinical research definitions used in the study were as follows: (i) age of onset: approximated to the specific month when the first symptom considered to be attributable to the neurological disorder was reported; (ii) duration of illness: time between the age of onset and the age at death; (iii) initial clinical diagnosis: the first diagnosis made by a neurologist; (iv) final clinical diagnosis: the last diagnosis recorded before death (where more than one possible clinical diagnosis was listed in the clinical records an attempt was made to ascertain which diagnosis was thought to be most likely by the neurologist); (v) initial presenting symptoms: first symptoms considered to be

attributable to the neurological disorder; (vi) alien limb: defined as a 'feeling that one limb is foreign' or 'has a will of its own', together with 'observable involuntary motor activity', including grasping of nearby objects or 'intermanual conflict' - where the reported symptoms fulfilled this definition or when 'alien limb phenomenon' was documented by neurologists, this feature was recorded as present since limb levitation alone was not considered as alien limb phenomenon (Joseph and Rossor 2004); (vii) falls: reported as present when an unprovoked fall was mentioned; (viii) backward falls: >50% of the falls were in the backward direction; (ix) pyramidal signs: when there was documentation of a Babinski's sign and pathologically brisk reflexes; and (x) response to L-dopa: a reported improvement of >30% coinciding with the introduction of L-dopa was recorded as being a positive response. A 4-point scale of improvement post-L-dopa was used as follows: 1=nil or <30% improvement; 2=moderate response (30–50% improvement); 3=good response (51–70% improvement) and 4=excellent response (71–100% improvement). A transient response to L-dopa was defined as a reported benefit lasting <2 years of commencing on L-dopa.

Neuropathological methods and pathological diagnosis

Cases were selected from the archive of the Queen Square Brain Bank where brain donation takes place according to ethically approved protocols and tissue is stored under a license from the Human Tissue Authority. In all cases the neuropathological diagnosis was reviewed by two neuropathologists (T.R. and J.L.H.) using established pathological criteria. The minimal pathological features required for the diagnosis of CBD were tau-positive neuronal and glial lesions, including astrocytic plaques and extensive thread pathology in both grey and white matter of cerebral cortex and striatum along with focal neuronal loss in cortical regions and in the substantia nigra (Dickson *et al.*, 2002; Ince *et al.*, 2008). Other neuropathological diagnoses established for cases in the present series included PSP (Litvan *et al.*, 1996; Ince *et al.*, 2008), frontotemporal lobar degeneration (Cairns *et al.*, 2007), dementia lacking distinctive histopathology (Josephs *et al.*, 2004), Alzheimer-type or α -synuclein pathologies (Ball *et al.*, 1997; Ince *et al.*, 2008) and Parkinson's disease (Oppenheimer, 1984).

Statistical methods

Four diagnostic parameters were calculated for CBD cases in the Queen Square Brain Bank database: (i) sensitivity: the percentage of pathologically diagnosed CBD cases that had been diagnosed clinically as CBS in life; (ii) specificity: the percentage of cases that did not have CBD pathology, which had been clinically diagnosed as not having that diagnosis in life; (iii) positive predictive value: the percentage of cases that had been diagnosed clinically as CBS and were pathologically confirmed as CBD; and (iv) negative predictive value: the percentage of cases that were not clinically diagnosed with CBS and were confirmed post-mortem not to have CBD pathology. The calculations of positive and negative predictive values depend on the prevalence of disease in a targeted population, whereas sensitivity and specificity are constant measures of clinical diagnostic acumen. Confidence intervals at 95% for each diagnostic parameter were calculated by Stata 10.0 statistical programme. Final clinical and neuropathological diagnoses were cross-tabulated using a 2 \times 2 contingency table. Clinical features from patient subgroups were compared using the Student's *t*-test

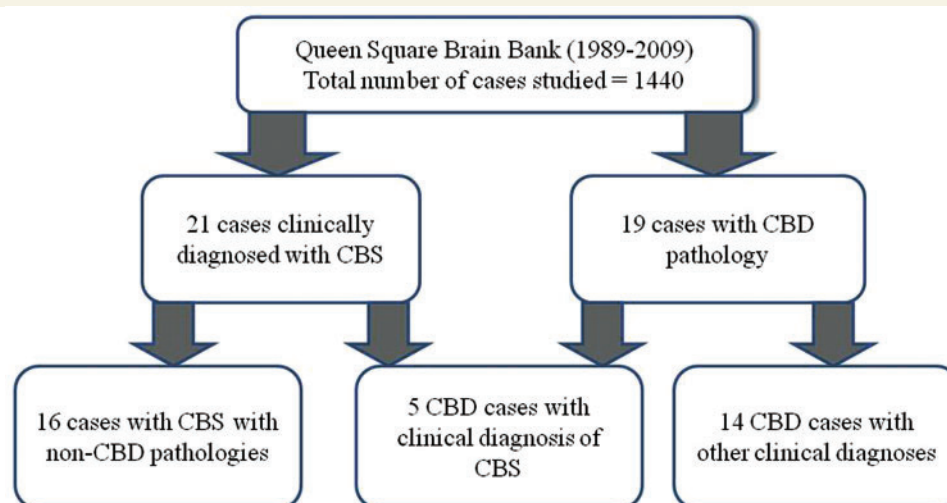


Figure 1 Cases with either a clinical diagnosis of CBS or pathological diagnosis of CBD included in the present study.

for continuous variables and the chi-square or Fisher's exact tests for categorical variables by Statistical Package for the Social Sciences (SPSS 17.0).

Results

All cases included in the present study

Of the 1440 cases in the Queen Square Brain Bank collected over the 20-year period, there were 179 cases with a pathological diagnosis of PSP, 117 multiple system atrophy and 608 Parkinson's disease. We identified 35 patients (16 female, 19 male) with either a final clinical diagnosis of CBS or pathological diagnosis of CBD (Fig. 1). Twenty-one of these had been followed up regularly at the National Hospital for Neurology and Neurosurgery (nine under the movement disorders team, six under the cognitive disorders team, four jointly by both teams, one followed up by a general neurologist and the other by a neuropsychiatrist). Of the 14 cases seen in other hospitals, nine were under the care of general neurologists and five followed by movement disorders specialists.

Cases with pathological diagnosis of CBD

Clinical diagnoses of the pathologically diagnosed CBD cases

Of the 35 patients included in the present study, 19 (9 female, 10 male) had CBD pathology (Fig. 1). Five of these had been diagnosed with CBS at the time of death. The diagnoses in the other 14 cases were PSP ($n=8$), Parkinson's disease ($n=2$), frontotemporal lobar degeneration ($n=1$), Pick's disease ($n=1$), spastic quadriplegia with myoclonus ($n=1$) and Gilles de la Tourette's syndrome ($n=1$). At the time of first neurological specialist review, eight had been initially diagnosed with Parkinson's disease, two

with PSP and the rest with other movement disorder or dementia syndromes.

Incidental finding of CBD pathology in one case

One patient had the incidental finding of CBD pathology at post-mortem. The patient developed motor tics at age eight, followed by vocal tics several years later and was followed up with the psychiatrists at the National Hospital for Neurology and Neurosurgery, during which he joined the Queen Square Brain Bank brain donor programme. Four generations of his family had also had tics. At age 63 he died of metastatic carcinoma of the prostate. Before his death, there was no documentation of any neurological symptoms or signs suggestive of a progressive neurodegenerative disorder.

Clinical features of cases with CBD pathology

The demographic features of all pathologically confirmed CBD cases are summarized in Table 1 and are similar to those reported in previous studies (Gibb *et al.*, 1989; Litvan *et al.*, 1997; Grimes *et al.*, 1999; Murray *et al.*, 2007).

Nine CBD cases (47%) had a markedly asymmetrical presentation. Seven patients (37%) had delayed initiation of horizontal saccadic eye movements. The majority of cases with features suggestive of CBS were correctly diagnosed in life. Twelve (63%) were noted to have a vertical supranuclear gaze palsy. Initial clinical presentation of parkinsonism was observed in nine (47%), aphasia in three (16%) and memory decline characterized by retrieval difficulties in seven (37%), four of whom also had executive dysfunction. Six of 12 patients with initial gait difficulty also had symmetrical bradykinesia. Sixteen patients (84%) had been prescribed L-dopa, nine of whom (56%) had transient mild to moderate improvement and three (17%) had developed reversible and dose-related dystonic or choreiform movements of the limbs. Focal asymmetrical cortical atrophy was found in only three out of the 14 cases (21%) who had had a brain MRI.

Table 1 Clinical parameters of 19 cases with CBD

| Clinical parameters | All cases (n = 19) | CBD–CBS (n = 5) | CBD–Richardson's syndrome (n = 8) |
|--|------------------------|-------------------------------------|-------------------------------------|
| Female:male | 9:10 | 2:3 | 4:4 |
| Age of symptom onset, years | 66.3 (5.3) (56.6–77.2) | 69.0 (4.8) (64.3–76.3) [†] | 62.8 (3.7) (56.6–69.5) [†] |
| Duration of illness, years | 6 (1.8) (4.0–9.3) | 6.3 (1.7) (4.8–8.8) | 5.6 (1.9) (4.0–9.3) |
| Age of death, years | 71.7 (5.4) (63.8–81.6) | 75.3(4.2) (70.9–81.0) [†] | 68.1 (3.3) (65.1–73.8) [†] |
| Duration from final diagnosis to death, years | 2.3 (1.9) (0.1–6.3) | 3.2 (2.1) (1.0–6.3) [†] | 1.5 (0.5) (0.8–2.3) [†] |
| Cases where final clinical diagnosis was different from initial clinical diagnosis | 14 cases | 4 cases | 7 cases |
| Disease duration at time of final clinical diagnosis, years | 4.2 (1.9) (1.0–8.0) | 3.6 (1.9) (0.1–5.5) | 4.1 (2.1) (2.4–8.0) |
| Duration from final diagnosis to death, years | 1.9 (1.1) (0.0–3.8) | 2.5 (1.3) (1.0–3.8) | 1.5 (0.5) (0.8–2.3) |

Data are mean (SD) (range); [†] $P < 0.05$ comparing between CBD–CBS and CBD–Richardson's syndrome subgroups using Student's *t*-test.

Clinical features of CBD subgroups

CBD cases clinically diagnosed with CBS

Four of the five pathologically confirmed CBD cases who were considered to have CBS (CBD–CBS) had received an alternative earlier diagnosis [Parkinson's disease ($n = 2$), PSP ($n = 1$) and spastic paraparesis ($n = 1$)]. All had presented with a clumsy useless limb and had subsequently developed symptoms of ideomotor apraxia and action myoclonus (Table 2). Focal limb dystonia ($n = 4$), cortical sensory loss ($n = 4$), alien limb ($n = 3$) and stimulus-sensitive myoclonus ($n = 2$) were also noted. Delayed initiation of horizontal saccades was observed in three cases. Of the four patients who had received L-dopa, only one had a positive L-dopa challenge test with transient improvement in mobility and subsequently developed a reversible L-dopa induced foot dystonia. None of the three cases who had an MRI showed focal or asymmetrical cortical atrophy. One patient had decreased speech fluency at presentation that later manifested as progressive non-fluent aphasia with preserved comprehension.

CBD cases clinically diagnosed with PSP

Among the eight CBD cases who had been diagnosed with PSP, seven were initially considered to have had a different disorder [Parkinson's disease ($n = 3$), unclassifiable akinetic rigid syndrome ($n = 1$), multiple system atrophy ($n = 1$), Alzheimer's disease ($n = 1$) and frontotemporal lobar degeneration ($n = 1$)]. All of them had a vertical supranuclear gaze palsy ($n = 8$) (Table 2). Seven had presented with gait difficulty and five had prominent postural instability with backward falls in the first year. Other symptoms and signs pointing, in hindsight, towards a clinical diagnosis of PSP were apraxia of eyelid opening ($n = 5$), frontalis hyperactivity ($n = 4$) and frontal and subcortical cognitive impairment ($n = 4$). All patients were prescribed L-dopa, six of whom experienced transient mild to moderate improvement and two of whom developed L-dopa induced dyskinesia. The MRI of one patient showed unequivocal midbrain atrophy. One patient had aphasia at presentation, characterized by fluent phonemic paraphasia.

Not surprisingly, the clinical features of this PSP-lookalike subgroup (CBD–Richardson's syndrome) were very different from the CBD–CBS subgroup. There were more CBD–CBS patients with initial presentation of a useless limb, limb apraxia and dystonia, action myoclonus, cortical sensory loss, alien limb and asymmetrical clinical features ($P < 0.05$, Table 2). On the other hand, there

were more CBD–Richardson's syndrome patients with vertical supranuclear gaze palsy, early falls and symmetrical bradykinesia ($P < 0.05$, Fig. 2).

One of the two CBD–Richardson's syndrome patients, with asymmetric presentation, manifested clinical features of CBS at late stage, whereas the other had recorded absence of these features (Fig. 2).

CBD cases clinically diagnosed with Parkinson's disease

Two patients presented with strongly asymmetrical tremor-predominant parkinsonism and the presumptive diagnosis of Parkinson's disease remained unchanged throughout the disease course. Review of the notes, however, revealed a poor L-dopa response, short duration of disease (4.5 and 5.7 years), early onset of falls (0.1 and 2.8 years) and early wheelchair dependence (4 and 5 years). The hand tremor was coarse, jerky and more obvious on movement than at rest and neither patient had a classical pill-rolling resting tremor. One patient had perseveration, apraxia of eyelid opening and developed visual hallucinations after an increase of L-dopa to 800 mg/day. Ocular movements were not recorded at late stage of disease in one patient.

CBD case clinically diagnosed with Pick's disease

One patient presented with verbal communication and language difficulties (progressive non-fluent aphasia phenotype) and was initially diagnosed with depression. Three years after the onset of her first symptoms, she was noted to have orofacial apraxia and dysphagia and 2 years later, she developed prominent abulia and anhedonia (behavioural variant of frontotemporal degeneration phenotype). In 2004, she was diagnosed with Pick's disease. Seven years into her illness, she developed limb apraxia, a symmetrical akinetic-rigid syndrome, gait difficulty, falls and a vertical supranuclear gaze palsy with delayed initiation of saccades in all directions. She died at age 74 after a disease course of 9 years.

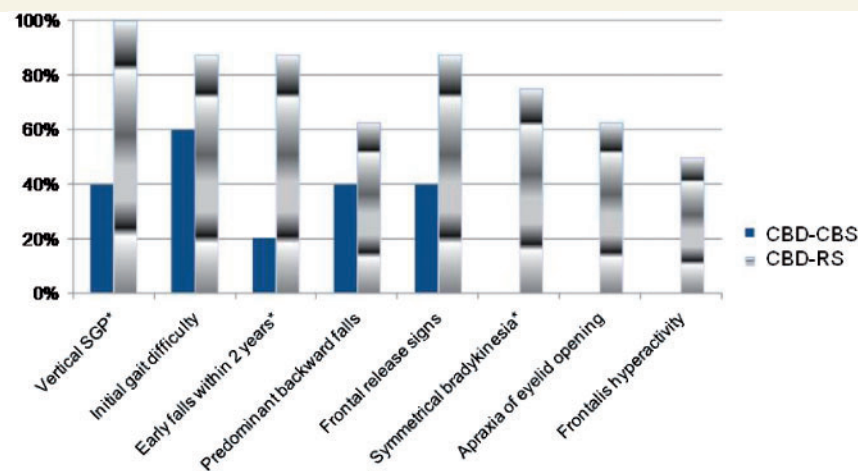
CBD case clinically diagnosed with frontotemporal lobar degeneration

This patient presented with an asymmetrical tremor-predominant parkinsonism in association with early striking behavioural change and memory impairment. He was initially diagnosed with Parkinson's disease although there was no response to therapeutic doses of L-dopa. Four years into his illness, disinhibition, anti-social behaviour and excessive spending were striking clinical features

Table 2 Clinical features of CBD–CBS and CBD–Richardson's syndrome subgroups

| Clinical features | CBD–CBS subgroup (n = 5) | CBD–Richardson's syndrome subgroup (n = 8) | P-values |
|---|--------------------------|--|-------------------|
| Classical CBS phenotype | | | |
| Initial useless limb | 5 | 0 | 0.001* |
| Asymmetrical features | 5 | 2 | 0.02* |
| Alien limb | 3 | 0 | 0.04* |
| Limb dystonia | 4 | 1 | 0.03* |
| Cortical sensory loss | 4 | 0 | 0.002* |
| Limb apraxia | 5 | 1 | 0.005* |
| Action myoclonus | 5 | 2 | 0.02* |
| Delayed initiation of saccade | 3 (unknown:1) | 3 | ns |
| Duration from first symptom to onset of delayed initiation of saccade | 4.7 years (2.5–7.7) | 3.7 years (2.5–5.8) | ns |
| Classical PSP phenotype | | | |
| Symmetrical bradykinesia | 0 | 6 | 0.02* |
| Vertical supranuclear gaze palsy | 2 (unknown:1) | 8 | 0.04* |
| Predominant downgaze abnormalities | 0 | 3 | ns |
| Duration from first symptom to onset of supranuclear gaze palsy | 5.9 years (4–7.7) | 3.4 years (1.2–7.3) | ns |
| Duration from first symptom to onset of falls | 2.4 years (1.0–3.0) | 1.0 years (0.0–3.0) | 0.04 [†] |
| Early falls within 2 years | 1 | 7 | 0.03* |
| Predominant backward falls | 2 | 5 | ns |
| Frontal release signs | 2 | 7 | ns |
| Apraxia of eyelid opening | 0 | 5 | ns |
| Frontalis hyperactivity | 0 | 4 | ns |
| Cognitive/psychiatric features | | | |
| Initial behavioural change | 0 | 4 | ns |
| Initial memory decline | 1 | 3 (unknown:1) | ns |
| Initial aphasia | 1 | 1 (unknown:1) | ns |
| Orobuccal apraxia | 1 | 0 (unknown:1) | ns |
| Hallucination | 0 | 1 | ns |
| Pyramidal/extrapyramidal features | | | |
| Initial parkinsonism | 2 | 4 | ns |
| Tremor | 2 | 2 | ns |
| Pyramidal signs | 2 | 4 | ns |

ns = not statistically significant. * $P < 0.05$ comparing between CBD–CBS and CBD–Richardson's syndrome subgroups using Chi-square test; [†] $P < 0.05$ comparing between CBD–CBS and CBD–Richardson's syndrome subgroups using Student's *t*-test.



CBD: corticobasal degeneration; CBS: corticobasal syndrome; RS: Richardson's syndrome; SGP: supranuclear gaze palsy; * p value < 0.05 , comparing between CBD–CBS and CBD–RS subgroups using Chi-square test

Figure 2 The differentiating clinical features between the CBD–CBS and CBD–Richardson's syndrome subgroups. SGP = supranuclear gaze palsy. * P -value $< .05$, comparing between CBD–CBS and CBD–Richardson's syndrome subgroups using chi-squared test.

and the diagnosis was revised to frontotemporal lobar degeneration. A few months before death, he was noted to have a vertical downgaze supranuclear gaze palsy. The patient died at the age of 69 years after a disease course of 5 years.

CBD case clinically diagnosed with spastic quadriparesis with myoclonus of unknown cause

This patient presented with difficulty walking and recurrent falls and examination revealed bilateral pyramidal leg weakness with decreased vibration sense. She was first investigated for possible multiple sclerosis. In the following 2 years, the pyramidal weakness gradually involved her arms and she developed generalized marked action myoclonus and a symmetrical akinetic rigid syndrome without response to L-dopa. She had pathological reflexes, equivocal plantar responses and normal cortical sensation. In 1995, despite extensive investigations, no underlying cause for her spastic quadriparesis was identified. Differential diagnosis shortly before death included spinal interneuronitis and primary lateral sclerosis. MRI showed symmetrical cerebral atrophy with focal atrophy in the peri-Rolandic area. The patient died at age 75 years after a disease course of 8 years.

CBD cases with secondary pathology

One of the five clinically diagnosed CBS patients, who died aged 77 years, had Lewy body pathology in the neocortex and brain stem and moderate cerebral amyloid angiopathy. Another who presented with right hand apraxia and alien limb, had a cerebral infarction of the left middle cerebral artery territory in addition to the characteristic pathological changes associated with CBD.

Two of the eight cases, who had been clinically diagnosed as PSP, had additional pathological findings. One patient, who died at age 74 with a history of early falls, supranuclear gaze palsy, apraxia of eyelid opening in association with frontal executive dysfunction and one recorded episode of hallucination, was found to have severe cerebral amyloid angiopathy and pathological ageing with amyloid- β deposition in the neocortical and medial temporal regions. Another patient, who initially presented with walking difficulties followed by the development of classical Richardson's syndrome, was found to have small vessel cerebral vascular disease with Binswanger-type cerebral white matter changes.

The patient who was clinically diagnosed with Pick's disease had mild small vessel cerebral vascular disease with pathological ageing.

Cases with a clinical diagnosis of CBS

We identified 16 cases with CBS that did not have associated CBD pathology. There were six cases with PSP, five with Alzheimer's disease, two with Parkinson's disease, one with frontotemporal lobar degeneration-TDP43 subtype 2, one with frontotemporal lobar degeneration-TDP43 with motor neuron disease and one with dementia lacking in distinctive histology. The clinical features of the cases with CBS are summarized in Table 3.

Although five out of the six cases with pathological changes of PSP and CBS had asymmetrical clinical features, they also manifested some features that might have suggested PSP i.e. vertical

supranuclear gaze palsy was noted in three cases and early falls within 2 years of onset of first symptoms was also reported in three cases. Four had prominent frontal release signs including positive palmomental and grasp reflex, glabellar tap and utilization behaviour, and one of whom had frontal cognitive dysfunction. The mean onset of vertical supranuclear gaze palsy was 2.2 years from first symptom onset; this short duration had borderline statistical significance when compared to cases with CBD, Parkinson's disease and frontotemporal lobar degeneration pathologies ($P=0.09$). There were significantly more PSP (100%) and CBD cases (80%) with unprovoked falls when compared to the cases of Alzheimer's disease (0%) ($P=0.005$). Apraxia of eyelid opening was noted in three PSP cases while none of the CBD or Alzheimer's disease cases had this feature ($P=0.06$). Parkinsonism at presentation was observed in both the Parkinson's disease cases, three of the PSP cases, but in none of the Alzheimer's disease cases ($P=0.07$). One patient with Alzheimer's disease presented with word-finding difficulty followed by expressive aphasia.

Both Parkinson's disease cases also had focal limb dystonia in late stage of disease and one had limb apraxia. The mean duration of illness of Parkinson's disease cases (17.3 years) was much longer than the rest of the cases ($P=0.01$). Both had moderate response to L-dopa for prolonged duration of 5.3 and 19.8 years, respectively.

The patient with frontotemporal lobar degeneration-TDP43-motor neuron disease presented with dyspraxia of the right hand followed by speech and swallowing difficulty. Nerve conduction studies revealed chronic partial denervation and fasciculations in the late stages of the illness. Another patient with frontotemporal lobar degeneration-TDP43 subtype 2 presented with clumsiness of one arm followed by behavioural changes suggestive of frontotemporal dementia-like syndrome. The patient had early marked delayed in initiation of horizontal saccades. The patient with dementia lacking in distinctive histology presented with depression, limb apraxia and dystonia. Cognitive decline and behavioural changes followed.

Additional pathology in the CBS cases

Of the cases with PSP pathology ($n=6$), one had mild cerebral amyloid angiopathy. Among the Alzheimer's disease cases ($n=5$), one had incidental Lewy body pathology, one had cerebral amyloid angiopathy and one had small vessel cerebral vascular disease. One of the Parkinson's disease cases had minor limbic cortical Lewy body involvement while the other had moderate neocortical Lewy bodies. The patient with frontotemporal lobar degeneration-TDP with motor neuron disease pathology also had Alzheimer pathology (Braak and Braak stage II) and small vessel cerebral vascular disease.

Diagnostic accuracy of CBD and other parkinsonian disorders

Of the 19 pathologically diagnosed CBD cases, only five were accurately diagnosed as CBS in life, giving a sensitivity of 26.3% (Table 5). The positive predictive value of the clinical diagnosis of

Table 3 Clinical features of cases with CBS

| Clinical features | Cases with CBS (n=21) | | | | |
|---|-----------------------|---------------------|-------------------------------------|-------------------------------------|-------------------------------|
| | CBD pathology (n=5) | PSP pathology (n=6) | Alzheimer's disease pathology (n=5) | Parkinson's disease pathology (n=2) | FTLD pathology and DLDH (n=3) |
| Classical CBS phenotype: | | | | | |
| Initial useless limb | 5 | 2 | 2 | 0 | 1 |
| Asymmetrical features | 5 | 5 | 2 | 1 | 2 |
| Alien limb | 3 | 1 | 2 | 0 | 0 |
| Limb dystonia | 4 | 4 | 0 | 2 | 2 |
| Cortical sensory loss | 4 | 2 | 5 | 0 | 0 |
| Limb apraxia | 5 | 4 | 5 | 1 | 2 |
| Action myoclonus | 5 | 3 | 5 | 0 | 0 |
| Duration from first symptom to onset of myoclonus | 2.7 years (1.3–4) | 4.1 years (1.5–6.8) | 4.0 years (2.0–6.5) | na | na |
| Delayed initiation of saccade | 3 | 3 (nk:1) | 1 | 0 (nk:1) | 1 |
| Classical PSP phenotype: | | | | | |
| Vertical SGP | 0 | 0 (nk:1) | 3 | 1 (nk:1) | 1 |
| Predominant downgaze | 2 | 3 | 1 | 0 | 2 |
| Abnormalities | 0 | 2 | 1 | 1 | 0 |
| Duration from first symptom to onset of SGP | 5.9 years (4–7.7) | 2.2 years (1.7–3.1) | 2.0 years (2.0–2.0) | na | na |
| Early falls within 2 years | 1 | 3 | 1 | 0 | 1 |
| Unprovoked falls | 4 | 6 | 0 | 0 | 2 |
| Frontal release signs | 2 | 4 | 1 | 2 | 2 |
| Apraxia of eyelid opening | 0 | 3 | 0 | 0 | 2 |
| Cognitive/psychiatric features | | | | | |
| Initial memory decline | 1 | 1 (nk:1) | 4 | 0 (nk:1) | 1 |
| Initial aphasia | 1 | 0 (nk:1) | 1 | 0 (nk:1) | 0 |
| Hallucination | 0 | 0 | 1 | 1 | 0 |
| Pyramidal/extrapyramidal features | | | | | |
| Initial parkinsonism | 2 | 3 | 0 | 2 | 0 |
| Pyramidal signs | 2 | 4 | 1 | 0 | 1 |

DLDH = dementia lacking in distinctive histology; na = not applicable; nk = not known, features not recorded in case notes; SGP = supranuclear gaze palsy; FTLD = frontotemporal lobular degeneration.

CBS was 23.8%, with five cases confirmed to have CBD pathology out of 21 cases clinically diagnosed with CBS. The high specificity for CBD (98.9%) indicated that cases without CBD pathology were correctly identified in life as not having the condition.

The positive predictive value for a clinical diagnosis of Parkinson's disease in the Queen Square Brain Bank was 82.7% (564 out of 682), 69% for PSP (131 out of 190) and 70.1% for multiple system atrophy (82 out of 117), figures which contrast strikingly with those obtained for CBD in this study (Table 4).

The sensitivities for other major parkinsonian disorders were also much higher than in CBD (Table 4). The sensitivity for Parkinson's disease was 92.8% (564 out of 608), indicating the high proportion of cases with Parkinson's disease pathology that had been correctly diagnosed with Parkinson's disease in life. The sensitivity for PSP was 73.2% (131 out of 179) and 70.1% for multiple system atrophy (82 out of 117). In agreement with previous studies, the specificity for Parkinson's disease was lower than other parkinsonian disorders suggesting Parkinson's disease was over-diagnosed (Litvan *et al.*, 1998).

Discussion

A previous study of 143 cases of parkinsonism followed by movement disorder specialists at the National Hospital for Neurology and Neurosurgery reported that of four cases with CBD pathology, only one had been diagnosed correctly in life; whereas in the three cases with clinical CBS, only one had CBD pathology at post-mortem (Hughes *et al.*, 2002). Diagnostic accuracy of CBD does not appear to have improved in the decade since this article was published, suggesting that the clinical spectrum of CBD remains poorly delineated and that the nosological entity first described by Rebeiz and colleagues (1967) is extremely difficult to diagnose accurately in life. The low sensitivity in predicting CBD reported in this study is consistent with the findings of other published clinicopathological series (Litvan *et al.*, 1997; Grimes *et al.*, 1999; Boeve, 2005; Murray *et al.*, 2007). It is also evident that CBS is much more likely to be caused by a pathology other than that described as characteristic of CBD, which is reflected by the low positive predictive value of 23.8% in our series. Five of the eleven cases with CBS presentation followed by movement

Table 4 Summary of diagnostic accuracies for CBD and other parkinsonian disorders among a total of 1440 cases in the Queen Square Brain Bank for Neurological Disorders database over a 20-year period

| Disorder | Sensitivity (95% CI) | Specificity (95% CI) | PPV (95% CI) | NPV (95% CI) |
|-------------------------|----------------------|----------------------|------------------|------------------|
| CBD | 26.3 (9.1–51.0) | 98.9 (98.2–99.4) | 23.8 (8.2–47.2) | 99.0 (98.4–99.5) |
| PSP | 73.2 (66.1–79.5) | 95.3 (94.0–96.4) | 69.0 (61.8–75.4) | 96.2 (94.9–97.2) |
| Multiple system atrophy | 70.1 (60.9–78.2) | 97.4 (96.3–98.2) | 70.1 (60.9–78.2) | 97.4 (96.3–98.2) |
| Parkinson's disease | 92.8 (90.4–94.7) | 85.8 (83.3–88.1) | 82.7 (79.6–85.5) | 94.2 (92.3–95.8) |

CI = confidence interval; NPV = negative predictive values; PPV = positive predictive values.

disorder specialists were confirmed to have CBD pathology. The positive predictive value for movement specialists was 45.5%, which is almost twice as high as the overall positive predictive value. Out of the remaining 10 cases diagnosed with CBS, followed by general neurologists or cognitive neurologists, none had CBD pathology.

CBD cases correctly identified in previous published series manifested all the classical features reported in the seminal description by Rebeiz and colleagues (1967), but together they constituted less than half of all cases with CBD pathology (28 out of 60) (Table 5). Most of the cases in our series had been followed by movement disorder specialists, which differs from some of the other reported series where referral came primarily from cognitive disorder clinics (Boeve, 2005; Murray *et al.*, 2007; Shelley *et al.*, 2009). The difference in referral source almost certainly accounts for the marked overlap between CBD and PSP identified in our series whereas in the publications coming from cognitive disorder clinics, confusion between CBD and frontotemporal dementia, progressive non-fluent aphasia and Alzheimer's disease was more frequent (Hodges *et al.*, 2004; Alladi *et al.*, 2007; Josephs *et al.*, 2008). Hodges *et al.* (2004) reported nine cases with a clinical diagnosis of CBS, of whom seven had been confirmed to have CBD pathology and one each had frontotemporal dementia-motor neuron disease and dementia lacking in distinctive histology. In a series of 100 patients with pathologically confirmed focal cortical syndromes 12 presented with CBS and six of them had CBD pathology while the other six fulfilled pathological criteria for Alzheimer's disease (Alladi *et al.*, 2007). Conversely, of the 12 cases with CBD pathology, on autopsy, 6 had presented with CBS, 4 with behavioural or cognitive variant of frontotemporal degeneration and 2 with progressive non-fluent aphasia.

Some previous publications have reported overlap between CBD and PSP, but to a significantly lesser extent than found in our study (Boeve, 2005; Josephs *et al.*, 2006; Murray *et al.*, 2007). In the Mayo Clinic series, 7 out of 32 CBD cases (22%) had been diagnosed with PSP in life and 6 out of 36 cases (17%) with CBS were found to have PSP pathological changes (Boeve, 2005). In one study where 10 pathologically diagnosed CBD cases were reconstructed as case vignettes and presented to neurologists, 42% of CBD cases received a clinical diagnosis of PSP (Litvan *et al.*, 1997). In the present study, 8 out of 19 CBD cases had been diagnosed with PSP (42%) and of the 21 cases clinically diagnosed with CBS, 6 were found to have PSP pathology (29%).

In our cohort, there are two main clinical variants that present to movement disorder specialists and are associated with the

Table 5 Summary of sensitivity in predicting CBD pathology in life

| Studies | CBD cases | Cases accurately diagnosed in life | Sensitivity (%) |
|-----------------------------|------------|------------------------------------|---------------------------|
| Grimes <i>et al.</i> (1999) | 13 | 4 | 31 |
| Boeve <i>et al.</i> (2005) | 32 | 18 | 56 |
| Murray <i>et al.</i> (2007) | 15 | 6 | 40 |
| | Total = 60 | Total = 28 | Overall sensitivity = 47% |

pathological changes considered characteristic of CBD. We have provisionally termed those patients who present with the classical features first described by Rebeiz and colleagues (1967) and subsumed under the generic rubric of the corticobasal syndrome, CBD–CBS. The more problematic and numerous group are patients who closely resemble classical PSP and which we have termed CBD–Richardson's syndrome. These cases are characterized by vertical supranuclear gaze palsy, early falls within 2 years and symmetrical bradykinesia and, therefore, had been given a clinical diagnosis of PSP (Fig. 2). Four of eight cases in the CBD–Richardson's syndrome subgroup would have fulfilled the probable National Institute of Neurological Disorders and Stroke–PSP diagnostic criteria, the other four being excluded on the grounds of amnesia and aphasia (Litvan *et al.*, 1996). A previous Queen Square Brain Bank study identified vertical supranuclear gaze palsy, early falls and frontolimbic cognitive dysfunction as the characteristic features of Richardson's syndrome (Williams *et al.*, 2005). Symmetrical motor handicap has been considered a helpful diagnostic pointer in distinguishing PSP from CBD, and represented one of the reasons why some of the CBD–Richardson's syndrome cases had been clinically diagnosed with PSP. Post-mortem studies showed that aphasia and dementia can be presenting features in both CBD and PSP (Masliah *et al.*, 1991; Grimes *et al.*, 1999; Josephs and Duffy 2008). Of interest, the age of symptom onset and age of death were significantly younger in the CBD–Richardson's syndrome subgroup (62.8 and 68.1 years) compared to the CBD–CBS subgroup (69 and 75.3) although considerable overlap makes this an unreliable distinguishing criterion in the individual case (Table 1).

Delayed initiation of saccades may be helpful as a feature suggestive of underlying parietal lobe dysfunction and this ocular

abnormality has been shown to correlate with the degree of limb apraxia in cases with CBS (Vidailhet *et al.*, 2000), however, this can be a difficult clinical sign to elicit with certainty. A supranuclear gaze paresis in both the vertical and horizontal plane can also be observed in CBD, but when present it is usually in the terminal phase of the illness. In PSP, vertical saccades are slow and hypometric and are more affected than horizontal ones (Vidailhet *et al.*, 1994). Clinical diagnostic criteria for PSP have emphasized the importance of downgaze abnormalities (Lees, 1987; Litvan *et al.*, 1996; Williams *et al.*, 2005).

Our study identified Richardson's syndrome as the most common phenotypic presentation of CBD, while the classical presentation of CBS was only found in a quarter of CBD cases. The clinical features in CBD-Richardson's syndrome cases closely resemble classical cases with PSP pathology. We retrospectively noted some clinical features that might point to underlying CBD pathology but further validation of these differences will be required. For instance, vertical supranuclear gaze palsy was detected at a later stage in CBD-Richardson's syndrome (3.4 years) than in cases with PSP pathology and CBS (2.2 years). Vertical supranuclear gaze palsy predominantly affecting downgaze was infrequent in CBD-Richardson's syndrome (three in eight). Delayed initiation of saccades noted in three CBD-Richardson's syndrome cases (38%) can be helpful when present in distinguishing CBD-Richardson's syndrome from PSP-Richardson's syndrome. This feature however is not specific for CBD pathology and can be found in cases with PSP and Alzheimer's disease pathology presenting with CBS. Age of symptom onset in our CBD-Richardson's syndrome subgroup (62.8 years, SD 3.7) was younger than the archival Queen Square Brain Bank cases with PSP pathology (66.4 years, SD 12) (Williams *et al.*, 2005). Nevertheless, until more reliable diagnostic markers become available, the division of CBD–CBS and CBD-Richardson's syndrome subtypes can only be confirmed retrospectively. The classical PSP phenotype was accountable for over a third of all CBD cases, whereas PSP was the most common pathology underlying cases with CBS presentation, emphasizing the considerable diagnostic difficulties and significant overlap between these two primary four repeat tauopathies. Conversely, among the Queen Square Brain Bank archival collection of PSP cases, CBS is a rare clinical presentation occurring in only 6 of the 179 pathologically diagnosed PSP cases (3%), and only 5 out of 160 PSP cases (3%) in the Mayo Clinic series were found to have CBS presentation (Tsuboi *et al.*, 2005).

Three other clinical presentations of CBD were also noted in this study: (i) a rapidly progressive L-dopa unresponsive asymmetrical tremulous-parkinsonism with early postural instability; (ii) progressive non-fluent aphasia and (iii) behavioural variant of frontotemporal dementia. Progressive non-fluent aphasia and behavioural or cognitive variant of frontotemporal degeneration are both recognized clinical phenotypes of CBD (Josephs *et al.*, 2006; Geda *et al.*, 2007; Murray *et al.*, 2007). CBD can also present as an amnesic syndrome or posterior cortical atrophy, and is sometimes misdiagnosed as Alzheimer's disease (Grimes *et al.*, 1999; Boeve, 2005).

As few as one in four cases with clinical CBS who come to autopsy are associated with CBD pathology, suggesting that

previous studies based on clinical diagnostic criteria and neuroimaging studies alone could be considered as unreliable. Post-mortem series prior to the publication of validated neuropathological criteria (Dickson *et al.*, 2002) may also have introduced error due to the overlapping pathological findings of CBD with other tauopathies such as PSP and Pick's disease. Secondary pathologies observed in 12 out of our 35 cases may, in some cases, have influenced the phenotype. Specific topographic distribution of tau pathology has been reported to correlate with clinical phenotypes in a small study that reported an increased tau burden in mid-frontal and inferior-parietal cortices in three PSP cases who presented with CBS (Tsuboi *et al.*, 2005).

Clinical presentation of CBS can be associated with a variety of underlying pathologies. If the disease course is very malignant with rapid clinical progression, the differential diagnoses of frontotemporal dementia-TDP43 with progranulin mutation, neurofilament inclusion body disease and prion disease should be considered. If the symptom onset is acute followed by a static course, cerebrovascular disease is more likely whereas slow symptom progression with long disease duration along with sustained L-dopa response are more suggestive of Parkinson's disease. *microtubule-associated protein tau* or progranulin mutation should be considered in cases with at least one first degree relative with CBS, dementia or primary progressive aphasia (Cairns *et al.*, 2007; Le Ber *et al.*, 2008; Tartaglia *et al.*, 2009). A recent study identified initial episodic memory complaints as a specific predictor for Alzheimer's disease with CBS presentation (Shelley *et al.*, 2009). In our series, initial memory decline was also more common in Alzheimer's disease with CBS while none of the CBD–CBS cases had this feature. On the other hand, cortical sensory loss and action myoclonus were equally common in both Alzheimer's disease–CBS and CBD–CBS subgroups and it is interesting to note that action myoclonus was an early feature (within first 3 years of illness) in three of five Alzheimer's disease–CBS cases.

We have identified three features which we believe are helpful in excluding CBD in cases presenting with CBS: namely, a sustained initial L-dopa response for over 2 years, early vertical supranuclear gaze palsy within 2 years of first symptom onset and finally, a disease duration of over 10 years. By applying these criteria retrospectively, we can exclude two Parkinson's disease and two PSP cases, along with another case diagnosed with frontotemporal lobar degeneration-TDP43 with motor neuron disease supported by electrophysiological findings. These more stringent criteria allow the exclusion of five false positive cases; accuracy in predicting CBD pathology in patients with CBS is improved from 23.8% to 31.3% (5 of 16 cases) and accuracy in predicting tau pathology in CBS reaches 69% (5 CBD, 6 PSP out of 16 cases). CBS is much more sensitive in predicting tau pathology than CBD pathology. Other post-mortem series had an overall 83% of CBS cases with tauopathy (Wadia *et al.*, 2007). PSP-like syndrome and progressive non-fluent aphasia are other clinical presentations that were identified to accurately predict underlying tau pathology (Hodges *et al.*, 2004; Josephs *et al.*, 2006). In the present series, 14 out of 19 CBD cases (73%) had a clinical presentation of either CBS, PSP or progressive non-fluent aphasia.

CBD and PSP are sporadic diseases sharing important biological and morphological features. In both conditions, the possession of H1 allele of the *microtubule-associated protein tau* gene and, in particular, the H1/H1 genotype is a risk factor and the accumulation of 4R-tau in both neuronal and glial inclusions is characteristic (Baker *et al.*, 1999; Houlden *et al.*, 2001). These similarities have led some authors to propose that CBD and PSP are actually the same disorder with a wide spectrum of pathological and clinical manifestations (Scaravilli *et al.*, 2005). Nevertheless, their classical clinical presentations are strikingly different and the neuropathological diagnostic criteria of CBD and PSP were validated with high sensitivity and specificity (Litvan *et al.*, 1996; Dickson *et al.*, 2002). Although both conditions share extensive neuronal tau pathology, astrocytic plaques of CBD are characteristic while in PSP, tufted astrocytes are the hallmark glial lesion (Dickson, 1999). Furthermore Ishizawa *et al.* (2001) have also demonstrated distinct patterns of microglial activation and tau distribution in pathologically diagnosed CBD and PSP cases. These findings support the notion that CBD and PSP are distinct if closely related clinicopathological entities, which have a tendency to occur in patients sharing a similar genetic predisposition.

The greatest strength of this study is its size and the use of modern immunohistochemical techniques to characterize the underlying pathology. All patients were reviewed by hospital specialists and the majority (60%) was followed up at the National Hospital for Neurology and Neurosurgery, a tertiary referral centre, where atypical presentations, overlap syndromes and diagnostic conundrums are frequently seen. An over-inclusion of diagnostically more challenging cases occurs in any brain bank post-mortem series and the retrospective review of medical records has inherent limitations. The predominant referral from movement disorder clinics can also potentially lead to referral bias. Cognitive and language functions were not, until recently, consistently tested and recorded in those patients presenting with predominant motor handicap and could have resulted in underestimation of neuropsychiatric features. Six of 35 cases did not receive full neuropsychological evaluations. Nevertheless, we believe that our findings are relevant for neurological practice.

Conclusion

We have identified a number of pathologically confirmed CBD cases whose clinical picture more closely resembled PSP than CBS. CBD cases with PSP-like presentation often have delayed onset of vertical supranuclear gaze palsy after 3 years and infrequent observation of downgaze predominant abnormalities. Despite the clinical heterogeneity of CBD and the increasingly wide differential diagnosis of the CBS, we conclude that CBD should continue to be considered a distinct clinicopathological entity with an abnormality of tau aggregation that closely links it with PSP.

Acknowledgements

We wish to thank the patients and their families, without whose support none of this research would have been possible. Susan

Stoneham, Robert Courtney, Hilary Ayling and Kate Strand for their help with tissue preparation, data retrieval and technical support. Dr Constantin Kallis for his statistical advice. Drs Laura Silveira-Moriyama, Laura Parkkinen, Connie Luk, Rohan de Silva and Zeshan Ahmed for their valuable advice on data presentation, all of which were essential to this study.

Funding

The Reta Lila Weston Trust; The PSP Association, Europe (to L.A.M.).

Conflict of Interest: H. L. received the Junior Award for excellence in clinical research from the Movement Disorder Society and presented this work in the Presidential Lecture Plenary Session at the 13th International Congress of Parkinson's Disease and Movement Disorders in Paris, France on 9th June 2009.

References

- Case Records of the Massachusetts General Hospital. Weekly clinicopathological exercises. Case 38-1985. A 66-year-old man with progressive neurologic deterioration. *N Engl J Med* 1985; 313: 739–48.
- Alajouanine T. Aphasia and artistic realization. *Brain* 1948; 71: 229–41.
- Alladi S, Xuereb J, Bak T, Nestor P, Knibb J, Patterson K, et al. Focal cortical presentations of Alzheimer's disease. *Brain* 2007; 130: 2636–45.
- Arai T, Ikeda K, Akiyama H, Shikamoto Y, Tsuchiya K, Yagishita S, et al. Distinct isoforms of tau aggregated in neurons and glial cells in brains of patients with Pick's disease, corticobasal degeneration and progressive supranuclear palsy. *Acta Neuropathol* 2001; 101: 167–73.
- Baker M, Litvan I, Houlden H, Adamson J, Dickson D, Perez-Tur J, et al. Association of an extended haplotype in the tau gene with progressive supranuclear palsy. *Hum Mol Genet* 1999; 8: 711–5.
- Ball MJ, Murdoch GH. Neuropathological criteria for the diagnosis of Alzheimer's disease: are we really ready yet? *Neurobiol Aging* 1997; 18: S3–12.
- Ballan G, Tison F. A historical case of probable corticobasal degeneration? *Mov Disord* 1997; 12: 1073–4.
- Boeve BF. Corticobasal degeneration: the syndrome and the disease. In: Litvan I, editor. *Atypical parkinsonian disorders: clinical and research aspects*. New Jersey: Humana Press; 2005.
- Boeve BF, Maraganore DM, Parisi JE, Ahlskog JE, Graff-Radford N, Caselli RJ, et al. Pathologic heterogeneity in clinically diagnosed corticobasal degeneration. *Neurology* 1999; 53: 795–800.
- Cairns NJ, Bigio EH, Mackenzie IR, Neumann M, Lee VM, Hatanpaa KJ, et al. Neuropathologic diagnostic and nosologic criteria for frontotemporal lobar degeneration: consensus of the Consortium for Frontotemporal Lobar Degeneration. *Acta Neuropathol* 2007; 114: 5–22.
- Casseron W, Azulay JP, Guedj E, Gastaut JL, Pouget J. Familial autosomal dominant cortico-basal degeneration with the P301S mutation in the tau gene: an example of phenotype variability. *J Neurol* 2005; 252: 1546–8.
- Dickson DW. Neuropathologic differentiation of progressive supranuclear palsy and corticobasal degeneration. *J Neurol* 1999; 246 (Suppl. 2): I16–15.
- Dickson DW, Bergeron C, Chin SS, Duyckaerts C, Horoupian D, Ikeda K, et al. Office of Rare Diseases neuropathologic criteria for corticobasal degeneration. *J Neuropathol Exp Neurol* 2002; 61: 935–46.
- Geda YE, Boeve BF, Negash S, Graff-Radford NR, Knopman DS, Parisi JE, et al. Neuropsychiatric features in 36 pathologically confirmed cases of

- corticobasal degeneration. *J Neuropsychiatry Clin Neurosci* 2007; 19: 77–80.
- Gibb WR, Luthert PJ, Marsden CD. Corticobasal degeneration. *Brain* 1989; 112 (Pt 5): 1171–92.
- Grimes DA, Lang AE, Bergeron CB. Dementia as the most common presentation of cortical-basal ganglionic degeneration. *Neurology* 1999; 53: 1969–74.
- Hodges JR, Davies RR, Xuereb JH, Casey B, Broe M, Bak TH, *et al.* Clinicopathological correlates in frontotemporal dementia. *Ann Neurol* 2004; 56: 399–406.
- Horoupian DS, Wasserstein PH. Alzheimer's disease pathology in motor cortex in dementia with Lewy bodies clinically mimicking corticobasal degeneration. *Acta Neuropathol* 1999; 98: 317–22.
- Houlden H, Baker M, Morris HR, MacDonald N, Pickering-Brown S, Adamson J, *et al.* Corticobasal degeneration and progressive supranuclear palsy share a common tau haplotype. *Neurology* 2001; 56: 1702–6.
- Hughes AJ, Daniel SE, Ben-Shlomo Y, Lees AJ. The accuracy of diagnosis of parkinsonian syndromes in a specialist movement disorder service. *Brain* 2002; 125: 861–70.
- Imamura A, Wszolek ZK, Lucas JA, Dickson DW. Corticobasal syndrome with Alzheimer's disease pathology. *Mov Disord* 2009; 24: 152–3; author reply 3.
- Ince PG, Clark B, Holton JL, Revesz T, Wharton S. Disorders of movement and system degenerations. In: Love S, Louis DN, Ellison DW, editors. *Greenfield's neuropathology*. 8th edn, London: Arnold; 2008. p. 889–1030.
- Ishizawa K, Dickson DW. Microglial activation parallels system degeneration in progressive supranuclear palsy and corticobasal degeneration. *J Neuropathol Exp Neurol* 2001; 60: 647–57.
- Jendroska K, Rossor MN, Mathias CJ, Daniel SE. Morphological overlap between corticobasal degeneration and Pick's disease: a clinicopathological report. *Mov Disord* 1995; 10: 111–4.
- Josephs KA, Duffy JR. Apraxia of speech and nonfluent aphasia: a new clinical marker for corticobasal degeneration and progressive supranuclear palsy. *Curr Opin Neurol* 2008; 21: 688–92.
- Joseph KA, Rossor MN. The alien limb. *Practical Neurology* 2004; 4: 44–5.
- Josephs KA, Duffy JR, Strand EA, Whitwell JL, Layton KF, Parisi JE, *et al.* Clinicopathological and imaging correlates of progressive aphasia and apraxia of speech. *Brain* 2006; 129: 1385–98.
- Josephs KA, Holton JL, Rossor MN, Braendgaard H, Ozawa T, Fox NC, *et al.* Neurofilament inclusion body disease: a new proteinopathy? *Brain* 2003; 126: 2291–303.
- Josephs KA, Holton JL, Rossor MN, Godbolt AK, Ozawa T, Strand K, *et al.* Frontotemporal lobar degeneration and ubiquitin immunohistochemistry. *Neuropathol Appl Neurobiol* 2004; 30: 369–73.
- Josephs KA, Petersen RC, Knopman DS, Boeve BF, Whitwell JL, Duffy JR, *et al.* Clinicopathologic analysis of frontotemporal and corticobasal degenerations and PSP. *Neurology* 2006; 66: 41–8.
- Kertesz A, McMonagle P, Blair M, Davidson W, Munoz DG. The evolution and pathology of frontotemporal dementia. *Brain* 2005; 128: 1996–2005.
- Kreisler A, Mastain B, Tison F, Fenelon G, Destee A. Multi-infarct disorder presenting as corticobasal degeneration (DCB): vascular pseudo-corticobasal degeneration? *Rev Neurol* 2007; 163: 1191–9.
- Le Ber I, Camuzat A, Hannequin D, Pasquier F, Guedj E, Rovelet-Lecrux A, *et al.* Phenotype variability in progranulin mutation carriers: a clinical, neuropsychological, imaging and genetic study. *Brain* 2008; 131: 732–46.
- Lees AJ. The Steele-Richardson-Olszewski syndrome (progressive supranuclear palsy). In: Marsden CD, Fahn S, editors. *Movement disorders 2*. London: Butterworth-Heinemann; 1987. p. 272–87.
- Lhermitte J, Levy G, Kyriaco N. Les perturbations de la représentation spatiale chez les apraxiques. *Rev Neurol (Paris)* 1925; 2: 586–600.
- Litvan I, Agid Y, Calne D, Campbell G, Dubois B, Duvoisin RC, *et al.* Clinical research criteria for the diagnosis of progressive supranuclear palsy (Steele-Richardson-Olszewski syndrome): report of the NINDS-SPSP international workshop. *Neurology* 1996; 47: 1–9.
- Litvan I, Agid Y, Goetz C, Jankovic J, Wenning GK, Brandel JP, *et al.* Accuracy of the clinical diagnosis of corticobasal degeneration: a clinicopathologic study. *Neurology* 1997; 48: 119–25.
- Litvan I, Hauw JJ, Bartko JJ, Lantos PL, Daniel SE, Horoupian DS, *et al.* Validity and reliability of the preliminary NINDS neuropathologic criteria for progressive supranuclear palsy and related disorders. *J Neuropathol Exp Neurol* 1996; 55: 97–105.
- Litvan I, MacIntyre A, Goetz CG, Wenning GK, Jellinger K, Verny M, *et al.* Accuracy of the clinical diagnoses of Lewy body disease, Parkinson disease, and dementia with Lewy bodies: a clinicopathologic study. *Arch Neurol* 1998; 55: 969–78.
- Masellis M, Momeni P, Meschino W, Heffner R Jr, Elder J, Sato C, *et al.* Novel splicing mutation in the progranulin gene causing familial corticobasal syndrome. *Brain* 2006; 129: 3115–23.
- Masliah E, Hansen LA, Quijada S, DeTeresa R, Alford M, Kauss J, *et al.* Late onset dementia with argyrophilic grains and subcortical tangles or atypical progressive supranuclear palsy? *Ann Neurol* 1991; 29: 389–96.
- McMonagle P, Blair M, Kertesz A. Corticobasal degeneration and progressive aphasia. *Neurology* 2006; 67: 1444–51.
- Murray R, Neumann M, Forman MS, Farmer J, Massimo L, Rice A, *et al.* Cognitive and motor assessment in autopsy-proven corticobasal degeneration. *Neurology* 2007; 68: 1274–83.
- O'Sullivan SS, Burn DJ, Holton JL, Lees AJ. Normal dopamine transporter single photon-emission CT scan in corticobasal degeneration. *Mov Disord* 2008; 23: 2424–6.
- Oppenheimer. Diseases of the basal ganglia, cerebellum and motor neurons. In: Adams JH, Corsellis JA, Duchon LW, editors. *Greenfield's neuropathology*. 4th edn, New York: Wiley; 1984. p. 699–747.
- Pittman AM, Myers AJ, Abou-Sleiman P, Fung HC, Kaleem M, Marlowe L, *et al.* Linkage disequilibrium fine mapping and haplotype association analysis of the tau gene in progressive supranuclear palsy and corticobasal degeneration. *J Med Genet* 2005; 42: 837–46.
- Rebeiz JJ, Kolodny EH, Richardson EP Jr. Corticodentatonigral degeneration with neuronal achromasia: a progressive disorder of late adult life. *Trans Am Neurol Assoc* 1967; 92: 23–6.
- Rebeiz JJ, Kolodny EH, Richardson EP Jr. Corticodentatonigral degeneration with neuronal achromasia. *Arch Neurol* 1968; 18: 20–33.
- Renner JA, Burns JM, Hou CE, McKeel DW Jr, Storandt M, Morris JC. Progressive posterior cortical dysfunction: a clinicopathologic series. *Neurology* 2004; 63: 1175–80.
- Rippon GA, Staugaitis SM, Chin SS, Goldman JE, Marder K. Corticobasal syndrome with novel argyrophilic glial inclusions. *Mov Disord* 2005; 20: 598–602.
- Scaravilli T, Tolosa E, Ferrer I. Progressive supranuclear palsy and corticobasal degeneration: lumping versus splitting. *Mov Disord* 2005; 20 (Suppl. 12): S21–8.
- Shelley BP, Hodges JR, Kipps CM, Xuereb JH, Bak TH. Is the pathology of corticobasal syndrome predictable in life? *Mov Disord* 2009; 24: 1593–9.
- Tang-Wai DF, Graff-Radford NR, Boeve BF, Dickson DW, Parisi JE, Crook R, *et al.* Clinical, genetic, and neuropathologic characteristics of posterior cortical atrophy. *Neurology* 2004; 63: 1168–74.
- Tartaglia MC, Sidhu M, Laluz V, Racine C, Rabinovici GD, Creighton K, *et al.* Sporadic corticobasal syndrome due to FTLTDP. *Acta Neuropathol* 2010; 119: 365–74.
- Tartaglia MC, Sidhu M, Laluz V, Racine C, Rabinovici GD, Creighton K, *et al.* Sporadic corticobasal syndrome due to FTLTDP. *Acta Neuropathol* 2010; 119: 365–74.
- Tsuboi Y, Josephs KA, Boeve BF, Litvan I, Caselli RJ, Caviness JN, *et al.* Increased tau burden in the cortices of progressive supranuclear palsy presenting with corticobasal syndrome. *Mov Disord* 2005; 20: 982–8.

- Vandenberghe W, Sciot R, Demaerel P, Van Laere K. Sparing of the substantia nigra in sporadic Creutzfeldt-Jakob disease presenting as an acute corticobasal syndrome. *Mov Disord* 2007; 22: 1668–9.
- Vidailhet M, Rivaud-Pechoux S, Rivaud S, Gouider-Khouja N, Pillon B, Bonnet AM, et al. Eye movement disorders in corticobasal degeneration. Eye movements in parkinsonian syndromes. *Adv Neurol* 2000; 82: 161–7.
- Vidailhet M, Rivaud S, Gouider-Khouja N, Pillon B, Bonnet AM, Gaymard B, et al. Eye movements in parkinsonian syndromes. *Ann Neurol* 1994; 35: 420–6.
- Wadia PM, Lang AE. The many faces of corticobasal degeneration. *Parkinsonism Relat Disord* 2007; 13 (Suppl. 3): S336–40.
- Watts RL, Williams RS, Growden JD. Corticobasal ganglionic degeneration. *Neurology* 1985; 35 (Suppl. 1): 178.
- Williams DR, de Silva R, Paviour DC, Pittman A, Watt HC, Kilford L, et al. Characteristics of two distinct clinical phenotypes in pathologically proven progressive supranuclear palsy: Richardson's syndrome and PSP-Parkinsonism. *Brain* 2005; 128: 1247–58.