

# Hippocampal vascular reserve associated with cognitive performance and hippocampal volume

Valentina Perosa,<sup>1,2,3</sup> Anastasia Priester,<sup>1</sup> Gabriel Ziegler,<sup>2,3</sup> Arturo Cardenas-Blanco,<sup>2,3</sup> Laura Dobisch,<sup>2,3</sup> Marco Spallazzi,<sup>4</sup> Anne Assmann,<sup>1</sup>  Anne Maass,<sup>3</sup> Oliver Speck,<sup>3,5,6,7</sup> Jan Oltmer,<sup>3</sup> Hans-Jochen Heinze,<sup>1,3,5,6</sup>  Stefanie Schreiber<sup>1,3,5,\*</sup> and Emrah Düzel<sup>2,3,5,8,\*</sup>

\*These authors contributed equally to this work.

See Wiesmann and de Leeuw (doi:10.1093/brain/awz408) for a scientific commentary on this article.

Medial temporal lobe dependent cognitive functions are highly vulnerable to hypoxia in the hippocampal region, yet little is known about the relationship between the richness of hippocampal vascular supply and cognition. Hippocampal vascularization patterns have been categorized into a mixed supply from both the posterior cerebral artery and the anterior choroidal artery or a single supply by the posterior cerebral artery only. Hippocampal arteries are small and affected by pathological changes when cerebral small vessel disease is present. We hypothesized, that hippocampal vascularization patterns may be important trait markers for vascular reserve and modulate (i) cognitive performance; (ii) structural hippocampal integrity; and (iii) the effect of cerebral small vessel disease on cognition. Using high-resolution 7 T time-of-flight angiography we manually classified hippocampal vascularization patterns in older adults with and without cerebral small vessel disease *in vivo*. The presence of a mixed supplied hippocampus was an advantage in several cognitive domains, including verbal list learning and global cognition. A mixed supplied hippocampus also was an advantage for verbal memory performance in cerebral small vessel disease. Voxel-based morphometry showed higher anterior hippocampal grey matter volume in mixed, compared to single supply. We discuss that a mixed hippocampal supply, as opposed to a single one, may increase the reliability of hippocampal blood supply and thereby provide a hippocampal vascular reserve that protects against cognitive impairment.

- 1 Department of Neurology, Otto-von-Guericke University, Magdeburg, Germany
- 2 Institute of Cognitive Neurology and Dementia Research, Otto-von-Guericke-University, Magdeburg, Germany
- 3 German Center for Neurodegenerative Diseases (DZNE), Magdeburg, Germany
- 4 Department of Neurology, Azienda Ospedaliero-Universitaria, Parma, Italy
- 5 Center for Behavioral Brain Sciences (CBBS), Magdeburg, Germany
- 6 Leibniz-Institute for Neurobiology (LIN), Magdeburg, Germany
- 7 Institute of Physics, Otto-von-Guericke University, Magdeburg, Germany
- 8 Institute of Cognitive Neuroscience, University College London, London, UK

Correspondence to: Valentina Perosa  
Clinic for Neurology, c/o Universitätsklinikum Magdeburg, Leipziger Strasse 44, Haus 64,  
39120 Magdeburg, Germany  
E-mail: valentina.perosa@med.ovgu.de

Received June 17, 2019. Revised September 12, 2019. Accepted October 7, 2019. Advance Access publication January 29, 2020

© The Author(s) (2020). Published by Oxford University Press on behalf of the Guarantors of Brain.

This is an Open Access article distributed under the terms of the Creative Commons Attribution Non-Commercial License (<http://creativecommons.org/licenses/by-nc/4.0/>), which permits non-commercial re-use, distribution, and reproduction in any medium, provided the original work is properly cited. For commercial re-use, please contact [journals.permissions@oup.com](mailto:journals.permissions@oup.com)

**Keywords:** 7 tesla MRI; anterior choroidal artery; cerebral small vessel disease (CSVD); hippocampus; vascular patterns

**Abbreviations:** AchA = anterior choroidal artery; ADAScog = Alzheimer's Disease Assessment Scale-Cognitive Subscale; CDR = Clinical Dementia Rating; CSVD = cerebral small vessel disease; CVLT-II = California Verbal Memory Test – II; MMSE = Mini Mental State Examination; MoCA = Montreal cognitive Assessment; MTL = medial temporal lobe; PCA = posterior cerebral artery; ToF = time-of-flight; VBM = voxel-based morphometry

## Introduction

The hippocampus is critical for episodic memory (Zola-Morgan, 1986; Düzel *et al.*, 2001), spatial navigation (O'Keefe and Nadel, 1979; Suthana *et al.*, 2009), consolidation of long-term memory (Frey and Frey, 2008; Düzel *et al.*, 2010) and contributes to many other cognitive faculties. Moreover, a wide range of diseases is related to hippocampal dysfunction (for a review see Small *et al.*, 2012).

A sufficient blood supply is a decisive factor to preserve function of any brain region. In fact, a positive relation between resting cerebral blood flow and cognition has recently been observed in older adults for global (Rabbitt *et al.*, 2006; Ogoh, 2017) and hippocampal cerebral blood flow (Heo *et al.*, 2010). Differences in perfusion might also lead to differences in structural integrity (Maass *et al.*, 2015; Boraxbekk *et al.*, 2016). This aspect is especially relevant for the hippocampus, which is particularly sensitive to hypoxia (Duvernoy, 2013). The latter probably relates to both the conformation of the intrahippocampal vessels (Duvernoy, 2013) and the relative lack of capillary anastomoses between them (Klosovskii, 1963).

Hippocampal vessels are small (average diameter 0.5 mm), restricting their visualization and examination so far to post-mortem studies. Autopsy studies (Marinković *et al.*, 1992; Erdem *et al.*, 1993) have highlighted that the hippocampus is vascularized by the posterior cerebral artery (PCA) and the anterior choroidal artery (AchA), from which the hippocampal arteries, directly or indirectly, arise. The exact origin of the hippocampal arteries anatomically varies across individuals and includes PCA branches, such as the inferior temporal arteries, the posterolateral choroideal artery and the splenial artery (Lang, 1981; Marinković *et al.*, 1992). Most importantly, the contribution of the AchA to hippocampal vascularization is variable, and when existent, pertains to the hippocampal head, which is in these cases partially vascularized by the uncus branch of the AchA (Gastaut and Lammers, 1961; Erdem *et al.*, 1993). A dedicated post-mortem study (Erdem *et al.*, 1993) classified five different hippocampal vascularization patterns (A–E) according to the origin of the hippocampal arteries. In two of them (A and E) the AchA contributes to the hippocampal supply (mixed supply), while in the remaining three (B–D), it does not (single supply). Recently, the same classification was demonstrated *in vivo* adopting high-resolution time-of-flight (ToF) angiography at 7 T MRI and showing a comparable frequency of the hippocampal patterns to post-mortem studies (Spallazzi *et al.*, 2018).

Sporadic cerebral small vessel disease (CSVD) denotes the pathological alteration of the cerebral small vessels (<1 mm in diameter), such as arterioles, venules and capillaries. It mainly relates to age and vascular risk factors, and comprises hypertensive arteriopathy and cerebral amyloid angiopathy (CAA), which occur independently or together in the ageing brain (Pantoni, 2010; Charidimou *et al.*, 2016, 2017). Hippocampal vessels, which present an average diameter of 0.5 mm, are also affected (Hecht *et al.*, 2018). In fact, hippocampal atrophy and neuronal loss (Krill *et al.*, 2002; Small *et al.*, 2012), hippocampal microinfarcts (Hecht *et al.*, 2018), as well as decreased regional cerebral blood volume (Wu *et al.*, 2008) have been observed in patients with CSVD. Nonetheless, the extent of the structural harm in the medial temporal lobe (MTL) in CSVD patients is still a matter of debate and some studies report a sparing of this brain region (Lambert *et al.*, 2015, 2016). The cognitive profile of the CSVD cohort is, however, consistent with a concomitant deleterious effect on the MTL and also includes deficits in episodic memory (Xiong *et al.*, 2016; van Leijsen *et al.*, 2019), a cognitive domain strongly related to hippocampal function. Recently, stronger focus has been directed towards the interplay between CSVD, MTL degeneration and cognitive decline (O'Sullivan *et al.*, 2009; Jokinen *et al.*, 2016; van Leijsen *et al.*, 2019), as well as on the mediating role of CSVD on the cognitive trajectories in Alzheimer's disease (Krill *et al.*, 2002; Boyle *et al.*, 2018). Converging evidence indicates that microvascular pathology independently contributes to both structural degeneration of the MTL, and MTL-related cognitive decline (Zhang *et al.*, 2013; Iturria-Medina *et al.*, 2016; Boyle *et al.*, 2018).

In light of this evidence, we aimed to investigate *in vivo* the link between hippocampal vascularization and cognition, in a cohort that included older adults with and without CSVD.

So far, it remains unexplored whether differences in the hippocampal vascularization influence: (i) MTL-related and global cognition; (ii) hippocampal structure; and (iii) MTL-related and global cognition, as well as hippocampal structure in face of CSVD. Hippocampal vascularization patterns were characterized using 7 T ToF-angiography, while cognition was evaluated adopting neuropsychological tests that assess cognitive domains related to the hippocampal function [such as memory and learning in the California Verbal Memory Test – II (CVLT-II) (Delis *et al.*, 2000)], and more comprehensive cognitive measures assessing global cognition [such as Mini Mental State Examination (MMSE), and Montreal cognitive Assessment (MoCA)].

Furthermore, we used high-resolution voxel-based morphometry (VBM) at 7 T structural MRI to investigate whether hippocampal vascularization patterns are accompanied by variations in hippocampal volume. We hypothesized that the presence of a mixed hippocampal supply through both the PCA and AchA, may increase the reliability of blood supply to the hippocampus. This increased vascular reserve may be a protective factor for hippocampal structural integrity and cognitive function in normal ageing but particularly in older adults with small vessel disease.

## Materials and methods

### Participants

A total of 47 older adults [mean (standard deviation, SD) age 71 (8.2); 44% females] were included in this study, between June 2017 and June 2018. For all participants, depression was an exclusion criterion and was assessed using the Geriatric Depression Scale (GDS) (Brink *et al.*, 1982). No participant achieved the cut-off score of 10, indicating mild depression. Moreover, contraindications for scanning at 7 T, according to the recommendations of the German Ultrahigh Field Imaging (GUFi) network, were another exclusion criterion from our study. All participants underwent a neurological examination to exclude undiagnosed conditions as well as an extensive neuropsychological test battery, which is described below. All participants provided written informed consent according to the Declaration of Helsinki and were compensated for travel costs. The study was approved by the local Ethics Committee (93/17; 28/16).

Twenty of the participants [mean age (SD) 71 (8.5); 35% females] showed neuroimaging markers of CSVD. Eight of them (40%) fulfilled the modified Boston criteria of a possible (1/20) or probable (7/20) CAA (Linn *et al.*, 2010). The remaining 12 CSVD participants did not fulfil the modified Boston criteria for the existence of CAA (Supplementary Table 1). The majority of the CAA participants had CSF measures of amyloid- $\beta_{1-42}$ , phosphorylated tau (p-tau) and total tau (t-tau) available (see Supplementary material for methodological details). This allowed us to apply the biomarker-based ‘ATN’ (amyloid- $\beta$ , tau, neurodegeneration) classification suggested by the National Institute on Aging – Alzheimer’s Association (NIA-AA) to depict a profile of concurrent Alzheimer’s disease pathology (Jack *et al.*, 2018): ‘A’ was assessed using CSF amyloid- $\beta_{1-42}$ , ‘T’ was assessed adopting CSF p-tau and ‘N’ was assessed using CSF t-tau. According to our locally established thresholds, only one of the CAA participants fulfilled the criteria for CSF amyloid- $\beta_{1-42}$  positivity associated with amyloid plaque formation, but did not fulfil the criteria for CSF p-tau or t-tau positivity (Jack *et al.*, 2018). The same combination was also found in one non-CAA CSVD participant. Thus, both participants present Alzheimer’s pathological change as part of the Alzheimer’s continuum (Jack *et al.* 2018) (Supplementary Table 1).

Participants with CSVD were recruited from a dedicated prospective longitudinal 3 T MRI study conceived to investigate disease pathophysiology in CSVD and its relationship to cognitive performance. The study was set up in 2016 and is

led by the Department of Neurology and the German Center for Neurodegenerative Diseases (DZNE) in Magdeburg (ethical approval no 28/16). Currently the cohort comprises ~100 participants with CSVD. Inclusion criteria are the existence of MRI iron-sensitive sequences [gradient recalled echo (GRE)  $T_2^*$ -weighted or susceptibility-weighted (SWI) imaging], which need to show haemorrhagic CSVD markers, i.e. at least one cerebral microbleed in deep (basal ganglia, thalamus, brainstem) or lobar locations and/or cortical superficial siderosis. MRI prior inclusion is conducted for diagnostic purposes. The initial reasons to perform a diagnostic MRI are manifold and comprise e.g. headache, epileptic seizures, gait disturbances, cognitive impairment and transient ischaemic attack. Participants have to be between 60 and 90 years old and need to be able to provide written informed consent. Exclusion criteria are genetic neurological disease, history of psychiatric disease, alcohol or drug abuse, as well as cerebrovascular malformations. Participants undergo 3 T MRI, a neuropsychological test battery and upon agreement lumbar puncture with CSF examination.

Healthy controls were recruited from an existing pool of ~100 cognitively normal community-dwelled elderly from the DZNE with an available 3 T MRI with iron-sensitive sequences. We screened the MRI scans of all subjects and selected those that were free of cerebral microbleeds and/or cortical superficial siderosis. They were allowed to show caps or pencil-thin lining periventricular white matter hyperintensities (WMH) and/or punctate foci of deep WMH, both scored as grade 1 (mild) on the WMH Fazekas visual rating scale, which represent a common finding in ageing (Fazekas *et al.*, 1987). Twenty-seven controls agreed to take part in the 7 T study.

According to the MMSE and Clinical Dementia Rating (CDR), the CSVD cohort included 10 cognitively normal subjects (MMSE > 26, CDR = 0), nine cases that fulfilled the criteria for mild cognitive impairment (22 < MMSE ≤ 26, 0 < CDR ≤ 1), one case of mild dementia (MMSE = 18; CDR = 0.5) and no participants with severe dementia (MMSE ≤ 18 points; CDR > 1.0). All control subjects were cognitively normal.

Presence of CSVD was assessed on a 3 T MRI according to the standards for reporting vascular changes on neuroimaging (STRIVE) criteria (Wardlaw *et al.*, 2013), by a specialized neurologist (S.S., 10 years’ experience). CSVD neuroimaging markers comprised haemorrhagic (cerebral microbleed, cortical superficial siderosis) and non-haemorrhagic markers (WMH, lacunes, perivascular spaces) (Supplementary Table 2).

### 7 T MRI

All participants underwent a 7 T ultrahigh-field MRI scan using a Siemens MAGNETOM 7 T scanner equipped with a Nova Medical 32-channel head-coil. The protocol included a  $T_1$ -weighted sequence with 3D magnetization-prepared rapid gradient echo (3D-MPRAGE; voxel size  $1 \times 1 \times 1 \text{ mm}^3$  isotropic). The acquisition parameters were as follows: echo time 2.89 ms, repetition time 2250 ms, flip angle  $5^\circ$ , inversion time 1050 ms, receiver bandwidth (RBW) 130 Hz/pixel, echo spacing 8.3 ms, 3D matrix dimensions  $256 \times 256 \times 176$ . GRAPPA (generalized autocalibrating partial parallel acquisition) was enabled with an acceleration factor of 2 and 32 reference lines. The ToF-angiography provides contrast of

flowing blood, thus allowing the visualization of cerebral arteries. ToF was acquired with a voxel size of  $0.28 \times 0.28 \times 0.28 \text{ mm}^3$  isotropic and the following parameters: echo time 4.59 ms, repetition time 22 ms, flip angle  $23^\circ$ , RBW 130 Hz/pixel; GRAPPA factor 3, 32 reference lines. To limit the acquisition time, the ToF covered a certain part of the brain only: the origin of the slab was set at the bottom of the hippocampus and extended 5 cm in the dorsal direction, allowing depiction of the circulus Willisii and the hippocampal arteries. More sequences were included in the protocol but did not play a role in this study. Scanning time summed up to 50 min. Thin pillows were placed at the sides of the participant's head to minimize head motion.

### 3 T MRI

To diagnose or exclude CSVD, all participants underwent a 3 T scan prior to 7 T MRI [mean interval (SD) in days, 62 (23)]. Measurements were performed in a Siemens Verio scanner with a Siemens 32-channel array coil. The protocol included a  $T_2$ -weighted fluid-attenuated inversion recovery (FLAIR) sequence (voxel size  $1 \times 1 \times 1 \text{ mm}^3$  isotropic, echo time 395 ms, repetition time 5000 ms, flip angle  $120^\circ$ , RBW 781 Hz/px; GRAPPA factor 2, 24 reference lines), to localize lacunes and evaluate WMH (Fazekas *et al.*, 1987). A  $T_2$ -weighted sequence permitted us to individuate perivascular spaces (Potter *et al.*, 2015) (voxel size  $0.5 \times 0.5 \times 2 \text{ mm}^3$  isotropic, echo time 63 ms, repetition time 6500 ms, flip angle  $120^\circ$ , RBW 222 Hz/px; GRAPPA with factor 2, 24 reference lines was enabled). Cerebral microbleed and cortical superficial siderosis were rated using a susceptibility-weighted 3D gradient-echo pulse sequence (voxel size  $1 \times 1 \times 2 \text{ mm}^3$  isotropic, echo time 28 ms, repetition time 20 ms, flip angle  $17^\circ$ , RBW 100 Hz/px; GRAPPA with factor 2, 24 reference lines were enabled). An MPRAGE sequence was also included in the protocol, as an anatomical reference (voxel size  $1 \times 1 \times 1 \text{ mm}^3$  isotropic, echo time 4.37 ms, repetition time 2500 ms, flip angle  $7^\circ$ , GRAPPA with factor 2, 24 reference lines were enabled). Furthermore, a diffusion-weighted imaging sequence permitted the exclusion of recent small subcortical infarcts in all participants at the time of the 3 T MRI (voxel size  $1.8 \times 1.8 \times 5.0 \text{ mm}^3$ , echo time 72 ms, repetition time 8800 ms, flip angle  $120^\circ$ , GRAPPA with factor 2, 38 reference lines were enabled). Scanning time totalled  $\sim 45$  min.

### Image processing and analysis

7 T  $T_1$ -weighted and ToF images were first converted from DICOM to NIFTI format using the dcm2nii routine of the MRICron software package (<https://www.nitrc.org/projects/mricron>).  $T_1$  images were then bias corrected using SPM12 (Statistical Parametric Mapping software; Wellcome Trust Centre for Neuroimaging, London, UK) supported by MATLAB R2014b (Mathworks, Sherborn, MA, USA).

To determine the hippocampal patterns, we adopted the same method described by Spallazzi *et al.* (2018). An anatomical reference was needed to set the vessels in relation to the hippocampus. To this end, a hippocampal mask was created for each subject: structural images were first automatically segmented using the subcortical segmentation pipeline (Fischl *et al.*, 2004) of Free Surfer 6.0 (<https://surfer.nmr.mgh.harvard.edu>). Results were then visually inspected to ensure

correct segmentation of the region of interest, i.e. the hippocampus. We extracted the hippocampal region (left and right) and obtained hippocampal volumes (left, right and sum of both sides). Total intracranial volume was also extracted. Subsequently, hippocampal masks were co-registered to the corresponding ToF, using Advanced Normalization Tools (ANTs, <http://stnva.github.io/ANTs/>). Registration of the  $T_1$  image to ToF was performed using the same software.

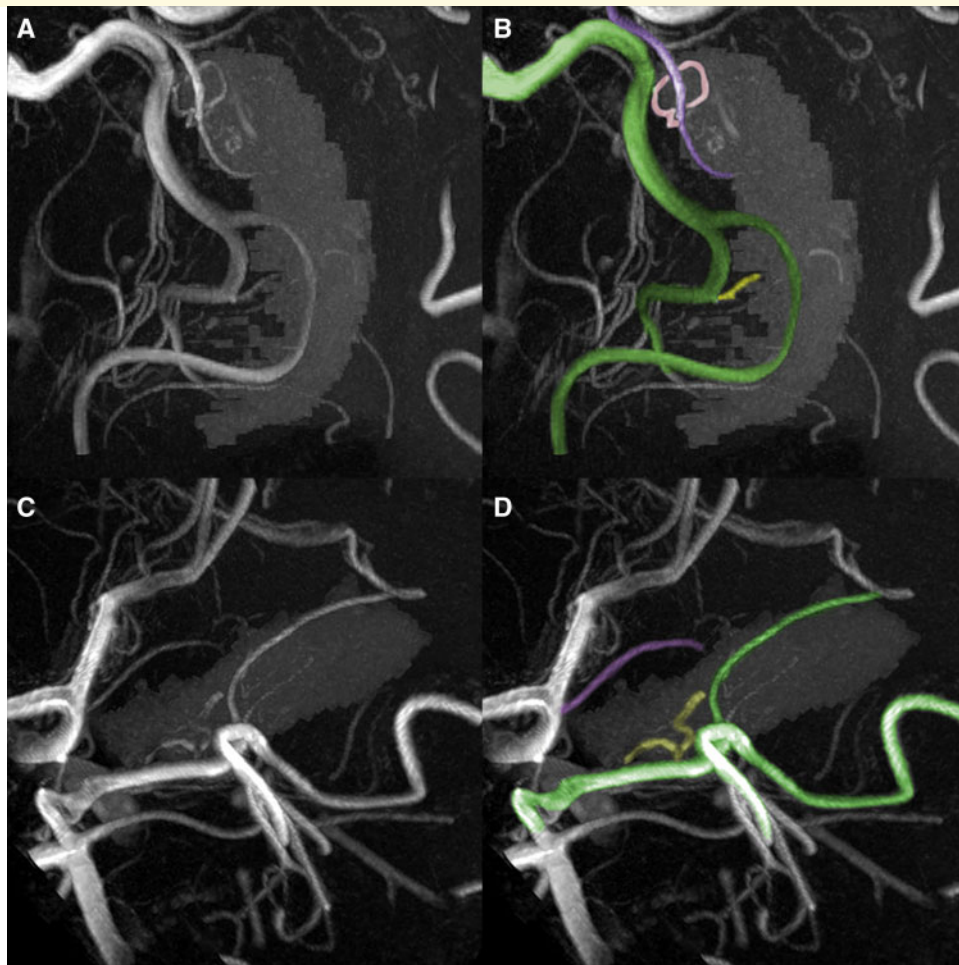
Afterwards we inspected the vessels supplying the hippocampus separately in each hemisphere and respectively assigned the hippocampal vascularization pattern. For this purpose, the ToF-angiography was processed as a maximum intensity projection in MeVisLab (MeVis, Bremen, Germany). The ToF was then visualized together with the hippocampal mask, which allowed a 3D representation of the vessels and the related hippocampal region (Supplementary Video 1). This approach, however, did not always allow the visualization of all arteries because of a loss of continuity in the maximum intensity projection. For this reason, we also inspected all hemispheres using MRICron, where the  $T_1$  hippocampal mask was overlaid to the MR-angiography. Images were inspected in sagittal, coronal and axial view (for more details see Spallazzi *et al.*, 2018).

Our main aim was to determine the contribution of the AchA to the hippocampal supply, which corresponds to pattern A and E according to Erdem *et al.* (1993). We therefore adopted a dichotomized approach, labelling each hippocampus as mixed supplied (by PCA and AchA) or single supplied (PCA only) (Fig. 1). Mixed supply applied when the uncus branch originating from the AchA was identified and seen penetrating the hippocampal region. As participation of the AchA also varied between hemispheres in the same subject, we assigned participants to two different groups, which we will also refer to as a 'score of hippocampal supply': Group 0 = absence of mixed supply in both hemispheres; and Group 1 = mixed supply in at least one hemisphere

We investigated 94 hemispheres of all 47 participants and were able to identify mixed or single supply in 85 (90%) of them. In the remaining cases, the presence of the uncus branch originating from the AchA, and thus its participation to the hippocampal vascular supply, was doubtful (e.g. due to movement artefacts or because the small vessels of the choroideal plexus and its anastomoses could not be differentiated from the AchA). The vascularization patterns were classified by a trained medical student (A.P., 2 years' experience), who repeated the classification several times using a random order. Furthermore, 21 randomly selected subjects (42 hemispheres) were rated again by a trained neurologist (V.P., 5 years' experience). Corresponding inter-rater reliability was good as indicated by an intraclass correlation coefficient (ICC) of 0.83. Furthermore, there was no relationship between the presence of a mixed supply across both hemispheres, demonstrated by an average measure ICC of 0.17.

### Neuropsychological test battery

All participants underwent a neuropsychological test battery comprising the MMSE (Folstein *et al.*, 1975), the CDR, the Alzheimer's Disease Assessment Scale-Cognitive Subscale (ADAScog), the MoCA and the CVLT-II. The MMSE (Strauss *et al.*, 1991) was adopted, together with the CDR (Morris, 1993) to detect cognitive impairment in the participants. The MMSE, the ADAScog (Rosen *et al.*, 1984) and the



**Figure 1 Visualization of hippocampal supply.** Representation of the hippocampal supply using a maximum intensity projection of the 7 T ToF-angiography in MeVisLab. The hippocampal mask obtained from the T<sub>1</sub>-weighted sequence was adopted as an anatomical reference. In case of mixed hippocampal supply (**A** and **B**) the anterior choroidal artery (AChA, in violet) participates to the vascularization with an uncus branch (highlighted in pink) together with the hippocampal arteries (in yellow) which arise from the posterior cerebral artery (PCA, in green) or its branches. In case of single hippocampal supply (**C** and **D**) no uncus branch can be detected.

MoCA (Nasreddine *et al.*, 2005) served as measures of global cognition. The factorial nature of the MMSE and MoCA, i.e. the tests' subscores, was exploited to assess specific cognitive domains (e.g. memory, language, attention and executive speed) as previously validated in large cohorts (Freitas *et al.*, 2012). The German version of the CVLT-II (Delis *et al.*, 2000) was adopted to measure verbal memory, as a MTL-specific domain. In the test, a 'shopping list' of 16 words (list A), clustered in four semantic categories (fruits, spices, clothing, tools), was presented to the participant during five consecutive learning trials (LT 1–5). An interference list (list B) with four items was then presented and recalled. Immediately thereafter, list A was recalled freely and with the suggestion of cues (short-delay free recall and short-delay cued recall). After 20 min free and cued recall were repeated (long-delay free recall and long delay cued recall).

## Statistics

The influence of CSVD and hippocampal supply, as well as the effect of the interaction between both factors on cognitive

performance, was calculated using a two-way ANOVA: the presence of CSVD (without CSVD, with CSVD) and the score of hippocampal supply (see above) were included as between-subjects factors, while the results of the cognitive tests (ADAScog, MMSE, MMSE subscores, MoCA, MoCA subscores, CVLT-II scores) were set respectively as dependent variables. Age and sex were always considered as covariates. Significance threshold was set at  $P < 0.05$  for all statistical analyses and adjusted for multiple comparisons using Bonferroni correction. Two-tailed independent and paired sample *t*-tests were used *post hoc* to compare differences between groups and performance between trials in the CVLT-II. All aforementioned statistical analyses were conducted using the Statistical Package for Social Science (IBM SPSS statistics), version 23.

To pinpoint the effects of the hippocampal supply on the CVLT-II performance, we first characterized the individual cognition by fitting a linear regression model to each participant's CVLT-II data using custom-made scripts (MATLAB, R2014b; Mathworks, Sherborn, MA, USA), for trials 1–5:

$$f(\text{trial}) = a + b \times (\text{trial} - 3) \quad (1)$$

In the linear function,  $a$  represents the offset (or overall performance) and  $b$  the rate of change of the individual learning curve. Both parameter values were also further analysed as dependent variables in the two-way ANOVA described above.

After confirming normal distribution of hippocampal volume ( $\text{mm}^3$ ) using Shapiro-Wilk test, we performed univariate ANOVAs on sum of both hippocampal volumes to assess differences between participants with CSVD and controls as well as between participants with CAA and non-CAA cases. Tests were adjusted for total intracranial volume as a covariate.

### Voxel-based morphometry

For VBM,  $T_1$ -weighted MPRAGE scans from 7 T imaging were initially bias corrected using ANTs (Advanced Normalisation Tools, <http://stnva.github.io/ANTs/>). VBM was performed using the CAT12 toolbox (r1355, Structural Brain Mapping group, Jena University Hospital, Jena, Germany, <http://www.neuro.uni-jena.de/cat/>) implemented in SPM12 (Statistical Parametric Mapping; Wellcome Trust Centre for Neuroimaging, London, UK), supported by MATLAB R2014b (Mathworks, Sherborn, MA, USA). To facilitate initial registration, each dataset was manually reoriented, setting the origin of the coordinate system at the anterior commissure.  $T_1$ -weighted scans were then segmented into grey and white matter. Each segmented image was visually inspected to exclude artefacts and underwent a sample homogeneity check to identify outliers. Grey and white matter images were warped to a common template using DARTEL (Diffeomorphic Anatomical Registration Through Exponentiated Lie Algebra) (Ashburner, 2007). Grey matter images were then smoothed using a Gaussian kernel at 6 mm full-width at half-maximum. As our hypothesis on vascular reserve is focused on the hippocampal region, we restricted our voxel-based grey matter analysis to this region using a mask. The region of interest consisted of the bilateral hippocampus, as provided by the neuromorphometrics atlas in CAT12, and was then co-registered to the template image available in CAT12. We performed VBM group analysis on the subjects with no mixed supplied hippocampus (11 subjects, five with and six without CSVD) and those with two mixed supplied hippocampi (12 subjects, five with and seven without CSVD). A general linear model (GLM) was specified in SPM12, comparing subjects with no mixed supplied hippocampus, with those, who presented two hippocampi with a mixed supply. We applied age, sex and total intracranial volume (calculated using CAT12) as nuisance variables. Differences between the two groups were assessed. All clusters with an uncorrected threshold of  $P < 0.001$  at peak value were considered, while a cluster threshold in voxel number was not applied.

### Data availability

De-identified data are available from the corresponding author upon reasonable request subject to a material transfer agreement.

## Results

### Sample

Participants with and without CSVD were matched for age, sex and education (Table 1). Prevalence of vascular risk factors, i.e. arterial hypertension, diabetes mellitus and hyperlipidaemia, was slightly higher in older adults with CSVD, as expected (Table 1).

We determined the participation of the AchA to the hippocampal vascularization in 47 participants (94 hemispheres). Supplementary Fig. 1 summarizes the main steps of that approach. Finally, 43 participants (84 hemispheres) remained for analysis. Of these, we individuated a mixed supply in a total of 32 subjects (12 with CSVD, 20 without CSVD) and a single supply in 11 participants (five participants with CSVD, six without CSVD) (Supplementary Fig. 1). Prevalence of mixed supplied hemispheres was comparable in both groups (50% in participants with CSVD versus 46% in participants without CSVD).

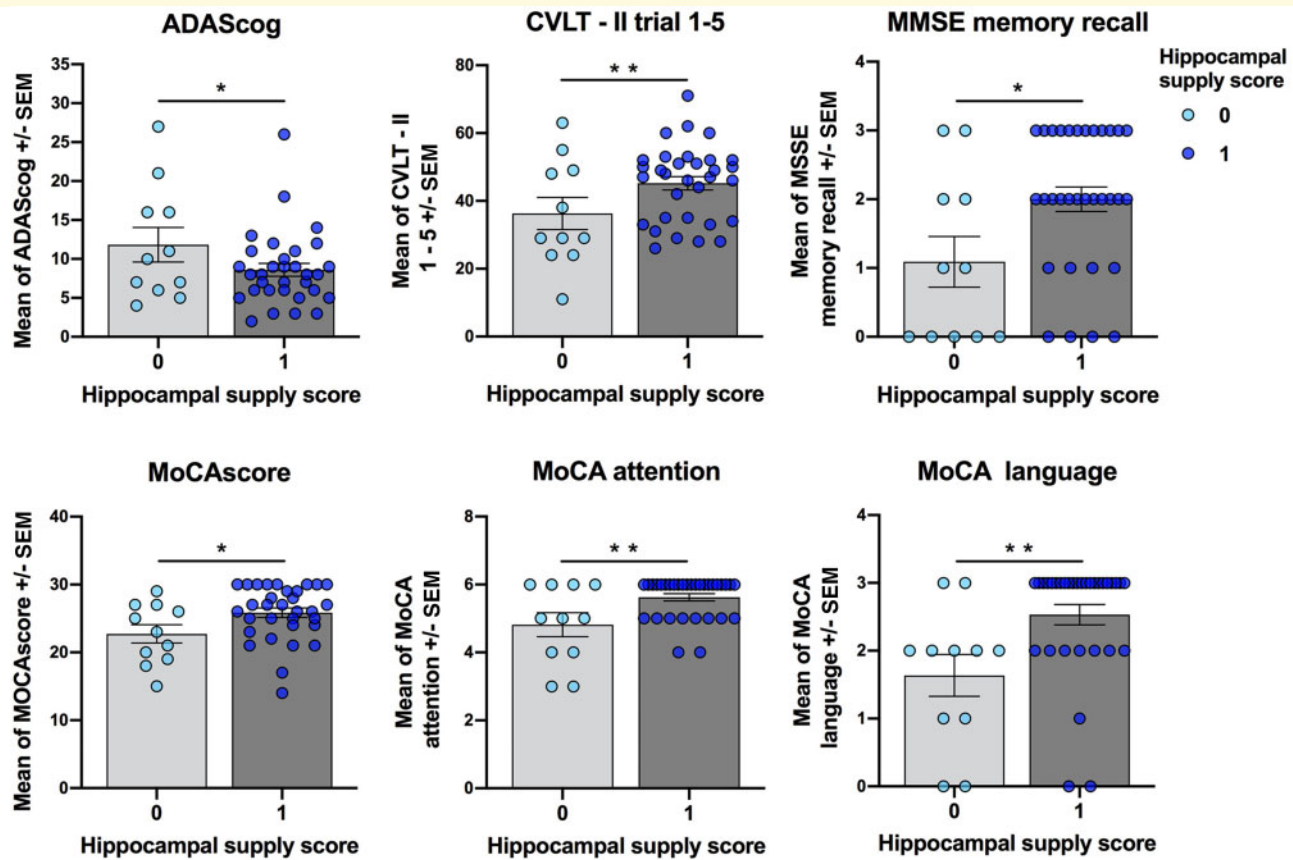
### Cognition

There was a significant main effect of group (CSVD versus no CSVD) on most of the cognitive tests, i.e. participants with CSVD performed worse (Supplementary Table 3). Moreover, the score of mixed supply had a significant main effect on a consistent part of the cognitive tests (Fig. 2 and Supplementary Table 3). Participants with at least one compared to participants with no mixed supplied hippocampus showed better global cognition [for ADAScog:  $F(1,40) = 4.34$ ,  $P = 0.045$ ; *post hoc* test not significant (ns); for MoCA:  $F(1,40) = 5.99$ ,  $P = 0.020$ ;  $t(41) = -2.17$ ,  $P = 0.036$ ]. Moreover, memory performance [MMSE memory recall:  $F(1,40) = 7.28$ ,  $P = 0.011$ ;  $t(41) = -2.27$ ,  $P = 0.029$ ] and verbal memory performance [CVLT-II LT1-5:  $F(1,40) = 7.67$ ,  $P = 0.009$ ;  $t(41) = -2.06$ ,  $P = 0.046$ ] were considerably better in the participants with at least one mixed supplied hippocampus. To investigate the effects of the hippocampal supply on the CVLT-II (verbal memory) we analysed the parameters reflecting the individual learning over five verbal memory

**Table 1 Demographics and vascular risk factors of the sample**

Variable	CSVD ( $n = 20$ )	Controls ( $n = 27$ )	P-value
Mean age, years [SD]	71 [8.5]	71 [8.2]	0.164
Female sex, $n$ (%)	7 (35)	14 (44)	0.256
Mean education, years [SD]	14.28 [3.84]	16.02 [2.54]	0.068
Arterial hypertension, $n$ (%)	18 (90)	14 (51)	0.082
Diabetes mellitus, $n$ (%)	5 (25)	3 (10)	0.015
Hyperlipidaemia, $n$ (%)	12 (60)	12 (44)	0.083

Independent samples  $t$ -test or  $\chi^2$ -test were conducted.  $P$ -values  $< 0.05$  were considered statistically significant.



**Figure 2** Effect of hippocampal vascular supply on cognitive domains. Bar graphs show differences in the results of the cognitive tests between groups with different scores of hippocampal supply (0 = absence of mixed supply in both hemispheres; 1 = mixed supply in at least one hemisphere). Values are given as mean  $\pm$  standard error of the mean (SEM). Independent samples t-tests were conducted for comparisons between conditions; \* $P < 0.05$ , \*\* $P < 0.01$  (Bonferroni-corrected).

trials, i.e. intercept and rate of change (see ‘Materials and methods’ section). Intercept (mean performance) [ $F(1,40) = 4.55$ ,  $P = 0.035$ ;  $t(41) = -2.07$ ,  $P = 0.045$ ] and rate of change [ $F(1,40) = 5.97$ ,  $P = 0.019$ ;  $t(41) = -2.35$ ,  $P = 0.026$ ] were found to be significantly higher in participants with at least one mixed supplied hippocampus, indicating both a higher average memory performance and a better learning rate during the task execution (Fig. 3). Interestingly, the MoCA subscores of attention [ $F(1,40) = 8.06$ ,  $P = 0.007$ ;  $t(41) = -2.37$ ,  $P = 0.036$ ] and language [ $F(1,40) = 1.26$ ,  $P = 0.009$ ;  $t(41) = -2.88$ ,  $P = 0.006$ ] were also higher in participants with mixed supply of at least one hippocampus compared to those with no mixed supply (Fig. 2).

Most interestingly, we further observed an interaction between the presence of CSVD and the score of mixed supply on verbal memory. This suggests that in the CSVD group participants with single supplied hippocampus (= 0) performed worse compared to the ones with at least one mixed supplied hippocampus (= 1) (Fig. 4 and Supplementary Table 3). Furthermore, a similar trend was observed in the ADAScog. On the other hand, no differences were observed within the participants without CSVD.

## Voxel-based morphometry

To investigate whether differences in hippocampal vascular supply might also be reflected in hippocampal volume, a voxel-based comparison of local grey matter volume was performed between subjects with a mixed and with a single supply in both hemispheres, respectively. Given our hypothesis about the vascular reserve, we focused the analysis on our region of interest, the hippocampus. We observed a significant difference in grey matter volume between these groups in terms of a bilateral hippocampal clusters (Table 2). The observed effects were localized in the anterior part of the hippocampus, which aligns with the hippocampal supply territory of the AchA. A *post hoc* t-test confirmed that a higher grey matter volume of the hippocampus was associated with a bilateral mixed supply, compared to single hippocampal supply (Table 2 and Fig. 5), while no effect was shown when considering the opposite as a working hypothesis (volume in group with bilateral single supply > mixed supply). The analysis was repeated in the CSVD and no CSVD group independently, finding no significant differences in our region of interest. Furthermore, to exclude a major influence of the presence

of CSVD in the VBM analysis, a comparison between participants with and without CSVD was performed and remained without any effect in the hippocampus (data not shown).

No significant difference in hippocampal volume between participants with CSVD and controls [ $F(1,46) = 0.01$ ,  $P = 0.920$ ;  $t(45) = -0.13$ ,  $P = 0.901$ ], as well as between participants with possible/probable CAA and non-CAA [ $F(1,19) = 0.01$ ,  $P = 0.937$ ;  $t(18) = 0.529$ ,  $P = 0.604$ ] was observed on Free Surfer based segmentation measures.

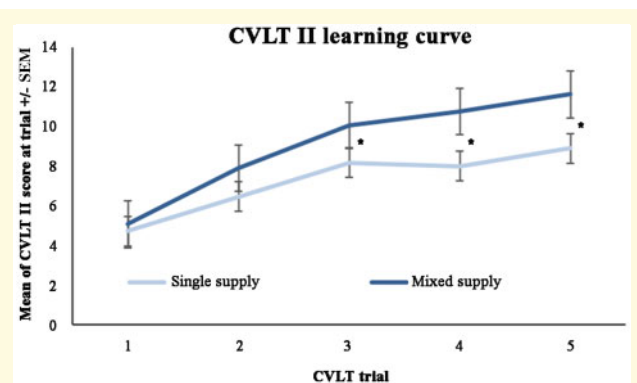
## Discussion

In this high-field neuroimaging study we conducted an *in vivo* investigation of how hippocampal vascular supply

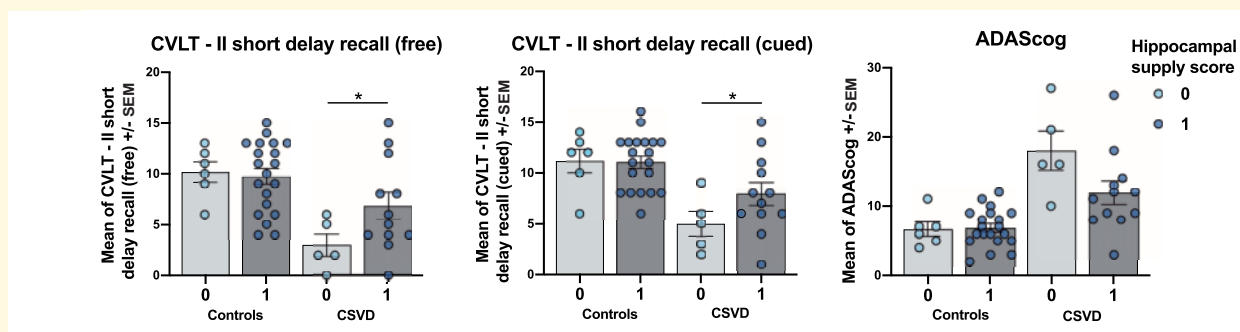
relates to cognition and hippocampal structure in older adults with and without small vessel disease pathology. We hypothesized that hippocampal vascularization might modulate cognition and that hippocampal supply by both the AChA and PCA might constitute a vascular reserve mechanism for cognition and hippocampal structure, compared to the hippocampal vascularization by the PCA alone. Furthermore, we hypothesized that hippocampal vascular supply is especially relevant in face of CSVD pathology, in which small vessel damage may result in higher susceptibility towards vascular reserve mechanisms.

One of the main findings of our study is a positive effect of having a mixed supply in at least one hippocampus on MTL-related cognitive domains, e.g. verbal memory, but also on other cognitive domains, e.g. attention and language, and on global cognition. There was an interaction effect between hippocampal supply and diagnosis (i.e. older adults with and without CSVD) on verbal memory, suggesting that a mixed hippocampal supply in at least one hemisphere also provides a vascular reserve for MTL-related cognitive function in participants with small vessel pathology. Furthermore, we found that mixed, compared to single, vascular supply patterns were associated to higher anterior hippocampus volumes.

The positive effect of mixed hippocampal vascularization on memory across the whole cohort was evident in several neuropsychological tests, e.g. in the CVLT-II LT 1–5 and in the MMSE memory recall. Our results are consistent with the well-documented importance of the hippocampus for declarative memory in general (Milner, 1972; Mayes *et al.*, 2002; Yonelinas *et al.*, 2002) and verbal memory in particular (Fernández *et al.*, 1998; Papanicolaou *et al.*, 2002; Bonner-Jackson *et al.*, 2015). In our study, mixed hippocampal supply had a positive main effect on the learning of novel words (CVLT-II LT 1–5) in the whole group. Consistent with this result, learning in the CVLT-II has previously been related to hippocampal function, with evidence for a correlation between (anterior) hippocampal activation and performance (Johnson *et al.*, 2001).



**Figure 3 CVLT-II learning curve.** Curves represent mean of CVLT-II score (mean of remembered words) at each encoding trial in subjects with single supply (score of hippocampal supply = 0) and mixed supply (score of hippocampal supply = 1). Learning occurs in both groups, but the score is significantly higher in LT 3–5 in subjects with mixed hippocampal supply. This is in line with our finding of a higher rate of change of performance in subjects with mixed, compared to single supply. Values are mean  $\pm$  SEM. Independent-sample *t*-tests were conducted for comparisons between conditions; \* $P < 0.05$ .



**Figure 4 Effect of hippocampal supply in CSVD and controls on cognition.** Bar graphs show differences in cognitive tests between groups with different scores of hippocampal supply (0 = absence of mixed supply in both hemispheres; 1 = mixed supply in at least one hemisphere) and presence or absence of CSVD. Values are mean  $\pm$  SEM. Independent samples *t*-tests were conducted for comparisons between conditions; \* $P < 0.05$ , \*\* $P < 0.01$  (Bonferroni-corrected).

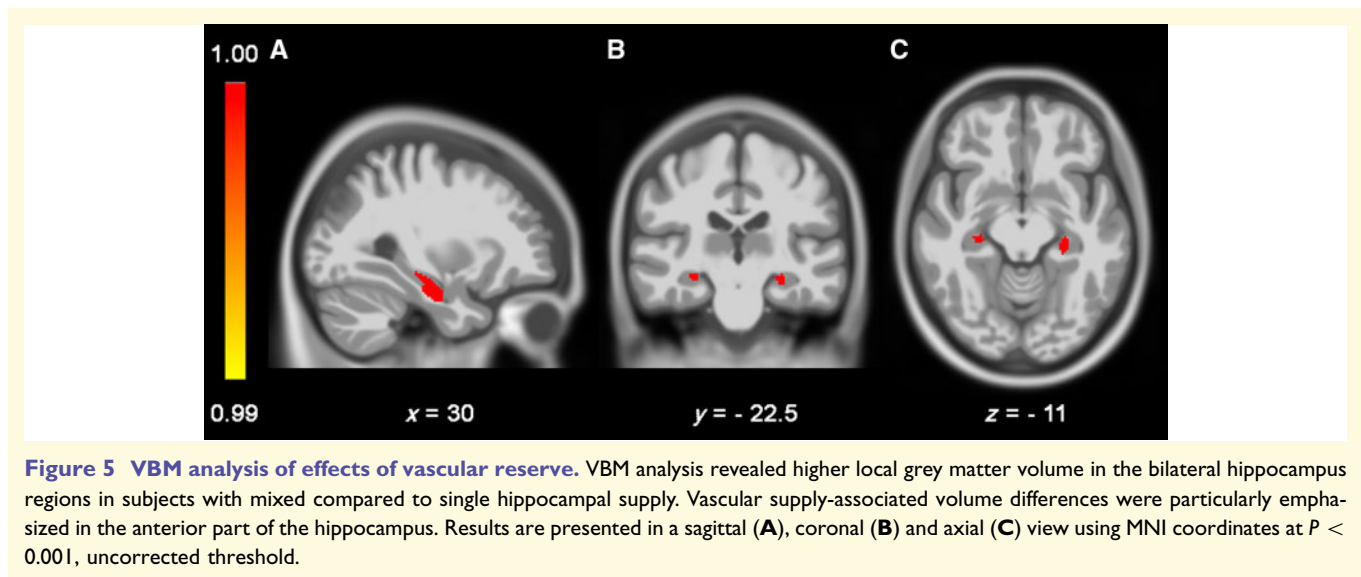


**Table 2 VBM analysis**

Voxels, <i>n</i>	MNI coordinates, mm			Region	<i>F</i>	<i>Z</i>	<i>P</i> (cluster)	<i>P</i> (peak)
	<i>x</i>	<i>y</i>	<i>z</i>					
<b>Single hippocampal supply</b>								
389	26	−11	−27	Right hippocampus	35.13	4.69	<0.001*	<0.001
99	−27	−27	−10.5	Left hippocampus	21.18	3.83	0.029	<0.001
<b>Bilateral mixed hippocampal supply</b>								
581	26	−11	−27	Right hippocampus	5.93	4.83	<0.001*	<0.001
163	−27	−27	−11	Left hippocampus	4.60	4.00	0.014	<0.001

VBM results for the comparison between subjects with bilateral mixed and single hippocampal supply. All clusters >30 voxels are displayed, which were significant at uncorrected cluster level ( $P < 0.001$ ). *F* and *t*-statistics for group comparison are both reported (*t*-statistic for bilateral mixed supply > single supply).

\*Clusters that survived familywise error correction  $P < 0.05$ .



**Figure 5 VBM analysis of effects of vascular reserve.** VBM analysis revealed higher local grey matter volume in the bilateral hippocampus regions in subjects with mixed compared to single hippocampal supply. Vascular supply-associated volume differences were particularly emphasized in the anterior part of the hippocampus. Results are presented in a sagittal (A), coronal (B) and axial (C) view using MNI coordinates at  $P < 0.001$ , uncorrected threshold.

A further reason why we investigated the effects of vascularization on the CVLT-II is the fine separation of learning and recall provided by this test (Pohlack *et al.*, 2012; Wicking *et al.*, 2014). Analysing the learning curve of each subject, we observed that the presence of mixed supply in at least one hippocampus had a positive main effect on learning rate and average performance.

There was, moreover, an interaction between hippocampal vascular supply and CSVD on both cued and free short delay recall, where the presence of a single supply pattern in CSVD was disadvantageous. This indicates that mixed supply becomes especially relevant for declarative verbal memory in the face of small vessel pathology, suggesting the particular relevance of this vascular reserve mechanism when small vessels are damaged.

We also observed a positive effect of mixed supply on ADAScog, MoCA attention, and MoCA language subscores and thus on measures of global cognition and domains beyond memory. This can be related to the fact that the hippocampus participates in several cognitive domains, including visuoconstruction (Brickman *et al.*, 2011; Seidl *et al.*, 2012), attention (Goldfarb *et al.*, 2016), motivation

and executive function (Wall and Messier, 2001; Frodl *et al.*, 2006). The involvement of this brain structure in a wide range of cognitive processes (Kosel *et al.*, 1982; Rubin *et al.*, 2014) could explain why subjects with a mixed supplied hippocampus obtained better results in the ADAScog and MoCA questionnaires, which are general measures of cognition, as well as in part of their subscores. Thus, the advantage represented by a mixed hippocampal supply might transfer to other cognitive functions.

We further found evidence for mixed hippocampal vascularization being tied to structural brain differences, i.e. a higher hippocampal volume for mixed, compared to single vascular supply. A possible mechanism underlying this observation might be that single supplied hippocampi have less vascular reserve and are more vulnerable to neuronal injury (Saur *et al.*, 2006; Guadagno *et al.*, 2008) and neurodegeneration (Fierstra *et al.*, 2010). An overlap of perfusion territories has been shown to be protective (van der Zwan *et al.*, 1992; Liebeskind, 2003; Lau *et al.*, 2012) and it is conceivable that an overlap of the AchA and PCA territories might also provide higher vascular reserve. This mechanism appears particularly plausible, when

considering that the AchA and PCA, respectively, belong to the anterior and posterior system of the *circulus Willisii* and a decrease in blood flow in one of the two territories can be compensated by the other (Wallin *et al.*, 2018). A putative decrease in perfusion (as believed to be found in single supplied hippocampi in ageing and/or CSVD) might lead to ischaemia and, especially in a hypoxia-sensitive brain area such as the hippocampus (Duvernoy, 2013), to neural injury. Moreover, the above reported differences in hippocampal volumes were found in the anterior part of the hippocampus, which is consistent with the putative supply territory of the AchA in case of mixed hippocampal supply. Hence, the anterior hippocampal region seems to profit from a mixed blood supply and might thus be less subject to atrophy, when the AchA is involved in the hippocampal vascularization. However, it is important to note that the known extent of the AchA territory in general and in the medial temporal lobe in particular, is still debated (Takahashi *et al.*, 1994; Hamoir *et al.*, 2004; Ois *et al.*, 2009) given its variability (Slobodan Marinković *et al.*, 1999), and the technical limitations of investigating perfusion in small territories.

Whether lower perfusion, structural damage or both are the neural substrates of the negative effect of a single supply on cognitive measures remains to be determined. However, previous research has shown that greater hippocampal volume relates to better memory performance in cognitively healthy older adults (Walhovd *et al.*, 2004; Pohlack *et al.*, 2012). Furthermore, a decreased perfusion contributes as an independent factor to cognitive decline in healthy ageing (Alosco *et al.*, 2013; Steffener *et al.*, 2013) and traumatic brain injury (Lin *et al.*, 2016). A negative association between task performance and cerebral blood flow even exists in healthy young subjects (Bertsch *et al.*, 2009).

Our study suffers from some limitations. In post-mortem studies, hippocampal arteries had an average diameter of 0.5 mm, but the directly supplying hippocampal branches, including the AchA uncal branch, could be even smaller with a minimum diameter of 0.2 mm (Marinković *et al.*, 1992; Erdem *et al.*, 1993). Therefore, possibly some of the uncal branches were below the detection threshold of our high resolution of time of flight angiography (0.28 mm isotropic) or could have been obscured by motion artefacts (Mattern *et al.*, 2018), leading to a potential underestimation of the number of mixed supplied hippocampi. Nonetheless, prevalence of mixed hippocampal supply observed in our study was consistent with a previous post-mortem study (53% in the present study; 60% in Erdem *et al.*, 1993), indicating that the number of overlooked uncal branches is at most marginal. While the use of 7 T ToF-angiography allowed for the first time the *in vivo* depiction of the hippocampal vessels and thus went beyond current capabilities at 3 T (von Morze *et al.*, 2007), further improvement by using even higher resolution (e.g. 0.15 mm isotropic) and motion correction would be advisable. In the absence of pathological examination, we can not definitely

exclude concurrent Alzheimer's disease pathology in our CSVD cohort, especially when considering the overlap between CAA and Alzheimer's pathology (Charidimou *et al.*, 2017). However, the biomarker-based ATN (amyloid- $\beta$ , tau, neurodegeneration) classification (Jack *et al.*, 2018) performed on part of the CSVD cohort and the lack of hippocampal atrophy in our participants with CSVD in general and in those with CAA in particular, give us some confidence that we did not include subjects with a developed Alzheimer's disease pathology. In addition, excluding the presence of CSVD markers from healthy controls may have increased the probability of including 'successful agers' who have avoided age-related vascular disease. Nonetheless, the role that vascular lesions in general and CSVD in particular plays in 'successful agers' is still a matter of debate (Harrison *et al.*, 2018; Dang *et al.*, 2019). Finally, our cross-sectional study design does not allow us to make any statement about the causal influence of hippocampal vascularization on the variability of cognition and structural changes in the hippocampus over time. Longitudinal studies are necessary to rule out the possibility of a reverse causality, i.e. that smaller hippocampi are *a priori* supplied by one artery only.

Further research is needed to pinpoint the relation between vascularization and hippocampal perfusion (e.g. adopting arterial spin labelling), vascularization and hippocampal function (e.g. using 7 T ultrahigh-resolution resting state or task-based functional MRI), as well as between vascularization and the degree of further pathology beyond CSVD (e.g. Alzheimer's disease pathology). Interactive pathophysiological mechanisms between vascular and Alzheimer's disease pathology have been extensively hypothesized (Webb *et al.*, 2012; Kiviniemi *et al.*, 2016; Geurts *et al.*, 2018), but studies about the role of hippocampal vascularization in Alzheimer's disease pathology are thus far missing. Impaired perivascular clearance of pathological proteins, such as amyloid or tau, might link vascular and Alzheimer's disease pathology (Mestre *et al.*, 2017). Hippocampal vascularization could play a substantial role for the clearance of those proteins and might drive the accumulation of at least medial temporal lobe tau (Iliff *et al.*, 2013).

The neuropsychological test battery adopted in the present study is well-established to measure global cognition and memory, but the application of tasks, which more specifically target MTL-related cognitive domains, such as spatial navigation memory tasks, pattern separation/completion tasks (Berron *et al.*, 2016), would help to shed more light on the effects of the hippocampal vascularization patterns on cognition. Furthermore, to assess whether or not hippocampal vascularization differentially affects hippocampal subregions, neuroimaging methods allowing a distinction of the subfields (Mueller *et al.*, 2018) are needed. In fact, vascularization possibly relates to the differential susceptibility of hippocampal subfields to hypoxia (Kreisman *et al.*, 2014), e.g. the greater

vulnerability of CA1 in comparison to other subfields in the presence of vascular pathology (Small *et al.*, 2012).

Besides possibly representing a mechanism of cognitive reserve and its interaction with neurodegenerative pathologies, hippocampal vascularization may help to understand the pathophysiology and clinical phenotype of other conditions closely related to this crucial brain region. For example, hippocampal sclerosis is in about 50% of cases unilateral and associated with vascular risk factors and memory loss (Zarow *et al.*, 2012). However, the causes determining its laterality remain unclear. Furthermore, both unilateral and bilateral acute hippocampal infarcts have been observed and may be the cause of transient global amnesia (Yang *et al.*, 2008), which induces reversible memory loss. One may speculate that hippocampal supply patterns may moderate laterality effects and that mixed supply could potentially serve as a protective or compensatory factor against the development of hippocampal sclerosis or infarcts and/or against their impact on MTL-related cognitive function.

Our findings establish a link between hippocampal vascularization and cognition and between vascularization and hippocampal structural integrity. Vascular hippocampal supply also revealed an effect in presence of small vessel pathology, suggesting that vascularization patterns might become relevant for hippocampus-related functional circuits, when small vessel damage exists. We interpret our results as hippocampal vascular reserve conveyed by mixed hippocampal supply. Considering directly the influence of vascularization on cognition is an innovative aspect of our work which might open new perspectives in the study of hippocampal injury and its cognitive consequences.

## Acknowledgements

We are very grateful to all participants who volunteered to take part in the study. We thank Anna Ludwig and Denver Huff for help in subject recruitment and data collection. We also wish to thank Renate Blobel-Lüer and Klaus Tempelmann for their dedicated efforts in scanning standardization and quality assurance.

## Funding

This work was funded by the BMBF (EnergI-Consortium, TP01) and the German Research Foundation, CRC 779 (TP A07).

## Competing interests

The authors report no competing interests.

## Supplementary material

Supplementary material is available at *Brain* online.

## References

- Alosco ML, Brickman AM, Spitznagel MB, Garcia SL, Narkhede A, Griffith EY, *et al.* Cerebral perfusion is associated with white matter hyperintensities in older adults with heart failure. *Congest Heart Fail* 2013; 35: 682–8.
- Ashburner J. A fast diffeomorphic image registration algorithm. *Neuroimage* 2007; 38: 95–113.
- Berron D, Schütze H, Maass A, Cardenas-Blanco A, Kuijff HJ, Kumaran D, *et al.* Strong Evidence for Pattern Separation in Human Dentate Gyrus. *J Neurosci* 2016; 36: 7569–79.
- Bertsch K, Hagemann D, Hermes M, Walter C, Khan R, Naumann E. Resting cerebral blood flow, attention, and aging. *Brain Res.* 2009; 1267: 77–88.
- Brink TL, Yesavage JA, Lum O, Heersema PH, Adey M, Rose TL, *et al.* Screening tests for geriatric depression. *Clin Gerontol*, 1982; 1: 37–43.
- Bonner-Jackson A, Mahmoud S, Miller J, Banks SJ. Verbal and non-verbal memory and hippocampal volumes in a memory clinic population. *Alzheimer's Res Ther* 2015; 7: 1–10.
- Boraxbekk CJ, Salami A, Wåhlin A, Nyberg L. Physical activity over a decade modifies age-related decline in perfusion, gray matter volume, and functional connectivity of the posterior default-mode network—a multimodal approach. *Neuroimage* 2016; 131: 133–41.
- Boyle PA, Yu L, Wilson RS, Leurgans SE, Schneider JA, Bennett DA. Person-specific contribution of neuropathologies to cognitive loss in old age. *Ann Neurol* 2018; 83: 74–83.
- Brickman AM, Stern Y, Small SA. Hippocampal subregions differentially associate with standardized memory tests. *Hippocampus* 2011; 21: 923–8.
- Charbonneau S, Whitehead V, Collin I. The Montreal Cognitive Assessment, MoCA: a brief screening. *Am Geriatr Soc* 2005; 53: 695–9.
- Charidimou A, Boulouis G, Gurol ME, Ayata C, Bacskai BJ, Froesch MP, *et al.* Emerging concepts in sporadic cerebral amyloid angiopathy cerebral amyloid angiopathy clinical aspects. *Brain* 2017; 140: 1829.
- Charidimou A, Pantoni L, Love S. The concept of sporadic cerebral small vessel disease: a road map on key definitions and current concepts. *Int J Stroke* 2016; 11: 6–18.
- Cummings J. The National Institute on Aging—Alzheimer's Association Framework on Alzheimer's disease: application to clinical trials. *Alzheimer's Dement* 2019; 15: 172–8.
- Dang C, Yassi N, Harrington KD, Xia Y, Lim YY, Ames D, *et al.* Rates of age- and amyloid  $\beta$ -associated cortical atrophy in older adults with superior memory performance. *Alzheimer's Dement* 2019; 11: 566–75.
- Delis DC, Kramer JH, Kaplan E, California Ober BA. Verbal Learning Test. 2nd edn. London: Pearson; 2000.
- Duvernoy HM. The human hippocampus. München: JF Bergmann-Verlag; 2013.
- Düzel E, Bunzeck N, Guitart-Masip M, Düzel S. NOvelty-related motivation of anticipation and exploration by dopamine (NOMAD): implications for healthy aging. *Neurosci Biobehav Rev* 2010; 34: 660–9.
- Duezel E, Vargha-Khadem F, Heinze HJ, Mishkin M. Brain activity evidence for recognition without recollection after early hippocampal damage. *Proc Natl Acad Sci* 2001; 98: 8101–6.
- Erdem A, Yaşargil MG, Roth P. Microsurgical anatomy of the hippocampal arteries. *J Neurosurg* 1993; 79: 256–65.
- Fazekas F, Chawluk JB, Zimmerman A, June M. MR signal abnormalities at 1.5 T in Alzheimer's Dementia and normal aging. *AJNR* 1987; 149: 351–6.

- Fernández G, Weyerts H, Schrader-Bölsche M, Tendolkar I, Smid HG, Tempelmann C, et al. Successful verbal encoding into episodic memory engages the posterior hippocampus: a parametrically analyzed functional magnetic resonance imaging study. *J Neurosci* 1998; 18: 1841–7.
- Fierstra J, Poublanc J, Han JS, Silver F, Tymianski M, Crawley AP, et al. Steal physiology is spatially associated with cortical thinning. *J Neurol Neurosurg Psychiatry* 2010; 81: 290–3.
- Fischl B, Salat DH, Van Der Kouwe JW, Makris N, Quinn BT, Dale AM. Sequence-independent segmentation of magnetic resonance images. *Neuroimage* 2004; 23: 69–84.
- Folstein MF, Folstein SE, McHugh PR. ‘Mini-mental state’. A practical method for grading the cognitive state of patients for the clinician. *J Psychiatr Res* 1975; 12: 189–98.
- Freitas S, Simoes MR, Marôco J, Alves L, Santana I. Construct validity of the montreal cognitive assessment (MoCA). *J Int Neuropsychol Soc* 2012; 18: 242–50.
- Frey S, Frey JU. Chapter 7 ‘Synaptic tagging’ and ‘cross-tagging’ and related associative reinforcement processes of functional plasticity as the cellular basis for memory formation. *Prog Brain Res* 2008; 169: 117–43.
- Frodl T, Schaub A, Banac S, Charypar M, Jäger M, Kümmler P, et al. Reduced hippocampal volume correlates with executive dysfunctioning in major depression. *J Psychiatry Neurosci* 2006; 31: 316–25.
- Gastaut H, Lammers HJ. *Anatomie du rhinencéphale*. Paris; 1961.
- Geurts LJ, Zwanenburg JJM, Klijn CJM, Luijten PR, Biessels GJ. Higher pulsatility in cerebral perforating arteries in patients with small vessel disease related stroke, a 7T MRI Study. *Stroke* 2018; 50: 62–8.
- Goldfarb EV, Chun MM, Phelps EA. Memory-guided attention: independent contributions of the hippocampus and striatum. *Neuron* 2016; 89: 317–24.
- Guadagno J V, Jones PS, Aigbirhio FI, Wang D, Fryer TD, Day DJ, et al. Selective neuronal loss in rescued penumbra relates to initial hypoperfusion. *Brain* 2008; 131: 2666–78.
- Hamoir XL, Grandin CB, Peeters A, Robert A, Cosnard G, Duprez T. MRI of hyperacute stroke in the AChA territory. *Eur Radiol* 2004; 14: 417–24.
- Harrison TM, Maass A, Baker SL, Jagust WJ. Brain morphology, cognition, and  $\beta$ -amyloid in older adults with superior memory performance. *Neurobiol Aging* 2018; 67: 162.
- Hecht M, Krämer LM, von Arnim CAF, Otto M, Thal DR. Capillary cerebral amyloid angiopathy in Alzheimer’s disease: association with allocortical/hippocampal microinfarcts and cognitive decline. *Acta Neuropathol* 2018; 135: 681–94.
- Heo S, Prakash RS, Voss MW, Erickson KI, Ouyang C, Sutton BP, et al. Resting hippocampal blood flow, spatial memory and aging Susie. *Brain Res* 2010; 42: 1556–62.
- Iloff JJ, Nedergaard M, Lee H, Yu M, Benveniste H, Feng T, et al. Brain-wide pathway for waste clearance captured by contrast-enhanced MRI. *J Clin Invest* 2013; 123: 1299–309.
- Iturria-Medina Y, Sotero RC, Toussaint PJ, Mateos-Pérez JM, Evans AC, Weiner MW, et al. Early role of vascular dysregulation on late-onset Alzheimer’s disease based on multifactorial data-driven analysis. *Nat Commun* 2016; 7: 11934.
- Jack CR, Bennett DA, Blennow K, Carrillo MC, Dunn B, Haeberlein SB, et al. NIA-AA Research Framework: Toward a biological definition of Alzheimer’s disease. *Alzheimer’s Dement*. 2018; 14: 535–62.
- Johnson SC, Saykin AJ, Flashman LA, McAllister TW SM. Brain activation on fMRI and verbal memory ability: functional neuroanatomic correlates of CVLT performance. *J. Int. Neuropsychol. Soc.* 2001; 7: 55–62.
- Jokinen H, Melkas S, Madureira S, Verdelho A, Ferro JM, Fazekas F, et al. Cognitive reserve moderates long-term cognitive and functional outcome in cerebral small vessel disease. *J Neurol Neurosurg Psychiatry* 2016; 87: 1296–302.
- Kiviniemi V, Wang X, Korhonen V, Keinänen T, Tuovinen T, Autio J, et al. Ultra-fast magnetic resonance encephalography of physiological brain activity-Glymphatic pulsation mechanisms? *J Cereb Blood Flow Metab* 2016; 36: 1033–45.
- Klosovskii BN. Fundamental principles of the development, structure and function of the vaso-capillary network of the brain. In: Klosovskii BN, editors. *The development of the brain and its disturbance by harmful factors*. Oxford: Pergamon; 1963.
- Kosel KC, Van Hoesen GW, Rosene DL. Non-hippocampal cortical projections from the entorhinal cortex in the rat and rhesus monkey. *Brain Res* 1982; 244: 201.
- Kreisman NR, Soliman S, Gozal D, Wang Y, Guo SZ, Bonen A, et al. Regional differences in hypoxic depolarization and swelling in hippocampal slices regional differences in hypoxic depolarization and swelling in hippocampal slices. *J Neurophysiol* 2014; 83: 1031–8.
- Kress BT, Iloff JJ, Xia M, Wang M, Wei HS, Zeppenfeld D, et al. Impairment of paravascular clearance pathways in the aging brain. *Ann Neurol* 2014; 76: 845.
- Kril JJ. Patients with vascular dementia due to microvascular pathology have significant hippocampal neuronal loss. *J. Neurol Neurosurg Psychiatry* 2002; 72: 747–51.
- Lambert C, Benjamin P, Zeestraten E, Lawrence AJ, Barrick TR, Markus HS. Longitudinal patterns of leukoaraiosis and brain atrophy in symptomatic small vessel disease. *Brain* 2016; 139: 1136–51.
- Lambert C, Sam Narean J, Benjamin P, Zeestraten E, Barrick TR, Markus HS. Characterising the grey matter correlates of leukoaraiosis in cerebral small vessel disease. *NeuroImage Clin* 2015; 9: 194–205.
- Lang J. *Klinische Anatomie des Kopfes. Neurokranium–Orbita–Kraniozervikaler Übergang*. Berlin/Heidelberg/New York: Springer; 1981.
- Lau AYL, Wong EHC, Wong A, Mok VCT, Leung TW, Wong KSL. Significance of good collateral compensation in symptomatic intracranial atherosclerosis. *Cerebrovasc Dis* 2012; 33: 517–24.
- Liesbeskind DS. Collateral circulation. *Stroke* 2003; 34: 2279–84.
- Lin CM, Tseng YC, Hsu HL, Chen CJ, Chen DYT, Yan FX, et al. Arterial spin labeling perfusion study in the patients with subacute mild traumatic brain injury. *PLoS One* 2016; 11: 1–11.
- Linn J, Halpin A, Demaerel P, Ruhland J, Giese AD, Dichgans M, et al. Prevalence of superficial siderosis in patients with cerebral amyloid angiopathy. *Neurology* 2010; 74: 1346–50.
- Maass A, Duzel S, Goerke M, Becke A, Sobieray U, Neumann K, et al. Vascular hippocampal plasticity after aerobic exercise in older adults. *Mol Psychiatry* 2015; 20: 585–93.
- Marinković S, Gibo H, Brigante L, Nikodijević I, Petrović P. The surgical anatomy of the perforating branches of the anterior chorooidal artery. *Surg Neurol* 1999; 52: 30–6.
- Marinković S, Milisavljević M, Puškaš L. Microvascular anatomy of the hippocampal formation. *Surg Neurol* 1992; 37: 339–49.
- Mattern H, Sciarra A, Godenschweiger F, Stucht D, Lüsebrink F, Rose G, et al. Prospective motion correction enables highest resolution time-of-flight angiography at 7T. *Magn Reson Med* 2018; 80: 248–58.
- Mayer AR, Holdstock JS, Isaac CL, Hunkin NM, Roberts N. Relative sparing of item recognition memory in a patient with adult-onset damage limited to the Hippocampus. *Hippocampus* 2002; 12: 325–40.
- Mestre H, Kostrikov S, Mehta RI, Nedergaard M. Perivascular spaces, glymphatic dysfunction, and small vessel disease. *Clin Sci* 2017; 131: 2257–74.
- Milner B. Disorders of learning and memory after temporal lobe lesions in man. *Clin Neurosurg* 1972.
- Morris JC. The clinical dementia rating (CDR): current version and scoring rules. *Neurology* 1993; 43: 2412.
- Mueller SG, Yushkevich PA, Das S, Wang L, Van Leemput K, Iglesias JE, et al. Systematic comparison of different techniques to measure hippocampal subfield volumes in ADNI2. *NeuroImage Clin*. 2018; 17: 1006–18.

- Nasreddine ZS, Phillips NA, Bedrian V, Charbonneau S, Whitehead V, Collin I, et al. The montreal cognitive assessment, MoCA: A brief screening. *J Am Geriatr Soc* 2005; 53: 695–9.
- O’Keefe J, Nadel L. Précis of O’Keefe & Nadel’s the hippocampus as a cognitive map. *Behav Brain Sci* 1979; 2: 487–94.
- O’Sullivan M, Ngo E, Viswanathan A, Jouvent E, Gschwendtner A, Saemann PG, et al. Hippocampal volume is an independent predictor of cognitive performance in CADASIL. *Neurobiol Aging* 2009; 30: 890–7.
- Ogoh S. Relationship between cognitive function and regulation of cerebral blood flow. *J Physiol Sci* 2017; 67: 345–51.
- Ois A, Cuadrado-Godia E, Solano A, Perich-Alsina X, Roquer J. Acute ischemic stroke in anterior choroidal artery territory. *J Neurol Sci* 2009; 281: 80–4.
- Pantoni L. Cerebral small vessel disease: from pathogenesis and clinical characteristics to therapeutic challenges. *Lancet Neurol* 2010; 9: 689–701.
- Papanicolaou AC, Simos PG, Castillo EM, Breier JI, Katz JS, Wright AA. The hippocampus and memory of verbal and pictorial material. *Learn Mem* 2002; 9: 99–104.
- Pohlack ST, Meyer P, Cacciaglia R, Liebscher C, Ridder S, Flor H. Bigger is better! Hippocampal volume and declarative memory performance in healthy young men. *Brain Struct Funct* 2012; 219: 255–67.
- Potter GM, Chappell FM, Morris Z, Wardlaw JM. Cerebral perivascular spaces visible on magnetic resonance imaging: development of a qualitative rating scale and its observer reliability. *Cerebrovasc Dis* 2015; 39: 224–31.
- Rabbitt P, Scott M, Thacker N, Lowe C, Jackson A, Horan M et al. Losses in gross brain volume and cerebral blood flow account for age-related differences in speed but not in fluid intelligence. *Neuropsychol Rev* 2006; 20: 549–57.
- Rosen G, Davis L, Mohs C. A new rating scale for Alzheimer’s disease. *Am J Psychiatry* 1984; 141: 1356–64.
- Rubin RD, Watson PD, Duff MC, Cohen NJ. The role of the hippocampus in flexible cognition and social behavior. *Front Hum Neurosci* 2014; 8: 1–15.
- Saur D, Buchert R, Knab R, Weiller C, Röther J. Iomazenil-single-photon emission computed tomography reveals selective neuronal loss in magnetic resonance-defined mismatch areas. *Stroke* 2006; 37: 2713–9.
- Seidl U, Traeger TV, Hirjak D, Remmele B, Wolf RC, Kaiser E, et al. Subcortical morphological correlates of impaired clock drawing performance. *Neurosci Lett* 2012; 512: 28–32.
- Small, Scott A; Schobel, Scott A; Buxton Richard B; Witter MP. BCA. A pathophysiological framework of hippocampal dysfunction in ageing and disease. *Nat Rev Neurosci* 2012; 12: 585–601.
- Spallazzi M, Dobisch L, Becke A, Caffarra P, Duzel E. Hippocampal vascularization patterns: a high resolution 7T time-of-flight magnetic resonance angiography study. *NeuroImage Clin* 2018; 39: 561–3.
- Steffener J, Brickman AM, Habeck CG, Salthouse TA, Stern Y. Patterns of cognition in aging. 2013; 34: 1–23.
- Strauss E, Sherman EMS, Spreen O. A compendium of neuropsychological tests: administration, norms, and commentary. Oxford: Oxford University Press; 1991.
- Suthana NA, Ekstrom AD, Moshirvaziri S, Knowlton B, Bookheimer Y. Encoding of Spatial Information. *J Neurosci* 2009; 29: 10512–9.
- Takahashi S, Fukasawa H, Ishii K, Sakamoto K. The anterior choroidal artery syndrome-I. Microangiography of the anterior choroidal artery. *Neuroradiology* 1994; 36: 337–9.
- Walhovd KB, Fjell AM, Reinvang I, Lundervold A, Fischl B, Quinn BT, et al. Size does matter in the long run: Hippocampal and cortical volume predict recall across weeks. *Neurology* 2004; 63: 1193–7.
- Wall PM, Messier C. The hippocampal formation-orbitomedial prefrontal cortex circuit in the attentional control of active memory. *Behav Brain Res* 2001; 127: 99–117.
- Wallin A, Román GC, Esiri M, Kettunen P, Svensson J, Paraskevas GP, et al. Update on vascular cognitive impairment associated with subcortical small-vessel disease. *J Alzheimer’s Dis* 2018; 62: 1417–41.
- Wardlaw JM, Smith EE, Biessels GJ, Cordonnier C, Fazekas F, Frayne R, et al. Neuroimaging standards for research into small vessel disease and its contribution to ageing and neurodegeneration. *Lancet Neurol* 2013; 12: 822–38.
- Webb AJS, Simoni M, Mazzucco S, Kuker W, Schulz U, Rothwell PM. Increased cerebral arterial pulsatility in patients with leukoaraiosis: Arterial stiffness enhances transmission of aortic pulsatility. *Stroke* 2012; 43: 2631–6.
- Wicking M, Nees F, Steiger F. Neuropsychological measures of hippocampal function. *Hippocampus Clin Neurosci* 2014; 34: 60–70.
- Wu W, Brickman AM, Luchsinger J, Ferrazano P, Pichiule P, Yoshita M, et al. The brain in the age of old: The hippocampal formation is targeted differentially by diseases of late-life. *Ann Neurol* 2008; 64: 698–706.
- Xiong L, Davidsdottir S, Reijmer YD, Shoamanesh A, Roongpiboonsopit D, Thanprasertsuk S, et al. Cognitive profile and its association with neuroimaging markers of non-demented cerebral amyloid angiopathy patients in a stroke unit. *J Alzheimer’s Dis* 2016; 52: 171–8.
- Yang Y, Kim SY, Kim JH. Ischemic evidence of transient global amnesia: Location of the lesion in the hippocampus. *J Clin Neurol* 2008; 4: 59–66.
- Yonelinas AP, Kroll NEA, Quamme JR, Lazzara MM, Sauvé M-J, Widaman KF, et al. Effects of extensive temporal lobe damage or mild hypoxia on recollection and familiarity. *Nat Neurosci* 2002; 5: 1236.
- Zarow C, Weiner MW, Ellis WG, Chui HC. Prevalence, laterality, and comorbidity of hippocampal sclerosis in an autopsy sample. *Brain Behav* 2012; 2: 435–42.
- Zhang M, Chen M, Wang Q, Yun W, Zhang Z, Yin Q, et al. Relationship between cerebral microbleeds and cognitive function in lacunar infarct. *J Int Med Res* 2013; 41: 347–55.
- Zola-Morgan S. SLR. ADG. Human amnesia and the medial temporal region: enduring memory impairment following a bilateral lesion limited to field CA1 of the hippocampus. *J Neurosci* 1986; 2: 2950–67.
- van der Zwan A, Hillen B, Tulleken CAF, Dujovny M, Dragovic L. Variability of the territories of the major cerebral arteries. *J Neurosurg* 1992; 77: 927–40.
- van Leijns EMC, Tay J, van Uden IWM, Kooijmans ECM, Bergkamp MI, van der Holst HM, et al. Memory decline in elderly with cerebral small vessel disease explained by temporal interactions between white matter hyperintensities and hippocampal atrophy. *Hippocampus* 2019; 29: 500–10.
- Von Morze C, Xu D, Purcell DD, Hess CP, Mukherjee P, Saloner D, et al. Intracranial time-of-flight MR angiography at 7T with comparison to 3T. *J Magn Reson Imaging* 2007; 26: 900–4.