doi:10.1093/brain/awaa418 BRAIN 2021: 144; 574–583 | 574

BRAIN
A JOURNAL OF NEUROLOGY

Bi-allelic truncating mutations in *VWA1* cause neuromyopathy

Marcus Deschauer,[1,†] Holger Hengel,[2,3,4,†] Katrin Rupprich,[5] Martina Kreiß,[6] Beate Schlotter-Weigel,[7] Mona Grimmel,[4] Jakob Admard,[4] Ilka Schneider,[8] Bader Alhaddad,[9] Anastasia Gazou,[4] Marc Sturm,[4] Matthias Vorgerd,[10] Ghassan Balousha,[11] Osama Balousha,[12] Mohammed Falna,[12] Jan S. Kirschke,[13] Cornelia Kornblum,[14] Berit Jordan,[8,15] Torsten Kraya,[8] Tim M. Strom,[9] Joachim Weis,[16] Ludger Schöls,[2,3] Ulrike Schara,[5] Stephan Zierz,[8] Olaf Riess,[4,17] Thomas Meitinger[9] and Tobias B. Haack[4,9,17]

[†] These authors contributed equally to this work.

See Arribat (doi.10.1093/brain/awaa464) for a scientific commentary on this article.

The von Willebrand Factor A domain containing 1 protein, encoded by *VWA1*, is an extracellular matrix protein expressed in muscle and peripheral nerve. It interacts with collagen VI and perlecan, two proteins that are affected in hereditary neuromuscular disorders. Lack of VWA1 is known to compromise peripheral nerves in a *Vwa1* knock-out mouse model. Exome sequencing led us to identify bi-allelic loss of function variants in *VWA1* as the molecular cause underlying a so far genetically undefined neuromuscular disorder. We detected six different truncating variants in 15 affected individuals from six families of German, Arabic, and Roma descent. Disease manifested in childhood or adulthood with proximal and distal muscle weakness predominantly of the lower limbs. Myopathological and neurophysiological findings were indicative of combined neurogenic and myopathic pathology. Early childhood foot deformity was frequent, but no sensory signs were observed. Our findings establish *VWA1* as a new disease gene confidently implicated in this autosomal recessive neuromyopathic condition presenting with child-/adult-onset muscle weakness as a key clinical feature.

1 Department of Neurology, Technical University of Munich, School of Medicine, 81675 Munich, Germany
2 Department of Neurology and Hertie-Institute for Clinical Brain Research, University of Tübingen, 72076 Tübingen, Germany
3 German Center of Neurodegenerative Diseases (DZNE), 72076 Tübingen, Germany
4 Institute of Medical Genetics and Applied Genomics, University of Tübingen, 72076 Tübingen, Germany
5 Department of Neuropediatrics, University Hospital Essen, 45147 Germany
6 Institute of Human Genetics, University of Bonn, 53127 Bonn, Germany
7 Department of Neurology, Ludwig Maximilian University Munich, 80337 Munich, Germany
8 Department of Neurology, University of Halle-Wittenberg, 06097 Halle, Germany
9 Institute of Human Genetics, Technical University of Munich, School of Medicine, 81675 Munich, Germany
10 Department of Neurology, University Hospital Bergmannsheil, Heimer Institute for Muscle Research, 44789 Bochum, Germany
11 Department of Pathology and Histology, Al-Quds University, Eastern Jerusalem, Palestinian Authority
12 Faculty of Medicine, Al-Quds University, Eastern Jerusalem, Palestinian Authority
13 Department of Diagnostic and Interventional Neuroradiology, Technical University of Munich, School of Medicine, 81675 Munich, Germany
14 Department of Neurology, University Hospital Bonn, 53127 Bonn, Germany
15 Department of Neurology, University Hospital Heidelberg, 69120 Heidelberg, Germany
16 Institute for Neuropathology, Medical Faculty, RWTH Aachen University, 52074 Aachen, Germany
17 Center for Rare Diseases, University of Tübingen, 72076 Tübingen, Germany

Received June 18, 2020. Revised September 1, 2020. Accepted September 23, 2020. Advance access publication January 18, 2021
© The Author(s) (2021). Published by Oxford University Press on behalf of the Guarantors of Brain. All rights reserved.
For permissions, please email: journals.permissions@oup.com

Correspondence to: Marcus Deschauer
Department of Neurology, Technical University Munich
School of Medicine, Ismaninger Str. 22, 81675 Munich, Germany
E-mail: marcus.deschauer@tum.de

Keywords: VWA1; mutations; neuromyopathy; exome sequencing

Introduction

Neuromuscular disorders are characterized by progressive muscle weakness arising from damage to anterior horn cells, peripheral nerves, neuromuscular junction or muscle itself. The majority of pathologies have a genetic aetiology with more than 150 loci being associated with muscle disorders and approximately 100 loci with neurogenic weakness (Benarroch *et al.*, 2020). Some gene defects can result in myopathic and neurogenic weakness in the same patient. These disorders were named neuromyopathy (Milone and Liewluck, 2019).

The implementation of next generation sequencing-based genetic testing such as gene panel or whole exome sequencing has proven a powerful tool to address the diagnostic challenge associated with the extreme genetic heterogeneity and phenotypic variability of neuromuscular disorders (Kuhn *et al.*, 2016; Krenn *et al.*, 2020). However, it is estimated that at least half of the affected individuals and their families remain without a definitive molecular diagnosis partly due to technical limitations, e.g. targeted short-read sequencing approaches or incomplete annotation of detected variants. This diagnostic gap is commonly believed to be addressed in the nearby future by full genome datasets augmented with long-read sequences and/or RNA sequencing (Cummings *et al.*, 2017). Another major challenge in rare disease diagnosis as well as research is that although the putatively disease-causal defect might be readily detected, it might take years to establish statistical evidence supporting the association of a given variant or potential disease gene with a specific phenotype.

Here, we report results of an exome sequencing study in six families comprising 15 individuals clinically diagnosed with a neuromuscular disorder without a molecular diagnosis. Bi-allelic truncating variants in *VWA1* (encoding for the von Willebrand Factor A domain containing 1 protein) were detected. This protein is a component of basement membranes particularly in muscle and peripheral/central nervous system. Thus, a novel candidate gene for a neuromyopathy was identified.

Material and methods

Patients and exome sequencing

Exome sequencing was performed at two centres in Munich (Families F1 and F2) and Tübingen (Families F3, F4, F5, and F6) on genomic DNA from affected Patients F1-II.2, F2-II.1, F3-II.3, F3-II.4, F4-II.2, F5-II.2, and F6-II.1, as previously described (Haack *et al.*, 2012; Fritzen *et al.*, 2018). Families F1 and F2 were initially investigated in the context of a follow-up research study on a clinically preselected cohort of 10 individuals remaining without a diagnosis after diagnostic panel analysis of myopathy-associated disease genes (Kuhn *et al.*, 2016). Informed consent was obtained from all individuals or their guardians. The study was approved by the ethics committee of the medical faculty of the Technical University of Munich. Genetic findings are summarized in Table 1.

RNA sequencing

Fibroblasts for RNA extraction were available from two patients (Patients F1-II.2 and F5.II.1). RNA was isolated using QIAGEN RNeasy® Mini Kit. RNA quality was assessed with the Agilent 2100 Fragment Analyzer total RNA kit (Agilent Technologies, Inc.). All samples had high RNA integrity numbers (RIN >9). Using the NEBNext® Ultra II Directional RNA Library Prep kit with 100 ng of total RNA input for each sequencing library, poly(A)-selected sequencing libraries were generated according to the manufacturer's manual. All libraries were sequenced on the Illumina NovaSeq 6000 platform as 2×100 bp paired-end reads and to a depth of ~50 million clusters each. Quality of raw RNA-seq data in FASTQ files was assessed using ReadQC (version 2020_03) to identify potential sequencing cycles with low average quality and base distribution bias. Reads were preprocessed with SeqPurge (version 2020_03) and aligned using STAR (version 2.7.3a) allowing spliced read alignment to the human reference genome (build GRCh37). Alignment quality was analysed using MappingQC (ngs-bits version 2020_03) and visually inspected with Broad Integrative Genome Viewer (version 2.8.2). Based on the Ensembl genome annotation (GRCh37, Ensembl release 97), read counts for all genes were obtained using subread (version 2.0.0). For comparative gene expression analysis, we used in-house transcriptome datasets from 50 fibroblast cell lines derived from individuals with unrelated phenotypes as controls. Raw gene counts were normalized by weighted trimmed mean of M-values (TMM) normalization and modelled with a generalized linear model following the method implemented in edgeR (version 3.26.8) (Robinson *et al.*, 2010; McCarthy *et al.*, 2012). *Z*-scores were calculated based on log2-transformed normalized expression values.

Clinical examinations

Muscle MRI scans of seven patients were performed in different centres with different protocols but grading of fatty infiltration and oedema of all scans was performed by a

Table 1 Genetic findings in individuals with bi-allelic *VWA1* variants

ID	Sex	Ethnicity	cDNA (NM_022834.4)	Protein (NP_073745.2)	Consanguinity of parents
Family 1		Roma	c.252del	p.(Glu85Serfs*58)	First cousins
F1-II.2	Male		homozygous		
F1-II.4	Female				
F1-II.5	Female				
F1-II.6	Male				
Family 2		German	c.62_71dup	p.(Gly25Argfs*74)	No
F2-II.1	Male		c.94C>T	p.(Arg32*)	
			compound heterozygous		
Family 3		Arab	c.62_71del	p.(Gly21Alafs*12)	First cousins
F3-II.3	Female		homozygous		
F3-II.4	Male				
F3-II.5	Female				
F3-II.7	Male				
F3-II.9	Female				
Family 4		German	c.62_71dup	p.(Gly25Argfs*74)	No
F4-II.1	Female		c.879del	p.(Arg293Serfs *58)	
F4-II.2	Female		compound heterozygous		
Family 5		German	c.186_209del	p.(Pro63_Ala 70del)	No
F5-II.1	Male		homozygous		
F5-II.2	Male				
Family 6		German	c.62_71dup	p.(Gly25Argfs*74)	No
F6-II.1	Male		homozygous		

single radiologist (J.S.K.). For grading of fatty infiltration a modified Mercuri scale was used (1: no fatty atrophy to 4: >60% fatty atrophy; Schlaeger *et al.*, 2018). For grading of oedema the Morrow scale was used (1: no oedema to 4: severe intramuscular oedema; Morrow *et al.*, 2013). Brain MRIs performed at different centres were available from three patients. Muscle biopsies were available from three patients. Cryosectioning and staining were performed according to standard protocols. Evaluation was performed by two co-authors who are experts in histological examination of muscle biopsies (M.V. and I.S.). Transmission electron microscopy of glutaraldehyde-fixed, resin-embedded muscle tissue of one individual was performed as described previously (Goswami *et al.*, 2015). EMG was performed in seven patients and nerve conduction studies in 10 patients in different centres using standard methods.

Data availability

The data that support the findings of this study are available from the corresponding author, upon reasonable request. Human variants and phenotypes have been deposited in the ClinVar database (www.ncbi.nlm.nih.gov/clinvar) under the submission reference SUB6915912.

Results

Exome analysis

In Patient F1-II.2, based on the reported consanguinity of the parents and autosomal recessive pattern of inheritance, we prioritized homozygous non-synonymous variants with a minor allele frequency (MAF) $<$ 0.1% in the Genome Aggregation Database [gnomAD (11/2019)] and our in-house databases containing ~19 700 exomes. The homozygous deletion c.252del [p.Glu85Serfs58*] (GeneBank: NM_022834.4) in *VWA1* (MIM: 611901) was considered a good candidate because of its predicted truncating nature and expression in peripheral nerve and muscle tissue. Moreover, the same filtering strategy lead us to the identification of compound heterozygous truncating variants (c.62_71dup; c.94C>T, [p.Gly25Argfs*74]; [p.Arg32*]) in another similarly affected individual (Patient F2-II.1). A subsequent search for bi-allelic *VWA1* variants in a cohort of individuals with neuromuscular disorders unsolved after exome sequencing based on scientific collaboration (Family F3) or diagnostic routine exome sequencing (Families F4–F6) identified different pathogenic variants in an additional 10 affected individuals from four families. No additional candidate variants in genes known to be associated with neurological or muscular disorders (either recessive or dominant) were identified in the exome datasets of investigated individuals. Sanger sequencing showed full segregation in all available healthy and affected family members and that variants were bi-allelic (Fig. 1).

All six identified variants are either absent or very rare (MAF $<$ 0.001) in gnomAD (Supplementary Table 1). None of the variants have been reported in a homozygous state in gnomAD or our in-house databases containing >19 700 exome datasets of individuals with unrelated phenotypes. Furthermore, no homozygous loss-of-function *VWA1* variants were observed in gnomAD (v.2.1.1 and v.3).

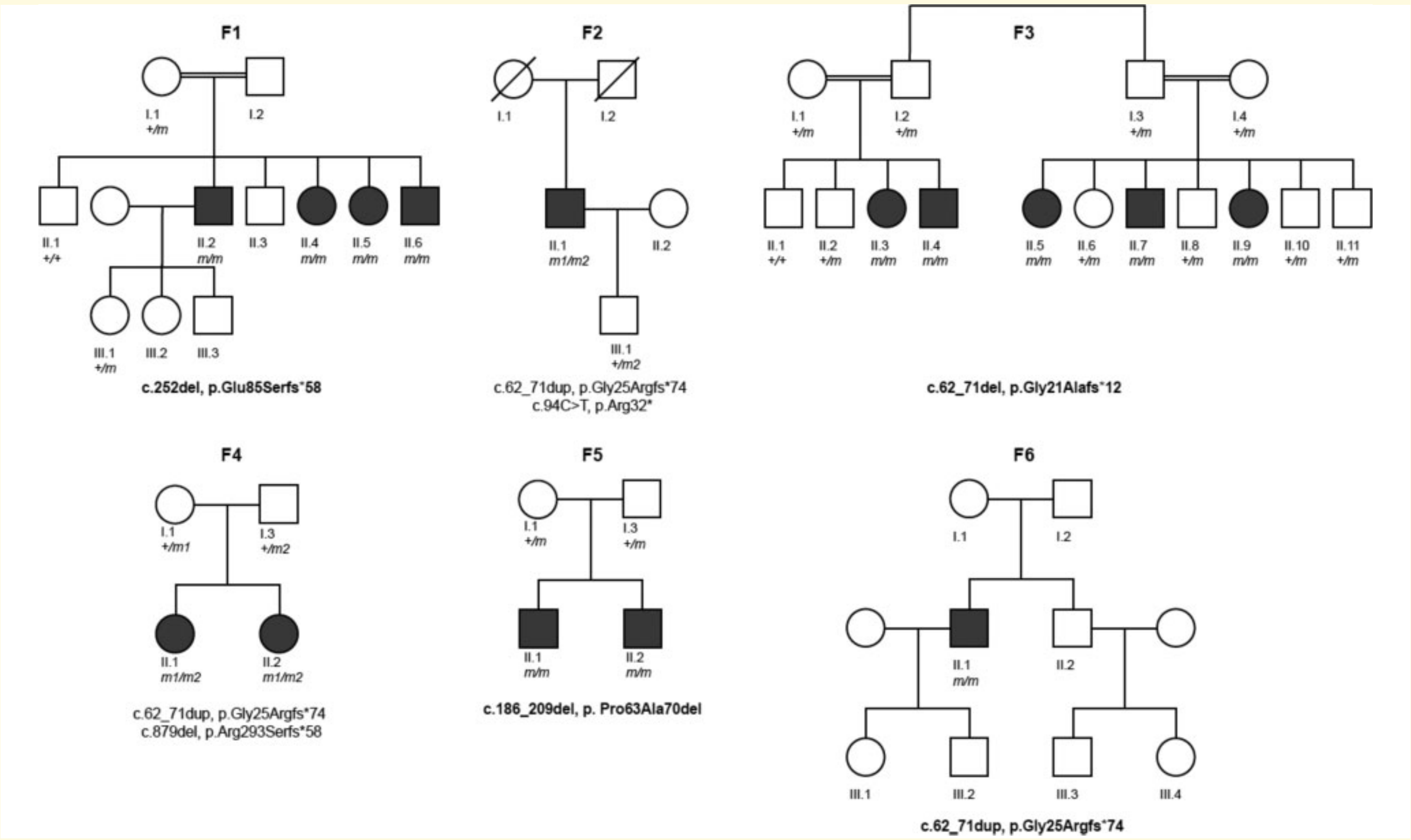
F1
I.1 +/m
I.2
II.1 +/+
II.2 m/m
II.3
II.4 m/m
II.5 m/m
II.6 m/m
III.1 +/m
III.2
III.3
c.252del, p.Glu85Serfs*58
F2
I.1
I.2
II.1 m1/m2
II.2
III.1 +/m2
c.62_71dup, p.Gly25Argfs*74
c.94C>T, p.Arg32*
F3
I.1 +/m
I.2 +/m
I.3 +/m
I.4 +/m
II.1 +/+
II.2 +/m
II.3 m/m
II.4 m/m
II.5 m/m
II.6 +/m
II.7 m/m
II.8 +/m
II.9 m/m
II.10 +/m
II.11 +/m
c.62_71del, p.Gly21Alafs*12
F4
I.1 +/m1
I.3 +/m2
II.1 m1/m2
II.2 m1/m2
c.62_71dup, p.Gly25Argfs*74
c.879del, p.Arg293Serfs*58
F5
I.1 +/m
I.3 +/m
II.1 m/m
II.2 m/m
c.186_209del, p. Pro63Ala70del
F6
I.1
I.2
II.1 m/m
II.2
III.1
III.2
III.3
III.4
c.62_71dup, p.Gly25Argfs*74

Figure 1 Pedigrees of investigated families. Pedigrees of six families with bi-allelic variants in *VWA1* in affected individuals. Filled black symbols = affected individuals; crossed symbols = deceased individual. Variants in *VWA1* are presented below pedigrees. Homozygous variants are presented in bold (*m* in the pedigrees). Compound heterozygous mutations are presented in two rows (first row, *m1* in the pedigrees and second row, *m2* in the pedigrees).

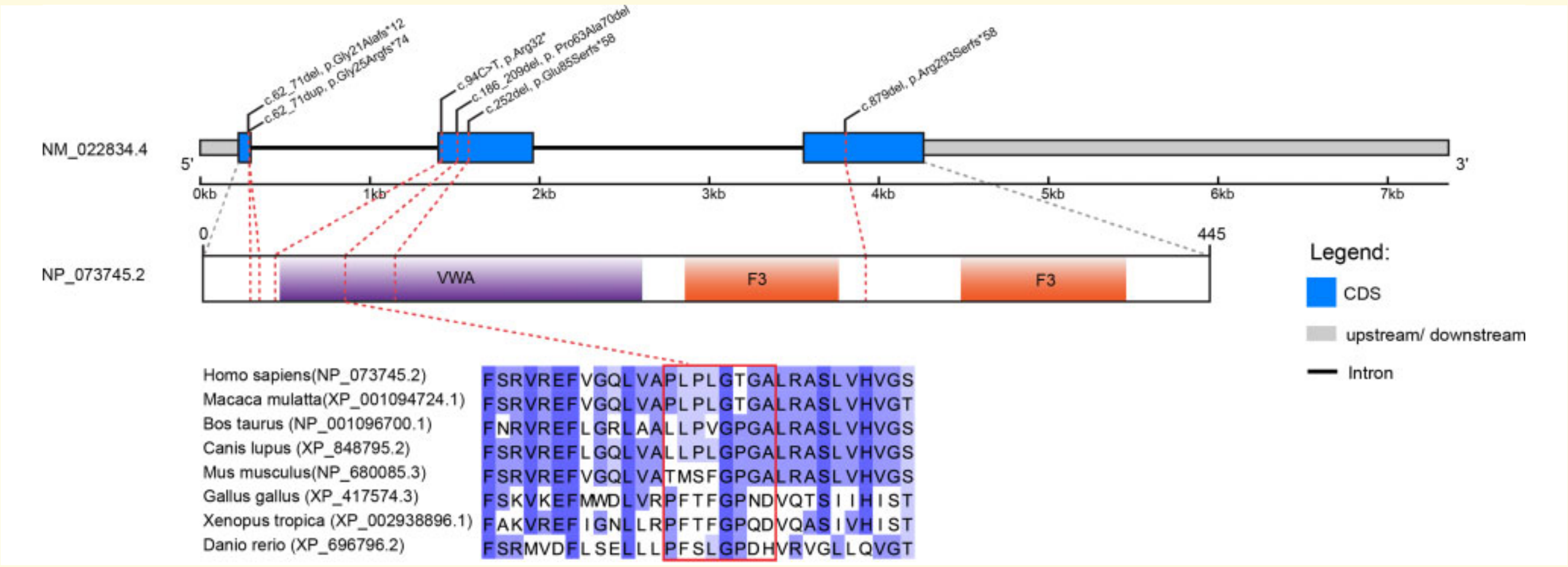
c.62_71del, p.Gly21Alafs*12
c.62_71dup, p.Gly25Argfs*74
c.94C>T, p.Arg32*
c.186_209del, p. Pro63Ala70del
c.252del, p.Glu85Serfs*58
c.879del, p.Arg293Serfs*58
NM_022834.4
5'
3'
0kb
1kb
2kb
3kb
4kb
5kb
6kb
7kb
0
445
NP_073745.2
VWA
F3
F3
Legend:
CDS
upstream/ downstream
Intron
Homo sapiens(NP_073745.2) FSRVREFVGQLVAPLPLGTGALRASLVHVGS
Macaca mulatta(XP_001094724.1) FSRVREFVGQLVAPLPLGTGALRASLVHVGT
Bos taurus (NP_001096700.1) FNRVREFLGRLAALLPVGPGALRASLVHVGS
Canis lupus (XP_848795.2) FSRVREFLGQLVALLPLGPGALRASLVHVGS
Mus musculus(NP_680085.3) FSRVREFVGQLVATMSFGPGALRASLVHVGS
Gallus gallus (XP_417574.3) FSKVKEFMWDLVRPFTFGPNDVQTSIIHIST
Xenopus tropica (XP_002938896.1) FAKVREFIGNLLRPFTFGPQDVQASIVHIST
Danio rerio (XP_696796.2) FSRMVDFLSELLLPFSLGPDHVRVGLLQVGT

Figure 2 Variants in *VWA1*. Structure of *VWA1* (*top*) and VWA1 (*bottom*) with protein domains and motifs (predicted by PFAM; El-Gebali *et al.*, 2019) of the gene product and position of the identified variants. Conservation of the amino acids across different species that are deleted due to the c.186_209del [p.Pro63Ala70del] variant.

Five of the six identified variants are predicted loss of function variants due to a premature termination of protein translation. One variant c.186_209del [p.Pro63Ala70del] is an in-frame deletion resulting in a deletion of eight amino acids within the VWA1 domain. One of these amino acids, the glycine at position 67, is highly conserved across different species including *Xenopus tropica* and *Danio rerio* (Fig. 2).

A 10-bp tandem repeat is located in exon 1 of *VWA1*. This repeat is duplicated in one variant (c.62_71dup [p.Gly25Argfs*74]) and deleted in another variant (c.62_71del [p.Gly21Alafs*12]). Interestingly, the duplication was detected in three independent German families, either in homozygous state (Family F6) or in compound heterozygosity with other loss of function variants (Families F2 and F4), which initially raised the possibility of a founder mutation. However, analysis of the respective exomes did not reveal shared rare variants in direct proximity to the duplication. Among the identified *VWA1* variants the duplication is the most frequent variant in gnomAD v.3.0 (11/2019) with a MAF of 0.06%. Both, the duplication and the deletion are present in different populations (European, Latino, African, South Asian, Ashkenazi Jewish). We therefore hypothesize that this tandem repeat is prone to *de novo* alterations and that the variants have occurred independently of one another.

The parents of the affected individuals of Families 1 and 3 were reportedly consanguineous resulting in homozygous state of the *VWA1* variant in the affected family members. In Family 5 the homozygous *VWA1* variant c.186_209del, which was not present in gnomAD, is located within a 5.6 Mb run of homozygosity indicative for a distant relatedness of the parents.

RNA sequencing

Analysis of *VWA1* mRNA in RNA-seq data from Patient F5-II.1 showed the presence of the in-frame deletion c.186_209del in the transcript. No significant changes ($z = 0.8$) were observed in overall *VWA1* transcript expression levels compared to controls. In contrast, the position of the frameshift variant c.252del was not covered in the RNA-seq data of Patient F1-II.2 due to significantly reduced ($z = -1.7$) expression level of the *VWA1* transcript. This observation is in line with a partial nonsense-mediated mRNA decay (Supplementary Fig. 1). Differential expression analyses did not reveal transcriptome-wide significant changes pointing towards pathway-specific alterations or changes in the expression levels of postulated interaction partners of the VWA1 protein.

Clinical characteristics

Neurological examination

Fifteen affected individuals from six independent families of German, Arabic, and Roma origin were identified. Phenotypic details are summarized in Table 2 and Supplementary Table 2. Clinical onset varied substantially ranging from age 2 years to 54 years with weakness in the lower limbs affecting proximal and distal muscles as first symptom. There was prominent weakness of foot extension with difficulties of standing on heels in all patients. In addition, three individuals showed proximal arm muscle weakness. Muscle atrophy was prominent in lower legs in four individuals only (illustrated in Patient F5-II.2 in Fig. 3). Congenital or early childhood foot deformities were reported in 11 of 15 cases (illustrated in six individuals in Fig. 3). Three individuals received operative extensions of the Achilles tendon (illustrated in Patients F4-II.2 and F3-II.7 in Fig. 3). Sensory symptoms or signs were absent. No clinical signs of CNS involvement were observed.

Histological examination of muscle biopsies

Muscle biopsies of three individuals (Patients F1-II.2, F2-II.1, and F5-II.1) revealed myopathic changes (increased fibre size variation and increase of internalized nuclei) in tibialis anterior, biceps brachii and gastrocnemius muscle, respectively (illustrated in haematoxylin and eosin staining in Fig. 4A–C). In the biopsy of Patients F1-II.2 and F5.II.1, neurogenic changes were also observed (ATPase staining Fig. 4D and F). A report of an additional biopsy of the quadriceps muscle of Patient F2-II.1 also revealed a mixture of myopathic and neurogenic changes. Electron microscopy of the muscle biopsy of Patient F1-II.2 revealed groups of mitochondria with paracrystalline osmiophilic inclusions in several muscle fibres (Fig. 4G). There were no disruptions of the continuity of muscle fibre basal laminae or other overt alterations of the endomysial extracellular matrix (Fig. 4I). However, several muscle fibres showed invaginations of the sarcolemma that were not associated with myotendinous junctions (Fig. 4I).

Neurophysiological examination

EMG revealed abnormal motor unit action potentials in six of seven patients showing a mixed myopathic and neurogenic pattern. Myopathic changes were prominent in proximal muscles whereas chronic neurogenic changes were dominant in distal muscles. Fibrillations were present in six of seven patients. Nerve conduction studies revealed diminished motor amplitudes at the legs in 6 of 10 patients with normal or mildly reduced velocities (Supplementary Table 2). Sensory potentials of sural nerves were normal in four of seven patients. In two patients, amplitudes were mildly reduced and in Patient F2-II.1 who suffered from insulin-dependent diabetes for many years no stimulus response was observed (Supplementary Table 2).

Magnetic resonance examination

Fatty degeneration in upper and lower legs was observed in all seven investigated individuals. Intriguingly, muscle MRI of lower limbs showed a rather uniform pattern with predominant affection of the vastus (medialis/lateralis/intermedius) and the gastrocnemius (medial more than lateral head) as well as the peroneal muscles. In more advanced stages, also the tibialis anterior, semimembranosus, semitendinosus, and biceps femoris muscles were severely affected. All patients showed a relative sparing of the gracilis, sartorius, and soleus muscles (Supplementary Table 2). In Patient F5-II.2 a sandwich sign in the vastus laterals muscles was observed (Fig. 5). Brain MRI was performed in three individuals (Patients F2-II.1, F4-II.2 and F6-II.1) and was normal.

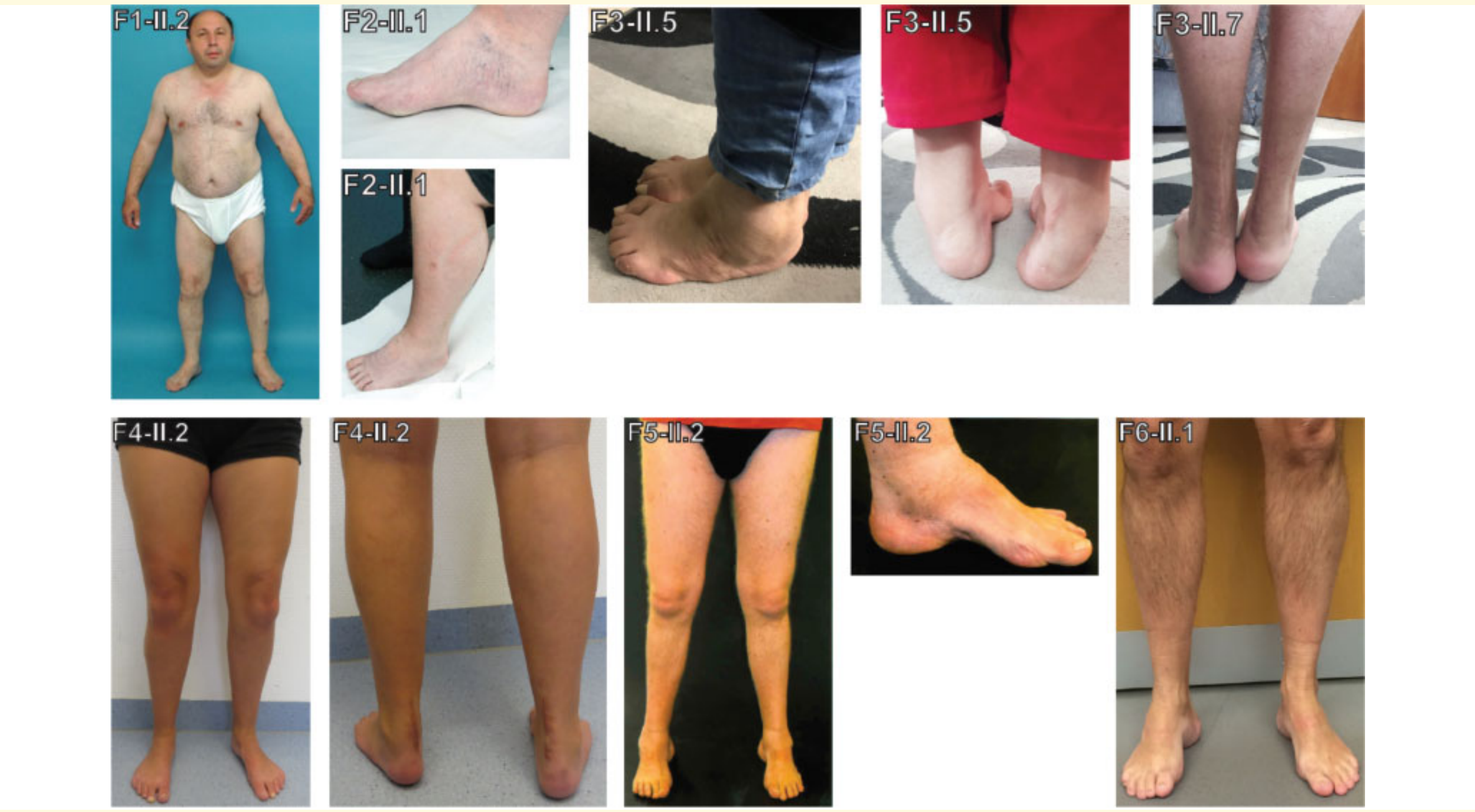

Figure 3 Phenotypic findings illustrated by photos of patients. Images of affected individuals showing foot deformities with pes cavus in Patients F2-II.1, F4-II.2, F5-II.1 and F6-II.1, pes equinovarus in Patient F3-II.5, surgically corrected pes equinovarus in Patient F3-II.7 and Achilles tendon lengthening in Patients F4-II.2 and F3-II.7. Lower leg atrophy can be clearly seen in Patient F5-II.2.

Discussion

We have identified truncating bi-allelic variants in *VWA1* in six families with a so far genetically unidentified neuromuscular disorder with autosomal recessive inheritance. All variants are very rare in control data bases and they segregated with the disease in our families.

VWA1 is located on chromosome 1p36.33 and codes for the 445 amino acids of the VWA1 protein (also known as WARP) which is a member of the von Willebrand factor A domain (VWFA) protein superfamily containing a VWA-domain followed by two fibronectin III repeats (Fitzgerald *et al.*, 2002) (Fig. 1B). Human VWA1 (NP_073745.2) and mouse (NP_680085.3) protein are 75.3% identical. A reporter gene knock-in mouse model showed that VWA1 is a component of basement membranes in several tissues including muscle and vasculature of CNS and endoneurium of peripheral nerves. Interaction of VWA1 with collagen VI and perlecan was identified leading to the hypothesis that VWA1 functions in establishing or maintaining the blood–brain barrier and blood–neural barrier (Allen *et al.*, 2008). Pathogenic variants in collagen genes (*COL6A1*, *COL6A2*, *COL6A3*, and *COL12A1*) (Mohassel *et al.*, 2018) and in the perlecan gene *HSPG2* (Nicole *et al.*, 2000) cause well-known neuromuscular disorders such as congenital myopathies type Bethlem/Ullrich and Schwarz-Jampel syndrome, indicating this pathway as highly relevant for neuromuscular diseases. Electron microscopy of muscle performed in one of our patients showed paracrystalline inclusions in the mitochondria, a finding that can also be observed in collagen VI-related myopathies (Mohassel *et al.*, 2018). However, no changes of muscle fibre basal laminae were observed. A sandwich sign that is typically observed in collagen VI myopathies in muscle MRI (Mohassel *et al.*, 2018) was present in one of our patients only. Our first RNA-seq-based studies performed on patient-derived fibroblast cell lines established from two patients did not indicate a significant alteration of the proteins that a relevant in the basement membranes. However, these preliminary results are of limited significance because of the small sample size ($n = 2$) and the fact that fibroblast cell lines might not represent a suitable model system for a disease phenotype predominantly affecting neuronal and/or muscle cells.

In another mouse model with VWA1-null mutation motor function and behavioural testing showed significantly delayed response to acute painful stimulus and impaired fine motor coordination suggesting compromised peripheral nerve function. Immunostaining of VWA1-interacting ligands showed that collagen VI microfibrillar matrix was severely reduced and mislocalized in peripheral nerves. Ultrastructural analysis revealed reduced fibrillar collagen deposition within the peripheral nerve extracellular matrix and abnormal partial fusing of adjacent Schwann-cell basement membranes. However, there were no abnormalities reported in muscle (Allen *et al.*, 2009).

The phenotype of the affected individuals reported in this study was characterized by muscle weakness affecting

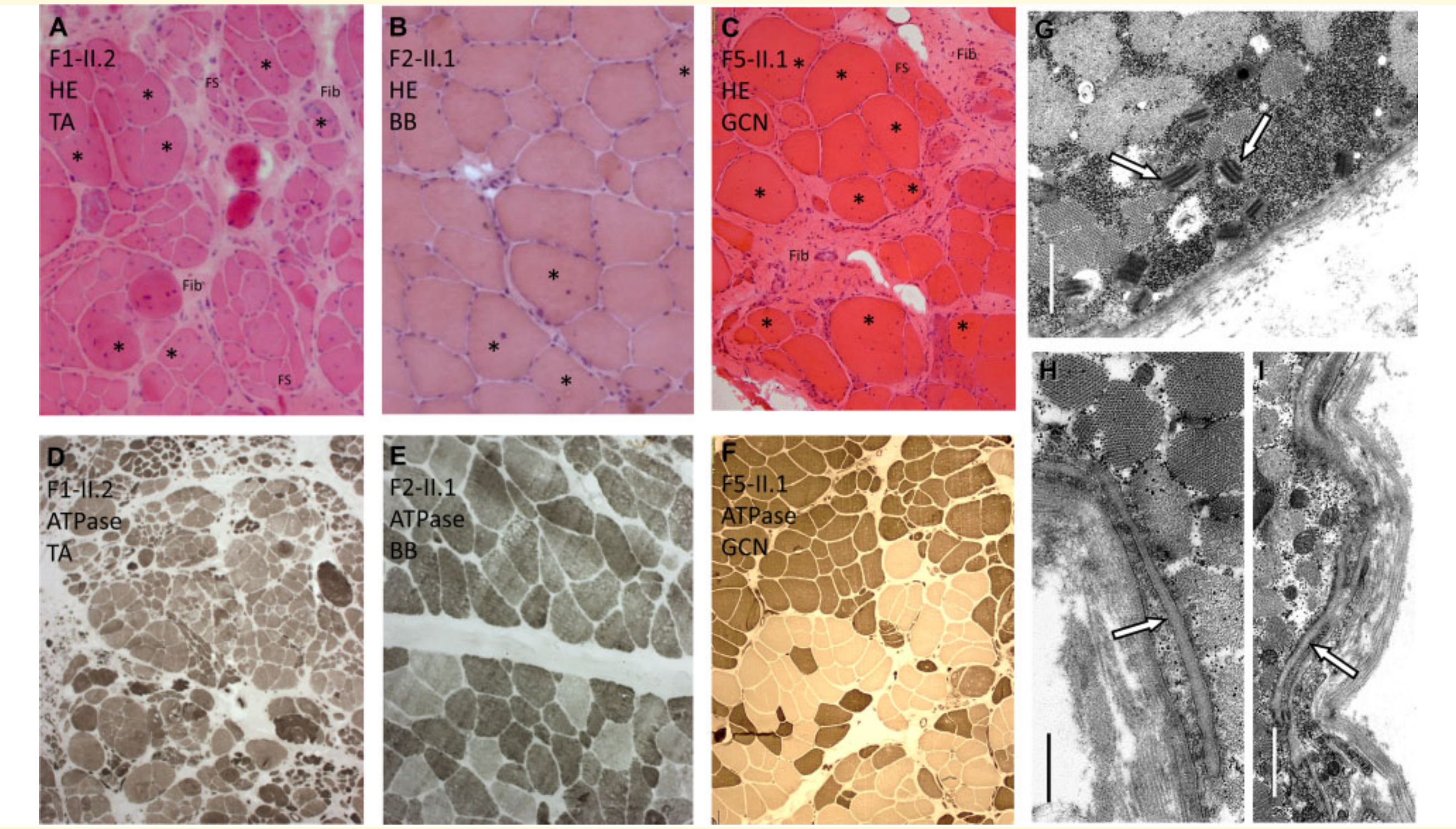

Figure 4 Muscle biopsy findings. (**A**–**C**) Haematoxylin and eosin stainingand (**D**–**F**) ATPase stainingof muscle biopsies in Patients F1-II.2, F2.II.1 and F5-II.1 are shown. (**G**–**I**) Electron microscopy of the muscle biopsy in Patient F1-II.2 is demonstrated. (**A**) Patient F1-II.2: tibialis anterior muscle (TA) showing severely increased fibre size variation, increase of internalized nuclei (asterisk), regenerative changes with whorled fibres (WF), fibre splitting (FS) and increased endomysial and perimysial fibrosis (Fib). (**B**) Patient F2-II.1: biceps brachii muscle (BB) showing mild increase of fibre size variation and of internalized nuclei (asterisk). (**C**) Patient F5-II.1: Gastrocnemius muscle (GCN) showing severely increased fibre size variation, increase of internalized nuclei (asterisk) and increased endomysial and perimysial fibrosis (Fib). (**D**) Patient F1-II.2: ATPase staining demonstrating grouping of atrophic fibres and fibre types indicating neurogenic changes. (**E**) Patient F2-II.1: ATPase staining demonstrating only mild fibre type grouping. (**F**) Patient F5-II.1: ATPase staining demonstrating fibre type grouping. (**G**) Electron microscopy shows osmiophilic paracrystalline inclusions (arrows) in several muscle fibre mitochondria (Scale bar = 1.5 μm). (**H**) No apparent focal disruptions of muscle fibre basal lamina (arrow) integrity was observed (Scale bar = 0.8 μm), but (**I**) invaginations of the sarcolemma (arrow) are seen (Scale bar = 1.5 μm).

primary foot extension in nearly all individuals, a finding compatible with motor neuropathy. Foot deformities were frequently present, a typical sign in hereditary neuromuscular disorders. Some patients showed pes cavus typically observed in hereditary neuropathies. Other patients showed pes equinovarus that can be observed in certain neuropathies (e.g. TRPV4 and GDAP1 related) and myopathies (e.g. GMPPB and LMNA related), sometimes with congenital onset overlapping with distal arthrogryposis (Senderek *et al.*, 2003; Quijano-Roy *et al.*, 2008; Evangelista *et al.*, 2015; Astrea *et al.*, 2018). Additionally, proximal muscle weakness was observed in most individuals being a typical myopathic sign. EMG showed mixed myopathic and neurogenic changes. Reduced amplitudes in motor nerve conduction studies correlated with neurogenic changes in EMG indicating axonal neuropathy or motor neuron affection. Muscle biopsies of affected individuals demonstrated myopathic changes and also neurogenic changes in two individuals. Together, our observations argue that the muscular phenotype associated with loss of VWA1 function likely arises from neurogenic as well as myopathic damage and can be accordingly designated as neuromyopathy.

Several other examples for neurogenic and myopathic changes being present in the same affected individual have been reported rendering hereditary neuromyopathies an increasingly recognized disease entity. Mutations in the bicaudal Drosophila homologue 2 [*BICD2* (MIM: 609797)] were first described in autosomal dominant spinal muscular atrophy with predominant lower limb weakness and hereditary spastic paraplegia (MIM: 61529). In some individuals myopathic changes were observed in EMG in addition to myohistologically confirmed neurogenic and myopathic changes (Unger *et al.*, 2016; Bugiardini *et al.*, 2019). Mutations in the genes coding small heat-shock 27-kD protein 1 and 8 [*HSPB1* (MIM: 602195) and *HSPB8* (MIM: 608014)] were initially identified in individuals with autosomal dominant distal hereditary motor neuropathy (dHMN). Subsequently individuals with *HSPB1* and *HSPB8* mutations were found

Table 2 **Phenotypic features in individuals with bi-allelic VWA1 variants**

ID	Age of weakness onset, years	Current age, years	First symptom[a]	Muscle weakness[b]						Foot deformities
				Upper legs		Lower legs		Arms		
				Ant.	Post.	Ant.	Post.	Prox.	Dist.	
Family 1										
F1-II.2	43	64	Leg weakness	4/5	4/5	2–3/5	4/5	4/5	4/5	No
F1-II.4	54	60	Leg weakness	5/5	5/5	4/5	5/5	5/5	5/5	No
F1-II.5	46	53	Leg weakness	5/5	5/5	4/5	5/5	5/5	5/5	No
F1-II.6	41	46	Leg weakness	4/5	3/5	4/5	4/5	4/5	5/5	No
Family 2										
F2-II.1	13	46	Leg weakness	4/5	4/5	0/5	4/5	4/5	4/5	Bilateral pes cavus
Family 3										
F3-II.3	3	11	Leg weakness	5/5	5/5	4/5	5/5	5/5	5/5	Bilateral pes cavus
F3-II.4	6	9	Leg weakness	4/5	5/5	3/5	4/5	5/5	5/5	Bilateral pes cavus
F3-II.5	3	34	Leg weakness	ND						Bilateral congenital pes equinovarus
F3-II.7	2	30	Leg weakness	ND						Bilateral congenital pes equinovarus
F3-II.9	18	25	Leg weakness	ND						Bilateral pes cavus
Family 4										
F4-II.1	2	17	Delayed start of walking	5/5	5/5	4/5	5/5	5/5	5/5	Bilateral congenital pes equinovarus
F4-II.2	3	13	Gait difficulty	5/5	5/5	4/5	5/5	5/5	5/5	Bilateral pes equinus
Family 5										
F5-II.1	School age	45	Leg weakness	4/5	4/5	5/5	5/5	5/5	5/5	Bilateral pes cavus
F5-II.2	School age	44	Leg weakness	5/5	5/5	1–2/5	2–3/5	5/5	5/5	Bilateral pes cavus
Family 6										
F6-II.1	40	44	Leg weakness	5/5	5/5	4/5R, 5/5L	5/5	5/5	5/5	Bilateral congenital pes cavus

Additional phenotypic features and results of instrumental examinations are listed in Supplementary Table 2. Ant. = anterior; Dist. = distal; ND = not done; Post. = posterior; Prox. = proximal.

[a] Apart from foot deformities.

[b] Medical research council (MRC) scale.

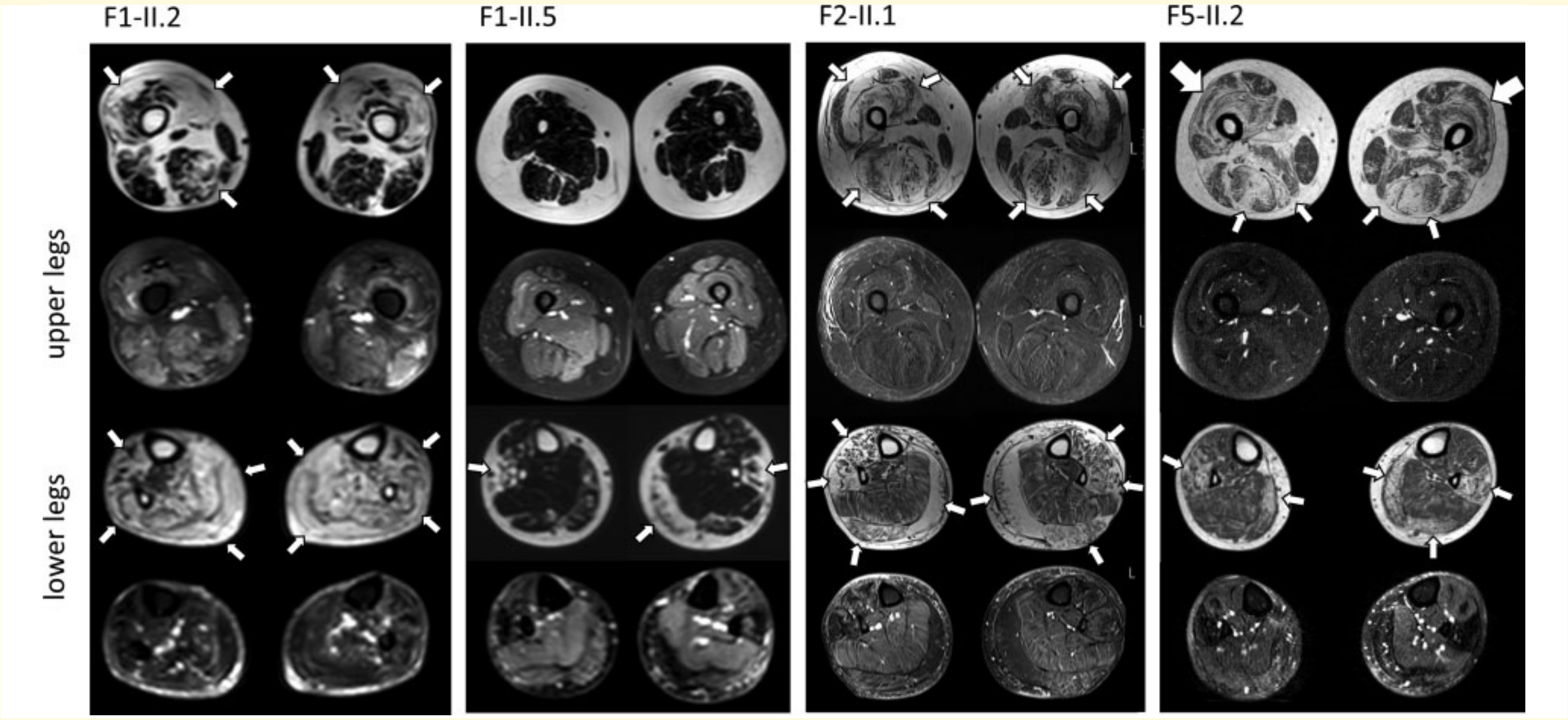

Figure 5 **Muscle MRI findings.** MRI of the legs demonstrates fatty degeneration (thin arrows) of muscle in Patients F1-II.2, F1-II.5, F2-II.1, and F5-II.2. There is predominant affection of the vastus and the medial head of the gastrocnemius as well as the peroneal muscles. A 'sandwich sign' (thick arrows) in the vastus lateralis muscles was present in Patient F5-II.2.

to have a coexisting neuropathy and distal myopathy (Ghaoui *et al.*, 2016; Lewis-Smith *et al.*, 2016; Bugiardini *et al.*, 2017; Cortese *et al.*, 2018). Furthermore, a pathogenic variant in mitofusin 2 [*MFN2* (MIM: 608507)] was identified in an individual with neuromyopathy (Bugiardini *et al.*, 2019). There is the remaining possibility that secondary myopathic changes are observed in a neurogenic process, and *vice versa* EMG can appear neurogenic in a chronic end-stage myopathy. However, in the affected individuals reported in this manuscript coexisting myopathic and neurogenic changes were observed early in the disease course. Our findings support the notion that separation of clinical entities into either nerve or muscle damage may not be appropriate in certain neuromuscular disorders.

There is striking variability of age of onset of the affected individuals not only between the families but also within family F3. Onset in childhood was present in Families F2–F5 whereas adult-onset was observed in Families F1 and F6. In hereditary neuromuscular disorders variable age of onset not explained by the gene defect is sometimes observed. For example, in patients with late-onset Pompe disease bearing similar acid α-glucosidase genotypes onset can range from <1 year to 52 years (Kroos *et al.*, 2007). In our families we did not identify additional variants that are likely to act as disease modifiers in other genes such as collagen VI genes that are known to interact with VWA1.

In conclusion, we provide compelling evidence that bi-allelic truncating *VWA1* variants are the disease-causing molecular defect of a neuromuscular disorder with autosomal recessive inheritance. Findings of muscle biopsies and needle EMG revealed neurogenic and myopathic changes indicating a neuromyopathy. Genetic testing of *VWA1* should be included in the diagnostic work-up of individuals presenting with progressive muscle weakness primarily affecting proximal and distal muscles of the legs, and also in neuromuscular disorders with foot deformities.

Web resources

The URLs for the data presented herein are:
gnomAD server, https://gnomad.broadinstitute.org
Online Mendelian Inheritance in Man (OMIM), https://omim.org/

Acknowledgements

We thank all the families for their participation. We thank Dr Sarah Bublitz for support with the clinical examination, Prof. Gisela Stoltenburg-Didinger for help with myopathological investigations, and Dr Leila Scholle for providing fibroblasts of one patient. We thank Melanie Kraft, Claudia Bauer, Karin Hamann and Beate Kootz for excellent technical assistance. We thank Mrs E. Beck and Dr I. Katona for support with electron microscopy.

Funding

H.H. was supported by the intramural fortüne program (#2554-0-0). T.B.H. was supported by the German Bundesministerium für Bildung und Forschung (BMBF) through the Juniorverbund in der Systemmedizin “mitOmics” (FKZ 01ZX1405C to T.B.H.), the intramural fortüne program (#2435-0-0) and by the Deutsche Forschungsgemeinschaft (DFG, German Research Foundation – Projektnummer 418081722). C.K., H.H., and L.S. are members of the European Reference Network for Rare Neurological Diseases (ERN-RND), project ID 739510.

Competing interests

The authors report no competing interests.

Supplementary material

Supplementary material is available at *Brain* online.

References

Allen JM, Brachvogel B, Farlie PG, Fitzgerald J, Bateman JF. The extracellular matrix protein WARP is a novel component of a distinct subset of basement membranes. Matrix Biol 2008; 27: 295–305.

Allen JM, Zamurs L, Brachvogel B, Schlötzer-Schrehardt U, Hansen U, Lamandé SR, et al. Mice lacking the extracellular matrix protein WARP develop normally but have compromised peripheral nerve structure and function. J Biol Chem 2009; 284: 12020–30.

Astrea G, Romano A, Angelini C, Antozzi CG, Barresi R, Battini R; the Italian CMD Network, et al. Broad phenotypic spectrum and genotype-phenotype correlations in GMPPB-related dstroglycanopathies: an Italian cross-sectional study. Orphanet J Rare Dis 2018; 13: 170.

Benarroch L, Bonne G, Rivier F, Hamroun D. The 2020 version of the gene table of neuromuscular disorders (nuclear genome). Neuromuscul Disord 2020; 29: 980–1018.

Bugiardini E, Rossor AM, Lynch DS, Swash M, Pittman AM, Blake JC, et al. Homozygous mutation in hspb1 causing distal vacuolar myopathy and motor neuropathy. Neurol Genet 2017; 3: e168.

Bugiardini E, Khan AM, Phadke R, Lynch DS, Cortese A, Feng L, et al. Genetic and phenotypic characterisation of inherited myopathies in a tertiary neuromuscular centre. Neuromuscul Disord 2019; 29: 747–57.

Cortese A, Laura M, Casali C, Nishino I, Hayashi YK, Magri S, et al. Altered TDP-43-dependent splicing in HSPB8-related distal hereditary motor neuropathy and myofibrillar myopathy. Eur J Neurol 2018; 25: 154–63.

Cummings BB, Marshall JL, Tukiainen T, Lek M, Donkervoort S, Foley AR, et al. Improving genetic diagnosis in Mendelian disease with transcriptome sequencing. Sci Transl Med 2017; 9: eaal5209. doi: 10.1126/scitranslmed.aal5209.

El-Gebali S, Mistry J, Bateman A, Eddy SR, Luciani A, Potter SC, et al. The Pfam protein families database in 2019. Nucleic Acids Res 2019; 47: D427–32.

Evangelista T, Bansagi B, Pyle A, Griffin H, Douroudis K, Polvikoski T, et al. Phenotypic variability of TRPV4 related neuropathies. Neuromuscul Disord 2015; 25: 516–21.

Fitzgerald J, Ting ST, Bateman JF. WARP is a new member of the von Willebrand factor A-domain superfamily of extracellular matrix proteins. FEBS Lett 2002; 517: 61–6.

Fritzen D, Kuechler A, Grimmel M, Becker J, Peters S, Sturm M, et al. De novo FBXO11 mutations are associated with intellectual disability and behavioural anomalies. Hum Genet 2018; 137: 401–11.

Ghaoui R, Palmio J, Brewer J, Lek M, Needham M, Evila A, et al. Mutations in HSPB8 causing a new phenotype of distal myopathy and motor neuropathy. Neurology 2016; 86: 391–8.

Goswami A, Jesse CM, Chandrasekar A, Bushuven E, Vollrath JT, Dreser A, et al. Accumulation of STIM1 is associated with the degenerative muscle fibre phenotype in ALS and other neurogenic atrophies. Neuropathol Appl Neurobiol 2015; 41: 304–18.

Haack TB, Hogarth P, Kruer MC, Gregory A, Wieland T, Schwarzmayr T, et al. Exome sequencing reveals de novo WDR45 mutations causing a phenotypically distinct, X-linked dominant form of NBIA. Am J Hum Genet 2012; 91: 1144–9.

Krenn M, Tomschik M, Rath J, Cetin H, Grisold A, Zulehner G, et al. Genotype-guided diagnostic reassessment after exome sequencing in neuromuscular disorders: experiences with a two-step approach. Eur J Neurol 2020; 27: 51–61.

Kroos MA, Pomponio RJ, Hagemans ML, Keulemans JL, Phipps M, DeRiso M, et al. Broad spectrum of Pompe disease in patients with the same c.-32-13T->G haplotype. Neurology 2007; 68: 110–5.

Kuhn M, Glaser D, Joshi PR, Zierz S, Wenninger S, Schoser B, et al. Utility of a next-generation sequencing-based gene panel investigation in German patients with genetically unclassified limb-girdle muscular dystrophy. J Neurol 2016; 263: 743–50.

Lewis-Smith DJ, Duff J, Pyle A, Griffin H, Polvikoski T, Birchall D, et al. Novel HSPB1 mutation causes both motor neuronopathy and distal myopathy. Neurol Genet 2016; 2: e110.

McCarthy DJ, Chen Y, Smyth GK. Differential expression analysis of multifactor RNA-seq experiments with respect to biological variation. Nucleic Acids Res 2012; 40: 4288–97.

Milone M, Liewluck T. The unfolding spectrum of inherited distal myopathies. Muscle Nerve 2019; 59: 283–94.

Mohassel P, Foley AR, Bonnemann CG. Extracellular matrix-driven congenital muscular dystrophies. Matrix Biol 2018; 71-72: 188–204.

Morrow JM, Matthews E, Raja Rayan DL, Fischmann A, Sinclair CD, Reilly MM, et al. Muscle MRI reveals distinct abnormalities in genetically proven non-dystrophic myotonias. Neuromuscul Disord 2013; 23: 637–46.

Nicole S, Davoine CS, Topaloglu H, Cattolico L, Barral D, Beighton P, et al. Perlecan, the major proteoglycan of basement membranes, is altered in patients with Schwartz-Jampel syndrome (chondrodystrophic myotonia). Nat Genet 2000; 26: 480–3.

Quijano-Roy S, Mbieleu B, Bonnemann CG, Jeannet PY, Colomer J, Clarke NF, et al. De novo LMNA mutations cause a new form of congenital muscular dystrophy. Ann Neurol 2008; 64: 177–86.

Robinson MD, McCarthy DJ, Smyth GK. edgeR: a bioconductor package for differential expression analysis of digital gene expression data. Bioinformatics 2010; 26: 139–40.

Schlaeger S, Klupp E, Weidlich D, Cervantes B, Foreman S, Deschauer M, et al. T2-weighted dixon turbo spin echo for accelerated simultaneous grading of whole-body skeletal muscle fat infiltration and edema in patients with neuromuscular diseases. J Comput Assist Tomogr 2018; 42: 574–9.

Senderek J, Bergmann C, Ramaekers VT, Nelis E, Bernert G, Makowski A, et al. Mutations in the ganglioside-induced differentiation-associated protein-1 (GDAP1) gene in intermediate type autosomal recessive Charcot-Marie-Tooth neuropathy. Brain 2003; 126: 642–9.

Unger A, Dekomien G, Guttsches A, Dreps T, Kley R, Tegenthoff M, et al. Expanding the phenotype of BICD2 mutations toward skeletal muscle involvement. Neurology 2016; 87: 2235–43.