

# Two distinct prions in fatal familial insomnia and its sporadic form

Atsuko Takeuchi, Shirou Mohri, Hideaki Kai, Akira Tamaoka, Atsushi Kobayashi, Hidehiro Mizusawa, Yasushi Iwasaki, Mari Yoshida, Hiroshi Shimizu, Shigeo Murayama, Shigetoshi Kuroda, Masanori Morita, Piero Parchi, Tetsuyuki Kitamoto

Accelerating clinical advancements -  
from development to delivery.

DISCOVER MORE

HOUSTON  
**Methodist**<sup>®</sup>  
NEUROLOGICAL INSTITUTE

# BRAIN COMMUNICATIONS

## Two distinct prions in fatal familial insomnia and its sporadic form

 **Atsuko Takeuchi**<sup>1</sup>, **Shirou Mohri**<sup>1</sup>, **Hideaki Kai**<sup>1</sup>, **Akira Tamaoka**<sup>2</sup>, **Atsushi Kobayashi**<sup>3</sup>, **Hidehiro Mizusawa**<sup>4</sup>, **Yasushi Iwasaki**<sup>5</sup>, **Mari Yoshida**<sup>5</sup>, **Hiroshi Shimizu**<sup>6</sup>, **Shigeo Murayama**<sup>7</sup>, **Shigetoshi Kuroda**<sup>8</sup>, **Masanori Morita**<sup>9</sup>,  **Piero Parchi**<sup>10,11</sup> and **Tetsuyuki Kitamoto**<sup>1</sup>

Fatal familial insomnia is a genetic prion disease, which is associated with the aspartic acid to asparagine substitution at codon 178 of the prion protein gene. Although the hallmark pathological feature is thalamic and olivary degeneration, there is a patient with an atypical fatal familial insomnia without the hallmark feature. The cause of the pathological variability is unclear. We analysed a Japanese fatal familial insomnia kindred and compared one atypical clinicopathological fatal familial insomnia phenotype case and typical fatal familial insomnia phenotype cases with transmission studies using multiple lines of knock-in mice and with protein misfolding cyclic amplification. We also analysed the transmissibility and the amplification properties of sporadic fatal insomnia. Transmission studies revealed that the typical fatal familial insomnia with thalamic and olivary degeneration showed successful transmission only using knock-in mice expressing human–mouse chimeric prion protein gene. The atypical fatal familial insomnia with spongiform changes showed successful transmission only using knock-in mice expressing bank vole prion protein gene. Two sporadic fatal insomnia cases with thalamic and olivary degeneration showed the same transmissibility as the typical fatal familial insomnia phenotype. Interestingly, one sporadic fatal insomnia case with thalamic/olivary degeneration and spongiform changes showed transmissibility of both the typical and atypical fatal familial insomnia phenotypes. Protein misfolding cyclic amplification could amplify both typical fatal familial insomnia cases and sporadic fatal insomnia cases but not the atypical fatal familial insomnia phenotype or other sporadic Creutzfeldt–Jakob disease subtypes. In addition to clinical findings and neuropathological features, the transmission properties and the amplification properties were different between the typical and atypical fatal familial insomnia phenotypes. It is suggested that two distinct prions were associated with the diversity in the fatal familial insomnia phenotype, and these two prions could also be detected in sporadic fatal insomnia.

Downloaded from <https://academic.oup.com/braincomms/article/11/fcz045/5670523> by guest on 24 April 2024

- 1 Department of Neurological Science, Tohoku University Graduate School of Medicine, Sendai 980-8575, Japan
- 2 Department of Neurology, Division of Clinical Medicine, Faculty of Medicine, University of Tsukuba, Tsukuba, Ibaraki 305-8576, Japan
- 3 Laboratory of Comparative Pathology, Graduate School of Veterinary Medicine, Hokkaido University, Sapporo 060-0818, Japan
- 4 The National Center Hospital, National Center of Neurology and Psychiatry, Tokyo 102-0076, Japan
- 5 Department of Neuropathology, Institute for Medical Science of Aging, Aichi Medical University, Nagakute, Aichi 480-1195, Japan
- 6 Department of Pathology, Brain Research Institute, University of Niigata, Niigata 951-8585, Japan
- 7 Department of Neurology and Neuropathology (The Brain Bank for Aging Research), Tokyo 173-0015, Japan
- 8 Zikei Hospital, Okayama 702-8508, Japan
- 9 Research and Development Division, Japan Blood Products Organization, Kobe 650-0047, Japan
- 10 Department of Experimental, Diagnostic and Specialty Medicine (DIMES), University of Bologna, Bologna 40126, Italy
- 11 IRCCS Istituto delle Scienze Neurologiche, Bologna 40123, Italy

Correspondence to: Tetsuyuki Kitamoto, Department of Neurological Science, Tohoku University Graduate School of Medicine, 2-1, Seiryomachi, Aoba-ku, Sendai-shi 980-8575, Japan  
E-mail: [kitamoto@med.tohoku.ac.jp](mailto:kitamoto@med.tohoku.ac.jp)

Received September 5, 2019. Revised November 18, 2019. Accepted November 25, 2019. Advance Access publication December 9, 2019

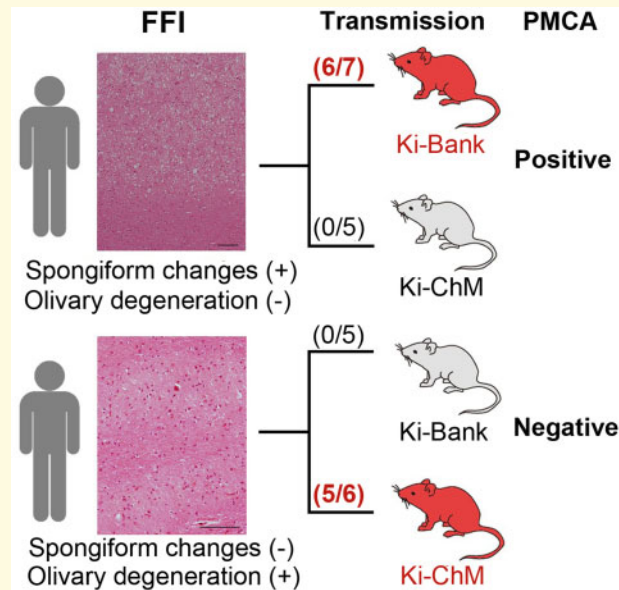
© The Author(s) (2019). Published by Oxford University Press on behalf of the Guarantors of Brain.

This is an Open Access article distributed under the terms of the Creative Commons Attribution Non-Commercial License (<http://creativecommons.org/licenses/by-nc/4.0/>), which permits non-commercial re-use, distribution, and reproduction in any medium, provided the original work is properly cited. For commercial re-use, please contact [journals.permissions@oup.com](mailto:journals.permissions@oup.com)

**Keywords:** fatal familial insomnia; sporadic fatal insomnia; knock-in mouse; transmission study; protein misfolding cyclic amplification

**Abbreviations:** FFI =fatal familial insomnia; lv =large vacuolation; OD =olivary degeneration; PMCA =protein misfolding cyclic amplification; *PRNP* =human prion protein gene; PrP =prion protein; PrP<sup>C</sup> =normal cellular isoform; PrP<sup>Sc</sup> =disease-associated isoform; SC =spongiform changes; sCJD =sporadic Creutzfeldt–Jakob disease; sFI =sporadic fatal insomnia; sv =small vacuolation

### Graphical Abstract



## Introduction

Fatal familial insomnia (FFI) was first described in 1986 in Italy (Lugaresi *et al.*, 1986). This disease was subsequently reported as a genetic prion disease that was linked to the codon 178 point mutation (aspartic acid to asparagine substitution: D178N) of the prion protein gene (*PRNP*) (Medori *et al.*, 1992). Meanwhile, the same D178N mutation has been reported in a subtype of familial Creutzfeldt–Jakob disease (Goldfarb *et al.*, 1991). Goldfarb *et al.* revealed that the phenotypic variability among the patients with the D178N mutation depended on a common polymorphism at *PRNP* codon 129, methionine or valine. The D178N mutation gene coupled with methionine at codon 129 develops FFI, and the D178N mutation gene coupled with valine at codon 129 develops familial Creutzfeldt–Jakob disease (Goldfarb *et al.*, 1992).

The pathological hallmark of the typical FFI phenotype is severe neuronal loss and atrophy in thalamic nuclei and the inferior olivary nucleus. However, atypical FFI cases with predominant lesions in the cerebral cortex, consisting of a spongiform encephalopathy, rather than thalamic degeneration/olivary degeneration (OD), have been reported (McLean *et al.*, 1997; Saitoh *et al.*, 2010). Moreover, FFI cases with conspicuous spongiform

changes (SC) in the cerebral cortex in addition to typical thalamic degeneration/OD have been reported in cases with a relatively long clinical course (i.e. >18 months) (Manetto *et al.*, 1992; Parchi *et al.*, 1995, 1998b; Sasaki *et al.*, 2005). Western blot analysis revealed that non-glycosylated bands of the abnormal form of the prion protein (PrP<sup>Sc</sup>) in patients with the D178N mutation had electrophoretic mobility of 19 kDa (type 2) irrespective of the pathological phenotypic variability. Apart from the clear effect on disease duration of the codon 129 genotype on the wild-type *PRNP* allele (Parchi *et al.*, 1998a, b), the reason for the phenotypic diversity among individuals with the 129M-D178N has not been fully elucidated. Meanwhile, the infectivity of the FFI prion has been examined by transmission studies in animal models (Collinge *et al.*, 1995; Tateishi *et al.*, 1995; Telling *et al.*, 1996; Sasaki *et al.*, 2005).

In this study, we focused on a Japanese FFI kindred with the 129M-D178N genotype showing distinct clinicopathological features, namely atypical FFI without thalamic degeneration/OD and typical FFI (Saitoh *et al.*, 2010). The mother in the kindred showed the atypical FFI phenotype with rapidly progressing dementia. Histopathological examination and immunohistochemical analysis revealed SC throughout the cerebral cortex and a synaptic pattern of PrP deposition, respectively. The type and glycosylation

pattern of accumulated PrP<sup>Sc</sup> were the same as those of typical FFI cases, but a larger amount of PrP<sup>Sc</sup> was detected than in patients with typical FFI. To explore the possible involvement of multiple prions in the phenotypic variability of 129M-D178N, we carried out experimental transmissions of prions from the kindred using multiple lines of knock-in mice. Challenges with knock-in mice expressing bank vole PrP with M109 (Ki-Bank) (Kobayashi *et al.*, 2019b) or knock-in mice expressing human-mouse chimeric PrP (Ki-ChM) (Taguchi *et al.*, 2003) revealed that the transmissibility varied between FFI phenotypes. We also found that typical FFI prions but not the atypical FFI prion could be amplified efficiently with protein misfolding cyclic amplification (PMCA) using recombinant cellular prion protein (PrP<sup>C</sup>) as a substrate (cell-PMCA). Moreover, we analysed the transmissibility and the amplification property of the thalamic form of sporadic Creutzfeldt–Jakob disease (sCJD-MM2T) because sCJD-MM2T was recognized as sporadic fatal insomnia (sFI) due to the involvement of the same prion as FFI (Mastrianni *et al.*, 1999; Moda *et al.*, 2012).

## Materials and methods

### Ethics statement

Brain tissues were obtained at autopsy after receiving written informed consent for research use. Animal experiments were performed in strict accordance with the Regulations for Animal Experiments and Related Activities at Tohoku University. The protocol was approved by the Institutional Animal Care and Use Committees of Tohoku University (2017Mda-81).

### Sources of prion inocula for transmission experiments

Brain homogenates were prepared from patients with FFI with the 129M/M genotype and from patients with sFI. The diagnosis of Creutzfeldt–Jakob disease, the *PRNP* genotype and the PrP<sup>Sc</sup> type was confirmed by immunohistochemistry, *PRNP* sequence analysis and western blot analysis, respectively (Kitamoto *et al.*, 1992, 1993). The subtyping of Creutzfeldt–Jakob disease was carried out according to the classification by Parchi *et al.* (1999).

### Transmission experiments

Knock-in mice carrying human PrP with the 129M/M or 129V/V, Ki-Bank mice and Ki-ChM mice were produced as described previously (Kitamoto *et al.*, 1996, 2002; Asano *et al.*, 2006; Kobayashi *et al.*, 2007, 2019b). Inoculated mice were sacrificed after the onset of clinical disease. One hemisphere of the brain was immediately frozen for western blotting, and the other hemisphere was fixed in 10% buffered formalin for immunohistochemistry.

## Immunohistochemistry

Immunohistochemistry of mouse brain tissues was performed as described previously (Kobayashi *et al.*, 2019b). The anti-PrP antiserum PrP-N was used as the primary antibody (Kitamoto *et al.*, 1991). Goat-anti-rabbit immunoglobulin polyclonal antibody labelled with the peroxidase-conjugated dextran polymer, EnVision+ (Dako), was used as the secondary antibody.

## Western blotting analysis

PrP<sup>Sc</sup> was extracted from brains with collagenase treatment as described previously with some modifications (Grathwohl *et al.*, 1996). The protease-resistant core of PrP<sup>Sc</sup> of the samples was subjected to SDS–PAGE and western blotting. Anti-PrP monoclonal antibodies 3F4 (Signet, Dedham, MA, USA) or SAF83 (Bertin Pharma) were used as the primary antibodies. Anti-mouse or Anti-rabbit EnVision+ was used as the secondary antibody.

## Cell-PMCA procedures

Human brain homogenates from patients with sCJD (MM1, MV1, MM2, MV2, VV1 and VV2) or FFI were seeded. Cell lysates as substrate from FreeStyle 293F cells (Invitrogen) expressing human PrP<sup>C</sup> with methionine at codon 129 as a substrate or human brain homogenates as seed for cell-PMCA were prepared as previously described (Takeuchi *et al.*, 2016), with some modifications. The cell-PMCA methods are described in detail in the Supplementary material.

## Data availability

The data that support the findings of this study are available from the corresponding author upon reasonable request.

## Results

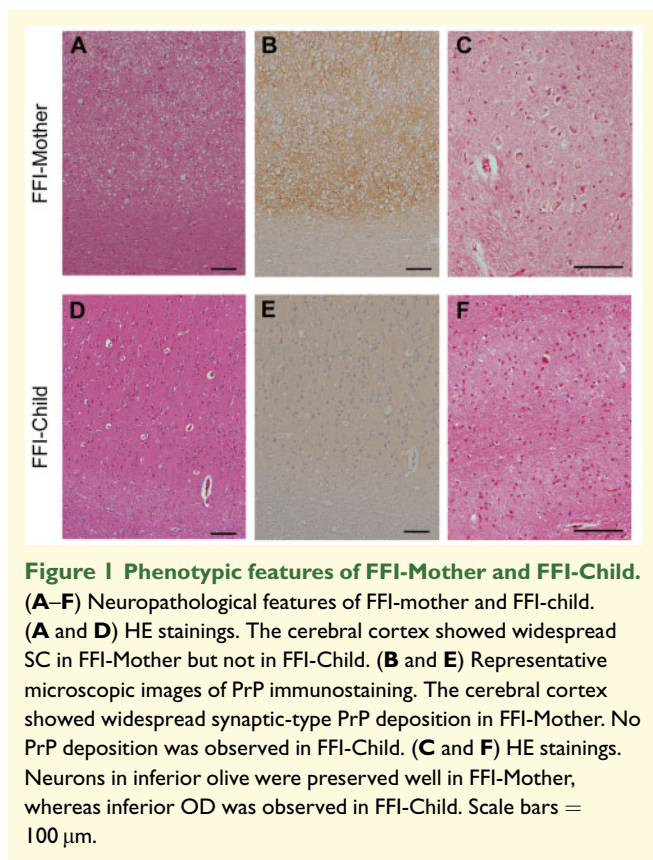
### Neuropathological findings of the fatal familial insomnia kindred and sFI

We analysed the neuropathology of the Japanese FFI kindred with the 129M/M genotype. Details of the clinical features and post-mortem studies of the two patients have been described elsewhere (Saitoh *et al.*, 2010), and the clinical details are re-summarized in Table 1. Briefly, FFI-Mother was the biological mother of FFI-Child and she presented atypical phenotypic features of FFI, but FFI-Child showed a typical FFI phenotype. SC throughout the cerebral cortex and synaptic pattern of PrP deposition were observed in the brain of FFI-Mother, whereas neuronal loss and gliosis in the thalamus and inferior olive were not observed (Fig. 1A–C). FFI-Child

**Table 1 Clinical details of the FFI kindred<sup>a</sup>**

	FFI-Mother	FFI-Child
Clinical manifestations	Onset at 60 years Rapidly progressive dementia, becoming mute at 5 months after onset Sleep disturbance (–) Akinetic mutism (+) Total clinical duration: 14 months	Onset at 54 years Dysphagia and loss of appetite as an initial symptom Followed by insomnia and hypersomnolence, diplopia, ataxic gait and impotence Akinetic mutism (–) Total clinical duration: 13 months
Neurological examinations	2 months after onset Severe memory disturbance, rigidity and brisk deep tendon reflexes No cerebellar ataxia PSD (–) in EEG	7 months after onset Mild memory disturbance, cerebellar ataxia, brisk deep tendon reflexes Loss of deep sleep and marked reduction of REM sleep in polysomnography PSD (–) in EEG

<sup>a</sup>Clinical details of these patients have been reported elsewhere (Saitoh et al., 2010).



exhibited a severe neuronal loss in the inferior olive without SC or PrP deposition (Fig. 1D–F). In western blotting with tissues from the frontal cortex, discrimination between FFI-Mother PrP<sup>Sc</sup> and FFI-Child PrP<sup>Sc</sup> was rather difficult because both of them were type 2 PrP<sup>Sc</sup> with a di-glycoform dominant pattern, but the amount of PrP<sup>Sc</sup> from the frontal cortex of FFI-Mother was ~70 times greater than that of FFI-Child (Supplementary Fig. 1). We also analysed the neuropathological features of two additional Japanese FFI cases, FFI-I37 and FFI-I75 (Table 2). Both FFI-I37 and FFI-I75 showed spotty SC in

addition to severe neuronal loss in the inferior olive. It was previously reported that neuropathological findings with a combination of SC and neuronal loss in the inferior olive are observed in patients with typical FFI (Parchi et al., 1995).

We also analysed the neuropathology of 10 cases of sFI based on SC and OD (Table 2). Eight of the 10 cases of sFI showed various ranges of SC in the brains, such as spotty (lesion is usually within 1 mm<sup>2</sup>), partial (lesion spreads beyond gyrus or involves all cortical layers) or widespread (lesion spreads beyond one lobe) in addition to the remarkable atrophy in the inferior olive (Table 2). sFI-I48 was previously described as the MM2-thalamic form with widespread cortical pathology (Hirose et al., 2006), and sFI-T00/06 showing partial SC was previously reported as a thalamic variant of sCJD with severe brain atrophy and plaque-like PrP deposition (Yamashita et al., 2001). These results demonstrated that the combination of SC and OD was also commonly observed in the brains of patients with sFI, as previously reported (Abu-Rumeileh et al., 2018).

## Transmission studies of the FFI kindred and sFI

We carried out transmission studies using knock-in mice and inocula from the FFI kindred and three cases of sFI. Although neither FFI-Mother prion nor FFI-Child prion was transmissible to Ki-Hu129M/M mice or Ki-Hu129V/V mice, a difference in the transmissibility was observed between FFI-Mother and FFI-Child (Table 3 and Fig. 2) when Ki-Bank or Ki-ChM mice were used as recipients. FFI-Mother prion was successfully transmitted to Ki-Bank mice (Ki-Bank [FFI-Mother]), and PrP deposition in the brains was observed by immunohistochemistry, but the inoculated Ki-ChM mice did not develop the disease (Fig. 2). In contrast, FFI-Child prion was successfully transmitted to Ki-ChM mice (Ki-ChM [FFI-Child]) instead of Ki-Bank mice (Fig. 2). Western blot analysis revealed that the molecular weight of the accumulated

**Table 2** Histopathological findings in the brains and amplification with cell-PMCA of patients with FFI and sFI

Case number	PRNP genotype	Histopathology		Amplification with cell-PMCA <sup>b</sup>	Reference
		OD [number of neurons in the olivary nucleus/mm <sup>2</sup> (mean ± SEM)] <sup>a</sup>	Spongiform changes		
FFI-Mother	129M/M 219E/E D178N	Negative (55.1 ± 15.9)	+++	Negative	Saitoh <i>et al.</i> (2010)
FFI-Child		Positive (11.8 ± 2.8)	–	Positive	
FFI-I37		Positive (4.5 ± 6.5)	+	Positive	
FFI-I75		Positive (0.3 ± 0.8)	+	Positive	
sFI-H91		Positive (2.2 ± 1.2)	+	Positive	Kawasaki <i>et al.</i> (1997)
sFI-I110		Positive (1.2 ± 1.1)	+	Positive	
sFI-T00/06		Positive (7.0 ± 7.3)	++	Positive	Yamashita <i>et al.</i> (2001)
sFI-I48		Positive (0.6 ± 0.8)	+++	Positive	
sFI-J86		Positive (5.0 ± 3.9)	–	Positive	Hirose <i>et al.</i> (2006)
sFI-H10		Positive (0)	+	Positive	
sFI-H94		Positive (1.2 ± 1.2)	+	Positive	
sFI-J93		Positive (2.7 ± 3.1)	+	Positive	
sFI-I43		Positive (1.8 ± 2.0)	+++	Positive	
sFI-J99		Positive (6.8 ± 3.1)	–	Positive	

–, absent; +, spotty (lesion is usually within 1 mm<sup>2</sup>); ++, partial (lesion spreads beyond gyrus or involves all cortical layers); +++, widespread (lesion spreads beyond one lobe).

<sup>a</sup>The average and standard deviation of the number of neurons at each of 5 places/mm<sup>2</sup> in the inferior olive.

<sup>b</sup>The cases were described as positive if the brain samples with 10<sup>-3</sup>-fold dilution could be amplified using this PMCA method.

**Table 3** Transmission of FFI or sFI to multiple knock-in mice lines

Inoculum <sup>a</sup>	Knock-in mice line	Attack rate (n/n <sup>0</sup> )	Mean incubation period (days ± SEM)
FFI-Mother	Ki-Hu129M/M	0/6	~1037
	Ki-Hu129V/V	0/5	~998
	Ki-ChM	0/5	~907
	Ki-Bank	6/7	454 ± 104
FFI-Child	Ki-Hu129M/M	0/6	~886
	Ki-Hu129V/V	0/6	~767
	Ki-ChM	5/6	502 ± 133
	Ki-Bank	0/5	~903
sFI-H91	Ki-Hu129M/M	0/3	~806
	Ki-Hu129V/V	0/6	~799
	Ki-ChM	4/5	342 ± 25
	Ki-Bank	0/6	~803
sFI-I110	Ki-Hu129M/M	0/4	~752
	Ki-Hu129V/V	0/4	~722
	Ki-ChM	3/6	394 ± 23
	Ki-Bank	0/5	~770
sFI-T00/06	Ki-Hu129M/M	0/6	~907
	Ki-Hu129V/V	0/4	~661
	Ki-ChM	5/6	572 ± 135
	Ki-Bank	2/7	690, 707

n: number of positive mice; n<sup>0</sup>: number of inoculated mice.

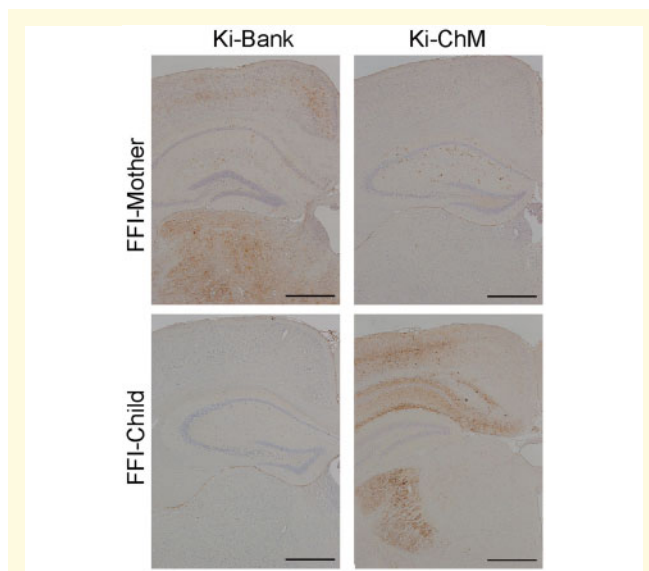
<sup>a</sup>Intracerebral inoculation with 20 µl of a 10% (w/v) brain homogenate from either of the patients with FFI or sFI.

PrP<sup>Sc</sup> in the brains of Ki-Bank [FFI-Mother] or Ki-ChM [FFI-Child] was smaller than that of the PrP<sup>Sc</sup> in the Ki-Bank or Ki-ChM mice inoculated with sCJD-MM1 prions, consistent with type 2 PrP<sup>Sc</sup> (Supplementary Fig. 2A). The distinct differences in transmissibility between FFI-Mother and FFI-Child strongly suggested that two different prions were associated with the phenotypic variability among patients with the 129M-D178N mutation.

We analysed the transmission properties of three cases of sFI, such as sFI-H91 (spotty SC) (Kawasaki *et al.*, 1997), sFI-T00/06 (partial SC) and sFI-I110 (spotty SC) (Table 2). The transmissibility of each sFI case is shown in Table 3. Similar to FFI-Child prion, sFI-H91, sFI-I110 and sFI-T00/06 prions transmitted to Ki-ChM mice successfully and type 2 prions were accumulated in the brains of the infected mice (Supplementary Fig. 2B). Interestingly, sFI-T00/06 prion was also transmitted to two of the seven inoculated Ki-Bank mice (Table 3 and Supplementary Fig. 2B), whereas Ki-Bank mice inoculated with brain homogenates from sFI-H91 or sFI-I110 did not develop the disease. Successful transmission of sFI-T00/06 prion to both Ki-Bank mice and Ki-ChM mice correlated with the sFI-T00/06 pathology with a relatively prominent SC in addition to OD, whereas sFI-H91 and sFI-I110 had only spotty SC in a limited area.

### Protein misfolding cyclic amplification of FFI and sFI

We performed cell-PMCA of prions from FFI and sFI cases using substrate lysates prepared from 129M human PrP-expressing 293F cells to compare the amplification properties between FFI-Mother prion and FFI-Child prion (Table 2). FFI-Child prion could be amplified significantly, and strong signals were detected with up to a 10<sup>-4</sup>-fold dilution, whereas a slight amplification was observed only from a 10<sup>-2</sup>-fold dilution when FFI-Mother prion was used as the seed (Supplementary Fig. 3A). Interestingly, prions from both FFI-I37 and FFI-I75 amplified efficiently even at a 10<sup>-4</sup>-fold dilution. These results revealed that the



**Figure 2 Transmission studies. Immunohistochemical analysis of the brains from the inoculated mice with the FFI kindred.** Transmission of FFI-Mother's sample was successful in Ki-Bank mice but not in Ki-ChM mice. Positive PrP stainings were observed mainly in the cerebral cortex and thalamus of Ki-Bank mice. Transmission of FFI-Child's sample was successful in Ki-ChM mice but not in Ki-Bank mice. Positive PrP stainings were observed mainly in the cerebral cortex, hippocampus and lateral geniculate body of the Ki-ChM mice. Scale bars = 500  $\mu$ m.

amplification efficiency was also different between the atypical FFI prion and typical FFI prions in this cell-PMCA condition.

Since it appeared that OD in a typical FFI phenotype would be coupled with efficient amplification, we also carried out cell-PMCA in the 10 sFI cases. Similar to the typical FFI cases, significant amplification was detected from all 10 cases of sFI (Table 2 and Supplementary Fig. 3B), which revealed that prions associated with OD, namely M2T prions, were specifically amplified. To confirm the reliability for the detection of M2T with cell-PMCA, we examined 115 samples with all subtypes of sCJD and non-Creutzfeldt–Jakob disease. No significant signal of the amplified products from sCJD-MM1, sCJD-MM2C (Supplementary Fig. 3B), other sCJD subtypes without OD (data not shown) or non-Creutzfeldt–Jakob disease (data not shown) was observed.

## Discussion

In this study, we have demonstrated that one FFI case with an atypical phenotype is likely caused by a prion strain that is distinct from that associated with typical FFI cases, using two independent methodologies, animal transmission studies and cell-PMCA. Furthermore, it appeared that the atypical prion might exist in sFI.

**Table 4 Previous reports of the experimental transmission of FFI and sFI using a mouse model**

Inocula	Number of patients (successful transmission)	Recipient	Reference
FFI	1	Wild-type NZW mice	Tateishi et al. (1995)
FFI	2	Tg (human PrP129M) mice	Collinge et al. (1995)
FFI	3 <sup>a</sup>	Tg (human/mouse PrP chimera) <sup>b</sup> mice	Telling et al. (1996)
sFI	1	Tg (human/mouse PrP chimera) <sup>b</sup> mice	Mastrianni et al. (1999)
FFI	1 <sup>c</sup>	Wild-type NZW mice Tg (hamster PrP) mice	Sasaki et al. (2005)
sFI	1 <sup>d</sup>	Ki (human PrP129MM) mice	Moda et al. (2012)

<sup>a</sup>Three of the four patients with FFI were transmitted to Tg mice. The inoculated Tg mice with one patient with FFI with SC and OD did not develop the disease after 350 days post-inoculation.

<sup>b</sup>The Tg mice have the same PrP sequence of Ki-ChM mice.

<sup>c</sup>This case has widespread SC and OD.

<sup>d</sup>This case has widespread SC; however, OD has not been described.

## Reasons why two distinctive prions have detected in fatal familial insomnia or sFI

The transmission properties of FFI or sFI using transgenic mice were demonstrated in several laboratories (Table 4). However, previous studies might have missed the full extent of prion strain diversity in patients carrying the D178N-129M haplotype because the results were obtained by limited transmission experiments using a single transgenic mouse line or only one patient. In this study, we performed transmission studies using multiple knock-in mouse lines (Ki-humanized mice, Ki-Bank mice and Ki-ChM mice) and samples from an FFI kindred carrying the 129M/M genotype showing two distinct clinicopathological features. Notably, we showed that the atypical FFI phenotype without thalamic/olivary is associated with a different prion, indicating that two distinct prions were generated by the same mutation and *PRNP* haplotype in this kindred. In addition, the successful transmission of one patient with sFI to both Ki-ChM and Ki-Bank mice suggested that two distinct prions were associated with the sporadic form.

## Experimental transmission using knock-in mice

In the present study, prions from typical FFI or sFI with OD successfully transmitted to Ki-ChM mice expressing human-mouse chimeric PrP<sup>C</sup>, whereas none of the inoculated Ki-Hu129M/M mice or Ki-Hu129V/V mice developed the disease. To our knowledge, the successful transmission of only one sCJD-MM2T case to Ki-

Hu129M/M mice was reported by [Moda et al. \(2012\)](#) (Table 4), which is not consistent with our transmission data in typical FFI or sFI. Because M2T prions may preferentially accumulate in the thalamus, it is possible that the amount of PrP<sup>Sc</sup> in our inoculum from the cerebral cortex might have been insufficient to cause infection. To confirm the infectivity of M2T prion to Ki-Hu129M/M mice, a secondary passage will also be needed in the future. Nevertheless, it was clarified that Ki-ChM mice were more susceptible to M2T prions than Ki-Hu129M/M mice when the same dose of inoculum was used. At present, experimental transmission using Ki mice instead of Tg mice would be suitable for identifying prion strains. Ki mice carrying different *PRNP* genes but expressing the same level of PrP<sup>C</sup> allow analysing the susceptibility to each prion strain based only on the length of the incubation period. MMiK prion among patients with dura mater graft-associated Creutzfeldt–Jakob disease with the 129M/M genotype were successfully transmitted to Ki-Hu129V/V mice with a shorter incubation period than Ki-129M/M mice ([Kobayashi et al., 2007](#)). The incubation periods of the mice inoculated with MMiK prion were the same as those of mice inoculated with sCJD-VV2 prions, which revealed that MMiK prion was identical to V2 prion ([Kobayashi et al., 2009, 2010](#)). It would not be appropriate to use Tg mice to evaluate the susceptibility to prion strains by comparing the length of the incubation period, because the incubation period is significantly affected by the variable expression levels of PrP<sup>C</sup> in Tg mice. For example, Tg-Bank mice with the M109 genotype in addition to the I109 genotype spontaneously developed the disease, whereas Ki-Bank mice did not ([Kobayashi et al., 2019b](#)), which makes Ki-Bank mice more suitable to prove the prion infectivity than Tg-Bank mice. In the present study, typical FFI or sFI prions were successfully transmitted to Ki-ChM mice but not to Ki-Bank mice. However, the atypical FFI case with SC and the sFI case with SC were successfully transmitted to Ki-Bank mice. A previous study reported the successful transmission of a sCJD-MM2 case with bank voles ([Nonno et al., 2006](#)). It will be necessary to investigate the presence of OD or SC pathology in this case.

### Diagnosis of FFI or sFI according to pathological finding in the inferior olivary nucleus

Neuronal loss or degeneration in the dorsomedial thalamic nucleus or the inferior olivary nucleus has been adopted as neuropathological hallmark for FFI or sFI ([Lugaresi et al., 1986](#); [Parchi et al., 1999](#)). However, we consider OD, the most important neuropathological finding for the diagnosis of the disease. Relatively severe neuronal loss in the medial thalamus is also seen in the brains of patients with sCJD-MM1 after a long-term illness (>15 months), while the number of neurons in the

inferior olive or the lateral thalamus is largely preserved irrespectively of the disease duration ([Kobayashi et al., 2019a](#)). Accordingly, [Kobayashi et al.](#) have recently reported that, in cases of sCJD-MM1 with MM2T pathology, neuronal loss in the inferior olivary nucleus rather than in the medial thalamus is more specific for FFI or sFI. Thereby, we propose that the diagnosis of FFI or sFI could be readily achieved based on the neuropathological findings of both thalamic and olivary atrophy. Because cell-PMCA could amplify the M2T prion selectively from the brains even in the presence of co-occurring M1 or M2C prions (or both) ([Takeuchi et al.](#), unpublished data), this cell-PMCA may also be useful for the detection of M2T prion in addition to the neuropathological findings in the inferior olivary nucleus.

### Addressing unresolved issues in FFI or sFI

By providing evidence for the existence of two distinct prions associated with the pathological variability of patients with FFI, our study helps to explain unresolved issues in FFI. It has been reported that there are patients with FFI who exhibit multiple and mixed clinical symptoms of both FFI and Creutzfeldt–Jakob disease ([Zarranz et al., 2005](#); [Synofzik et al., 2009](#); [Chen et al., 2018](#)) and that patients with FFI also show significant neuropathological phenotypic variability ([Manetto et al., 1992](#); [McLean et al., 1997](#); [Yamashita et al., 2001](#); [Sasaki et al., 2005](#)). The genotype at codon 129 in the non-mutated allele is known to affect the clinical and pathological features in FFI. It has been reported that significant SC in the cerebral cortex characterize a number of patients with FFI with the 129 methionine/valine genotype because of their longer survival ([Parchi et al., 1995, 1998b](#)). However, the coexistence of typical and atypical prions might also be associated with unusual clinical and pathological features in patients with FFI irrespectively of the effect of disease duration.

Furthermore, it is unknown why a lower amount of PrP<sup>Sc</sup> in the thalamus than in other parts of the brain causes remarkable thalamic degeneration in FFI or sFI. It might be difficult to analyse accurately the distribution of M2T prion if a larger amount of atypical prions coexist in the brain. The actual distribution of M2T prion in the brain will only be revealed by a specific quantitative analysis.

It is still uncertain why the distinctive prion strain appeared only in a single case (i.e. the present case), given that, to date, other atypical FFI cases have not been demonstrated. However, it has been reported worldwide that there are large, genetically identified FFI pedigrees in which patients showing heterogeneous phenotypic features have appeared. In the future, it will be necessary to perform a detailed genetic analysis and also search for environmental factors or pathological



**Table 5 A new classification of sCJD-MM2**

Current classification	Pathological change	PrP immunostain	PMCA	Transmission	Proposed classification	Prion
MM2T	Thalamic degeneration/OD	negative	Positive	Ki-ChM (+) Ki-Bank (–)	MM2T	M2T
MM2C	Large vacuolation	Perivacuolar PrP deposits	Negative	Ki-ChM (–) Ki-Bank (+)	MM2C (lv)	M2C (lv)
Newly identified	Spongiform changes (small vacuolation)	Synaptic PrP deposits	Negative	Ki-ChM (–) Ki-Bank (+)	MM2C <sup>a</sup> (sv)	M2C (sv)

<sup>a</sup>At the beginning of this study, we detected SC in MM2T patients. However, the SC were mainly in the cerebral cortex. Therefore, an atypical type 2 prion associated with spongiform change is classified as MM2C (sv).

changes that influence the clinicopathological course in such large FFI pedigrees.

In inherited prion diseases, phenotypic variability has also been reported in Gerstmann–Sträussler–Scheinker disease linked to the P102L mutation. Two distinct pathological phenotypes were observed in patients with the P102L genotype; one with both SC and amyloid plaques and the other without SC (Parchi *et al.*, 1998a; Piccardo *et al.*, 1998). The Gerstmann–Sträussler–Scheinker P102L mutation generates two different types of abnormal PrP<sup>Sc</sup> fragments of 21 and 8 kDa, respectively. The 21-kDa PrP<sup>Sc</sup> fragment was only seen in the brains with SC, whereas the 8-kDa fragment was seen in all cases (Parchi *et al.*, 1998a; Piccardo *et al.*, 1998). Experimental transmission studies revealed different infectivity between 21- and 8-kDa PrP<sup>Sc</sup> in knock-in mice carrying the 101L/L PrP gene (homologous to codon 102 in humans) (Piccardo *et al.*, 2007). Consequently, two distinct prion strains were associated with phenotypic diversity in Gerstmann–Sträussler–Scheinker P102L. The occurrence of multiple prion strains and phenotypic diversity in subjects carrying the same *PRNP* mutation might be a common feature in inherited prion diseases.

## A new classification of sCJD-MM2

In the present study, we have identified a new type 2 prion associated with typical SC and synaptic PrP deposition. SC and synaptic PrP deposition are considered hallmarks of MM1, the most common Creutzfeldt–Jakob disease phenotype, and are currently used by neuropathologists for the identification of MM1 prion. However, here, we showed that the type 2 prion can also be detected in association with typical SC and synaptic PrP deposition and that the transmission properties of these atypical M2 prions were different from those of the MM1 prion. Interestingly, the atypical type 2 prion did not show any large confluent vacuoles or perivacuolar PrP deposition, which are landmarks of sCJD-MM2C.

The classification of sCJD was established according to codon 129 genotyping, PrP<sup>Sc</sup> typing and the pathological findings (Parchi *et al.*, 1999). We propose revising MM2C as MM2C [large vacuolation (lv)] to distinguish it from MM2C [small vacuolation (sv)] (Table 5). We recently identified an MM2C (sv + lv) case with both widespread SC with synaptic PrP deposition and large confluent vacuoles with perivacuolar PrP staining without

OD (Kitamoto *et al.*, unpublished data), suggesting that there are MM2 cases in which M2T, M2C (lv) or M2C (sv) prions exist independently or in combination.

It is still uncertain whether M2C (sv) prion and M2C (lv) prion differ or not. The sCJD-MM2C (lv) was transmitted successfully to Ki-Bank mice (Kobayashi *et al.*, 2019b) but not to Ki-ChM mice (Korth *et al.*, 2003; Kitamoto *et al.*, unpublished data) and neither M2C (sv) prion nor M2C (lv) prion could be amplified by our cell-PMCA. At present, M2C (sv) prion has not been discriminated from M2C (lv) prion according to the transmissibility or amplification properties. However, Cracco *et al.* (2017) have reported that the biochemical properties of sFI prion were different from those of sCJD-MM2C prion based on a detailed comparative assay of the PrP<sup>Sc</sup> conformer. It would be useful to analyse the biochemical properties of M2C (sv) prion if we can identify a sporadic form of MM2C (sv) without OD.

## Supplementary material

Supplementary material is available at *Brain Communications* online.

## Acknowledgment

We thank H. Kudo, A. Yamazaki, Y. Sasaki and M. Yamamoto for their excellent technical assistance and B. Bell for critical review of the article.

## Funding

This study was supported by Grant-in-Aid for Scientific Research from Japan Society for the Promotion of Science (18H02738, 19K22588, and 19KK0213 to T.K. and 18K07490 to A.T.) and a Grant-in-Aid for Scientific Research on Innovative Areas (Brain Protein Aging and Dementia Control) from Ministry of Education, Culture, Sports, Science and Technology (T.K.). Research for the development of decontamination/disinfection procedures against various sCJD subgroups has been supported by a Grant-in-Aid from the Research Committee of Surveillance and Infection Control of Prion Disease, the Ministry of Health, Labor and Welfare of Japan (T.K.).

## Competing interests

The authors report no competing interests.

## References

- Abu-Rumeileh S, Redaelli V, Baiardi S, Mackenzie G, Windl O, Ritchie DL, et al. Sporadic fatal insomnia in Europe: phenotypic features and diagnostic challenges. *Ann Neurol* 2018; 84: 347–60.
- Asano M, Mohri S, Ironside JW, Ito M, Tamaoki N, Kitamoto T. vCJD prion acquires altered virulence through trans-species infection. *Biochem Biophys Res Commun* 2006; 342: 293–9.
- Chen S, He S, Shi XH, Shen XJ, Liang KK, Zhao JH, et al. The clinical features in Chinese patients with PRNP D178N mutation. *Acta Neurol Scand* 2018; 138: 151–5.
- Collinge J, Palmer MS, Sidle KC, Gowland I, Medori R, Ironside J, et al. Transmission of fatal familial insomnia to laboratory animals. *Lancet* 1995; 346: 569–70.
- Cracco L, Notari S, Cali I, Sy MS, Chen SG, Cohen ML, et al. Novel strain properties distinguishing sporadic prion diseases sharing prion protein genotype and prion type. *Sci Rep* 2017; 7: 38280.
- Goldfarb LG, Haltia M, Brown P, Nieto A, Kovanen J, McCombie WR, et al. New mutation in scrapie amyloid precursor gene (at codon 178) in Finnish Creutzfeldt-Jakob kindred. *Lancet* 1991; 337: 425.
- Goldfarb LG, Petersen RB, Tabaton M, Brown P, LeBlanc AC, Montagna P, et al. Fatal familial insomnia and familial Creutzfeldt-Jakob disease: disease phenotype determined by a DNA polymorphism. *Science* 1992; 258: 806–8.
- Grathwohl KU, Horiuchi M, Ishiguro N, Shinagawa M. Improvement of PrPSc-detection in mouse spleen early at the preclinical stage of scrapie with collagenase-completed tissue homogenization and Sarkosyl-NaCl extraction of PrPSc. *Arch Virol* 1996; 141: 1863–74.
- Hirose K, Iwasaki Y, Izumi M, Yoshida M, Hashizume Y, Kitamoto T, et al. MM2-thalamic-type sporadic Creutzfeldt-Jakob disease with widespread neocortical pathology. *Acta Neuropathol* 2006; 112: 503–11.
- Kawasaki K, Wakabayashi K, Kawakami A, Higuchi M, Kitamoto T, Tsuji S, et al. Thalamic form of Creutzfeldt-Jakob disease or fatal insomnia? Report of a sporadic case with normal prion protein genotype. *Acta Neuropathol* 1997; 93: 317–22.
- Kitamoto T, Mohri S, Ironside JW, Miyoshi I, Tanaka T, Kitamoto N, et al. Follicular dendritic cell of the knock-in mouse provides a new bioassay for human prions. *Biochem Biophys Res Commun* 2002; 294: 280–6.
- Kitamoto T, Muramoto T, Hilbich C, Beyreuther K, Tateishi J. N-terminal sequence of prion protein is also integrated into kuru plaques in patients with Gerstmann-Straussler syndrome. *Brain Res* 1991; 545: 319–21.
- Kitamoto T, Nakamura K, Nakao K, Shibuya S, Shin RW, Gondo Y, et al. Humanized prion protein knock-in by Cre-induced site-specific recombination in the mouse. *Biochem Biophys Res Commun* 1996; 222: 742–7.
- Kitamoto T, Ohta M, Doh-Ura K, Hitoshi S, Terao Y, Tateishi J. Novel missense variants of prion protein in Creutzfeldt-Jakob disease or Gerstmann-Straussler syndrome. *Biochem Biophys Res Commun* 1993; 191: 709–14.
- Kitamoto T, Shin RW, Doh-Ura K, Tomokane N, Miyazono M, Muramoto T, et al. Abnormal isoform of prion proteins accumulates in the synaptic structures of the central nervous system in patients with Creutzfeldt-Jakob disease. *Am J Pathol* 1992; 140: 1285–94.
- Kobayashi A, Asano M, Mohri S, Kitamoto T. Cross-sequence transmission of sporadic Creutzfeldt-Jakob disease creates a new prion strain. *J Biol Chem* 2007; 282: 30022–8.
- Kobayashi A, Asano M, Mohri S, Kitamoto T. A traceback phenomenon can reveal the origin of prion infection. *Neuropathology* 2009; 29: 619–24.
- Kobayashi A, Iwasaki Y, Takao M, Saito Y, Iwaki T, Qi Z, et al. A novel combination of prion strain co-occurrence in patients with sporadic Creutzfeldt-Jakob disease. *Am J Pathol* 2019a; 189: 1276–83.
- Kobayashi A, Matsuura Y, Takeuchi A, Yamada M, Miyoshi I, Mohri S, et al. A domain responsible for spontaneous conversion of bank vole prion protein. *Brain Pathol* 2019b; 29: 155–63.
- Kobayashi A, Sakuma N, Matsuura Y, Mohri S, Aguzzi A, Kitamoto T. Experimental verification of a traceback phenomenon in prion infection. *J Virol* 2010; 84: 3230–8.
- Korth C, Kaneko K, Groth D, Heye N, Telling G, Mastrianni J, et al. Abbreviated incubation times for human prions in mice expressing a chimeric mouse-human prion protein transgene. *Proc Natl Acad Sci USA* 2003; 100: 4784–9.
- Lugaresi E, Medori R, Montagna P, Baruzzi A, Cortelli P, Lugaresi A, et al. Fatal familial insomnia and dysautonomia with selective degeneration of thalamic nuclei. *N Engl J Med* 1986; 315: 997–1003.
- Manetto V, Medori R, Cortelli P, Montagna P, Tinuper P, Baruzzi A, et al. Fatal familial insomnia: clinical and pathologic study of five new cases. *Neurology* 1992; 42: 312–9.
- Mastrianni JA, Nixon R, Layzer R, Telling GC, Han D, DeArmond SJ, et al. Prion protein conformation in a patient with sporadic fatal insomnia. *N Engl J Med* 1999; 340: 1630–8.
- McLean CA, Storey E, Gardner RJ, Tannenber AE, Cervenakova L, Brown P. The D178N (cis-129M) “fatal familial insomnia” mutation associated with diverse clinicopathologic phenotypes in an Australian kindred. *Neurology* 1997; 49: 552–8.
- Medori R, Tritschler HJ, LeBlanc A, Villare F, Manetto V, Chen HY, et al. Fatal familial insomnia, a prion disease with a mutation at codon 178 of the prion protein gene. *N Engl J Med* 1992; 326: 444–9.
- Moda F, Suardi S, Di Fede G, Indaco A, Limido L, Vimercati C, et al. MM2-thalamic Creutzfeldt-Jakob disease: neuropathological, biochemical and transmission studies identify a distinctive prion strain. *Brain Pathol* 2012; 22: 662–9.
- Nonno R, Di Bari MA, Cardone F, Vaccari G, Fazzi P, Dell’Omo G, et al. Efficient transmission and characterization of Creutzfeldt-Jakob disease strains in bank voles. *PLoS Pathog* 2006; 2: e12.
- Parchi P, Castellani R, Cortelli P, Montagna P, Chen SG, Petersen RB, et al. Regional distribution of protease-resistant prion protein in fatal familial insomnia. *Ann Neurol* 1995; 38: 21–9.
- Parchi P, Chen SG, Brown P, Zou W, Capellari S, Budka H, et al. Different patterns of truncated prion protein fragments correlate with distinct phenotypes in P102L Gerstmann-Sträussler-Scheinker disease. *Proc Natl Acad Sci USA* 1998a; 95: 8322–7.
- Parchi P, Giese A, Capellari S, Brown P, Schulz Schaeffer W, Windl O, et al. Classification of sporadic Creutzfeldt-Jakob disease based on molecular and phenotypic analysis of 300 subjects. *Ann Neurol* 1999; 46: 224–33.
- Parchi P, Petersen RB, Chen SG, Autilio-Gambetti L, Capellari S, Monari L, et al. Molecular pathology of fatal familial insomnia. *Brain Pathol* 1998b; 8: 539–48.
- Piccardo P, Dlouhy SR, Lievens PM, Young K, Bird TD, Nochlin D, et al. Phenotypic variability of Gerstmann-Straussler-Scheinker disease is associated with prion protein heterogeneity. *J Neuropathol Exp Neurol* 1998; 57: 979–88.
- Piccardo P, Manson JC, King D, Ghetti B, Barron RM. Accumulation of prion protein in the brain that is not associated with transmissible disease. *Proc Natl Acad Sci USA* 2007; 104: 4712–7.
- Saitoh Y, Ogawa M, Naito Y, Komatsuzaki Y, Tagaya H, Arima K, et al. Discordant clinicopathologic phenotypes in a Japanese kindred of fatal familial insomnia. *Neurology* 2010; 74: 86–9.
- Sasaki K, Doh-Ura K, Wakisaka Y, Tomoda H, Iwaki T. Fatal familial insomnia with an unusual prion protein deposition pattern: an autopsy report with an experimental transmission study. *Neuropathol Appl Neurobiol* 2005; 31: 80–7.
- Synofzik M, Bauer P, Schols L. Prion mutation D178N with highly variable disease onset and phenotype. *J Neurol Neurosurg Psychiatry* 2009; 80: 345–6.

- Taguchi Y, Mohri S, Ironside JW, Muramoto T, Kitamoto T. Humanized knock-in mice expressing chimeric prion protein showed varied susceptibility to different human prions. *Am J Pathol* 2003; 163: 2585–93.
- Takeuchi A, Kobayashi A, Parchi P, Yamada M, Morita M, Uno S, et al. Distinctive properties of plaque-type dura mater graft-associated Creutzfeldt-Jakob disease in cell-protein misfolding cyclic amplification. *Lab Invest* 2016; 96: 581–7.
- Tateishi J, Brown P, Kitamoto T, Hoque ZM, Roos R, Wollman R, et al. First experimental transmission of fatal familial insomnia. *Nature* 1995; 376: 434–5.
- Telling GC, Parchi P, DeArmond SJ, Cortelli P, Montagna P, Gabizon R, et al. Evidence for the conformation of the pathologic isoform of the prion protein enciphering and propagating prion diversity. *Science* 1996; 274: 2079–82.
- Yamashita M, Yamamoto T, Nishinaka K, Udaka F, Kameyama M, Kitamoto T. Severe brain atrophy in a case of thalamic variant of sporadic CJD with plaque-like PrP deposition. *Neuropathology* 2001; 21: 138–43.
- Zarranz JJ, Digen A, Atares B, Rodriguez-Martinez AB, Arce A, Carrera N, et al. Phenotypic variability in familial prion diseases due to the D178N mutation. *J Neurol Neurosurg Psychiatry* 2005; 76: 1491–6.